MALOCCLUSION RELATED TO PRIMARY CLOSURE OF THE ANTERIOR PALATE IN COMPLETE CLEFT LIP AND PALATE PATIENTS

C. K. CHAN. B.D.S.

A Thesis submitted in partial requirement
for the degree of
MASTER OF DENTAL SCIENCE

Department of Preventive Dentistry
Faculty of Dentistry
University of Sydney
1988

ACKNOWLEDGEMENTS

The author would like to express her gratitude to all the people who assisted with the preparation of this thesis especially to;-

Associate Professor Keith Godfrey, Department of Preventive Dentistry who gave valuable advice and his expert guidance in the field of cleft palate treatment and who supervised the preparation of this thesis.

Drs. D. Dey and P.G. Thompson, plastic surgeons at the Royal Alexandra Hospital for Children, for permission to use their patients in this study.

Drs. I. Bomba, D.J. Bradley, J.H. Chapman, S.M. Chapman, R. Cerny, R. Fox, J.K. Hawkins, R.G. Henry, B. Kerr, W.J. Mackie, R.J. Masson, R.Y. Norton, K.R. Powell, J.F. Reading and P.J. Taylor, orthodontists, for allowing me access to their patients' study models.

M. Angel and A. Lyon of the Speech Pathology Department and K.Lucas of the Dental Department of the Royal Alexandra Hospital for Children for access to the medical and dental records of the patients used in this study.

Mrs J. Thwaite, Mrs K. Daniels and Mrs J. Jeffreys, Faculty librarians and my sister, Ming, for their assistance with the library research for this thesis.

Drs C. Vasseleu and D. Lake, my colleagues and my father for their advice and help in the preparation of illustrative material for this thesis.

Drs. R.J. Masson, W.L. Scully, P.G. Hardman, I.B. Patrick and B.J. Spark for their help and encouragement and the use of their secretarial staff especially Mrs A. Swindale in the typing of this thesis.

The study subjects and their parents who "collaborated most willingly and made the study possible"

TABLE OF CONTENTS

LIST OF FIGURES AND TABLES

INTRODUCTION

(A) AIMS OF TREATMENT OF CLEFT LIP AND PALATE PATIENTS

The main aims of treatment in cleft lip and palate patients are:

1) to obtain readily understood speech,
2) to produce an acceptable appearance,
3) to rehabilitate the mouth to enable the child to have a good functional dental occlusion. (C.P.C. RAHC)*

To obtain understandable speech, the surgeon has to create a long, flexible soft palate which is able to close off the orophanynx from the nasopharynx efficiently and leave no fistulous passages along the cleft line between the mouth and nose. The lip and nose have to be repaired for function and aesthetics. A good dental occlusion has to be established for speech aesthetics and mastication. Problems of middle ear function may also affect the cleft palate child in particular but are not of direct concern in this present study, apart from the possible relationship with the timing of palate repair (See Chapter 3(A)). It is important to have a clear idea of the relative

*C.P.C., RAHC - Cleft Palate Clinic, Royal Alexandra Hospital for Children.

importance of these three aims because while they are to some extent dependent on each other, the achievement of one may lessen the chances of achieving another, so some compromises have to be made. The above aims are considered to be in their correct order of priority by many treatment centres thoughout the world today. The first two aims have largely been achieved by centres thoughout the world as well as here at the Royal Alexandra Hospital for children in Sydney and this study is concerned with achieving part of the third aim of cleft treatment.

(B) AIM OF THIS STUDY

The patient with a repaired complete unilateral or bilateral cleft of the lip and palate has a number of dental as well as orthodontic problems, such as abnormalities of tooth development resulting in missing teeth, supernumeraries and malformed teeth; malpositioned and rotated upper anterior teeth (due to the lack of room in the premaxillary region), and a high incidence of crossbite malocclusion (due to collapsed maxillary buccal segments, varying degrees of maxillary hypoplasia and other causes.) (Dahl and Hanusardottir 1979, Shaw, 1979).

This study is concerned with the orthodontic problem of medial collapse of the maxillary buccal segments and the resultant crossbite malocclusion found in many complete

cleft lip and palate patients. The first part of the literature review will discuss the factors contributing to this collapse and the development of the crossbite malocclusion. The next part will then look at different ways surgery and orthodontics can be used to prevent or treat the collapsed maxillary arches and resultant crossbite malocclusions. These include:

1) modifying the timing of surgical treatment;
2) the use of early maxillary orthopaedics to place or maintain the segments in optimal position;
3) the use of two-layered soft tissue flap closures to minimize scar tissue formation and as a spacer in the alveolar cleft region;
4) the use of bone grafts to maintain an intact arch form;
5) the use of periosteoplasty to induce bone formation in the alveolar cleft region.

Collapse of the maxillary buccal segments and other maxillary deformities can be reflected in the arch form and occlusion in the form of crossbites - unilateral, bilateral, anterior and posterior. Chapter 4 will look at the different ways used by others to assess arch collapse. This study will use the Huddart and Bodenham (1972) form of crossbite assessment to evaluate the effects of treatment on the maxilla and the dental occlusion.

The aim of this study is to investigate the effects of a triangular labial flap (Dey 1974) on the occlusion and maxillary development of a group of complete unilateral and bilateral cleft lip and palate patients. This bulky labial flap is placed in the alveolar cleft at the time of the primary repair of the lip and anterior palate to restrict or prevent medial rotation and collapse of the buccal segments which tends to occur after lip repair. This flap is also used to reinforce closure of the nasal floor thus preventing the laying down of unwanted scar tissue and subsequent fistulae occurring in this region. It was also perceived to maintain the correct labio-lingual relationships between the upper and lower incisor teeth. (Throughout the thesis, this flap will be known as the Dey triangular flap).

The hypothesis of this study is that the Dey triangular flap helps to reduce medial rotation and collapse of the alveolar segments and to maintain the upper and lower incisor teeth in their correct labio-lingual relationships, thereby decreasing the incidence of crossbites occurring in the complete cleft lip and palate patient.

CHAPTER 1

THE ORTHODONTIC PROBLEM

A) ORIGINAL CONDITION (prior surgery)

A complete cleft of the lip and palate is the severest form of oral clefting. It is a cleft which extends right through the lip, alveolus, hard and soft palate antero-posteriorly, and in the vertical plane, it extends from the roof of the oral cavity up to the nostril opening and floor of the nasal cavity. The cleft can be unilateral or bilateral. A complete unilateral or bilateral cleft of the lip, alveolus and palate occurs in about 1 in 1600 births (Huddart 1967(A)). The aetiology of cleft lip and palate is multi-factorial. It appears to be determined by a genetic predisposition involving several genes as well as certain environmental factors prevailing around the time of facial development. (Ross and Johnston 1972).

The cleft deformity is established in the first six to eight weeks of intra-uterine life. Embryologically, two developmental causes have been postulated:

1) A failure of fusion of the maxillary processes with the nasal processes (the classical theory of Dursy and His) (Stark 1954) or;

2) A failure of the mesoderm (which is thought to be deficient) to penetrate into the epithelial membranes of

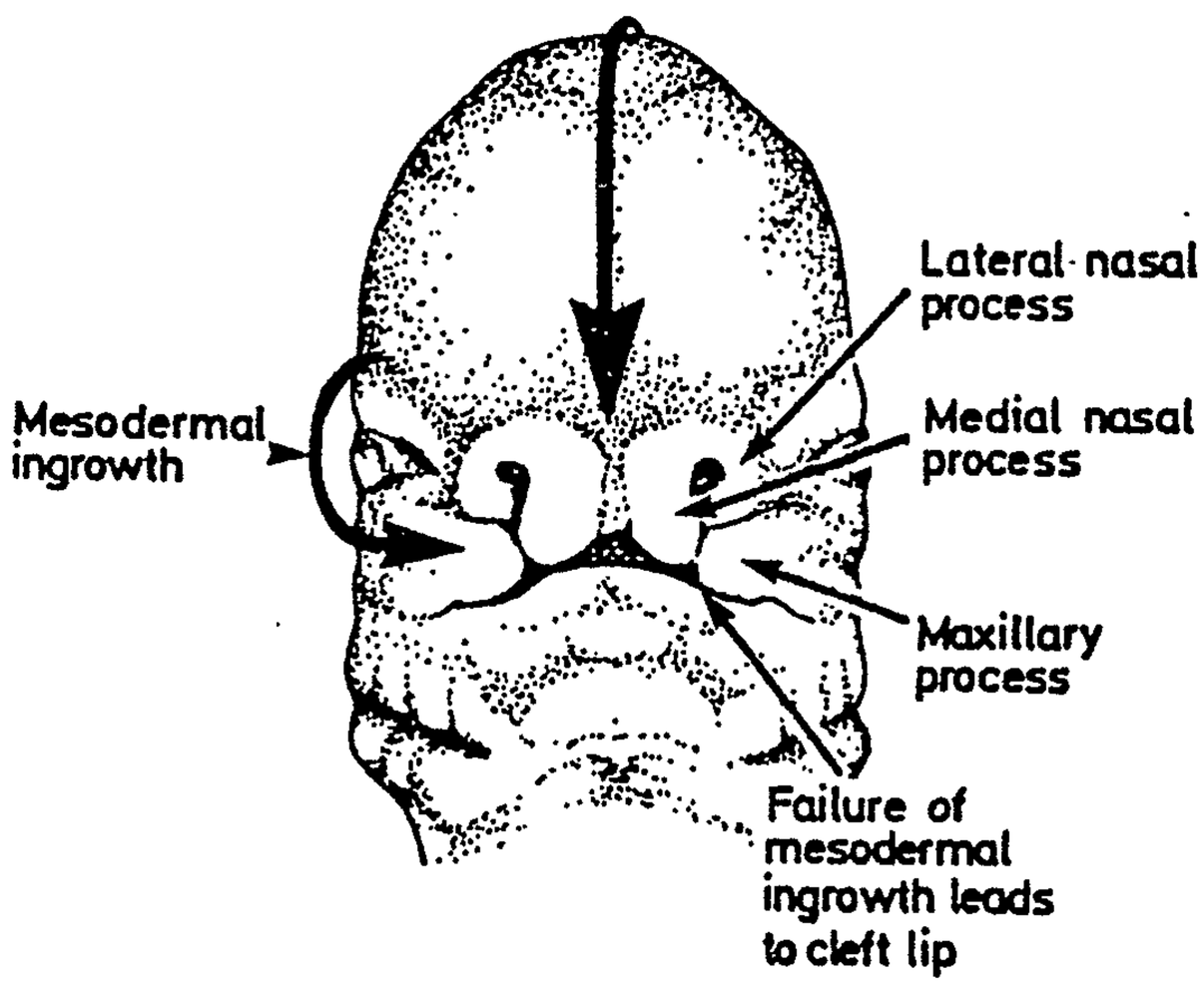

FIGURE 1

Embryo at six weeks old.
(From Davies 1985)

the medial and lateral nasal processes and the maxillary processes. When this happens, a cleft of the lip and anterior palate results. (Stark 1954). See Figure 1. This is the current more popular theory. This mesodermal deficiency has been attributed to the deficiencies in the formation of neural crest cells, their abnormal migration, proliferation and differentiation. Neural crest cells are responsible for the development of the mesenchymal cells of the facial processes so any neural crest injury would cause a growth deficiency and result in cleft formation. (McCredie 1974, Vig et al 1984).

The posterior palate develops from two shelves on the inner aspect of the maxillary processes. Initially, these shelves are separated by the tongue which with age descends thus allowing the two shelves to begin to fuse in the midline by the end of the eighth week of intra-uterine life. They fuse from the incisive foramen region backwards to the uvula region. This process is completed by approximately 10 weeks of intra-uterine life. Failure of the fusion of these shelves will result in the formation of a cleft palate. To understand how the orthodontic problem develops, a brief description of the original pre-surgical condition will now follow.

Where there is a complete unilateral or bilateral cleft of the lip, alveolar process and palate, the upper jaw is divided into two or three separate bony segments, as

the case may be. These segments are thus free to move in response to any forces acting on them (Huddart 1967 (A)). Pruzansky (1955) showed that there was a considerable variation in the pre-surgical morphology and spatial relationships of the cleft segments in these cases. In some instances, medial displacement of the alveolar segments and even overlapping in the anterior region occurs prior to any form of surgery, while more commonly, the premaxilla is displaced anteriorly and the lesser segments are displaced laterally resulting in a widening of the clefts.

FACTORS AFFECTING THE PRE-SURGICAL MORPHOLOGY OF THE CLEFT AND THE SPATIAL RELATIONSHIPS OF THESE ALVEOLAR SEGMENTS

See Figure 2.

These are - (Huddart 1967 (A)):

1) A localized tissue deficiency.
2) The presence of an abnormal balance of muscle forces.
3) The direction and amount of growth of the cartilaginous nasal septum becoming altered.
4) The lack of attachment of the lesser segment or buccal segments to the growing septal cartilage.

(1) Tissue Deficiency

The mechanical presence of the cleft and a localized tissue deficiency enables medial collapse of the alveolar segments or can contribute to the width of the

FIGURE 2

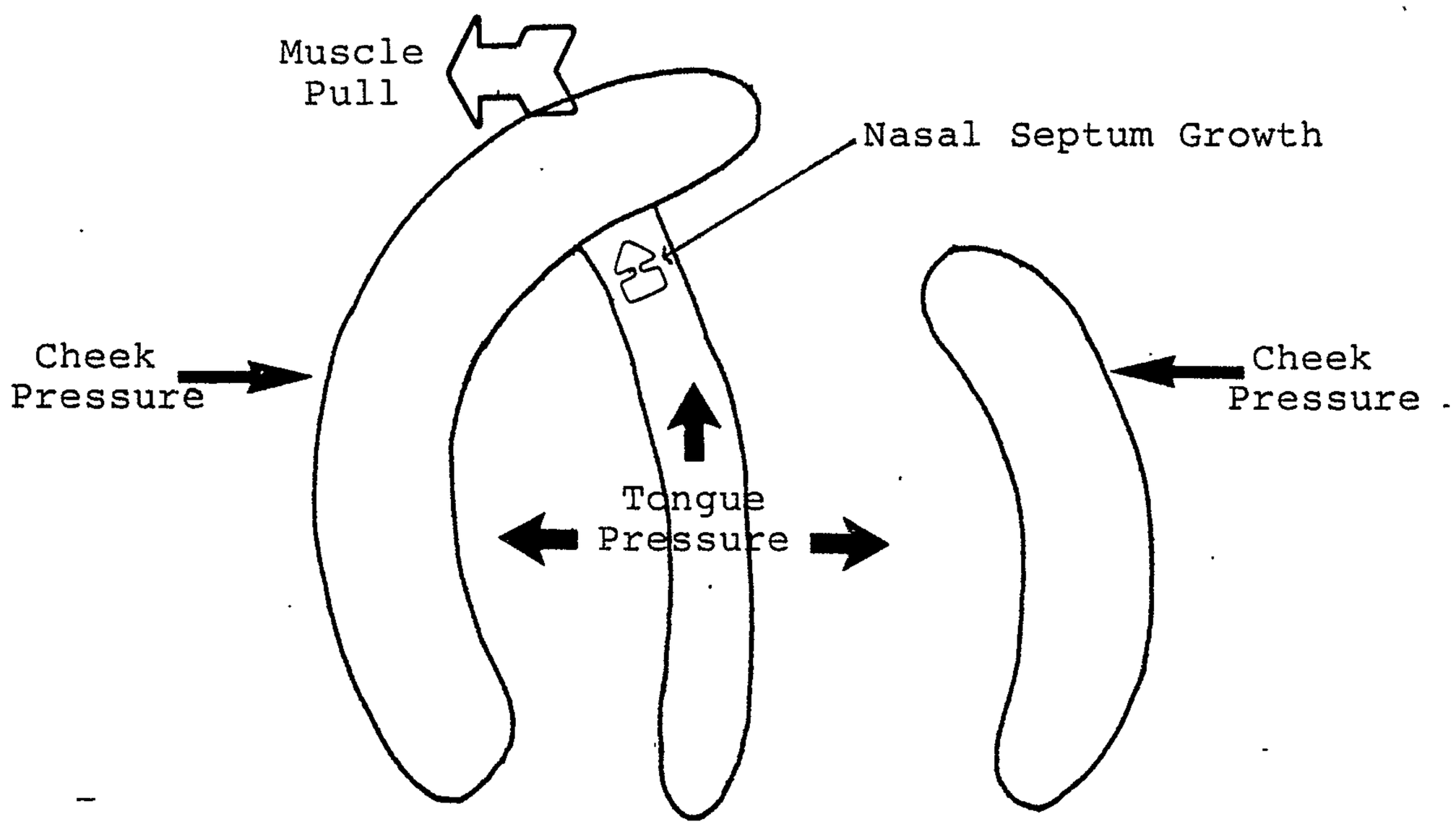

(A) Forces acting on an unrepaired unilateral cleft maxilla.

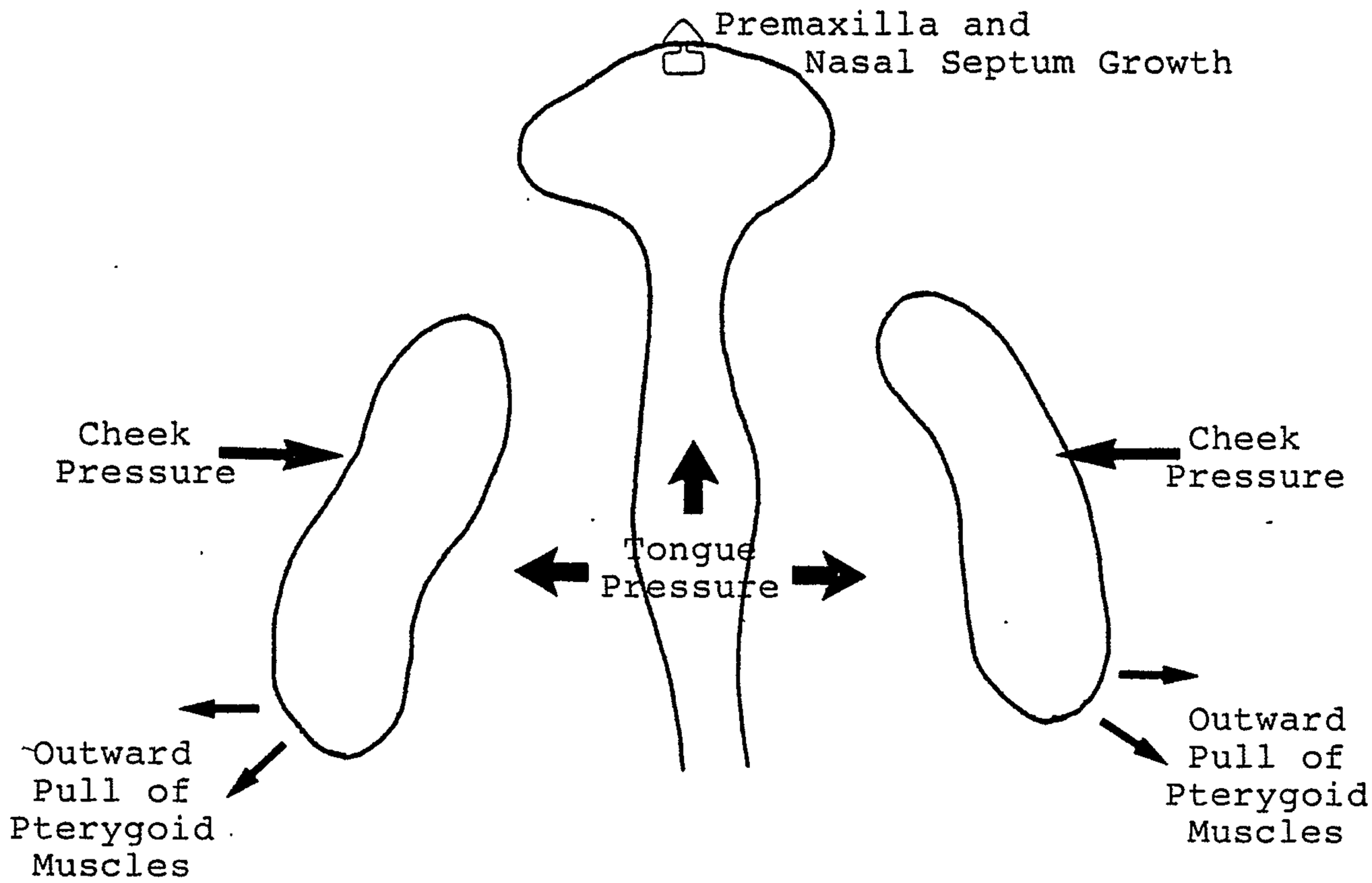

(B) Forces acting on an unrepaired bilateral cleft maxilla.

cleft. Stark (1954) studied embryos with clefts of the lip and palate and found that these cases showed mesodermal deficiencies. Coupe and Subtelny (1960) demonstrated that these tissue deficiencies existed in variable degrees according to the cleft type and that complete bilateral clefts of the lip and palate had the greatest degree of tissue deficiency and lateral displacement of the palatal shelves. Huddart et al (1969) and Huddart (1970) also found a displacement of the segments in complete cleft cases as well as a deficiency in both the areas and widths of the palatal tissues in these cases. After looking at skulls of foetusus, newborn and adults, Van Limborgh (1964) concluded that the tissue deficiencies in cleft cases were confined to the region of the clefts.

(2) Abnormal Muscle Balance

In a normal child, the system of muscles consisting of the orbicularis-oris, the buccinator, the pterygo-mandibular raphe and the superior constrictor muscles, forms a ring around the dental arches and is in equilibrium with the tongue muscles (Slaughter and Pruzansky 1954, Graber 1972). In a patient with a complete cleft of the lip and palate, the integrity of the dental arch is broken and any disturbance to this equilibrium will lead to either collapse or lateral displacement of the arches.

Due to the cleft, the tensor palati muscles are also

non-functional and so the outwards pull of the pterygoid muscle is unopposed (Subtelny 1955). The segments are therefore pulled apart posteriorly, thus making the width of the cleft in the alveolar process and palatal bones greater than would be the case if it was due solely to the absence of tissue. Further widening of the cleft can be caused by the tongue forcing its way into the cleft and pushing the segments apart.

In unilateral cleft cases, the premaxilla and the centre-line are displaced to the unaffected side by the pull of the divided labial musculature (Pruzansky 1955, Huddart 1967 (A)).

(3) Altered Direction and Amount of Growth of Nasal Septal Cartilage

In unilateral cases, the growth of the septum is unrestrained on the side of the cleft and this also contributes to the displacement of the centre-line to the unaffected side (Latham and Burston 1964).

In bilateral cases, the growth of the septum is unrestrained and projects forward like a snout carrying the premaxilla and prolabium with it.

(4) The Lack of Attachment of the Lesser Segment in unilateral cases or buccal segments in bilateral cases to the growing septal cartilage leaves them positioned too far distally and at too high a level (Burston 1958).

The above factors are said to contribute to the width of the cleft and the lateral displacement of the alveolar segments seen frequently in newborn cleft babies. However, pre-surgical collapse of the alveolar segments has also been found and described in newborn infants by Pruzansky (1955), Foster (1962), and Van Limborgh (1964). It has been suggested by Foster (1962) that pre-surgical collapse is due to a combination of the following factors:

1) the presence of the bony defect,
2) pressure from buccal musculature, and
3) the early forward growth of the nasal septum carrying the premaxilla with it and this allows the lesser segment(s) to move medially under the influence of pressure from the cheeks.

It can, therefore, be seen that many factors contribute to the great variation in pre-surgical morphology of the dental arches.

B) THE ORTHODONTIC PROBLEM (After Surgical Repair)

I) Medial collapse of the alveolar segments.

II) Crossbite malocclusion.

Surgical repair of the cleft lip and palate will restore normal function and muscle balance and will usually result in a narrowing of the cleft. (Harvold 1954, Slaughter and Pruzansky 1954, Pruzansky and Aduss 1967, Mazaheri et al 1971, Harding and Mazaheri 1972). Proper surgical repair will also aid in directing the natural growth processes into proper channels (Slaughter and Pruzansky 1954). Correct anatomic repositioning of soft tissue and bony elements will restore the functional matrix and lead to more normal growth and facial development (Veau 1938, Moss 1971).

However, in patients with repaired complete clefts of the lip and palate, certain deformities of the maxilla are seen to occur fairly frequently. These deformities are described by Harvold 1954, Foster 1962, and Crikelair et al 1972. See Figure 3. They are:

1) Medial collapse of the cleft segments,

2) An anterior-posterior shortening of the maxilla,

3) A decreased height of the maxilla on the cleft side. This results in an upward tilting of the occlusal plane and open-bite tendencies in the alveolar cleft regions.

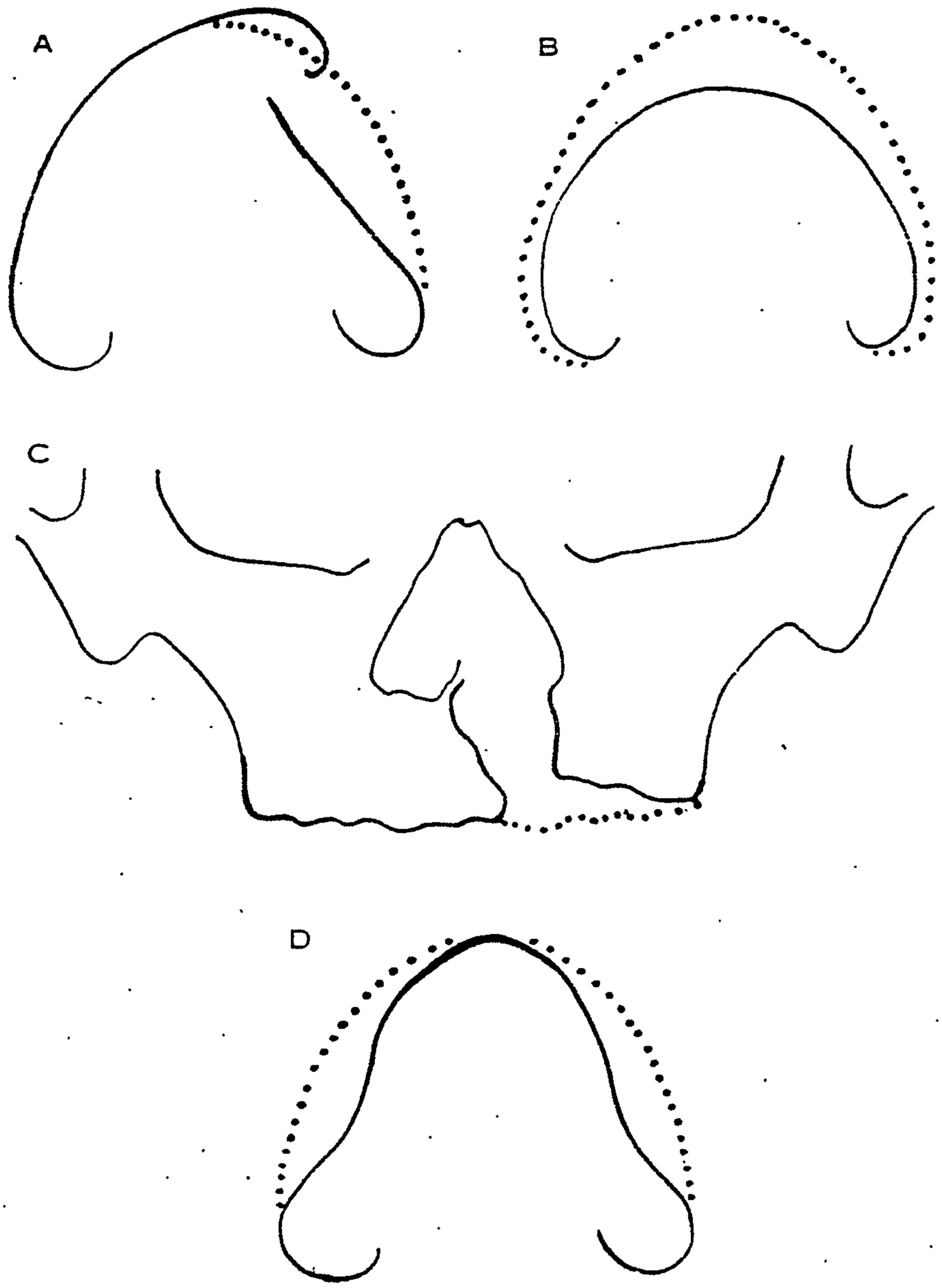

FIGURE 3

Types of Maxillary Deformity. (A) Medial collapse of the cleft segment in a complete unilateral cleft palate. (B) Anterior-posterior maxillary shortening and constriction. (C) Inferior-superior shortening of the maxilla on the cleft side with upward tilting most notable at the cleft itself. (D) Hourglass or buckling defect with medial collapse of lateral alveolar ridges. (From Crikelair et al 1972)

4) A buckling inwards in the premolar regions or an hour glass deformity of the lateral portions of the alveolar arch,

and Dahl (1979) added:

5) A transverse palatal growth inhibition in the maxilla.

Excepting for (3), all these deformities are reflected in the occlusion in the form of crossbite malocclusions found in complete bilateral and unilateral cleft lip and palate cases. These deformities are considered to be partly due to the surgical management of the cleft and partly due to the congenital defect itself.

This study is concerned mainly with the first of these deformities - the problem of medial collapse of the cleft segments and its resultant crossbite malocclusion.

(I) MEDIAL COLLAPSE OF THE ALVEOLAR SEGMENTS

This collapse is found after lip and/or palate surgical repair. It is a differential displacement, being more marked at the anterior end of the alveolar segments in the canine region. This type of collapse is due to:-

(A) tension resulting from a lip or palate repair,

(B) scar tissue contraction from wound-healing especially in the alveolar cleft region,

(C) a large alveolar gap deficiency.

See Figure 4.

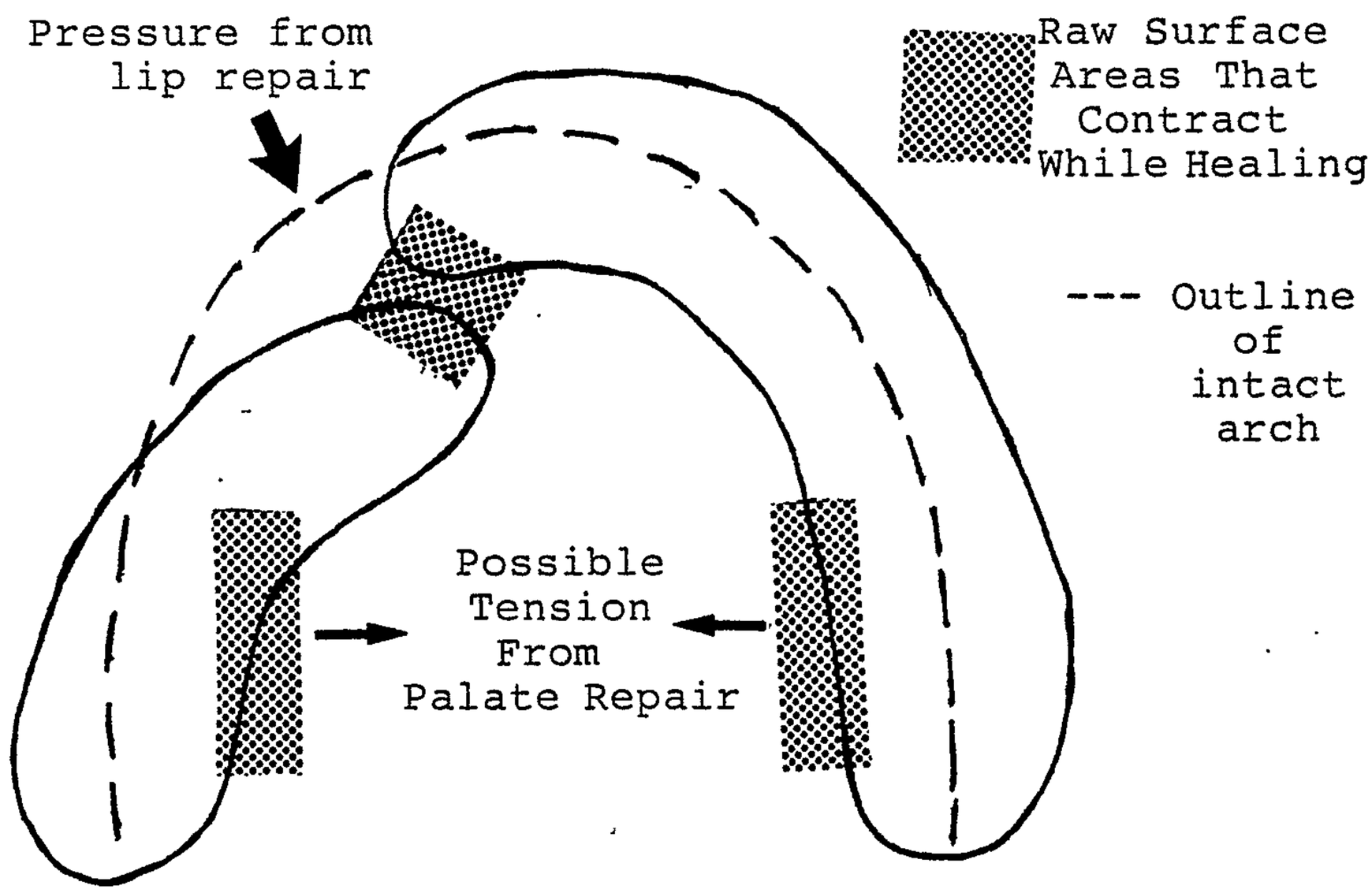

FIGURE 4

Possible causes of medial collapse of the alveolar segments in cleft lip and palate cases.

A) Tension from a Lip or Palate Repair

As previously mentioned, the basic problem with clefts is a deficiency of tissue in the cleft region. (Coupe and Subtelny 1960, Van Limborgh 1964, Huddart et al 1969). This deficiency, together with the tension from unyielding scar tissue and from muscular contractions across the cleft after lip and palate repairs, may lead to collapse of the alveolar segments.

It has been shown that surgical repair of a cleft lip restores the labio-buccal muscle sphincter and creates a functioning lip which moulds and retracts the alveolar portion of the protruding premaxilla and brings the maxillary segments closer together, resulting in a narrowing of the cleft and a more symmetrical arch form. (Harvold 1954, Pruzansky 1955, Hagerty et al 1964, Harding and Mazaheri 1972, Wada et al 1984). In unilateral cleft cases, the effect of the repaired lip is to mould the major segment back to the midline (Harvold 1954, Wada et al 1984). Similarly surgical repair of the palate, especially the restoration of muscle function in the soft palate, will also result in narrowing of the cleft. (Slaughter and Pruzansky 1954, Aduss and Pruzansky 1968).

However, a lip or palate repair that is subsequently under excessive tension, either as a result of excessive cleft width or due to a deficiency of tissues or to

surgical inadequacies, will lead to increased compressive forces acting on the dental arches and could subsequently cause collapse of the alveolar segments behind the premaxilla. (Hagerty et al 1964). Bardach and Mooney (1984) and Bardach et al (1984A) in animal and human studies respectively, have shown that a repaired cleft lip exerts more pressure on the alveolar segments than a normal lip.

Collapse of the alveolar segments does not always occur after lip repair. (Pruzansky and Aduss 1964, Wada et al 1984). In a longitudinal study, Pruzansky and Aduss (1964) found that collapse only occurred in 39.5% of their 33 unilateral complete cleft lip and palate cases after lip surgery. They also found that the original width of the alveolar cleft was not related to the final arch form following lip repair. They later listed four conditions which would affect the amount of medial collapse of the alveolar segments in complete cleft lip and palate cases. They are: (Pruzansky and Aduss 1967)

1) The size and shape of the alveolar process adjoining the cleft is determined by the number of developing teeth at the margins of the defect. The presence of well-formed or even bulbous alveolar borders act as a buttress to prevent collapse of the segments.

2) The size and shape of the inferior turbinate on the side of the cleft also determines the amount of medial

collapse that may occur. Where the turbinate on the cleft side fills the nasal cavity, contact between the deviated septum and turbinate may also prevent approximation of the segments.

3) The size, inclination and degree of deviation of the septum together with its relationship to the turbinates may limit medial movements.

4) The size and spatial relationship of the palatal shelves to each other are highly variable. When the shelves are displaced horizontally towards each other, the tendency towards medial movement will be more inhibited than if the shelves are at a more acute angle.

(B) Wound Healing and Scar Tissue Contraction.

The other cause of post-surgical collapse is wound healing and scar tissue contraction. When the palate is repaired, mucoperiosteal flaps are mobilized and joined in the midline after releasing incisions close to the alveolar processes are made on each side. Areas of denuded bone remain in the palate close to the alveolar processes. These areas heal by secondary intention ie. epithelialization then granulation tissue formation takes place and eventually scar tissue is formed. See Figure 4. Granulation tissue contracts during wound healing and this causes medial collapse of the buccal segments and medial tipping of the teeth (Ross 1970).

It has been shown by Kremenak and associates (Kremenak 1984) that myofibroblasts found in granulation tissue may be responsible for this wound contraction. In animal experiments, they also found that severing the attachments between the wound margins and the central granulation tissue or covering the denuded bony areas with autogenous buccal mucosa or mucoperiosteal grafts led to decreased wound contraction. The scar tissue which is subsequently formed also contracts as it matures and this also has a constricting effect on maxillary growth. (Muir 1966, Ross 1970, Kremenak and Searls 1971, Crikelair et al 1972, Dey 1974).

When the cleft lip and nose are repaired, the anterior alveolar cleft area is usually repaired with a single nasal layer. This leaves a raw oral surface to heal by secondary intention. Wound healing and the subsequent scar tissue contraction will drag the edges of the cleft together and contribute to medial collapse of the alveolar segments, (Burian 1955, Muir 1966, Battle and Whitfield 1970). In the posterior region where the unrepaired maxilla is usually over-expanded (Subtelny 1955), this contraction force will restore normal width in the tuberosity region. Due to bony support from the zygoma, collapse of the alveolar segments is less likely to occur in this region. However, in the anterior maxilla there is very little bony support especially on the cleft side, so this contraction force would cause medial collapse of the alveolar segments. The bony

movement is basically a medial tipping of the entire segment (more-so anteriorly), with the dento-alveolar structures being most affected and the nasal cavity least. This explains the differential displacement of the alveolar segments and the decreasing incidence and severity of crossbites occurring from the canine tooth backwards.

Thus surgery appears to be the main cause of medial collapse of the alveolar segments. However, this type of collapse has also been found in the newborn as mentioned previously as well as in adults with unrepaired clefts. (Innis 1962, Van Limborgh 1964, Atherton 1967, Bishara et al 1976B, 1985, 1986). Bishara et al (1985) looked at 30 cases with unoperated clefts and reviewed numerous unrepaired cleft studies and concluded that in the maxillary arch, the relationships of the cleft to the non-cleft segments varied from normal to different degrees of medial collapse, especially in the canine region. There is, therefore, also some degree of crossbite malocclusion present prior to any surgical treatment in some cases. They felt that surgery should not be considered as the sole cause of arch collapse as mild collapse is often present in many unrepaired complete clefts cases. On the other hand, some authors such as Ortiz-Monasterio et al (1966) have found the buccal occlusion of unrepaired cases to be quite normal. Ross (1970) and Ponitz and Spyropoulos (1979) use the dento-alveolar compensatory

mechanism to explain the development of a satisfactory occlusion in these cases inspite of the mild skeletal deficiencies and alveolar displacements present.

(II) CROSSBITE MALOCCLUSION IN COMPLETE CLEFT LIP AND PALATE PATIENTS

Moyers (1973) states that "crossbite" is the term used to indicate an abnormal bucco-lingual (labio-lingual) relationship of teeth. It may include one or more teeth and may be unilateral or bilateral. The most common form of crossbite is the lingual crossbite and is the situation where the buccal cusps of the maxillary teeth occlude lingually to the buccal cusps of the mandibular teeth. Crossbites can reflect maxillary arch collapse or skeletal growth discrepancies and are a frequent finding in complete cleft lip and palate cases. (Foster 1962, Kling 1964, Pruzansky and Aduss 1964, Bernstein 1972, Bergland and Sidhu 1974, Ranta et al 1974, Dahl et al 1981, Athanasiou et al 1986). Crossbites can be either due to displacement of the dento-alveolar structures or skeletal in origin and can occur in the anterior and/or buccal segments.

Factors Contributing to the Formation of Anterior Crossbite in Complete Cleft Cases.

1) Tightness of the repaired lip: From clinical observations, it can be seen that a tight lip repair

acts as a permanent retrusive force inhibiting the normal forward growth and displacement of the developing maxilla and alveolar processes and the normal downwards and forwards eruption of the upper incisor teeth resulting in the development of anterior crossbites. (Harvold 1954, Ross and Johnston 1972, Vargervik 1981, Gnoinski 1982, Ogidan and Subtelny 1983). This has also been shown in animal experiments by Bardach et al (1979) and by Bardach and Mooney (1984). With animal experiments, they were able to isolate the factor of lip pressure following lip repair alone and study its sole effects on cranio-facial growth. They found increased anterior crossbites and decreased maxillary dimensions and a correlation between the amount of lip pressure and the degree of growth inhibition in the lip repaired groups when compared to the surgically created but unrepaired cleft group.

Bardach et al (1984A) also did a study on lip pressure changes following lip repair on 44 infants with complete unilateral clefts of the lip and palate. They monitored lip pressures from 3 months (pre-operative) through to 2 years of age (just prior to palate repair) in a group of cleft as well as a group of normal children. They found that lip repair significantly "increased" lip pressures and this increased lip pressure remained significantly higher than in the group of normal children for the 2 year duration of the study. They also noted that eruption of the anterior deciduous teeth coincided with

a time of increasing lip pressures.

Fortunately, modern surgical techniques do not usually result in an excessively tight upper lip although differences in the quantity of lip tissue available, in the techniques used and between surgeons do allow for some variation in tension (See Chapter 2 later).

Harvold (1954), Vargervik (1981) and Ogidan and Subtelny (1983) feel that early orthodontic treatment to place the premaxilla in a better position thus allowing the permanent incisor to erupt into a better position, and the application of protrusive and extrusive forces to the alveolar process and teeth will counteract the inhibiting effects of a tight lip repair and scar tissue.

2) Scar tissue contraction: As previously mentioned, many techniques of palatoplasty leave an area of denuded bone close to the anterior alveolar process and incisor teeth. This area heals by secondary intention and the formation of scar tissue. Many of the supporting fibres in the periodontal ligament of the teeth extend for some distance into the surrounding mucosa and unfortunately are caught up in this scar tissue. Initial contraction of the healing wound would cause a mild retrusion of the incisor segment which may result in a crossbite of one or more teeth developing. Subsequent tooth eruption and vertical development of the alveolar process are

resisted by the scar tissue present and a posterior deflection of the dento-alveolar structures is induced. (Ross 1970, Huddart et al 1983). This together with pressure from a repaired lip can cause the posterior eruption of the incisor teeth and an anterior crossbite malocclusion to develop.

Dahl et al (1981) found that Norwegian cases with a 1-layer vomero-plasty closure of the hard palate had a higher incidence of anterior crossbite than Danish cases who had 2- layered repairs of the hard palate. It should be noted that two-layered repairs result in less scar tissue formation. (See Chapter 3(c)).

3) Tongue posture may also act to inhibit normal anterior dento-alveolar development. Unless the tongue can produce an adequate forward pressure on the incisors and the alveolar bone in rest position as well as in function, compensatory anterior growth will not occur. Children with clefts may have a low tongue posture, related to maxillary dental arch collapse and mouth-breathing and these cases have particularly severe and progressive maxillary incisor retrusion with growth. (Ross and Johnston 1972).

4) Mandibular incisor support for the upper incisors and the anterior alveolar growth: If there is inadequate vertical development of the maxillary incisors or if they are posterior to the mandibular

incisors, interincisal support does not occur. A retrusive tendency is more liable to be expressed in these cases. (Ross and Johnston 1972).

5) Protrusive movements of the mandible may also be used by certain patients with too short a soft palate in an attempt to compensate for velopharyngeal incompetence. Owing to the insertion of muscle fibres from the lateral pharyngeal wall on to the medial surface of the mandibular body, the pharyngeal space can be reduced to a certain extent by protruding the mandible. The retrusion of the upper incisors into a retrusive position may also bring about an anteriorly forced bite relationship which causes the mandible to slide forward resulting in an anterior crossbite. These protrusive movements also act as an unfavourable orthopaedic factor leading eventually to anterior crossbite formation (Gnoinski 1982).

6) A reduced anterior-posterior growth of the maxilla, due to surgical interference and subsequent scar tissue inhibition of growth sites and growth mechanisms, can result in a hypoplastic maxilla and an anterior crossbite malocclusion developing. The possible growth mechanisms of the skeletal units of the head are those of cartilaginous, sutural, periosteal and endosteal growth. In cleft lip and palate cases, all these mechanisms are affected by periosteal stripping and post-operative scarring. For example, as a result of

palatal surgery, a continuum of scar tissue joins the maxilla, the palatine bones and the pterygoid plates of the sphenoid, inhibiting separation of these bones. This scar tissue would inhibit appositional growth at the growth sites of the maxillary tuberosities and the nearby sutures. Ross and Johnston (1972) feel that this scar tissue causes a mild long term inhibition of the anterior-posterior growth of the maxilla. In anterior palate closures, scarring of the nasal septum is involved. This too could inhibit anterior maxillary growth. (Wada and Kremenak 1978). Moss (1971) has also suggested that the facial skeleton is stimulated to reach its final form and size under the influences of normal function. In complete cleft cases, the functions of speech, mastication and respiration may be impaired due to the defect itself and also to abnormal muscle insertions (Delaire 1978 A&B). According to Moss (1971) and Delaire (1978 A&B), this should lead to reduced anterior-posterior growth of the maxilla as well and could result in anterior crossbite formation.

Factors Contributing to the Formation of Buccal Crossbites in Complete Cleft Cases.

1) Post-operative "collapse" or medial collapse of the alveolar segments (as described previously). This would contribute to the formation of crossbites in the buccal segments.

2) Hourglass maxillary deformity (Bilateral buckling

inwards of the lateral portions of the alveolar arch). If surgical incisions are placed too close to the alveolar ridge where the teeth are developing and this area is left denuded, the teeth will subsequently erupt lingually into crossbite relationship with their lower counterparts and there will be localized dento-alveolar deformity. This is due to the contraction effects of scar tissue (Crikelair et al 1972, Dey 1974, Kremenak 1984). This is usually seen in the premolar region after palate repairs, as shown in Figure 3(d).

3) A long-term inhibition of transverse maxillary growth. From longitudinal implant studies, Dahl (1979) showed that spontaneous transverse growth was inhibited in patients with repaired complete clefts of the lip and palate. Dahl (1979) attributed this growth inhibition to two reasons - (i) a bony ankylosis and (ii) a fibrous ankylosis. Prydso et al (1974) demonstrated that a two layered palato-vomer plasty (used to repair the hard palate) may result in a bony ankylosis between the maxillary segment on the cleft side and the nasal septum. Dahl (1979) felt that this bony fusion between the nasal septum and the maxillary segments coupled with an abnormal position of the mid-palatine suture would restrict transverse maxillary growth. He also felt that the scar tissue formed after palate repairs would inhibit growth through a fibrous ankylosis. Ross and Johnston (1972) agree with the latter. This restriction in the transverse growth of the maxilla could contribute

to the formation of a lingual crossbite malocclusion.

4) The increasing retrusive position of the maxilla in the face of patients with repaired complete clefts will result in an apparent reduction in maxillary width. Since the maxillary dental arch becomes narrower from posterior to anterior, this has the effect of causing the formation of lingual crossbites as the mandible grows forward normally while maxillary growth is inhibited. The eruption of the lingually inclined upper central incisors or mandibular overclosure can also cause the mandible to posture forward into centric occlusion on closure and this would also lead to an impairment of borderline buccal teeth relationships. (Ross and Johnston 1972, Bergland and Sidhu 1974).

CHAPTER 2

TYPES OF REPAIR

This chapter will briefly describe the surgical procedures most commonly used in the primary repair of complete clefts of the lip and palate. This will enable the reader to be familiar with the surgical procedures discussed in the study later on. The basic principles and aims of the repair procedures and the effects of each of these procedures on maxillary growth and the occlusion will also be discussed.

A) LIP AND NOSE REPAIR

Steffensen (1953) listed 5 criteria for a satisfactory cleft lip repair:

1) accurate skin, muscle and mucous membrane union.
2) symmetrical nostrils and nostril floors.
3) symmetrical vermilion border.
4) slight eversion of the lip.
5) a minimal scar which by its contraction will not interfere with the accomplishment of the other stated requirements, and Musgrave (1971) added:
6) preservation of cupid's bow and the vermilion - cutaneous ridge.

   and Ross and Johnston (1972) added:
7) the buccal sulcus should be reconstructed as completely as possible. (This is required if the labial flange of a prosthesis needs to be made and

is very difficult to achieve in bilateral cleft lip and palate cases).

The history of cleft lip repair has been reviewed by Musgrave (1971) and Millard (1980). It shows a steady improvement in the cosmetic and functional results as surgeons have gradually come to appreciate the true nature of the deformity. The recognition that in unilateral clefts, elements of the lip such as the cupid's bow and the philtrum are always present and should be preserved, and the development of tissue saving operations have led to far more natural looking lip repairs.

The nasal deformity which always co-exists with the cleft lip is now more effectively dealt with than ever before, although there is still argument about how much of the deformity should be treated at the primary operation. The more popular view today is that early nasal surgery to place the alar cartilages and other nasal soft tissues into their anatomically correct positions will enable the nose to grow normally subsequently. (McComb 1975, Delaire 1978B, Mulliken 1985). The alar cartilages can be freed from the overlying skin and mucosal attachments and replaced in their correct position and then held by transfixion sutures.

Another important advancement in the surgical repair of

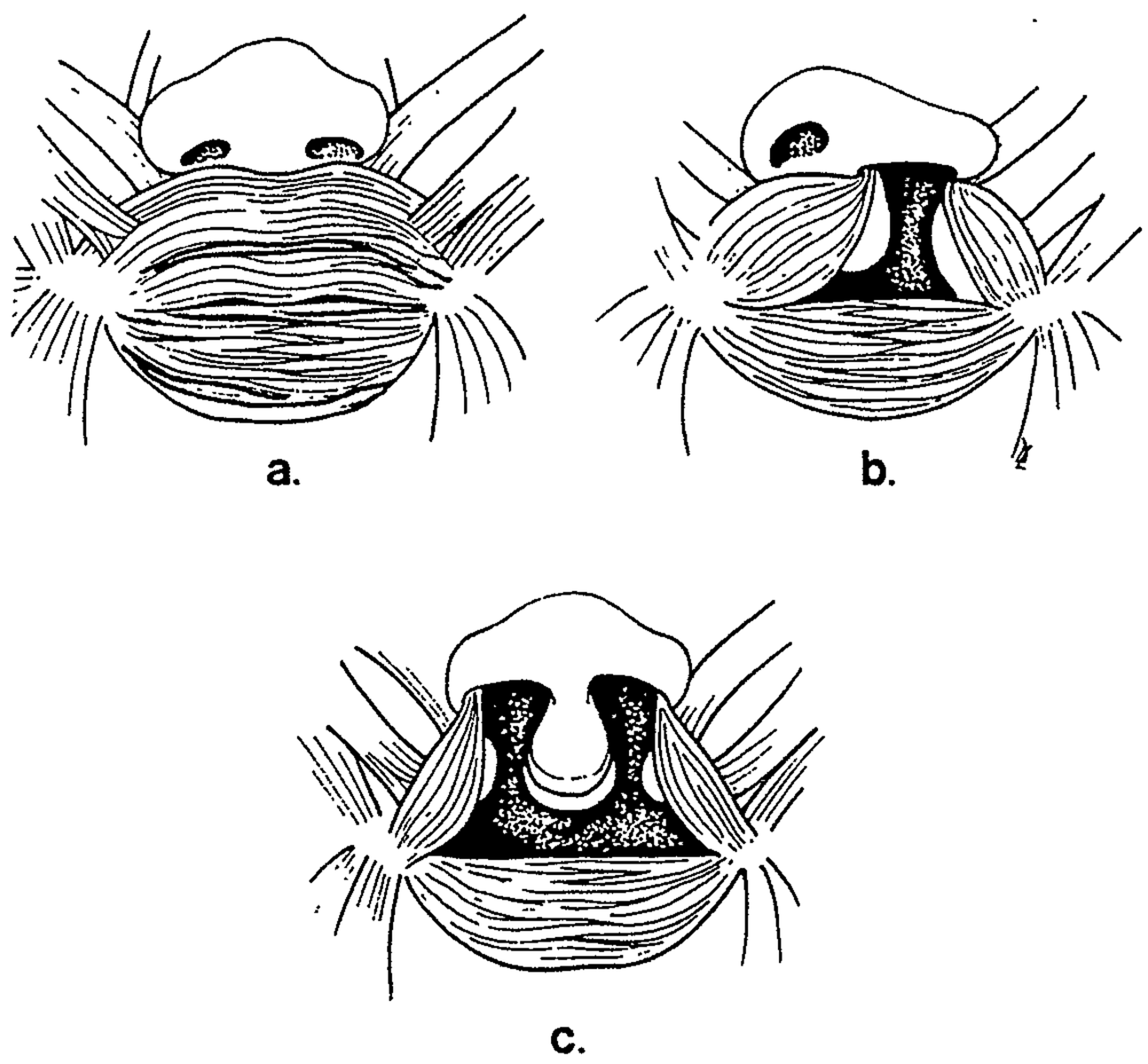

FIGURE 5

The configuration of the orbicularis oris muscle. (a) Normal. (b) Unilateral cleft lip. The orbicularis oris muscle runs parallel to the edges of the cleft and inserts into the margins of the piriform fossa. (c) Bilateral cleft lip. There is no muscle in the prolabium. (From Edwards and Watson 1980)

the cleft lip is the recognition that the main muscle of the lip (the orbicularis oris muscle) runs parallel to the free margins of the cleft, sweeps upwards and then attaches itself to the base of the nostril. See Figure 5. In the bilateral cleft, the muscle in each lateral segment of the lip runs in this way too. There is also no muscle in the prolabium. The currently accepted view of muscle anatomy in the cleft lip patient is based on dissection studies by Fara (1968), Delaire (1978B) and Kaplan (1982). Unless the muscle is freed from its abnormal insertion at the base of the nostril and rotated in a transverse direction across the cleft during lip repair, the lip will exhibit abnormal bulges on each side when in function, even though it may look excellent at rest. Reconstruction of the orbicularis oris muscle sphincter will not only allow the lip to function more naturally but will also draw the two halves of the maxilla together thus narrowing the alveolar cleft. The deflected premaxilla will also return to the midline. (Harvold 1954, Pruzansky 1955, Mazaheri et al 1971, Ogidan and Subtelny 1983, Wada et al 1984).

Excessive width of the cleft is due to a number of previously mentioned reasons (see "Original Condition" section in Chapter 1). This excessive cleft width would mean that more extensive dissections have to be done to free tissues used to close the lip and palate without tension. Extensive dissections and the resultant

periosteal damage and scar tissue formed, coupled with a tense lip repair, would contribute towards maxillary collapse, maxillary growth inhibition and subsequent crossbite formation. (Kremenak and Searls 1971, Ross and Johnston 1972). Hence many have recommended the use of pre-surgical orthopaedics to improve the relationships of the alveolar segments prior to lip repair and post-surgical orthopaedics to maintain the corrected positions of the alveolar segments.

The importance of muscle reconstruction has been recognised by many operators such as Veau (1938), Slaughter and Pruzansky (1954), Randall et al (1974), Delaire (1978B) and Kernahan and Bauer (1983).

From dissections and histological studies, Delaire (1978 A&B) hypothesized that skeletal malformations in cleft lip and palate cases resulted from functional abnormalities due to abnormal muscular insertions in the lip, nose and anterior nasal spine region. In the normal child, muscles in this premaxillary region attach to the lower and anterior aspect of the nasal septum and nasal spine. Delaire believes that forward growth of the septal cartilage brings about a forward traction of the premaxillary periosteum via these muscle attachments. He feels that this promotes forward growth of the anterior surface of the maxilla. This is similar to the effects of the buccal shields of the Frankel Regulator in stimulating bony growth (Frankel 1969).

Delaire believes that the lack of muscle insertion into the central median suture area of the premaxilla of cleft patients may also lead to growth restrictions anteriorly and subsequently to the development of a crossbite malocclusion. He believes that correct anatomical repositioning and reattachment of all these muscles in the premaxillary region at the time of lip repair will restore normal facial development. This is in agreement with the ideas of Veau (1938), of Moss and his functional matrix theory of growth (1971) and of Fisher, Godfrey and Stephens (1976). Recent work by Siegel (1983) has also implicated the failure to reconstruct the orbicularis sphincter with subsequent growth deficiencies of the face. Delaire (1978B) goes as far as saying that with this type of functional closure, the use of presurgical orthopaedics and primary bone-grafting procedures to avoid subsequent alveolar collapse and deformities is not necessary.

In the closure of bilateral cleft lips, a significant development was the recognition that the prolabium belonged embryologically to the lip (Stark 1958) and that however small it may appear to be, the vertical height of the prolabium must be accepted as the definitive vertical height of the upper lip. A small prolabium has been shown to have the ability to stretch and enlarge. Manchester (1965) found that when lip tissue from the lateral elements were joined together in the midline below the level of the prolabium and the

prolabium was used to lengthen the columella instead, a very long and tight lip was produced. This tight lip would inhibit forward growth of the maxilla and cause anterior crossbites to form. He therefore devised his own technique (Manchester 1965) using the prolabium as part of the lip, for repairing bilateral clefts and this is the technique mainly used at the Royal Alexandra Hospital for Children for bilateral repairs.

There are many different operations for cleft lip repair and they can be divided into four basic groups as follows: (See Figure 6).

1) The straight line closures.
2) The lower one-third Triangular Flap operations.
3) The upper one-third Triangular Flap operations.
4) Quadrilateral Flaps.

1) The Straight-Line Closures - The incision lines may be vertical or oblique, straight or curved. This procedure has the advantage of producing the shortest incision line on the lip and therefore the shortest scar. However, staight line incisions contract longitudinally and tend to produce shortening of the lip on the repaired side (Lindsay 1972). Manchester's (1965) repair for bilateral clefts is a modified example of this type of closure.

2) The Lower One-Third Triangular Flap Operation - These operations include the one by Tennison (1952);

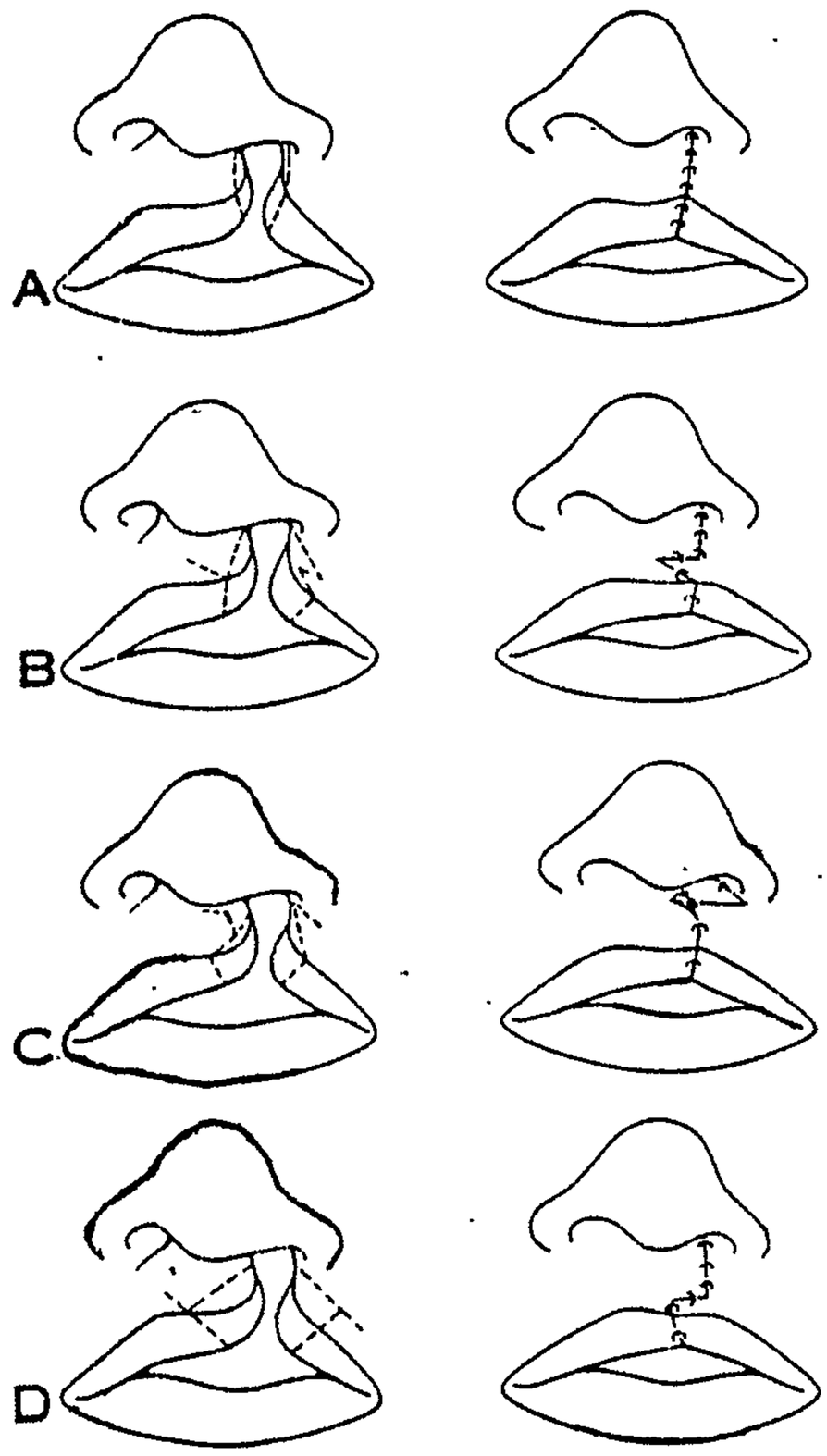

FIGURE 6

Comparative drawings of basic cleft lip operations. (A) Straight line operation; (B) Lower one-third triangular flap operation; (C) Upper one-third triangular flap operation; (D) Lower one-third rectangular flap operation.
(From Ross and Johnston 1972)

which was later modified by Randall (1959) and many others subsequently. This is the lip repair used mainly at the Royal Alexandra Hospital for Children. This technique brings the medial side of the cleft cupid's bow down into a more normal position and the triangular defect so formed is filled in with a triangular flap from the lateral side. See Figure 6B. The use of the "z-plasty" principle to form triangular flaps has the advantage of breaking up the long straight line incision so that it does not contract longitudinally and produce shortening of the repaired side of the lip. This operation also has the advantage of not wasting tissues and moving more tissue into the lower third of the lip. In this way, a desirable full lip with a natural Cupid's bow is formed. This may also produce a less tense lip repair and subsequently less anterior crossbite formation and arch collapse. A disadvantage of this operation is the interruption of the philtral groove with a short transverse or oblique line in the lower portion of the lip which may remain quite obvious. The lip tends also to become elongated on the cleft side.

3) <u>The Upper One-Third Triangular Flap Operations</u> - These operations interrupt the long staight line of repair to a degree, without interfering with the philtral ridge of the lower lip on the cleft side. An example of this type of operation is the Rotation-advancement flap by Millard (1955). This consists of bringing down the medial side of the cleft

Cupid's bow as a large rotation-advancement flap and using tissue on the lateral side to fill in the defect high in the upper third of the lip instead of down at the vermilion. There is no tissue wastage here and the procedure produces a more natural alar base and floor of the nose than do the other operations (Lindsay 1972).

4) Quadrilateral Flap Operations - These are rarely used today and operations consist of rectangular flaps with the same principles as the triangular flaps. Le Mesurier's (1949) lip operation is an example of a quadrilateral flap procedure.

There have not been many published clinical studies solely comparing the effects of different types of lip repair on maxillary growth and the occlusion because of the difficulties in eliminating the many other variables, for example palatal repair, that could also affect maxillary growth and the occlusion. Lindsay (1972) felt that the Millard procedure may produce a lip which is tighter in its lower third because it does not move extra tissue into this area. This was verified by Peat (1980) who found that the Millard rotation advancement method of lip repair was more detrimental to the incisor relationship resulting in twice the incidence of incisor crossbites when compared with other z-plasty techniques. However, his sample size for the Millard repair group was only 13 compared to 29 cases for the Davies z-plasty sample and this could mean that

the surgeon was more skilled with the Davies z-plasty procedure resulting in better z-plasty repairs.

Onizuka and Isshiki (1975) compared the effects of four different methods of lip repair on the maxilla of 137 cases with cleft lips only. They found that cases repaired by the staight line method resulted in growth retardation of the maxilla in all directions and that triangular flap repairs showed posterior arch width retardation. However, Wada et al (1984) found that the Tennison lip repair did not inhibit maxillary growth. Most operators nowadays feel that the type of lip repair makes little difference so far as the effects on the underlying structural elements are concerned, provided the result is a supple lip (ie. not tight) and as long as the surgery conserves tissues and is atraumatic. It has been shown in both human and animal studies, that a tight lip can inhibit the anterior-posterior growth of the maxilla and cause retraction of upper anterior teeth as well as anterior dental arch collapse and therefore should be avoided. (Harvold 1954, Hagerty and Hill 1963, Vargervik 1981, Gnoinski 1982, Bardach and Mooney 1984).

B) <u>ANTERIOR PALATE REPAIR (Repair of the alveolar cleft)</u>

Management of the alveolar cleft and anterior hard palate is a controversial subject. The timing of the repair as well as the type of repair are all subject to debate. There are surgeons who prefer to repair the

anterior palate and floor of the nose at the time of lip repair because access is good then. The view of the cleft is not obstructed by the repaired lip. (Manchester 1965, Muir 1966, Dey 1974, Millard 1976). There are also others who avoid interfering with bony structures during the growth period and so leave closure of the anterior palate till growth has been completed. In this way, scar tissue cannot inhibit growth and the premaxillary vomerine suture growth centre cannot be interfered with. (Slaughter and Pruzansky 1954, Schweckendiek 1955, Bernstein 1972, Friede 1978, Ross 1984A). Some older techniques of lip repair even ignore the problem of the cleft alveolus and consequently the patient is left with an oro-nasal fistula between the repaired lip and the repaired secondary palate. These fistulae can be a nuisance to the patients because they allow unwanted nasal emission of air during speech and also let food and drink escape into the nose. The controversy over the timing of the repair will be discussed in more detail in a separate section later. The different types of management of the alveolar cleft and anterior palate will now be discussed.

The child with a complete cleft of the lip and palate usually has displaced maxillary segments due to a number of factors previously discussed. (See "Original Condition" section in Chapter 1). For reasons previously mentioned, re-positioning of these segments to narrow the cleft and improve the arch form would facilitate

surgical repair. This can be achieved by a lip adhesion procedure (Randall 1965, Walker et al 1966) or by pre-surgical orthopaedics (Huddart 1961, Brogan 1973, Hotz and Gnoinski 1976). A lip adhesion procedure is a simple preliminary operation in which the floor of the nose and the upper 3mm of the lip are closed, thus converting a wide complete cleft into a narrower incomplete one. The backward pull of the adhesion permits definitive closure of the lip in a few weeks. Pre-surgical orthopaedics is the use of orthodontic devices and elastic strapping to bring displaced lip and maxillary tissues back to normal pre-operatively (Brogan 1986). (This will be covered in more detail later on). See Figure 7. The need for pre-surgical orthopaedics is also a controversial subject. There are observers such as Pruzansky (1964), Mazaheri et al (1971) and Hanada and Krogman (1975) who feel that the lip repair alone would reduce the width of the cleft and bring the deflected premaxilla back into alignment without the need for pre-surgical orthopaedics.

Besides the use of lip adhesion and pre-surgical orthopaedics, the problem of the protruding premaxilla in complete bilateral cleft cases has been corrected by surgical repositioning of the premaxilla. (Browne 1949, Lindsay 1972). Surgical repositioning usually involves an osteotomy of the vomerine bone, thus allowing the protruding premaxilla to be set more distally in the face. This procedure, however, may cause damage to the

FIGURE 7

A) An example of an infant wearing a pre-surgical orthopaedic appliance and strapping.

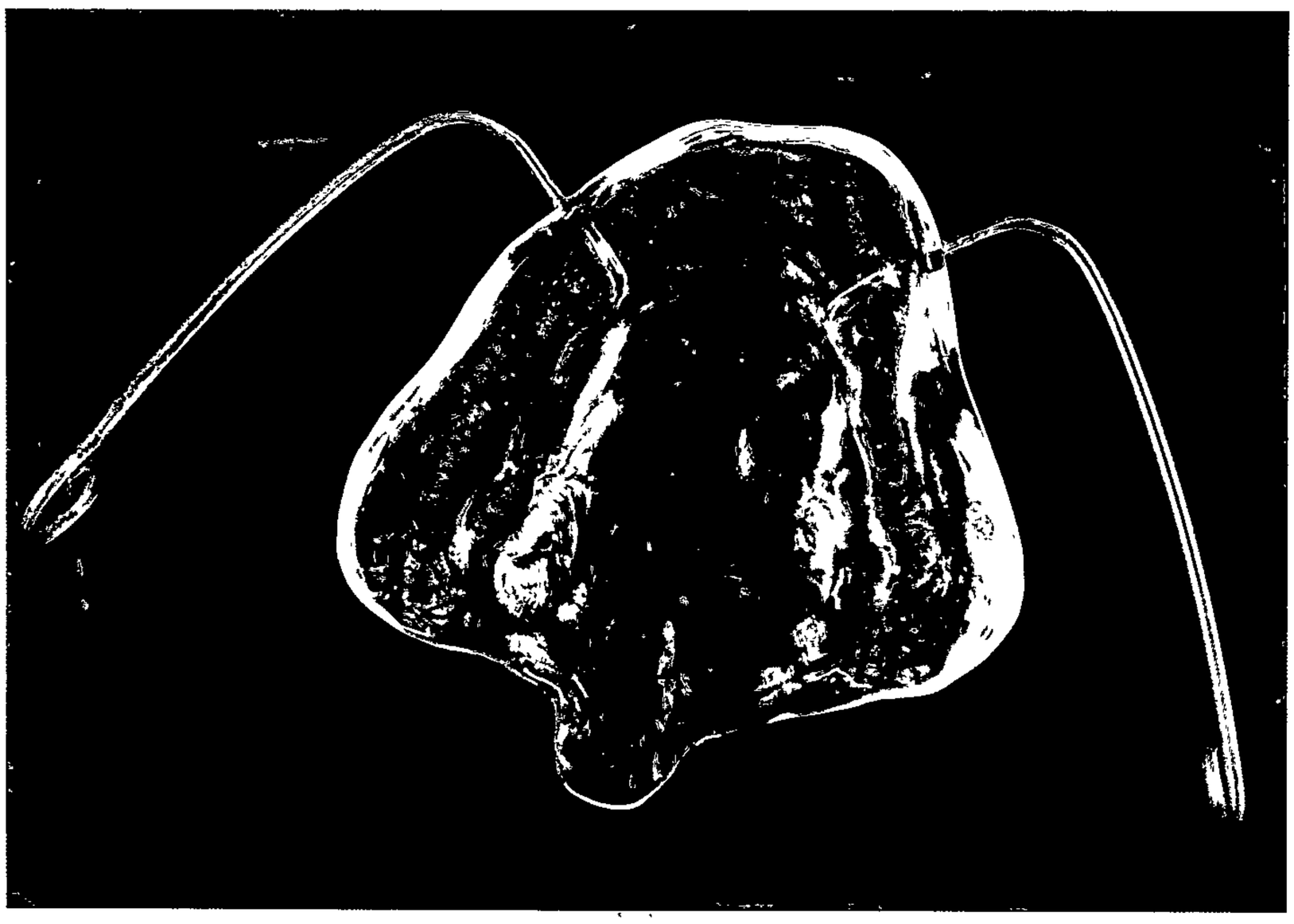

B) An example of a "passive" - type pre-surgical orthopaedic appliance for a bilateral case.

growth centre of the premaxillary - vomerine suture and lead to later mid-face growth deficiency. (Friede and Morgan 1976, Ross and Johnston 1972, Vargervik 1983). This is seldom used nowadays. It has also been shown with cephalometric studies that if the premaxilla is not interfered with, it becomes less protrusive as the rest of the face grows forward. (Narula and Ross 1970, Hanada and Krogman 1975, Vargervik 1983).

The alveolar cleft and anterior palate can be closed in a number of ways. It is a difficult area to repair as the flaps available are in general insufficient and difficult to mobilize. It can be closed by one or two layers of soft tissue alone or may have a bone graft included in the closure as well. Two-layered closures should be done where possible to avoid fistula formation, the contraction phase of wound healing by secondary intention and the laying down of unnecessary scar tissue. Scar tissue contraction contributes towards inward collapse of the alveolar segments. The flaps used for closure can be vomerine, lateral nasal, labial mucosal, palatal mucoperiosteum or tongue flaps. These will be described in more detail later on. (See Chapter 3(C).)

Elevation of a vomer flap should not be more extensive than is necessary to close the nasal layer without tension, as it is possible that this procedure may interfere with growth of the vomer and subsequently the

midface. It has been observed in human studies (Pruzansky and Aduss 1967, Friede and Johanson 1977) and in animal studies (Wada and Kremenak 1978) that surgical trauma to the vomer may lead to growth restrictions of the midface. (Also see Bone graft section later). However, in a recent international study of cephalometric radiographs from different treatment centres throughout the world, Ross (1984B) found that anterior-posterior growth of the maxilla was not affected by either the use of vomer flaps or by soft tissue alveolar closures. Bone grafts also can be inserted at the time of primary lip repair to prevent collapse of the dental arch. Skoog (1969) used a periosteal flap from the anterior surface of the maxilla to repair and obtain bony closure of the alveolar cleft area. This technique was called periosteoplasty.

At the Royal Alexandra Hospital for Children, the anterior palate and lip repairs are carried out at the same time. A septal or vomer flap is used to repair the anterior palate and this has been reinforced with a Dey triangular labial flap since late 1972. The effects of this flap on the occlusion and on the relationships of the maxillary segments are being investigated in this study.

C) POSTERIOR PALATE REPAIR (Secondary Palate Repair)

The aims of posterior palate closure are:

1) to provide an intact roof to the mouth for easier food intake and to decrease upper respiratory tract and middle ear infections and;

2) to provide a mobile, soft palate capable of velopharyngeal closure that will allow the child to develop good speech.

The early cleft palate closures involved apposition of mucosal tissues and suturing them together but the incidence of breakdown was high even after relaxing incisions to relieve tension were introduced by Von Langenbeck in 1861. He also added the concept of using mucoperiosteal flaps, which are thicker, to his palate closure operations to prevent breakdown.

With the Von Langenbeck closure of the secondary palate, the edges of the cleft are pared and the soft tissues of the two halves of the palate (ie. the mucoperiosteum anteriorly and the soft palate posteriorly) are slid towards each other and sutured together in the midline. To allow this to happen, release incisions have to be made on each side and these run inside the alveolar process from the region of the canine anteriorly, curving around the maxillary tuberosity to end just behind the region of the pteryoid hamulus. See Figure 8. This medial displacement of palatal tissue leaves raw areas on each side. Epithelialization and

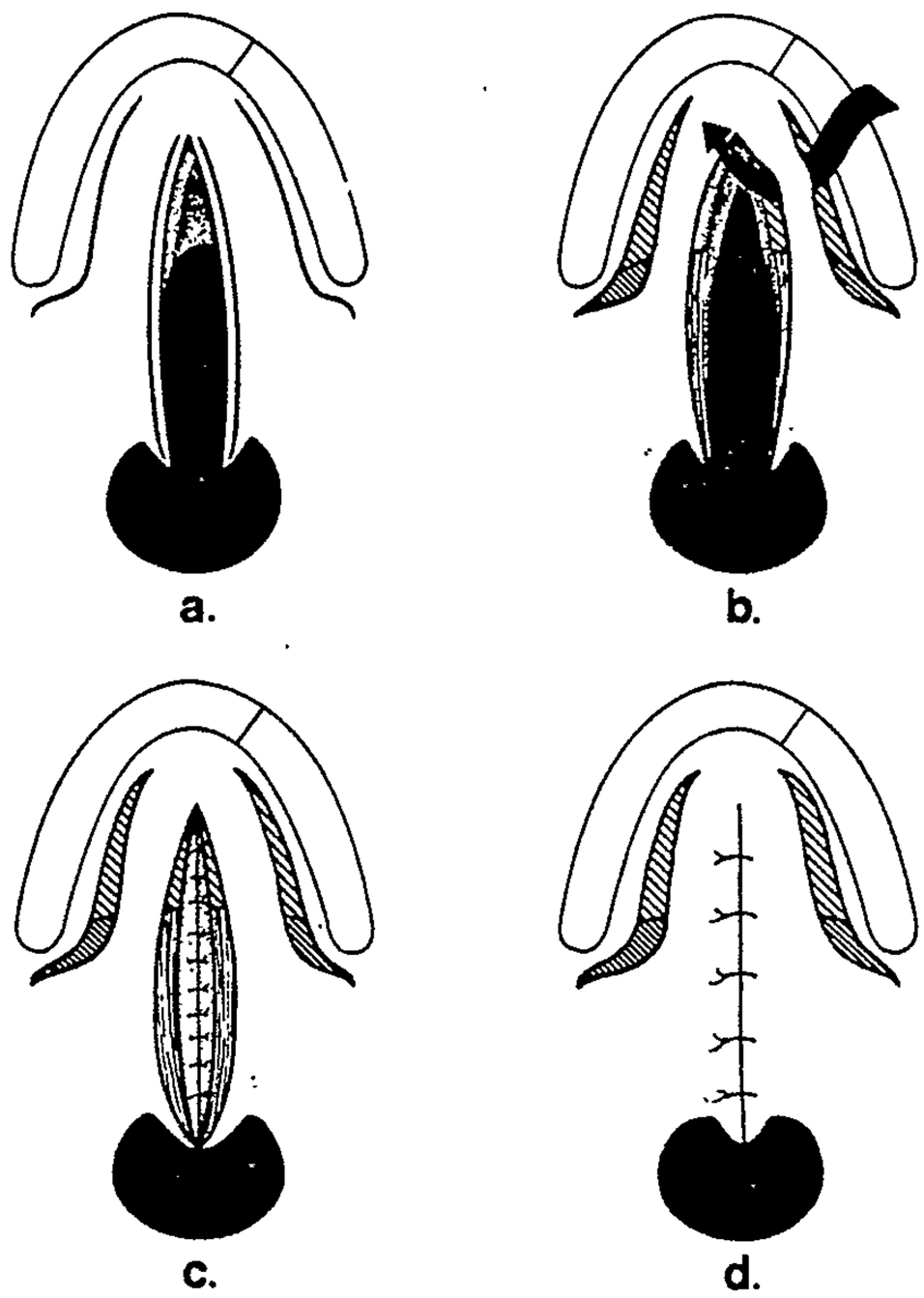

FIGURE 8

The Von Langenbeck operation for closure of the secondary palate. NB - Slashed lines indicate raw surfaces. (From Edwards and Watson 1980)

healing takes place quickly but some scar tissue is inevitably formed. This scar tissue contracts during healing and has been blamed for tethering and restricting the laterally growing palatal bones and for pulling the maxillary teeth medially into crossbite relationships with their mandibular counterparts, and for collapse of the maxillary segments medially. (Ross 1970, Kremenak and Searls 1971, Crikelair et al 1972, Dahl 1979, Jonsson et al 1980).

In a review of a series of studies on the effects of palatal surgery on Beagle dogs by Kremenak and Searls (1971), it was found that the surgical variable which interfered most with post-surgical jaw growth was the mucoperiosteal denudation of palatal bone adjacent to deciduous teeth. They also found that neither interruption of the blood supply nor the extensive mobilization of mucoperiosteal flaps were critical variables in influencing post-surgical jaw growth.

One criticism of the Von Langenbeck operation has been that it does nothing to lengthen the palate. A short palate, not capable of velopharyngeal closure results in hypernasal speech. The push-back operations such as the Wardill V-Y palate operation (Wardill 1937, Kilner 1937) were developed for the purposes of lengthening the palate and thus improving speech. See Figure 9. Here, the raised mucoperiosteal flaps are slid backwards (to lengthen the palate) and medially and then sutured in

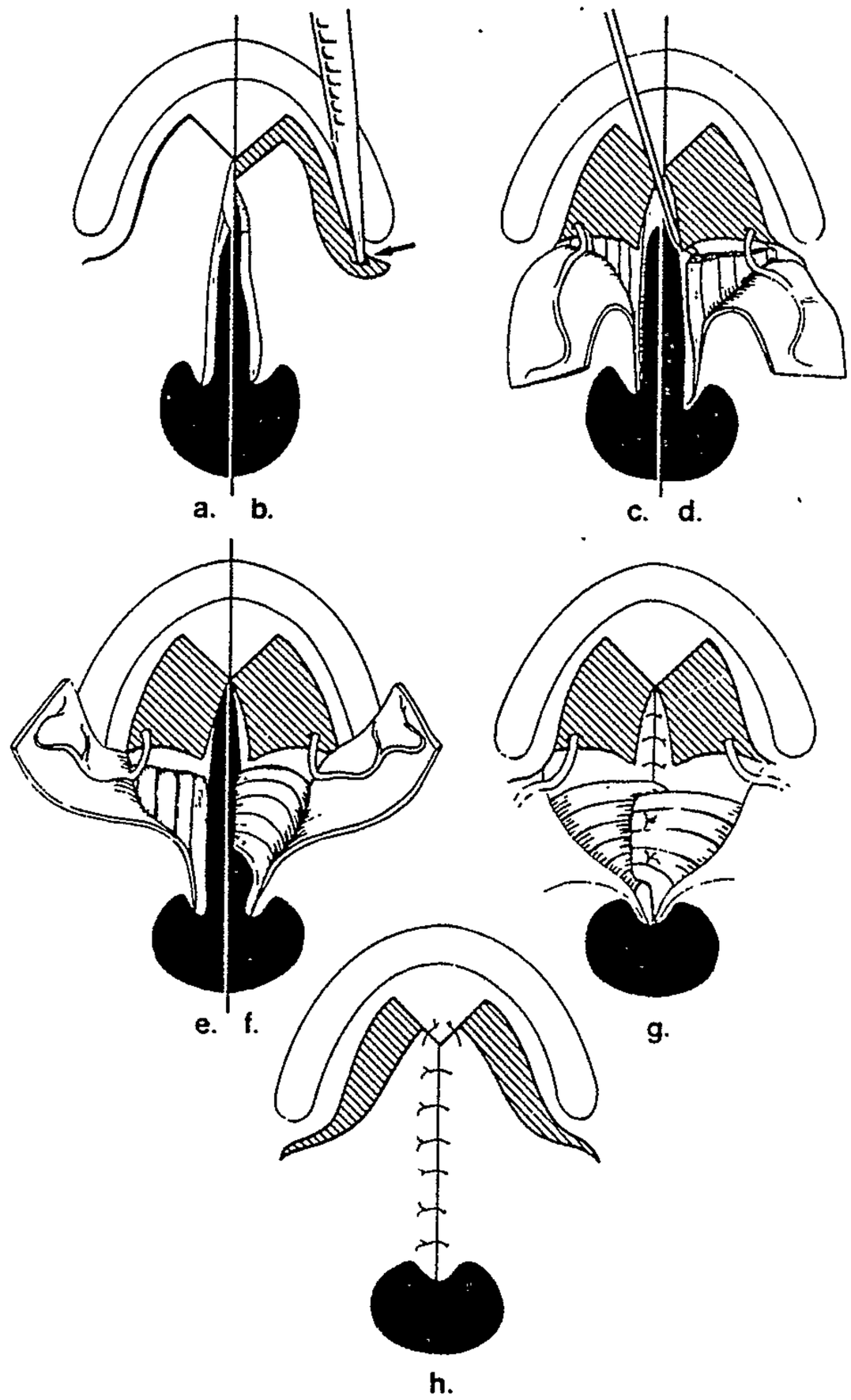

FIGURE 9

The Wardill-Kilner push-back operation, modified after Braithwaite for closure of the secondary palate. NB - Slashed lines indicate raw surfaces. (From Edwards and Watson 1980)

the midline. This involves freeing the aponeurotic and muscular attachments of the soft palate from the back of the hard palate and undermining the nasal mucosa as far as possible from the upper surface of the hard palate. The greater palatine vessels are also teased out of the greater palatine foramina or are divided. Bishara (1974) found no difference in maxillary growth between patients who had Wardill V-Y palatal repairs with and without division of their greater palatine vessels. Kremenak et al (1978) carried out various V-Y palatoplasties on Beagle dogs to study its effect on maxillary growth. They found that severance of the neurovascular bundle led to non-survival of the flaps and that contraction during the healing of open palatal wounds led to aberrations in maxillary growth. The hamulus of the pterygoid plates is also fractured to release the tensor palati muscle, therefore facilitating closure of the soft palate.

Due to the push-back operation, much larger raw areas are left antero-laterally in the hard palate to heal by secondary intention than with the Von Langenbeck procedure. Therefore, more scar tissue should be formed with the push-back operation and this would mean that there should be more maxillo-facial deformity and crossbites developing with the push-back procedures. Ross and Johnston (1972) hypothesized that as a result of more extensive dissections and the hamulus being fractured with the push-back operation, a continuum of

scar tissue joined the maxillae, the palatine bones and the pterygoid plates. They felt that a maxillary fibrous ankylosis would take place and inhibit maxillary growth too. Kremenak et al (1978), however, found no such ankylosis in Beagle dogs who had undergone V-Y palate operations with pterygoid plates dissections.

Palmer et al (1969) found that children who had Von Langenbeck palate repairs had less incisor crossbites and less buccal segment collapse than those who had push-back repairs. Blocksma et al (1975) also found that the incidence of maxillary deformity and dental arch collapse was higher in cases who had push-back procedures done than in those who had Von Langenbeck operations. Dahl et al (1981) also found similar results in their study of Norwegian and Danish cleft cases. To isolate the effects of the palate operation only, Jonsson and Thilander (1979) used cases with clefts of the palate only in their study. They too found that their cases who had been operated by the Von Langenbeck technique had a lower frequency of crossbite occlusion when compared to those who had the push-back repair. However, Bishara et al (1976A) found no statistical differences in the anterior-posterior and vertical maxillary growth and in the incidence of malocclusion between the two methods of palatal repair.

Both methods of palatal repair are widely used throughout the world and the results reported are quite

different and difficult to compare. This can be explained by the variations in operative techniques amongst different surgeons even when performing the same operation, variations in the extent of the clefting and differences in methods and timing of assessment. Here at the Royal Alexandra Hospital for Children, the Wardill V-Y push-back operation is used to repair the secondary palate.

CHAPTER 3

METHODS USED TO REDUCE OR PREVENT COLLAPSE OF THE MAXILLARY ALVEOLAR SEGMENTS AND CROSSBITE MALOCCLUSIONS

There have been many different strategies used by surgeons and orthodontists in their attempts to decrease or prevent medial collapse of the maxillary alveolar segments and crossbite malocclusions developing in complete cleft lip and palate patients. These include:-

a) The modification of the times or ages at which surgical repairs are carried out.

b) The use of early maxillary orthopaedics to place or maintain the alveolar segments in their optimum positions.

c) The use of two-layered soft tissue flap closures in the alveolar cleft region to minimize or prevent the contraction phase of wound healing. This also prevents or reduces the amount of scar tissue formed and the soft tissue acts as a filler in the alveolar cleft region.

d) The use of bone-grafting to maintain an intact arch form.

e) The use of periosteoplasty to induce bone formation in the alveolar cleft region.

The above mentioned methods will now be reviewed in more detail.

3(A) TIMING OF SURGICAL REPAIR

Hotz (1973) believed that the goal of cleft lip and palate treatment was to restore anatomical continuity and normal function with the least possible damage to growth and development through surgical intervention. In order to meet these requirements, compromises are inevitable. A common way of minimising the risk of medial collapse of the maxillary arches and post-surgical aberrations of facial growth has been to simply postpone surgical repairs until a later age. The different philosophies for the varied timing of surgical treatment and their effects on function, maxillary growth and the occlusion of cleft patients relate to the different elements of the cleft defect: lip, nose and posterior palate.

A) TIMING OF CLEFT LIP AND NOSE REPAIR

There are many different schools of thoughts as to when the lip should be repaired. In some parts of the world, infants are operated upon during the first forty-eight hours of birth so that the parents do not have to ever see their child's deformity. However, there are many difficulties with doing a repair at such a young age, such as the lack of soft tissue to work with, and the risk that associated congenital anomalies may not have been diagnosed yet and other life-threatening complications will arise.

There are also surgeons who carry out a repair of the lip, hard and soft palate all in the one operation in the neo-natal period. (Davies 1966, Huddart et al 1969). The main reasons for doing this simultaneous repair are to reduce the number of times a very young child would have to be hospitalised and separated from his mother for surgery and to solve the problem of dealing with babies who will not be brought back for follow-up treatment after their mothers are discharged from the maternity home. Huddart et al (1983) use presurgical orthopaedics to time this repair. They feel that the repair should be done when the segments are in their corrected positions and the cleft is reduced by about 50% of its original size.

The majority of surgeons prefer to wait until the child is older, usually between six weeks to six months old before operating. This delay allows the lip and nose to increase in size while the cleft decreases in size, thereby enabling more accuracy (especially when attempting Delaire's (1978B) functional closures) and less tension in the surgical repair thus lessening the chances of medial collapse of the maxillary arches. The older child is also more able to withstand a longer operation and the orthodontist can use this time pre-surgically to move the segments of the alveolar arch into proper alignment. The parents, in the meantime, can be assisted in coming to terms with the child's deformity and be prepared for the various problems which

may arise during childhood.

Another favoured way of assessing timing of repair was based on the "rule of tens" which stated that surgery should be delayed until the infant weighed 10 pounds, had a haemoglobin concentration of 10g/dl and was at least 10 weeks old.

Crikelair (1969) in reviewing all the possible reasons for repairing a cleft lip, concluded that the only reason for surgical repair of a cleft lip was to make the child look as normal as possible eventually. He felt that lip repair was not an emergency operation and that the older the child was, the larger the tissues would be and therefore the easier the surgery would be, with less tension resulting. This was also a finding of Hagerty and Hill's (1963) study. They found that children who had their lip repairs deferred until they were 2 years old had less lingual version of the upper incisors.

There is also disagreement over whether the nasal deformity should be corrected at the time of the lip repair or left until later. There are those who believe that early nasal surgery will lead to scarring and subsequent growth inhibition and further nasal deformity. (Musgrave 1971, Abyholm et al 1981). The opposing and recently more popular view is that early nasal surgery to place the alar cartilages and nasal

soft tissues into their correct positions will allow the nose to grow and develop normally. (Randall 1964, Moss 1971, McComb 1975, Delaire 1978B, Mulliken 1985).

B) TIMING OF PALATE REPAIR

1) Closure of the Primary Palate (anterior palate)

Many surgeons (eg: Manchester 1965, Dey 1974, Millard 1976) repair the anterior alveolar cleft and floor of the nose at the same time as the lip is repaired because they have more direct access to the area without the repaired taut lip being in the way. This also avoids the problem of residual fistulae in the area which may be difficult to close later on because of the lack of access, and fistulae here can also make life awkward for the young patient. In speech, he may have trouble with nasal air escape on pronunciation of some consonant sounds, and food, fluid and nasal secretions can pass from the mouth up to the nasal cavity and vice versa.

Millard (1976) feels that the ideal time for anterior alveolar cleft closure is when the alveolar segments are in near approximation without being in actual contact, but in good alignment and before final lip closure. He feels that this is best achieved by pre-surgical orthopaedics or an early lip adhesion procedure.

There are, however, some people who feel that alveolar closure should be left till the child is older and has

completed a large proportion of his or her growth. The width of the alveolar cleft decreases too with growth making surgical closure easier and with less tension. These people also feel that early operations on the growing bony parts of the cleft will result in scarring of the maxilla, collapse of the alveolar segments, damage to tooth buds and subsequent growth inhibition of the maxilla. (Slaughter and Pruzansky 1954, Burian 1955, Schweckendiek 1955, Graber 1964, Bernstein 1972, Hotz and Gnoinski 1976, Ponitz and Spyropoulos 1979, Friede et al 1980, and Trier and Dreyer 1984). Closure of the alveolar cleft usually involves the raising of a vomer/septal flap or some mucoperiosteal flaps and may therefore involve trauma to growing periosteum and to the vomerine-premaxillary suture which according to Friede (1978) will lead to impaired maxillary growth. According to Brash and Todd (quoted by Graber (1950)), the anterior maxillary arch will have developed to 5/6ths of its definitive size by the fifth year of life. Graber, therefore, urged that palatal surgery be delayed till the child is four to five years old to avoid subsequent maxillary deformities developing. Dey (1974) disagrees with these people. He feels that early surgery on the anterior palate does not necessarily interfere significantly with bony growth and that the maxillary deformity and crossbites are due to medial rotation of the maxillary buccal segments which occur very rapidly after lip repair.

In a study of 45 patients with complete clefts of the lip and palate and who had their alveolar clefts repaired in infancy, Bernstein (1972) found a 10% increase in the incidence of anterior collapse of the buccal segments and a 5% increase in the incidence of posterior crossbites when they were compared with cases that did not have their alveolar clefts repaired in infancy. He felt that the early repair of the alveolar cleft tended to anchor the anterior aspect of the maxillary alveolar process onto the premaxillary segment resulting in collapse of the buccal segments. He also felt that orthodontic expansion of this collapse would be no problem but was concerned that the stability of the correction would be a problem due to scarred tissue tensions from the alveolar cleft repairs. He also feared that scarring from early surgery to the palate would inhibit lateral maxillary growth. As a result of his findings, he advised against early surgery to the alveolar cleft. I feel that his results only show a small increase in the occurrences of crossbite and alveolar collapse and this small increase is outweighed by the functional advantages that the patient enjoys with early alveolar cleft closure.

It appears that timing of closure of the anterior alveolar cleft is still a very controversial subject with some advocating early closure for functional purposes while others prefer to wait until the child is at least 4 to 5 years old, or later thus supposedly

avoiding maxillary growth disturbances. Here at the Royal Alexandra Hospital for children, the anterior palate is closed at the same time as the lip which is when the baby is between six weeks and three months old for reasons previously mentioned.

2) Closure of the Secondary (posterior) Palate

The secondary palate consists of the hard palate anteriorly and the soft palate posteriorly. The ideal timing for closure of the hard palate is also very controversial and the age selected for repair is usually dependent upon the philosophy of the surgeon and team responsible for the cleft child's rehabilitation.

One philosophy is that early repair of the complete palate will obviate the need to use a prosthetic obturator and lead to better speech and hearing outcomes for the patient while the other philosophy is that the early repair of the hard palate will lead to scarring of the maxilla and subsequent growth inhibition and maxillary deformity.

The advocates of early repair of the hard and soft palate feel that to develop good speech, the child must have a long and complete palate for velopharyngeal closure, for good articulation and to reduce the incidence of middle ear infection thus improving the child's hearing. Middle ear infections and improper Eustachian tube drainage (due to abnormal tensor veli

palatini muscle attachments) are the two main causes of hearing loss in cleft palate children (Veau 1931, Manchester 1965, Kaplan 1981, Huddart et al 1983). They believe that the earlier the palate is repaired, the sooner the soft palate and tongue function normally and speech can therefore develop normally without developing any compensatory actions first. Early repair of the complete palate restores normal muscular forces in the nasopharyngeal region, prevents protrusion of the tongue into the cleft, allows proper Eustachian tube drainage, thus decreasing the incidence of middle ear infections and resulting in better hearing and speech development. Kaplan (1981) feels that because speech begins at approximately nine months of age, the soft palate should be repaired as soon after three months of age as possible to allow for the resolution of oedema and the maturation of scar tissue before the soft palate can function properly. There have been many studies showing that early repair of the palate results in better speech development and some of these have been reviewed by Millard (1980) and Kaplan (1981).

The advocates of delayed hard palate repair (Gillies and Fry 1921, Slaughter and Pruzansky 1954, Schweckendiek 1955, Graber 1964, Hotz and Gnoinski 1976, Friede et al 1980) agree that early repair of the soft palate will be better for speech but they fear that early repair of the hard palate will cause maxillary growth disturbances resulting in maxillary retrognathia and an increased

incidence of crossbite malocclusion. They based their philosophy on the studies, by Graber and others, of repaired cases in the late 1940's which implicated early surgery as the cause of most of the gross mid-facial deficiencies. It has since been shown that traumatic procedures such as those of Brophy's (1923), who compressed and wired the two palatal halves of the maxilla together and Denis Browne's (1949) premaxillary set-back operation were the cause of these facial deformities rather than the early timing of the surgery.

Observations of unrepaired cleft cases by Mestre et al (1960), Ortiz-Monasterio et al (1966), Bishara et al (1976B) and others showing no gross maxillary growth deficiencies, also helped substantiate their beliefs to delay hard palate closure till the cleft child has completed most of his growth. Graber (1950) advocated delaying closure of the hard palate till the child was four to five years old but Schweckendiek (1955) recommended that hard palate closure be delayed till the child is 12 to 14 years old when jaw growth is virtually complete. Hotz and Gnoinski (1976) and many others have taken up Graber's recommendation.

Friede et al (1980), Poupard et al (1983), Bardach et al (1984B), Hotz et al (1984) and Jorgensen et al (1984) have all shown improved occlusion and facial growth in children who had delayed hard palate surgery compared to early palate repair cases. Bardach et al (1984B) and

Ross (1984B) who studied Schweckendiek's patients found near normal facial growth and occlusion. Except for Schweckendiek's patients, many of these patients had not reached their pubertal growth spurt at the time of the study and this may have had an effect on the results.

On the other hand, Blijdorp and Egyedi (1984), Gavron et al (1984) and Robertson (1984) have found no differences between the occlusion and facial growth of children who had delayed hard palate closure and those who had early palate closure. (Early closure is usually done before four years of age). Robertson's study is an 11 year study while the other two studies are on patients that are now fully grown.

Kremenak et al (1985) also looked at the effects of palatal surgery (a simple mucoperiosteal excision), performed at different ages, on the subsequent maxillary growth of 50 non-cleft Beagle pups. They found no significant differences in arch and jaw width increases between the different experimental groups. All experimental groups, however, exhibited significantly less growth than the unoperated control group. They concluded that: (1) the traditional assumptions about the growth advantages of late palatal surgery may have been ill-founded, and (2) palatoplasties performed prior to the eruption of primary molars may be no more "damaging" to maxillary growth than those performed soon after their eruption, and may be only slightly more

damaging than those postponed until late in the primary dentition.

While there is evidence to show that unoperated palates and those that are delayed until after the age of 12 years frequently result in excellent maxillary growth and skeletal relationships, the data regarding delaying hard palate closure until age of four to eight years are quite equivocal and contradictory. Ross (1984B) even found a trend towards less favourable facial growth following the delayed hard palate procedures.

The speech results of children with delayed hard palate closures have been shown to be disappointing and Witzel et al (1984) confirm this with their recent review of the many studies done on speech of children with delayed hard palate closure. Because of poor speech results, many centres are now reverting back to earlier total palate closures.

From x-ray studies showing the posterior position of the tongue and the increased distance between the pterygoid plates in unrepaired cleft patients, Malek et al (1984) has introduced a new sequence to the repair of complete clefts of the lip and palate. He closes the soft palate first at three months of age after some orthopaedic treatment, and at six months, the lip and hard palate are closed together completely without raising any mucoperiosteal flaps. He repairs the soft palate first

to prevent the tongue from falling back into the nasopharynx and causing more lateral displacement of the pterygoid processes. He believes in early repair of the soft palate first to normalise tongue position and allow it to exert regular pressure anteriorly on the maxillary alveolar segments. With this tongue pressure he counter-balances the pressures from the lip repair which would have caused collapse of the alveolar segments if the lip had been repaired first instead of the palate. The short term evaluation of results of dental occlusion and speech appear to be quite promising.

Kaplan (1981) has listed four recommended approaches to palate closure:-

1) Delayed complete palate repair (12 to 24 months) - the most popular approach - a compromise between getting some good speech and not disturbing growth too much.
2) Late complete palate repair (2 to 5 years) - emphasis here is on facial growth.
3) Early complete palate repair (3 to 9 months) - emphasis here is on speech results.
4) Early soft palate repair (3 to 9 months) and delayed hard palate repair (5 to 15 years) - an attempt to achieve both good speech and facial growth results.

At the Royal Alexandra Hospital for Children, posterior palate closure is done early (between 9 to 12 months) where possible to allow for normal development of

swallowing, speech, respiration and hearing, (N.B. Lip and anterior palate are repaired at six weeks to three months). It should also be noted that the surgical repairs for these children match the embryonic concept of cleft formation by completely repairing first the primary palate defect and then the residual secondary palate cleft (Godfrey 1984).

It can therefore be seen that timing of palate closure is a very controversial subject. The results of the different studies of the effects of timing of surgical repair of the clefts on maxillary growth and the occlusion are conflicting as many other different factors are influencing the outcomes of these studies as well. From longitudinal growth studies, Pruzansky et al (1973) and Berkowitz (1985) came to the conclusion that age alone was not a primary variable in determining the effects of the cleft repair on facial growth. They felt that the quantitative and qualitative characteristics of the defect, the general health and the genotype of the individual were determining factors.

3(B) EARLY MAXILLARY ORTHOPAEDICS

Early maxillary orthopaedics (also known as pre- and post-surgical orthopaedics) is used in conjunction with primary bone-grafting, or Muir/Dey soft tissue stabilizing flaps, to prevent collapse of the maxillary segments and the subsequent crossbite malocclusion so commonly seen in cases of clefts of the lip, alveolus and palate. Its aims are:- (Huddart 1967(A), Hotz 1973, Brogan 1973)

1) to reduce the width of the alveolar and palatal cleft,
2) to reposition displaced alveolar and lip segments prior to lip repair,
3) to stabilize alveolar segments thus preventing their collapse after lip repair,
4) to normalize oral functions and,
5) to create or maintain regular intermaxillary relationships before and after surgical repairs.

It has also been found to have a social benefit (Huddart 1984) in that it improves the morale of the parents by providing care and attention at a very early stage. The advocates of early maxillary orthopaedics feel that by placing the elements of the jaw, nose and lip into their correct relationships and by reducing the width of the cleft, surgical repair is facilitated and the commonly seen subsequent development of arch collapse and gross dental deformity may be reduced or avoided. (McNeil

1954, Brauer and Cronin, 1964, Battle and Whitfield 1970, Huddart 1979, Larson et al 1983 , Brogan 1986).

One of the first advocates of early maxillary orthopaedics was McNeil (1954) who, by using an oral appliance, aimed to bring about a reduction in the width of the cleft by stimulating growth of the palatal shelves. Burston (1960) who further developed the technique felt that increased growth of tissue on the margins of the cleft was the result of the appliances stimulating the blood supply of the palate and keeping the tongue out of the cleft.

Studies by Huddart and Crabb (1977), however, showed that the appliances actually retarded tissue growth. Despite this finding, pre-surgical orthopaedics is found to produce a significant narrowing of the cleft and Huddart (1979) felt that this was because the appliance actually prevented the maxillary arch from becoming wider with subsequent cranio-facial growth and with unbalanced muscle action due to the cleft. (The plate prevented the tongue from forcing its way into the cleft and causing further displacement of the segments in both the horizontal and vertical planes). This allowed growth of the palatal shelves to take place. Another finding was that with use of the appliance, there was a reduction in the steepness of the slope of the palatal shelves, i.e. the shelves became more horizontally oriented which also helped to narrow the palatal cleft.

A narrow cleft enables surgical repair to be carried out with less tissue undermining, less tension and therefore with less likelihood of repair breakdown. Subsequent collapse of the alveolar segments can thus be avoided. (Hotz and Gnoinski 1979).

Repositioning of displaced soft tissues and bony elements will facilitate surgical repair and improve the aesthetics of the repair. Arch forms and deviated nasal septums can be improved by the use of pre-surgical orthopaedics. (Godfrey 1985). There are many different types of pre-surgical orthopaedics carried out but they fall basically into two categories - the "active" type and the "passive" type. "Active" pre-surgical orthopaedics comprises active repositioning of the alveolar segments using plates with springs and screws to expand collapsed alveolar segments or using plates made from sectioned and re-aligned models. (McNeil 1954, Huddart 1961, Brogan 1973). "Passive" pre-surgical orthopaedics comprises the "growth-guidance" plates of Hotz and Gnoinski (1976) and Rosenstein (1969). These plates do not have active elements to align the segments. Hotz and Gnoinski (1976) use a plate of soft and hard acrylic resin - the hard acrylic base provides for stabilization of the segments while the soft lining adapts to the underlying growing structures. The hard parts are also adjusted to guide further growth. The increase in the size of the non-cleft alveolar arches is considerable during the

first six months of life (Sillman 1964), and Hotz (1973) feels that this growth spurt should not be inhibited amongst cleft patients by untimely surgery but should be harnessed to obtain proper alignment or even approximation of the alveolar segments. Approximation of the alveolar segments in a butt-joint would also help to prevent further collapse of the arches after lip surgery. (Huddart 1967 A).

In bilateral clefts, there is usually a forward positioning of the premaxilla relative to the buccal alveolar segments (Huddart 1970). This has the effect of separating the prolabium from the lateral elements of the upper lip. Retrusion of this premaxilla can be achieved by means of gentle extra-oral strapping across the premaxilla and prolabium, attached either directly to the face or to some form of head cap. In complete clefts, premaxillary strapping should never be used without an intra-oral appliance to stabilize the maxillary alveolar segments or else the force of the strapping on the cheeks may cause severe contraction of the maxilla. (Ross and Johnston 1972). See Figure 7. Hotz (1983) disagrees with the use of strapping because she feels that the premaxilla is not protrusive but is in the correct position.

Some operators continue to use plates to maintain the correct lateral dimensions of the alveolar segments after lip surgery (Hagerty 1957, Rosenstein 1969, Hotz

and Gnoinski 1976, Lennartsson et al 1984). In doing so, they prevent the medial rotation and collapse of the alveolar segments which tend to occur after lip repair. This is called post-surgical orthopaedics. Hotz and Gnoinski (1979) feel that after lip closure, the orthopaedic plate serves as a retainer and spreads the force of the united lip musculature evenly over the whole surface of the alveolar arch thus avoiding local pressure and collapse. They advocate plate usage till soft palate repair takes place. Rosenstein (1969) and Jacobson and Rosenstein (1984) feel that their passive appliance is for maintaining the posterior width of the maxillary segments while the pressure of the newly repaired lip moulds the premaxilla back into alignment. After the segments are thus aligned, an autogenous alveolar bone graft is placed to stabilize the segments in their improved arch form. (See Section on Bone-grafting). Some workers such as Brogan (1973) and Dey (1974) advocate the use of soft tissue flaps to stabilize the alveolar segments (See Section on "Two-layered flap repairs of the anterior palate"). Brogan (1973) advocates the use of the Muir mucosal flap (Muir 1966) to stabilize his arches and prevent their collapse after pre-surgical alignment, whilst at the Royal Alexandra Hospital for Children, a bulky Dey-triangular flap (Dey 1974) is used for arch stabilization.

The fourth aim of early maxillary orthopaedics is to

normalize oral functions. The plate facilitates feeding by acting as an intact palate enabling the baby to suck normally on a nipple. It also acts as an obturator, keeping the tongue out of the cleft preventing further displacement of the alveolar segments and protecting the nasal septum from irritations. This plate separates the oral and nasal cavities and facilitates their separate functions, enabling the tongue to adopt a more normal posture in swallowing and later on in speech. It is hoped that by restoration of the functional matrix, facial growth will proceed normally. (Hotz and Gnoinski 1976, Lubit 1976, Fisher, Godfrey and Stephens 1976).

Long term evaluation of early maxillary orthopaedics have revealed conflicting results. As previously mentioned, it was hoped by advocates, that the use of early maxillary orthopaedics would result in better occlusions and fewer crossbites forming later on. Robertson (1973), O'Donnel et al (1974) and Peat (1982) have all found less crossbite malocclusions in children who have had pre-surgical treatment. Robertson (1973) found that the deciduous occlusion of a group of children who had undergone pre-surgical orthopaedics was significantly better than the group that did not undergo pre-surgical orthopaedics. The upper dental arches of the children who did not receive early treatment were significantly narrower in the canine and molar region and they had a more severe crossbite scoring. However, his two groups of children were from different areas and

had been treated by different surgeons, so other variables such as different surgical techniques may have to be considered when looking at these results.

More recently Peat (1982) studied the effects of pre-surgical orthopaedics on children with complete bilateral clefts. He found that the incidence of anterior crossbite was significantly less in pre-surgically treated cases than in the untreated cases. He felt that by reducing the malrelationship between the premaxilla and maxillary segments, it was possible to reduce the length of incisions used in lip reconstruction, thus reducing the amount of scar tissue produced. This was his explanation for the decreased incidence of incisor crossbite occurring in the pre-surgically treated cases.

In contrast, Huddart (1973) found no significant differences between the deciduous occlusions and arch forms of a group of 40 pre-surgically treated children and a group of 13 non-pre-surgically treated children from the Birmingham Regional Plastic Unit. Larson et al (1983) too, found no significant differences between the occlusion of pre-surgically and non-pre-surgically treated children with unilateral clefts in both the deciduous and mixed dentition stages except that the pre-surgically treated group had larger overjets than the non-treated group.

The long term use of post-surgical orthopaedics to prevent collapse of the maxillary segments has been studied by Hotz and Gnoinski (1976), Hagerty and Mylin (1981) and Lennartsson et al (1984). Hotz and Gnoinski (1976) found improved facial growth, less maxillary collapse and better occlusions in their survey of cleft cases that had reached the mixed dentition stage. However, these were also cases subjected to their changed surgical regime which involved delaying hard palate closure till the patient was 6 to 8 years old. Studies of their earlier cases (Gnoinski 1982) using post-surgical orthopaedics and early hard palate closure (2 years of age) showed that post-surgical orthopaedics did not prevent maxillary collapse and crossbites occurring in the permanent dentition. Hagerty and Mylin (1981) found that a high proportion of arch symmetry was maintained when they used a pin-retained orthopaedic appliance until the hard palate was repaired at 6 years of age. Arch asymmetry was their criterion for judging arch collapse in unilateral cleft cases. Lennartsson et al (1984) found that post-surgical orthopaedics had no long term effects on the maxillary dimensions and dental occlusions of unilateral cleft lip and palate patients.

The long term effects of early maxillary orthopaedics on facial growth have been studied cephalometrically by Robertson (1973,1983), Gnoinski (1982), Peat (1982), Nordin et al (1983), and Ross (1984B). Robertson in 1973, and in 1983, found that patients who had undergone

pre-surgical orthopaedics had more satisfactory facial profiles (at ages 5 years and 10 years old respectively) than those who had not undergone pre-surgical orthopaedics. The maxilla was found to be more definitely retrusive in those cases where pre-surgical orthopaedics had not been employed. To eliminate the possibility of surgical variations, the children of the latter study were all operated on by the same surgeon.

Nordin et al (1983) also found that maxillary growth in patients who had early maxillary orthopaedics was closer to normal than those who did not have early orthopaedic treatment.

On the other hand, Gnoinski (1982) in a long term study of very early cases who had undergone McNeil-type pre-surgical orthopaedics (1954) and conventional surgery, found that prolonged orthopaedic and orthodontic periods did not prevent unfavourable skeletal development.

Ross (1984B) in his international study of cleft treatment from major centres throughout the world concluded that pre-surgical orthopaedics had no influence on the anterior-posterior skeletal development of complete unilateral cleft lip and palate patients. Peat (1982) also confirmed this finding in bilateral cleft lip and palate cases.

The other significant long term finding of the effects of pre-surgical orthopaedics is that tongue-tip behaviour patterns in older pre-surgically treated cases are significantly closer to normal than in non-pre-surgically treated cases and this helps in speech development. The plate reduces the space available for the tongue to a normal amount (Stuffins 1979).

Pruzansky (1964) and Mazaheri et al (1971) felt that lip repair by itself would reduce the width of the cleft and correct the positions of the displaced alveolar segments without the need for pre-surgical orthopaedics. They noted that the incidence of malocclusion (crossbite occurences) was no greater in their cases without pre-surgical treatment than in those cases that had pre-surgical treatment. Pruzansky (1964) also pointed out that not all arches collapsed after lip repair and that only approximately 40% of his cases exhibited lingual crossbites and these were easily corrected orthodontically later on. The cost of the treatment and the number of visits the child had to make to obtain early maxillary orthopaedic treatment were also of concern to these people. They felt that the cleft patients' co-operation was also taxed heavily with their constantly having to wear an appliance and visit specialists.

The conflicting results of different long term evaluation studies of early maxillary orthopaedics are

due to the many varied types of appliances and methods used, variations in the intensity and duration of appliance usage, the different surgical procedures used, differences in timing of repairs, the different methods of treatment assessment as well as many other variables. These variables make the comparisons between different studies very difficult.

A review of the literature shows no conclusive evidence that early maxillary orthopaedics alone prevents arch collapse and dental deformity or that it reduces the subsequent need for orthodontic treatment. Its long term effects on maxillary growth and the occlusion are difficult to assess because other subsequent influences such as the effects of surgery are taking place at the same time. It appears that to prevent arch collapse after surgery, early maxillary orthopaedics should be used in conjunction with some form of stabilization such as bone grafting or bulky soft tissue flaps.

The overall value of early maxillary orthopaedics seems to be its potential to facilitate lip and palatal surgery by improving the spatial relationships between the different bony segments and by improving the ratio between the width of palatal tissues and the width of the cleft. It is also used for its ability to normalize oral and nasal functions and for its social benefit.

3(C) TWO-LAYERED FLAP REPAIRS OF THE ANTERIOR PALATE

A cleft of the alveolus and anterior palate can be closed by raising a mucoperiosteal or mucoperichondrial flap from the nasal septum (a vomerine or septal cartilage flap) and suturing it to either the nasal mucosa of the lateral wall of the nose or to the mucoperiosteum of the opposite edge of the cleft. (Pichler 1926, Veau 1931). This one-layer closure leaves a raw oral surface to heal by secondary intention and the contraction phase of the healing wound together with the scar tissue formed subsequently will drag the edges of the cleft together and contribute to collapse of the alveolar arches and crossbite formation. (Muir 1966, Battle and Whitfield 1970, Kremenak 1984). This one-layer closure also frequently breaks down due to tension at the suture lines or to infection and results in a fistula forming. The early alveolar closures were one-layer closures. See Figure 10A and 10C.

To avoid the laying down of unnecessary scar tissue and fistula formation, two-layered closures were devised. In 1926, Campbell utilized a vomer flap, which was based along the cleft margin, and a lateral flap to close the anterior palate. These flaps were overlapped across the cleft leaving no raw areas in the mouth or nasal floor and therefore no reason for contracture. See Figure

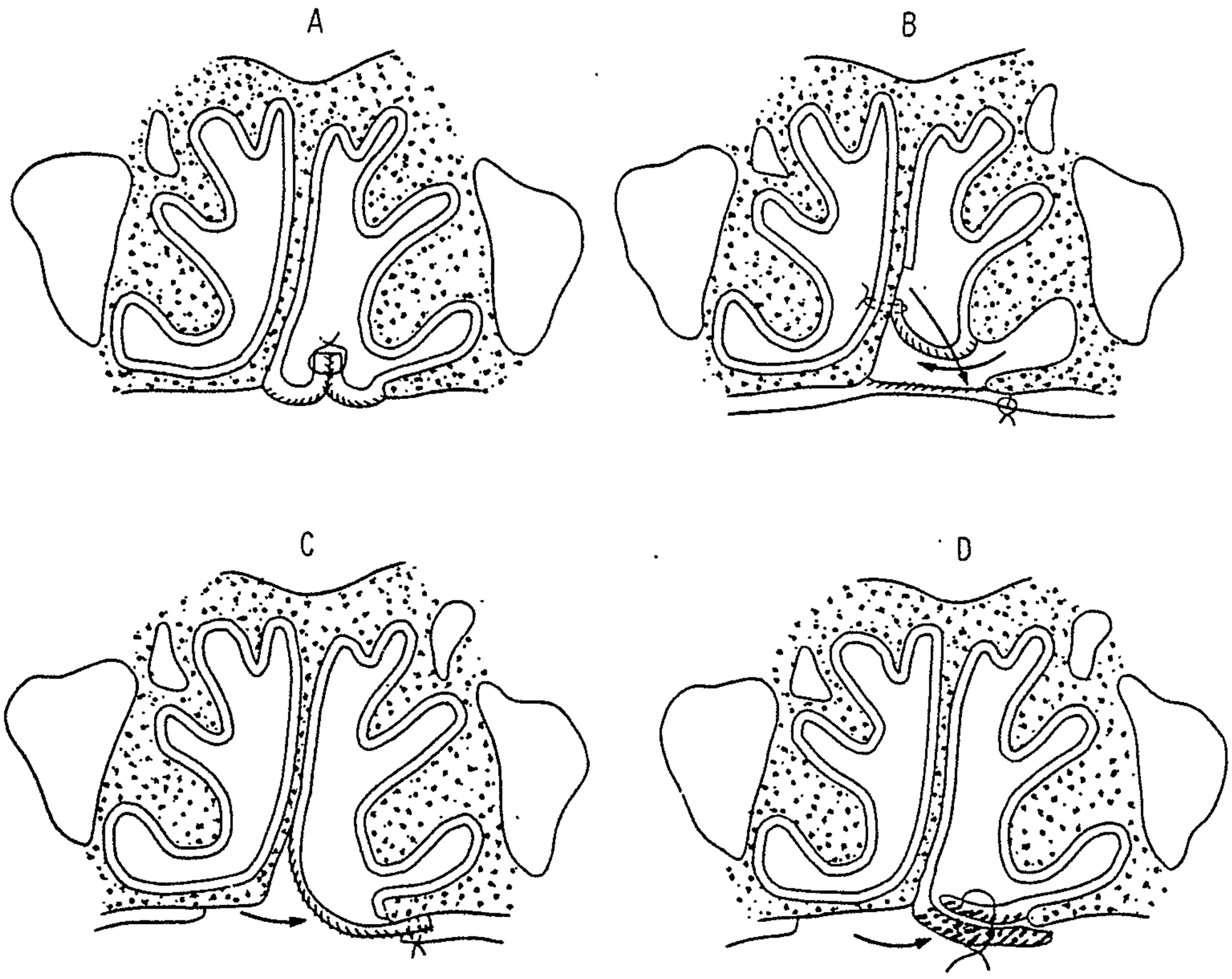

FIGURE 10

Cross-section diagrams of various types of repairs of the anterior palate, with slashed lines indicating raw surfaces. (A) Closure technique commonly used. (B) Campbell-type flaps. (C) Veau-type flap. (D) Closure with our turnover flaps. (From Isshiki and Morimoto 1968)

10B. This two-layered closure was later used by Backdahl and Nordin (1961) and others for bone grafting. Veau (1938) who also believed in the surgical principle of closing raw areas, later devised a flap of palatal mucoperiosteum based posteriorly which he swung across the cleft to reinforce the nasal closure behind the alveolus. See Figure 11. However, this flap did not reach forward into the area of the alveolar cleft where healing breakdown frequently occurred and fistulae are commonly found.

Burian (1955) noticed that in operated complete cleft lip and palate cases where the alveolar segments did not come into contact in the region of the alveolar cleft, there was little or no micrognathia and the dental occlusion was normal except for the break at the alveolar cleft. He therefore felt that it was inadvisable to bring the poles of the cleft together. In order to prevent collapse and contact of the alveolar segments and fistula formation, he placed a flap of labial lip mucosa into the alveolar cleft to reinforce the single-layered nasal closure. See Figure 12. He later dropped this flap after discussions with Veau, who considered the resultant gap in the alveolar process as an imperfection much worse than a naso-buccal fistula. In follow-ups, Burian observed that except for a transverse constriction in the premolar region, those patients operated with this labial flap had less alveolar deformity than those without the labial flap

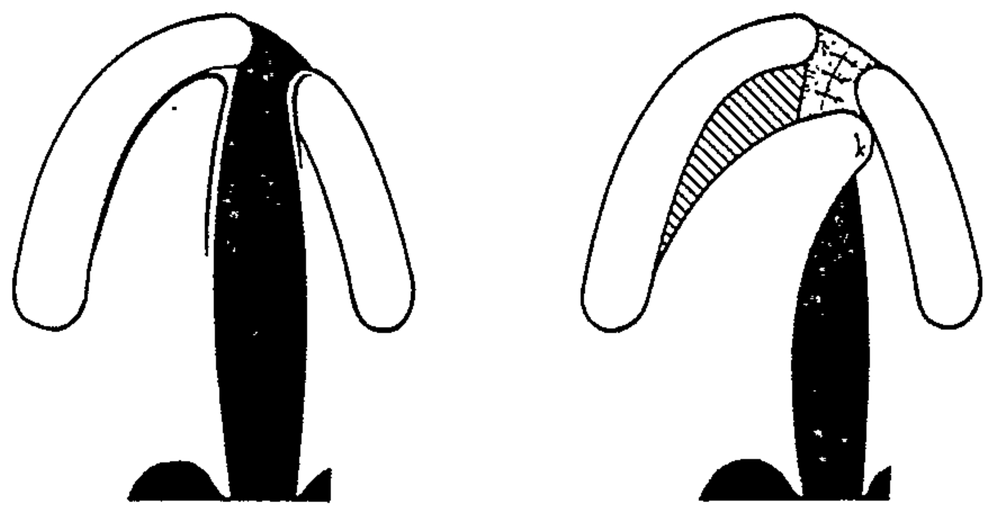

FIGURE 11

Veau mucoperiosteal flap for closure of oral aspect of anterior palate cleft. Shown in association with nasal mucosal closure of alveolar cleft. Incisions are made and the mucoperiosteal flap elevated and transposed across cleft.
(From Edwards and Watson 1980)

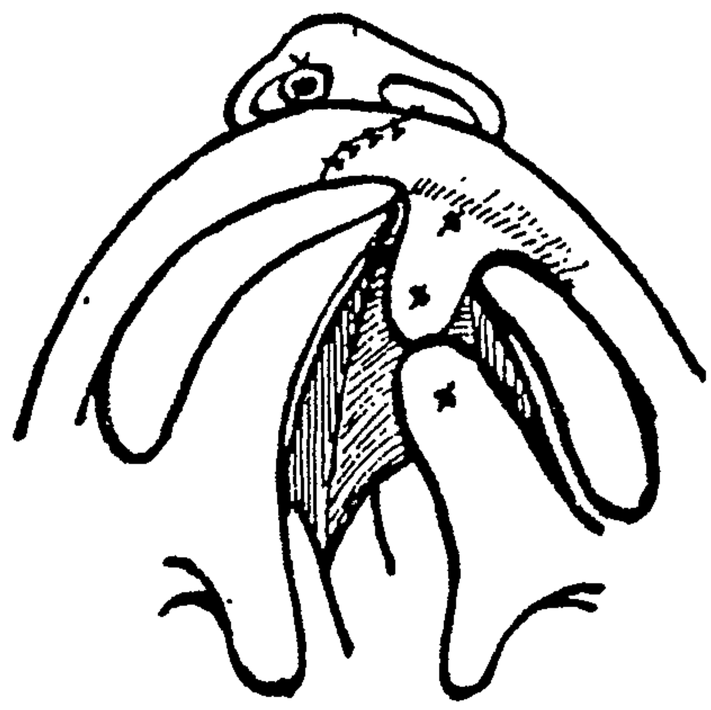

FIGURE 12

Burians' labial flap to reinforce nasal floor closure.
(From Burian 1955)

placed. Here the transverse constriction was thought to be the result of scarring after shifting of the Veau palatal flap so the Veau palatal flap was dropped as well. In 1976, Hotz and Gnoinski reported that they had abandoned the use of the Burian mucosal flap because it resulted in a canine crossbite occurring, each time it was used.

Stellmach (1966) found that with the use of the Burian labial mucosal flap in the repair of the alveolar cleft, there resulted in too much loss of the inner lining of the upper lip. This caused an inward traction of the lip and also resulted in a lip with a narrow vermilion border. He therefore developed a vomerine flap based anteriorly and this flap was turned 180 degrees to achieve oral closure for the nasal layer. He also incorporated this flap into his bone grafting procedures later on.

Muir (1966), who felt that medial collapse of the alveolar segments was due to scar tissue contraction in the alveolar cleft region rather than tension of the repaired lip, also advocated two-layered closures. He used mucosal tissue from the free edge of the cleft lip to reinforce the nasal floor closure. See Figure 13. This tissue could be better spared than the labial mucosal flap of Burian's as it was normally discarded at the primary lip operation. He reported no fistulae or alveolar collapse following this technique.

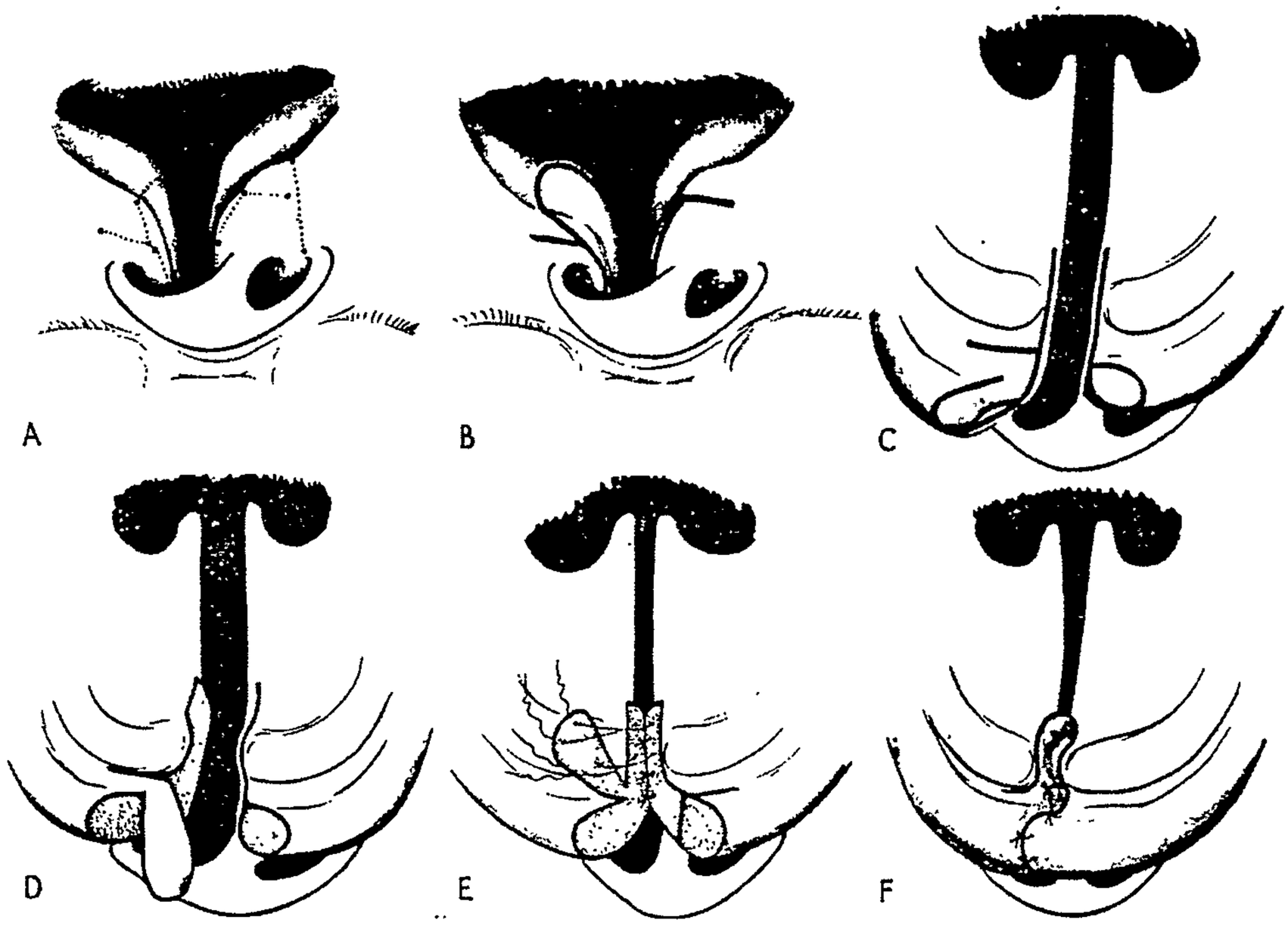

FIGURE 13

The Muir Flap for Anterior Palate Repair.

A, A left cleft lip and palate showing the markings for a triangular flap type of repair.

B, The incisions. The tissue of the free edge of the lip on the lateral (left) side of the cleft will be used for the flap to repair the alveolar cleft.

C, View of the posterior aspect of the lip to show the design of the flap.

D, The flap has been raised on a narrow base.

E. The nasal layer has been sutured and two "A" stitches have been passed through the flap.

F, Shows the flap in position at the completion of the operation.

(From Muir 1966)

McComb and Brogan (1984) feel that the Muir flap not only prevents fistula formation but also minimises scarring and tethering of the arch and also acts as a spacer between the alveolar segments to prevent their collapse. The incidence of anterior and posterior crossbites is therefore decreased as well.

In 1972, Dey also added a bulky triangular soft tissue flap from the inner surface of the lip to his primary anterior palate repair operations. This flap was carried through the alveolar gap and reinforced the closure of the nasal floor. It consisted of muscle tissue and red lining which was mobilized from its attachment to the alar cartilage at its base. See Figure 14. Dey's original objective of this manoeuvre (Dey 1974) was to allow the vertically disposed muscle fibres in the cleft margin to resume a more horizontal line as part of the Orbicularis Oris muscle and to mobilize the nostril fully but he found that a triangular corner of tissue fell naturally into the alveolar cleft and was easily fixed there without tension. He therefore used this triangular flap of tissue to reinforce closure of the nasal floor. According to Dey (1974), this flap appears to prevent narrowing of the alveolar gap after the operation either by eliminating secondary healing on the oral surface of the nasal floor and its subsequent fibrous tissue contraction or by its mere presence and bulk. He has also noticed that the upper incisors appear to maintain

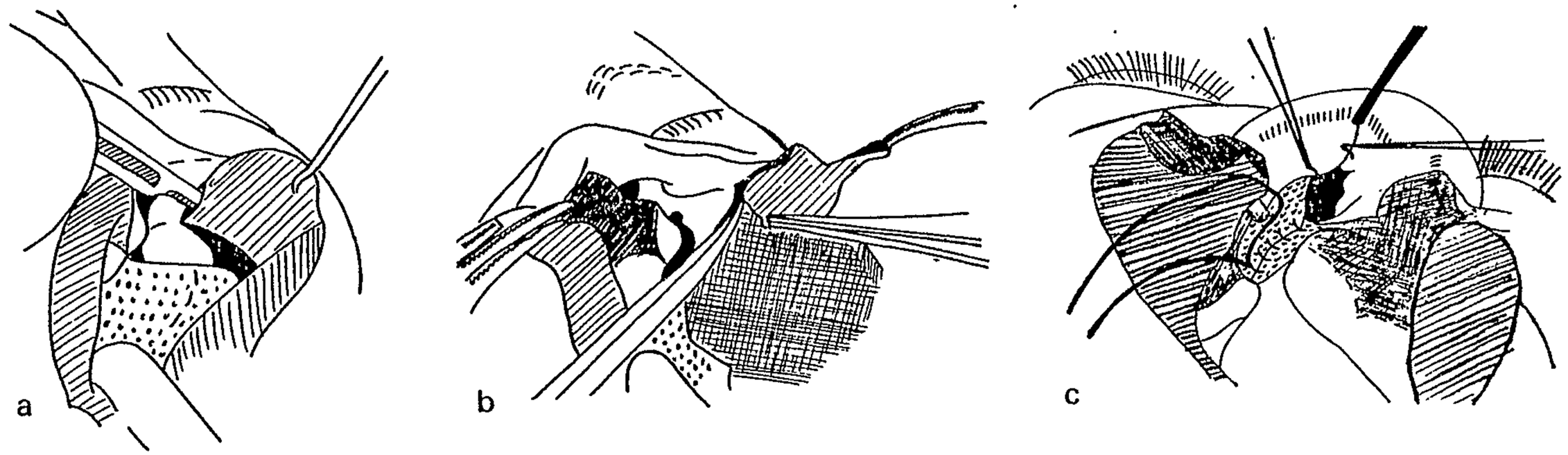

FIGURE 14

(a) The origin of the triangular labial flap - from an operative photograph. (b) The mobilization of the labial flap from the alar base. (c) The use of the flap to reinforce the nasal floor in the interalveolar area. (From Dey 1974)

their proper antero-posterior relationships with the mandibular incisors in cases where this flap is placed. This procedure is similar to that advocated by Muir (1966) although the Dey triangular flap differs in detail, size and in formation. This study looks at the effects of Dey's triangular flap on arch collapse and crossbite incidences.

Isshiki and Morimoto (1968) also advocate two-layered closures of the anterior palate and have presented their modified versions of the Campbell and Wardill-Kilner palate repairs. See Figure 10D.

To reinforce the raw surface of the vomer flap in hard palate closure, Strenstrom and Thilander (1974) used an autogenous skin graft. They found no maxillary constriction and the occlusion was perfect in all except three cases in a 10-year follow-up study. These three cases were complete unilateral cleft lip and palate cases with cuspid and bicuspid crossbites on the cleft side. The sample size here was very small (only 10 cases) and four of the cases had cleft palates only.

Recently Llewelyn (1986) reported that he was using a bulky tongue flap as the second layer in his primary anterior palatal repair of bilateral cases. He felt that this additional tissue from the tongue helped to counter the tissue deficiency in the cleft area, which he regarded as being partially responsible for the

collapse of the alveolar segments. No long term orthodontic studies on the effects of these flaps have been carried out to date.

The repair of the lip and anterior palate should therefore be undertaken to avoid subsequent tension and with a minimum of scarring if collapse of the alveolar segments is to be avoided. A one-layer closure is not desirable as it is liable to lead to healing by secondary intention, scarring, contracture and collapse. A lining should always be added to reduce scarring where possible and any of the above-mentioned flaps or repairs can be used. Collapse of the alveolar segments can also be reduced by the mechanical filling-in of the alveolar cleft with bulky soft tissue flaps.

3(D) BONE-GRAFTING

Bone-grafting into the alveolar cleft is another method of repairing the cleft of the anterior palate and preventing collapse of the maxillary buccal segments. It is used to restore the divided maxilla into a stable and continuous unit. The graft is often placed after pre-surgical orthopaedics, orthodontic expansion or surgery has been used to re-align the displaced palatal segments.

Bone-grafting aims at:(Rehrmann 1964, Turvey et al 1984)

a) replacement of missing bone or bone which may not develop because of early operations (includes closure of oro-nasal fistulae);
b) the creation of an architecturally complete bony arch;
c) stabilizing the alveolar margins to prevent the inward collapse of the alveolar segments and subsequent crossbite formation;
d) provision of a matrix for the eruption or orthodontic movement into the arch of teeth bordering the cleft;
e) support for the alar base on the cleft side;
f) stabilizing the premaxilla in complete bilateral cleft cases by bony unions of the premaxilla to the lateral segments.

Boyne and Sands (1976) have classified bone-grafting into 4 types according to the timing of the grafting procedure:-

1) Primary bone-grafting - applies to the placement of bone-grafts in children less than two years of age. This may be done together with the lip repair or later.
2) Early secondary bone-grafting - applies to those grafting procedures between the ages of two and five years old.
3) Secondary bone-grafting - applies to bone-grafting undertaken in children between the ages of six and 15 years old.
4) Late secondary bone-grafting - applies to the reconstruction of the residual defect in physically mature adults.

As this thesis is concerned with ways to prevent collapse of the maxillary buccal segments and reduce crossbite formation, Late Secondary Bone-grafting will not be included in the literature review.

There have been many different types of bone-grafting materials used. Some of these are:-

1) Rib grafts (Backdahl and Nordin 1961, Monroe et al 1968).
2) Iliac crest grafts (Stellmach 1966).
3) Tibial grafts (Ritsilia et al 1972).
4) Cranial bone grafts (Wolfe and Berkowitz 1983).

5) Chin-grafts (Tideman 1985).

The last two above are more embryologically compatible with alveolar bone and less resorption takes place (Tideman 1985).

Autogenous bone is the material of choice as allogenic bone-grafts do not seem to survive. For survival of the graft, it also has to be covered by flaps of mucoperiosteum and attached gingiva (Abyholm et al 1981, Brogan 1986). Cortical, cancellous bone and bone marrow have all been used but the favoured bone types are cancellous bone and bone marrow. (Boyne and Sands 1976, Abyholm et al 1981, Jackson et al 1981). This is because they have better osteogenic capacities and they also allow teeth to erupt while cortical bone does not.

Rib grafts have been more popular in the past in primary bone-grafting procedures because of the iliac crest being not well developed in the infant and it also being a growing centre which surgeons feared to disturb. These grafts were usually inserted into the alveolar cleft via a buccal approach. Nowadays, secondary bone-grafting is the more popular choice and cancellous bone for this procedure is taken from the iliac crest, cranial bones or the chin.

The idea of bone-grafting clefts started in Europe at the beginning of this century but it was not until the

1950's that Schmid (1955) and Nordin and Johanson (1955) popularised it. These people and many others felt that if the alveolar cleft was closed and stabilized by bone-grafting at the primary lip operation, the subsequent collapse of the alveolar segments and the frequently prevailing crossbite malocclusions (at that time) would be prevented.

By the 1970's, many who had earlier advocated the procedure had abandoned it because their results showed a long term negative effect on the growth of the maxilla, collapse of the alveolar segments and crossbites still occurring. The latter, in some cases even increased in frequency. (Kling 1964, Pickrell et al 1968, Rehrmann et al 1970, Jolleys and Robertson 1972, Friede and Johanson 1974, Robertson and Jolleys 1983, Reichert et al 1984).

Pickrell et al (1968) evaluated 25 children who had their anterior alveolar clefts closed with a primary autogenous rib graft and they found that: -

1) Primary rib grafts in the maxilla do not increase in size concomitantly with facial growth and development.
2) Teeth do not migrate and erupt spontaneously through a rib-bone graft.
3) Rib-grafts do not form a true alveolar process and a permanent alveolar notch remains.
4) The orthopaedic effect of the bone-graft decreases

as its incorporation progresses.

Robertson and Jolleys (1983) came to similar conclusions in an 11-year follow up of 14 patients who each had an autogenous rib graft placed at the age of 15 months. As a control, they had 14 non-grafted patients whose cleft types were matched with those of the grafted patients and who, other than the graft, had the same treatment protocols. They found that bone-grafting inhibited forward maxillary growth especially between the ages of 1 to 5 years and that dental arch measurements were slightly less in the grafted group than in the non-grafted group. They also noted that bone formed was not sufficient to support a tooth in its normal position. They concluded that primary bone-grafting was of no benefit to the patient.

Friede and Johanson (1974) found that early bone-grafted patients had significantly greater maxillary retrognathia and that this increased with age. However, many of their cases were not just grafted in the alveolus but throughout the entire cleft of the palate. They noted that if the graft was only confined to the alveolar area, the maxillary retrognathia was less severe and the facial appearances of these patients were quite acceptable.

Reichert et al (1984) also found that primary bone-grafting led to vertical hypoplasia of the canine

region resulting in open bites occurring in this part of the cleft as well as mesio-occlusion of the teeth in the lesser segments.

It has been suggested that if the graft produces a solid bony union across the cleft , with no sutures or growth centre, this will tether the two halves of the maxilla together and prevent their normal growth. Animal studies such as those by Thilander and Stenstrom (1967), and Engdahl (1972) showed that bone-grafting led to the consolidation of sutures and this in turn resulted in inhibition of maxillary growth especially in the area of the cleft. Thilander and Stenstrom (1967) found limited and asymmetrical growth in guinea pigs which had their maxillo-premaxillary sutures excised and were then bone-grafted, whereas the guinea pigs who had their cleft defect left open exhibited normal facial growth.

Pruzansky (1964) also felt that primary bone-grafting immobilized the premaxilla and the segments which then prohibits orthodontic manipulation of these same segments at a later stage. He also felt that it maintained excessive width of the cleft posteriorly which then became a disadvantage in velopharyngeal reconstruction.

There are, however, still a few advocates of primary bone-grafting and these people have not found that

bone-grafting at this early age is more harmful or that it has more negative effects on maxillary growth than other types of early closures. (Matthews et al 1970, Lynch et al 1970, Schmid et al 1974, Enany 1981, Rosenstein et al 1982, Nordin et al 1983). None of these investigators found excessive attenuation of maxillary development in patients who had undergone primary bone-grafting.

Recently, Rosenstein et al (1982) have done a long term survey of their first 16 primary bone-grafting cases of 14 years ago and, cephalometrically, they found no differences in the maxillary position between the primary osteoplasty group and the non-grafted group. Both groups had SNA and SNB readings considerably less than the non-cleft population but it has been shown that the maxilla, in a child with a complete cleft of the lip and palate, is more retrognathically positioned in relation to the cranial base compared to a normal child. (Foster 1962, Chapman 1966, Ross and Johnston 1967, Mowbray 1977).

Nordin et al (1983) followed their primary bone-grafting cases to the age of 13 years and they too found no statistically significant differences cephalometrically between their bone-grafted group and other studies of non-grafted cleft cases. Like Rosenstein's cases, there were statistical differences between their bone-grafting cases and their non-cleft cases especially when

involving maxillary measurements.

In a cephalometric study of 9 of Rosenstein's bone-grafted cases, Enany (1981) found that the mandible was positioned more distally and exhibited more upward instead of backward growth compared to mandibles in non-grafted cases. She felt that this helped to explain why the dental bases remained in a harmonious relationship to each other in bone-grafted cases even though the maxilla in these cases were more retrognathically placed.

Larson et al (1983), using the same sample as Nordin et al (1983), studied the dental occlusion of bone-grafted cases and found that with bone-grafted cases, the incidence of canine - only crossbites was significantly higher than with other studies of non-grafted cases. However, the incidence of lingual crossbite was lower in their bone-grafting groups than in the non-grafted studies compared. They also found that their bone-grafted cases had significantly wider arches in the molar region when compared to non-cleft material. This seems to confirm Pruzansky's (1964) observation regarding the maintenance of excessive width posteriorly and the prevention of collapse of the buccal segments posteriorly. Larson et al felt that the higher incidence of crossbites in the canine region was due to the surgical intervention for the bone-graft in that area. Scar tissue here would cause the canine to erupt

in a more palatal position. The overall occlusion of their cases was assessed to be better than the Friede and Johanson (1974) sample and they felt that this was due to their surgical technique which minimises the amount of scar tissue formed by leaving no raw surfaces to heal by secondary intention. As discussed previously, scar tissue will cause the eruption of teeth palatally and inhibit maxillary growth as well.

The people such as Rostenstein and Nordin, who still advocate primary bone-grafting, stress that their good results are due to limited dissection of the anterior surface of the maxilla, minimal tissue mobilization and not leaving large raw surfaces to heal by secondary intention thus allowing large amounts of scar tissue to form. Rosenstein et al (1982) stressed that their dissections did not use any vomerine flaps or involve the vomerine-premaxillary suture. Friede and Morgan (1976) and Friede (1978) have cautioned against involving the vomerine-premaxillary suture surgically. From their implant and histological studies, they came to the conclusion that traumatic surgery to the suture will lead to impaired mid-facial growth. Wada and Kremenak (1978), in Beagle dog experiments, have also found that surgical trauma to the vomer or absence of the vomer led to inhibition of anterior - posterior growth of the mid-face.

In a recent international study of cephalometric

radiographs from treatment centres throughout the world, Ross (1984B) came to the conclusion that some techniques of primary bone-grafting could lead to inhibition of maxillary growth.

It appears from reviewing the literature that only a minority of operators are satisfied with their long term results of primary bone-grafting. Others have found that the incidence of crossbites are not reduced, maxillary growth is inhibited and later orthodontic manipulation is more difficult due to the intact alveolar arch and the build up of scar tissue from the mobilization of soft tissue flaps to cover the graft. Some operators have also found that teeth do not always erupt through the grafted area. The few centres that do have success stress that their success is dependent on their surgical technique which entails minimal tissue mobilization, avoidance of exposure of large raw surfaces to heal by secondary intention and the avoidance of the premaxillary-vomerine suture. Rosenstein (1984) also stresses the use of tiny bone chips of cancellous bone or bone marrow instead of large struts or blocks of cortical bone which seem to be less conducive to tooth eruption.

Secondary bone-grafting in the mixed dentition stage or later is, however, gaining more widespread success today and it does not appear to inhibit maxillary growth (Braun and Sotereanos 1981, Abyholm et al 1981, Turvey

et al 1984). Abyholm et al (1981) feel that if bone-grafting is carried out after the child is 7-8 years old, it is unlikely that any disturbance to the growth of the anterior maxilla will occur as most of the growth is completed by then. It has been shown that the optimal timing for performing a secondary alveolar bone-graft is just prior to canine eruption in the age range 8-12 years old. (Abyholm et al 1981, El Deeb et al 1982, Turvey et al 1984). These people have also found that as the tooth erupts, more alveolar bone is induced to form. From radiographic studies, El Deeb et al (1982) found that the prognosis for canine eruption through the graft was most favourable if the graft was performed when the canine root was 1/4 to 1/2 formed whereas Turvey et al (1984) found that the more favourable time for bone-grafting was when the canine root was 1/2 to 2/3rds formed. Secondary bone-grafting is usually performed after the collapsed arches have been orthodontically expanded by appliances such as the quadhelix or repositioned by orthognathic surgery. The repositioned segments are then stabilized with a bone-graft and generally no retention devices are needed afterwards. (Abyholm et al 1981). A complete bony union across the skeletal defect is their explanation for this stability.

From a review of the literature, it appears that primary bone grafting is presently losing its popularity as it not only fails to fulfil all the aims listed previously

by its originators, but it also appears to have deleterious effects on maxillary growth and the occlusion. Secondary bone-grafting, however, is gaining in popularity as the long term studies are showing excellent results.

3(E) PERIOSTEOPLASTY ("BONELESS" BONE-GRAFTING)

Skoog introduced periosteoplasty in 1964 in an attempt to achieve bony union across the cleft without having to take bone from elsewhere. (Skoog 1969). He used a periosteal flap taken from the anterior surface of the maxilla to close the alveolar cleft. He believed that the osteogenic capacity of this periosteal flap could be used to rebuild the bony defect and therefore reduce collapse of the maxillary segments. He also hoped that the tooth buds would migrate into the newly formed bone.

The surgical procedure is based on three main premises. (Skoog 1969).

1) The periosteum covering the maxillary segments possesses normal growth potential.
2) Denuded bone in this area will regenerate normal periosteum similar to other bones.
3) The re-established interaction between growth centres on the medial and lateral sides and the biomechanics of the soft tissue environment will determine the growth and development of the united maxilla.

When it was criticized that the technique entailed operating on a juvenile maxilla which would endanger future maxillary development, Skoog quoted Bjork (1966) who used implant techniques to show that the anterior portion of the maxilla was never a growth site,

therefore Skoog felt that periosteoplasty would not impair maxillary growth.

There are two types of periosteoplasties performed. Primary or infant periosteoplasty is carried out up to the age of two years in connection with the primary surgical repair. Early secondary or delayed periosteoplasty is performed during the juvenile period between the ages of 2 and 10 years.

Skoog (1967) also introduced "Surgicel" (an oxidised regenerated cellulose) between the periosteal flaps as a scaffolding to bring about more bone formation.

In a follow-up study of 36 infant periosteoplasty patients aged between 5 to 8 years of age and with complete clefts of the primary and secondary palate; Hellquist and Ponten (1979) found that cephalometrically there was a bimaxillary retrognathia but this was within the limits reported by other Scandinavian cleft studies of the same age group whose treatment did not include either periosteoplasty or bone-grafting. They also found that the anterior crossbite incidence increased in the period from 5 to 8 years of age while the incidence of lingual crossbites decreased in that same period. They felt that the decrease in lingual crossbites was due to good bone-formation in the alveolar cleft which acted as a stabilizer after orthodontic expansion in the deciduous dentition stage was carried out.

However, after their twenty year longitudinal studies, Hellquist and Svardstrom (1984) drew the following conclusions on infant periosteoplasty:-

1) With large alveolar clefts, there was a lack of periosteum for the repair. (This was also a finding of Ritsilia et al 1972).
2) There was insufficient bone formation.
3) There was an increased crossbite frequency.
4) Maxillary growth was disturbed.

They therefore abandoned infant periosteoplasty in favour of delayed periosteoplasty.

Rintala and Ranta (1984) from their long term studies on the use of Skoog's periosteal flap as well as the use of free tibial periosteal grafts to repair the alveolar clefts, also came to similar conclusions as Hellquist and Svardstrom. They also added that the collapse of the lateral maxillary segments was not prevented and that early bony union of the maxillary segments did not facilitate later orthodontic treatment and that later orthodontic treatment was necessary in every case. The procedure also added to the amount of scar tissue formed and secondary maxillary growth problems. They have now also abandoned the use of both techniques in their primary repair.

Hellquist and Svardstrom (1984) recommend the use of delayed periosteoplasty performed at an age of 5 to 6 years in small alveolar clefts instead. Their studies

showed that there is a higher percentage of good bone formed, crossbites are not increased and that maxillary growth is undisturbed with delayed periosteoplasty. In delayed periosteoplasty, no periosteal flap transfer from the outer aspect of the maxilla takes place. Instead, relaxing incisions in the periosteum are made to allow medial advancement of the periosteal layers over the alveolar cleft. For large alveolar clefts they recommend the use of secondary bone-grafting instead.

The use of infant periosteoplasty as a way of repairing the alveolar cleft and stabilizing the maxillary segments has therefore been shown to be unsuccessful on a long term basis.

CHAPTER 4

ASSESSMENT OF ARCH COLLAPSE

There are many different ways of assessing the success or failures of different treatment procedures carried out on the cleft patient. Arch form and dental occlusion are two variables which orthodontists use to evaluate and compare the effects of different treatment procedures such as bone grafting, on a patient with a complete cleft of the lip and palate. The amount of arch collapse and maxillary constriction can be assessed by studying changes in arch form and the occlusion.

(I) ASSESSMENT BY DESCRIPTIVE CLASSIFICATION OF ARCH FORMS

Pruzansky and Aduss (1967) categorised arch forms after surgical treatment into 3 general forms:-

1) approximation of the cleft alveolar segments into end-to-end contact producing a symmetrical arch form.
2) overlap of the alveolar segments to produce the "collapsed" arch form.
3) approximation of the alveolar segments but without contact. See Figure 15.

Huddart and Bodenham (1972) simplified arch form

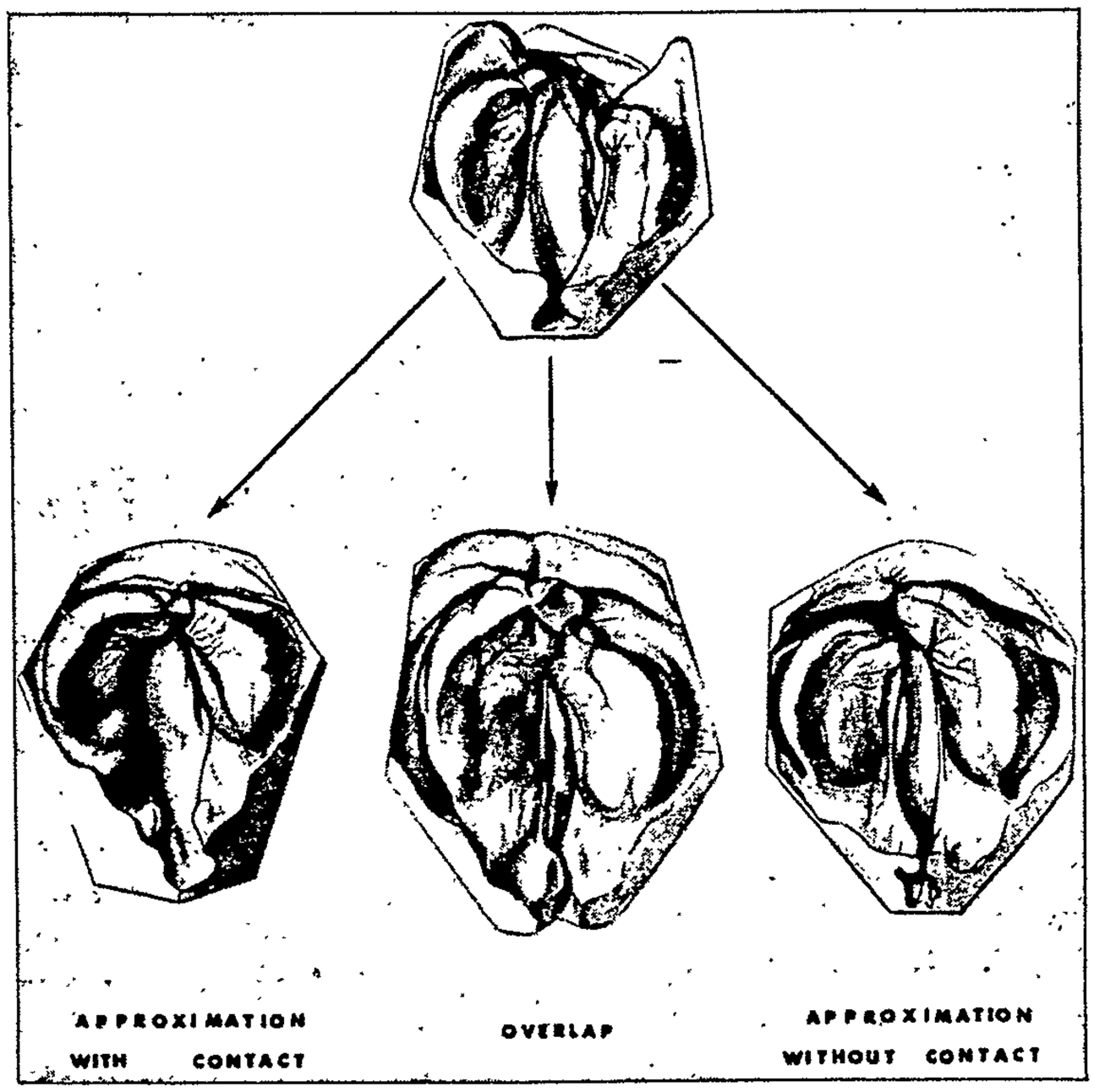

FIGURE 15

Categorisation of arch form following repair of the lip. (From Pruzansky and Aduss 1967)

ARCH FORM

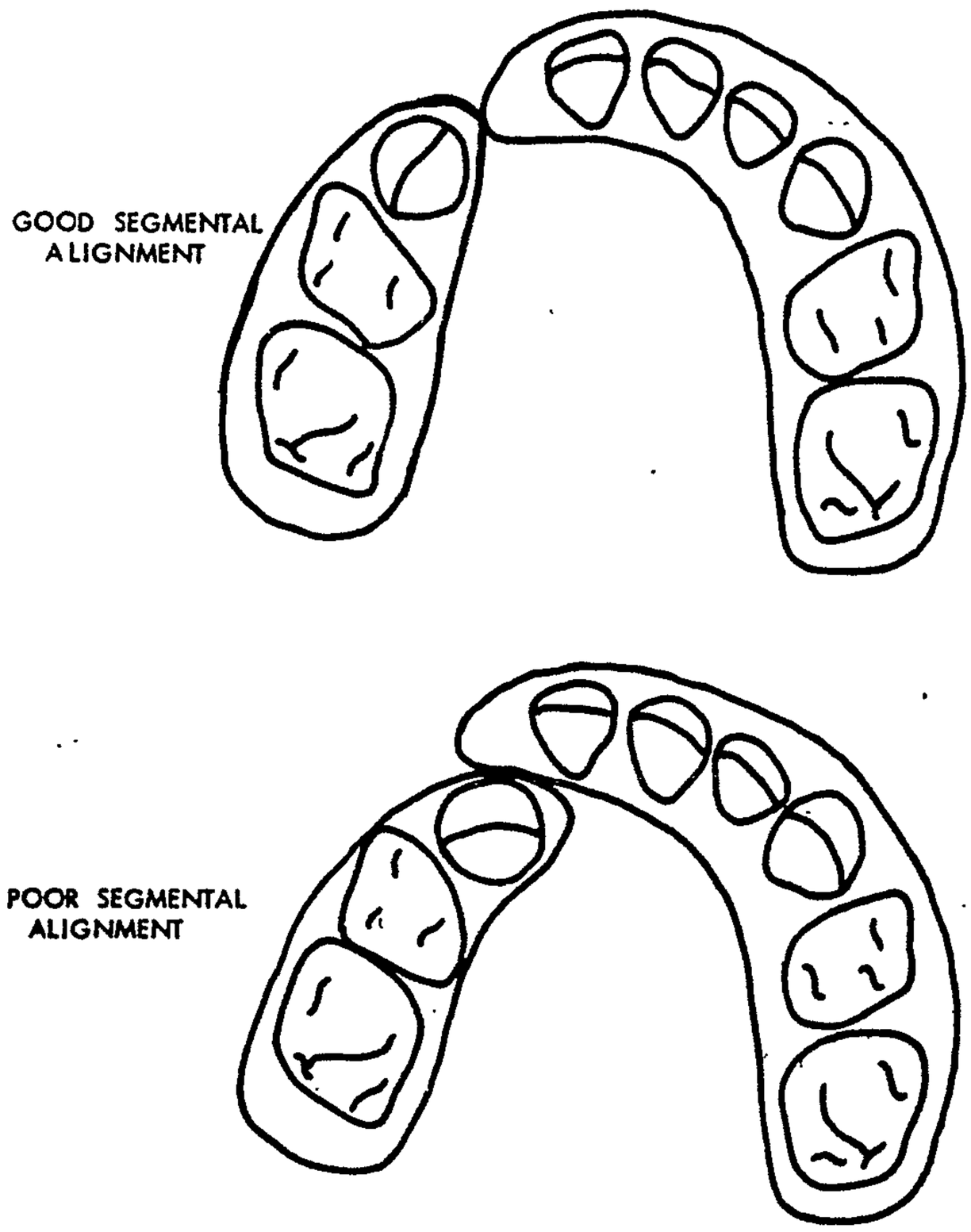

FIGURE 16

Huddart and Bodenham's classification of arch form. NB. With good segmental alignment, there may or may not be actual contact of the greater and lesser segments. (From Huddart and Bodenham 1972)

classification into 2 categories:-

1) good segmental alignment.

2) poor segmental alignment.

See Figure 16.

The above descriptive classifications are rather vague and do not give any idea of the severity of the problem for comparison with other cases nor do they necessarily indicate whether or not there was an associated dental crossbite malocclusion. Pruzansky and Aduss (1967) found in their studies that, while the prevalence of crossbite was less frequent with a symmetrical arch form, a significant number of cases rated as "collapsed" demonstrated no or only slight crossbite malocclusions. Huddart and Bodenham (1972) found that even with only 2 categories, their method of assessment was hopelessly inaccurate and they suggested the need for devising some form of numerical classification to describe segmental alignment.

(II) ASSESSMENT BY DIRECT MEASUREMENT SYSTEMS

Hagerty et al (1964) studied the amount of dental arch collapse by using measurements of dental arch areas as indicators of collapse in post-operative cleft palate patients. Sets of dental study models were trimmed in centric occlusion with the bases of each model parallel to the occlusal plane. Each model was then photographed separately at a fixed distance, with the centre of the

occlusal plane directly in front of the point of focus. Mandibular photographs were then marked for outline of the buccal and labial borders of the alveolar processes and the midline of the lower arch was derived geometrically. This midline was then transferred to the maxillary photograph. Upper and lower photographs were then placed "in occlusion". The upper photo was then divided into quadrants and the area of each quadrant was determined with a rolling disc planimeter. Dental arch collapse was reflected by the asymmetry of the anterior quadrants and by the differences in the areas of each quadrant. Hagerty et al (1964) admit that this technique introduces subjective differences, for example, in tracing the outline of the gingiva, or in establishing the upper midline from the mandibular arch.

Stockli (1971) designed a numerical measurement system to express the spatial relationship of the two maxillary segments in the frontal and sagittal planes especially in the alveolar cleft region. He placed marks on study models and then converted them into a two-dimensional system by making photostatic copies of these models. See Figure 17. This measuring system was designed in relation to three anatomical landmarks (the interincisal point and the 2 bilateral tuberosity points) which are easily identified on the casts. Stockli felt that the exact value of each measurement may not be as important as the range of values for each measurement, which may serve as a basis for the establishment of a more refined

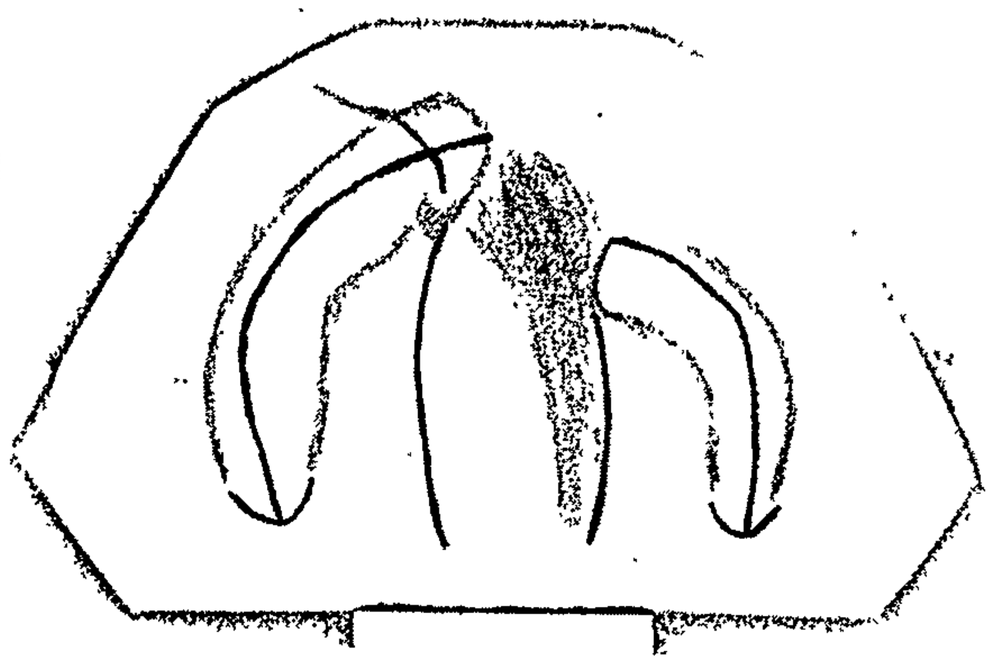

FIGURE 17

Top: Model of complete unilateral cleft lip and palate cases. Crests of alveolar ridges, medial borders of palatal shelves, tuberosities, incisive papilla and attachment of labial frenum marked with pencil.
Bottom: Two-dimentional reproduction of plaster cast shown above, obtained by using a Rank Xerox 914 copier machine.

(From Stockli 1971).

grouping when large numbers of cases are evaluated. This method of assessment is similar to the ones used by Huddart (1967B) and Mazaheri et al (1971). However, the one used by Huddart (1967B) has two major inadequacies:

1) It is limited to studies before palatal closure, as one of its reference structures is the nasal septum, and;
2) It does not describe the configuration of the alveolar cleft.

Berkowitz and Pruzansky (1968) felt that the above methods only allowed a two-dimensional representation of a three-dimensional problem so they introduced stereophotogrammetry for more accurate studies of cleft palate casts. The basic principle of stereophotogrammetry is that of binocular vision. When two photographs of the same object are taken from slightly separated points, they can be viewed in a manner that will give a three-dimensional model surface. Depth perception is improved and the effect of relief is created. A series of standardized projections can thus be created and reproduced for consecutive casts. The authors tried to quantify the variation in the amount of tissue and the shape of each palatal segment for a single type of cleft, as well as the changes in the area of the palatal shelves as a result of growth or surgery.

Due to the excessive costs involved in extrapolating geometric data with stereoplotters, Berkowitz et al

(1982) are now using an optical profilometer for measuring casts. This consists of an optical system and photodetectors which observe the change in the energy distribution of an image spot of light as a function of the depth of the sample surface at the measurement point. The case surface is scanned to provide measurement information over the complete surface. Contour data is therefore created and then measured by a computer.

More recently, Butow (1984) has described a method for the geometric linear analysis of dental models of unilateral cleft lip and palate cases. The effects of different treatment procedures on the position of the lesser segment can be analysed. The casts are photographed and graph drawings are made of these photographs. This is another two-dimensional study and the disadvantage of this method is that it cannot be used for bilateral cleft cases.

(III) ASSESSMENT OF DENTAL OCCLUSION

The dental occlusion has been used in many studies to evaluate the results of cleft palate treatment. Handelman and Pruzansky (1968) feel that the occlusion may be regarded as an index to jaw development. Anterior-posterior jaw dysplasias may be reflected in the precise interdigitation of the maxillary and mandibular dentition; for example, an Angle's Class III

molar and canine relationship may indicate maxillary underdevelopment or mandibular prognathism. Collapse of the palatal shelves or restricted lateral maxillary development may be reflected in the lingual interdigitation of the maxillary posterior teeth. (ie. lingual crossbites).

The dentally assessed success or failure of cleft treatments may also be related to the frequency with which crossbites appear in the sample studied. Maxillary deformity such as arch collapse may manifest itself in the occlusion as crossbites. The incidence of crossbite malocclusion varies amongst different investigations and with different surgical techniques used; therefore, many different crossbite classifications have been evolved.

Kling (1964) in an assessment of primary bone grafting procedures, classified the buccal occlusion into:-

1) Bilateral complete crossbite.
2) Bilateral incomplete crossbite.
3) Unilateral complete and unilateral incomplete crossbite.
4) Unilateral complete crossbite.
5) Unilateral incomplete crossbite.

Complete crossbite = crossbite comprises molars and canines on one side.

Incomplete crossbite = crossbite of only first molars and canine on one side.

Pruzansky and Aduss (1964) divided the occlusion into 6 categories:-

1) no-crossbite present;
2) canine crossbite only;
3) buccal crossbite only;
4) anterior and buccal crossbite;
5) anterior and canine crossbite;
6) incisor crossbite only.

N.B. Pruzansky's term "buccal crossbite" refers to the same condition as Moyer's lingual crossbite.

Matthews et al (1970) used the following categories:-

1) Class A - where all segments of the maxilla are in normal occlusion with the mandible.
2) Class B (1) - the tooth bordering the cleft on the lesser segment is in lingual occlusion.
3) Class B (2) - normal occlusion of the greater segment but lingual occlusion of the lesser segment.
4) Class B (3) - the maxillary arch is perfect but is too small.
5) Class C - an overall Class III occlusion of all segments of the maxilla and, in addition, collapse of some part of the small maxillary arch.

Unfortunately, all these different classifications are so dissimilar that effective comparison of the results of different cleft studies is extremely difficult. Huddart and Bodenham (1972) felt that these descriptive

classifications did not show the extent of the severity of the cases and being non-numerical, they were not so amenable to statistical analyses. Therefore, they developed a numerical method of classifying the severity of crossbites.

THE HUDDART AND BODENHAM METHOD OF CROSSBITE CLASSIFICATION (1972)

With this classification, each maxillary tooth is awarded a number of points depending on its position relative to its opponent in the mandible. A normal bucco-palatal or labio-palatal relationship of an upper tooth with its lower opponent is scored as 0, a cusp-to-cusp relationship is a -1 and a full lingual occlusion is scored as -2. See Figure 18.

The maxillary arch is divided into two buccal segments and a labial segment. In the labial segment, the lateral incisors are not assessed as they are often absent or unreliable in their positions. A score for each segment is produced by adding together the scores for the individual teeth constituting the segment and a total occlusal score is obtained by summing the segmental scores.

Huddart and Bodenham (1972) compared their numerical classification with Pruzansky's descriptive classification and found that observer reliability and

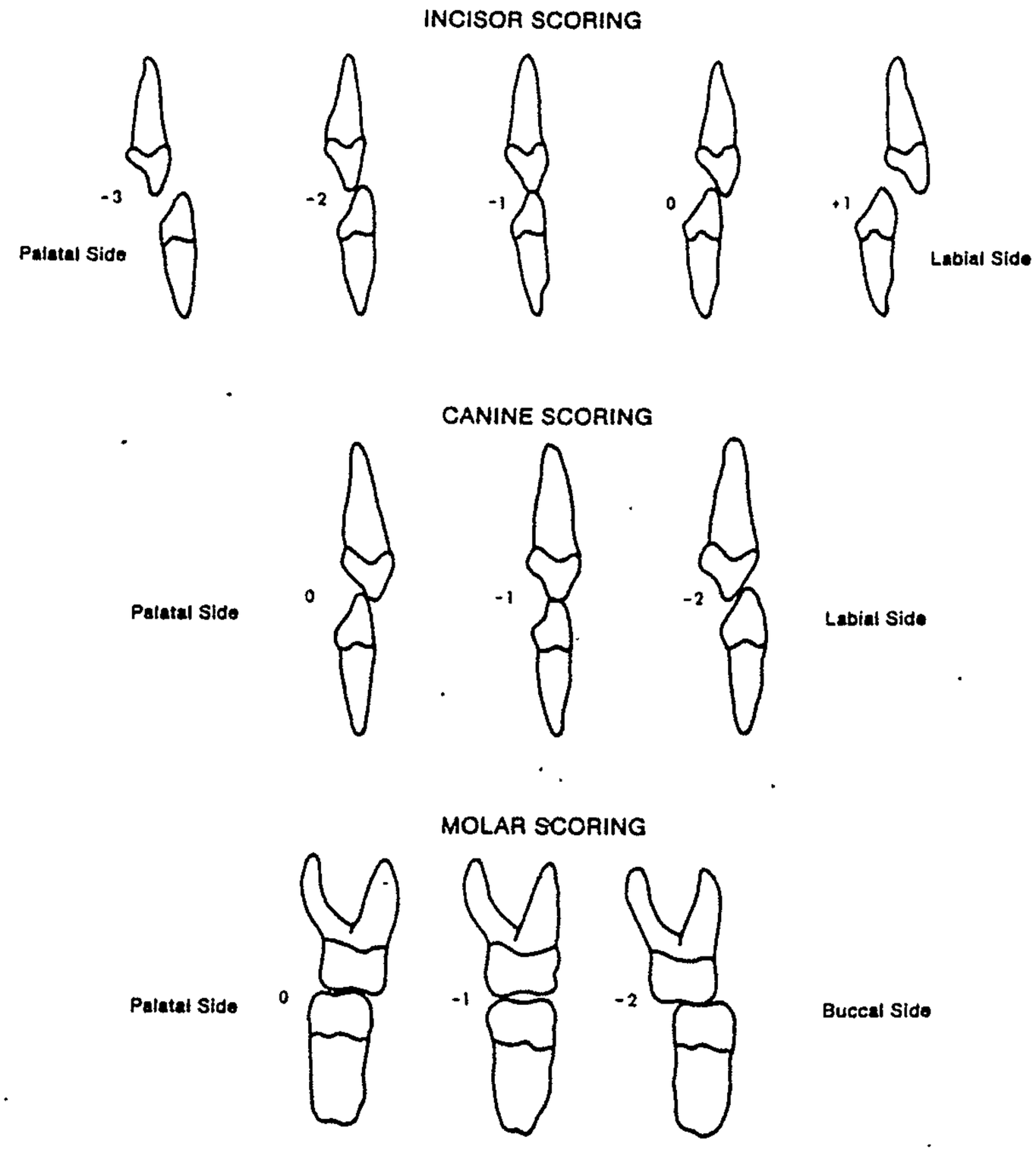

FIGURE 18

Huddart and Bodenham's scoring of buccolingual dental relationships. (From Huddart and Bodenham 1972)

consistency were very similar, no matter which classification was used. They also found that the numerical classification was more suited for future studies due to its facility for ranking different malocclusions in order of severity and its ease of statistical handling. The numerical classification also gave more detailed information about the occlusion than the descriptive classification.

Arch collapse and maxillary constriction can be increased or prevented by different treatment procedures. These procedures, therefore, need to be assessed for their effectiveness and this can be done by studying and comparing the changes in arch form and the dental occlusion of the patient.

ORIGINAL WORK: STUDY

MATERIALS AND METHODS

Subjects

The 91 patients for this study were selected from the files of the Speech Pathology Department of the Royal Alexandra Hospital for Children, Camperdown, Sydney. They fulfilled the following criteria:-

1) Their surgical repairs of the lip and palate were carried out by either of two senior plastic surgeons at the Royal Alexandra Hospital for Children. Both these surgeons used the same operative techniques.
2) They all had complete clefts of the lip and palate - either unilateral or bilateral. Of all the different types of clefts occurring, only cases with complete clefts of the lip and palate were chosen because maxillary collapse and constriction is greatest in these cases (Norden et al 1973). Cases with soft tissue bridges at the base of the nose (Simonart's bands) were excluded because it was felt that these soft tissue bridges prevented the aberrant muscle systems from effectively distorting the palatal segments. Burian (1955) felt that these soft tissue bridges signified that the original developmental defect was not complete and growth impairment was thus less marked.

3) None of the patients had undergone any orthodontic treatment after primary surgery. However, many of the bilateral and some very wide unilateral clefts had undergone pre-surgical orthopaedics prior to their initial lip repair.

4) No bone-grafting was carried out in their initial repair.

5) None of the patients had severe cranio-facial abnormalities or syndromes.

6) All the patients were born between 1963 and 1983.

Type of Primary Repair

Unilateral Group

Repair of the unilateral cleft cases consisted of a modified Tennison or Davies Z-plasty for the lip, anterior septal cartilage mobilization and anterior palate closure with a septal flap tucked into the cleft margin. This was carried out when the babies were between 6 weeks to 3 months old. The remaining posterior palate repair consisted of a Wardill V-Y pushback procedure with the preservation of the neuro-vascular bundles and displacement of the hamulae. This was done when the child was between 9 to 12 months old. This is the standard repair carried out at the hospital. Since late 1972, an additional wide triangular flap of labial mucosa has been placed in the alveolar gap as part of the anterior palate repair (Dey 1974). See Figure 14. The 39 patients who had this

additional triangular labial flap placed formed the experimental group. The other 31 patients without this flap placed, but who had the same standard repair for the lip and palate, formed the control group.

Bilateral Group

Repair of the bilateral cleft cases consisted of a Manchester lip repair with anterior palate closure using septal flaps usually when the children were 2 to 3 months old. The remaining posterior palate repair consisted of a Wardill V-Y pushback procedure (as above). This was also done at 9-12 months. Most of these cases had undergone pre-surgical orthopaedics prior to their lip repairs. This is the standard bilateral cleft repair at the hospital. After 1972, wherever possible, a Dey triangular flap was placed in the alveolar gap as part of the anterior palate repair as described for the unilateral repairs. Here, 11 patients with Dey triangular flaps formed the experimental group and 10 cases that did not have Dey flaps placed formed the control group.

The distribution of subjects according to sex, cleft type and type of alveolar management is shown in Table I. It is interesting to note the preponderance of males and of left-sided clefts. In the unilateral cases, the left side is involved about twice as frequently as the right side. These findings are similar to those from

TABLE 1

DISTRIBUTION OF SUBJECTS BY SEX, CLEFT SIDE AND TYPE OF ALVEOLAR MANAGEMENT

Unilateral Cleft Cases

ALVEOLAR MANAGEMENT	FEMALES		MALES		TOTAL CASES
	Right Cleft	Left Cleft	Right Cleft	Left Cleft	
Standard Repair (No Flap)	4	6	3	18	31
Dey Triangular Flap Placed	4	8	12	15	39
SUB-TOTAL	8	14	15	33	
TOTAL	22		48		70

Bilateral Cleft Cases

ALVEOLAR MANAGEMENT	FEMALES	MALES	TOTAL CASES
Standard Repair (No Flap)	4	6	10
Dey Triangular Flap Placed	3	8	11
TOTAL	7	14	21

other studies. (Ross & Johnston 1972).

Method of Data Collection

Study models prior to any form of orthodontic treatment were obtained from the patients or their orthodontists and articulated in centric occlusion. Where possible, full face, profile and intra-oral photographs were obtained to examine facial proportions and to verify model articulations. A short history of each patient was also obtained where possible. If patients were too young to have study models taken, they were examined and classified directly from the mouth.

Method of Scoring

The Huddart and Bodenham (1972) numerical method of scoring crossbites was used. (See Chapter on "Assessment of arch collapse"). Each maxillary tooth was awarded a number of points depending on its position relative to its opponent in the mandible.

A normal bucco-palatal or labio-palatal relationship of an upper tooth with its lower opponent was scored as 0, a cusp-to-cusp or edge-to-edge relationship was a -1, and a full lingual occlusion was scored as -2. See Figure 18.

A score for each segment was produced by adding together

the scores for the individual teeth constituting the segment, and a total score was obtained by summing the segmental scores. The lateral incisors were not assessed as they were often absent or unreliable in their positions. The first permanent molars were included in this study when present, but not the second permanent molars. If a tooth was missing or had not erupted, it was given a score corresponding to the mean value of the neighbouring teeth within the segment. Scoring of the incisors was modified so that a score of 0 was given if the overjet was normal or greater than normal.

This method of classification was chosen because it allows for statistical analysis to be applied and it also gives a representation of the location, extent and severity of the crossbite malocclusion. This allows us to rank cases in order of severity which is not possible with purely descriptive classifications. It has also been used in other studies (See Tables 4 to 7) therefore enabling comparisons to be made between my results and those of other studies.

Statistical Analysis of Findings

Thirty patients were scored on two separate occasions (a few weeks apart) using the Huddart and Bodenham (1972) scoring system. A students "t"-test was used to compare the two observations in order to test the reliability or

scoring error of the scoring system. The null hypothesis could not be rejected at the 0.05 level. ie. the differences in scoring on the two different occasions were not large enough to be statistically significant.

The student's "t"-test was also used to compare the differences between the crossbite mean values occurring in the standard repair group and in the Dey triangular flap group. The 0.05 level of significance was used for comparison.

RESULTS

The data on which all the results were based are given in Appendices 1 to 4.

UNILATERAL CASES

The numerical results are presented in Tables 2A, 2B and 3.

1) There was a decrease in the mean anterior crossbite scores in the Dey triangular flap groups in the deciduous and mixed dentition stages when compared to the standard repair groups. However, these differences were not statistically significant. (t=1.26, t=1.29 respectively at P=0.05.) When the permanent dentition scores were compared, no differences were found between the mean anterior scores of the standard repair group and the Dey triangular flap group. See Tables 2A&B.

   In the standard repair group of unilateral cases, 32% had anterior crossbites whereas only 13% of all unilateral cases in the triangular flap group had anterior crossbites. (Here, an anterior crossbite was recorded when both of the deciduous or permanent central incisors were in crossbite. (Ranta et al 1974)). A tooth with a score of -1 i.e. an edge-to-edge bite was not considered as being in

TABLE 2A

Comparison of cross-bite scores of complete unilateral cleft lip and palate cases who either had a standard anterior palate repair or had an additional Dey-triangular flap placed in their anterior palate repair.

	Anterior	Cleft side	Non-cleft side	Total
DECIDUOUS DENTITIONS				
Standard Repair Group				
6 Cases				
Mean	-1.83	-6.33	-1.16	-9.33
Range	-6to0	-8to-3	-4to0	-17to-4
Standard Deviation	±2.32	±2.25	±1.83	±4.93
Dey Triangular Flap Group				
16 Cases				
Mean	-0.87	-4.62	-0.31	-5.81
Range	-4to0	-8to-1	-2to0	-13to-1
Standard Deviation	±1.26	±2.19	±0.60	±3.25
"t" values	1.26	1.62	1.68	1.97
Significance (P=0.05)	N.S.	N.S.	N.S.	N.S.
MIXED DENTITIONS				
Standard Repair Group				
19 cases				
Mean	-2.05	-6.15	-2.26	-10.47
Range	-5to0	-12to-1	-9to0	-22to-1
Standard Deviation	±1.899	±3.08	±2.84	±6.38
Dey Triangular Flap Group				
18 Cases				
Mean	-1.33	-5.11	-1.00	-7.44
Range	-4to0	-11to0	-6to0	-15to0
Standard Deviation	±1.46	±2.72	±1.50	±4.05
"t" values	1.29	1.09	1.67	1.71
Significance (P=0.05)	N.S.	N.S.	N.S.	N.S.

TABLE 2B

Comparison of crossbite scores of complete unilateral cleft lip and palate cases who either had a standard anterior palate repair or had an additional Dey-triangular flap placed in their anterior palate repair.

	Anterior	Cleft side	Non-cleft side	Total
PERMANENT DENTITIONS				
Standard Repair Group				
6 Cases				
Mean	-2.5	-7.33	-3.83	-13.66
Range	-6to0	-11to-4	-6to0	-20to-4
Standard Deviation	±2.26	±2.88	±2.04	±6.09
Dey Triangular Flap Group				
5 Cases				
Mean	-2.6	-4.4	-2.0	-9.0
Range	-6to0	-8to-1	-6to0	-20to-2
Standard Deviation	±3.13	±2.88	±2.45	±7.75
"t" values	0.06	1.68	1.36	1.12
Significance (P=0.05)	N.S.	N.S.	N.S.	N.S.

crossbite. Many of the upper central incisors were only in edge-to-edge relationships with their lower counterparts and most of the crossbites involved only a rotated incisor on one side or one with the crown displaced palatally i.e. the strong clinical impression was that most of the crossbites were dentally rather than skeletally based.

2) Lingual crossbites on the posterior teeth were more prevalent on the cleft side than on the unaffected side. The buccal segment crossbite scores for the Dey triangular flap groups were consistently smaller than the standard repair group scores in all the three stages of dental development. But these differences were again not statistically significant. See Tables 2A&B.

3) The collapse of the dental arches and the crossbites appear to be mainly due to a medial rotation of the lesser segments. This can be seen from the crossbite scoring pattern i.e. the canines on the cleft side had the largest score and the scores decreased as the teeth more posteriorly in that segment were scored. See Appendices 1&2.

4) The upper first permanent molars were usually in good bucco-palatal relationships with the lower molars. Two cases out of a sample of 23 i.e. 9% in the Dey triangular flap group had first permanent

molars in crossbite whilst five cases out of 25 ie. 20% of the standard repair group had their first permanent molars in crossbite relationship.

5) In the Dey triangular flap group, 18 cases out of 39 had good alignment or only very slight collapse compared to 6 out of 31 cases of the standard repair group who had good arch alignment or very slight collapse.

BILATERAL CASES

(Due to the small number of cases available, the mixed dentition and permanent dentition cases were combined into one group).

1) In the deciduous dentition, the mean score in the Dey triangular flap group for the anterior segment was -1.6 which was larger than the score of -0.28 for the standard repair group. However, the reverse was found in the mixed and permanent dentition group. Here the mean anterior segment score for the Dey triangular flap group was -1.00 while the score for the standard repair group was -1.66. These differences were once again not statistically significant (see Table 3). Only one case out of 11 (9%) of all bilateral cases with the Dey triangular flap placed had anterior crossbite. In the standard repair group, one case out of 10 (10%), had an

TABLE 3

Comparison of crossbite scores of bilateral cleft lip and palate cases who either had standard anterior palate repairs or had an additional Dey-triangular flap placed in their anterior palate repair.

	ANTERIOR	RIGHT SIDE	LEFT SIDE	TOTAL
DECIDUOUS DENTITIONS				
Standard Repair Group				
7 Cases				
Mean	-0.28	-6.0	-6.14	-12.42
Range	-2to0	-8to-3	-9to-4	-17to-8
Standard Deviation	±0.76	±1.73	±1.77	±2.64
Dey Triangular Flap Group				
5 Cases				
Mean	-1.6	-3.6	-3.8	-9.0
Range	-4to0	-5to-3	-5to-3	-14to-6
Standard Deviation	±1.67	±0.89	±1.10	±3.32
"t" value	1.86	2.81	2.60	1.99
Significance (P=0.05)	N.S.	P<0.05 significant	P<0.05 significant	N.S.
MIXED AND PERMANENT DENTITIONS				
Standard Repair Group				
3 Cases				
Mean	-1.66	-5.0	-6.66	-13.33
Range	-4tp0	-8to-3	-12to-3	-21to-9
Standard Deviation	±2.08	±2.65	±4.73	±6.66
Dey Triangular Flap Group				
6 Cases				
Mean	-1.00	-4.00	-4.33	-9.33
Range	-3to0	-8to0	-10to0	-15to-2
Standard Deviation	±1.26	±3.41	±3.61	±4.76
"t" values	0.61	0.44	0.83	1.05
Significance (P=0.05)	N.S.	N.S.	N.S.	N.S.

anterior crossbite.

2) The mean buccal segment crossbite scores for Dey triangular flap groups were all consistently smaller than the standard repair group scores. However, these differences were only statistically significant ($p < 0.05$) for the deciduous dentition scores. See Table 3.

3) Left-sided buccal crossbite scores appeared to be consistently higher than right-sided buccal crossbite scores. See Table 3.

4) First permanent molar crossbites were observed in approximately 33% of bilateral cases. (Two cases out of six in the Dey triangular flap group and one case out of three in the standard repair group). The majority of canines were in crossbite relationship, and in the buccal segments, the scores decreased as a more posterior tooth was scored. This was similar to the trend observed in the unilateral cases.

LONG-TERM OBSERVATIONS

1) There appears to be a lesser number of oro-nasal fistulae occurring in the triangular flap cases than in the standard repair cases.

2) The Dey triangular flap does not appear to grow and in many cases, it cannot be distinguished from the surrounding tissues in the depth of the alveolar clefts of the older children. There are a few cases where bone has been observed to be laid down in the alveolar cleft region (Thompson 1985). This effect is similar to the raising of periosteal flaps in periosteoplasty cases. See Chapter 3(E).

3) Photographs of the patients showed only a slight maxillary retrusion in most cases especially in the post-1972 cases.

DISCUSSION

The factors contributing to the development of post-operative dento-facial deformities and malocclusion in the cleft patient are complex and not fully understood. The literature review has attempted to discuss the factors considered to contribute towards the development of these dento-facial deformities and crossbite malocclusions. In the past, surgery has been totally blamed for collapse of the maxillary alveolar segments and the high incidence of crossbite malocclusions found in complete cleft lip and palate cases. However, a small degree of collapse of the maxillary alveolar segments and crossbite malocclusions have been found in newborn infants and unrepaired cleft cases. (Pruzansky 1955, Foster 1962, Innis 1962, Bishara et al 1986). Therefore, it can be seen that surgery cannot be totally responsible for these problems. Other factors should also be taken into account as well.

Slaughter and Brodie (1949) felt that surgery either aided in directing the natural growth processes into proper channels through the establishment of muscle balance across the defect or, it grossly interfered with normal developmental changes by hindering growth through interferences with the blood supply, the destruction of growth centres or through the constricting effects of scar tissue.

Studies have shown that repairs of the lip and soft palate will re-establish the muscle balance across the cleft and this in turn moulds the displaced segments back to their normal relationship. (Slaughter and Pruzansky 1954, Pruzansky and Aduss 1964, Mazaheri et al 1971, Wada et al 1984, Malek et al 1984). When properly carried out, (i.e. repairs not resulting in tension and no large raw surfaces are left to heal by secondary intention) these two procedures should have no deleterious effects on maxillary growth.

However, all current procedures for hard palate repair require soft tissue flaps to be elevated and retropositioned, leaving large areas of denuded bone (especially in the alveolar cleft region) to heal by secondary intention with its resultant scar tissue formation. The contraction effects of wound-healing by secondary intention and the scar tissue subsequently formed, together with the local tissue deficiency in the cleft region, will lead to medial collapse of the alveolar segments. Subsequently, the constricting and unyielding effects of the scar tissue formed are conjectured to be the causes of maxillary growth inhibition and the development of crossbite malocclusions in complete cleft lip and palate patients. (Muir 1966, Ross 1970, Crikelair et al 1972, Dey 1974, Peat 1982, Kremenak 1984).

Collapse of the maxillary alveolar segments and other

maxillary deformities may be reflected as a lingual interdigitation of the maxillary teeth with their mandibular counterparts. In this study, the cleft side buccal segments were predominantly in crossbite malocclusion. This is consistent with the findings of Norden et al (1973), Dahl and Hanusardottir (1979) and Peat (1982) who reported between 75-100% of cases with crossbite malocclusions in the buccal segments. The pattern of the crossbite scores in this study also showed a decreasing score occurring from canine to molars, indicating that the crossbite malocclusions were due mainly to medial rotation or medial collapse of the lesser segments. (See Appendices 1,2,3,4.) Medial rotation of the lesser segments after surgical repair was also found in studies by Harvold (1954), Pruzansky and Aduss (1967), Handelman and Pruzansky (1968), Bernstein (1972), Bergland and Sidhu (1974), Dahl et al (1981), and Peat (1982). Many of the first permanent molars in this study were found to be in good bucco-lingual relationships with their lower counterparts. This was also one of the findings of Ranta et al (1974).

In this study, collapse of the alveolar segments was found in 81% of unilateral cases with the standard alveolar repair, whilst only 54% of unilateral cases with the triangular flap alveolar repair exhibited alveolar collapse. Pruzansky and Aduss (1967) found that medial collapse of the alveolar segments after lip

and palate repair occurred in 55.17% of their unilateral cleft lip and palate cases. Bernstein (1972) found a 10% increase in the incidence of collapse of the alveolar segments in cleft cases where the alveolar cleft had been repaired in infancy.

There have been many different surgical and orthodontic strategies used in combination or separately, to prevent or treat the collapsed maxillary arches and the subsequent crossbite malocclusion of cleft patients. These include, modifying the timing of surgical repairs, early maxillary orthopaedics, orthodontic expansion, bone-grafting, periosteoplasty and the use of different two-layered soft tissue flaps to repair the cleft palate. These techniques are intended to prevent collapse by either adding more soft or hard tissues to the cleft area (thus solving the localized problem of tissue deficiency) or by preventing the formation of large amounts of scar tissue through either improving the ratio between the cleft width and the lip and palatal tissues or through decreasing the amount of wound healing by secondary intention. Studies of the various successes and failures of these treatment strategies have been discussed in the literature review. Comparison of the results of some of these strategies with results from the current study are shown in Tables 4 to 7.

Comparisons of the results between different cleft

TABLE 4

Comparison of crossbite scores for repaired complete unilateral clefts of the lip and palate in the deciduous dentition stage with results from other studies

STUDY	TREATMENT	SAMPLE SIZE	ANTERIOR SCORE	CLEFT SEGMENT SCORE	NON-CLEFT SEGMENT SCORE	TOTAL SCORE
Huddart and Bodenham (1972)	Standard soft tissue primary repair.	34	-2.06	-3.98	-0.72	-6.76
Huddart (1973)	Pre-surgical orthopaedics.	40	-0.6	-3.9	-1.7	-6.2
	No Pre-surgical orthopaedics.	13	-0.5	-3.3	-1.9	-5.7
Hellquist and Ponten (1979)	One periosteoplasty.	21	-1.0	-3.8	-0.5	-5.3
	Two periosteoplasties.	15	-1.0	-4.1	-1.3	-6.4
Bomba (1979) N.B. Cases include ones with Simonart's bands.	Standard soft tissue repair.	25	-1.32	-5.44	-0.96	-7.72
	Standard soft tissue repair with Dey triangular flap.	27	-0.78	-4.54	-0.81	-6.04
Jonsson et al (1980)	Palate repair = vomer flap with skin graft.	11	-1.0	-1.8	-0.3	-3.1
	Palate repair = modified Von Langenbeck technique.	11	-0.4	-3.2	0	-3.6
Hellquist et al (1983)	Delayed periosteo-plasty.	19	-1.1	-4.0	-0.5	-5.6
Larson et al (1983)	Primary bone-grafting but No pre-surgical orthopaedics.	36	-1.8	-3.2	-0.4	-5.4
	Primary bone-grafting with pre-surgical orthopaedics.	45	-1.1	-3.5	-0.4	-5.0
Lennartsson et al (1984)	Post-surgical orthopaedic plate worn.	17	-1.81	-5.00	-1.19	-8.00
	Post-surgical orthopaedic plate SELDOM worn.	17	-0.44	-4.43	-0.69	-5.56
Present study (1985)	Standard soft tissue primary repair.	6	-1.83	-6.33	-1.16	-9.33
	Standard soft tissue primary repair with Dey Triangular Flap.	16	-0.87	-4.62	-0.31	-5.81

TABLE 5

Comparison of crossbite scores for repaired complete unilateral clefts of the lip and palate in the mixed dentition stage with results from other studies.

STUDY	TREATMENT	SAMPLE SIZE	ANTERIOR SCORE	CLEFT SEGMENT SCORE	NON-CLEFT SEGMENT SCORE	TOTAL SCORE
Friede and Johanson (1977)	Vomerflap, post-surgical orthopaedics and orthodontic expansion in deciduous dentitions.	50	-2.4	-4.7	-1.4	-8.5
	Vomer flap and primary bone-grafting with post-surgical orthopaedics and orthodontic expansion.	29	-3.2	-5.3	-2.8	-11.3
Hellquist and Ponten (1979)	one periosteoplasty.	21	-2.1	-3.4	-0.7	-6.2
	Two periosteoplasties (N.B. Both groups had maxillary expansion).	15	-1.4	-2.5	-1.1	-4.9
Larson et al (1983)	Primary bone-grafting but NO pre-surgical orthopaedics.	29	-2.2	-3.9	-0.8	-6.9
	Primary bone-grafting with pre-surgical orthopaedics.	9	-1.6	-3.7	-1.7	-7.0
Hellquist et al (1983)	Delayed periosteoplasty (Had orthodontic expansion).	19	-1.2	-2.7	-0.3	-4.1
Present study (1985)	Standard soft tissue primary repair.	19	-2.05	-6.15	-2.26	-10.47
	Standard soft tissue primary repair with Dey Triangular Flap.	18	-1.33	-5.11	-1.00	-7.44

TABLE 6

Comparison of crossbite scores for repaired complete bilateral clefts of the lip and palate in the deciduous dentition stage with results from other studies.

STUDY	TREATMENT	SAMPLE SIZE	ANTERIOR SCORE	CLEFT SCORE OR RIGHT SIDE	CLEFT SCORE OR LEFT SIDE	TOTAL SCORE
Hellquist et al (1983)	Delayed periosteo-plasty.	9	-0.4	-1.8	-3.1	-5.3
Larson et al (1983)	Pre-surgical orthodpaedics and primary bone grafting.	18	-1.2	-3.1	-3.6	-7.8
Present study (1985)	Standard soft tissue primary repair.	7	-0.28	-6.0	-6.14	-12.42
	Standard soft tissue primary repair with Dey Triangular Flap.	5	-1.6	-3.6	-3.8	-9.0

TABLE 7

Comparison of crossbite scores for repaired complete bilateral clefts of the lip and palate in the mixed and permanent dentition stages with results from other studies.

STUDY	TREATMENT	SAMPLE SIZE	ANTERIOR SCORE	CLEFT SCORE OR RIGHT SIDE	CLEFT SCORE OR LEFT SIDE	TOTAL SCORE
Friede and Johanson (1974)	Hard palate repair with vomer flap and primary bone graft. (After orthodontic treatment).	9	-3.1	-3.3	-3.7	-10.1
Friede and Johanson (1977)	Hard palate repair with vomer flap (Had post-surgical orthopaedics and some orthodontic treatment) to stop collapse.	13	-1.7	-3.5	-4.2	-9.4
Hellquist et al (1983)	Delayed periosteo-plasty (Had orthodontic expansion.	9	-0.9	-1.2	-1.9	-4.0
Larson et al (1983)	Pre-surgical orthopaedics and primary bone grafting.	9	-1.3	-4.1	-4.3	-9.8
Present study	Standard soft tissue primary repair.	3	-1.66	-5.0	-6.66	-13.33
	Standard soft tissue primary repair with Dey Triangular repair.	6	-1.00	-4.00	-4.33	-9.33

studies is not easy. The materials may vary to a considerable extent with respect to:-

1) the severity of the clefting and the ages of the subjects used.
2) the growth patterns of patients (genetic and environmental differences in populations).
3) the surgical and other treatment strategies used.
4) different operator skills and experiences (even day-to-day variations by the same operator are possible).
5) the timing of treatment procedures.
6) the evaluation of different variables.
7) sample sizes.
8) the measurement techniques used.

There is also the difficulty of isolating the effects of one type of treatment strategy for study, when for the sake of the patient, other treatment strategies have to be carried out. However, with these limitations taken into consideration, a relative comparison has been attempted. The studies in Tables 4 to 7 all use the Huddart and Bodenham (1972) method of evaluation, therefore facilitating the comparisons of the results of this study with those listed.

The present study is concerned with the use of the Dey triangular flap (Dey 1974) as a second layer or oral lining in the repair of the alveolar cleft. It is used to avoid wound healing by secondary intention. As

previously mentioned, the contraction phase of this type of wound-healing in the alveolar cleft region and the subsequent scar tissue formed as a result of traditional palatal repairs, are responsible for medial collapse of the alveolar segments and the subsequent anterior and posterior crossbite malocclusions developing. From the results (see Tables 2 and 3) it can be seen that in the buccal segments of both unilateral and bilateral cases, the mean crossbite scores for the Dey triangular flap groups are consistently lower than the mean scores for the Standard repair groups. There appears to be a trend towards lesser collapse of the buccal segments in the triangular flap groups. However, with the exception of the bilateral deciduous dentition groups, these results are not statistically significant.

Two other studies by Bomba (1979) and Brogan (1985) using the Dey triangular flap and the Muir flap respectively in their alveolar cleft repairs, have also found that the degree of lateral crossbite is significantly reduced with the use of these flap repairs. Brogan (1985) also found that fistulae were virtually eliminated in the palate with the use of the Muir flap. This was also observed in this study.

Dey (1974) felt that this flap prevented medial collapse of the alveolar segments by either eliminating the contracting effects of healing by secondary intention (i.e. healing of large raw or denuded surfaces) or by

its mere presence and bulk. He felt that the physical presence of this bulky triangular flap helped to maintain the correct relationships of the alveolar segments and, therefore, would prevent subsequent occlusal impairment from occurring following lip and palate repairs. The soft tissue nature of the repair in the alveolar cleft region also allows the maxillary segments to separate during growth and facilitates later orthodontic expansion, without the restricting effects of a solid bone graft. Dahl (1979), in a longitudinal study using implants, found that spontaneous transverse palatal growth was inhibited in cleft lip and palate patients. He felt that "ankylosis" of the segments of the maxilla due to surgery, was the cause of restricted transverse growth, so he recommended that procedures such as bone-grafting, which produced bony union in the palate, not be used during the growth period. He also felt that scarring should be kept to a minimum.

Harding and Mazaheri (1972) also felt that the spatial relationships of the alveolar segments would improve with dento-alveolar adaptation after lip repair, provided these segments were not locked in by a surgical design or by fibrous tissue and provided the tongue was normal.

Dey also observed that the flap appeared to maintain the proper anterior-posterior relationships of the upper incisor teeth with their lower counterparts. In this

study, even though anterior crossbites were found in both types of repair cases, the anterior scores for the cases with the Dey triangular flap repair were lower than the cases with the standard repair groups in both the deciduous and mixed dentition stages of the unilateral cases, thus verifying Dey's observations. But these results were again not statistically significant. It appears that with the use of the Dey triangular flap, the amount of healing by secondary intention is decreased and there is less scar tissue contraction to draw the teeth into anterior crossbites. There was no difference between the anterior scores for the permanent dentition group. An explanation for this result may be that, by the time the permanent dentition fully erupts into position, many other genetic and environmental factors and influences unspecific to the cleft are also contributing to the positions of the anterior teeth. Anterior crossbites can be either dento-alveolar or basal in origin. As previously mentioned, many of the upper central incisors were only in edge-to-edge relationships with their lower counterparts and many of the crossbites were only due to rotated incisors or to crowns that were palatally tipped, i.e. these crossbites were dentally rather than skeletally based. Godfrey (1985) felt that these rotated incisors were due to crowding. He felt that the lack of alveolar bone due to the cleft condition caused the teeth to develop in rotated positions.

Cases where the crowns of the incisor teeth were palatally displaced could be due to a taut upper lip repair, especially in the bilateral cases where tissue deficiency is more severe, or to bulky soft tissue being left in the area after the repair. It should be noted also that the improvement in the anterior scores was not found in the deciduous dentition of the bilateral cases and tissue deficiency and premaxillary protrusion could be the explanation for the taut upper lips and the subsequent results.

From Tables 4, 5, 6 and 7, it can be seen that the anterior score for the Dey triangular flap repair groups compares favourably with the anterior scores of other studies. The buccal segment scores of the Dey triangular flap group also compares favourably with the scores from other studies. It should be noted that many of the cases in the studies listed have had orthodontic treatment of some form prior to their being scored, whereas the cases in this study were scored prior to any form of orthodontic treatment.

Figure 19 shows the maintenance of good arch form with the alveolar segments in alignment by the Dey triangular flap in two unilateral cases and a bilateral case. For comparison, two unilateral cases and a bilateral case from the standard repair group have been photographed below. Note the more severe collapse of the alveolar segment in these cases.

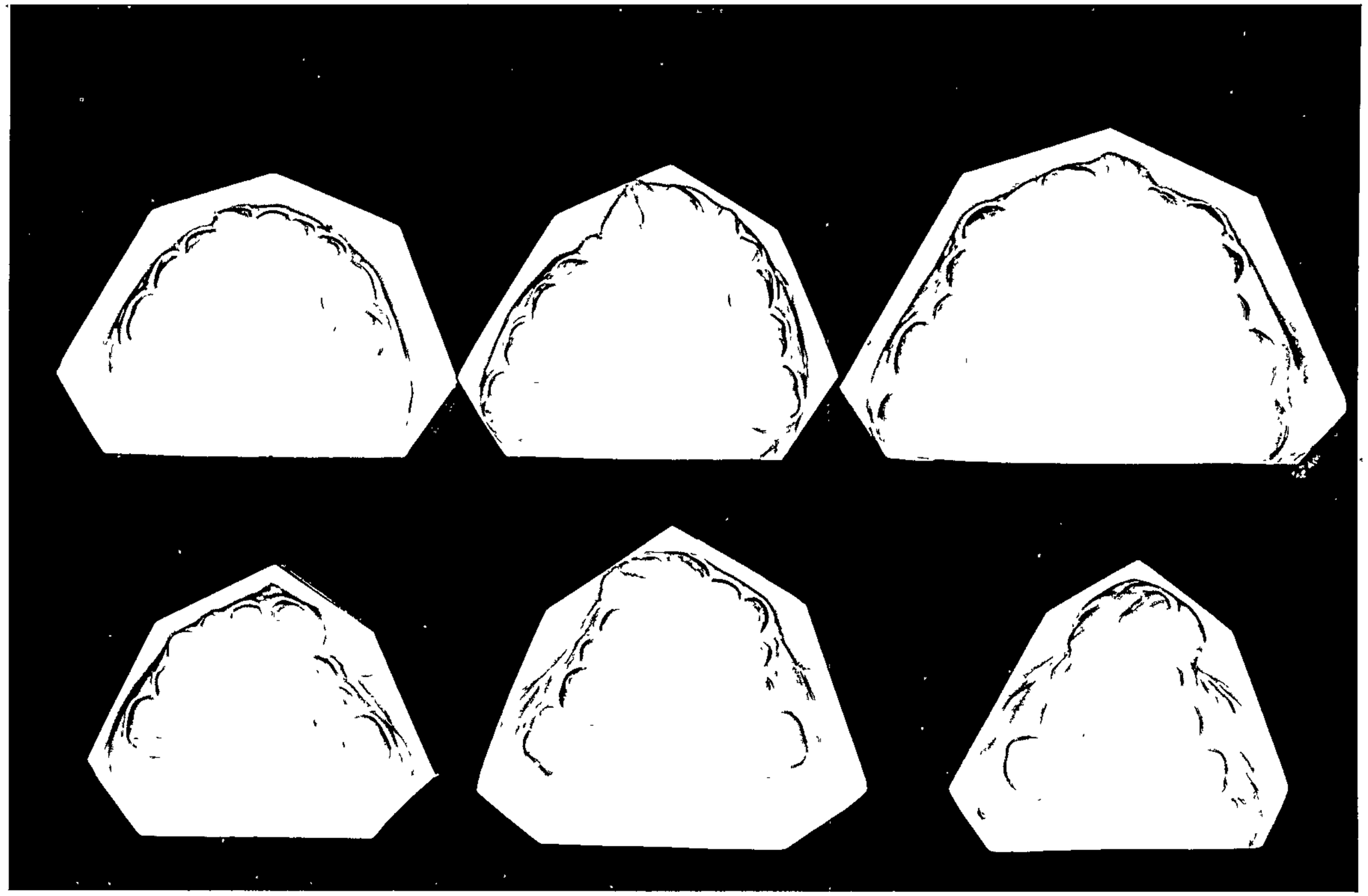

FIGURE 19

The top row shows the maintenance of alveolar segments in alignment and good arch form in two unilateral cases and a bilateral case in which Dey triangular flaps were placed. For comparison, two unilateral cases and a bilateral case from the Standard repair group have been photographed in the bottom row. Note the more severe collapse of the alveolar segments in these cases.

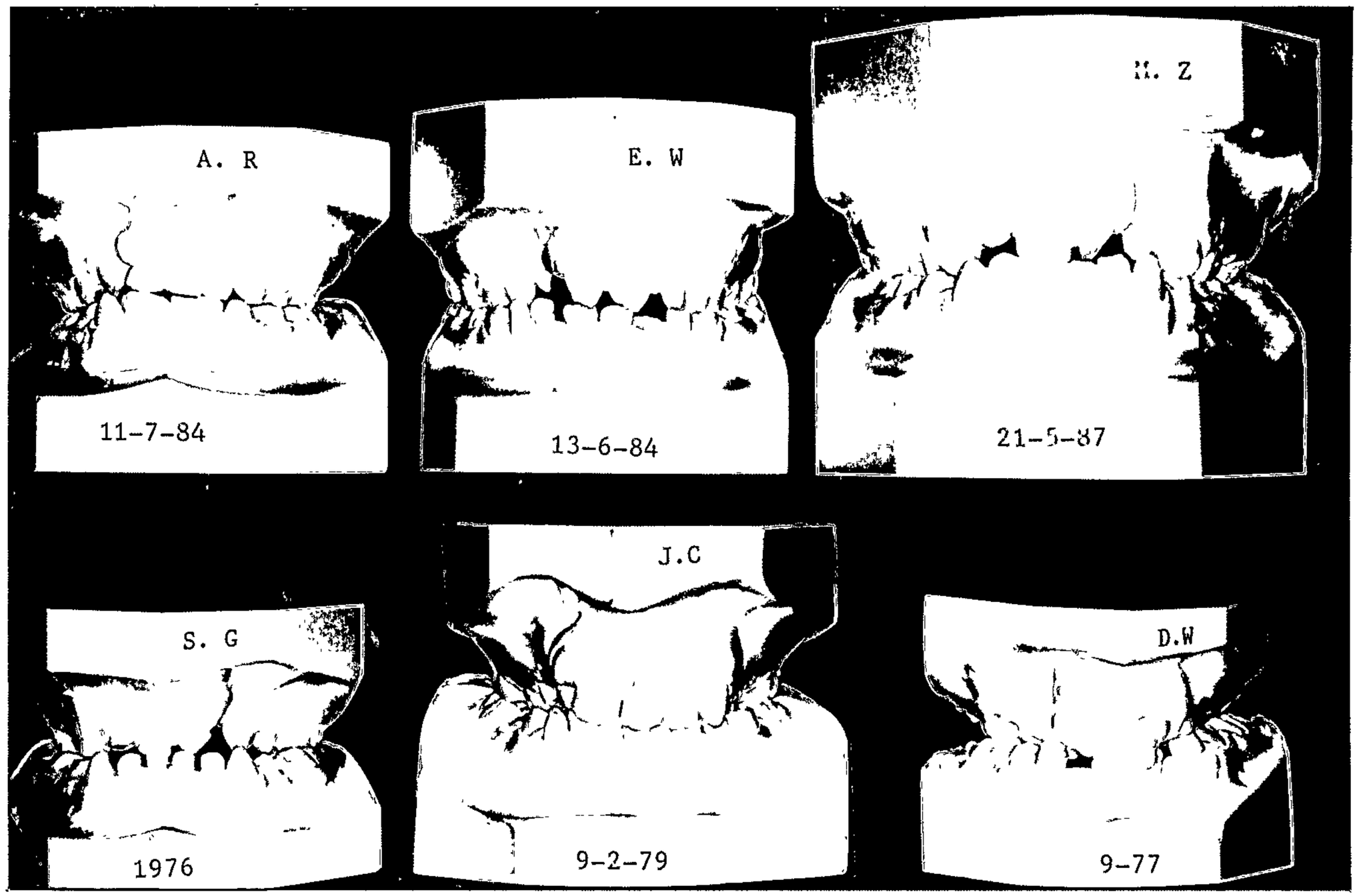

FIGURE 20

This shows the occlusion of the previous three cases from the Dey triangular flap group on the top row. For comparison, the previous three cases from the Standard repair group have been photographed in the bottom row. Note that the cases from the Dey triangular flap group have a lesser degree of crossbites.

Figure 20 shows the occlusion of three cases from the Dey triangular flap group and three cases from the standard repair group. Note the difference in severity of the crossbites between cases from the two groups.

The improvement in the scores of the Dey triangular flap groups could also be due to the general improvement in surgical techniques and skills of the surgeons with time, as all the cases with the Dey triangular flap repair were carried out post-1972, while the Standard repair group was carried out pre-1972. If this had been a prospective study, then the explanation above could have been clarified by including in the study, a group of post-1972 patients who did not have Dey triangular flaps placed in their operations.

Although no cephalometric study was undertaken, photographs of the patients showed only a slight maxillary retrusion in most cases, especially those operated on after 1972 with the Dey triangular flaps. If maxillary growth inhibition were significant, one would expect to see dental manifestations in the form of an increased incidence of anterior and posterior crossbite scores in these cases. i.e. a predominance of -2 and -3 scores for each individual tooth. Except for the canine scores, this was not the case. The anterior crossbite scores were mainly due to dental causes and the buccal scores were due to medial rotations of the alveolar segments rather than inhibition of transverse

maxillary growth. The observation that most of the upper first permanent molars were in good bucco-lingual relationships with their lower counterparts helps to verify this. However, the study models of the patients from this study were taken prior to the patients reaching their pubertal growth period, so late growth may still play a part in affecting skeletal relationships, although Godfrey (1985) believes that the pattern of malocclusion in cleft children is established very early (in the deciduous dentition stage) and will change only if additional traumatic influences prevail later on.

SUMMARY AND CONCLUSIONS

A study was carried out to investigate the effectiveness of a surgical modification to the repair of the anterior palate in preventing collapse of the maxillary alveolar segments and in reducing the degree of crossbite malocclusions developing in cleft lip and palate patients. The surgical modification entailed the addition of a triangular labial flap (Dey 1974) as a second layer to reinforce the standard one-layered closure of the cleft alveolus. The purpose of this flap is to prevent the palatal surface of the cleft alveolus healing by secondary intention. Wound contraction during healing by secondary intention tends to draw the alveolar segments and teeth medially resulting in arch collapse and crossbite malocclusions. It was hoped that the bulky nature of the flap would also act as a soft tissue bridge or spacer to maintain the alveolar segments in their correct relationships, at the same time allowing the segments to move apart with growth.

A review of the literature shows that collapse of the maxillary alveolar segments and lateral crossbite malocclusions are prevalent in patients with clefts of the lip and palate. It also shows that although collapse of the alveolar segments occurs primarily after surgical repairs of the lip and palate, a small degree of collapse and crossbite malocclusion can also be found in newborn infants and unrepaired cleft cases.

Experimental and clinical studies seem to indicate that the contraction effects of wound healing by secondary intention and of the scar tissue that subsequently forms, together with the local tissue deficiency due to the cleft are the main causes of arch collapse and crossbite malocclusion developing in cleft lip and palate patients. The literature review also looks at the more commonly used orthodontic and surgical strategies used in the past and present to reduce or prevent the collapse of the alveolar segments and the development of crossbite malocclusion in cleft patients.

The arch form and dental occlusion of 91 children born with complete cleft lip and palate were studied prior to their having any form of orthodontic correction done. The Huddart and Bodenham (1972) method of evaluation was used. All the children had standard lip and anterior palate closures when they were between 6 weeks to 3 months old and had Wardill-V-Y posterior palate closures at 9 to 12 months old. They were divided into 2 main groups - a control group and an experimental group. The experimental group all had a Dey triangular labial flap added to their alveolar cleft repairs. Although the results were not statistically significant and arch collapse and buccal crossbites were found in both groups, there appeared to be a trend for the cases with the Dey triangular flap added to have a lesser degree of buccal crossbites and arch - collapse than the control group. It was also observed that the anterior scores

for the deciduous and mixed dentition unilateral cases of the Dey triangular flap group were lower than the control group. The clinical impression is that anterior crossbites are dentally rather than skeletally based. Although no cephalometric study was undertaken, the photographs and crossbite scores showed that the flap had no significant effects on maxillary growth. The anterior and posterior scores of the Dey triangular flap group also compared favourably with those from other studies.

It appears that the Dey triangular flap has no negative effects on the dental arch and the occlusion of cleft lip and palate patients. Instead it may have a useful effect in reducing dental arch collapse and crossbite malocclusions by minimising the degree of healing by secondary intention and the amount of scar tissue subsequently formed and their deleterious effects on the dental arch and occlusion. The soft tissue nature of the alveolar cleft repair allows the maxillary segments to separate during growth, facilitates orthodontic expansion and enables the placement of a secondary bone-graft later on when maxillary growth inhibition is no longer a problem.

BIBLIOGRAPHY

ABYHOLM F.E., BERGLAND O., and SEMB G., (1981): Secondary bone-grafting of alveolar clefts. Scand J Plast Reconstr Surg. 15: 127-140.

ABYHOLM F.E., BORCHGREVINK H.C. and ESKELAND G., (1981): Cleft lip and palate in Norway, Part III-Surgical treatment of CLP patients in Oslo 1954-75. Scand J Plast Reconstr Surg. 15: 15-28.

ADUSS H., and PRUZANSKY S., (1968): Width of cleft at level of the tuberosities in complete unilateral cleft lip and palate. Plast Reconstr Surg. 41(2): 113-123.

ATHANASIOU A.E., MAZAHERI M., and ZARRINNIA K., (1986): Frequency of crossbite in surgically treated cleft lip and/or palate children. J Pedodontics. 10(4): 340-351.

ATHERTON J.D., (1967): Morphology of facial bones in skulls with unoperated unilateral cleft palate. Cleft Palate J. 4: 18-30.

BACKDAHL M., and NORDIN K.E., (1961): Replacement of the maxillary bone defect in cleft palate - A new procedure. Acta Chir Scand. 122: 131-137.

BARDACH J., BAKOWSKA J., McDERMOTT - MURRAY J., MOONEY M.P., and DUSDIEKER L.B., (1984A): Lip pressure changes following lip repair in infants with unilateral clefts of the lip and palate. Plast Reconstr Surg. 74: 476-481.

BARDACH J., KLAUSNER E.C., and EISBACH K.J., (1979): The relationship between lip pressure and facial growth after cleft lip repair: An experimental study. Cleft Palate J. 16: 137-146.

BARDACH J., and MOONEY M., (1984): The relationship between lip pressure following lip repair and craniofacial growth: An experimental study in Beagles. Plast Reconstr Surg. 73: 544-555.

BARDACH J., MORRIS H.L., and OLIN W.H., (1984B): Late Results of primary Veloplasty: The Marburg Project. Plast Reconstr Surg. 73: 207-215.

BATTLE R.J.V., and WHITFIELD P., (1970): The significance of the pre-alveolar cleft in assessing a prognosis in future maxillary development. Cleft Palate J. 6: 397-401.

BERGLAND O., and SIDHU S.S., (1974): Occlusal changes from the deciduous to the early mixed dentition in unilateral complete clefts. Cleft Palate J. 11: 317-326.

BERKOWITZ S., (1985): Timing Cleft Palate CLosure - Age should not be the sole determinant.
J Craniofacial Genetics and Developmental Bio Suppl. 1: 69-83. Samuel Pruzansky Festschrift Edition.

BERKOWITZ S., GONZALEZ G., and NGHIEM-PHU L., (1982): An optical profilometer - A new instrument for the three- dimensional measurement of cleft palate casts.
Cleft Palate J. 19(2): 129-138.

BERKOWITZ S., and PRUZANSKY S., (1968): Stereophotogrammetry of serial casts of cleft palate.
Angle Orthod. 38(2): 136-149.

BERNSTEIN L., (1972): Dental Occlusion and early repair of alveolar clefts. Arch Otolaryng. 96: 395-399.

BISHARA S.E., (1974): Comparisons of the effect of two palatoplasties on facial and dental relations.
Cleft Palate J. 11: 261-271.

BISHARA S.E., ENEMARK H., and THARP R.F., (1976A): Cephalometric comparisons of the results of the Wardill-Kilner and Von Langenbeck palatoplasties.
Cleft Palate J. 13: 319-329.

BISHARA S.E., JAKOBSEN J.R., KRAUSE J.C., and SOSA-MARTINEZ R., (1986): Cephalometric comparisons of individuals from India and Mexico with unoperated cleft lip and palate. Cleft Palate J. 23: 116-125.

BISHARA S.E., KRAUSE J.C., OLIN W.H., WESTON D., VAN NESS J., and FELLING C., (1976B): Facial and dental relationships of individuals with unoperated clefts of the lip and/or palate. Cleft Palate J. 13: 238-252.

BISHARA S.E., SOSA-MARTINEZ R., PATRON-VALES H., and JAKOBSEN J.R., (1985): Dentofacial relationships in individuals with unoperated clefts: comparisons between three cleft types. Am J Orthod. 87(6): 481-507.

BJORK A., (1966): Sutural growth of the upper face studied by the implant method.
Acta Odontol Scand. 24: 109-127.

BLIJDORP P., and EGYEDI P., (1984): The influence of age at operation for clefts on the development of the jaws. J Maxillofac Surg. 12: 193-200.

BLOCKSMA R., LEUZ C.A., and MELLERSTIG K., (1975): A conservative program for managing cleft palates without the use of mucoperiosteal flaps.
Plast Reconstr Surg. 55: 160-169.

BOMBA I., (1979): Thesis, University of Sydney.

BOYNE P.J., and SANDS N.R., (1976): Combined orthodontic-surgical management of residual palato-alveolar cleft defects. Am J Orthod. 70: 20-37.

BRAUER R.O., and CRONIN T.D., (1964): Maxillary orthopaedics and anterior palate repair with bone grafting. Cleft Palate J. 1: 31-42.

BRAUN T.W., and SOTEREANOS G.C., (1981): Alveolar reconstruction in adolescent patients with cleft palates. J Oral Surg. 39: 510-517.

BROGAN W.F., (1973): The early management of cleft lip and palate deformities. Aust Dent J. 18: 212-217.

BROGAN W.F., (1985): Personal communication.

BROGAN W.F., (1986): Cleft Palate Conference Sydney, February 1986.

BROPHY T.W., (1923): Cleft Lip and Palate. pp. 73. Philadelphia, Blakiston Co.

BROWNE D., (1949): Harelip.
Ann Roy Col Surg Engl. 5: 169.

BURIAN F., (1955): On the disturbances of growth of the upper jaw in operated cleft lips and palates. International Congress of Plastic and Reconstructive Surgery. Transactions of 1st Congress. pp. 224-228. Baltimore, Williams and Wilkins.

BURSTON W R., (1958): The early orthodontic treatment of cleft palate conditions. Dent Pract. 9: 42-52.

BURSTON W.R., (1960): The pre-surgical orthopaedic correction of the maxillary deformity in clefts of both primary and secondary palate. Trans Internat Soc Plastic Surg, 2nd cong, 1959. Edinburgh and London: E and S Livingston Ltd., 28-35.

BUTOW K.W., (1984): A relationship measurement method for the analysis of complete unilateral cleft lip and palate cases. Cleft Palate J. 21: 317-322.

CAMPBELL A., (1926): The closure of congenital clefts of the hard palate. Br J Surg. 13: 715-719.

CHAPMAN J.H., (1966): A serial growth study of children with unilateral cleft lip and palate from 6 to 16 years. Aust Orthodont Bull. 4(6): 4-7.

COUPE T.B., and SUBTELNY J.D., (1960): Cleft palate - deficiency or displacement of tissue?
Plast Reconst Surg. 26: 600-612.

CRIKELAIR G.F., (1969): Why repair a cleft lip? Cleft Palate J. 6: 93-107.

CRIKELAIR G.F., PRICE R., and COSMAN B., (1972): Hourglass maxillary collapse in repaired post alveolar clefts of the palate. Cleft Palate J. 9: 13-17.

DAHL E., (1979): Transverse maxillary growth in combined cleft lip and palate. Cleft Palate J. 16: 34-41.

DAHL E., and HANUSARDOTTIR B., (1979): Prevalence of malocclusion in the primary and early mixed dentition in Danish children with complete cleft lip and palate. Eur J Orthod. 1: 81-88.

DAHL E., HANUSARDOTTIR B., and BERGLAND O., (1981): A comparison of occlusions in two groups of children whose clefts were repaired by three different surgical procedures. Cleft Palate J. 17: 122-127.

DAVIES D., (1966): The one-stage repair of unilateral cleft lip and palate: A preliminary report. Plast Reconstr Surg. 38: 129-136.

DAVIES D., (1985): Cleft Lip and Palate. Br. Med J. 290: 625.

DELAIRE J., (1978A): The potential role of facial muscles in monitoring maxillary growth and morphogenesis. In: Muscle adaptation in the Craniofacial Region. Monograph No.8 in the Craniofacial Growth Series, Centre for Human Growth and Development. The University of Michigan, Ann Arbor, Michigan. Editors-D.S. Carlson, J.A. McNamara Jr. pp. 157-180.

DELAIRE J., (1978B): Theoretical principles and techniques of functional closure of the lip and nasal aperture. J Maxillofac Surg. 6: 109-116.

DEY D.L., (1974): A surgeon's view of the congenitally cleft maxilla. Med J Aust. 1: 708-711.

EDWARDS M., and WATSON A.C.H., (eds) (1980): Advances in the Management of Cleft Palate, Churchill Livingstone, Edinburgh, London, Melbourne and New York. pp 134-165.

EL DEEB M., MESSER L.B., LEHNERT M.W., HEBDA T.W., and WAITE D.E., (1982): Canine eruption into grafted bone in maxillary alveolar cleft defects. Cleft Palate J. 19: 9-16.

ENANY N.M., (1981): A cephalometric study of the effects of primary osteoplasty in unilateral cleft lip and palate individuals. Cleft Palate J. 18: 286-292.

ENGDAHL E., (1972): Bone regeneration in maxillary defects. Scand J Plast Reconstr Surg Suppl. 8, 66: 1-79.

FARA M., (1968): Anatomy and arteriography of cleft lips in stillborn children.
Plast Reconstr Surg. 42: 29-36.

FISHER J.L., GODFREY K., and STEPHENS R.I., (1976): Experimental strain analysis of infant adolescent and adult miniature swine skulls subjected to simulated mastication forces. J Biomechanics. 9: 333-338.

FOSTER T.D., (1962): Maxillary deformities in repaired clefts of the lip and palate.
Br J Plast Surg. 15: 182-190.

FRANKEL R., (1969): The treatment of Class II Division 1 malocclusion with functional correctors.
Am J Orthod. 55: 265-275.

FRIEDE H., (1978): The Vomero-premaxillary suture - A neglected growth site in mid-facial development of unilateral cleft lip and palate patients.
Cleft Palate J. 15: 398-404.

FRIEDE H., and JOHANSON B., (1974): A follow-up study of cleft children treated with primary bone grafting.
Scand J Plast Reconstr Surg. 8: 88-103.

FRIEDE H., and JOHANSON B., (1977): A follow-up study of cleft children treated with vomer flap as part of a three-stage soft tissue surgical procedure.
Scand J Plast Reconstr Surg. 11: 45-57.

FRIEDE H., LILJA J., and JOHANSON B., (1980): Cleft lip and palate treatment with delayed closure of the hard palate. Scand J Plast Reconstr Surg. 14: 49-53.

FRIEDE H., and MORGAN P., (1976): Growth of the vomero-premaxillary suture in children with bilateral cleft lip and palate. Scand J Plast Reconstr Surg. 10: 45-55.

GAVRON G., HAITAS G., SMIT G.L., WALKER D.H., and WOLFAARDT J., (1984): Long term results of one-stage and two-stage repairs of the cleft palate.
In: Hotz et al (ed) (1986) Op. Cit. pp.150-154.

GILLIES H.D., and FRY W.K., (1921): A new principle in the surgical treatment of congenital cleft palate and its mechanical counterpart. Br Med J. 1: 335-338.

GNOINSKI W.M., (1982): Early maxillary orthopaedics as a supplement to conventional primary surgery in complete cleft lip and palate cases - long term results.
J Maxillofac Surg. 10: 165-172.

GODFREY K., (1984): The Sydney Approach. In: Hotz et al (ed) (1986) Op. Cit. pp.172-175.

GODFREY K., (1985): Personal communication.

GRABER T.M., (1950): Changing philosophies in cleft palate management.
The Journal of Pediatrics. 37: 400-415.

GRABER T.M., (1964): A study of cranio-facial growth and development in the cleft palate child from birth to six years of age. In: Hotz R (ed) (1964) - Early Treatment of Cleft Lip and Palate, Hans Huber Medical Publisher, Berne. pp.30-43.

GRABER T.M., (1972): Orthodontics - Principles and Practice. 3rd edition, Philadelphia, London, W.B. Saunders Co. pp.139-144.

HAGERTY R.F., (1957): Cleft lip repair - Its orthodontic significance. Angle Orthod. 27: 1-10.

HAGERTY R.F., ANDREWS E.B., HILL M.J., CALCOTE C.E., KARESH S.H., LIFSCHIZ J.M., and SWINDLER D.R., (1964): Dental arch collapse in cleft palate.
Angle Orthod. 34: 25-36.

HAGERTY R.F., and HILL., M.J., (1963): Facial growth and dentition in the unoperated cleft palate.
J Dent Res. Vol 42 (Suppl. 1) pp.412-421.

HAGERTY R.F., and MYLIN W.K., (1981): Facial growth and arch symmetry in the surgical prosthetic treatment of cleft lip and palate.
Plast Reconstr Surg. 68: 682-688.

HANADA K., and KROGMAN W.M., (1975): A longitudinal study of post-operative changes in the soft tissue profile in bilateral cleft lip and palate from birth to six years. Am J Orthod. 67: 363-376.

HANDELMAN C.S., and PRUZANSKY S., (1968): Occlusion and dental profile with complete bilateral cleft lip and palate. Angle Orthod. 38: 185-198.

HARDING R.L., and MAZAHERI M., (1972): Growth and spatial changes in the arch form in bilateral cleft lip and palate patient. Plast Reconstr Surg. 50: 591-599.

HARVOLD E., (1954): Cleft lip and palate - Morphologic studies of facial skeleton. Am J Orthod. 40: 493-506.

HELLQUIST R., and PONTEN B., (1979): The influence of infant periosteoplasty on facial growth and dental occlusion from five to eight years of age in cases of complete unilateral cleft lip and palate.
Scand J Plast Reconstr Surg. 13: 305-212.

HELLQUIST R., and SVARDSTROM K., (1984): Changes in the treatment programme - 1964 to 1984 at the Uppsala Cleft Palate Centre.
In: Hotz et al (ed) (1986) Op. Cit. pp.131-134.

HELLQUIST R., SVARDSTROM K., and PONTEN B., (1983): A longitudinal study of delayed periosteoplasty to the cleft alveolus. Cleft Palate J. 20: 277-288.

HOTZ M., (1973): Aims and possibilites of pre- and post-surgical orthopaedic treatment in uni- and bi-lateral clefts. Trans Eur Orthod Soc. pp. 553-558.

HOTZ M., (1983): Orofacial development under adverse conditions. Eur J Orthod. 5: 91-103.

HOTZ M., and GNOINSKI W., (1976): Comprehensive care of cleft lip and palate children at Zurich University: A preliminary report. Am J Orthod. 70: 481-503.

HOTZ M., and GNOINSKI W., (1979): Effects of early maxillary orthopaedics in co-ordination with delayed surgery for cleft lip and palate.
J Maxillofac Surg. 7: 201-210.

HOTZ M., GNOINSKI W., PERKO M., NUSSBAUMER H., HOF E., and HAUBENSAK R., (eds.) (1986): Early treatment of cleft lip and palate - Proceedings of the third international symposium held at the University of Zurich, Switzerland 1984. Hans Huber Publishers Toronto, Lewiston, N.Y. Bern, Stuttgart.

HOTZ M., GNOINSKI W., PERKO M., NUSSBAUMER H., HOF E., and HAUBENSAK R., (1984): The Zurich approach 1964 - 1984. In: Hotz et al (ed) (1986) Op. Cit. pp. 42-48.

HUDDART A.G., (1961): Pre-surgical dental orthopaedics. Trans Br Soc Study Orthod. pp. 107-118.

HUDDART A.G., (1967A): Treatment procedures in cleft lip and palate cases. Br Dent J. 122: 185-192.

HUDDART A.G., (1967B): An analysis of the maxillary changes following pre-surgical dental orthopaedic treatment in unilateral cleft lip and palate cases.
Trans Eur Orthod Soc. 43: 299-317.

HUDDART A.G., (1970): Maxillary arch dimensions in bilateral cleft lip and palate subjects.
Cleft Palate J. 7: 139-155.

HUDDART A.G., (1973): An evaluation of pre-surgical treatment. Br J Orthod. 1: 21-25.

HUDDART A.G., (1979): Pre-surgical changes in unilateral cleft lip and palate. Cleft Palate J. 16: 147-157.

HUDDART A.G., (1984): Arch alignment and pre-surgical treatment - The West Midlands Approach.
In: Hotz et al (ed) (1986) Op. Cit. pp.37-41.

HUDDART A.G., and BODENHAM R.S., (1972): The evaluation of arch form and occlusion in unilateral cleft palate subjects. Cleft palate J. 9: 194-201.

HUDDART A.G., and CRABB J.J., (1977): The effects of presurgical treatment on palatal tissue area in unilateral cleft lip and palate subjects.
Br J Orthod. 4: 181-185.

HUDDART A.G., GOLDIN J.G., and STUFFINS G.M., (1983): Simultaneous lip and palate repair - A long term evaluation. Paper presented at 1983 Craniofacial Society International meeting (Birmingham).

HUDDART A.G., MacCAULEY F.J., and DAVIES M.E.H., (1969): Maxillary arch dimensions in normal and unilateral cleft palate subjects. Cleft Palate J. 6: 471-487.

INNIS C.O., (1962): Some preliminary observations on unrepaired hare-lips and cleft palates in adult members of the Dusan tribes of North Borneo.
Br J Plast Surg. 15: 173-181.

ISSHIKI N., and MORIMOTO M., (1968): Anterior cleft palate closure by turnover flaps.
Plast Reconstr Surg. 42: 249-251.

JACKSON I.T., SCHEKER L.R., VANDERVORD J.G., and McLENNAN J.G., (1981): Bone marrow grafting in the secondary closure of alveolar-palatal defects in children. Br J Plast Surg. 34: 422-425.

JACOBSON B.N., and ROSENSTEIN S.W., (1984): Early maxillary orthopaedics for the newborn cleft lip and palate patient - An impression and an appliance.
Angle Orthod. 54: 247-263.

JOLLEYS A., and ROBERTSON N.R.E., (1972): A study of the effects of early bone-grafting in complete clefts of the lip and palate - five-year study.
Br J Plast Surg. 25: 229-237.

JONSSON G., STENSTROM S., and THILANDER B., (1980): The use of a vomer flap covered with an autogenous skin graft as a part of the palatal repair in children with unilateral cleft lip and palate.
Scand J Plast Reconstr Surg. 14: 13-21.

JONSSON G., and THILANDER B., (1979): Occlusion, arch dimensions and craniofacial morphology after palatal surgery in a group of children with clefts in the secondary palate. Am J Orthod. 76: 243-255.

JORGENSON R.J., SHAPIRO S.D., and ODINET K.L., (1984): Studies on facial growth and arch size in cleft lip and palate. J Craniofac Genet Dev Biol 4: 33-38 - Abstract in Cleft Palate J. (1985) 22: 140.

KAPLAN E.N., (1981): Cleft palate repair at three months? Ann Plast Surg. 7: 179-190.

KAPLAN E.N., (1982): Lip repair: Problems and solutions. In: KERNAHAN D.A., and THOMSON H.G., (eds): Symposium on Pediatric Plastic Surgery. Vol. 21. St Louis: C.V. Mosby. pp.70.

KERNAHAN D.A., and BAUER B.S., (1983): Functional cleft lip repair: A sequential, layered closure with orbicularis muscle realignment.
Plast Reconstr Surg. 72: 459-466.

KILNER T., (1937): Cleft lip and palate repair technique. St Thomas's Hosp Rep. 2:237-140.

KLING A., (1964): Evaluation or results with reference to the bite. In: Hotz R., (ed) (1964): Early Treatment of Cleft Lip and Palate, Hans Huber Medical Publisher, Berne. pp 193-197.

KREMENAK C.R., (1984): Physiological aspects of wound healing: Contraction and growth.
Otolaryngol Clin North Am. 17: 437-453.

KREMENAK C.R., and SEARLS J.C., (1971): Experimental Manipulation of mid-facial growth: A synthesis of five years of research at the Iowa Maxillo-facial Growth Laboratory. J Dent Res. 50: 1488-1491.

KREMENAK C.R., WADA T., SEARLS J.C., MOORE C., SEYDEL S., MONAHAN C., and TATMAN D., (1985): Effects of age at palate surgery on maxillary growth.
J Dent Res. 64 (special issue): 349, Abstract 1567.

KREMENAK C.R., WADA T., SEYDEL S., MORRIS J., ALLEN T., MATHEWS Jr. J., and OLIN Jr. W., (1978): Effects of V-Y palatoplasty simulations on maxillary growth in Beagles.
J Dent Res. 57 (Special issue A): 94, Abstract 77.

LANNELONGUE (1872): Quoted by Millard D.R. Jr (1980) Op Cit. pp.249.

LARSON O., IDEBERG M., and NORDIN K.E., (1983): Early bone-grafting in complete cleft lip and palate cases following maxillo-facial orthopaedics. Part III - A study of the dental occlusion.
Scand J Plast Reconstr Surg. 17: 81-92.

LATHAM R.A., and BURSTON W.R., (1964): The effect of unilateral cleft of the lip and palate on maxillary growth pattern. Br J Plast Surg. 17: 10-17.

LE MESURIER A.B., (1949): A method of cutting and suturing the lip in the treatment of complete unilateral clefts. Plast Reconstr Surg. 4: 1-12.

LENNARTSSON B., FRIEDE H., and JOHANSON B., (1984): Effects of post-surgical jaw orthopaedic treatment in unilateral cleft lip and palate patients. Scand J Plast Reconstr Surg. 18: 227-231.

LINDSAY W.K., (1972): Surgery. In: ROSS R.B., and JOHNSTON M.C., (1972). Op. Cit. Chapter 9. pp 121-151.

LLEWELYN D., (1986): Personal communication.

LUBIT E.C., (1976): Cleft palate orthopaedics: Why, when, how. Am J Orthod. 69: 562-571.

LYNCH J.B., KERNWISNER H., EVANS R., BARNETT R., and LEWIS S.R., (1970): Cephalometric study of maxillary growth five years after alveolar bone-grafting of cleft palate infants. Plast Reconstr Surg. 46: 564-567.

MALEK R., PSAUME J., MOUSSET M.R., and TRICHET C., (1984): A new sequence and a new technique in complete cleft lip and palate repair. In: Hotz et al (ed) (1986). Op. Cit. pp. 162-166.

MANCHESTER W.M., (1965): The repair of bilateral cleft lip and palate. Br J Surg. 52: 878-882.

MATTHEWS D., BROOMHEAD I., GROSSMANN W., and GOLDIN H., (1970): Early and late bone-grafting in cases of cleft lip and palate. Br J Plast Surg. 23: 115-129.

MAZAHERI M., HARDING R.L., COOPER J.A., MEIER J.A., and JONES T.S., (1971): Changes in arch form and dimensions of cleft patients. Am J Orthod. 60: 19-32.

McCOMB H., (1975): Primary repair of the bilateral cleft lip nose. Br J Plast Surg. 28: 262-267.

McCOMB H., and BROGAN W.F., (1984): Early treatment of cleft lip and palate in Perth, Western Australia. In: Hotz et al (ed) (1986) Op Cit. pp. 170-171.

McCREDIE J., (1974): Embryonic neuropathy - A hypothesis of neurocrest injury as the pathogenesis of congenital malformations. Med J Aust. 1: 159-163.

McNEIL C.K., (1954): Oral and Facial Deformity, Pitman, London.

MESTRE J.C., DeJESUS J., and SUBTELMY J.D., (1960): Unoperated clefts at maturation. Angle Orthod. 30: 78-85.

MILLARD D.R., (1955): A primary camouflage of the unilateral harelip. Transactions of the International Society of Plastic Surgeons, 1st Congress, Baltimore, The Williams and Wilkins Co., 1957. pp. 160.

MILLARD D.R. Jr., (1976): Cleft Craft: The Evolution of its Surgery - Vol. I: The Unilateral Deformity, Boston, Little, Brown and Co. pp. 251.

MILLARD D.R. Jr., (1980): Cleft Craft: The Evolution of its Surgery - Vol III: Alveolar and Palatal Deformities, Boston, Little, Brown and Co. pp. 733-744.

MONROE C.W., GRIFFITH B.H., ROSENSTEIN S.W., and JACOBSON B.N., (1968): The correction and preservation of arch form in complete clefts of the palate and alveolar ridge. Plast Reconstr Surg. 41: 108.

MOSS M.L., (1971): Facial Growth: The Functional Matrix Concept. In: Grabb W., Rosenstein S., Bzoch K., (ed) (1971): Cleft Lip and Palate, Boston, Little, Brown and Co. pp.97-107.

MOWBRAY J.B., (1977): A cephalometric appraisal of a group of children with surgically repaired unilateral cleft lip and palate. Br J Orthod. 4: 33.

MOYERS R.E., (1973): Handbook of Orthodontics for the Student and General Practitioner, 3rd Ed., Year Book Medical Publishers Inc., Chicago, pp. 313.

MUIR I.F.K, (1966): Repair of cleft alveolus. Br J Plast Surg. 19: 30-36.

MULLIKEN J.B., (1985): Principles and techniques of bilateral complete cleft lip repair. Plast Reconstr Surg. 75: 477-486.

MUSGRAVE R.H., (1971): General Aspects of Unilateral Cleft Lip Repair. In: Grabb W., Rosenstein S., Bzoch K., (ed) (1971): Cleft Lip and Palate, Boston, Little, Brown and Co. pp. 175-194.

NARULA J.K., and ROSS R.B., (1970): Facial growth in children with complete bilateral cleft lip and palate. Cleft Palate J. 7: 239-248.

NORDEN E., LINDER-ARONSON S., and STENBERG T., (1973): The deciduous dentition after only primary surgical operations for clefts of the lip, jaw and palate. Am J Orthod. 63: 229-236.

NORDIN K.E., and JOHANSON B., (1955): Freie Knochen - transplantation bei Einstellung der Maxilla bei Lippen - Kiefer-Gaumenspalten. Fortschritte Kiefer - und Gesichtschirurgie 1, 168 - quoted by Robertson N.R.E., and Jolleys A., (1983): Op Cit.

NORDIN K., LARSON O., NYLEN B., and EKLUND G., (1983): Early bone-grafting in complete cleft lip and palate cases following maxillofacial orthopaedics - I - Method and the skeletal development from 7-13 years of age. Scand J Plast Reconstr Surg. 17: 33-50.

O'DONNEL J., KRISCHER J.P., SHIERE and F.R., (1974): An analysis of presurgical orthopaedics in the treatment of unilateral cleft lip and palate.
Cleft Palate J. 11: 374-393.

OGIDAN O., and SUBTELNY J.D., (1983): Eruption of incisor teeth in cleft lip and palate.
Cleft Palate J. 20: 331-341.

ONIZUKA T., and ISSHIKI Y., (1975): Development of the palatal arch in relation to unilateral cleft lip and palate surgery: A comparison of the effects of different surgical approaches.
Cleft Palate J. 12: 444-451.

ORTIZ-MONASTERIO F., SERRANO A., BARRERA G., RODRIGUEZ-HOFFMAN H., and VINAGERAS E.A., (1966): Study of untreated adult cleft palate patients.
Plast Reconstr Surg. 38: 36-41.

PALMER C.R., HAMLEN M., ROSS R.B., and LINDSAY W.K., (1969): Cleft palate repair: comparison of the results of two surgical techniques. Canad J Surg. 12: 32-39.

PEAT J.H., (1980): Letter to Professor K.Godfrey.

PEAT J.H., (1982): Effects of presurgical oral orthopaedics on bilateral complete clefts of the lip and palate. Cleft Palate J. 19: 100-103.

PICKRELL K., QUINN G., and MASSENGILL R., (1968): Primary bone grafting of the maxilla in clefts of the lip and palate. Plast Reconstr Surg. 41: 438-443.

PICHLER H., (1926): Quoted by Millard D.R. Jr (1980). Op. Cit. pp. 250.

PONITZ P.V., and SPYROPOULOS M.N., (1979): The dental occlusion in treated and non treated cleft lip and palate. Eur J Orthod. 1: pp. 181-187.

POUPARD B., COORNEART H., DEBAERE P.A., and TREANTON A.M., (1983): Cleft lip and cleft palate: can the hard palate be left open? A study of sixty-two cases with a follow up of six years or more. Ann Chir Plast Esthet. 28: 325-336. - Abstract in Cleft Palate J (1985). 22: 67-68.

PRUZANSKY S., (1955): Factors determining arch form in clefts of the lip and palate. Am J Orthod. 41: 827-851.

PRUZANSKY S., (1964): Presurgical orthopaedics and bone grafting for infants with cleft lip and palate: A dissent. Cleft Palate J. 1: 164-187.

PRUZANSKY S., and ADUSS H., (1964): Arch form and the deciduous occlusion in complete unilateral clefts.
Cleft Palate J. 4: 411-418.

PRUZANSKY S., and ADUSS H., (1967): Prevalence of arch collapse and malocclusion in complete unilateral cleft lip and palate. Trans Europ Orthod Soc. 43: 365-382.

PRUZANSKY S., ADUSS H., BERKOWITZ S., FRIEDE H., and OHYAMA K., (1973): Monitoring growth of the infant with cleft lip and palate.
Trans Eur Orthod Soc. pp. 538-546.

PRYDSO U., HOLM P.C.A., DAHL E., and FOGH-ANDERSEN P., (1974): Bone formation in palatal clefts subsequent to palato-vomer plasty.
Scand J Plast Reconstr Surg. 8: 73-78.

RANDALL P., (1959): A triangular flap operation for the primary repair of unilateral clefts of the lip.
Plast Reconstr Surg. 23: 331.

RANDALL P., (1964): Cleft lip. In: Gibson T. (ed) (1964): Modern Trends in Plastic Surgery, Vol 1. London, Butterworths. pp 17-29.

RANDALL P., (1965): A lip adhesion operation in cleft lip surgery. Plast Reconstr Surg. 35: 371.

RANDALL P., WHITAKER L.A., and LA ROSSA D., (1974): The importance of muscle reconstruction in primary and secondary cleft lip repair.
Plast Reconstr Surg. 54: 316-323.

RANTA R., OIKARI T., and HAATAJA J., (1974): Prevalence of crossbite in deciduous and mixed dentition in Finnish children with operated cleft palate.
Proceedings of Finnish Dental Soc. 70: 20-24.

REHRMANN A., (1964): Bone grafting in cleft palate repair. In: Gibson T., (ed) (1964): Op. Cit. pp. 50.

REHRMANN A., KOBERG W.R., and KOCH H., (1970): Long term post operative results of primary and secondary bone grafting procedures in complete clefts of the lip and palate. Cleft Palate J. 7: 206.

REICHERT H., WIDMAIER W., KARL P., and GUBISCH W., (1984): Experiences and conclusions following primary osteoplasty. In: Hotz et al (ed) (1986).
Op. Cit. pp. 103-105.

RINTALA A., and RANTA R., (1984): Primary treatment of cleft lip and palate at the Finnish Red Cross Cleft Center from 1966 to 1980. In: Hotz et al (ed) (1986).
Op. Cit. pp. 140-143.

RITSILIA V., ALHOPURO S., GYLLING U., and RINTALA A., (1972): The use of free periosteum for bone formation in congenital clefts of the maxilla - A preliminary report. Scand J Plast Reconstr Surg. 6: 57.

ROBERTSON N.R.E., (1973): Deciduous occlusion in children with repaired complete clefts of the lip and palate. Br J Orthod. 1: 5-10.

ROBERTSON N.R.E., (1983): Facial form of patients with cleft lip and palate. The long term influence of presurgical oral orthopaedics. Br Dent J. 155: 59-61.

ROBERTSON N.R.E., (1984): Two stage palatal surgery - Effects of early versus delayed hard palate repair in an 11 year follow up. In: Hotz et al (ed) (1986). Op. Cit. pp 149.

ROBERTSON N.R.E., and JOLLEYS A., (1983): An 11 year follow up of the effects of early bone grafting in infants born with complete clefts of the lip and palate. Br J Plast Surg. 36: 438-443.

ROSENSTEIN S.W., (1969): A new concept in the early orthopaedic treatment of cleft lip and palate. Am J Orthod. 55: 765-775.

ROSENSTEIN S.W., (1984): Treatment of complete clefts of the primary and secondary palate at Children's Memorial Hospital, Chicago. In: Hotz et al (ed) (1986). Op. Cit. pp. 71-75.

ROSENSTEIN S.W., MONROE C.W., KERNAHAN D.A., JACOBSON B.N., GRIFFITH B.H., and BAUER B.S., (1982): The case for early bone grafting in cleft lip and cleft palate. Plast Reconstr Surg. 70: 297-307.

ROSS R.B., (1970): The clinical implications of facial growth in cleft lip and palate. Cleft Palate J. 7: 37-47.

ROSS R.B., (1984A): The Toronto Approach. In: Hotz et al (ed) (1986). Op. Cit. pp. 31.

ROSS R.B., (1984B): Variables affecting facial growth in cleft lip and palate - an international study. In: Hotz et al (ed) (1986). Op. Cit. pp. 238-246.

ROSS R.B., and JOHNSTON M.C., (1967): The effect of early orthodontic treatment on facial growth in cleft lip and palate. Cleft Palate J. 4: 157-164.

ROSS R.B., and JOHNSTON M.C., (1972): Cleft Lip and Palate, Baltimore, Williams and Wilkins Co. pp. 17-46, pp. 121-157, pp. 158-205, pp. 227-288.

SCHMID E., (1955): Die Annaherung der kieferstumpfz bei Lippen-Kiefer-Gaumen Spalten: ihre Schadlichen Folgen und Vermeidung. Fortschritte der Kiefer-und Gesichtschirurgie, 1: 37. In: Roberston N and Jolleys A (1983). Op. Cit. pp. 438.

SCHMID E.W., WIDMAIER W., REICHERT H., and STEIN K., (1974): The development of cleft upper jaw following primary osteoplasty and orthodontic treatment. J Maxillofac Surg. 2: 92-95.

SCHWECKENDIEK H., (1955): Zur Zweiphasigen Gaumenspaltoperation bei primarem Velumverschluss. Fortschritte der Kiefer und Gesichts-Chirurgie. 1: 73-76, G. Thieme, Stuttgart. Quoted In: Kehrer B., Slongo T., Graf B., Bettex M., (eds): Long Term Treatment in Cleft Lip and Palate with co-ordinated Team Approach, Huber, Bern, 1981, pp. 254-262.

SHAW W.C., (1979): Orthodontic treatment of malocclusion associated with repaired complete clefts of lip and palate. Br J Orthod. 6: 73-83.

SIEGEL M., (1983): Progress Report N.I.H. Grant No. DE01697, University of Pittsburgh - Quoted by McWilliams B.J., Morris H., Shelton R., (1984): Cleft Palate Speech. Philadelphia, Toronto, B.C. Decker Inc. pp. 57.

SILLMAN J.H., (1964): Dimensional changes of the dental arches - longitudinal study from birth to 25 years. Am J Orthod. 50: 824.

SKOOG T., (1967): The use of periosteum and surgical for bone formation in congenital clefts of the maxilla. Scand J Plast Reconstr Surg. 1: 113.

SKOOG T., (1969): Repair of unilateral cleft lip deformity - maxilla, nose and lip. Scand J Plast Reconstr Surg. Surg. 3: 109-133.

SLAUGHTER W.B., and PRUZANSKY S., (1954): The rationale for velar closure as a primary procedure in the repair of cleft palate defects. Plast Reconstr Surg. 13: 341-357.

SLAUGHTER W.B., and BRODIE A.G., (1949): Facial clefts and their management in view of recent research. Plast Reconstr Surg. 4: 311.

STARK R.B., (1954): The pathogenesis of harelip and cleft palate. Plast Reconstr Surg. 13: 20-39.

STARK R.B., (1958): The Development of the center of the face with particular reference to surgical correction of bilateral cleft lip. Plast Reconstr Surg. 21: 177-192.

STEFFENSEN W.H., (1953): Further experience with the rectangular flap operation for cleft lip repair. Plast Recontr Surg. 11: 49.

STELLMACH R.K., (1966): Modern procedure in Uni - and bilateral clefts of lip, alveolus and hard palate with respect to primar osteoplasty. In: Schuchardt K. (1966) (ed): Treatment of Patients with clefts of Lip, Alveolus and palate. From the 2nd Hamburg International Symposium Stuttgart, Thieme, pp. 48-53.

STOCKLI P.W., (1971): Application of a quantitative method for arch form evaluation in complete unilateral Cleft lip and palate Cleft Palate J.8: 322-334.

STRENSTROM S., and THILANDER B., (1974): Management of cleft palate cases using a modified Dunn procedure with skin graft to vomer flap.
Scand. J. Plast Recontr Surg. 8: 67-72.

STUFFINS G.M., (1979): Speech and mental attitudes in the older presurgical child. In: Kehrer B., Slongo T., Graf B., Bettex M., (eds.) (1981): Long Term Treatment in Cleft Lip and Palate with Co-ordinated Team Approach, Proceedings of 1st International Symposium, Bern, Switzerland, 1979, Huber, Bern, pp. 199-206.

SUBTELNY J.D., (1955): Width of the nasopharynx and related anatomic structures in normal and unoperated cleft palate children. Am. J. Orthod 41: 889-909.

TENNISON C.W., (1952): The repair of the unilateral cleft lip by the stencil method.
Plast Reconstr Surg. 9: 118-120.

THILANDER B., and STENSTROM S., (1967): Treatment of primary cleft lip and palate cases in the light of the results of an experimental animal study.
Eur. Orthod. Soc. Report. 43rd. pp. 349-364.

THOMPSON P.G., (1985): Personal communications.

TIDEMAN H., (1985): Lecture from an Australian and New Zealand Association of Oral and Maxillo-facial surgeon's Conference held in Sydney in July 1985.

TRIER W.C., and DREYER T.M., (1984): Primary Von Langenbeck palatoplasty with Levator reconstruction: Rationale and Technique. Cleft Palate J. 21: 255-262.

TURVEY T.A., VIG K., MORIARTY J., and HOKE J., (1984): Delayed bone-grafting in the cleft maxilla and palate: A retrospective multidisciplinary analysis.
Am. J. Orthod. 86: 244-256.

VAN LIMBORGH J., (1964): Some aspects of the development of the cleft-affected face. In: Hotz R., (ed) (1964): Early Treatment of Cleft Lip and Palate, Hans Huber Medical Publisher, Berne, pp. 25-29.

VARGERVIK K., (1981): Orthodontic management of unilateral cleft lip and palate.
Cleft Palate J. 18: 256-270.

VARGERVIK K., (1983): Growth characteristics of the premaxilla and orthodontic treatment principles in bilateral cleft lip and palate.
Cleft Palate J. 20: 289-302.

VEAU V., (1931): Division palatine. In Anatomie Chirurgie Phonetique, Paris, Masson. pp. 85 - quoted by Kaplan E.N., (1981), Op. Cit.

VEAU V., (1938) - "Bec-de-lievre, formes clinique Chirurgie" Masson, Paris - quoted by Delaire J. (1978B) - Op. Cit.

VIG K.W.L., MILLICOVSKY G., and JOHNSTON M.C., (1984): Craniofacial Development: The possible mechanisms for some malformations. - Br. J. Orthod. 11: 114-118.

VON LANGENBECK B.R.K., (1861): Quoted by Lindsay W.K., (1972) Op. Cit. pp. 147-152.

WADA T., and KREMENAK C., (1978): Effects of vomer surgery on midfacial growth in Beagles. J. Dent. Res. 57 (spec. Issue A): 94 (Abstract 78).

WADA T., MIZOKAWA N., MIYAZAKI T., and ERGEN G., (1984): Maxillary dental arch growth in different types of cleft. Cleft Palate J. 21: 180-192.

WALKER J.C., COLLITO M.B., MANCUSI-UNGARO A., and MEIJER R., (1966): Physiologic considerations in cleft lip closure: The C-W technique.
Plast Reconstr Surg. 37: 552-557.

WARDILL W.E.M., (1937): The technique of operation for cleft palate. Br. J. Surg. 25: 117-130.

WITZEL M.A., SALYER K.E., and ROSS R.B., (1984): Delayed hard palate closure: The Philosophy Revisited.
Cleft Palate J. 21: 263-269.

WOLFE S.A., and BERKOWITZ S., (1983): The use of cranial bone-grafts in the closure of alveolar and anterior palatal clefts.
Plast Reconstr Surg 72: 659-666.

Appendix 1

Crossbite scores of individual unilateral cases with triangular flaps placed in their anterior palate repairs.

		NON-CLEFT						CLEFT						TOTAL				
CASE	SIDE OF CLEFT	1/A	2/B	3/C	4/D	5/E	6	1/A	2/B	3/C	4/D	5/E	6	NON CLEFT	CLEFT	ANTERIOR	TOTAL	SEGMENT RELATIONSHIP
A.B.	left	0		0	0	0		0		-2	-1	0		0	-3	0	-3	Good alignment
N.B.	left	0		0	0	0		0		-3	-2	0		0	-5	0	-5	
M.C.	right	0		0	0	0		0		-3	-3	-2		0	-8	0	-8	
D.D.	left	0		-2	0	0		0		-3	-3	-2		-2	-8	0	-10	
S.F.	left	0		0	0	0		-2		-2	-1	0		0	-3	-2	-5	
K.M.	left	0		0	0	0		0		-2	-1	-1		0	-4	0	-4	Good alignment
M.M.	left	0		0	0	0		0		-2	-1	0		0	-3	0	-3	Good alignment
S.M.	left	-2		-1	0	0		-2		-3	-3	-2		-1	-8	-4	-13	
A.R.	right	0		0	0	0		0		-1	0	0		0	-1	0	-1	Good alignment
L.T.	right	0		0	0	0		0		-3	-1	-1		0	-5	0	-5	Abutting
B.T.	right	-1		-1	0	0		0		-3	-2	-2		-1	-7	-1	-9	
G.S.	left	-1		0	0	0		-1		-2	-1	0		0	-3	-2	-5	Good alignment
K.D.	left	-2		-1	0	0		-1		-3	-2	-1		-1	-6	-3	-10	
P.M.	left	0		0	0	0		0		-2	-1	0		0	-3	0	-3	Good alignment
A.T.	right	0		0	0	0		-1		-2	-1	0		0	-3	-1	-4	
S.L.	right	0		0	0	0		-1		-2	-2	0		0	-4	-1	-5	
S.B.	left	0		0	0	0	0	0		0	0	0	0	0	0	0	0	Good alignment
K.B.	left	0		0	0	0	0	0		-2	-2	-1	0	0	-5	0	-5	Good alignment
J.B.	left	-2		-2	0	0	0	-1		-3	-2	-1	0	-2	-6	-3	11	

inc. = incomplete. c. = complete.

Appendix 1 (cont'd)

CASE	SIDE OF CLEFT	NON-CLEFT 1/A	2/B	3/C	4/D	5/E	6	CLEFT 1/A	2/B	3/C	4/D	5/E	6	TOTAL NON CLEFT	CLEFT	ANTERIOR	TOTAL	SEGMENT RELATIONSHIP
T.C.	right	0		-1	-1	-1	-1	-1		-3	-3	-2	-1	-5	-9	-1	-15	
P.H.	left	0		0	0	0	0	-2		-3	-2	-2	-1	0	-8	-2	-10	
A.J.	left	0		0	0	-1	-1	0		-2	0	-1	0	-2	-3	0	-5	Good alignment
P.L.	left	-2		0	0	0	0	-2		-3	-2	-1	0	0	-6	-4	-10	
D.P.	right	0		-1	-1	-1	0	0		-2	-2	-1	0	-3	-5	0	-8	
N.P.	right	0		0	0	0	0	0		-2	-2	0	0	0	-4	0	-4	Good alignment
S.S.	left	0		0	0	0	0	0		-3	-3	-2	-2	0	-11	0	-11	
J.S.	right inc. left c.	-2		0	0	0	0	-1		-3	-2	-1	0	0	-6	-3	-9	
N.W.	right	0		0	0	0	0	0		-2	-1	0	0	0	-3	0	-3	Good alignment
E.W.	right	0		0	0	0	0	0		-2	-1	0	0	0	-3	0	-3	Good alignment
S.W.	left	-1		0	0	0	0	-1		-2	-1	0	0	0	-3	-2	-5	Good alignment
C.W.	right	-1		0	0	0	0	-1		-1	-1	0	0	0	-2	-2	-4	Good alignment
S.M.	right	-1		-2	-2	-1	-1	-1		-2	-1	0	0	-6	-3	-2	-11	
M.G.	right	0		-1	-1	0	0	-1		-2	-2	0	0	-2	-4	-1	-7	Good alignment
C.G.	right	-2		-1	0	0	0	-2		-3	-3	-2	0	-1	-8	-4	-13	
H.C.	left	0		0	-2	0	0	0		-1	0	0	0	-2	-1	0	-3	Good alignment
M.J.	left	0		0	0	0	0	0		-2	0	0	0	0	-2	0	-2	Good alignment
L.M.	right	0		0	0	0	0	-1		-3	-2	0	0	0	-5	-1	-6	
J.M.	left	-3		-3	-2	-1	0	-3		-2	-2	-2	-2	-6	-8	-6	-20	
S.W.	left	-3		0	0	-2	0	-3		-2	-2	-2	0	-2	-6	-6	-14	

inc. = incomplete. c = complete.

Appendix 2

Crossbite scores of individual unilateral cases with Standard palate repairs.

		NON-CLEFT						CLEFT						Sub-total				
CASE	SIDE OF CLEFT	1/A	2/B	3/C	4/D	5/E	6/	1/A	2/B	3/C	4/D	5/E	6/	NON CLEFT	CLEFT	ANTERIOR	TOTAL	SEGMENT RELATIONSHIPS
G.B.	left	0	0	0	0	UE	-1	-2	-1	0	UE	0	-3	-1	-4			
C.B.	left	0	0	-2	-2	UE	0	-2	-3	-2	UE	-4	-7	0	-11			
C.D. (J)	right	-1	0	0	0	UE	-2	-3	-3	-2	UE	0	-8	-3	-11			
G.E.	left	0	0	0	0	UE	-1	-3	-3	-2	UE	0	-8	-1	-9			
S.G.	left	-3	-1	-1	-1	UE	-3	-3	-3	-2	UE	-3	-8	-6	-17			
C.W.	left	0	0	0	0	UE	0	-2	-2	0	UE	0	-4	0	-4			
W.B.	left	-2	0	0	-1	-1	-2	-3	-2	-2	-2	-2	-9	-4	-15			
D.B.	left	-2	-1	-1	0	0	-2	-2	-1	0	0	-2	-3	-4	-9	Good alignment		
R.C.	left	0	0	0	0	0	0	0	-1	-1	-1	0	-3	0	-3	Good alignment		
J.C.	right	0	0	0	-2	0	0	-3	-2	-2	-1	-2	-8	0	-10			
J.D.	right	0	0	0	0	0	0	-1	-1	0	0	0	-2	0	-2			
D.D.	left	0	0	0	0	0	0	-1	0	0	0	0	-1	0	-1	Good alignment		
C.D.	left	-1	-1	-1	-1	0	-2	-3	-2	-1	0	-3	-6	-3	-12			
K.F.	left	-2	0	0	0	0	-2	-3	-3	-1	0	0	-7	-4	-11			
M.H.	left	0	0	0	0	0	0	-2	-2	-1	0	0	-5	0	-5			
M.H.*	left	0	-1	0	-1	0	0	-4	-3	-3	-2	-2	-12	0	-14			
L.I.	BCLP (left c)	-1	-2	-2	-2	-1	-1	-3	-3	-2	-2	-7	-10	-2	-19			
C.M.	left	-2	-2	-1	-1	0	-2	-3	-2	-1	0	-4	-6	-4	-14			
G.P.	left	0	0	0	-1	-1	0	-1	-1	-1	-1	-2	-4	0	-6			
J.P.	right	-2	-1	-1	0	0	-2	-3	-3	-2	-1	-2	-9	-4	-15			
K.P.	right	0	0	0	0	0	-1	-2	-2	0	0	0	-4	-1	-5	Good alignment		
V.P,	left	-1	0	0	0	0	-2	-2	-1	0	0	0	-3	-3	-6	Good alignment		
C.S.	left	-2	-3	-2	-2	-1	-3	-3	-3	-2	-1	-8	-9	-5	-22			
G.S.	left	0	0	0	0	0	-1	-3	-2	-2	0	0	-7	-1	-8			
P.W.	BCLP (left c)	-2	-2	-2	-2	-3	-2	-3	-3	-2	-1	-9	-9	-4	-22			
K.A.	right	-3	-2	-1	-1	0	-3	-3	-1	-3	0	-4	-7	-6	-17			
R.A.	left	0	0	0	0	0	0	-2	-2	0	0	0	-4	0	-4	Good alignment		
G.A.	right	0	-1	-1	-1	-1	-1	-1	-1	-1	-1	-4	-4	-1	-9			
N.D.	left	0	-1	-1	-1	-1	-1	-3	-3	-2	-1	-4	-9	-1	-14			
R.L.	left	-1	-1	-2	-2	-1	-2	-3	-3	-2	-1	-6	-9	-3	-18			
L.W.	left	-2	-2	-2	-1	0	-2	-3	-3	-3	-2	-5	-11	-4	-20			

* = different person. c = complete.

Appendix 3

Crossbite scores of individual bilateral cases with triangular flaps placed in their anterior palate repairs.

CASE	RIGHT SIDE 1/A	2/B	3/C	4/D	5/E	6	LEFT SIDE 1/A	2/B	3/C	4/D	5/E	6	TOTAL RIGHT	LEFT	ANTERIOR	TOTAL
J.C.	0		-2	-1	0	UE	0		-2	-1	0	UE	-3	-3	0	- 6
T.C.	0		-2	-1	0	UE	0		-2	-1	0	UE	-3	-3	0	- 6
D.F.	-1		-2	-1	0	UE	-1		-3	-2	-1	UE	-3	-5	-2	-10
L.K.	-2		-2	-2	-1	UE	-2		-2	-2	-1	UE	-5	-5	-4	-14
E.K.	-1		-2	-2	0	UE	-1		-2	-1	0	UE	-4	-3	-2	- 9
L.E.	-2		-2	-3	-2	-1	0		-2	-3	0	0	-8	-5	-2	-15
M.J.	-1		-2	-2	0	0	-2		-2	-2	0	0	-4	-4	-3	-11
M.R.	0		-2	-2	-2	-2	0		-1	0	0	0	-8	-1	0	- 9
N.S.	0		-1	-1	-1	0	0		-3	-3	-2	-2	-3	-10	0	-13
P.W.	0		0	0	0	0	0		-2	-2	-1	-1	0	-6	0	- 6
M.Z.	0		-1	0	0	0	-1		0	0	0	0	-1	0	-1	- 2

Appendix 4

Crossbite scores of individual bilateral cases with Standard palate repairs.

CASE	RIGHT SIDE 1/A	2/B	3/C	4/D	5/E	6	LEFT SIDE 1/A	2/B	3/C	4/D	5/E	6	TOTAL RIGHT	LEFT	ANTERIOR	TOTAL
D.A.	-1		-3	-2	-1	UE	-1		-3	-2	0	UE	-6	-5	-2	-13
L.B.	0		-2	-1	0	UE	0		-2	-2	-1	UE	-3	-5	0	- 8
M.E.	0		-3	-3	-2	UE	0		-4	-3	-2	UE	-8	-9	0	-17
C.F.	0		-3	-2	-1	UE	0		-2	-2	-2	UE	-6	-6	0	-12
S.G.	0		-3	-3	-2	UE	0		-2	-2	0	UE	-8	-4	0	-12
A.S.	0		-2	-2	-1	UE	0		-3	-3	-2	UE	-5	-8	0	-13
M.W.	0		-3	-2	-1	UE	0		-3	-2	-1	UE	-6	-6	0	-12
J.B.	-2		-2	-1	0	0	-2		-2	-1	0	0	-3	-3	-4	-10
J.K.	0		-2	-1	-1	0	0		-3	-1	-1	0	-4	-5	0	- 9
D.W.	-1		-3	-1	-2	-2	0		-3	-3	-3	-3	-8	-12	-1	-21

Appendix 5.

Comparison of Scoring of Models on two Separate Occasions

Case	1st Scoring	2nd Scoring	Difference
E.K.	- 9	- 5	-4
L.W.	-19	-18	-1
R.L.	-14	-16	2
A.L.	-10	- 8	-2
M.H.	-12	-12	0
V.P.	- 6	- 6	0
N.B.	- 9	- 8	-1
K.B.	- 5	- 6	1
C.C.	-14	-11	-3
T.C.	-12	-12	0
L.C.	- 5	- 7	2
R.C.	0	- 2	2
J.C.	-10	- 9	-1
R.C.	- 5	- 6	1
K.D.	-10	-10	0
L.E.	-14	-12	-2
M.G.	- 7	- 8	1
P.H.	- 9	-11	2
A.J.	- 4	- 4	0
P.L.	-10	-10	0
J.M.	-10	-10	0
B.M.	-10	- 9	-1
M.H.	- 5	- 5	0
C.B.	-11	- 9	-2
C.G.	-13	-13	0
K.M.	- 4	- 7	3
M.Z.	- 2	- 5	3
W.B.	-12	-13	1
M.W.	-12	-12	0
A.R.	- 1	- 2	1

Number of cases = 30
Mean Difference = 0.0667
Standard Deviation = ± 1.6595
(29 Degrees of freedom)

$$\text{Standard Error of mean} = \frac{1.6595}{\sqrt{30}} = 0.3030$$

$$t = \frac{0.0667-0}{0.3030} = 0.2201 \text{ (with 29 degrees of freedom)}$$

When $t = 0.2201$, $P > 0.05$,
i.e. the null hypothesis cannot be rejected, there are no significant differences between the 2 scorings.