

OCCLUSION:

As well as having marginal ridges and grooves which are positioned to prevent food impaction the occlusal surface of a restoration should ensure that lateral forces are not applied to the restored tooth. Cuspal inclinations should be in harmony with the other teeth, which in older patients will have been worn down, and a restoration with steeper inclines will suffer more lateral force than is desirable. The lowering of cuspal inclines reduces harmful lateral stresses. ⁴⁴ Even more force may result if the interference provided by the new restoration becomes a starting mechanism for bruxism. The steep inclines on the restored tooth may lock with the opposing cusps and may result in increased mobility of either the restored or the opposing teeth. This traumatic occlusion will in turn result in intermittent loose contacts and loss of bone unless rectified.

ADAPTATION AND POSITION OF MARGINS:

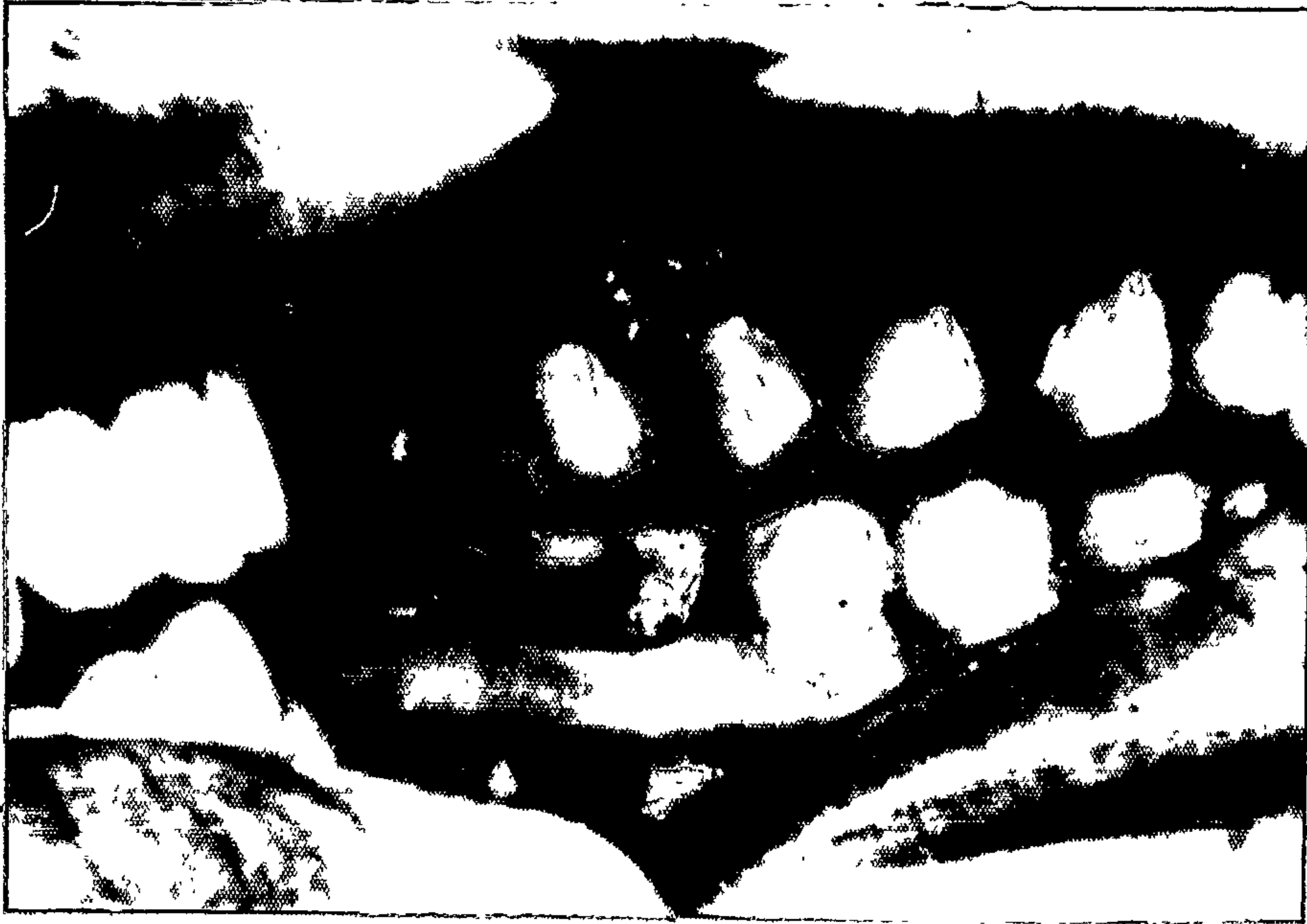
130

Waerhaug demonstrated that roughened tooth surfaces did not, in themselves, irritate gingival epithelial cells with which they were in contact, but rather that the epithelium adapted to them. The roughened surfaces did however facilitate plaque retention and so he concluded that unpolished, overhanging or deficient restorations will soon be covered with plaque and "the severe gingival inflammation so often seen adjacent to such restorations is due to the bacterial rather than the mechanical irritation". Therefore he recommended that restorations finished below the gingival margin should be well polished.

Although plaque may adhere to a well polished accessible surface it is easier to remove with good oral hygiene procedures than it is from an overhanging margin, a deficient margin or a rough surface. These areas are practically impossible for patients to clean adequately, particularly if they are subgingival, and have been shown to promote plaque accumulation and gingival inflammation. ^{2,51,60,76,100,126,130,131,141,152.}

28

As Christensen showed in 1966 the consistent evaluation of subgingival margins is very doubtful and rough surfaces, overhanging margins or spaces between restorations and cavity walls may be unsuspected. In the case of interproximal amalgam restorations, with subgingival margins, it has been shown by Trott and Sherkat (1964)



Gingivitis adjacent to Class V restorations.


that "under normal clinical conditions it is almost impossible to finish the margins flush with the tooth so as not to create a likely site for plaque formation and bacterial stagnation"¹²⁶. This may be an important factor in explaining the high incidence of plaque which Waerhaug (1975) found to occur on subgingival restora-¹³⁸tions.

37

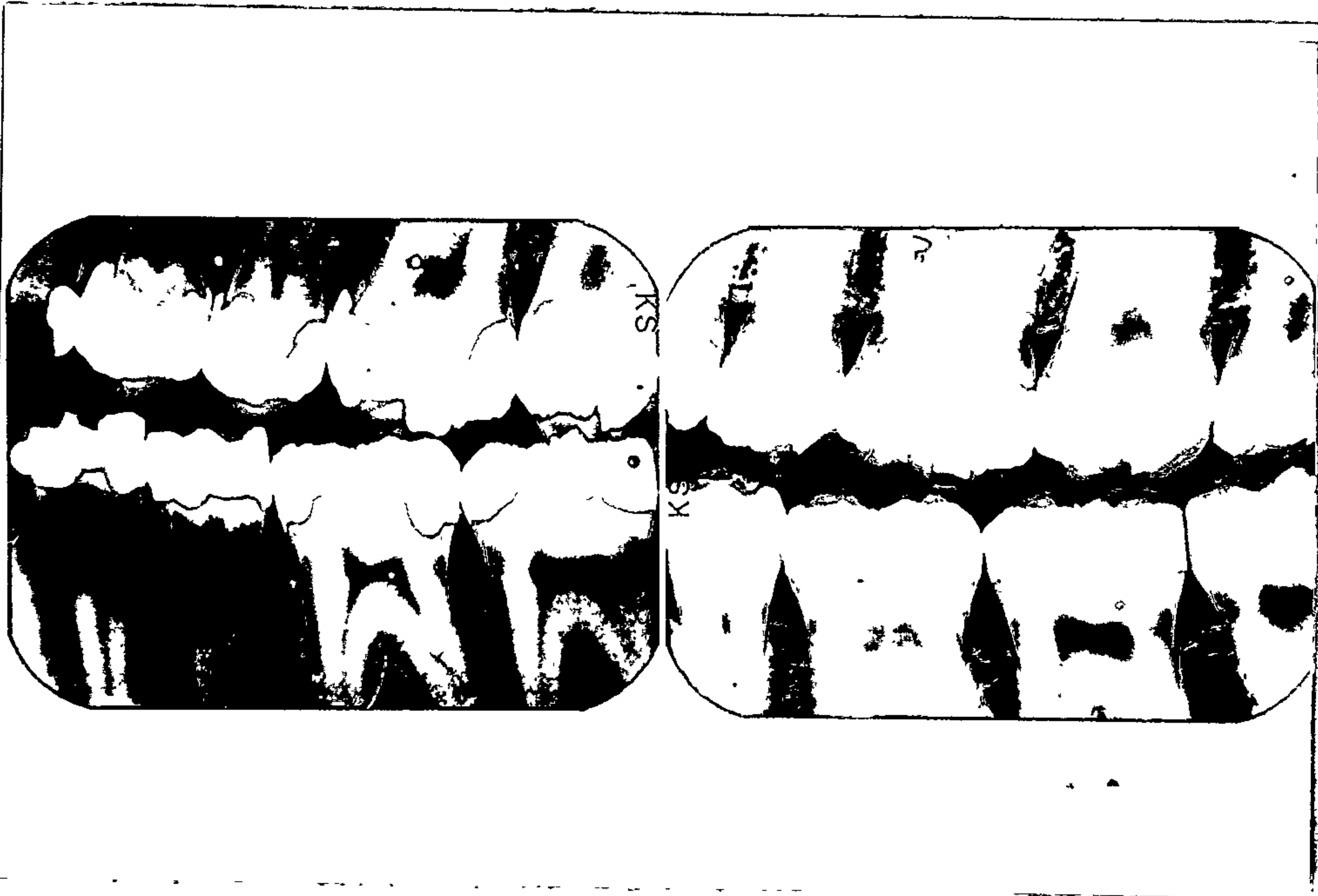
Gilmore & Sheiham (1971) in a survey of 1763 patients, with suitable radiographs, found that one quarter of all proximal restorations and one third of all posterior proximal restorations had overhanging margins and that there was significantly more severe periodontal destruction associated with the posterior restorations with overhangs than with homologous teeth without overhangs. It was concluded that posterior teeth with definite overhangs were positively related to the severity of periodontal disease in the subjects studied.

10

Bjorn, Bjorn & Grkovic examined 225 sets of 14-film intraoral radiographs and were surprised to find that three quarters of all measurable margins were defective in some way. Where there was excess filling material the reduction in bone height, compared to homologous teeth which were unrestored or had no obvious defect, was found to bear a clear relationship to the amount of excess filling material.



Interdental papillae associated with overhanging margins shown in radiograph below.



Note the improved interseptal bone after removal of the overhanging margins.

They found it striking in a subsequent survey of 387 crowns to find that the percentage of defects was even higher, 83% for gold crowns and 74% for porcelain. This was only assessing the proximal surfaces and perhaps a still higher incidence of defects could be expected if the lingual and facial aspects of the crown margins were examined. Approximately three quarters of the defects were larger than 0.2mm and were associated with periodontal bone loss, and they remarked that "One might think that an excess or deficiency of material amounting to 0.2mm still means a fairly good fit. However for plaque bacteria a 0.2mm shelf means quite a space for living".

Following his recent clinical study of the effects on the gingiva and alveolar bone, of removing overhanging amalgam margins, in which four groups:

- i) a control, with no treatment,
- ii) with overhangs removed and usual oral hygiene,
- iii) with professional plaque control and oral hygiene instructions,
- iv) with overhangs removed, professional plaque control and oral hygiene instruction,

45
were examined, Highfield (1976) noted the following points:

1. The removal of overhangs and good plaque control resulted in a significant decrease in inflammation.

2. Plaque control alone showed improvement in supragingival margin areas only. This was ascribed to the difficulty in removing plaque from subgingival overhangs.

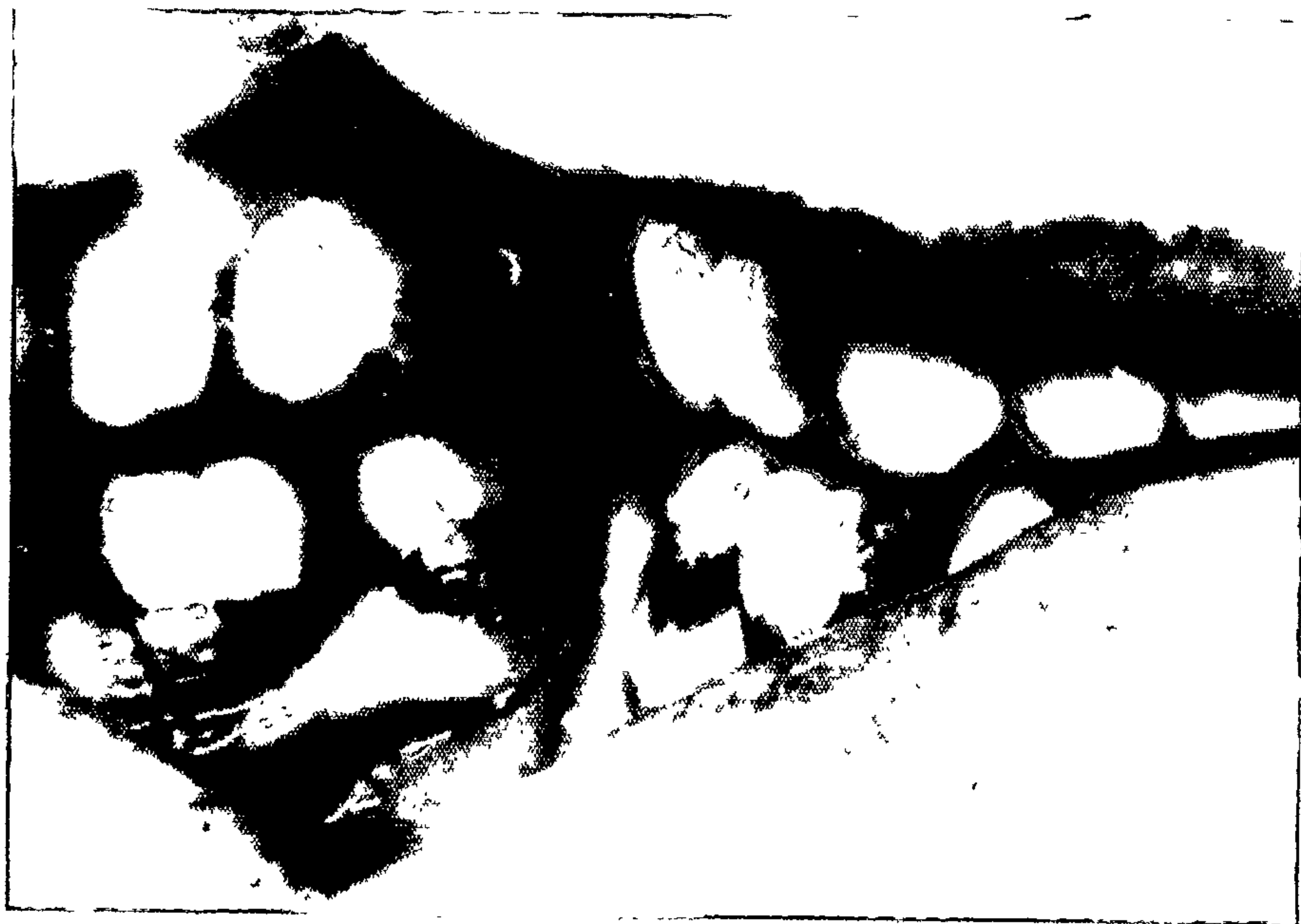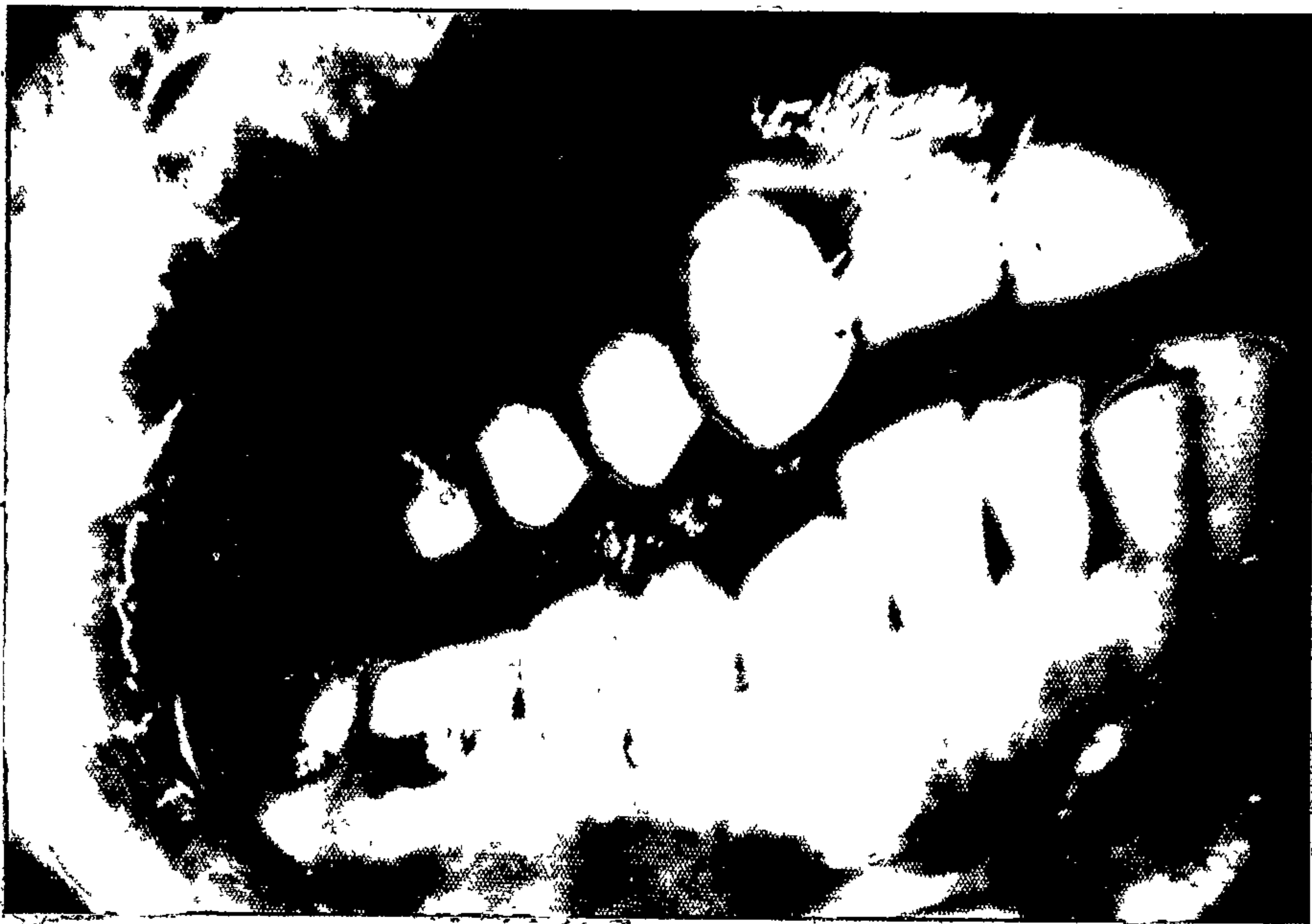3. Removal of overhangs without plaque control had a less significant improvement than groups iii and iv. This is said to indicate that plaque retention and not mechanical irritation is the cause of the damaging effect of overhangs. (Waerhaug & Zander ¹⁴² (1957) found plaque frequently on self-curing acrylic restorations and that overhanging margins, when present, did not demonstrably alter the tissue response. This also was taken to indicate that plaque formation and retention not mechanical irritation from an overhang was responsible for the gingival reaction.)

4. Even with good plaque control and overhang removal some gingival margins adjacent to subgingival restorations still remained inflamed. This would appear to reaffirm the undesirability of placing restoration margins subgingivally. Presumably plaque was still retained in surface defects or along the junction of the tooth and the restoration.

He states that "overhanging restorations are associated with a greater degree of gingival inflammation than other inter-proximal areas of the mouth. This effect is most apparent in a mouth with good oral hygiene because of the difficulties of adequately removing plaque from an overhanging restoration", and so inflammation of the related gingiva persists, whilst elsewhere in the mouth all is healthy.

These findings are in accord with Leon's ⁶⁰ (1976) clinical examination of 2888 Class II amalgam restorations in which no radiographs were taken and only gross defects were recorded and it was concluded that restorations with or without defects situated supra-gingivally were associated with little gingival disease but that irrespective of the quality of the restoration its presence at or below the gingival margin results in poorer gingival health.

Supragingival margins can be kept clean with good oral hygiene, but with defects and inefficient cleaning techniques plaque will accumulate and marginal gingivitis may occur. This will resolve if efficient plaque control is effected. ^{69,124,45} This is not necessarily so with subgingival margins and it is interesting that ¹³⁸ in Waehaug's investigations into the presence of plaque on subgingival restorations, all the restorations



Gingivitis adjacent to Class V restorations.

had marginal defects, few amalgams had been polished and nine out of ten were covered with plaque subgingivally.

In view of the difficulty involved in achieving marginal perfection subgingivally, the principle of "extension for prevention" below the gingival margin to prevent caries should be reappraised. Waerhaug (1969)¹³⁶ regards subgingival restorations as major aetiological factors in periodontal disease and describes the rule "extension for prevention of dental caries" as really meaning "extension for promotion of periodontal disease".

⁴⁷
Hoover & Lefkowitz (1965) found that teeth with amalgam or gold restorations in contact with the gingival sulcus had more gingivitis than unrestored areas.

¹⁰⁹
Silness (1970) found a relationship between the condition of the gingiva of bridge abutment teeth and the location of the retainer margin. Periodontal deterioration was most marked where the margins were subgingival, and less marked when they were level with the gingival crest. Supragingival margins did not seem to have changed the periodontal state which was the same as that adjacent to the control teeth.

¹¹²
In a later paper Silness & Ohm (1974) noted that the periodontium of patients who had received period-

ontal treatment and oral hygiene instruction and had no subgingival retainer margins in the embrasures was no better or worse on abutment teeth than on homologous control teeth. Those with subgingival margins and who had not been influenced to change their tooth cleaning habits showed considerable deterioration.

Having watched twelve specially designed crowns with sub and supragingival margins on the facial surfaces for three years, Richter and Ueno (1973) ⁹³ concluded that the fit and finish of full crowns may be more significant to gingival health than the location of the finishing line. The crowns, which were said to be "atypical in regard to excellence of margins and contours", showed no statistical difference in gingival health, sulcus depth, gingival contour or plaque accumulation in relation to the sub- and supragingival margins. However slight differences that were noted invariably favoured the supragingival margin.

⁷⁶
In contrast Mornann (1974) and his co-workers placed 16 perfectly adapted and well polished proximal inlays, which extended at least 1mm into the gingival sulcus, and provoked an inflammatory response. They ascribed the inflammation to "changes in papillary and sulcular topography, injuries to the junctional epithelium and loss of the gingival integrity".

These findings could also be used to support
Waerhaug's (1953)¹²⁹ view that the cavo-surface
margin is the "weak spot" in cemented restorations,
and Loe's (1968)⁶⁵ contention that "from a periodontal
point of view all margins of gold, porcelain and
acrylic crowns or inlays may be considered illfitting.
Due to the presence of luting material between the
preparation and the restoration, the cervical margin
of the latter and that of the preparation never
coincide."

Valderhaug & Birkeland (1976)¹²⁷ studied a group of
114 patients who had received 32 single crowns and
357 bridge retainers. Prior to receiving their
prostheses 96 patients had had periodontal treatment
and all patients had received oral hygiene instruction.
The gingival margins of the crowns were placed supra-
gingivally in all cases where it was possible having
regard to retention, aesthetics and earlier restorations.
After five years 98 (86%) of the patients were examined
and their periodontal condition assessed. They had
during the five years received six-monthly cleaning
by an hygienist and been subject to a regular oral
hygiene instruction programme.

Most Gingival Index Scores and sulcus depths were

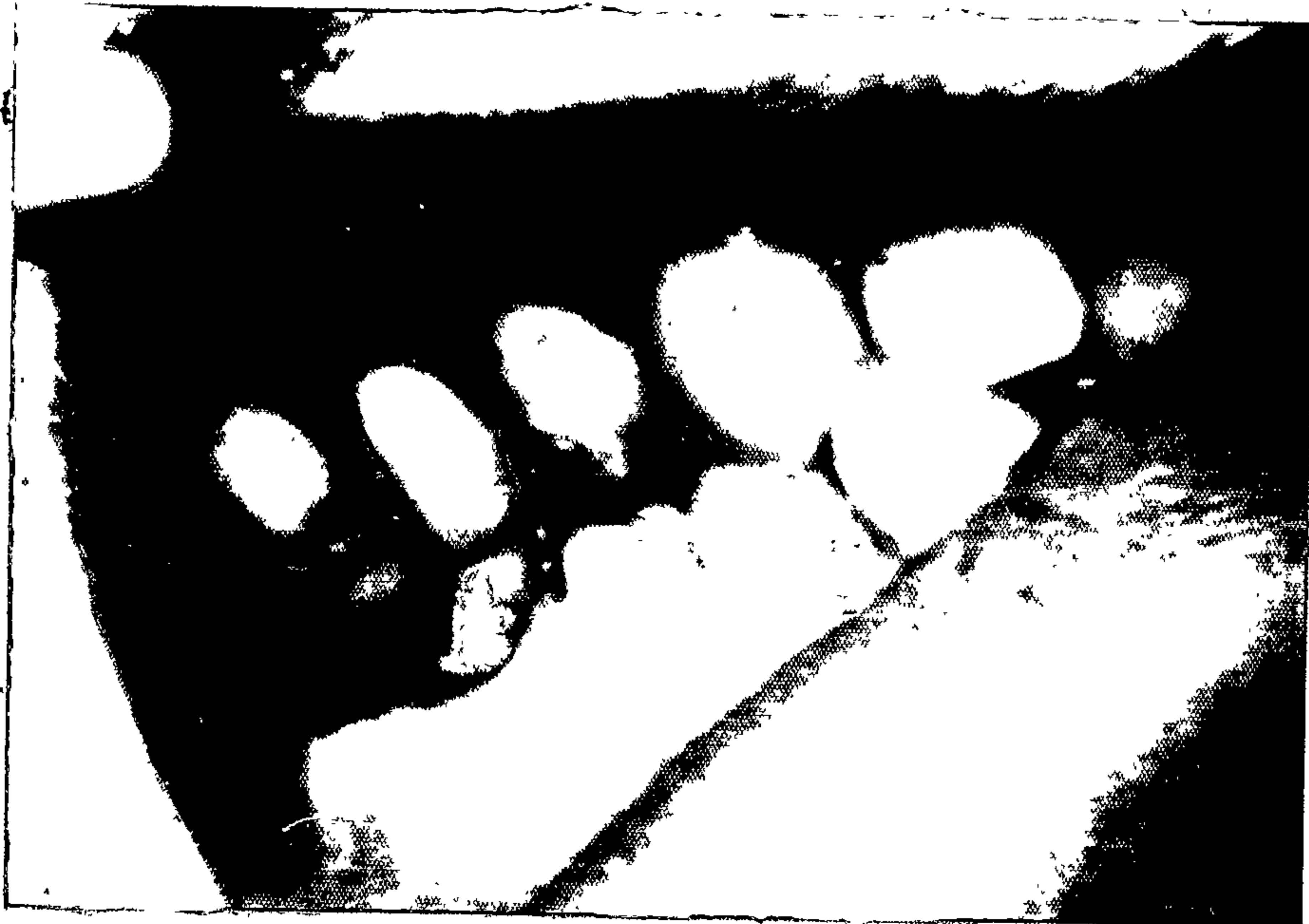
unchanged after five years where supragingival margins had been placed. Where margins were in the gingival crevice however, there was an increase in inflammation and sulcus depth, and it is interesting to note that whereas initially 65% of the crown margins had been placed subgingivally, after five years only 41% were still subgingival. It was concluded that with well made fixed prostheses and satisfactory oral hygiene, there is little likelihood of periodontal damage if crown margins are located supragingivally. Subgingival margins resulted in loss of attachment, giving either increased pocket depth or gingival recession.

75

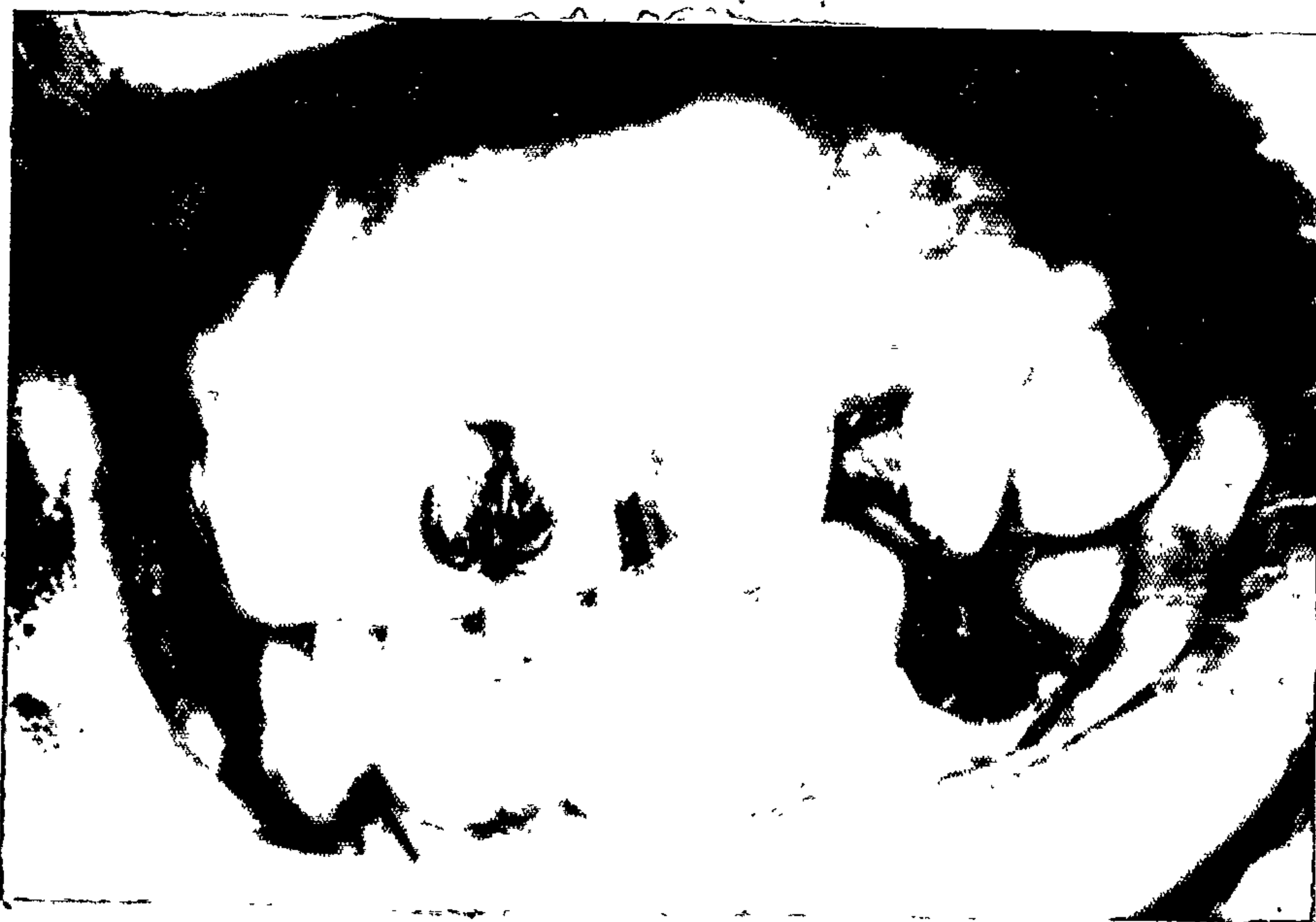In 1967 Marcum, having placed 66 gold crowns with margins below, at, and above the gingival crest, in the mouths of six dogs, reported that the crowns finished at the gingival crest caused the least inflammatory response. The response to subgingival margins was described as varying from slight to severe, but the same finding was reported for supragingival margins as well. In fact it was found that the margins above the gingiva caused slightly more inflammation than those below. The inflammation adjacent to the subgingival crowns was ascribed to inadequately finished margins and the crevice between the tooth and the restoration. Marcum thought that the response to the supragingival margins was due to plaque formation

and the adherence of food debris. As he expresses concern for "a better crown contour that deflects food away from the gingival crevice" it is conceivable that this finding, which is not in accord with most other investigations, is the result of overcontouring of the supragingival crowns. But whatever the reason for this unusual result the subgingival margins were still found to be injurious to gingival health, and they were not advocated as a standard procedure.

Sanchez-Sotres and others (19¹⁰⁰69) placed buccal amalgam, silicate and resin restorations in dogs and although there were inflammatory responses, concluded that there is no contraindication to placing restorations with smooth surfaces in the gingival sulcus. The response was greater with unpolished restorations, was related to the amount of debris accumulated and was considered to be the result of bacterial irritation with defects and the texture of the restorations playing a secondary role. Particular stress was placed by the writers on teaching patients to brush correctly in areas where subgingival restorations are placed and on the necessity for the dentist to watch these areas for the development of pathology.



Gingival recession adjacent to Class V amalgam.



Three reactions to subgingival margins.

125

Trivedi & Talim (1973) placed 54 Class V fillings of amalgam, silicate, acrylic and cast gold on the facial of premolars and 0.4mm into the gingival sulcus. Although after 60 days there were no clinical changes, 67% showed histological changes in the adjacent gingiva. Tissue in contact with silicate cement and acrylic resin had the highest percentage of inflammation, 81%. Some restorations were polished, some had overhanging margins, some patients were instructed to brush the area, others not to. The data compiled, indicated that "plaque and debris which accumulated on the unbrushed and unpolished surfaces were aetiologic factors in the gingivitis". Teeth with polished restorations, no overhanging margin and which were brushed showed the least inflammatory response.

The few surveys mentioned that have not criticised the subgingival placing of restoration margins, have each taken place in relationship to the facial surface of teeth, which is more accessible for cleaning. They have also emphasised the necessity for care in the preparation of the cavity and insertion of the filling material, the need to polish the restoration and the instruction of the patient in correct oral hygiene procedures. Although clinical signs of gingivitis may not have been seen, histological evidence was present in all studies.

Margins should be accessible for finishing and cleansable.

The subgingival placing of restoration margins should not be regarded as the normal practice, should be avoided if possible and when done should be regarded as a necessary compromise.

RESTORATIVE MATERIALS AND SURFACE FINISH:

Many restorative materials commonly used are believed to be inert and cast gold, gold foil, porcelain and heat cured acrylic have been shown to be well tolerated by the tissues. Polymerised self-curing acrylic is also well tolerated but chronic gingival inflammatory reactions have been shown to acrylic restorations which have polymerised in cavity preparations.

Zander in 1957, stated that self-curing acrylic, silicate, and amalgam all produced chronic inflammation and that the reaction to silicate and amalgam was similar to the reaction seen to calculus. App (1961) in an experiment on dogs found cast gold restorations to be well tolerated, but also described a tissue response to silicate and amalgam similar to that described by Zander. The inflammatory effect from calculus has been shown to be the result of plaque retention on the surface of the calculus not mechanical irritation from its roughness.

Self-curing resins probably are irritating during polymerisation, but once polymerised should no longer be a source of irritation. Similarly silicate cement may irritate during setting, but it is very difficult to assess the subsequent effect of its chemical instability. Waerhaug and Zander ¹⁴² (1957) observed that crevices ¹⁵⁴ existed between resin restorations and the tooth. Zander also said in 1957 that "a common finding was a crevice at the margin between the silicate cement and the wall of the cavity." Having examined cavities filled with silicate or composite resin, Brannstrom & Nyborg ²⁰ (1971) found it "evident that large amounts of bacteria can occur under unlined cavities filled with materials that contract during hardening, to leave a space between the filling and the cavity wall," and that it was "of interest to note that the uniform bacterial layer at the bottom of the cavity was largely as wide as the space for this type of fillings"(sic).

These spaces between restoration and tooth are areas for plaque retention and if situated beneath the gingiva cannot be cleaned. The gingival inflammation observed is more likely to be the result of bacterial plaque than irritation from the filling material. In view of these inherent marginal defects it is unwise to extend silicate or resin restorations beneath the gingival margin.

40

Similarly although in vitro studies have shown injury to gingival fibroblasts and HeLa cells, presumed to be caused by ions produced during amalgam corrosion, the frequent lack of reaction to pieces of amalgam accidentally introduced into the tissues¹⁰⁶, indicates that gingival inflammation, adjacent to amalgam restorations, may not be the result of an inherent chemical irritation from the material but may come from some other cause.

Rather than chemically or mechanically irritating features, the retention of bacterial plaque by restorations is a more likely source of gingival inflammation. In addition to the normal setting contraction the polishing of silicate restorations may result in small marginal fractures.⁵⁰

The gradual erosion of the restoration may give rough margins which retain plaque, or loss of contact which encourages food impaction and subsequent damage to the papilla.⁵⁶

Composite resins, as well as contracting, have been shown to accumulate plaque more quickly than enamel⁵⁸ and other restorative materials^{144,114} and cannot be satisfactorily polished,^{38, 43} although Heath & Wilson⁴³ (1976) state that "a good surface can be restored to composites by the use of an effective glazing agent".

Small defects which are the result of porosity and resemble pits and small lumps are difficult to avoid in acrylic resin. Wictorin (1972)¹⁴⁷ considers that with tooth brushing these microdefects may become scratch marks which make the removal of plaque and debris difficult. Ramfjord (1974)⁸⁹ says that the absorption of bacterial toxins by acrylic also may make it irritating if in contact with the gingiva.

It has been recommended by Larato (1971,1972)^{56,58} that the outline form for silicate and resin restorations should be limited to the extent of the carious lesion and that "only materials that 1) are insoluble in the mouth fluids, 2) have good dimensional stability and marginal seal and 3) retain a surface smoothness after polishing, should be used in cavities that extend to or below the gingival crest".

Although Skjorland (1973)¹¹⁴ found, in vitro, that plaque formation on silicate cement appeared initially to be inhibited, Larato (1971)⁵⁶ noted that of 184 silicate restorations stained for plaque 153 (83%) gave positive results. Proximal restoration defects were the result of poor anatomy or contact and class V faults were in marginal finish or seal. Plaque retention was particularly noticeable adjacent to or beneath the free gingiva, and was affected by the degree of erosion of the material.

131
Waerhaug (1957) considered that zinc oxyphosphate cement was well tolerated by the epithelium under favourable conditions and was less irritating than self-cured acrylic. The cement surface he regarded as a weak spot in restorations because a microscopic seal was difficult to obtain and refuge was provided for bacteria and plaque formation facilitated.

The mechanical and biological limitations of restorative materials should be understood and careful thought given to their use in suitable locations. Damage done by the materials themselves is not significant but intrinsic defects such as contraction on setting, tendency to retain plaque as with composite resin, disintegration in oral fluids and inability to take and keep a polish, are significant in attempting to avoid gingival inflammation with possibly more extensive consequences.

CHAPTER 7.

With the advent of the air turbine, the improvements of porcelain, the capability of fusing porcelain to metal and the availability of easily manipulated and accurate impression materials, the full coverage restoration has become far more commonly used than it used to be. Where once a gold inlay may have been used to restore an anterior tooth, now a porcelain fused to gold full veneer crown is often the chosen restoration. Where intra-coronal retainers or partial veneer crowns may have been used for bridge abutments now advantage is taken of the increased retention and better aesthetics of full coverage gold, or porcelain fused to gold, crowns.

By its very nature a full coverage crown presents a greater periodontal hazard than any other restoration. Its contour, occlusion and proximal relationship have to be re-created after the preparation is complete and its cavo-surface margin is the circumference of the tooth. Its success or failure periodontally depends to a large extent on the following features:

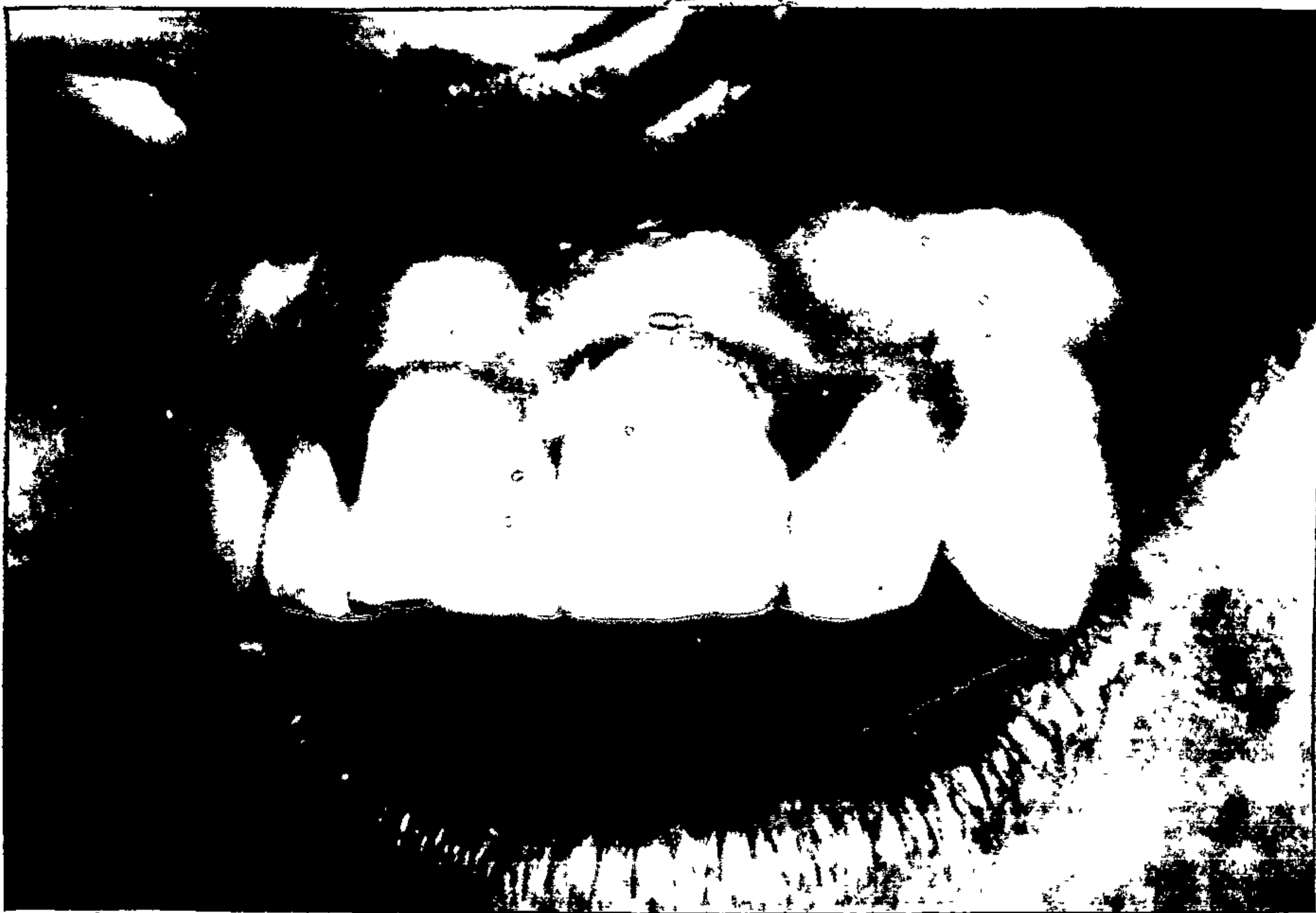- i) contour,
- ii) relationship of margin to gingiva,
- iii) accuracy of marginal adaptation.

CONTOUR:

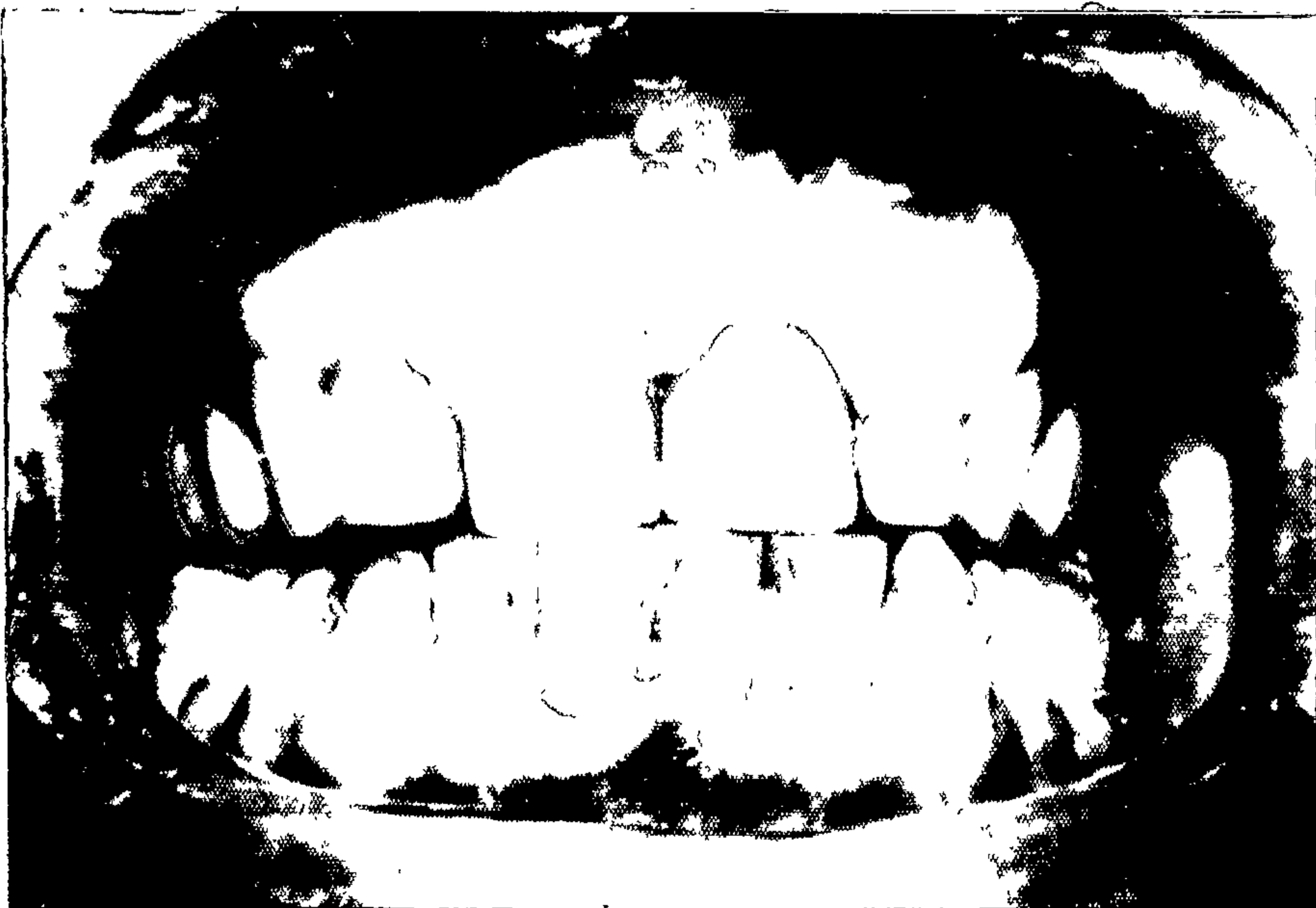
The importance of a restoration's contour has been discussed and the attainment of a satisfactory shape in a full coverage restoration requires careful consideration and attention by a dentist. Many appear not to take into account the bulk of material that is required to ensure strength, accurate fit and correct tooth shading in a full crown particularly when porcelain fused to metal is to be used. Teeth are frequently underprepared and in attempting to gain sufficient strength or an acceptable shade, technicians have no alternative but to overcontour the restoration.

It is aesthetically desirable that restored teeth approximate as closely as possible the shape of natural teeth and from a periodontal point of view that they should not enhance the retention of plaque on the interproximal, lingual and facial cervical surfaces by having excessive supragingival bulges.

In a survey of fifty full crown restorations compared with their unrestored homologous counterparts, Parkinson (1976)⁸² found that generally there was an increase in facio-lingual size at the height of contour.



Acrylic crown UL1 overcontoured at disto-facial line angle.



Porcelain crown UL1 overcontoured at mesio-facial line angle.

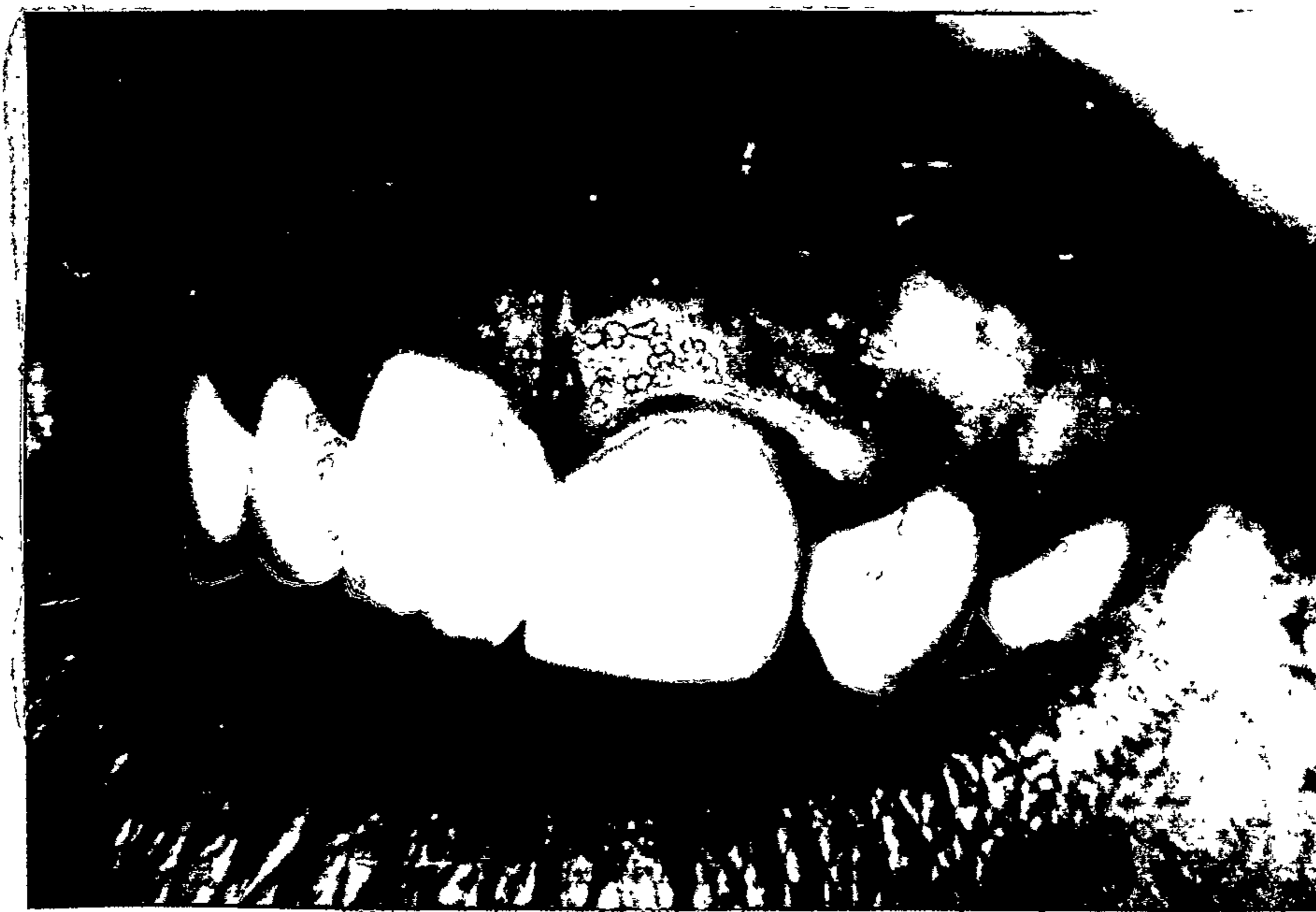Eighty percent of cast metal crowns had a greater facio-lingual dimension than their unrestored contralateral equivalents and all porcelain fused to metal crowns were from 0.2 to 1.6mm thicker. Another fifty crowns were measured in a technician's laboratory and a similar finding was made. A statistically significant increase in plaque retention on the restored teeth compared with their controls was also noted. This supports Yuodelis Weaver & Sapkos (1973)¹⁵³ in their contention that over-contoured restorations increase plaque retention.

⁸⁹
Ramfjord (1974) refers to "double contoured" crowns where a technician "makes an anatomically correct crown superimposed on a preparation which ended short of the cementum enamel junction, and the result is an anatomically abnormal relationship between the crown and the gingiva enhancing plaque retention". Carefully trimmed models and observation of the homologous tooth if present should reduce the incidence of such errors.

In the writer's experience the most common fault resulting in overcontouring is the under preparation of teeth at the facial proximal line angles. Frequently insufficient tooth structure is removed to allow for the restorative material which is to replace it and the resulting increased bulk of the restoration encroaches on the interdental papilla. This invasion of the



Overcontoured restorations which fill the embrasures and have excessive supragingival bulges. The gingiva is fibrotic and inflamed.



Porcelain crown UL1, lacks distal contact and is overcontoured - split papilla.

embrasure can be so marked that it is no longer possible for the embrasure to be cleaned. It is important that correct oral hygiene procedures are still practicable when restorations have been completed.

RELATIONSHIP OF CROWN MARGINS TO GINGIVA:

Traditionally these restorations were always carried below the gingival crest to avoid the recurrence of dental caries, to increase retention and to provide a more aesthetically pleasing restoration. In the light of our present knowledge of the accumulation of plaque at cavosurface angles which are not perfectly finished, the uncertainty of ensuring perfection in subgingival margins and the difficulty in controlling plaque in subgingival imperfections, the routine practice of extending the margins of restorations below the gingival crest is difficult to justify.

Where teeth have been restored previously, or there is extensive caries, the need to finish the preparation on sound tooth structure may require entering the gingival sulcus. Short clinical crowns may require extension for retention, but in some cases this may be avoided by the use of pins. Probably the most common reason for subgingival extension is aesthetic; particularly in the restoration of upper anterior teeth. Patients submitting to expensive and extensive crown and bridgework

generally have a high expectation of the appearance of the finished product. But, if in restoring a broken down unsightly tooth to proper form and function, a gingival problem were created or further periodontal disease were initiated, it would be poor therapy.

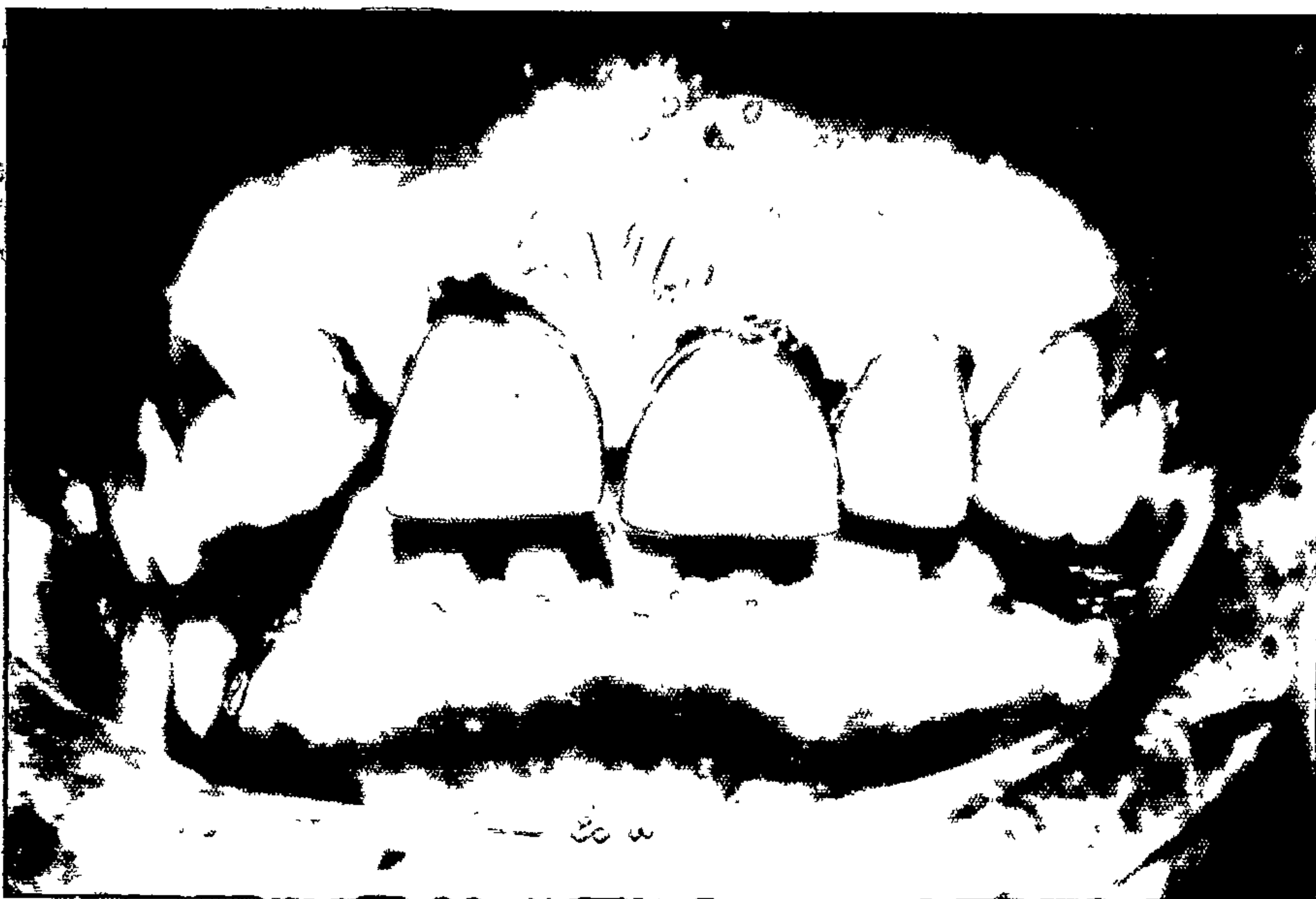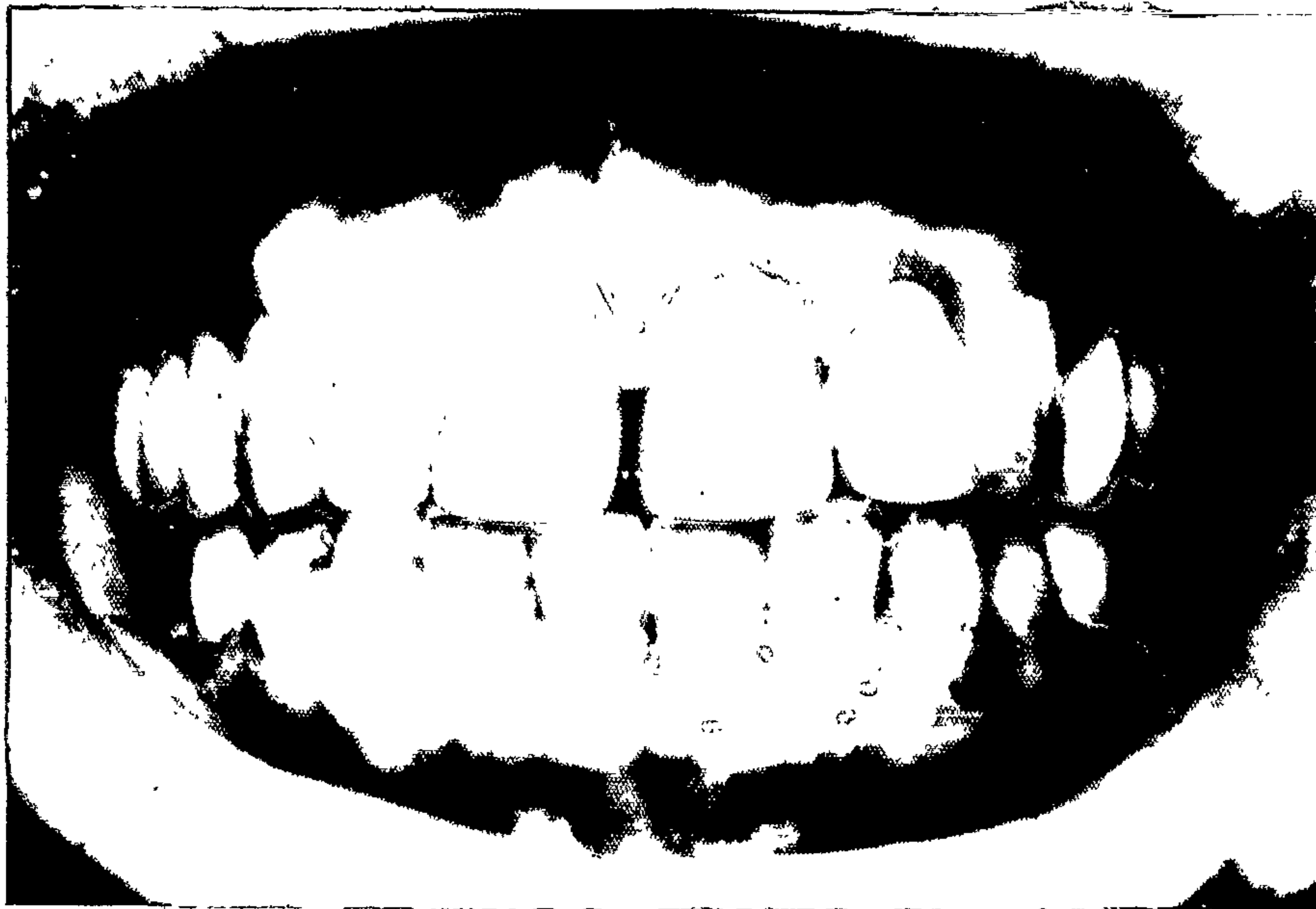
It may be desirable for a patient with a high lip line that the gingival margin of a crown be concealed but the need is not so pressing for a patient who does not show the gingival third of his teeth. Where possible, entry into the sulcus should be avoided, and when it cannot be avoided it should be done with caution.

Newcomb (1974)⁷⁸ having discarded nine crowns with defective labial margins or overcontoured labial surfaces from a group of 75 anterior full veneer crowns, assessed gingival inflammation at the mid-point of their labial aspect. He found that teeth with subgingival margins showed significantly more gingival inflammation and sulcus depth than their uncrowned control teeth. The closer the margin of the crown was placed to the bottom of the sulcus the greater was the inflammation and the least inflammation was shown when the crown margin was at the gingival crest or just into the sulcus.

Placing the gingival margin of full coverage crowns at or just below the gingival crest generally will ensure that the axial walls of the preparation are long enough to provide retention and cause a minimal amount of damage to the supporting tissues during preparation and after insertion of the crown.

The previously discussed hazards of the subgingival extension of restorations are even more marked for full coverage crowns because the gingival margin is so much longer, and includes both the mesial and distal embrasures. The finishing line on the proximal surfaces should follow the contour of the interdental papilla and not slice through in a straight line from the facial to the lingual. An incorrect proximal finishing line will cut gingival fibres, damaging the attachment, in an area which is already susceptible to plaque accumulation and disease.

Larato (1975)⁵⁹ found deeper gingival sulci adjacent to teeth with crowns that had subgingival margins than adjacent to unrestored teeth and considered that pathologic pocket depth is more commonly related to such teeth than to unrestored teeth. Silness (1970)¹⁰⁹ in his comprehensive study of periodontal conditions in patients with fixed bridges found the most harmful effects on the periodontium seemed to be



Gingivitis and full coverage crowns.

produced on those teeth with subgingival crown margins. Mannerberg (1971)⁷⁴ in a survey of his own patients decided that "despite an apparently clinically acceptable result it appears that the porcelain crown whose cervical border is placed down to 'half the depth of the gingival pocket' implies a risk for permanent inflammatory irritation of the gingiva".

Bergman, Hugoson, & Olsson (1971)⁸ noted that one year after cementation the Gingival Index of teeth restored with crowns which had subgingival margins was higher than for those with supragingival finishing lines and although after two years the differences were not considered significant, they stated that they considered that "the risk of clinically demonstrable gingival injury is greater when the crown margins are placed subgingivally".

Valderhaug & Birkeland's (1976)¹²⁷ five year survey of patients with crowns and bridges showed that only those patients with subgingival crown margins had increased sulcus depth. They also had greater loss of attachment than the patients with gingival and supragingival margins and had higher Gingival Index scores. One third of the margins placed beneath the gingiva were no longer subgingival after five years.

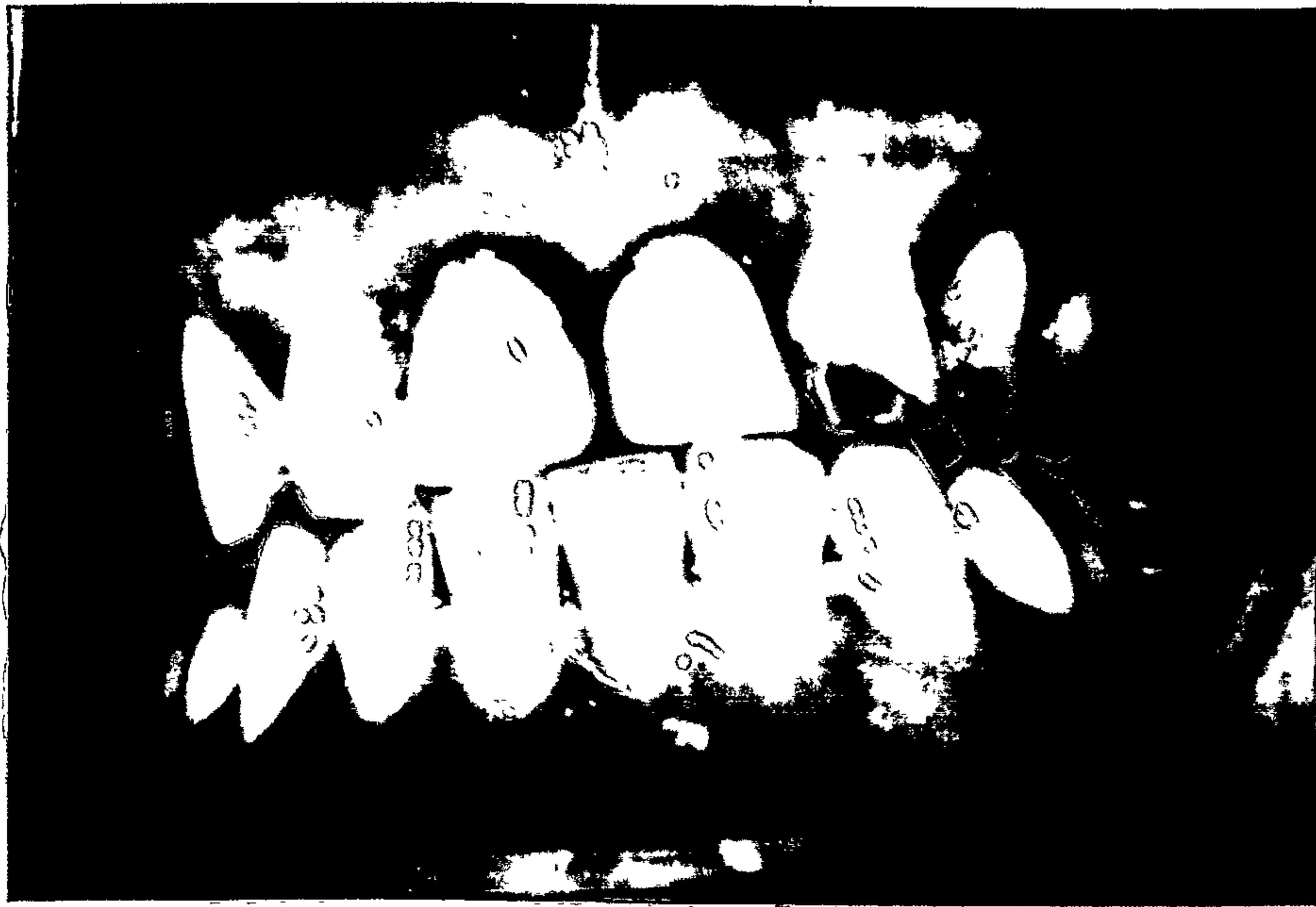This seems to indicate increased sulcus depth or gingival recession as consequences of placing crown margins subgingivally.

Gingival recession is often associated with subgingival crown margins and its possible relationship to subgingival tooth preparations in teeth with bony dehiscences has been mentioned earlier.

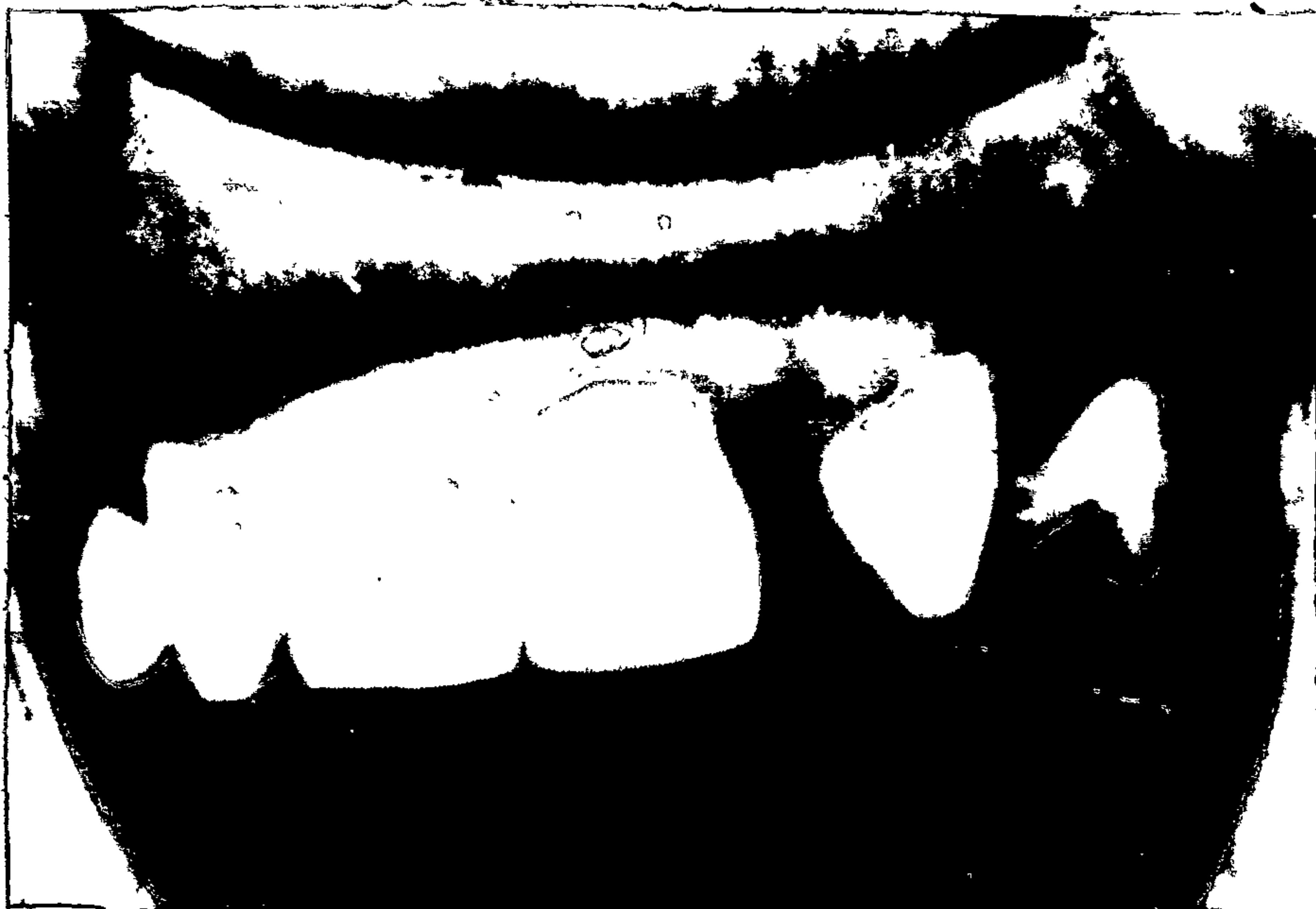MARGINAL ADAPTATION:

⁶⁵
 Loe (1968) regarded the margins of all crowns and inlays as illfitting from a periodontal viewpoint, due to the unavoidable presence of cement. Waerhaug ¹²⁹ (1953) saw the junction of a restoration and tooth as "the weak point" which provided refuge for bacteria and encouraged the retention of plaque. The less accurate the fit of a restoration the greater the amount of exposed cement and consequently the likelihood of plaque accumulating on its rough surface. A good marginal fit is essential to maintain healthy gingiva around a crowned tooth.

Cervical margins which are located subgingivally with exposed cement cannot be adequately cleaned and plaque may cover the cement not long after the insertion of the restoration. ¹³⁴ It is reasonable to assume that the greater the exposure of cement, the more plaque will



Acrylic crowns UR1, UL1 with deficient labial margins.

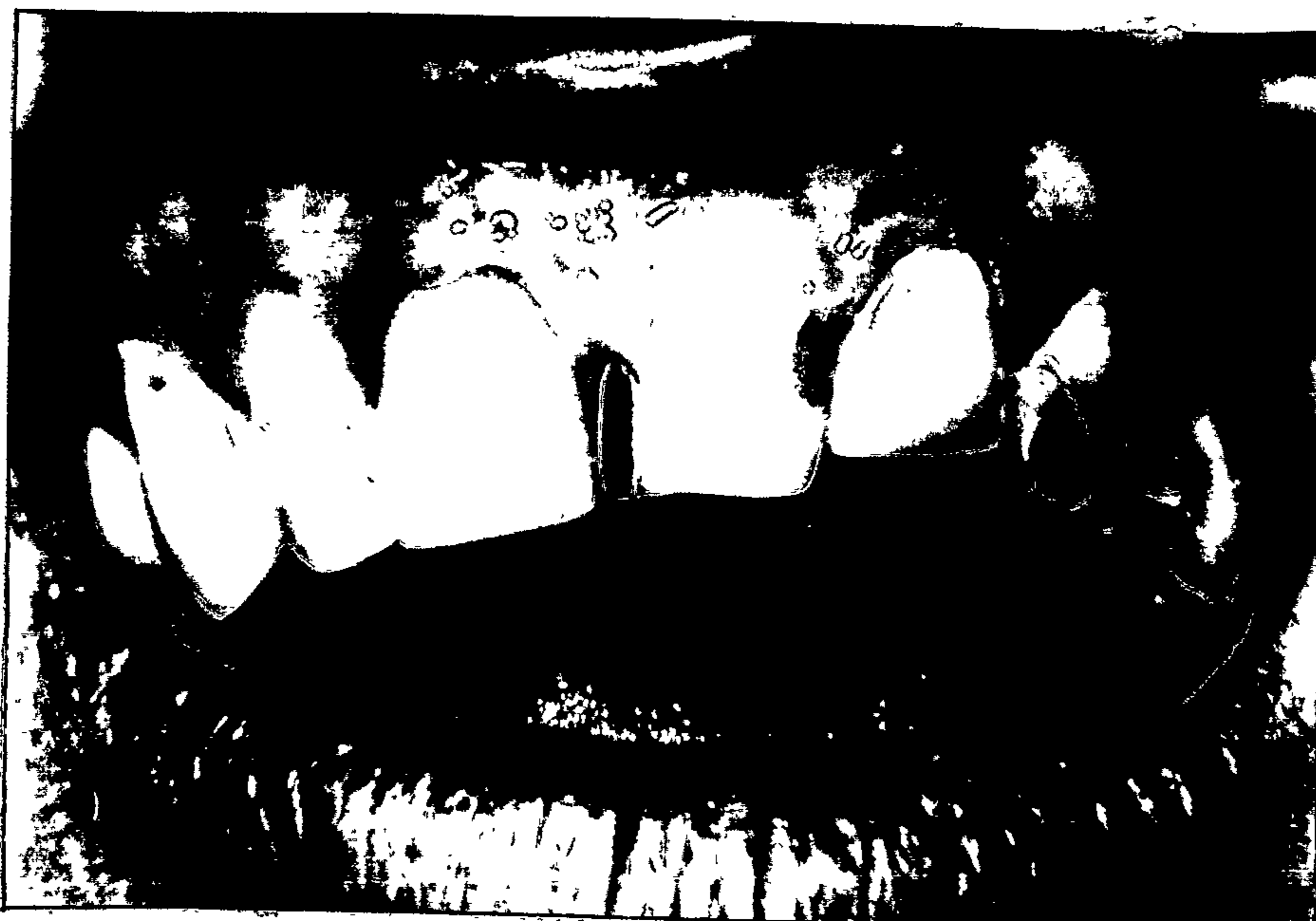

Porcelain crown, UL1, with labial overhanging margin.

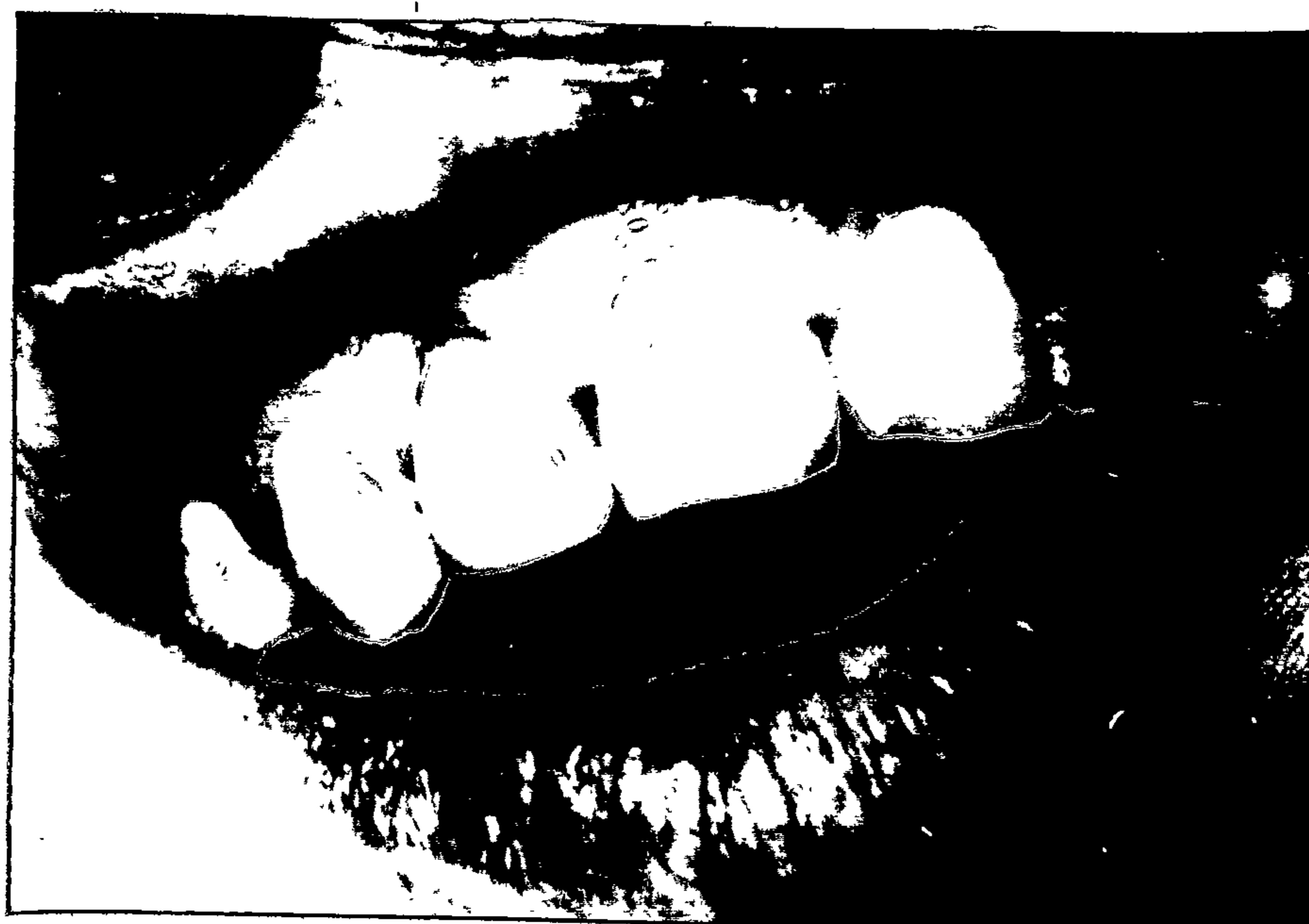¹¹¹
be present, and therefore it is desirable that as little cement as possible should be exposed. Also, even if as ¹³¹ Waerhaug (1956) states, the chemical irritation caused by the cement itself is minor, it is not desirable that more irritation than necessary be caused by extensive exposure of cement margins.

¹¹
Bjorn, Bjorn and Grkovic's (1970) assessment of proximal defects in 83% of 275 gold crowns and 74% of 98 porcelain crowns examined gave a striking indication of the incidence of marginal shortcomings in full coverage restorations and prompted them to suggest that an attempt be made to analyse the factors behind the lack of exactness in marginal adaptation that they found. The periodontal hazard that these marginal defects constitute is indicated by the bone loss which was associated with substantial defects (i.e. in excess of 0.2mm) in this survey.

It is of passing interest to note that in a study of crowns placed on anterior teeth by students at the Adelaide Dental School, ⁴⁸ Janenko (1976) found more overhanging margins associated with porcelain crowns than with porcelain fused to gold crowns but larger marginal gaps were more frequently related to the latter.



Acrylic crowns UR1 and UL2. UR1 has overhanging margin and 4mm pocket on labial.



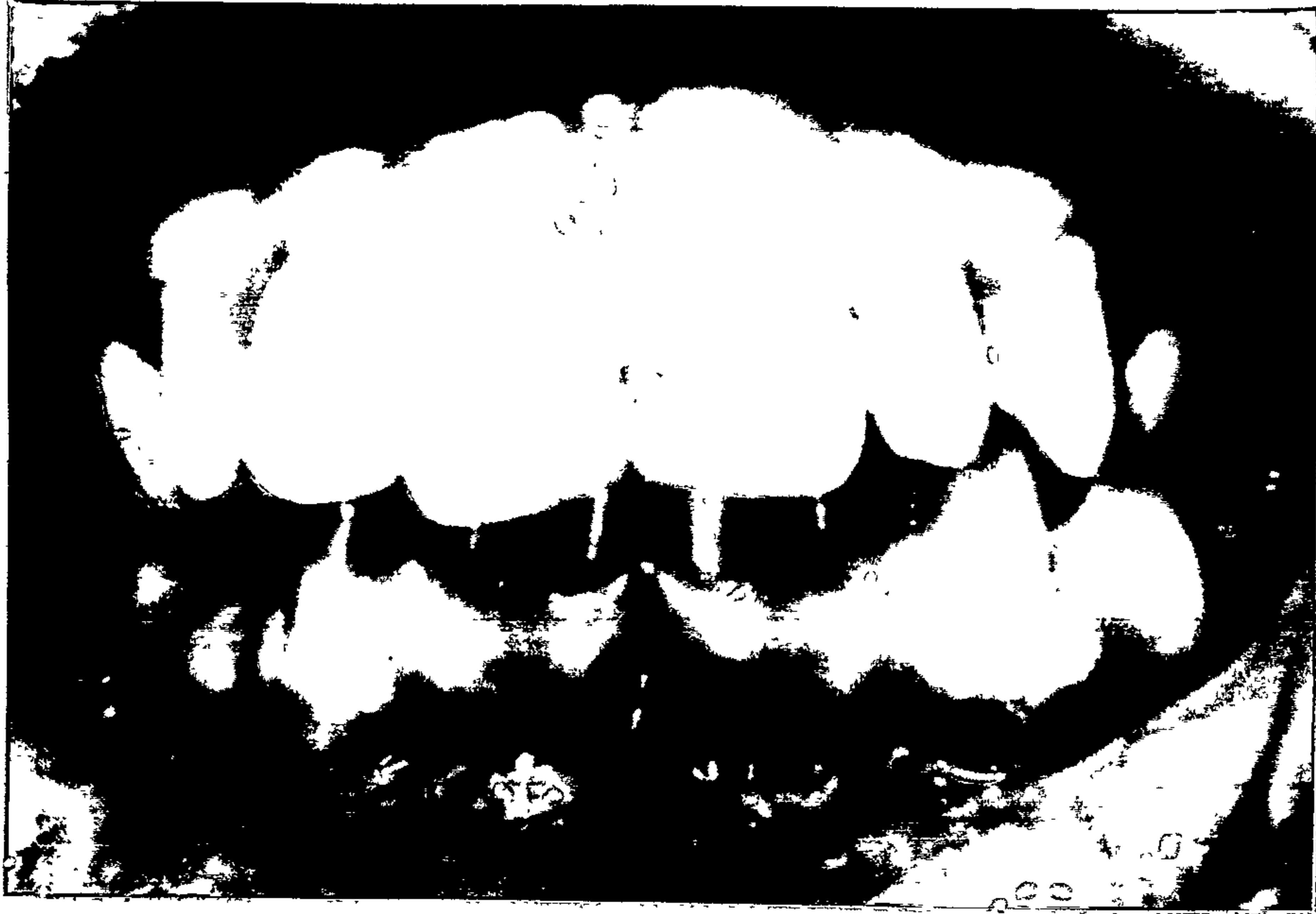Porcelain crown UR2 has overhanging labial margin and gingival recession.

129

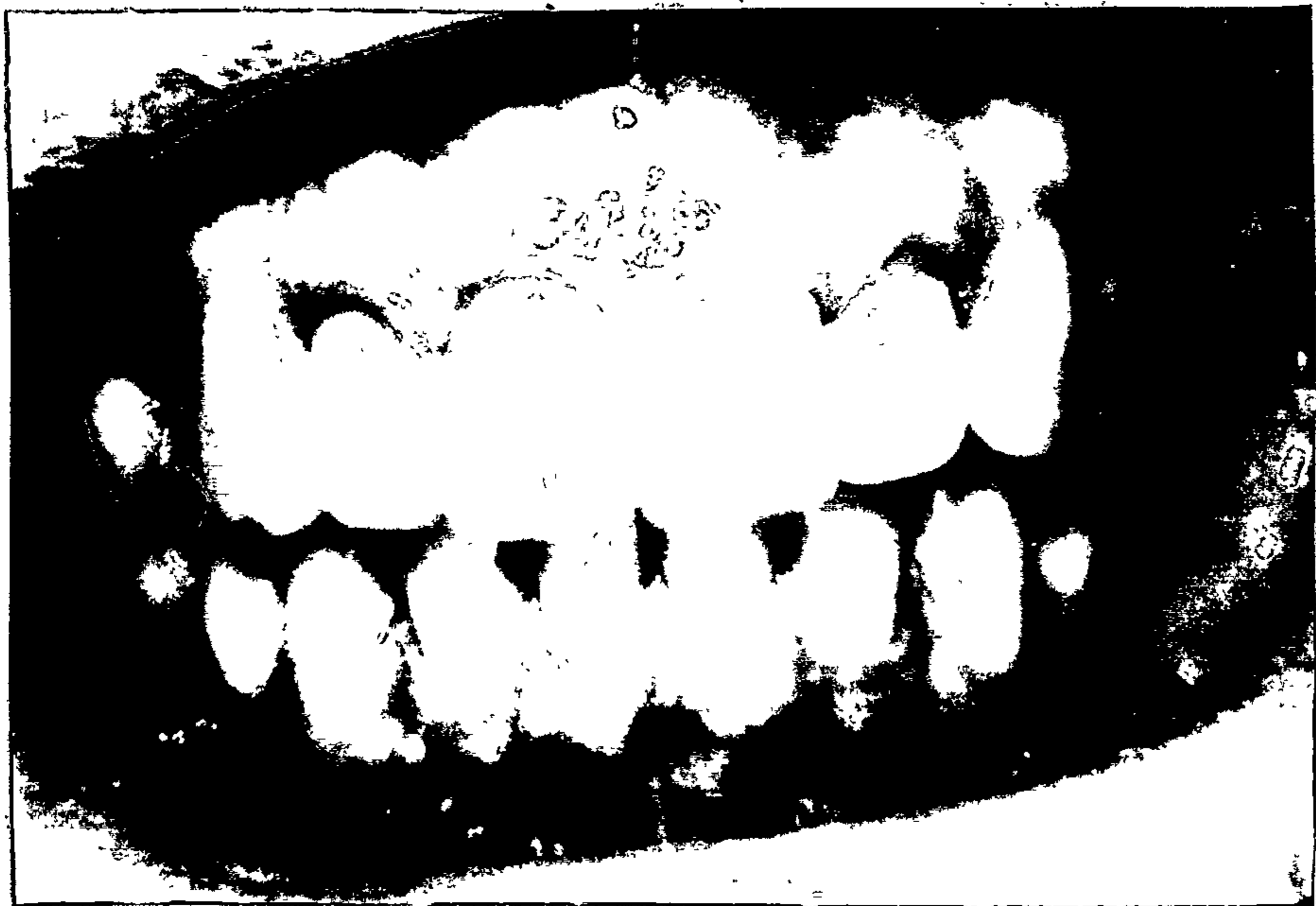Waerhaug in 1953 expressed concern not only about plaque retention on the surface of exposed cement but also in recesses in the cement, where bacteria once having invaded would be unlikely to be eliminated. He also felt that cells and tissue fluids would be more likely to be caught in defective margins and that the products of their subsequent degeneration and death would "ooze out and irritate the surrounding epithelium".

In order to reduce the exposed cement area at the margin of a seated restoration, a bevelled shoulder preparation has been advocated by Silness and Hegdahl¹¹¹ (1970). The less the angle of convergence of the bevel the better is said to be the result. Shoulder preparations are said to give the greatest exposure of cement as the result of a marginal discrepancy or incomplete seating home of a restoration. Chamfer and full bevel preparations fill an intermediate position between the bevelled and full shoulder preparations in regard to cemental exposure.

Venting of restorations when being cemented is an established and effective method of more fully seating a full coverage crown^{9,77}. After cementation every care must be taken to ensure that particles of cement are not left in the sulcus otherwise severe inflammatory¹²⁹ reactions with pus formation may result.



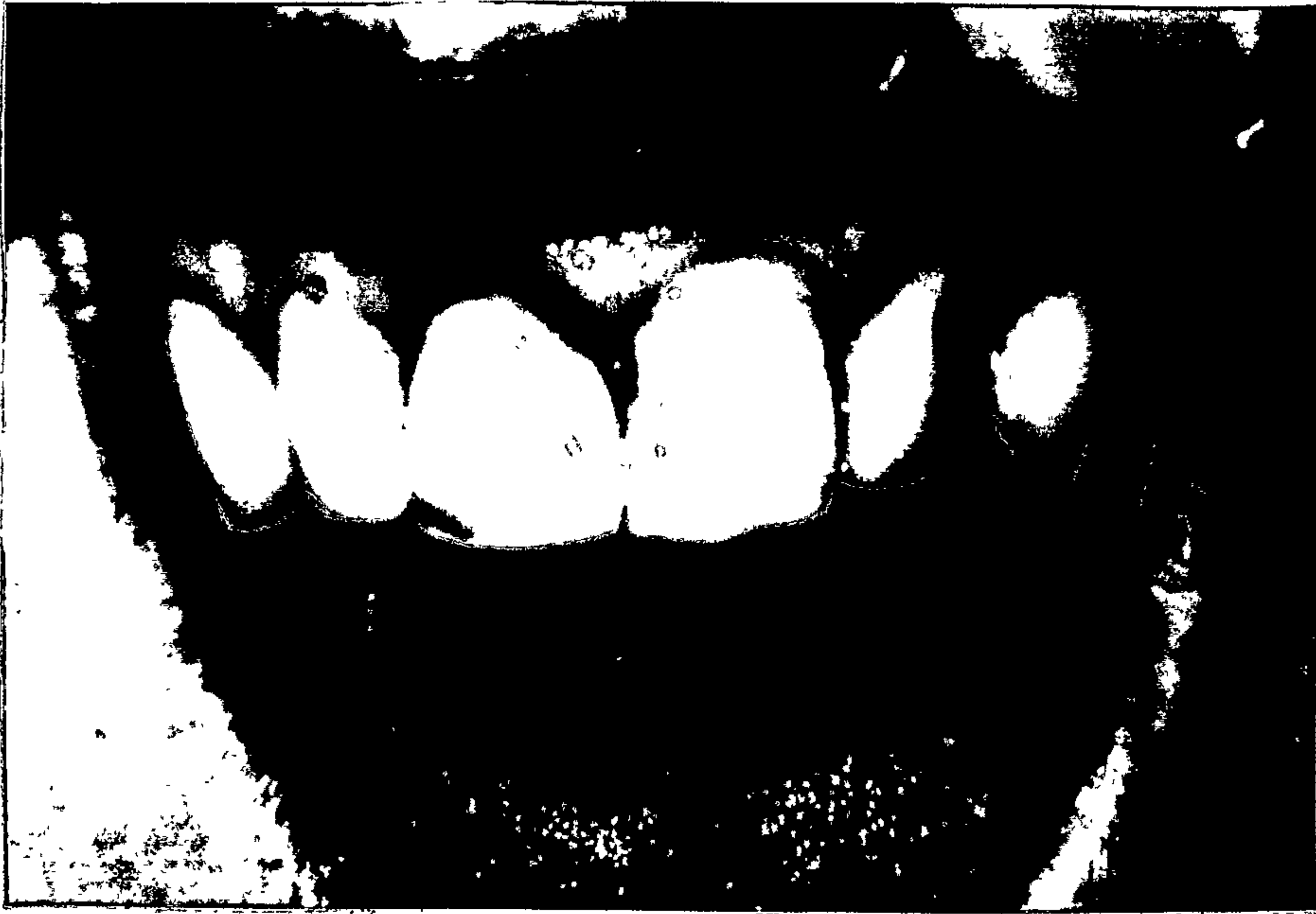Porcelain crown UR2 - mild gingivitis.



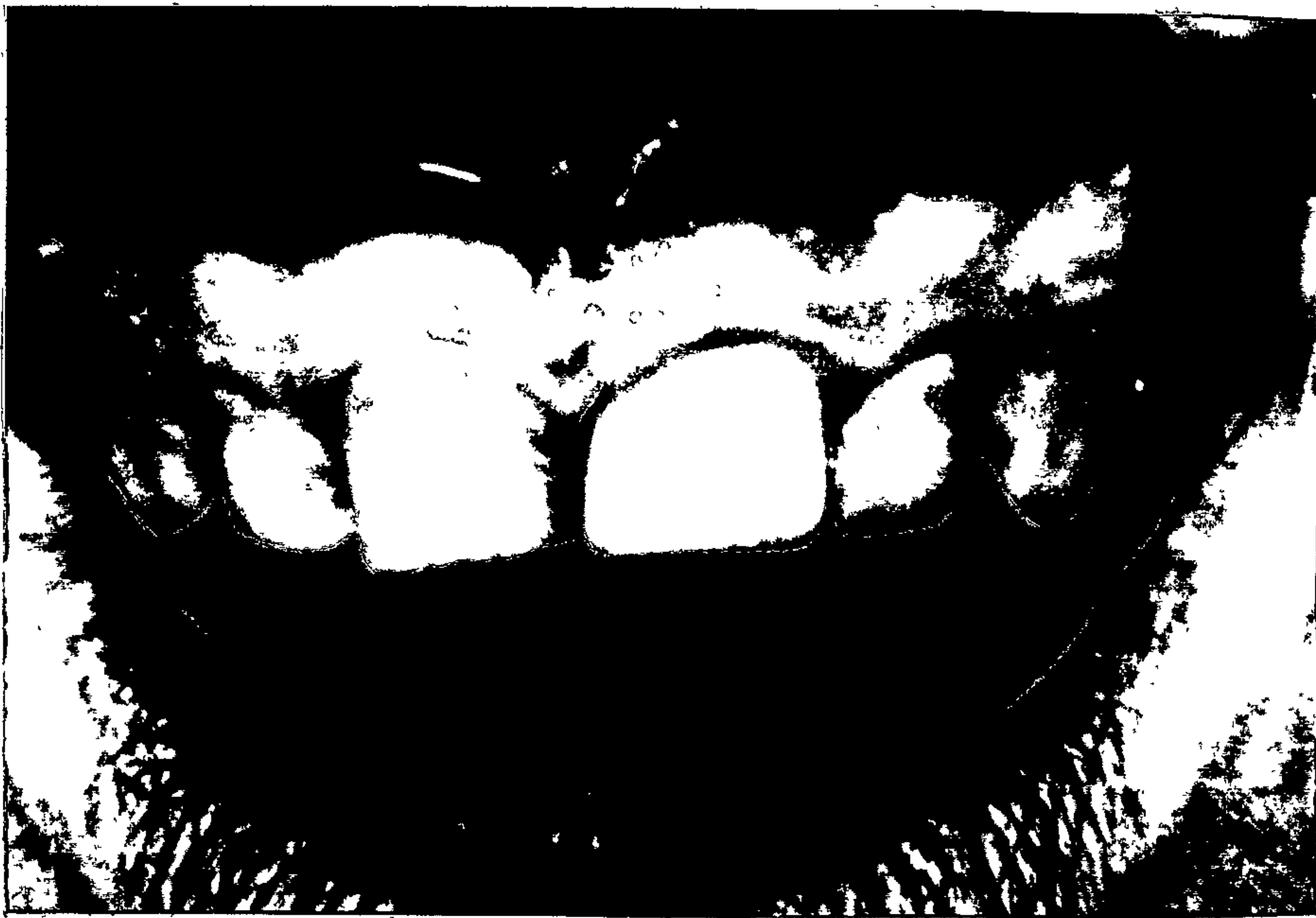Porcelain crowns UR1 and 2, UL1 and 2. Gingiva reasonable but embrasure between UL1 and 2 too reduced and there appears to be some gingival recession.

Wise and Dykema (1975)¹⁵¹ experimentally have shown porcelain to be more easily cleaned than the gold to which it is fused and Type C gold. Newcomb⁷⁸ in 1974 although recording more gingival inflammation for teeth with porcelain and porcelain fused to gold jacket crowns also noted significantly lower plaque scores for the crowns than for homologous uncrowned teeth. Similar observations were made by Chen May-lin.²⁷ (1976) Newcomb related the inflammation to the proximity of the crown margins to the bottom of the sulcus; Chen May-lin to the marginal fit and its relation to the gingiva. Plaque accumulated not on the crown but at the margin.

Although it does not have immunity to plaque formation glazed porcelain does appear to have a lower plaque retaining and debris collecting susceptibility than other restorative materials.⁴⁹ This of course is a great advantage in a restorative material and makes it an excellent choice for full coverage crowns. However the effect that a porcelain restoration has on its surrounding tissues, as with all restorative materials, depends, in the main, on its contour and the position and integrity of its margins.



Marginal gingivitis adjacent to class V restorations and acrylic crown. Plaque disclosed on crown and composite resin restoration on mesial of UL1.



Plaque and stains retained on natural teeth but not disclosed on porcelain crown.

CHAPTER 8.

A fixed bridge can be used to restore the function of the teeth it replaces or to improve a patient's appearance. It should be cleansable, comfortable and acceptable to the oral tissues and if well designed and well finished, is an excellent prosthesis. Bridges may also be used to prevent damage to adjacent and opposing teeth which may be caused by their shifting after the loss of a tooth. However when a tooth is lost the adjacent or opposing teeth do not always move and if movement does occur, it does not necessarily result in periodontal damage or occlusal disturbance.^{97,103}

The replacement of an extracted tooth by a fixed prosthesis, may be prudent in order to maintain contiguity of the dental arch and prevent tooth movement, food impaction or bone loss, if it is done soon after the removal of the tooth. When a tooth has been missing for some time however, and there are no signs of any damage to the supporting structures, nor are function or aesthetics impaired, the insertion of a fixed prosthesis may be unnecessary and could introduce problems such as gingivitis, food retention and impaction, destructive occlusal forces or pulpal damage, where previously no problems existed.

The effect of a fixed bridge on the periodontal structures will depend on the reaction of the tissues to -

- i) its retainers,
- ii) its pontics,
- iii) and the occlusal forces.

RETAINERS:

The characteristics of contour, contact, occlusion, surface finish, adaptation and the positioning of margins which have been discussed for restorations in general are, of course, equally applicable to fixed bridge retainers. Full coverage crowns are now more commonly used as abutment retainers for fixed bridges; they can give good retention and porcelain fused to metal can offer pleasing aesthetics.

The use of full coverage crowns in a mouth which is highly susceptible to caries is advantageous but under normal circumstances the advantages to be gained should be weighed against the conservation of tooth structure, the decreased amount of restorative material in proximity to the gingiva and the lesser insult to the pulp which would result from the use of a part coverage retainer.

108

Silness (1970) found, after comparing 242 abutment teeth with full and partial crowns used as retainers with their homologous teeth, that abutments which had complete crowns with full coverage had larger amounts

of soft deposits, more severe gingivitis and greater sulcus depth than their controls. This was regardless of whether the patients had been instructed in methods of improving their oral hygiene, or not. The periodontal condition of abutments with complete crowns which did not have subgingival margins and partial crowns with limited coverage did not differ significantly from their homologous controls in patients who had been instructed in oral hygiene.

Patients who had had oral hygiene instruction and had subgingival crown margins, showed a marked difference in gingival inflammation between the abutments and the control teeth when compared with the difference in a similar situation in non-instructed patients. The inflammation is more apparent when the rest of the mouth is healthy and its presence "confirms the common clinical observation that healing around subgingival margins cannot be obtained unless the margins are made accessible for tooth cleansing"¹⁰⁸.

From a periodontal point of view the selection of a full crown or part as an abutment is not as important as the extent of its coverage. In his extensive studies of patients with bridges, Silness (1970, 1974^{107,108,109,110,} Silness and Ohm 1974¹¹²) consistently related the amount of plaque retention, gingivitis and the sulcus depth of

abutment teeth when compared with their homologues, to the presence of subgingival margins. The periodontal health of patients who did not have subgingival retainer margins ^{108,112} was related to their oral hygiene.

These findings were also applicable to abutments which were joined together as well as to single unit retainers. ¹¹² In patients who had not had periodontal treatment or been taught oral hygiene the embrasure areas between joined abutments which had the margins of both retainers subgingivally showed significantly poorer periodontal health than the areas with which they were compared. Many had visible soft deposits and almost all bled on gentle probing. Considerable changes were found to have occurred in these embrasures and it was thought that the "impact" of two subgingival margins on the one papilla may have been the explanation. The inflammation was sometimes affected by overextension of the interproximal soldered joint which made the embrasures less accessible for cleansing. The authors discouraged "the use of bridge designs with two or more end abutments in cases where subgingival retainer margins have to be used especially in recipients who do not practice appropriate tooth cleansing methods".

Ninety-eight patients, with fixed prostheses, were examined by Valderhaug and Birkeland (1976) ¹²⁷ five years after the restorations were inserted. The mean sulcus depth of the teeth involved had increased only where the crown margin was subgingival or level with the gingival crest. Sulcus depths of 3mm or more were most frequent when the margins were subgingival and 83% of the sulcus measurements for supragingival margins were 2mm or less. Sulcus depth and gingivitis were unchanged after five years in most of the cases where margins had been placed supragingivally, but margins which had been placed in the gingival sulcus were associated with an increase in gingival inflammation and sulcular depth. More than one third of the margins which had originally been subgingival were above the gingival crest when the patients were re-examined.

The patients, during the five years, had participated in an oral hygiene programme and although the overall periodontal changes which occurred during the survey period were not great, those that did take place were, in the main, associated with subgingival restoration margins.

72

Makila and Salonen (1975) found that of a group of bridges which had been made between 1962 and 1971, and which they were able to examine, 23% of the partial crowns used had failed. Cement had broken in 13% and 22% of the abutments had caries at their margins. Despite these findings full coverage crowns should not be regarded as panaceas in fixed prosthesis construction and each case must be considered and treated with appreciation of the conditions and circumstances which are related to it. Full crowns may be necessary for retention or protection in one case and partial coverage or intracoronal retainers more than enough to ensure retention in another.

The important factor in maintaining a healthy periodontium supporting abutment teeth is not selecting a complete or partial crown as a retainer, but rather, having chosen the type of restoration necessary, ensuring that as little incursion as possible is made into the gingival sulcus. When retainers are joined adequate allowance must be made, when positioning the joint, for interproximal cleansing.

PONTICS:

The tissue contacting surfaces of bridge pontics are usually porcelain, acrylic or gold. The acceptability of glazed porcelain to the epithelium is generally acknowledged, but there is disagreement concerning gold

84,24,35,119

and acrylic when they are used on the gingival surfaces of pontics.

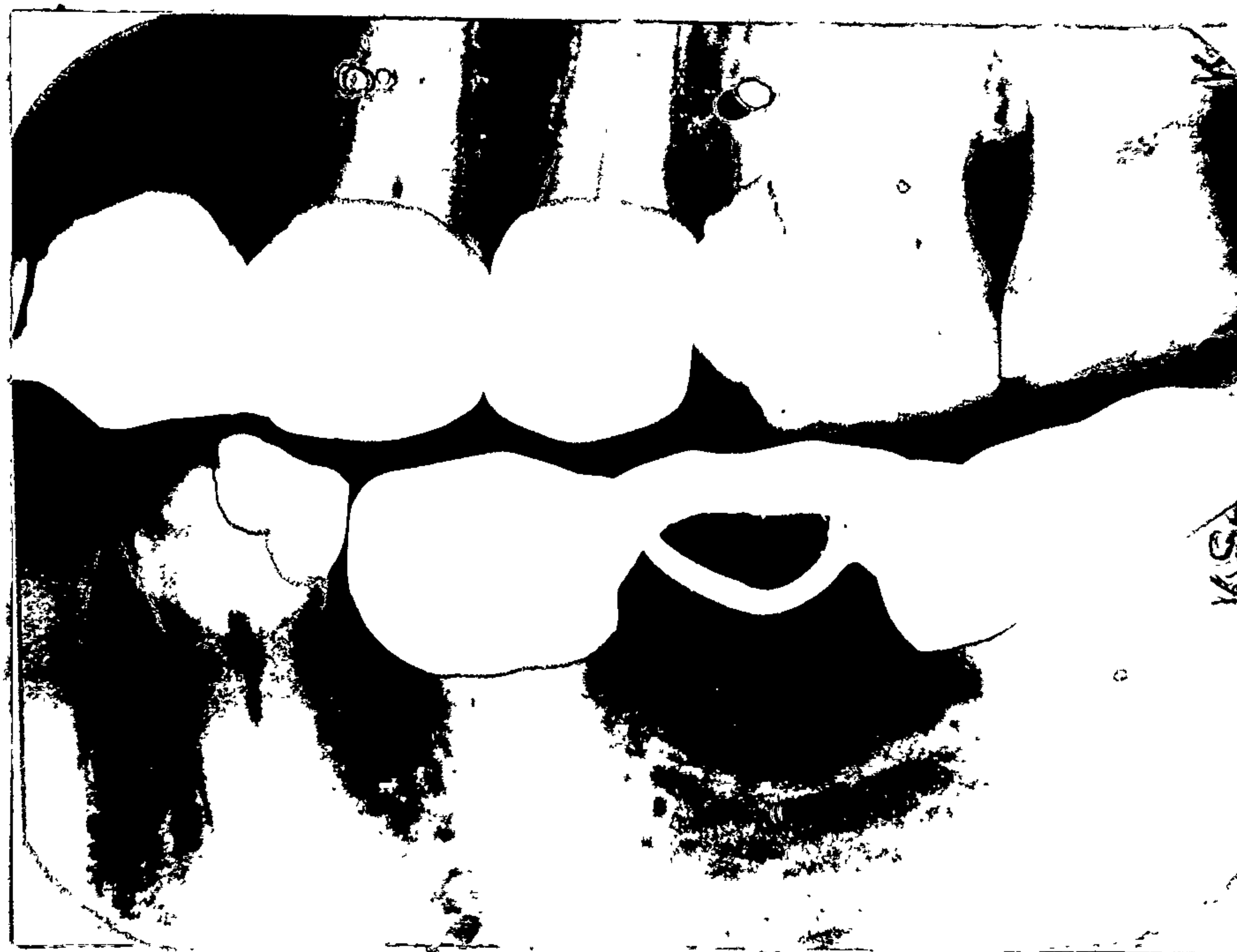After three months Allison and Bhatia (1958)⁴ found extensive inflammatory changes under acrylic pontics placed in monkeys to replace first molars, but very little change under porcelain. Cavazos (1968)²⁴ noted dramatic response to acrylic pontics after four months and a lesser response to gold, but concluded that both these materials are undesirable as tissue contacting surfaces. Gade (1963)³⁵ considered that gold, properly handled, may be satisfactory, but that the structure of acrylic is likely to change over a time "due to water imbibition and internal strains caused by temperature changes".

Podshadley (1968)⁸⁴ having examined four glazed porcelain, five unglazed but polished porcelain, five acrylic and four gold pontics, after six months, decided that although they all produced some changes, they were all equally well tolerated by the tissues.

Stein (1966)¹¹⁹ after the examination of five hundred pontics decided that all materials were susceptible to plaque formation and calculus deposits and that rather than the type of material used, the surface finish and shape of the pontic were the important features that



Calculus beneath acrylic pontics. It may also form on porcelain or gold, but is not evident radiographically.



determined the state of health of the ridge. The tissues adjacent to more than 33% of the pontics examined showed clinical evidence of inflammation. Many bridges which had no evidence of underlying inflammation were removed because of recurrent caries or technical failure and over 95% of these patients "had red ulcerative lesions of the residual ridge mucosa corresponding to the area circumscribed by the pontic's undersurface". The most severe lesions were beneath poorly designed stress-broken bridges and under pontics adjacent to the abutments of long span restorations.

The subject of pontic design is one on which there are many views. Function and hygiene are the important factors in posterior bridges, but in the anterior region design may have to be compromised for aesthetics. To find what he considered to be a satisfactory design for a pontic's gingival surface Stein made eighteen meticulously polished and glazed ridge-lapped pontics for nine patients with above average oral hygiene. (That is pontics fitted to the facial aspect of the mucosa but curving away from the ridge crest on the lingual side). Three patients had gold undersurfaces, three had acrylic and three had porcelain. Almost all the pontics developed some degree of inflammation which became worse after instruction in the use of floss silk was given. With a ridge-lapped surface it was claimed that floss silk scrapes the mucosa and depresses debris into the

the irregular undersurface of the closely adapted pontic and acts as a mechanical irritant which increases the inflammatory response.

When the more lingual part of the undersurface was removed the "ulcerated lesions" almost disappeared in thirty days. When the undersurface was reduced to a point contact the red areas completely disappeared in thirty days. These results were with polished and re-glazed surfaces; if the undersurfaces were not repolished or re-glazed after adjustment there was little remission of the inflamed areas. Modifying the outline form without ensuring surface smoothness did not prevent inflammation.

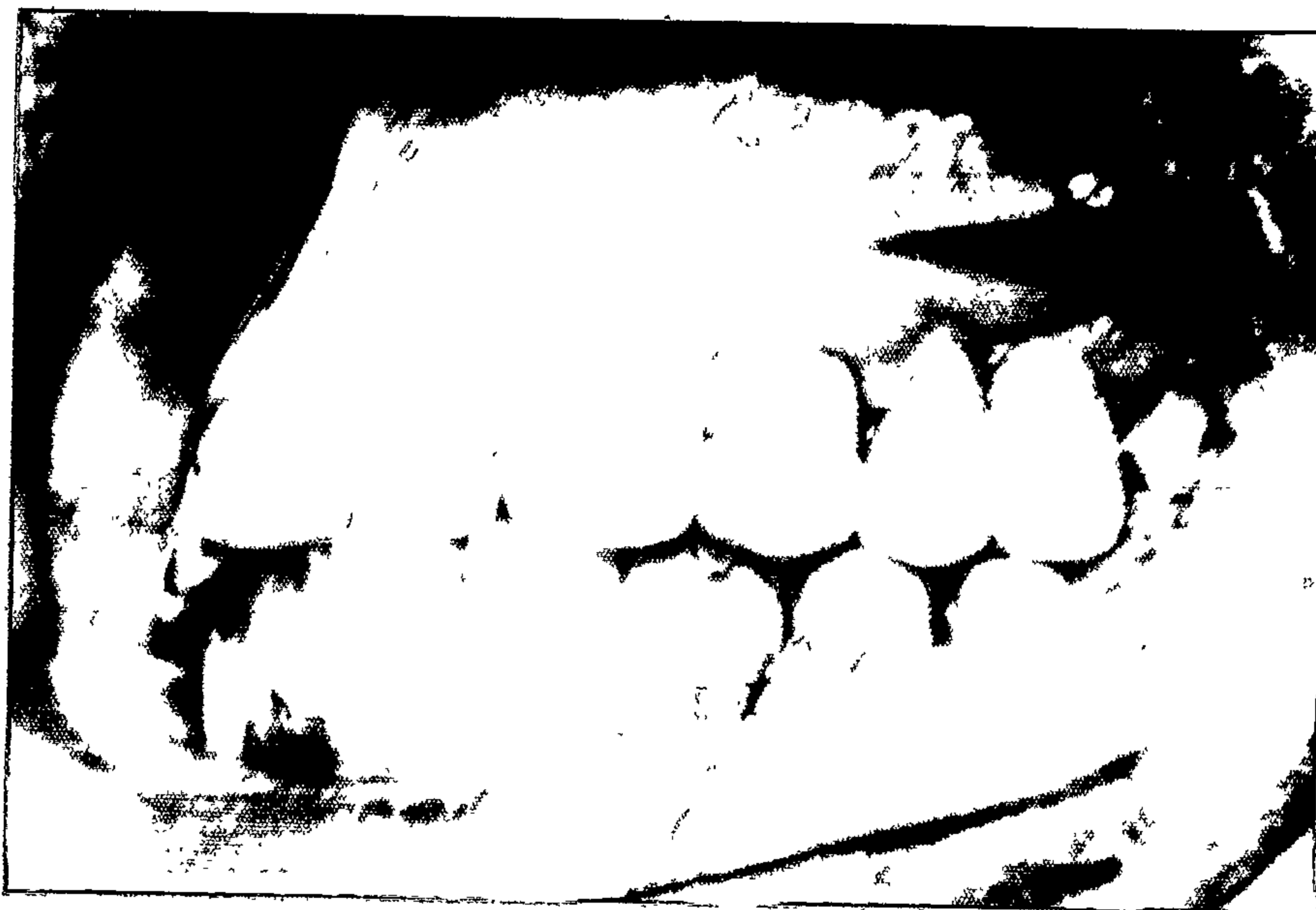Thirty more restorations were made with "pin point" contact and they remained free of inflammation. With minimal tissue contact and a well polished surface the underlying ridge remained healthy regardless of the material used. These observations were made over a ten year period.

Stein regarded the best pontic design to be a "modified ridge lap" in the posterior region and a "lap facing" in the anterior region with a pin point contact on the facial slope of the residual ridge. All surfaces should be convex and highly glazed or polished. He found that although initially routine pin point contact on the mucosa was made by the pontic, after a

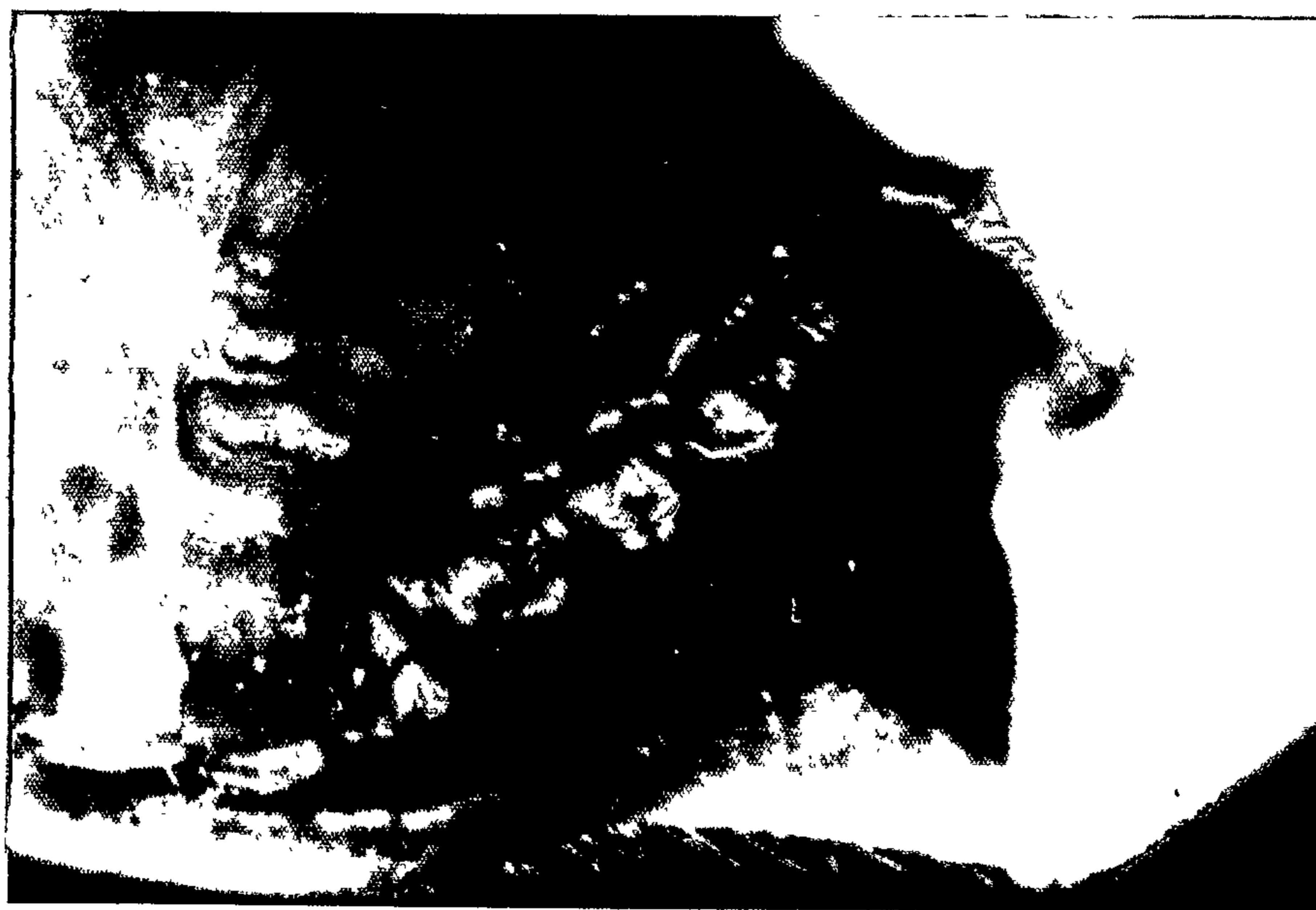month there was no contact between the mucosa and the pontic. Reynolds (1968)⁹¹ described this type of contact, which he also advocated as being "minimal, free of pressure, and thought of as having saliva contact rather than tissue contact".

In his study of 279 pontics Cavazos (1968)²⁴ concluded that the adaptation of a pontic to the ridge and the depth to which a cast is scraped to adapt the pontic, were very significant in causing unfavourable tissue changes which ranged from mild inflammation to acute ulceration. He found gold and acrylic undesirable as tissue contacting materials and to maintain healthy, hygienic conditions for a fixed prosthesis advocated that pontics "be constructed of highly glazed, high fusing porcelain of an ovoid design with a minimal adaptation to the tissue and properly re-inforced with a gold alloy casting".

Pontics with excessive tissue contact, such as the saddle shaped, which sits astride the alveolar ridge, as well as being more likely to foster inflammation, are said to pre-dispose the gingiva to hyperplasia and gingivitis.⁸⁷ Pontics which extend apically beyond the ridge and impinge on the alveolar mucosa cause irritation and inflammation.⁸⁷



Saddle shaped pontics with reduced embrasure space. There is inflamed hyperplastic tissue around pontics and marginal gingivitis around full coverage retainers.



Mirror view

Gade (1963)³⁵ advocated saddle shaped pontics, which he said reduced plaque and food retention and could "rest in contact with mucosa without causing clinical signs of irritation provided that no pressure at all is exercised on the tissues". Stein's (1966)¹¹⁹ subsequent findings do not support this contention as a general rule and have shown that inflammation is less with reduced tissue contact lingual to the crest of the ridge, if the under surface is polished. Highly polished saddle shaped pontics may also be non-irritating but the modified ridge lap design advocated by Stein has been shown to produce good results.

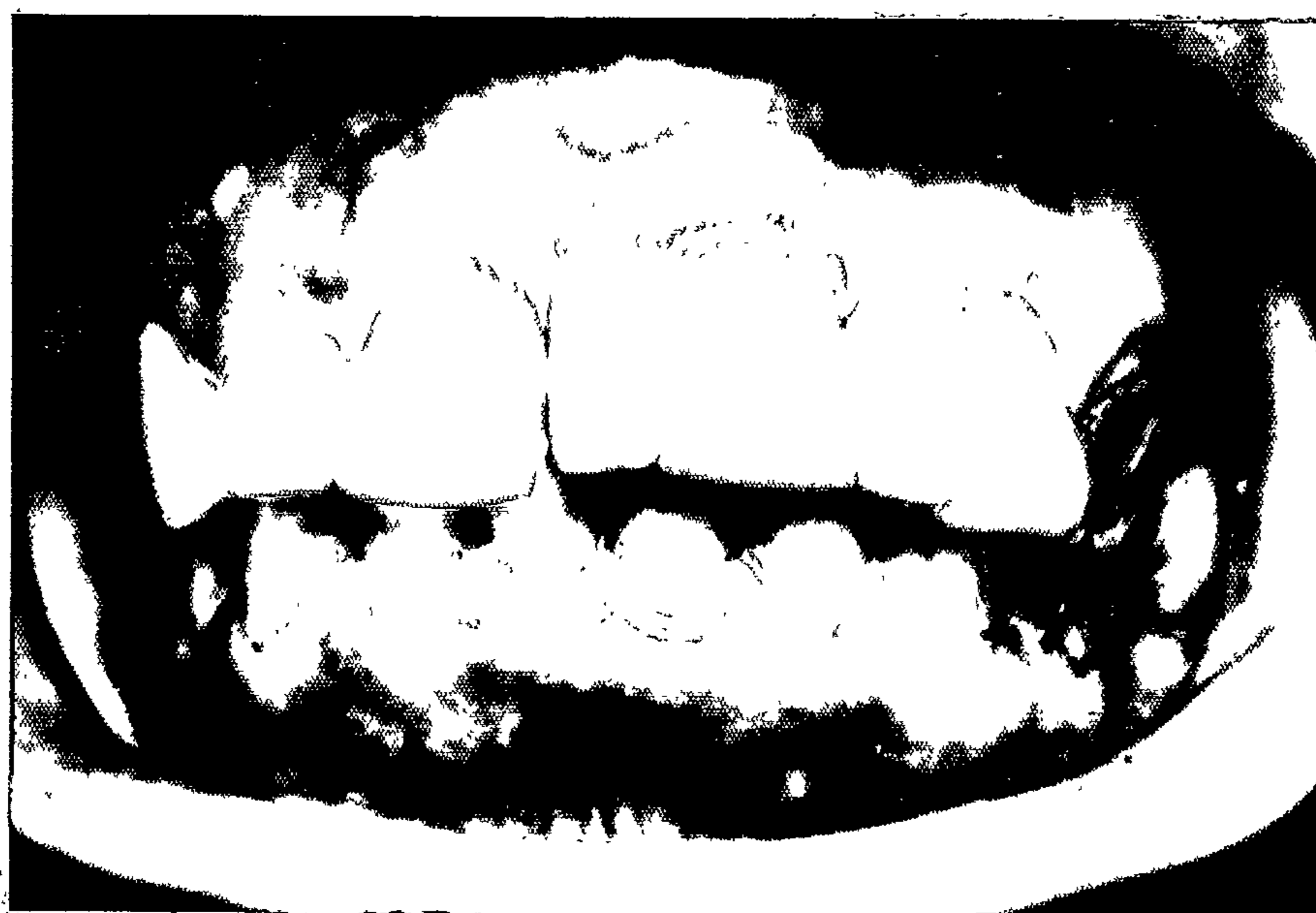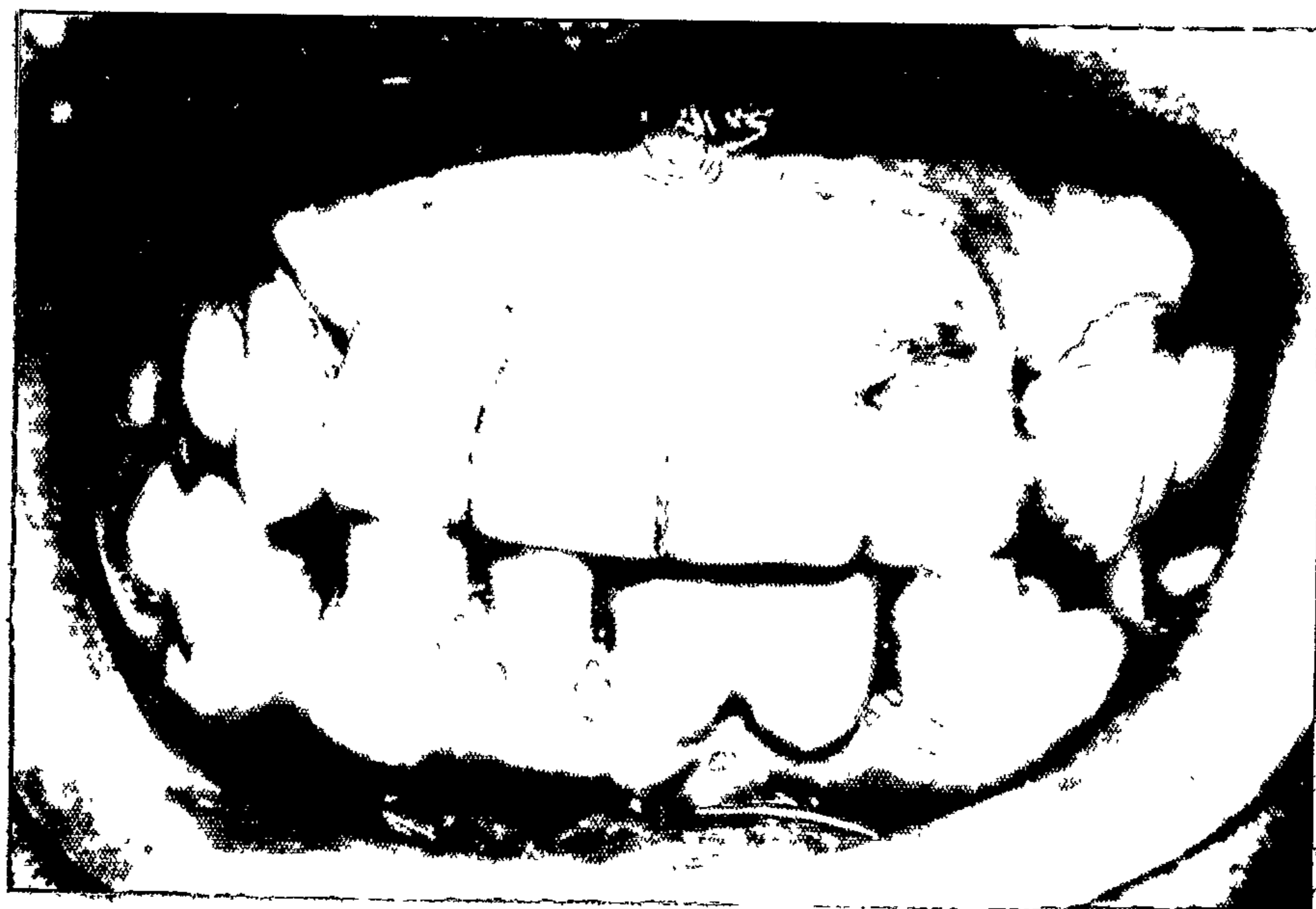A high glaze or polish and lack of pressure on the mucosa are two generally accepted requirements to reduce inflammation on the ridge beneath a pontic. Gold to porcelain or gold to acrylic margins in contact with the mucosa are recognised as undesirable. The join provides a site for bacterial accumulation.^{84,24,35,119,150}

Reinforcement of a pontic to provide rigidity is also important for the health of the underlying ridge. Stein (1966)¹¹⁹ found that the most severe lesions, which had not been obvious before the bridges were removed, were under stress-broken and long span prostheses.

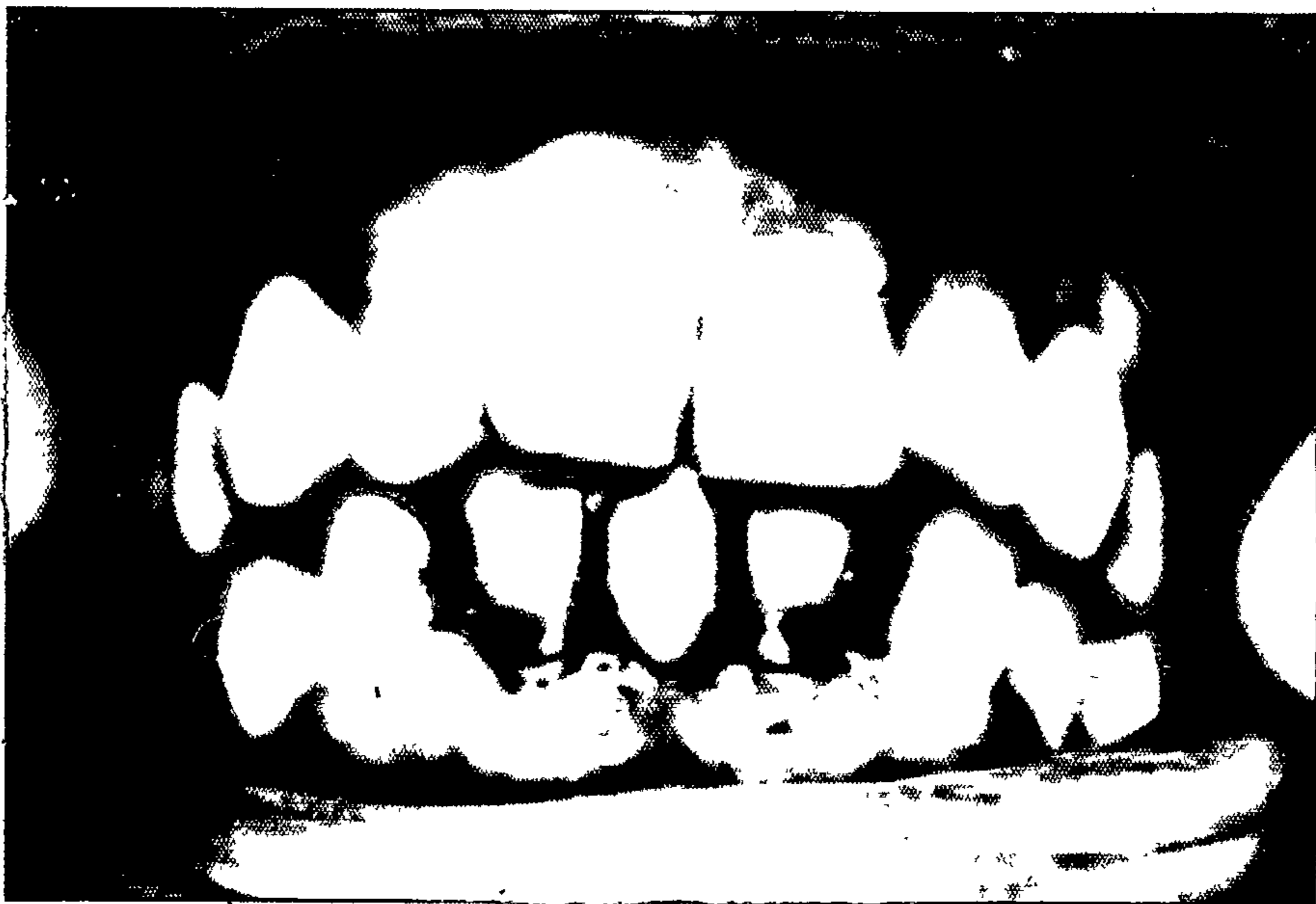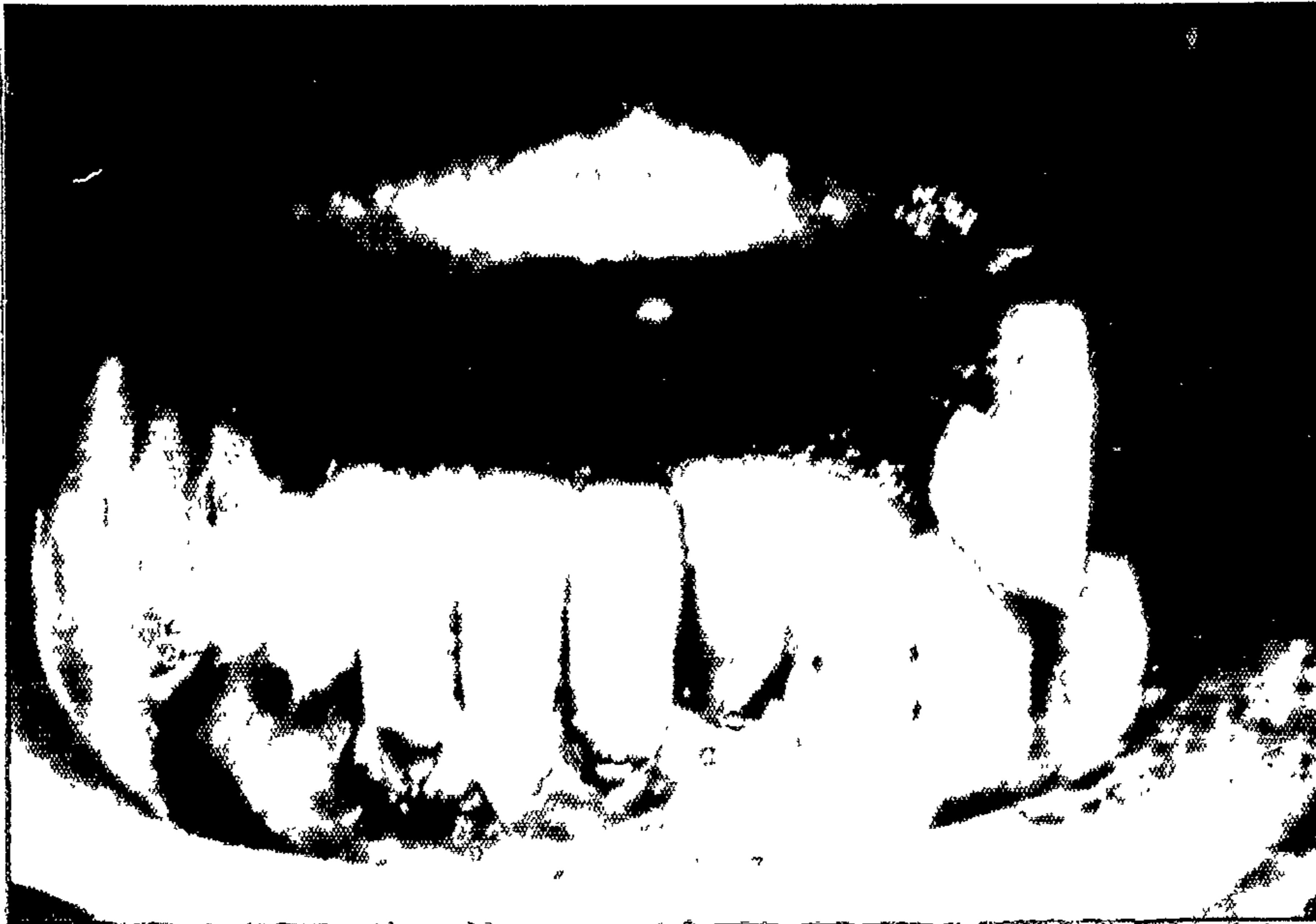A flexible framework will subject the underlying tissues to intermittent pressures which may be just as injurious as permanent pressure. "Proliferation of mucosa along the pontic margins seems to be typical for pontics moving slightly against the ridge."³⁵ Sufficient bulk of supporting gold, particularly in the gingivo-occlusal dimension,^{35,91} must be used to ensure rigidity. It may also be necessary to increase the number of abutments to reduce movement of a long span bridge which otherwise would have insufficient periodontal support. In such a case Silness¹¹² and Ohm's (1974) previously mentioned findings concerning joined abutments should be borne in mind.

Embrasures between abutments and pontics, pontics and pontics and between abutments should be sufficiently wide to allow efficient cleansing.

Satisfactory conditions for the maintenance of good oral hygiene are difficult to obtain when crowded or malaligned teeth are being replaced or used as abutments. For a satisfactory result, it is often advantageous to remove one or more teeth to give better form rather than fabricate a bizarre prosthesis which is neither aesthetic nor healthy.



Bizarre and unhealthy fixed bridges.



Bizarre and unhealthy fixed bridges.

OCCLUSAL FORCES:

119

Stein (1966) considered that the occlusal dimensions of pontics should conform to those of the remaining teeth, and if possible recreate the anatomy of the missing tooth. He stated that buccolingual reduction in width does not allow the correct movement of food away from teeth and introduces a situation similar to a malpositioned tooth, with possible gingival proliferation. Others have advocated some reduction in buccolingual width to reduce the area covered by the pontic base³⁵ or to reduce the occlusal forces on the abutments.⁹⁸ The elimination of occlusal interference whilst maintaining occlusal contact, positioning proximal contact points towards the buccal ensuring that the lingual embrasures are longer and wider than the buccal and establishing marginal ridges are important aspects of protecting the supporting structures and minor variations in the width of the occlusal table may not matter.

Although the cusps, inclines and grooves on the occlusal surface of teeth improve their efficiency and should be reproduced on restorations, the restored occlusal anatomy should be in harmony with the patient's existing occlusal form. Occlusal inclines on restorations that are steeper than the inclines on the natural teeth will place excessive lateral forces on the abutments.

These forces may result in either the loss of the retainer, the shifting of the abutment or increased mobility of the abutment. If a patient's teeth are well-worn, this wear should be reproduced on restorations, which should not be designed to some preconceived idea of proper shape but should conform occlusally with the remaining teeth.

Premature, uneven or uncomfortable contact of restorations may result in a patient clenching or grinding his teeth, and if this is combined with steep inclines which cause cusps to interlock, mobility and bone loss may result.⁹⁷

⁹⁸
Ross (1972) suggests that large occlusal contacts "may produce destructive forces when they are in heavy contact with large contacts of opposing teeth for long periods". Long steep opposing cusps may result in destructive lateral forces rather than forces directed along the long axis of the tooth.

Restorations should, ideally, produce vertical forces which are confined within those parts of the crown directly supported by the roots. An inclined tooth will not stand up to forces as well as one that is erect.⁹¹

Although clinically the crown may appear to be satisfactorily placed, there is a normal difference between the crown and root axes of teeth which often makes it difficult to achieve ideal axial loading.²⁹

The injury which results from incorrect occlusal loading may not produce clinical signs, but may only be visible radiographically in the early stages; often in the furcation area. Clarke (1976)²⁹ states that although "radiographic analysis, Ante's Law, occlusal analysis, periodontal assessment and inter- and intra-arch relationships" may indicate teeth which are not suitable abutments, a "proposed abutment tooth which adequately satisfies all of these considerations may still be unable to respond physiologically to increased loads". However if these considerations are disregarded the tissue response is likely to be unsatisfactory. The biological response of the periodontal support is not predetermined but will vary in individuals just as individuals' responses to poor oral hygiene do. Consequently he advocates careful radiographic assessment of bridgework to reveal signs of occlusal trauma on the attachment apparatus of the abutments.

If not done soon after the extraction, the replacement of lower first molars with fixed bridgework often

presents a dilemma. The second molar may have tipped lingually and mesially and the mesial aspect may have a deepened gingival sulcus. If a bridge is made, the mesial tooth structure of the tilted second molar should be removed and the crown carved as an upright tooth in order to direct the occlusal force more within the crown and along the long axis of the tooth. Because of the forces involved and the tilting of the second molar the results are uncertain. The replacement of second molars satisfactorily is even more uncertain. The roots of third molars are normally directed distally and any mesial tilting after the extraction of the second molar greatly accentuates what was originally an unsatisfactory crown-root relationship.

When a tooth has been missing for some time, if there is occlusal stability and no discomfort, despite the drifting or tilting of teeth, it is doubtful that its replacement would be of any benefit.^{89,97} In the case of lower molars a possible consequence is the loss of the abutments as well as the tooth being replaced.

In the preceding pages the writer has attempted to illustrate how, in treating dental caries or replacing missing teeth, an environment may be created which fosters periodontal disease. This environment results, not so much from operative procedures followed in carrying out treatment but rather from features of finished restorations which facilitate the retention of bacterial plaque in proximity to the gingiva.

Although damage apical to the cemento-enamel junction may result in an apical down growth of epithelium, the junctional epithelium appears well able to handle and repair injuries to the dento-gingival attachment which may occur during operative procedures. On the other hand an inflammatory reaction, on the part of the junctional epithelium, to persistent irritation, may cause deepening of the gingival sulcus.

The integrity of subgingival margins is difficult to assess and marginal defects accumulate bacterial plaque, which if located at the cervical margin of a restoration may proliferate apically, causing inflammation of the junctional epithelium and loss of periodontal attachment. This is a reason why "extension for prevention" of dental caries has become a controversial subject.

Some now consider that a visible well-finished margin provides better protection against secondary caries and is more conducive to oral health than a margin placed in an area in which it is not visible, cannot be adequately assessed or cleaned and may well encourage periodontal disease.

Most published reports of surveys and research indicate the undesirability of placing margins subgingivally because of the difficulty which exists in removing plaque from the surface of the restorations and from marginal defects. It has been shown that in patients who have been instructed in oral hygiene and maintain a good standard of tooth cleanliness inflammation still persists in the presence of subgingival restorations. In fact it is more noticeable because of the high standard of health of the rest of the periodontal tissues.

139
Waerhaug (1976) has advocated the use of an interdental brush to remove plaque from subgingival interproximal restorations and suggests that if restorations are extended subgingivally they should be

designed with the use of such a brush in mind, and allow access for it. Although the brush could not remove plaque adjacent to overhanging margins, it is claimed to prevent its apical proliferation.

The use of restorative materials which contract when setting, are unable to take and hold a good polish, disintegrate in the oral fluids or have other plaque accumulating characteristics, is undesirable in close relationship to the gingiva. For this reason silicate cement, composite resin and self-curing acrylic restorations should be limited to the extent of carious lesions and should not extend to or below the gingival crest.

The marginal integrity of restorations must be assured and the margins placed so that they are accessible for cleansing. Similarly the contours of restorations must allow adequate access for cleaning interproximally and not provide excessive facial and lingual supragingival bulges which may tend to retain plaque. They should not encroach on the interdental embrasure displacing or disturbing the form of the papilla.

The occlusal surface should be harmonious with the rest of the dentition and not have excessively steep inclines which may cause traumatic injury to teeth or their supporting tissues. It should also have properly formed marginal ridges and proximal form to assist in the efficient shedding of food and prevent its impaction.

More extensive restorations such as full crowns and fixed prostheses should be constructed after full consideration has been given to the need for them and not merely to replace a missing tooth or fill a space. Appearance, function and stabilisation of inter- and intra-arch relationships are all strong indications for fixed bridgework, but the need, in a mouth which, although some teeth have been missing for some time, is not unsightly, functions comfortably and has teeth that are firm and stabilised is not so apparent. Treatment may be fraught with unfortunate periodontal and occlusal consequences which would be better avoided.

The principles of margin location and integrity, and the desirable contours of crowns and bridge retainers are the same as for other, less extensive restorations. Adequate tooth preparation is essential

to allow sufficient space for the materials chosen to be used, without producing bulky overcontoured restorations. Pontics should be highly polished or glazed on the undersurface and have no join between materials in contact with the tissues. They should not cause any pressure on the ridge and should have minimal contact with it. Care should be taken in positioning contact points where bridge units are joined, to ensure that the interdental papilla is not displaced and there is adequate space for cleansing.

The temporary cementation of crowns and bridges for about two months in order to assess any suspected potential for periodontal or occlusal damage has been suggested by some writers^{9,22,44,82} and would appear to be a prudent precaution to take. The prostheses can be removed at the end of the trial period and the condition of the surrounding tissues seen and if necessary the appliances adjusted before permanent cementation.

Awareness of the hazards involved and skill in overcoming them are necessary if, whilst attempting to improve patients' appearance and masticatory function, the creation of conditions which are inimical to the health of the supporting tissues of their teeth is to be avoided.

REFERENCES.

1. Aiguier J.E. - Preventive measures in periodontology. J.Am.Dent. Assoc., 25:1:13-20, 1938.
2. Alexander A.G. - Periodontal aspects of conservative dentistry. Br. Dent.J., 125:3:111-114, 1968.
3. Alexander A.G., Morganstein S.I. and Ribbons J.W.- A study of the growth of plaque and the efficiency of self-cleansing mechanisms. Dent. Pract. & Dent. Rec. 19:9:293-297, 1969.
4. Allison J.R. and Bhatia H.L. - Tissue changes under acrylic and porcelain pontics.(abstr) J.Dent. Research, 37:1:66, 1958.
5. Almquist T.C., Cowan R.D. and Lambert R.L. - Conservative amalgam restorations. J.Pros.Dent., 29:524-528, 1973.
6. Anneroth G., Nordenram A. - Reaction of the gingiva to the application of threads in the gingival pocket for taking impressions with elastic materials. Odont. Revy., 20:301-310, 1969.
7. App G.R. - Effect of silicate, amalgam and cast gold on the gingiva. J.Pros.Dent., 11:522-532, 1961.

8. Bergman B., Hugoson A. and Olsson C. -
Periodontal and prosthetic conditions in
patients treated with removable partial
dentures and artificial crowns. A longitudinal
two year study. Acta Odont. Scand. 29:621,1971.
9. Berman M.H. - The complete coverage restoration
and the gingival sulcus. J.Pros. Dent.,
29:3:301-309, 1973.
10. Bjorn A., Bjorn H. and Grkovic B. - Marginal
fit of restorations and its relation to
periodontal bone level. Part I. Metal fillings.
Odont. Revy. 20:311-321, 1969.
11. Bjorn A., Bjorn H. and Grkovic B. - Marginal fit
of restorations and its relation to periodontal
bone level. Part II. Crowns. Odont. Revy.
21:337-346, 1970.
12. Black A.D. - The beginnings of diseases of the
peridental membrane and their prevention.
Dental Cosmos, 54:684-693, 1912.
13. Black A.D. - Something of the etiology and early
pathology of the diseases of the peridental membrane,
with suggestions as to treatment.
Dental Cosmos 55:1219-1226, 1913.

14. Black G.V. - Operative dentistry. Vol II.
Technical procedures in filling teeth.
Chicago, Medico-Dental Publishing Co.,
1908. p. 201.
15. Black G.V. - Beginnings of pyorrhea alveolaris -
Treatment for prevention. Dent. Items of
Interest 33:420-466, 1911.
16. Black G.V. - Special dental pathology: investing
tissues of the teeth and the dental pulp.
Chicago, Medico-Dental Publishing Co., 1915.p.16.
17. Ibid. p.20.
18. Ibid. pp.129-146.
19. Bradley R.E. - Periodontal failures related to
improper prognosis and treatment planning.
Dent. Clinics of N.Amer., 16:1:33-46 Jan. 1972
20. Brannstrom M. and Nyborg H. - The presence of
bacteria in cavities filled with silicate cement
and composite resin materials. Swedish Dent. J.,
64:149, 1971.
21. Bryan A.W. - Some common defects in operative
restorations contributing to the injury of
the supporting structures. J.Am.Dent. Assoc.,
14:1486-1489 1927.

22. Burch J.G. - Ten rules for developing crown contours in restorations.
Dent. Clinics of N.Amer. 15:3:611-618, 1971.
23. Burch J.G. - Periodontal considerations in operative dentistry.
J.Pros. Dent., 34:2:156-163, 1975.
24. Cavazos E. Jr. - Tissue response to fixed partial denture pontics
J.Pros. Dent., 20:143-153. 1968.
25. Charbeneau G.T. Cartwright C.B., Comstock F.W., Kahler F.W., Snyder D.T., Dennison J.B., Margeson R.D. - Principles and practice of operative dentistry. Philadelphia, Lea and Febiger 1975 485p. (p14p241)
26. Ibid pp102-137.
27. Chen May-lin - A clinical and radiographical evaluation in the adolescent of the periodontal response to porcelain jacket crowns provided in the definitive treatment of previously traumatised permanent incisors. Singapore Dent. J.2;1;3 1976.
28. Christensen G.J. - Marginal fit of gold inlay castings. J. Pros. Dent. 16:297-305, 1966.

29. Clarke N.G. - Treatment planning for fixed and removable partial dentures: A periodontal view. J.Prost. Dent. 36:1:44-50. 1976.
30. Cowley G.C. and Levine M. - The effect of plaque on gingival epithelium. Oral Sciences Review 1:103-127, 1972.
31. Crabb H.S.M. - A reappraisal of cantilever bridgework. J. Oral Rehabil., 1:1:3-17, 1974.
32. Donaldson D. - Gingival recession associated with temporary crowns. J.Periodont., 44:691-696, 1973.
33. Emslie R.D. - Prevention in relation to restorative and prosthetic dentistry. Int. Dent. J. 23:1:69-76, March 1973.
34. Fee A.H. - Contacts and contours. J. Am. Dent. Assoc. 27:1035-1045, 1940.
35. Gade E. - Hygienic problems of fixed restorations. Inter. Dent. J. 13:2:318-328, 1963.
36. Gartrell J.R. and Matthews D.P. - Gingival recession. The condition, process and treatment. Dent. Clinics of N.Amer., 20:1:199-213, 1976.
37. Gilmore N. and Sheiham A. - Overhanging dental restorations and periodontal disease. J. Periodont. 42:8-12, 1971.

38. Glantz P.O. Larsson L.A. - Surface roughness of composite resins before and after finishing. Acta Odont. Scand. 30:335-347, 1972.
39. Glickman, Irving, and Smulow J.B. - Periodontal disease: clinical radiographic and histopathologic features. Philadelphia, W.B.Saunders 1974 217p. (p43).
40. Goldschmidt P.R., Cogen R.B. and Taubman - S.B. Effects of amalgam corrosion products on human cells J.Perio. Research 11:108-115, 1976.
41. Harrison J.D. - Effect of retraction materials on the gingival sulcus epithelium. J.Pros.Dent. 11:514-521, 1961.
42. Hazen S.P. and Osborne J.W. - Relationship of operative dentistry to periodontal health. Dent. Clinics of N.Amer. 11:253 March 1967.
43. Heath J.R. and Wilson H.J. - Surface roughness of restorations Brit. Dent. J. 140:131-137, 1976.
44. Herlands R.E., Lucca J.J. and Morris M.L. - Forms, contours and extensions of full coverage restorations in occlusal reconstruction. Dent. Clinics of N.Amer. 6: 147-162, March 1962.

45. Highfield J.E. - A clinical study of the effects of removal of posterior metallic overhanging margins of restorations upon the periodontal tissues. M.Sc. Thesis Univ. of London, 1976
146p (pp96-105)
46. Hirschfeld, Isador - Food impaction. J.Am. Dent. Assoc., 17:1504-1528, 1930.
47. Hoover D.R. and Lefkowitz W. - Fluctuation in marginal gingivitis. J. Periodont. 36:310-314, 1965.
48. Janenko C. - Preliminary survey of the gingival condition adjacent to jacket crowns. Abstr.J.Dent. Research 55:3:524, 1976.
49. Johnson J.F., Mumford, George and Dykema R.W. - Modern practice in dental ceramics. Philadelphia W.B. Saunders 1967 (p285)
50. Jorgensen K.D. - Some observations on silicate cement. Acta Odont. Scand. 28:117-127, 1970.
51. Karlsen, Kjell-Gingival Reactions to dental restorations. Acta Odont. Scand., 28:895-904, 1970.
52. Karring T. and Loe H. - The three-dimensional concept of the epithelium-connective tissue boundary of gingiva. Acta Odont. Scand. 28:917-933, 1970.

53. Kelner R.M., Wohl B.R., Deasy M.J. and Formicola A.J. - Gingival inflammation as related to frequency of plaque removal. J. Periodont. 45:303-307, 1974.
54. Koivumaa K. and Virtanen K. - The effect of galvanism on accumulation of bacterial plaque in vivo. (Abstr) Periodontal Abstracts 20:118, 1972.
55. Lang N.P., Cumming B.R. and Loe H. - Tooth brushing frequency as it relates to plaque development and gingival health. J. Periodont 44:396-405, 1973.
56. Larato D.C. - Influence of silicate cement restorations on gingiva. J. Pros. Dent. 26:2:186-188, 1971.
57. Larato D.C. - Relationship of food impaction to interproximal intrabony lesions. J. Periodont. 42:237-238, 1971.
58. Larato D.C. - Influence of a composite resin restoration on the gingiva. J. Pros. Dent. 28:4:402-404, 1972.
59. Larato D.C. - Effects of artificial crown margin extension and tooth brushing frequency on gingival pocket depth. J. Pros. Dent. 34:6:640, 1975.

60. Leon A.R., Miss - Amalgam restorations and periodontal disease. Brit. Dent. J. 140:377-382, 1976.
61. Listgarten M.A. - Changing concepts about the dento-epithelial junction. J. Canad. Dent. Assoc. 36:270-275, 1970.
62. Listgarten M.A. - Normal development, structure, physiology and repair of gingival epithelium. Oral Sciences Review Vol I 1972 p46.
63. Ibid. p47.
64. Listgarten M.A. - Structure of surface coatings on teeth. A review. J.Periodont. 47:3:139-147, 1976.
65. Loe, Harald - Reaction of marginal periodontal tissues to restorative procedures. Inter.Dent. J. 18:4:759-778, 1968.
66. Loe, Harald - Present day status and direction for further research on the etiology and prevention of periodontal disease J.Periodont. 40:678-682, 1969.
67. Loe, Harald - Plaque control in periodontal disease. J.Amer. Dent. Assoc. 87:1034-1036, 1973.

68. Loe, Harald and Silness, John - Tissue reactions to string packs used in fixed restorations. J.Prost. Dent. 13:2:318-323, 1963.
69. Loe, Harald, Theilade, Else and Jensen S.B. - Experimental gingivitis in man. J.Periodont. 36:177-187, 1965.
70. McHugh W.D. - The interdental gingiva. J.Perio. Res. 6:227 1971
71. McHugh W.D. - The prevention of periodontal disease. p215 (in Eastoe J.E., Picton D.C.A. and Alexander A.G., editors. The prevention of periodontal disease. London, H.Kimpton 1971 244p.)
72. Makila E. and Salonen M. - A follow-up study of partial crowns as bridge retainers. Proc. Finnish Dent. Soc. 71:15, 1975 (abstr) Periodontal Abstracts 23:81 1975.
73. Malone W.F. and Manning J.I. - Electrosurgery in restorative dentistry. J. Prost. Dent. 20:417-425, 1968.
74. Mannerberg, Fritz - Gingival changes following crown therapy. Odont Revy 22:2:155-162, 1971.

75. Marcum J.S. - The effect of crown marginal depth upon gingival tissue. J. Pros. Dent. 17:479-487, 1967.
76. Mormann W., Regolati B. and Renggli H.H. - Gingival reaction to well-fitted subgingival proximal gold inlays. J. Clin. Periodont 1:120-125, 1974.
77. Mount G.J. - Crowns and the gingival tissues. Aust. Dent. J. 15: 253-258, 1970.
78. Newcomb G.M. - The relationship between the location of subgingival crown margins and gingival inflammation. J.Periodont. 45:151-154, 1974.
79. Noble W.H., McClatchey K.D. and Douglass G.D. - A histologic comparison of effects of electrosurgical resection using different electrodes. J. Pros. Dent. 35:5:575-579, 1976.
80. O'Leary T., Standish S.M. and Bloomer R.S. - Severe periodontal destruction following impression procedures. J. Periodont 44:43-48, 1973.
81. Oringer M.J. - Electrosurgery in dentistry. Philadelphia, W.B. Saunders, 2nd edit., 1975. 1134p. (p419).

82. Parkinson C.F. - Excessive crown contours facilitate endemic plaque niches.
J.Pros. Dent. 35:4:424-429, 1976.
83. Perel M.L. - Axial crown contours.
J.Pros. Dent. 25:642-649, 1971.
84. Podshadley A.G. - Gingival response to pontics.
J.Pros. Dent. 19:51-57, 1968.
85. Price C. and Whitehead F.I.H. - Impression material as foreign bodies. Brit. Dent. J. 133:9-14 1972.
86. Prichard J.F. - Advanced periodontal disease. Philadelphia W.B. Saunders, 2nd edit. 1972, 990p. (p522)
87. Ibid. - p900
88. Prime J.M. - Is operative dentistry failing?
J.Am.Dent. Assoc. 23:1:47-58 1936.
89. Ramfjord S.P. - Periodontal aspects of restorative dentistry. J. Oral Rehabil. 1:107-126 1974.
90. Ramfjord S.P. and Costich E.R. - Healing after simple gingivectomy. J. Periodont. 34:401-415, 1963.
91. Reynolds J.M. - Abutment selection for fixed prosthodontics. J.Pros.Dent. 19:5:483-488, 1968.

92. Richards S.A. - Pyorrhea Alveolaris: An additional theory regarding its cause. Dent. J. Aust. 5:11:742-746, 1933.
93. Richter W.A. and Ueno H. - Relationship of crown margin placement to gingival inflammation. J.Pros. Dent. 30:2:156-161, 1973.
94. Romano M.T. - Prevention and conservation in restorative dentistry (Part I). Dent. Clinics of N.Amer. July 1965 p445.
95. Romine E.R. - Relation of operative and prosthetic dentistry to periodontal disease. J.Am. Dent. Assoc. 44:742-747, 1952.
96. Rosen H. and Gitnick P.J. - Integrating restorative procedures into the treatment of periodontal disease. J. Pros. Dent. 14:2:343-354, 1964.
97. Ross I.F. - The relation between periodontal therapy and fixed restorative care. J. Periodont 42:1:13-20, 1971.
98. Ross I.F. - Problems connected with combined periodontal therapy and fixed restorative care. Dent. Clinics of N.Amer. 16:1:47-57, 1972
99. Russell, A.L.-International nutrition surveys: A summary of preliminary dental findings. J.Dent.Research. 42:233-244, 1963.

100. Sanchez-Sotres L., van Huysen G., and Gilmore H.W. - A histologic study of gingival tissue response to amalgam, silicate and resin restorations. *J. Periodont.* 40:543-546, 1969.
101. Schroeder H.E. - Quantitative parameters of early human gingival inflammation. *Archives of Oral Biol.*, 15:383-400, 1970.
102. Schroeder H.E. and Listgarten M.A. - Fine structure of the developing epithelial attachment of human teeth (Monograph) Basel S. Karger 1971, 107p..
103. Schweitzer J.M. - Restorative dentistry - a half century of reflections. *J.Prost. Dent.* 31:1:22-51, 1974.
104. Scoren R.D. - A review of some microbiological considerations of inflammatory periodontal disease. *Parodontologie* 19:1:6-15, 1965.
105. Scrivner E.I. - Gingival tissue management during fixed prosthodontic procedures. *Dent. Clinics of N.Amer.* 15:3:587-593, 1971.
106. Shafer W.G., Hine M.K., and Levy B.M. - A textbook of oral pathology W.B. Saunders, Philadelphia, 3rd. edit. 1974 853p. (p529).

107. Silness, John - Periodontal conditions in patients treated with dental bridges. J.Perio. Research, 5:60-68, 1970.
108. Silness, John - Periodontal conditions in patients treated with dental bridges. II The influence of full and partial crowns on plaque accumulation, development of gingivitis and pocket formation. J. Perio Research 5:219-224, 1970.
109. Silness, John - Periodontal conditions in patients treated with dental bridges. III The relationship between the location of the crown margin and the periodontal condition. J. Perio. Research 5:225-229, 1970.
110. Silness, John - Periodontal conditions in patients treated with dental bridges. IV The relationship between the pontic and the periodontal condition of the abutment teeth. J.Perio. Research, 9:50-55, 1974.
111. Silness, John and Hegdahl, Trond - Area of the exposed zinc phosphate cement surfaces in fixed restorations. Scand. J. Dent. Research 78:163-177, 1970.

112. Silness, John and Ohm, Elizabeth - Periodontal conditions in patients treated with dental bridges. V Effects of splinting adjacent abutment teeth. J. Perio. Research. 9:2:121-126, 1974.
113. Simon B.I., Schuback P., Deasy M.J. and Kelner R.M. - The destructive potential of electrosurgery on the periodontium. J. Periodont. 47:6:342-347, 1976.
114. Skjorland K.K. - Plaque accumulation on different dental filling materials. Scand. J.Dent. Research 81:538-542, 1973.
115. Skougaard M. - Duration of DNA synthesis in the gingival epithelial cells of marmosets. Acta Odont. Scand. 23:615-643, 1965.
116. Smith G.E. and Grainger D.A. - Biomechanical design of extensive cavity preparation for cast gold. J. Amer. Dent. Assoc. 89:1152-1157, 1974.
117. Socransky S.S., Gibbons R.J., Dale A.C. et al. - The microbiotia of the gingival crevice of man. Archives of Oral Biology 8:275-280, 1963.
118. Spalding G.R. - Gingivitis. J.Amer. Dent. Assoc. 23:11:2021-2027, 1936.

119. Stein R.S. - Pontic-residual ridge relationship: A research report. J.Pros. Dent. 16:251,1966.
120. Suomi J.D. - Periodontal disease and oral hygiene in an institutionalised population: Report of an epidemiological study. J. Periodont 40:5-10, 1969.
121. Suomi J.D., Greene J.C., Vermillion J.R. et al. - The effect of controlled oral hygiene procedures on the progression of periodontal disease in adults: Results after third and final year. J.Periodont. 42:3:152-160, 1972.
122. Swartz M.L., and Phillips R.W. - Comparison of bacterial accumulations on rough and smooth enamel surfaces. J.Periodont. 28:304-307, 1957.
123. Taylor A.C. and Campbell M.M. - Reattachment of gingival epithelium to the tooth. J.Periodont. 43:281-293, 1972.
124. Theilade E., Wright W.H., Jensen S.B. and Loe H.- Experimental gingivitis in man. J.Perio. Research, 1:1-13, 1966.
125. Trivedi S.C. and Talim S.T. - The response of human gingiva to restorative materials. J.Pros.Dent 29:73-80, 1973.
126. Trott J.R. and Sherkat A. - Effect of Class II amalgam restorations on health of gingiva: A clinical survey. J.Canad. Dent. Assoc. 30:766-770, 1964.

127. Valderhaug J. and Birkeland J.M. - Periodontal conditions in patients five years following insertion of fixed prostheses. J. Oral Rehab. 3:237-243, 1976.
128. Veldkamp D.F. - The relationship between tooth form and gingival health. Dental Practitioner 14:158, 1966.
129. Waerhaug, Jens - Tissue reactions around artificial crowns. J. Periodont. 24:172-185, 1953.
130. Waerhaug, Jens - Effect of rough surfaces upon gingival tissue. J.Dent. Research. 35:323-325, 1956.
131. Waerhaug, Jens - Effect of zinc phosphate cement fillings on gingival tissue. J.Periodont. 27:284-290, 1956.
132. Waerhaug, Jens - Observations on replanted teeth plated with gold foil. O.Surg. O. Med. O.Path. 9:780-791, 1956.
133. Waerhaug, Jens - A new concept of the epithelial attachment and the gingival crevice in health and disease. Aust. Dent. J.4:164-173, 1959.
134. Waerhaug, Jens - Histologic considerations which govern where the margins of restorations should be located in relation to the gingiva. Dent.Clinics of N.Amer. March 1960 p161.

135. Waerhaug, Jens - Current concepts concerning gingival anatomy. The dynamic epithelial cuff. Dent. Clinics of N.Amer. Nov. 1960 p715-722
136. Waerhaug, Jens - Needs and potentials for clinical research in periodontology. J.Periodont. 40:155-161, 1969.
137. Waerhaug, Jens - Epidemiology of periodontal disease pp1-19 (in Eastoe J.E., Picton D.C.A. and Alexander A.G. editors - The prevention of periodontal disease. London, H.Kimpton 1971 244p).
138. Waerhaug, Jens - Presence or absence of plaque on subgingival restorations. Scan. J. Dent. Research 83:193-201, 1975.
139. Waerhaug, Jens - The interdental brush and its place in operative and crown and bridge dentistry. J.Oral Rehab. 3:107-113, 1976.
140. Waerhaug, Jens and Loe, Harald - Tissue reaction to self-curing acrylic resin implants. Dental Practitioner 8:8:234-240, 1958.
141. Waerhaug, Jens and Zander H.A. - Implantation of acrylic roots in tooth sockets. O.Surg. O.Med.O.Path. 9:46-54, 1956

142. Waerhaug, Jens and Zander H.A. -
Reaction of gingival tissues to self-curing
acrylic restorations. J. Amer. Dent.
Assoc. 54:760-768, 1957.
143. Weinberg L.A. - Esthetics and the gingivae
in full coverage. J. Pros. Dent. 10:737,1960.
144. Weitman R.T. and Eames W.B. - Plaque accumu-
lation on composite surfaces after various
finishing procedures. J.Amer. Dent. Assoc.
91:101-106, 1975.
145. Welk D.A. and Laswell H.R. - Rationale for
designing cavity preparations in light of
current knowledge and technology.
Dent. Clinics of N.Amer. 20:2:231, 1976.
146. Wheeler R.C. - Complete crown form and the
periodontium. J. Pros. Dent. 11:722-734, 1961.
147. Wictorin L. - Effect of tooth brushing on
acrylic resin veneering material II Abrasive
effect of selected dentifrices and
toothbrushes. Acta Odont. Scand. 30:383-395,1972.
148. Wilcox C.E. and Everett F.G. - Friction on
the teeth and the gingiva during mastication.
J.Amer. Dent. Assoc. 66:513-520, 1963.

149. Wilhelmsen N.R., Ramfjord S.P. and Blankenship J.R. - Effects of electrosurgery on the gingival attachment in Rhesus monkeys. J.Periodont. 47:160-170, 1976.
150. Wing, George - Pontic design and construction in fixed bridgework. Dent. Pract. and Dent. Record. 12:390, 1962.
151. Wise M.D. and Dykema R.W. - The plaque retaining capacity of four dental materials. J.Pros. Dent. 33:2:178-190, 1975.
152. Wright W.H. - Local factors in periodontal disease. (Abstr) Periodontics 1:163, 1963.
153. Yuodelis R.A., Weaver J.D. and Sapkos S. - Facial and lingual contours of artificial complete crown restorations and their effect on the periodontium. J.Pros. Dent. 29:1:61-66, 1973.
154. Zander H.A. - Effect of silicate cement and amalgam on the gingiva J.Amer. Dent. Assoc. 55:11-15, 1957.