

THE ROLE OF OPERATIVE DENTISTRY IN  
THE AETIOLOGY OF PERIODONTAL DISEASE

Geoffrey M. Walker BDS, Sydney

A Treatise submitted in partial  
requirement for the degree of  
Master of Dental Surgery

Department of Preventive Dentistry

Faculty of Dentistry,  
University of Sydney

1977

## ACKNOWLEDGEMENTS

I wish to thank Mr. Sydney Levine for his help and encouragement, the use of his library and files and his permission to use some of his illustrations.

I should also like to thank Miss B. Bischoff for her advice and help in producing some of the illustrations.

## INDEX

	<u>Page</u>	
CHAPTER 1	RECOGNITION OF THE IATROGENIC NATURE OF SOME PERIODONTAL DISEASE.	1
CHAPTER 2	"EXTENSION FOR PREVENTION."	8
CHAPTER 3	THE EPITHELIAL ATTACHMENT.	14
CHAPTER 4	BACTERIAL PLAQUE AND GINGIVITIS.	22
CHAPTER 5	OPERATIVE DENTISTRY PROCEDURES	28
CHAPTER 6	THE COMPLETED RESTORATION	36
	i) Contour	37
	ii) Proximal contact and marginal ridges.	40
	iii) Occlusion.	44
	iv) Adaptation and position of margins.	45
	v) Restorative materials and surface finish.	56
CHAPTER 7	FULL COVERAGE CROWNS	61
	i) Contour	62
	ii) Relationship of crown margins to gingiva.	64
	iii) Marginal adaptation	68
CHAPTER 8	FIXED BRIDGEWORK	72
	i) Retainers	73
	ii) Pontics.	77
	iii) Occlusal forces.	84
CHAPTER 9	SUMMARY AND CONCLUSION	88

## CHAPTER 1.

Every dentist has seen damage to the gingiva caused by faulty, roughly finished and poorly contoured restorations, and every periodontist is aware of the important role which can be played by operative dentistry in the aetiology of periodontal disease. It is the writer's aim, in this treatise, to discuss operative dentistry and its relation to iatrogenic periodontal disease, and hopefully to offer suggestions that could decrease the incidence of iatrogenic periodontal disease. The discussion will be confined to the possible periodontal results of operative treatment, but will not deal with the operative treatment of mouths with existing periodontal disease.

Overhanging margins, occlusal interference, rough surfaces, open or loose contacts and faulty marginal ridges with resulting "food-traps" immediately come to mind, but there are other influences of operative dentistry on the maintenance of periodontal health, which, at first, may not be as obvious. At present there appears to be what could be described as a tendency to overtreatment; full coverage restorations are made where less radical treatment might suffice, spaces in the dental arch are filled merely because they are there and extensive restorations undertaken in order to rehabilitate the occlusion yet "often the examination of the mouths of elderly patients has revealed that, not only have a large number of natural teeth been retained, but that their

investing tissues are in good condition in spite of existing malocclusion. In others of this age group, teeth that had been extracted in youth and had not been replaced cause no serious interference with either structure or function.<sup>103</sup> All the restorative procedures involved present potential hazards to the supporting structures of teeth, and should be undertaken prudently.

When enlarged inflamed gingiva is seen in apposition to a restoration it is very easy to blame the patient's oral hygiene and care; but this may not be so. There are inherent dangers to the periodontium in operative procedures and in restorations, which should be understood for "in reality, aesthetic restorations and the maintenance of healthy gingivae start with the preparation of the tooth".<sup>143</sup>

The last twenty or so years have seen great technical advances in dentistry and probably the development that has had the greatest influence is the high speed handpiece. No longer is the preparation of a tooth for restoration an arduous physical task for the dentist and patient but on the contrary many preparations can be done in one visit, and enamel removed for full coverage crowns in a relatively short time. This, combined with the improved porcelains now available and the strength gained from being able to fuse porcelain to metal has resulted in increased

popularity and use of the full crown as the chosen restoration in many cases whereas, before, a more conservative restoration may have been used.

The more extensive gingival margin in this type of restoration makes its potential for damage to the supporting tissues much greater than in other restorations. Great care must be used in the preparation of teeth and in the fabrication, adjustment and cementation of full coverage crowns if periodontal damage is to be avoided. (The hazards and precautions involved with full coverage restorations will be discussed later.)

It should not be thought that the increased use of full coverage crowns or the tempting prospect of being able to complete multiple restorations in one visit have only recently created an awareness of iatrogenic periodontal disease. The problem has been recognised and discussed for many years.

Dr. G.V. Black was cognizant of the periodontal hazards related to operative procedures. In his "SPECIAL DENTAL PATHOLOGY" (1915) he mentions lack of contact of fillings and crowns, poor contacts, loose contacts, improper finish, imperfect margins, ligatures and pieces of rubber dam, and also a lack of knowledge of desirable form in finished restorations, as contributing factors in periodontal damage. His statement that

"the difficulty was not in their power of manipulation but was because of failure to gain a correct conception of the form required"<sup>18</sup> is as apt now as it was then.

In 1911 Black expressed concern over the large proportion of "grave conditions of the peridental membrane starting from these local injuries to the septal tissues... The large majority of these injuries occur because of faulty contact points, many of which are made by the dentist in filling proximal cavities."<sup>15</sup>

A.D. Black, who also placed great importance on correct contact points, in 1912 said, "I have during this year replaced or repaired more proximal fillings in the bicuspid and molars for the purpose of protecting the interproximal gum septum than I have altogether for recurrences of caries due to lack of extension in cavity preparation, to failures in condensation and to bad margins of fillings."<sup>12</sup> He also reported that in a group of 500 young adults between 20 and 35 years of age only 5% did not have gingivitis in some area and of the remainder, 37% of the areas of gingivitis were due to faulty restorations.<sup>13</sup>

In 1927, six papers delivered at the Seventh International Dental Congress symposium on "How may the factors of irritation to the periodontium be eliminated in dental restoration?" were published in the Journal of the American Dental Association. Although these papers

were, in the main, concerned with removable prosthetic appliances, and their effect on the periodontium, the point was made that in operative dentistry restorations may appear at first glance to be technically pleasing, have good margins and be well polished but are bound to fail if their presence causes gingival or periodontal inflammation.<sup>21</sup>

Hirschfeld<sup>46</sup> in 1929 read his paper on "Food Impaction" to the American Academy of Periodontology and in it listed improperly constructed restorations amongst the aetiological factors in the interproximal impaction of food. His description of the mechanisms involved was a great advance in understanding desirable relationships between adjacent and opposing teeth, and thus desirable forms and relationships of restorations.

In the following years the dangers of overhanging margins and food retention on crowns and fillings were stated,<sup>92, 1</sup> the desirable contacts and contours of restorations analysed,<sup>34</sup> and the possibility that gingivitis involving restored teeth might be prevented by proper finishing and contouring of the restorations pointed out.<sup>118</sup> Dentists were challenged by Prime in 1936 to produce better results in operative dentistry.<sup>88</sup>

In point of fact there had been enough published twenty-five years ago about the relationship of operative dentistry to periodontal disease to prompt one writer to

state that "'faulty dentistry' is discussed so much that one begins to wonder whether there is any operative dentistry correctly done. This prevalence of faulty dentistry offers abundant proof that its relationship to periodontal disease still is unrecognized and its importance unrealised".<sup>95</sup>

In recent years the number of papers on this subject have been more frequent and a growing number of them have been written by clinicians other than periodontists. But clinical observation still shows that the technical and physical aspects of operative dentistry are uppermost in practitioners' minds and concern for the biological aspects, particularly in regard to the periodontium lags behind. Retention it appears is the prime consideration. Contact, contour, occlusion and marginal adaptation are secondary. Protection of the pulp is important but protection of the periodontium, it would seem, is not so important.

To judge by the number of overhanging margins which appear in many consecutive bite-wing radiographs it would be logical to assume that as "food-traps" are generally corrected, because the patient finds them uncomfortable, overhangs are often forgotten because they are not uncomfortable.

Didactic textbooks on operative and restorative dentistry perused by the writer, with one exception,<sup>26</sup> give very little space to the supporting structures and their protection. Advice is given on protecting the gingiva during operative procedures and retracting it for impression taking but very little is said on designing restorations to conserve the gingiva.

The investigations and writings of G.V. Black were an undoubted major contribution to the advancement of modern dentistry, but, of course, they were limited by the facilities and knowledge at the turn of the century. He believed that the epithelium of the gingival crevice was attached to the cementum at the cemento-enamel junction and had no attachment at all to the enamel<sup>16</sup> and that it differed from the oral epithelium only in the number of cell layers and the flow of gingival fluid.<sup>17</sup> Holding these views, and also believing that, "it is an established fact that no decay begins and that there is no recurrence of decay in any part of the tooth covered by a healthy free border of gum"<sup>14</sup> it was logical that he should advocate that "the free border of the gum should be pressed away and the gingival wall [of the cavity] so cut that its margin will be covered by it when it returns to its normal position."<sup>14</sup>

In children and young people, because of the coronal position of the gingival margin and its anticipated apical migration with age, it was considered necessary "to so place the gingival wall of the cavity that it will be deeply covered by the free border of the gum when finished."<sup>14</sup>

Now, as the result of electron microscopy and improved laboratory preparation techniques, there is a better understanding of the nature of the epithelial

attachment.<sup>102</sup> The attachment of the junctional epithelium to enamel has been shown to be mediated by hemidesmosomes (inter-cellular bridges) and a cellular basement lamina and to resist separation. Disruption of the attachment is thought to occur within the junctional epithelium itself and to result from failures in cellular cohesion rather than in adhesion to the enamel.<sup>63</sup> One wonders if Black would have advocated such radical disruption of the dento-gingival attachment apparatus if this knowledge of its ultrastructure had been available to him.

The principle of "extension for prevention" has been questioned for some time.<sup>3,5,25,33,56,65,76,116,136,145.</sup> This applies not only to subgingival extension, but also to extending restorations in embrasures into so-called "self-cleansing" areas. It has been demonstrated that if active tooth cleaning is stopped, bacterial plaque accumulates on the dentition even when a diet of coarse food and fruit is maintained.<sup>69,42</sup> Mastication appears to limit the retention of plaque only on the occlusal and incisal areas.<sup>66</sup> Thus the idea of extending the margins of restoration into "self-cleansing areas" is difficult to support when those areas cannot be demonstrated.

The suggested use of the term "cleansable areas"<sup>94</sup> rather than "self-cleansing area" and "self-cleansing mechanism" appears to be a reasonable approach both to the facts, and, to the placing of restoration margins.

Caries and undermined enamel should be removed and the margins of restorations should be visible to ensure that they are properly finished and accessible to satisfactory oral hygiene procedures. Extension beyond these limits destroys sound tooth structure without increasing protection against caries. It may also damage the gingiva and encourage sub-gingival plaque formation. In a study of one hundred and eight extracted teeth with proximal restorations extended beneath the gingiva approximately 90% of the restorations were covered with plaque sub-gingivally.<sup>138.</sup>

Rough surfaces<sup>130, 122</sup> or inadequate marginal adaptation facilitate the retention of bacterial plaque. If the margins cannot be seen, it cannot be sure that they are properly adapted. With a simulated mouth in which teeth were mounted in acrylic and surrounded by soft denture reline material to represent the gingivae, ten dentists, experienced in operative dentistry, each examined ten MOD inlays. They were unable to evaluate consistently the marginal opening of gingival areas either with explorers or radiographs. They disagreed more on the clinical acceptability of gingival margins than on any other



Radiographic view of bone loss associated with overhanging margins.

marginal area. Gingival margins with openings up to four times the size of some of the rejected visible margins were accepted.<sup>28</sup>

A survey of 1763 subjects with suitable radiographs showed one third of all posterior teeth with proximal restorations and one quarter of all restored proximal surfaces had overhanging gingival margins and that there was significantly less alveolar supporting bone adjacent to the posterior teeth with overhangs than adjacent to homologous surfaces without overhangs.<sup>37</sup>

In another survey of 225 sets of 14 film intra-oral radiographs the investigators found that three-quarters of all measurable gingival margins had defects and that 55% of these faults were greater than 0.2mm. Marginal defects in excess of 0.3mm were associated with "a highly significant loss of marginal bone" and reduction in bone height bore a clear relationship to the amount of excess filling material.<sup>10</sup> Other surveys have produced similar results.<sup>60, 126.</sup>

Thus control of the marginal adaptation of subgingival restorations is very difficult and unpredictable. "Under normal clinical conditions it is almost impossible to finish the margins flush with the tooth so as not to create a likely site for plaque formation and bacterial stagnation."<sup>126</sup>

The placing of restoration margins sub-gingivally in an area that is no longer regarded as being sterile and self-cleansing<sup>117, 104</sup> should not be advocated as a routine procedure.

Occasionally it may be necessary for a restoration to be placed in the gingival crevice; particularly to improve the aesthetics of anterior jacket crowns. Requirements for retention in teeth with short clinical crowns extensive caries, or loss of tooth structure are other circumstances which may be considered to warrant sub-gingival margins.

Where possible pins should be used to enhance retention rather than increasing the depth of the gingival crevice. Carious lesions and lost tooth structure that need extension beneath the gingival margin could be treated, and better periodontal health maintained if the gingiva were re-contoured before the restorative procedures were carried out. This would enable the restoration margin to be seen and finished properly and obviate the insertion of a restoration under gingiva which is already inflamed.

The extension of the margins of proximal and cervical third restorations beneath the gingiva, was based on the principle that they would be in a disease-free area and covered by healthy gingiva, but the mere presence of some restorative materials produces an inflammatory

reaction:<sup>154,7</sup> More potentially destructive is the accumulation of plaque on restorations which may have surfaces to which microbial plaque is more adherent,<sup>138,144,58</sup> that are difficult to finish satisfactorily and that are virtually impossible for patients to clean adequately.

"Unfortunately the cause of much periodontal disease is dentistry itself."<sup>19</sup> In order to appreciate the response of the gingiva to irritation it is necessary to understand the nature of the dento-gingival attachment.

CHAPTER 3

The gingiva is that part of the oral mucosa that surrounds the teeth and is limited coronally by the gingival margin and apically by the muco-gingival junction. It is lined by epithelium on the vestibular side and between the gingival margin and the epithelial attachment to the tooth. A healthy gingival margin has a knife-edged appearance and the gingival surface is stippled. The stippling is thought to be caused by finger-like projections of connective tissue into the epithelium, which is internally characterised by intersecting ridges of varying depth and thickness<sup>52</sup>. The stippling is lost when the gingiva becomes inflamed and oedematous.

As previously mentioned, it is only since the development of electron microscopy that the nature of the epithelial attachment to teeth has begun to be understood. In 1921 Black's view that there was no attachment of the gingiva to teeth coronal to the cemento-enamel junction, where attachment was made to the cementum<sup>16</sup>, was challenged by Gottlieb's histological evidence of an "epithelial attachment."<sup>61</sup>

Gottlieb said that as the result of degeneration of ameloblasts, stratum intermedium and stellate reticulum the primary enamel cuticle, previously produced by the ameloblasts, came into intimate contact with the outer enamel epithelium which, in preparation for eruption, became

squamous epithelium and gradually keratinised against the primary enamel cuticle. The oral epithelium united with the outer enamel epithelium as the tip of the crown emerged into the keratinised oral cavity.

The sulcus formed because the keratinised layer, which had united with the enamel cuticle, separated from the non-keratinised part of the outer enamel epithelium. The sulcus moved apically as a result of the gradual keratinisation of the outer enamel epithelium and the splitting of the keratin layer from the non-keratinised epithelium. He called the keratinised layer the secondary enamel cuticle, and later, because it could be over cementum, the dental cuticle.

Before Gottlieb's paper, when gingival tissue adhering to extracted teeth was removed, the zone of perfect, unstained, caries-free enamel which was uncovered, was thought to have been in the sulcus, and caries-immune. Therefore it was thought desirable to place the gingival margin of proximal restorations in this area. In the Gottlieb concept it was clean because it had been covered by attached epithelium and not exposed to the oral environment.<sup>61</sup>

Although Gottlieb's views began to receive general acceptance they made little, if any, difference to where the gingival margins of restorations were placed. It

seemed that although Gottlieb's concepts were being taught Black's principles were being followed.

Clinicians found inconsistencies in Gottlieb's description of the epithelial attachment and its formation. They knew, as Black had, that instruments could be placed between gingiva and teeth and that the tissue would not be permanently damaged, but would heal quickly as a rule and not as an exception. It seemed that clinically the bottom of the sulcus was not where it had been shown to be histologically.<sup>135</sup>

With these inconsistencies in mind Waerhaug, in 1952, proposed a view of the epithelial attachment which was not that much different from Black's. It was based on the same principle as Black's, in that it acknowledged that one can slide thin pieces of metal or celluloid between tooth and gingiva as far as the cemento-enamel junction, but it appreciated a more intimate adaptation of crevicular epithelium to teeth with a form of adhesion rather than attachment. This he called the "epithelial cuff" and later "dynamic epithelial cuff" as distinct from Orban's "attached epithelial cuff".<sup>135</sup>

It was said not to be "a rigid system which is spoilt forever if it is once broken" and damage "will most likely always be followed by healing".<sup>133</sup> A normal crevice was described as one in which "the epithelial cuff adheres to

the tooth at the gingival margin without the existence of a bacterial plaque between. Pathologic conditions develop when bacterial plaque grows between the epithelial cuff and the tooth", but bacteria not retained on the tooth as plaque are removed by the flow of tissue fluid and partly destroyed by leucocytes.

102

Schroeder and Listgarten have shown that Black and Waerhaug's conclusions were not unreasonable, nor were Gottlieb's. With the electron microscope and improved fixing techniques they have shown that there is an actual epithelial attachment and have described the nature of the epithelium and its attachment. They have also offered an explanation of why, when probing the gingival sulcus, the tip of the probe may often reach the cemento-enamel junction but not represent the actual histological depth of the sulcus.

The epithelial lining of the gingival sulcus has been divided into two parts; the junctional epithelium and the oral sulcular epithelium. The former is the epithelial collar which provides the attachment to the tooth surface. It is continuous with the oral sulcular epithelium but structurally distinct. The latter, the coronal portion of the sulcular epithelium, is continuous with, and structurally similar to the oral epithelium of the gingiva, but not keratinised.

The name "junctional epithelium" was chosen in preference to the other names, previously in use, epithelial attachment, epithelial cuff, attached epithelial cuff, attachment epithelium and sulcular or crevicular epithelium, all of which were considered to have become associated with specific functional or clinical implications which may not be correct.

The junctional epithelium is located between the gingival connective tissue and the tooth and its attachment to each is mediated by hemidesmosomes and a basement lamina; the internal basement lamina to the tooth and the external basement lamina to the connective tissue. The coronal portion of the junctional epithelium forms the bottom of the sulcus.

Junctional epithelial cells seem to be less tightly bound to each other than cells of the oral sulcular epithelium, and there is a faster rate of cell desquamation. This is the result of a high rate of cellular turnover<sup>115</sup> and the relationship of the size of the germinative surface (the external basement lamina) to the desquamative surface (the bottom of the sulcus<sup>62</sup>). This suggests that the junctional epithelium is more fragile and permeable than the oral sulcular epithelium.

Leucocytes present in the junctional epithelium increase the inter-cellular spaces and make the epithelium

more permeable and likely to damage<sup>101</sup>. When metal strips, celluloid strips, or probes are placed in the gingival sulcus there is little resistance and the junctional epithelium is penetrated. The high rate of exfoliation of cells and the presence of "scavenging leucocytes" appears to result in the junctional epithelium being well equipped to handle these and other injuries and there is generally rapid replacement or repair.<sup>63,123</sup>

" Ideally the sulcus is very shallow but under the influence of local inflammation, perhaps as the result of restorative procedures or restorations it may deepen. The following excerpt from Schroeder and Listgarten's monograph<sup>102</sup> (page 102) describes the possible sequence of events which results in a deepened gingival sulcus, in the presence of mild inflammation or even "in the absence of clinically observable disease".

Under ideal conditions, a very shallow gingival sulcus is present which is lined in part by oral sulcular epithelium and the free surface of the junctional epithelium merging with each other. A few polymorphonuclear leucocytes can generally be observed within the intracellular spaces of the junctional epithelium (fig.36A). If, as a result of inflammation, the number of polymorphonuclear leucocytes in the junctional epithelium increases so as to occupy more than approximately 30% of the

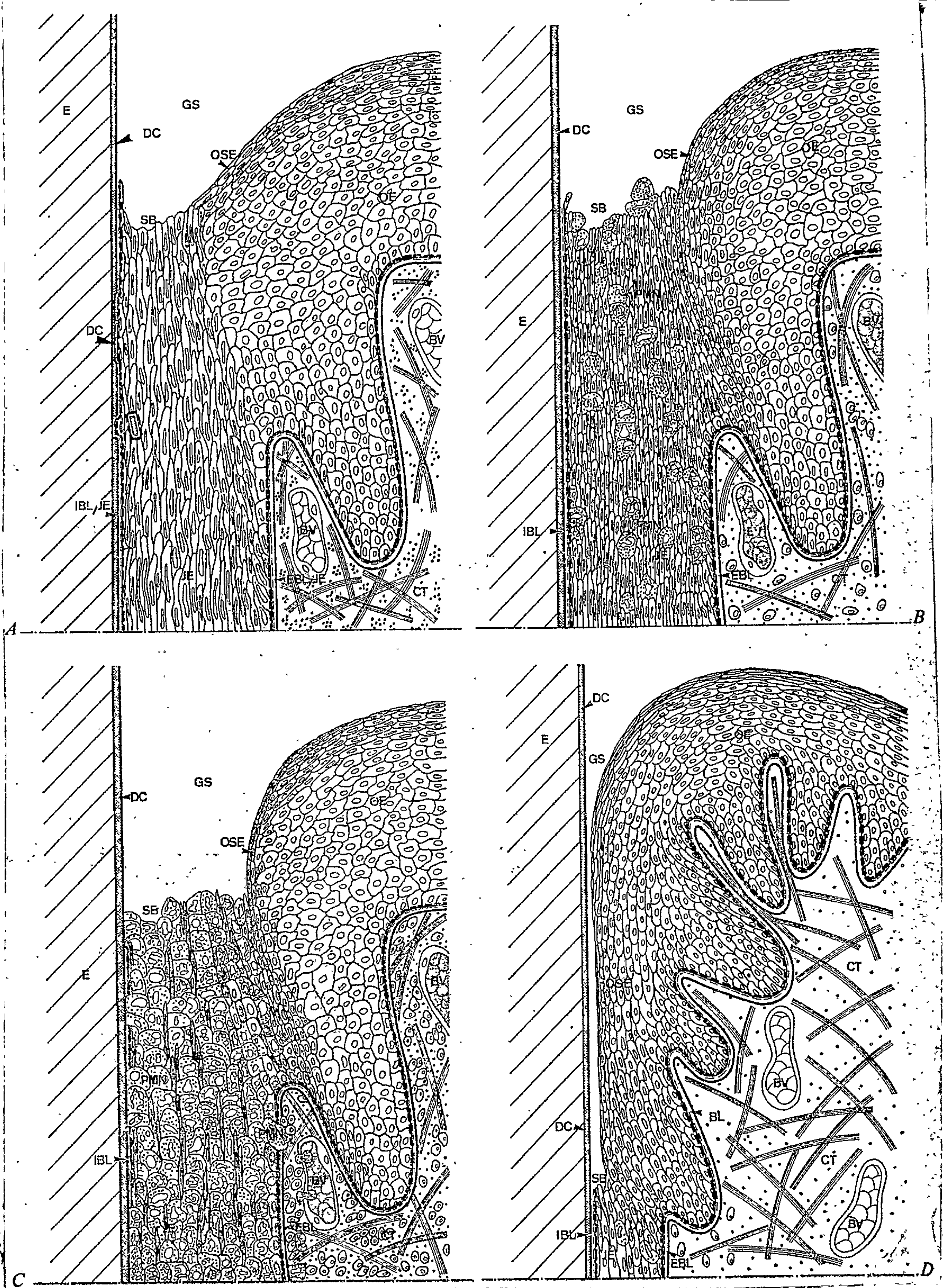


Illustration from H.E. Schroeder and M.A. Listgarten's monograph, "Fine Structure of the Developing Epithelial Attachment of Human Teeth". Basel, S. Karger 1971.

junctional epithelial tissue, the junctional epithelial cells become separated from one another and the tooth surface by the leucocytes. The demarcation between junctional and oral sulcular epithelium becomes more distinct (fig.36B). Should the relative volume of leucocytes increase to approximately 60% or more of the junctional epithelial tissue, many junctional epithelial cells become flattened and detached from one another and from the tooth surface. At this stage the oral sulcular epithelial border in contact with the junctional epithelium may assume the cytological appearance of an epithelial surface with packed squamous cells adjacent to the altered junctional epithelium (fig.36(C)). The most coronal cells of the junctional epithelium may gradually be lost so that the sulcus bottom shifts apically and the oral sulcular epithelium occupies a gradually increasing portion of the sulcular lining. Should the inflammatory reaction subside the number of polymorphonuclear leucocytes in the junctional epithelium will decrease and the sulcus bottom will become established at a more apical level, the oral sulcular epithelium providing most of the sulcular lining (fig. 36D). The surface cells of the oral sulcular epithelium, although closely approaching the tooth surface, do not have cytological characteristics

which seem compatible with the ability to reestablish an epithelial attachment."

The apical migration of the bottom of the sulcus may expose the non-mineralised layer which is of unknown origin and <sup>64</sup>generally found between the internal basement lamina and the tooth surface (dental cuticle), to the oral environment and the possibility of encroachment by micro-organisms.

CHAPTER 4.

It is generally accepted that accumulation of bacterial plaque in proximity to the gingival margin produces inflammation. Although periodontitis does not necessarily always follow chronic gingival inflammation it is preceded by it. Consequently the prime object of periodontal treatment is to eliminate from the dentition and its supporting structures any feature which encourages the collection of plaque or its retention.

The correlation between oral hygiene and periodontal disorder has always been obvious to clinicians, and epidemiological surveys have shown that the two most dominant factors relating to periodontal disease are age and oral hygiene.<sup>99</sup> The important relationship of age to periodontal disease may not necessarily mean that old people are less resistant to periodontal disease than the young, but rather that periodontal disease is a cumulative process and that there is a linear increase with age.<sup>137</sup> This leaves oral hygiene, or rather the lack of its effective maintenance, as the prime aetiological factor.

A significant confirmation of this correlation was made in 1965 by Loe<sup>69</sup> and his colleagues. A group of 12 healthy young adults with clinically normal gingivae, having stopped all oral hygiene procedures, rapidly accumulated debris on their teeth. Plaque formation began

shortly after tooth brushing stopped and increased steadily throughout the experiment.

It is noteworthy that the diet of the participants in the experiment was described as a "Standard Scandinavian diet which includes coarse bread and ample amounts of fresh fruit" which "would appear to indicate that the concept of self-cleansing with this type of diet is highly questionable".

They all developed gingivitis within 10 to 20 days. When oral hygiene was re-introduced and the plaque removed, the inflammation disappeared and the tissue returned to normal.

In a subsequent experiment<sup>124</sup> of a similar nature with 11 healthy young adults "with previously excellent oral hygiene and healthy gingivae" the same result was achieved in from 9 to 21 days. Those that took the longest to develop gingivitis accumulated plaque at a lower rate, and variations in the time required for the gingivae to return to normal were related to variations in the time taken to remove the plaque.

Plaque accumulation was not significantly different in the mandible and maxilla, but interproximal areas consistently showed the highest Plaque and Gingival Index scores. The oral surfaces with the exception of the mandibular molars had the lowest scores and the incisors showed the greatest variation in plaque accumulation, with heavy interproximal deposits but considerably less on the oral surfaces.

It could be said that the gingivitis which occurred in these experiments was the result of lack of physical stimulation, but subsequent experiments with chlorhexidene have proven this not to be true. The formation of plaque and gingivitis is inhibited by the use of 0.2% chlorhexidene gluconate mouth rinses twice a day, without the need for mechanical cleansing<sup>67</sup>.

In another experiment two large groups, one experimental and the other a control were matched on a basis of periodontal and oral hygiene status, past caries experience, age and sex. The experimental group's oral hygiene was maintained at a high level by frequent prophylaxes, oral hygiene instruction and dental health education, whilst the control group received only annual examinations and initial prophylaxis, and carried out their usual care and professional treatment. After three years, the mean gingival inflammation scores of the control group were greater than in the matching experi-

mental group and there was a loss of gingival attachment three and a half times greater than in the experimental group.

It was concluded that people "instructed in good oral hygiene practices and given frequent oral prophylaxes, have cleaner teeth, less gingival inflammation and a slower rate of apical migration of the epithelial attachment than persons not receiving these benefits," and that although "it may not be reasonable to maintain absolute oral cleanliness ...." even reasonably good levels of oral hygiene may minimise the rate of progression of periodontal disease, thus allowing an individual to maintain a functional dentition for all or most of his <sup>121</sup> life."

Good oral hygiene means effective plaque control. Shortly after a tooth is polished and exposed to saliva a salivary coating or pellicle starts to form on it. The nature of its formation is not clear, but it is thought to be derived from salivary protein with some bacterial protein content. <sup>64</sup> Bacterial colonisation of the pellicle takes place in the cervical area of the tooth and, if not dislodged, it continues to grow by multiplication and retention of new organisms and may become quite thick on the gingival margins and interdentially. <sup>67</sup> The thicker it becomes on the gingival margin the further it <sup>55</sup> extends towards the occlusal surface.

This "soft non-mineralised bacterial deposit"<sup>66</sup> is plaque. It forms not only on teeth, but also on artificial surfaces<sup>138,144,114,54</sup> in the mouth and produces gingivitis.

As plaque accumulates and matures significant changes in the microflora which apparently are related to the plaque's age rather than its quantity,<sup>69,124,30</sup> take place.

After 2-4 days there is a proliferation of fusiform and filamentous bacteria in addition to the normally present gram positive cocci and rods and the gram negative cocci and rods which appear during the first two days. Subsequently spirilla and spirochetes join what is now becoming a complex flora.

If bacterial plaque is not completely removed every 48 hours, gingivitis will develop.<sup>55</sup> So, morphological features which act as niduses for plaque retention in proximity to the gingiva or which are difficult to clean, are potential threats to the maintenance of a healthy periodontium. Similarly, restorations in proximity to the gingiva which, by their shape, location or physical characteristics encourage the retention of plaque or make its removal difficult, if not impossible, are threats to the maintenance of a healthy periodontium.

For example, composite resin, which is commonly used for cervical restorations, has been shown to accumulate bacterial plaque more quickly than tooth enamel and other restorative materials. It has been suggested by Weitman

and Eames (1975)<sup>144</sup> that the surface characteristics of composite resin prevent it being properly finished and it has been shown that in 24 hours the amount of plaque, measured planimetrically, on gingival composite restorations required 72 hours to form on adjacent teeth which were unrestored or restored with amalgam, gold foil, full cast crowns or porcelain fused to gold.

Larato (1972)<sup>58</sup> found that after two months, 24 of 37 patients, who practised good oral hygiene, but had composite resin restorations extended slightly into the gingival sulcus, had marginal gingivitis, as assessed by slight reddening of the gingival margin, oedema and bleeding from the sulcus on gentle probing. The homologous teeth, in almost all cases showed little or no plaque accumulation. Twentytwo subjects with restorations placed above the gingival margin, after staining, showed surface plaque, but the enamel between the margin and the gingiva in almost all cases was plaque-free and there was no adjacent gingivitis.

In view of its plaque accumulating characteristics composite resin is likely, if used in restorations with sub-gingival margins, to cause gingivitis even in patients who maintain good oral hygiene, and therefore it is not a suitable material for use in such locations.

CHAPTER 5.

Although there are dangers to the periodontium inherent in operative procedures, with thought, care and skill, the risks to the supporting tissues, provided they are healthy to begin with, should be minimal. To prepare teeth for restoration, when they are supported by unhealthy inflamed tissues, is to court failure. The physical difficulties of preparation and impression-taking whilst trying to control haemorrhage are, in themselves, a strong deterrent. But the doubtful accuracy of the procedures undertaken, and the unpredictability of tissue form after the completion of the operative procedures, should discourage any attempt at restorative dentistry prior to attaining periodontal health.

It would be unusual to find a patient who, on initial examination, did not require some scaling and cleaning in order to obtain a healthy gingival sulcus, particularly interdentally. Plaque which forms in the sulcus, sooner or later becomes mineralised and forms calculus, on top of which there is a non-mineralised layer. This layer consists mainly of bacteria, and their presence in intimate relationship to the junctional epithelium maintains inflammation and possible apical retreat of the attachment. If there are subgingival deposits on a tooth to be restored the first requirement is to remove them.

Although, as has been previously discussed, the sub-gingival extension of restoration margins is undesirable, there are undoubtedly times when it may be considered necessary. Mount (1970)<sup>77</sup> considers that the placing of the labial gingival margins of anterior jacket crown preparations 0.5 to 1mm within the gingival sulcus results in an aesthetically better restoration, but the closer the margin of the crown is to the base of the sulcus the greater is the risk of severe inflammation.<sup>78</sup>

Extensive caries or loss of tooth structure necessitates a large preparation in order to finish the margins on sound tooth structure and a short clinical crown may require apical extension of the margins in order to ensure retention.

The oral epithelium is susceptible to damage and the epithelium lining the sulcus, being non-keratinised, is even more liable to injury. Due care must be exercised when using stones, burs, discs, rubber cups, hand instruments, etc., in order to avoid damage. However a healthy gingival sulcus will recover from inadvertent mechanical injury caused during the preparation and insertion of restorations and the junctional epithelium will re-attach in 7-14 days.<sup>65, 123</sup>

Damage to the sulcus which extends below the cemento-enamel junction may result in a loss of connective tissue attachment and the cementum becoming covered by epithelium with a subsequent loss of periodontal support.<sup>89,90</sup> This apical retreat of the epithelial attachment generally results in permanent gingival recession, or pocket formation with alveolar bone loss.<sup>143</sup> It may be of even greater significance in sub-gingival preparations on teeth with bony dehiscences. In their case the absence of bony support beneath the facial gingiva may result in a weaker union between the gingiva and the teeth, which in turn may lead to marked recession of the gingival margin if the gingival fibres are damaged during preparations. Although its causation is uncertain, there is strong support for the view that the presence of dehiscences may have a large bearing on gingival recession.<sup>36,39.</sup>

The periodontal ligament is able to withstand strong forces for short times but if excessive force is applied haemorrhage, thrombosis, necrosis of periodontal fibres, and cemental tears may occur. These will normally resolve and only present a risk if infection is superimposed. However severe discomfort can be experienced by the patient. It is prudent not to use mechanical separators to obtain excessive separation of teeth, nor to use excessive or misdirected forces when seating crowns,

inlays or bridges or when malleting gold foil restorations in order to avoid damage to the cementum and periodontal ligament.

The use of retraction cord is necessary for an accurate impression of the gingival floor of preparations. It generally damages the gingival sulcus<sup>41</sup>, but if used with care in healthy circumstances, healing will take place in 6-10 days and the damage may be considered temporary. Care should be taken when placing retraction cord, that it is not pushed too far apically. In an experiment with dogs it was found by Loe and Silness (1963)<sup>68</sup> that with what was considered to be the normal force used clinically the cords often finished below the cemento enamel junction, causing unnecessary damage to the upper Sharpey's fibres.

Untreated cord is safe for from 5 to 30 minutes and can be used when there is no seepage or with 1:1000 epinephrine to control seepage or bleeding. Alum or 8% epinephrine can be used when heavy bleeding or seepage must be controlled but only for 5-10 minutes. Zinc chloride should not be used. It causes severe damage to the sulcular epithelium<sup>41</sup>.

It has been shown by Anneroth & Nordenram (1969) that the removal of dry thread from the gingival sulcus removes epithelial cells as well. This could explain why "the gingival tissue often begins to bleed a few seconds after the threads have been removed just at the critical time of the operating procedure when the operator injects the fluid component of the impression material in the crevicular area". When the thread was sprayed before removal, epithelial cells were not removed so it was recommended that the gingival sulcus be sprayed thoroughly before inserting the thread and before removing it and the area dried before taking the impression.

Electro-surgical techniques have been advocated for "troughing" the gingival sulcus in order to obtain more accurate impressions. <sup>73,81,105</sup> Control of all the variables in electro-surgical techniques, that is the proper current depth of incision, time in contact with the tissue, type of electrode and thickness of tissue appears to be very difficult and tissue necrosis is too frequently reported. <sup>113,79</sup> Retarded healing as a result of tissue necrosis makes plaque removal difficult and causes increased inflammation and there is often damage to underlying connective tissue. The possibility of harmful contact between the cementum and the electrode in adult patients poses a considerable risk of permanent periodontal damage. <sup>149</sup>

Reports have been made of rubber based impression material being forced into the periodontal tissues following electro-surgical preparation for impressions. A possibility suggested by O'Leary et al. (1973<sup>80</sup>) was that the surgical current may have caused retraction or necrosis of blood vessels emerging from bone and that subsequently the injection of impression material into the sulcus and the seating of the impression "may have forced the material into the bony channels where the vessels had been altered".

Price & Whitehead (1972) reported severe inflammatory responses to rubber based impression material forced into the tissues without prior use of electro-surgery.<sup>85</sup> In three cases the impression material was sub-periosteal, one between mucosa and periosteum and one inside the interdental septum. Inadvertent damage with an instrument either whilst preparing the tooth or placing the gingival retraction cord was thought to be the most likely cause of providing access to the tissues. The reaction in these cases showed polysulphide impression material to be a strong tissue irritant and one should be aware of the possibility of its being forced where it is not desired or required.

Having prepared a tooth without damaging the oral sulcular epithelium, resisted the temptation to trough

the sulcus electrosurgically, placed and removed retraction cord without damaging the junctional epithelium and taken an impression without forcing impression material into the interdental septum, one is beholden to ensure that the temporary restoration that is to be placed does not undo the good work.

The margins of temporary restorations should not extend beyond the preparation and should be well adapted. The restoration should not be over-contoured and impinge on the gingival tissues, should be polished and accessible for plaque control and should be in occlusion. If it is not in occlusion, over-eruption may occur and the subsequent restoration when inserted will require occlusal adjustment which will mean destruction of anatomic features which should have been incorporated in it during manufacture.

It would also appear that in the case of full coverage crowns, the sooner that the permanent restoration is inserted the less likelihood there is of gingival recession which has been shown to be promoted by temporary crown restorations<sup>32</sup>.

As added protection for the gingival margin it has been suggested that a protective surgical pack be applied to prevent inflammation, inhibit soft tissue proliferation and protect sensitive roots.<sup>96</sup> Another

suggestion is that the temporary restoration be finished short of the margin and cemented with a periodontal pack<sup>77</sup> cement. These measures, although no doubt effective, should not be necessary if a well constructed temporary restoration is inserted, and care taken to ensure that all traces of the temporary cement and impression material are removed from the gingival sulcus.

CHAPTER 6

The danger of permanent periodontal damage during or as a result of operative procedures is not great if care, knowledge and skill are used. Most iatrogenic periodontal disease associated with operative dentistry is caused by finished restorations and may be influenced by the following characteristics:

- i) contour,
- ii) proximal contact and marginal ridges,
- iii) occlusion,
- iv) adaptation and position of margins,
- v) possible inherent irritation of restorative materials,
- vi) surface finish.

These features can affect the retention of bacterial plaque and if they are not understood and controlled by the dentist periodontal disease may result.

Plaque initially accumulates on a tooth in the region of the gingival sulcus, with the greatest amount being formed interproximally.<sup>124,107</sup> Restorations should help to promote periodontal health by not increasing the retention of plaque in these areas, but, unfortunately, surveys have shown that this is not the case. Teeth with restorations in contact with the gingiva, generally have more gingivitis than unrestored teeth,<sup>47</sup> particularly if the restorations have marginal defects.<sup>37,2,126,51</sup>

CONTOUR:

The contour of a restoration is important in combating plaque formation and retention. For many years it was thought that the facial and lingual surfaces of restorations should be shaped with a supra-gingival bulge to protect the gingiva from food impaction. By deflecting food away from the sulcus and on to the attached gingiva, its keratinisation was thought to be enhanced<sup>146</sup> by physical stimulation. It has been shown that there is very little massage given to the gingiva by chewing other than on the lingual of maxillary teeth<sup>148</sup>. In any case, gingival inflammation begins in the gingival sulcus, which is not keratinised, and it is doubtful if the degree of keratinisation of the oral aspect of the gingiva is significant in its protection<sup>71</sup>.

In attempting to follow this protective but stimulating philosophy there has been a tendency to over-contour restorations and create shapes that are not seen in nature<sup>44</sup>, and which, rather than protect the gingiva, create areas which are difficult to clean.

The need for any bulge in crown form has been subjected to doubt by Perel's (1971) experiment in which axial tooth surfaces were undercontoured by grinding and overcontoured by the addition, to the facial surfaces, of self-curing resin. No significant changes were

produced by the undercontouring, but inflammatory and hyperplastic changes were observed both clinically and microscopically in the overcontoured areas. This was in accord with clinical observations which had shown that narrow, undercontoured crowns were conducive to gingival health, and also supported the concept of flattening the facial and lingual contours of restorations to make the cervical regions of teeth more accessible for cleaning.

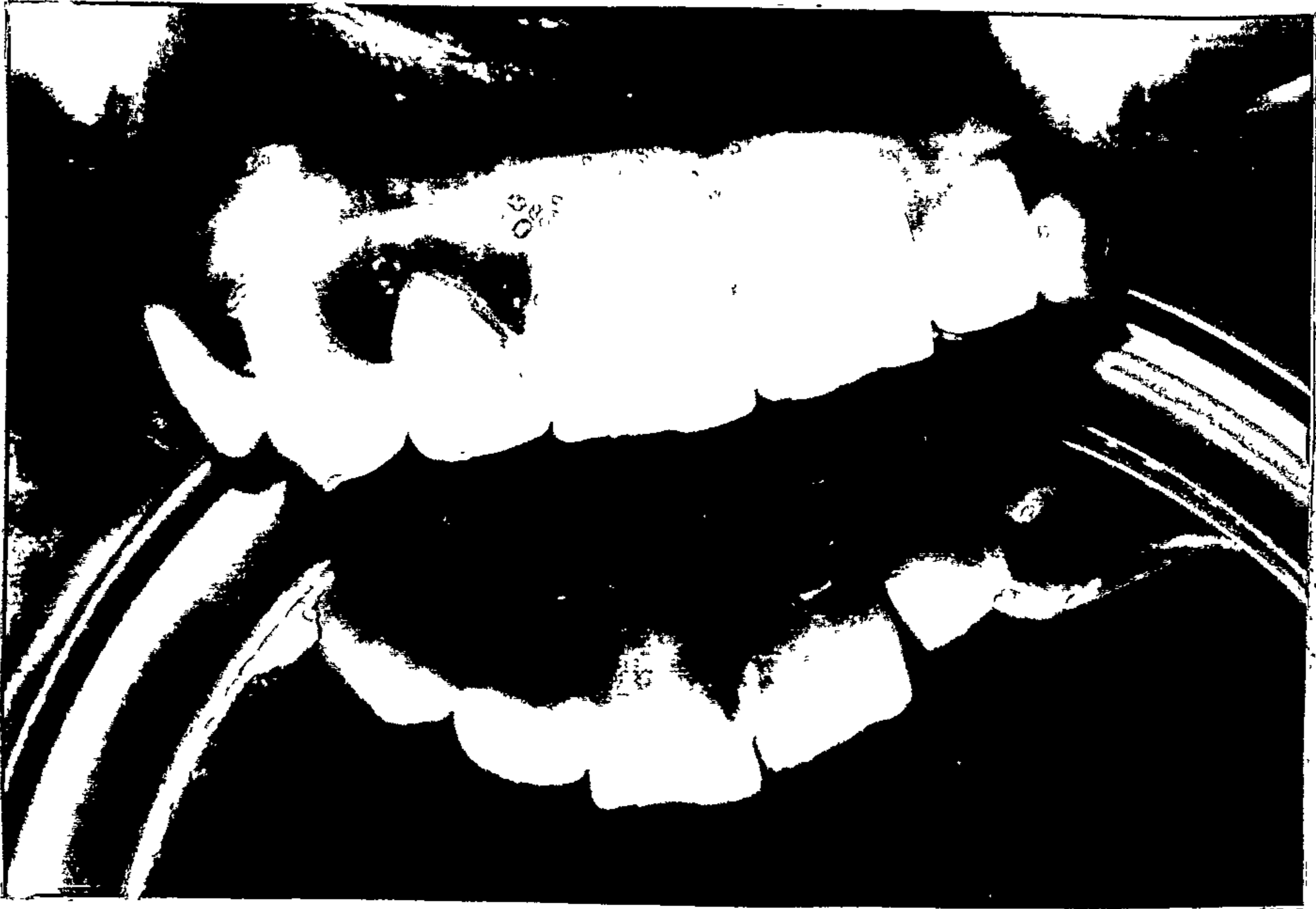Because the mandibular posterior teeth are lingually inclined, there is little if any protection provided by the slight bulge on their facial surfaces, but the height of the convexity on their lingual surfaces is raised. Yet, although the facial gingiva of lower molars seem no more subject to mechanical damage than that of other teeth, the lingual surfaces retain more plaque than any other lingual surfaces.

This fact supports the contention that "plaque build-up begins in, and its retention is greatest in the cervical region of the tooth, gingival to the height of contour". The more accentuated the contour the more plaque is retained. The area occlusal to the height of contour is more easily cleaned than that gingival to the height of contour and patients, even if instructed in the correct use of a toothbrush and other aids, are more

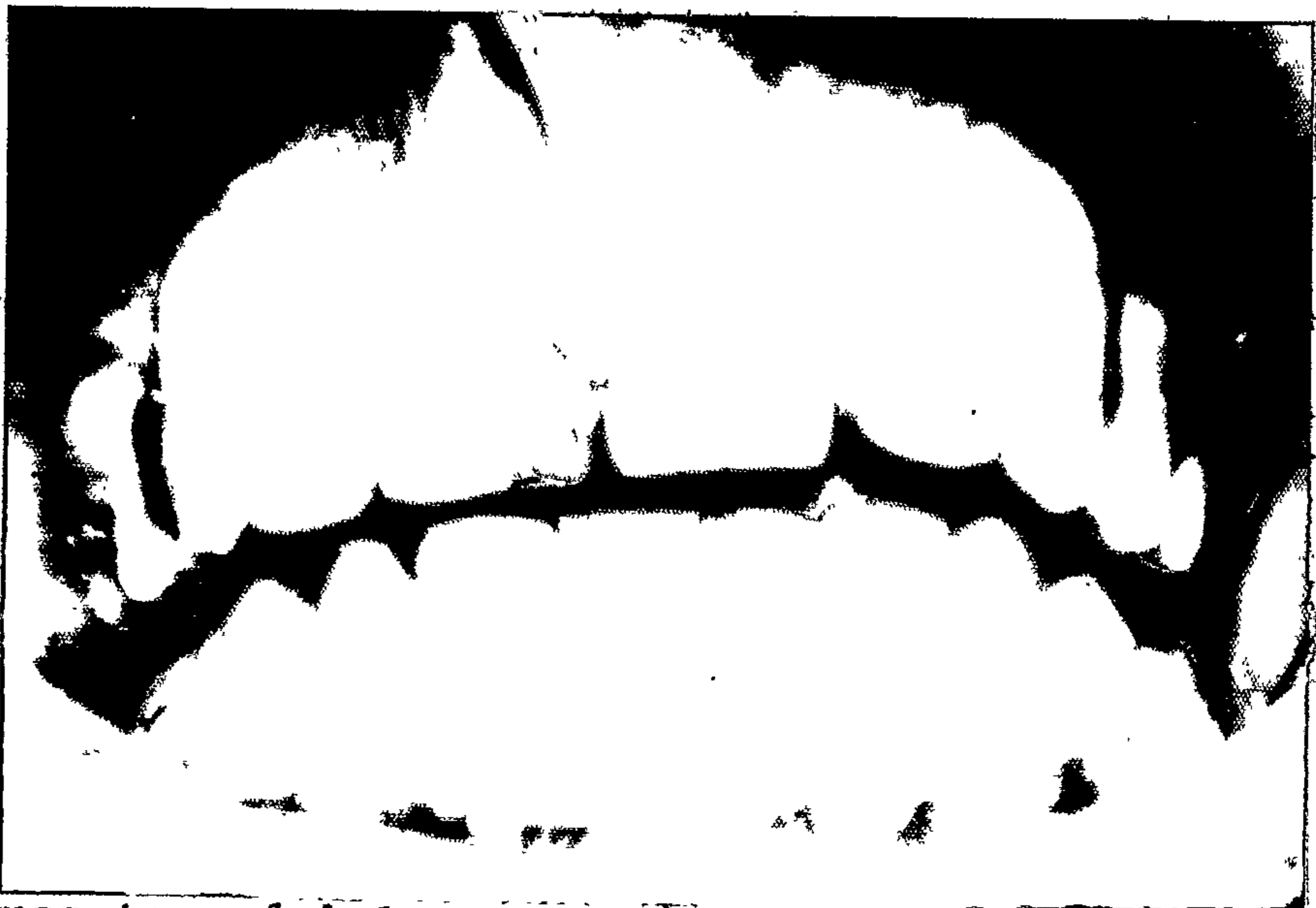likely to miss removing plaque if the supra-gingival bulge is large.

Although the facial and oral contours of restorations are often accentuated with the intention of protecting the gingiva, overcontouring at the facial and lingual line angles, particularly on the facial side, is generally done inadvertently. Full coverage preparations are frequently insufficiently prepared at facio-proximal line angles and the restorations overcontoured in order to gain sufficient strength, or the correct shade, in the material being used.<sup>143,44</sup> Other restorations are insufficiently carved in the laboratory or in the mouth. An overcontoured line angle as well as being poor aesthetically encourages plaque retention and impinges on the interdental papilla.

Care should be taken that restorations do not encroach on the space normally occupied by the interdental papilla. Overcontouring of proximal restorations may accentuate the "col" area, increasing its susceptibility to plaque retention, and enlarging the buccal and lingual papillae.<sup>89</sup> In the anterior region the interdental anatomy may be changed by overcontoured restorations and a "col" created. Plaque then becomes more difficult to remove and the papillae become inflamed. Proximal contours should follow normal embrasure outline and particular care should be taken that restorations are waisted



Composite resin mesial UR3 and distal UR1, porcelain crown UR2. Overcontoured linguo-distal line angle UR1, filling embrasure. Marked gingivitis labially and lingually with lingual gingival recession.



Overcontoured inlay UR1, displacing the interdental papilla.

in the gingival half.

PROXIMAL CONTACT:

Consideration of the embrasure space naturally involves the placing of the contact point, which forms the top of the space, and protects the interproximal gingiva from injury during mastication. The contact points normally represent the greatest mesio-distal dimension of the tooth. They are located close to the occlusal surface and in or towards the facial third of the proximal surfaces.<sup>34</sup> The further the contact point is placed from the occlusal plane the greater is the likelihood of food impaction.<sup>46</sup>

With age, contacts become worn and change to contact areas and eventually develop narrow facial and lingual embrasures, which tend to retain debris. Normally the interseptal tissues adapt to interproximal wear, but if it causes encroachment of the interdental papilla, a similar result to that caused by an overcontoured restoration may occur. The placing of a restoration with a reduced and correctly positioned contact will generally resolve the problem.<sup>34</sup>

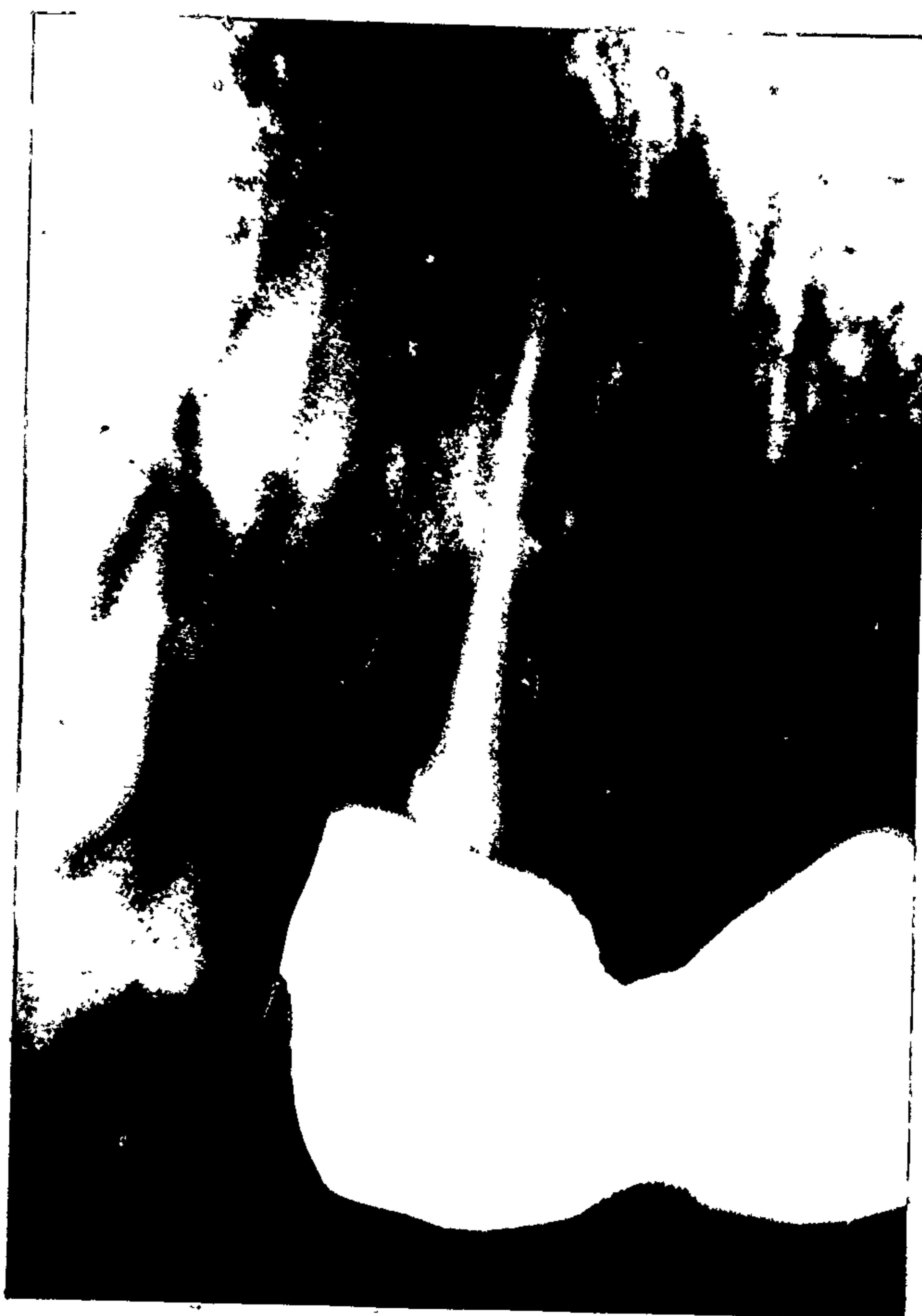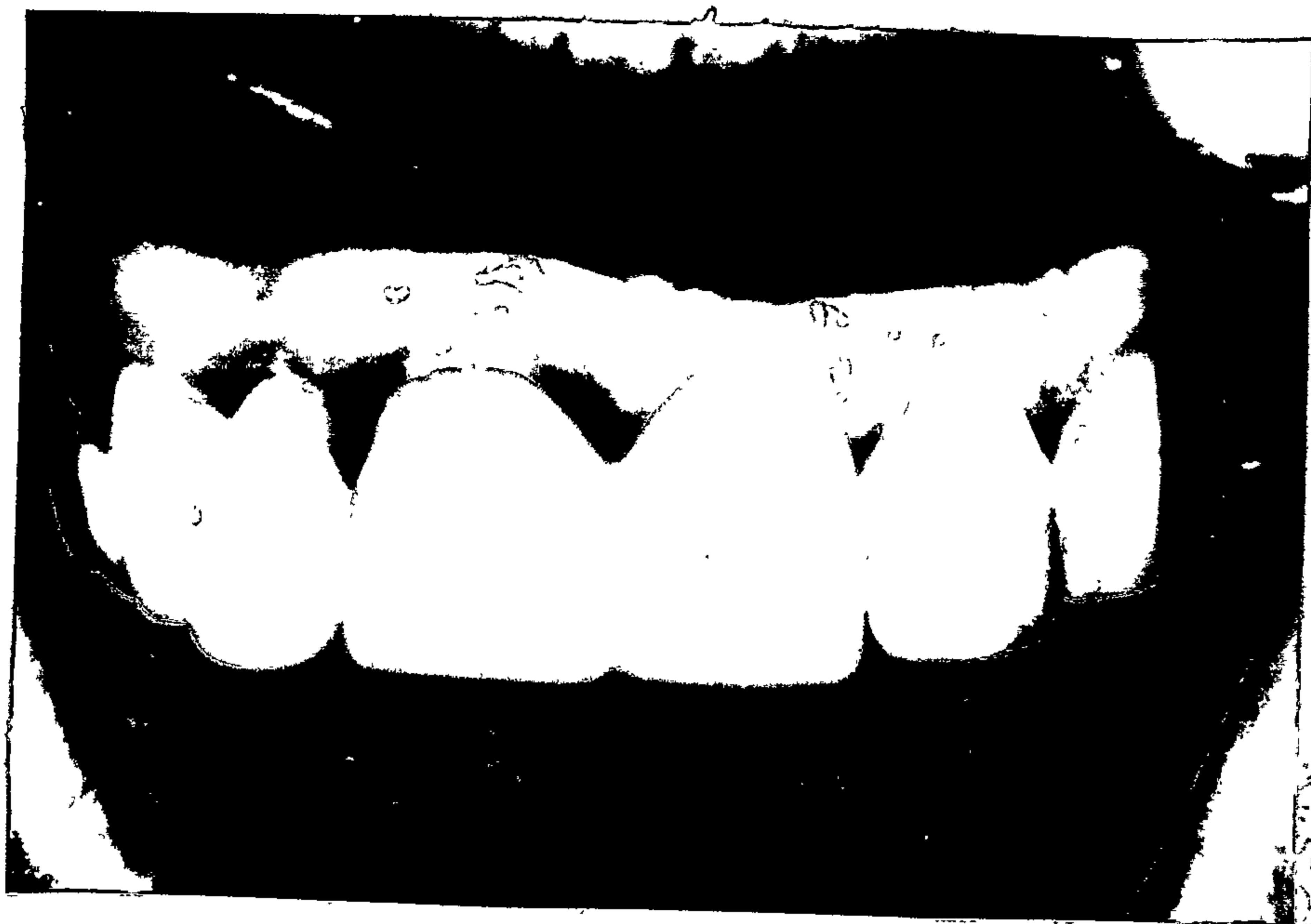
As teeth are wider on the facial side than the lingual side, the proximal surfaces converge towards the lingual. With the contact point placed in the facial third of the proximal surface, a larger embrasure is

formed on the lingual side than on the facial side when viewed from the occlusal. Restored marginal ridges should converge towards the lingual to maintain the natural embrasure shape which assists in shedding rather than retaining food particles. Adjacent marginal ridges should be of equal height to prevent food being funnelled interproximally and impacted.

46

Hirschfeld states in what is regarded by many as his classic paper on food impaction that the principle factors which act to prevent it are "(a) contiguity of the arch (b) proper location of the points of contact and (c) the presence of the marginal ridge and groove", and that improperly constructed restorations are one of the aetiological factors in the food impaction mechanism. Restorations may have lost contact during the finishing process, or contacts may be improperly placed. Occlusal contour may not have been given a marginal ridge in correct relationship to its adjacent tooth, may be steeply inclined mesiodistally leading to a wedgelike action forcing food interproximally or may be built up too much causing a buccolingual leverage during mastication and temporary opening of contacts.

Silicate restorations have a tendency to wash out and are a frequent site of food retention, particularly if they are used to establish contact points. They may



VMK cantilever bridge replacing UL1. UR1 has II mobility and radiograph shows signs of traumatic occlusion.

wear rapidly and the contact close. Large silicate and composite resin restorations, involving contact points, if adapted too tightly by a matrix strip, may be flattened and the contact lost.

The eventual tipping of a badly designed cantilever bridge also may create a food impaction problem. Before making a cantilever bridge careful assessment of the number of abutments and type of retainers to be used must be made to avoid displacement of the retainers or periodontal damage. The intended load must be correlated with the available support and patients subject to bruxism or habitual teeth clenching must be regarded as unsuitable. "There is the constant risk of creating in effect an orthodontic appliance, resulting in tilting or rotation of the abutment support or in periodontal damage, bone resorption and loosening of the supporting tooth or teeth."

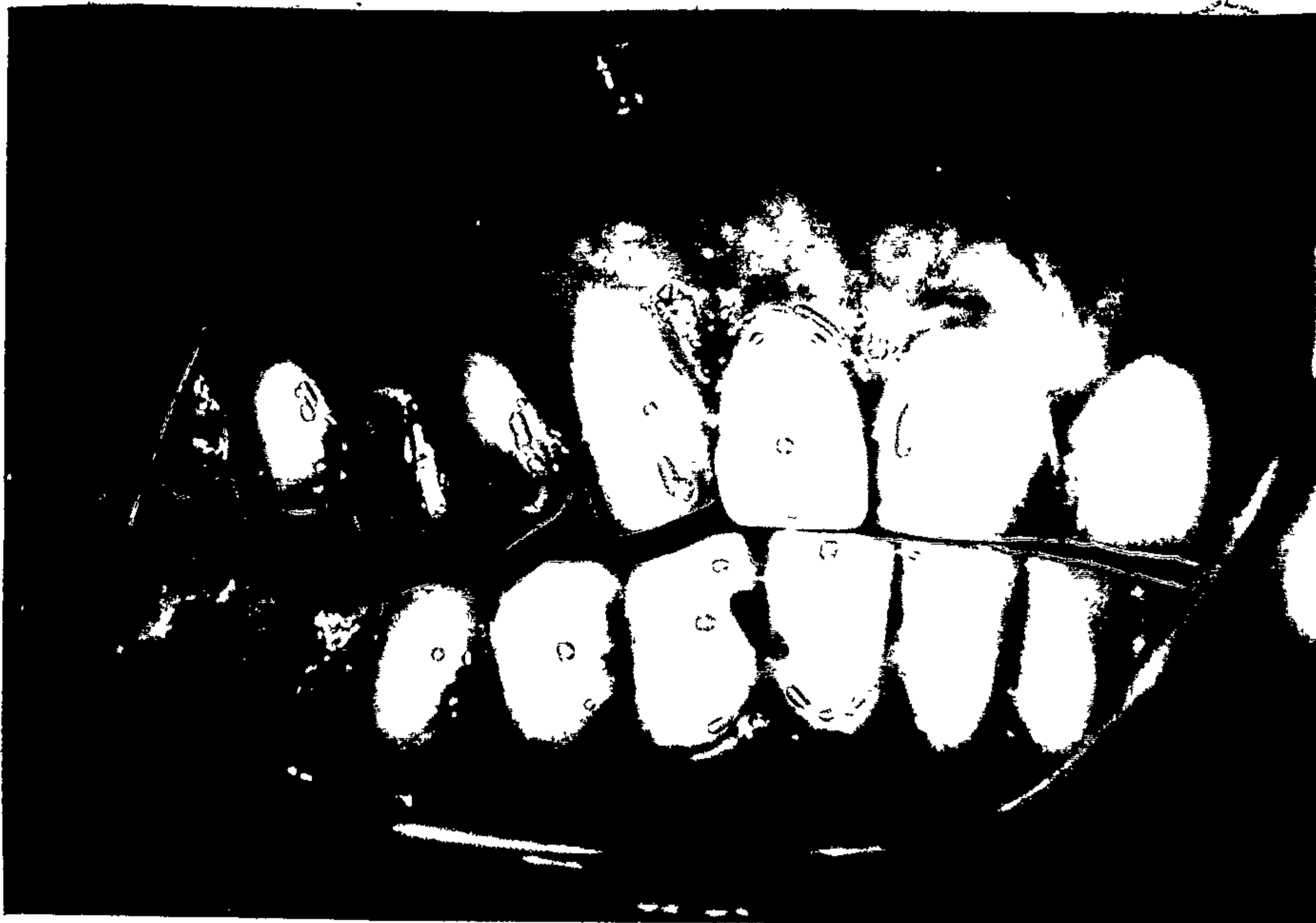Food impaction causes discomfort from a feeling of pressure between teeth, gingival inflammation from trauma, plaque retention and, it would be reasonable to assume, periodontal damage either from the repeated assault on the periodontium by the impacted food or plaque formation on retained food. It has been suggested that vertical bone loss and intrabony pockets are a result of food impaction, but in a survey of 121 skulls with 206 interproximal intrabony lesions Larato (1971) found that

Only 38 (18%) were associated with factors which were considered able to cause food impaction.<sup>57</sup>

Although a correlation between food impaction and intrabony pockets has not been demonstrated, interproximal areas having deficient or open contacts have been shown to have a greater mean pocket depth than areas with, what were considered to be, normal contacts.<sup>120</sup>

Despite Emslie's (1973) statement that "it is even possible that the trained periodontal patient will benefit by being regularly reminded to perform his oral toilet by discomfort from the trapped food"<sup>33</sup>, food impaction must be considered to place the periodontium at risk by the repeated trauma to the interdental gingiva and the chemical and bacterial irritation associated with the degradation of retained debris.

Debris may be retained interdentally for some time, for although the tight packing of fibrous food into an embrasure causes discomfort until it is removed, unless careful oral hygiene procedures are followed using floss and interdental wooden sticks, it is likely that everything will not be removed but only enough to relieve the discomfort. Patients with "food-traps" which they wish to be eliminated are often surprised to learn that they have not removed all the impacted food, which is often found to be deeply ensconced, and maturing, between facial and lingual papillae.



Food traps mesial and distal to LR6. Radiograph shows inadequate contact and uneven marginal ridges. Note overhanging margins.

