

CHAPTER 6

6.1 INTRODUCTION

The results presented in chapters 3 and 5 showed that warfarin treatment in the rat was associated with reduced growth and calcification of the cartilaginous nasal septum. It appears that this is the cause of the reduced outgrowth of the snout. Similar reduced growth in the human embryo would cause the distinctive face seen in the warfarin embryopathy.

From a review of published cases it has been stated that the facial features of the warfarin embryopathy only occurred after warfarin exposure between 6 and 9 weeks gestation (Hall et al., 1980). This suggests that the nasal septum undergoes some critical stage of development at this period.

To obtain information on the growth and development of the nasal septum in the first trimester of pregnancy sections of human embryos were examined and photographed at the Human Developmental Anatomy Center, National Museum of Health and Medicine, Armed Forces Institute of Pathology, Washington, DC 20306. Particular attention was given to sagittal sectioned embryos to ascertain outgrowth of the face and its relationship to the nasal septum.

It has been surmised that in the human embryo there is a ligament from the anterior border of the nasal septum extending laterally to the maxillae. This ligament was called the septo-premaxillary ligament and was thought to be responsible for pulling the maxillae forward as the nasal septum grows resulting in midfacial outgrowth (Latham, 1970). In the present study-silver stained sections were examined to confirm the existence and extent of this ligament.

6.2 METHODS

Photographs and histological sections of embryos were examined from the Human Developmental Anatomy Center collection.

Embryo numbers 991, 441, 449 and 1656.

Sagittal sections from 23 embryos aged between 6 and 9 weeks were photographed with a scale and measurements of the nasal septum were recorded (Fig. 6.1).

Carnegie stage	Age in days (approx)	Embryo numbers
Stage 18	44	144, 406, 991
Stage 19	48	390, 43, 837, 1584, 1390
Stage 20	51	1134E, 6202, 8226
Stage 21	52	632
Stage 22	54	875, 1458, 464
Stage 23	57	5422, 75, 145, 449, 972
39-41mm	56-63	1686, 362, 224

Sections of silver-stained embryos were examined for the septo-premaxillary ligament.

Embryo number	Crown-rump length (mm)
5622	41.5
HH 27	45
D 24	64
D 30	78
D 55	90

Coronal sections of a 33.5mm embryo (number 1134D) were reconstructed using 3D computer reconstruction to demonstrate the continuity of the chondrocranium at the end of the embryonic period. The embryo had been cut into 50 μ sections and every third section was photographed at the same magnification and the images assembled by 'best fit' of the spinal cord and eye from subsequent images. The images were digitalised using a fixed video camera and stored on computer as individual TIFF files.

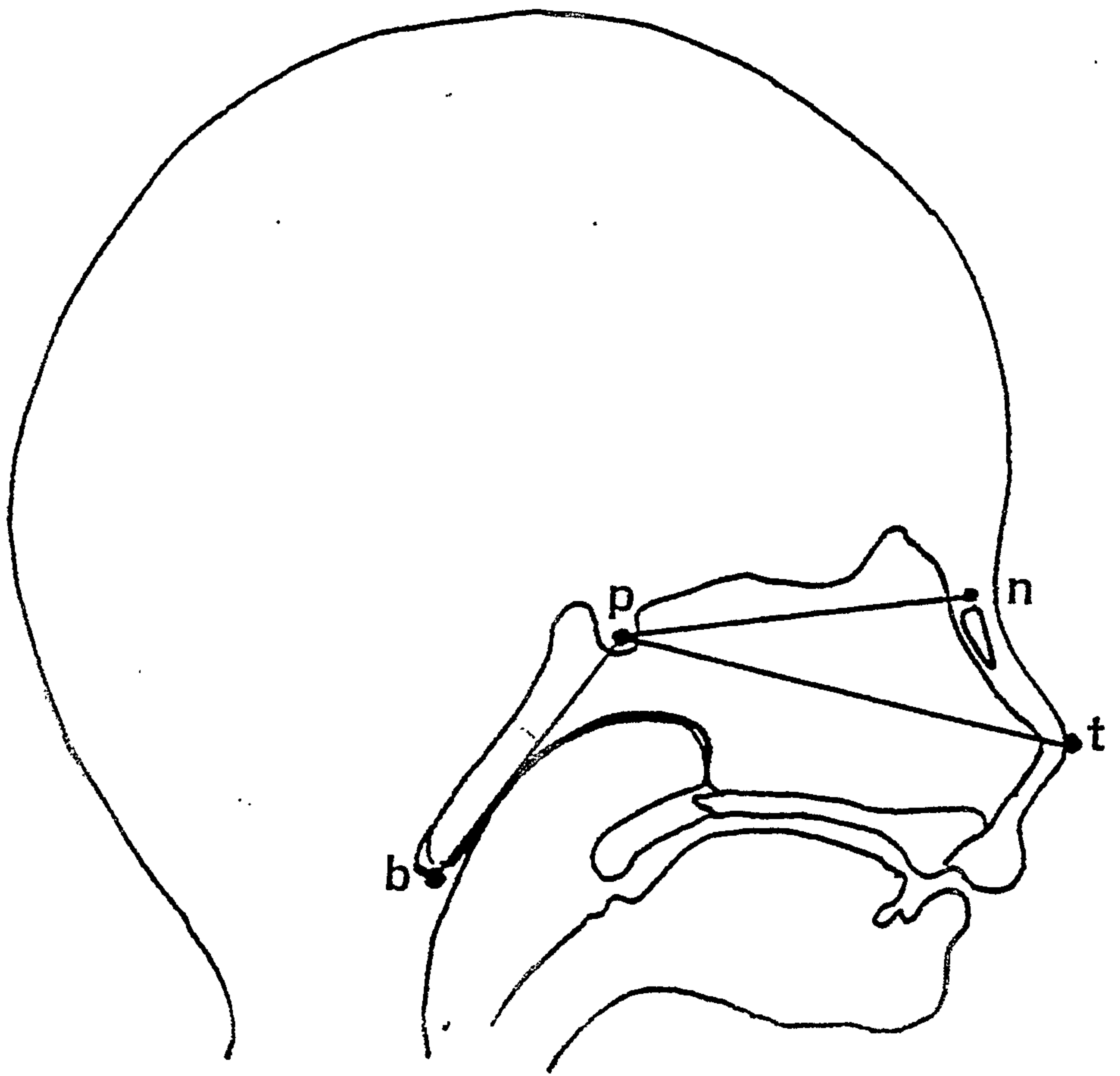
The TIFF files were converted to grey scale and the boundaries of the face, cartilage of the nasal capsule and chondrocranium, eye, spinal cord and Meckel's cartilage recorded as an individual grey scale. The 27 images were reconstructed using VoxelView (Vital images, Inc., 505 N. 4th Street, Fairfield, Iowa 52556). VoxelView is an interactive volume rendering system, which uses a compositing approach of reconstruction in which digital images are stacked in order (back to front) and then projected into a 2-dimensional picture.

Conformation of the correctness of fit was ascertained by the resulting facial profile and mid-sagittal view of the nasal septum. The individual structures were colour coded in Voxelview and the resulting 3-dimensional image recorded and printed.

Figure 6.1

Diagram showing the 4 cephalometric reference points used to obtain the measurements presented in Table 6.1

b = Basion p = Pituitary n = Nasion t = Tip of nose



6.3 RESULTS

6.3.1 Developmental of the midface in human embryos between weeks 7 and 10 of gestation.

WEEK 7

The nasal capsule can be distinguished for the first time in embryos of stage 18-19. Figure 6.2b shows a sagittal section through a stage 18 embryo. A small area of condensed mesenchyme that will become the nasal septum can be seen anterior to the developing pituitary. Mesenchyme can also be seen posterior to the pituitary and although in this section it appears discontinuous it unites with the presumptive nasal septum laterally around the stalk of the pituitary. In a coronal section from a stage 19 embryo (Fig. 6.3a) the condensed mesenchyme of the future septum can be seen. In a horizontal section from a slightly younger embryo (Fig. 6.3b) this condensed mesenchyme can be seen extending from the pituitary to the tip of the nose, and its 3-dimensional rod-like structure can be imagined.

WEEK 8

By Stage 20 (Fig. 6.4b) the midline mesenchyme has become cartilage and the nasal septal cartilage is evident in this sagittal section. The outgrowth of the septum, although not fully seen in this section, has produced a distinct "pig-like" facial profile (Fig.6.4a) in which the upper lip and nose protrude as a single snout-like process without an obvious nasal tip and the nares are everted.

In a coronal section of a stage 20 embryo (Fig. 6.5a) the condensed cartilaginous part of the septum is seen to be enclosed inferiorly by condensed mesenchyme which will form the vomer. The mesenchyme around the lateral side of the nasal cavity has not yet chondrified but shows the shape of the future capsule. The secondary palatal processes have not yet fused in the midline with the nasal septum.

In a mid-sagittal section of a stage 21 embryo (Fig. 6.5b) the full extent of the nasal septum can be seen. Note that the shape of the anterior border of the nasal septum determines the midfacial shape. The nasal septum is continuous underneath the pituitary with cartilage that extends back to

Figure 6.2

- a. Seven-week human embryo (number 991)

- b. Mid-sagittal section of the same embryo. Note the condensed mesenchyme of the future nasal septum (n) and of the future cranial base
(b). p = pituitary

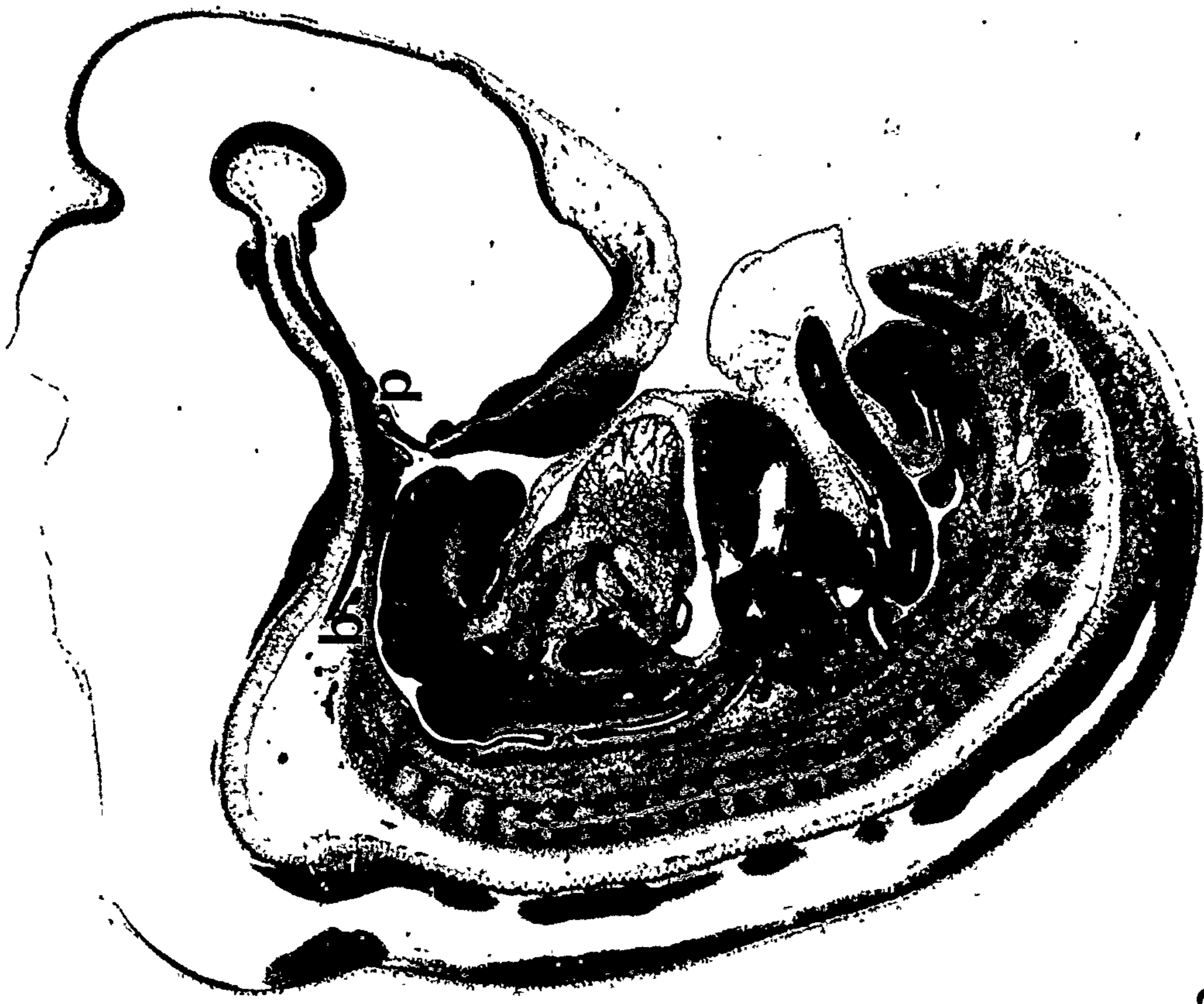
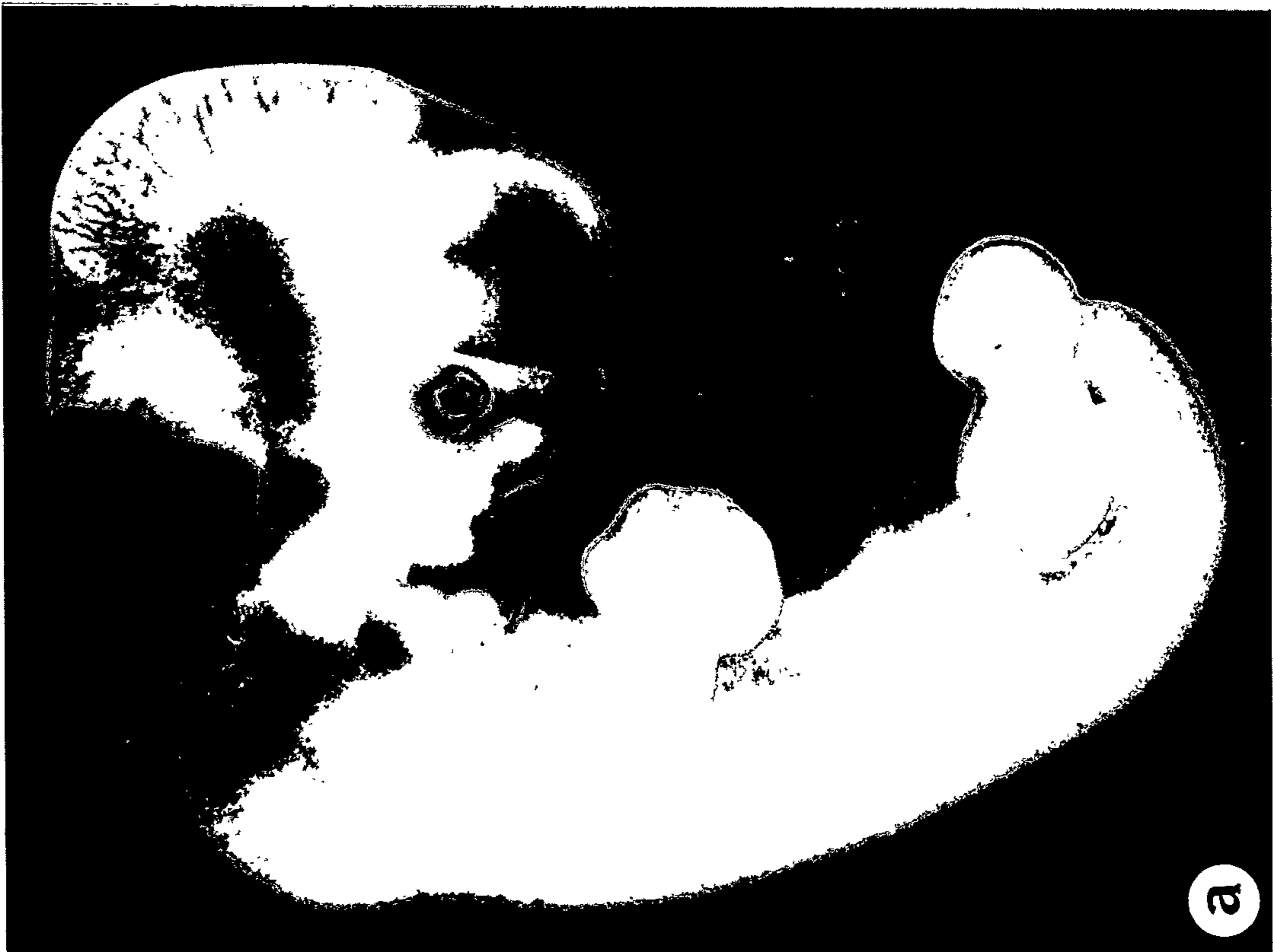

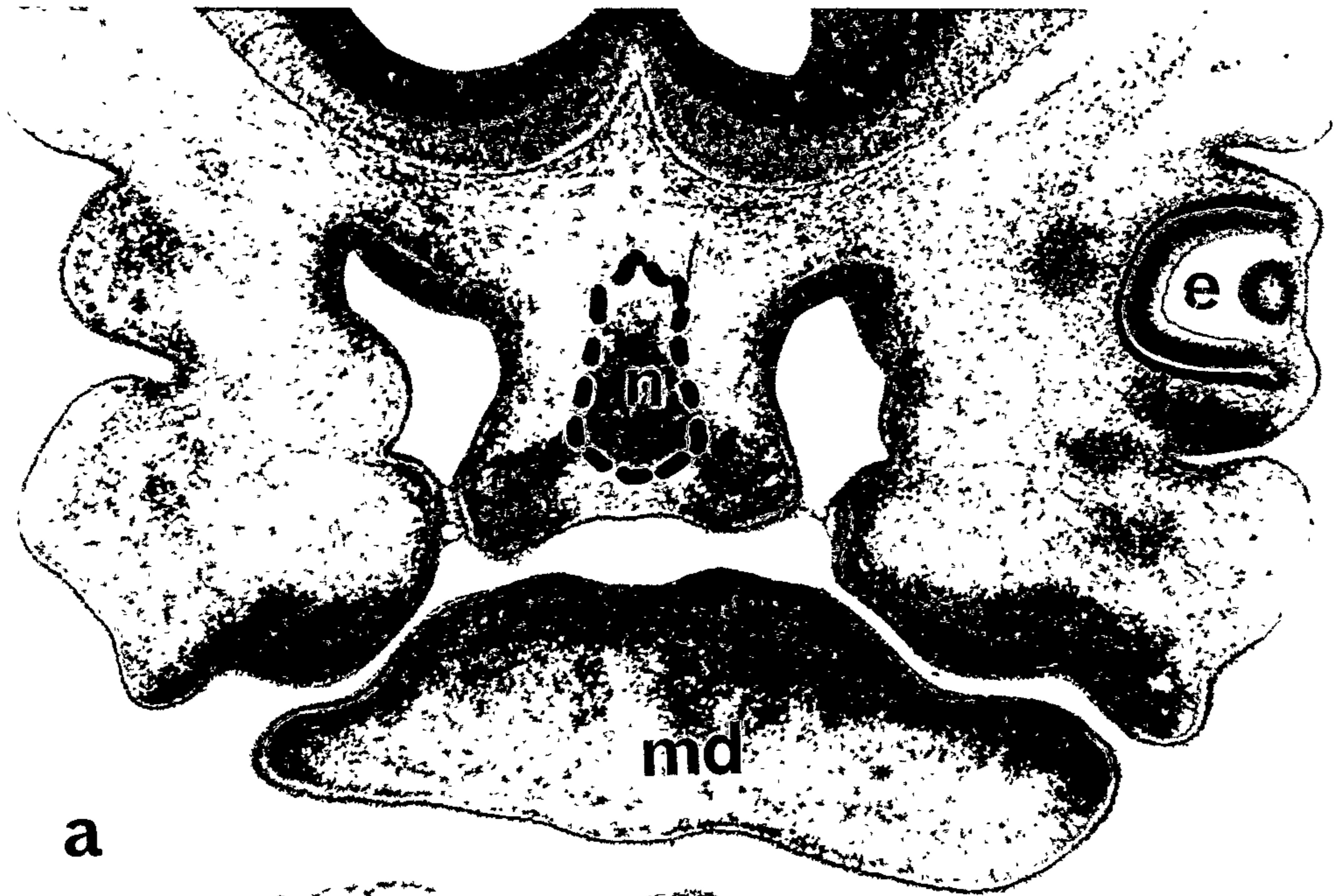
Figure 6.3

a. A coronal section of a stage 19 human embryo (number 9325). The condensed mesenchyme of future nasal septum is outlined (n).

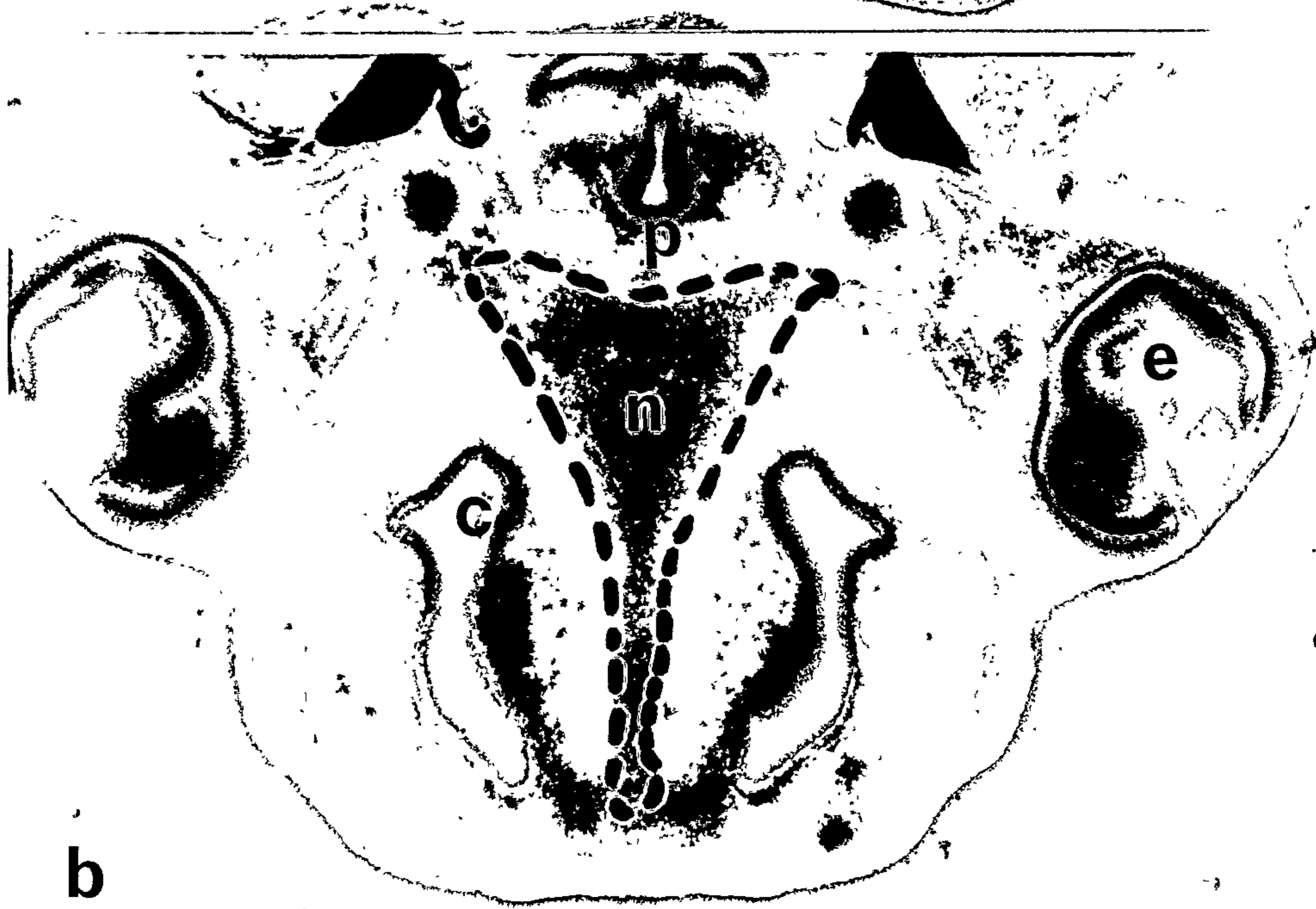md = mandible e = eye

b. A horizontal section of a stage 18 human embryo (number 492). Note the condensed mesenchyme of the future nasal septum (n).

c = nasal cavity p = pituitary e = eye



a



b

the foramen magnum. There is a distinct angle at the pituitary between the anterior and posterior cranial base. The nasal cartilage is a 3-dimensional structure shaped like a rod within the midface in continuity with the cartilage of the cranial base.

WEEK 9

By 57 days gestation (CR length 36.5mm) there has been considerable longitudinal growth of the nasal septum and this is reflected in a more recognisable human facial profile with a distinct nasal tip and the midface less retruded beneath the forehead (Fig. 6.6a). The corresponding sagittal section (Fig 6.6b) shows the anterior portion of the septum has grown considerably from that of the stage 21 (Fig 6.5b), it has a flat, straight inferior border extending from the sharp angulation around the pituitary forward into the external nose, the maxilla has moved downward and forward with this growth. The anterior shape of the septum now creates a longer external nose.

A coronal section (Fig. 6.7) from a similar-aged embryo shows the complete chondrification of the nasal capsule. The midline nasal septum is supported in the developing bony vomer and is continuous supero-laterally with the cartilage of the lateral walls of the nasal capsule. The secondary palate has closed and has fused with the inferior border of the vomer.

Twenty-seven sections of the head of a 33mm embryo (8-9 weeks gestation) were reconstructed to illustrate the continuity of the nasal septum with the rest of the cartilage of the nasal capsule and cranial base (Fig. 6.8). This underlines the strut-like nature of the nasal septum in the midface.

WEEK 10

At 70 days (Fig. 6.9a) the embryo exhibits a distinctly 'adult' facial profile. The nasal septum has not changed in general shape since 57 days but continued growth has resulted in further protrusion of the external nose (Fig 6.9 b).

Figure 6.4

a. Stage 20 human embryo (number 441).

b. Mid-sagittal section of the same embryo.

n = nasal septum p = pituitary b = cartilage of the posterior cranial
base of skull

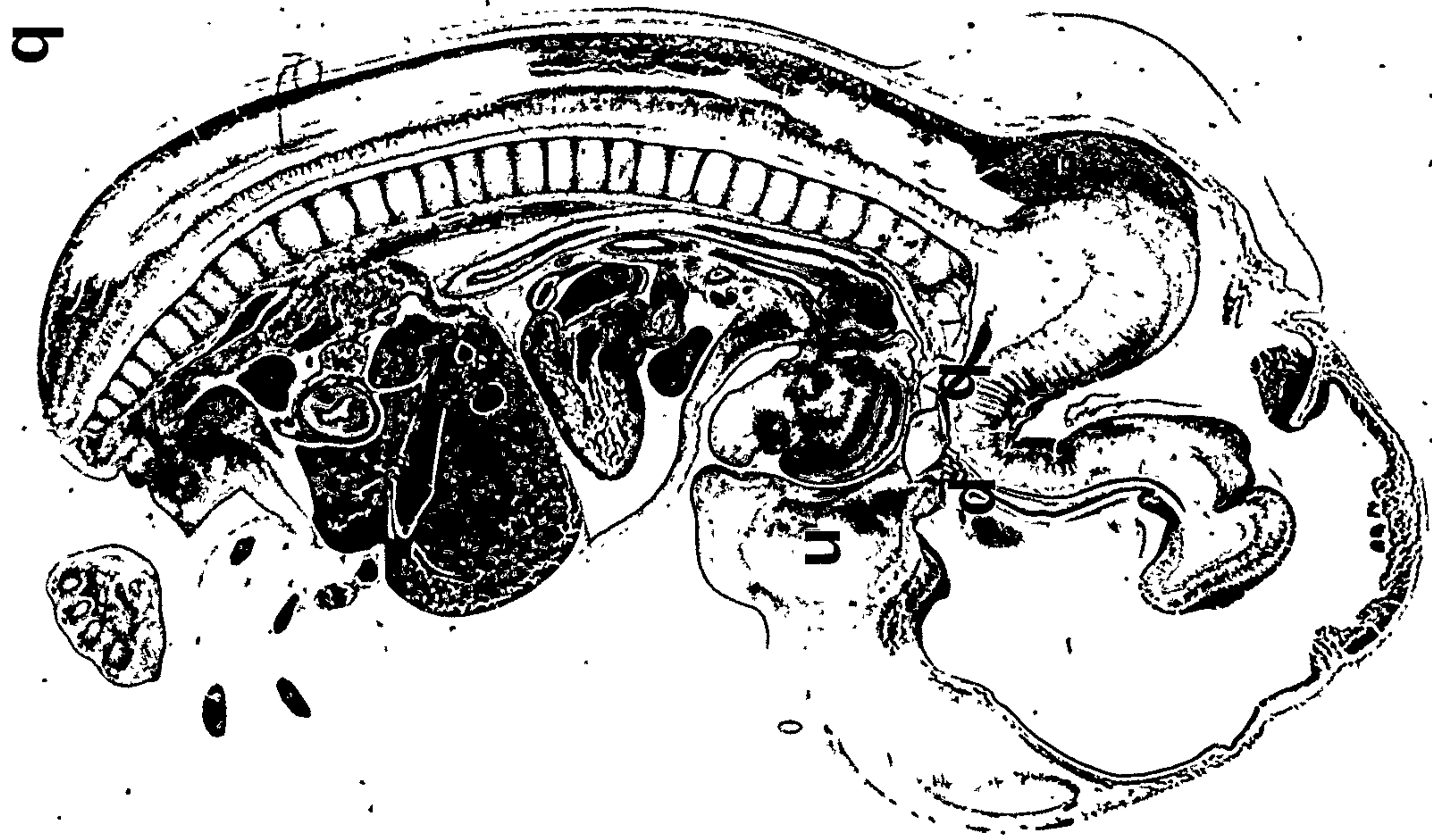
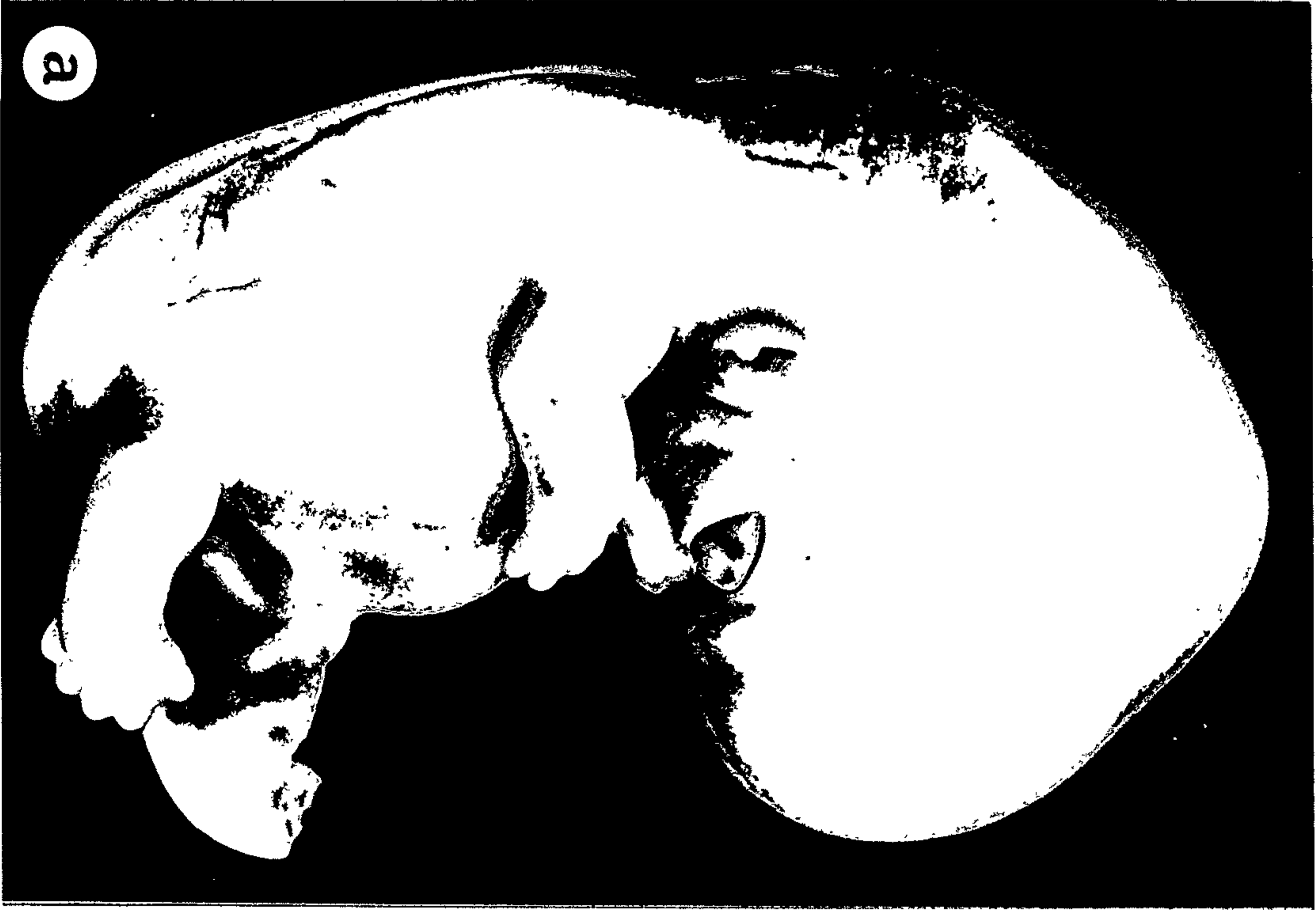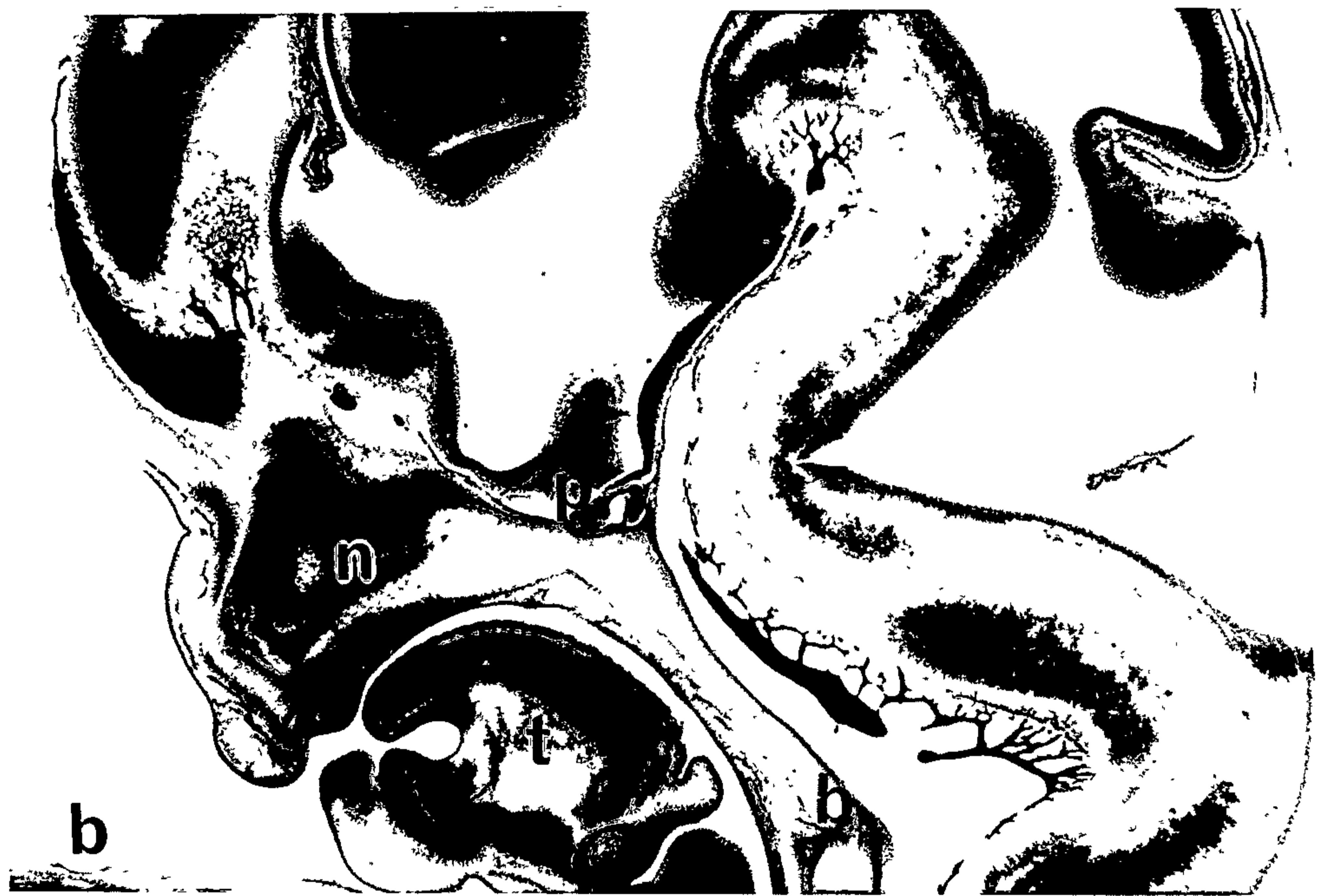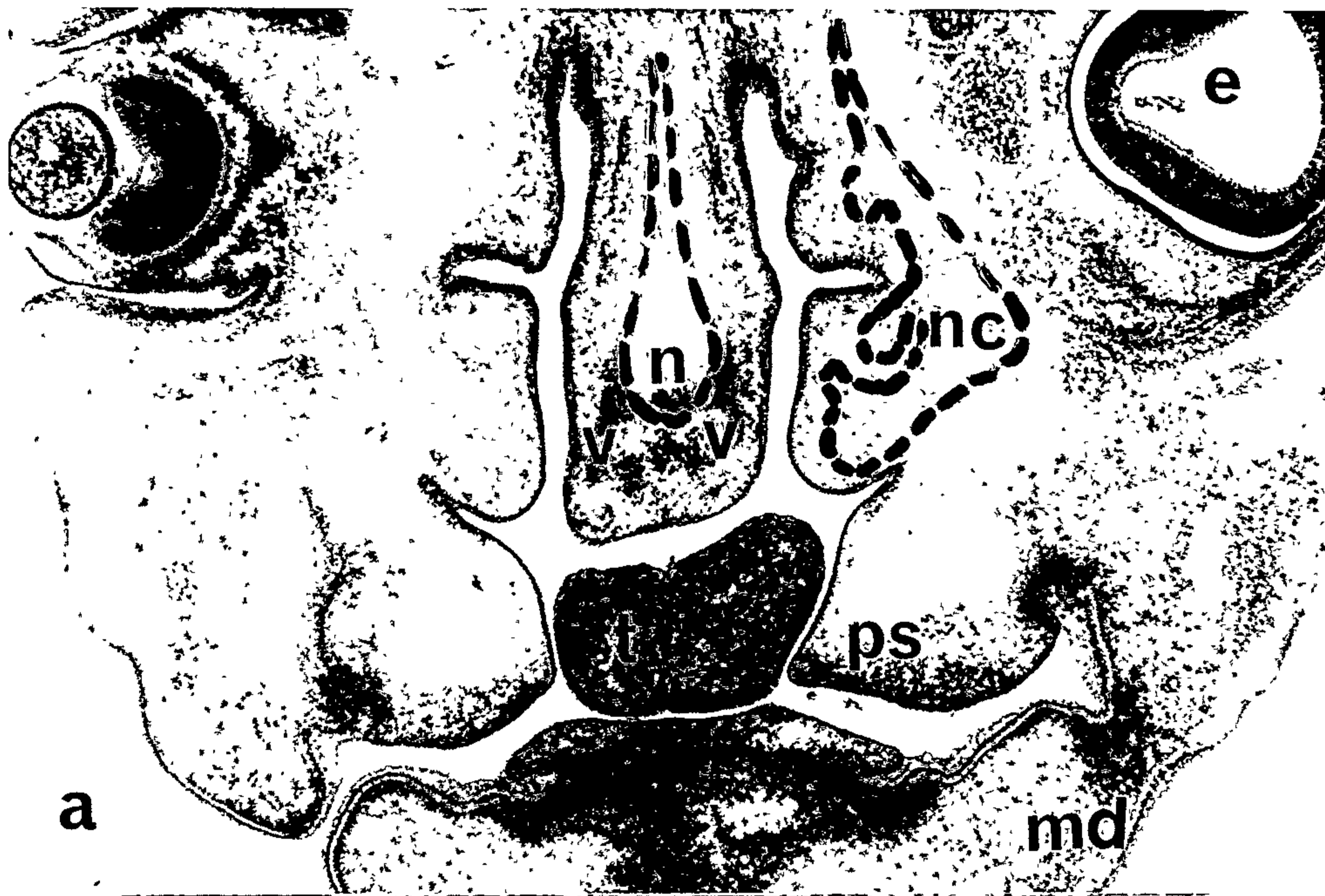


Figure 6.5

- a A coronal section of a stage 21 human embryo (number 9614). e = eye
md = mandible n = nasal septal cartilage nc = condensing
mesenchyme of the lateral cartilage of the nasal capsule ps = palatal
shelves t = tongue v = vomer
- b Mid-sagittal section of a stage 21 human embryo (number 632).
b = the basion (anterior border of the foramen magnum)
n = nasal septum p = pituitary t = tongue



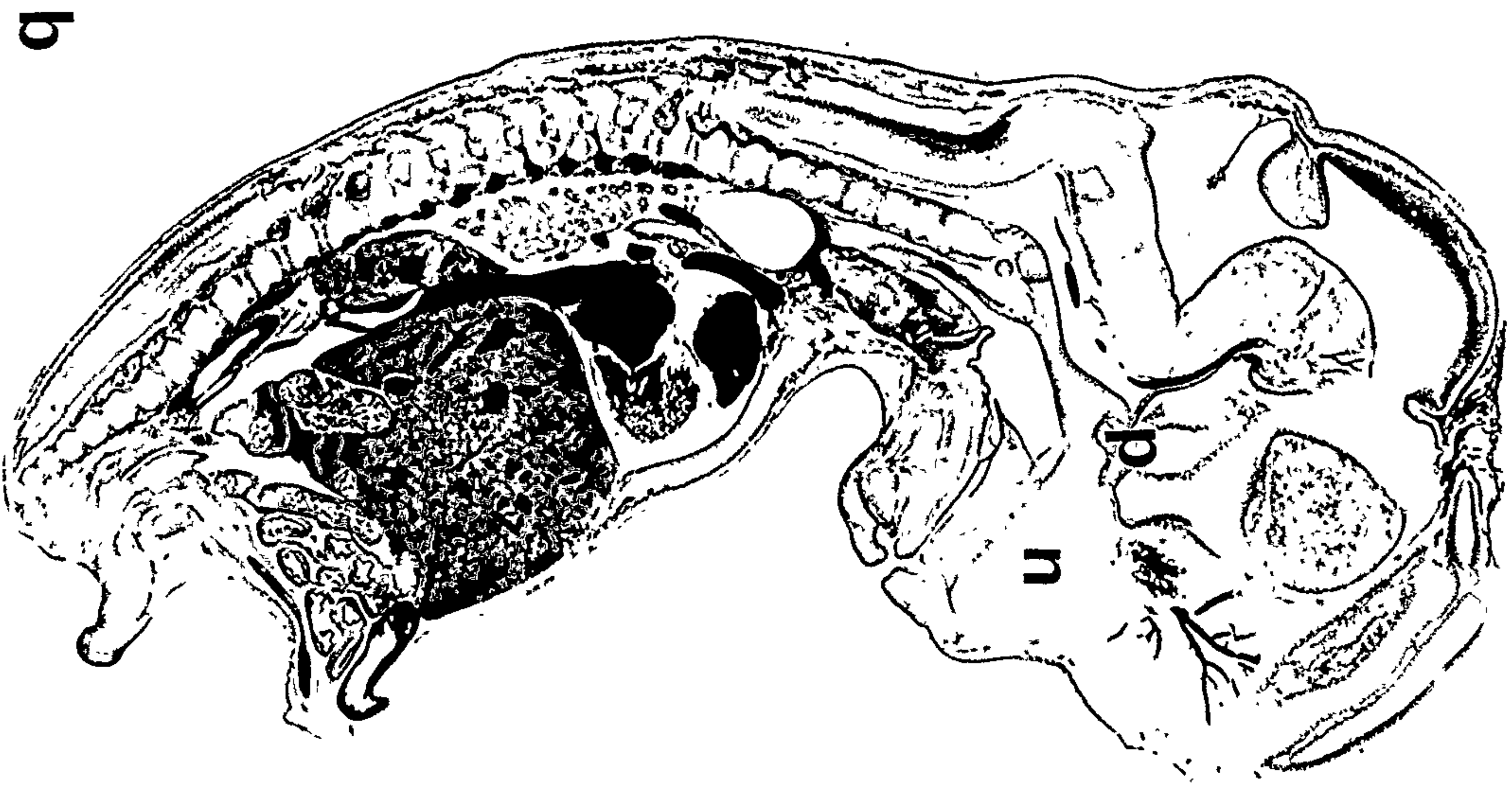


Figure 6.7


A coronal section through a 34.6mm human embryo (number 1031). Note the nasal septum (n) which is continuous with the lateral cartilage (nc) to make the nasal capsule. The right palatal shelf (ps) has fused with the left, and the nasal septum is supported by the bony vomer (v). e = eye

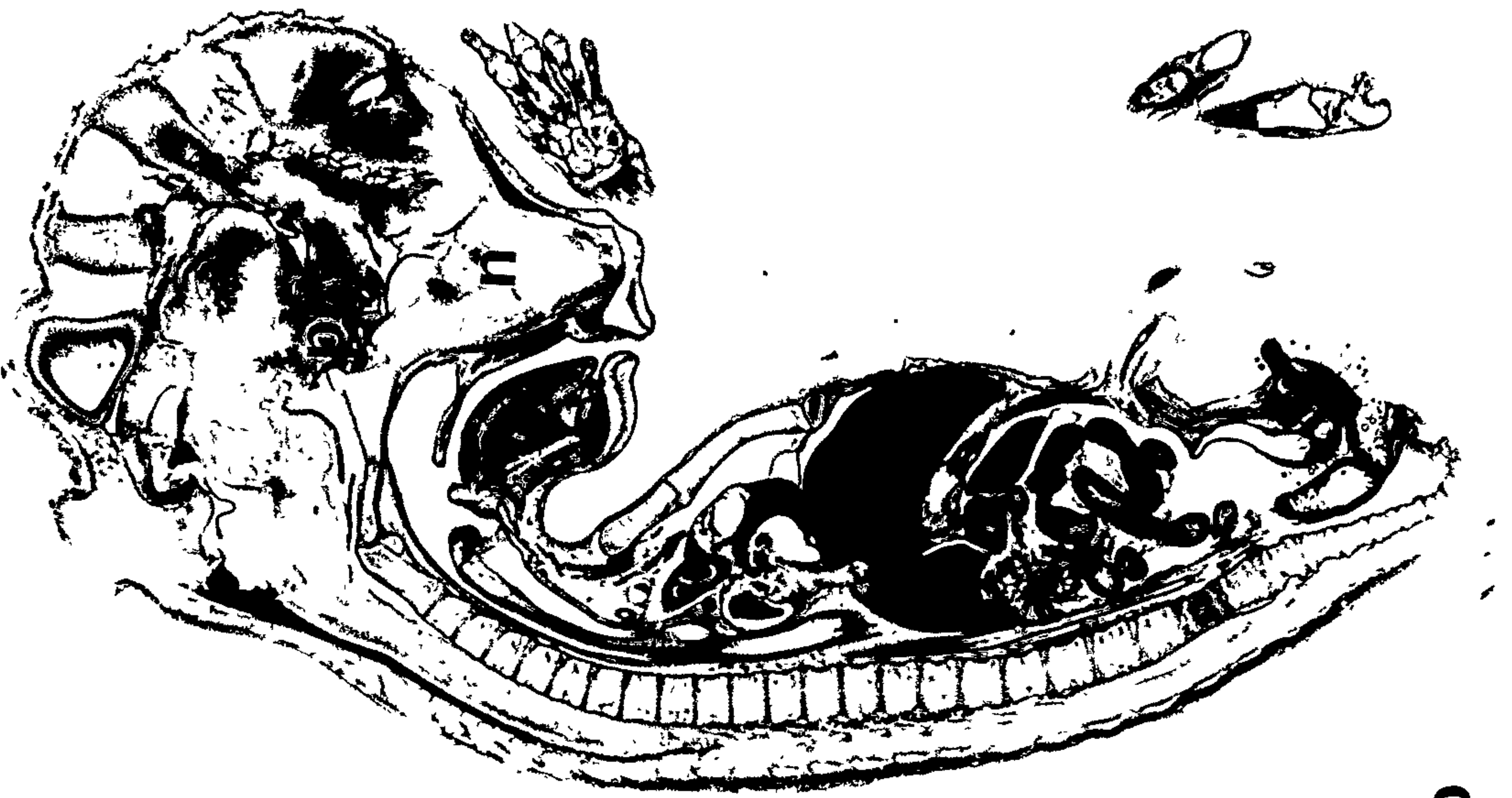


Figure 6.8

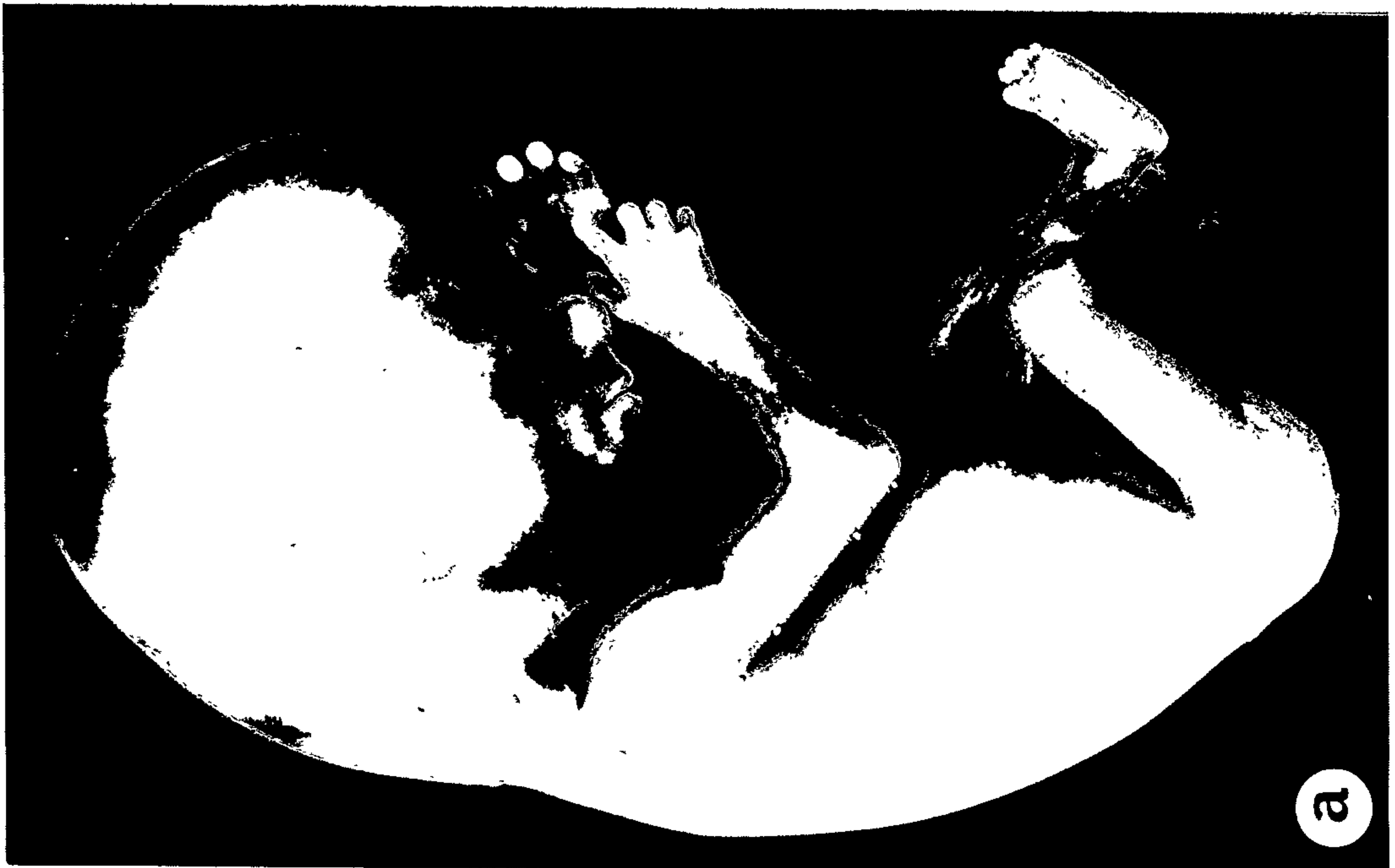
Reconstruction of a sectioned 33.5mm human embryo (number 1134D). The face and shoulders of the fetus can be seen as the red broken lines the contours show the outlines of the individual sections. The blue is the continuous cartilage of the midface and cranial base.

e = eye sp = spinal cord The green dots are Meckel's cartilage.





b



a

6.3.2 Growth of the nasal septum and posterior cranial base.

The length of the nasal septum (from the pituitary to the tip of the nose) increases 3-fold from 2.0 mm at day 44 to 6.4 mm at day 63 of gestation (Table 6.1). Other points of measurement indicate a lesser rate of growth. Figure 6.10 shows tracings of the nasal septum from a 44-day embryo through to a 63-day embryo photographed at the same scale. The extent of the growth and the change in shape of the nasal septum can be seen. The tip of the nose moves downward and forward from the cranial base. Figure 6.11 is a composite image of a day 44 embryo (406) with a 63 day embryo (362) traced at the same scale centred on a fixed pituitary and the cranial base remaining level. The crown rump measurements are 12mm and 39mm respectively indicating the rate of growth of the embryo.

Table 6.1 Embryonic cephalometric analysis

Age of embryo Carnegie Stage (days)	Number of embryos	Pituitary to tip of external nose (mm±SD)	Pituitary to nasion (mm±SD)	Pituitary to basion (mm±SD)
stage 18 (44-47)	3	2.0±0.2	1.9±0.1	2.1±0.1
stage 19 (48-50)	5	2.4±0.2	2.2±0.2	2.5±0.2
stage 20-21 (51-53)	4	2.8±0.4	2.5±0.3	2.8±0.3
stage 22 (54-56)	3	4.0±0.1	3.3±0.2	3.9±0.1
stage 23 (57-62)	5	4.9±0.5	4.0±0.4	3.9±0.4
9 weeks (63- 69)	3	6.4±0.3	5.1±0.2	4.8±0.4

Table 6.1 records the average measurements of nasal septum and anterior cranial base lengths. The lines of measurement are shown in Figure 6.1

6.3.3 Septo-premaxillary ligament?

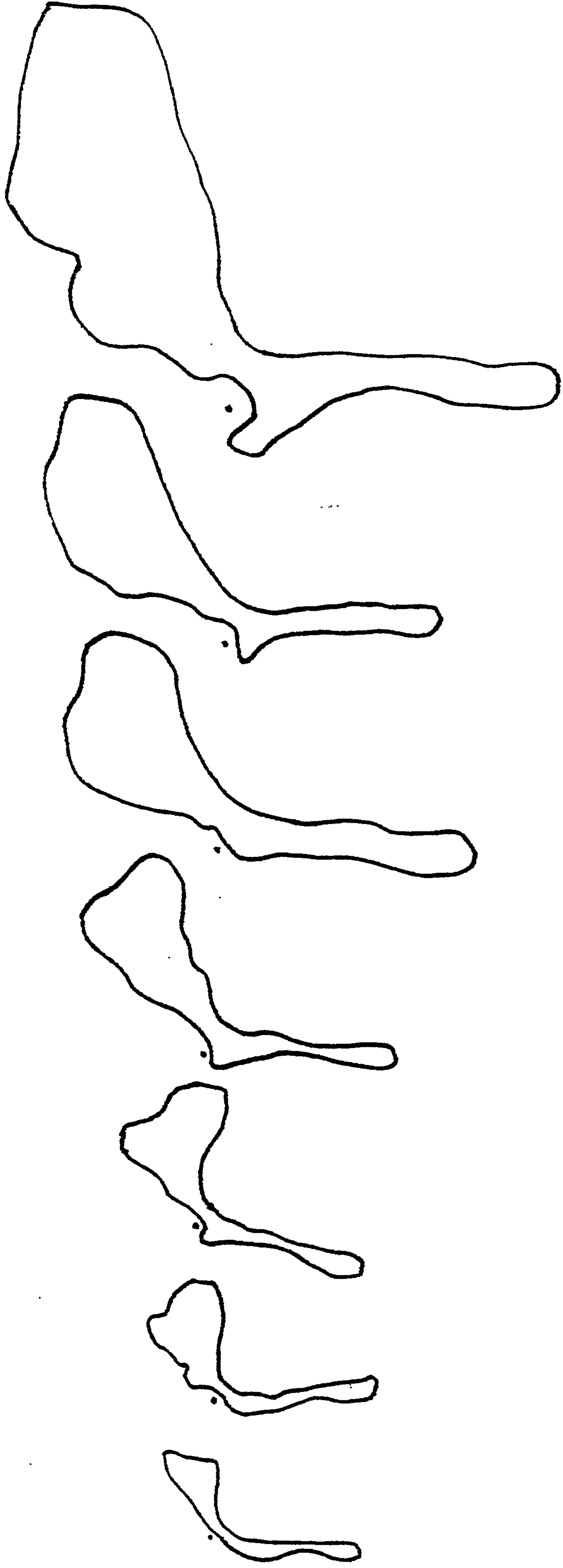
Examination of silver-stained embryos showed that the cartilage of the nasal capsule is surrounded by a thick perichondrium and the maxillae by an equally thick periosteum. In certain regions these coverings appear to merge. For instance in a mid-sagittal section (Fig. 6.12a) a fibre band passes from the tip of the nasal septum to the maxilla (primary palate).

Figure 6.10

Outline of representative nasal septa from the following embryos. A scale is provided with 1mm gradations.

The fetuses used for the tracings are

Stage 18	number 406
Stage 19	number 1390
Stage 20	number 6202
Stage 21	number 632
Stage 22	number 1458
Stage 23	number 75
9 Weeks	number 362



Week 9

Stage 23

Stage 22

Stage 21

Stage 20

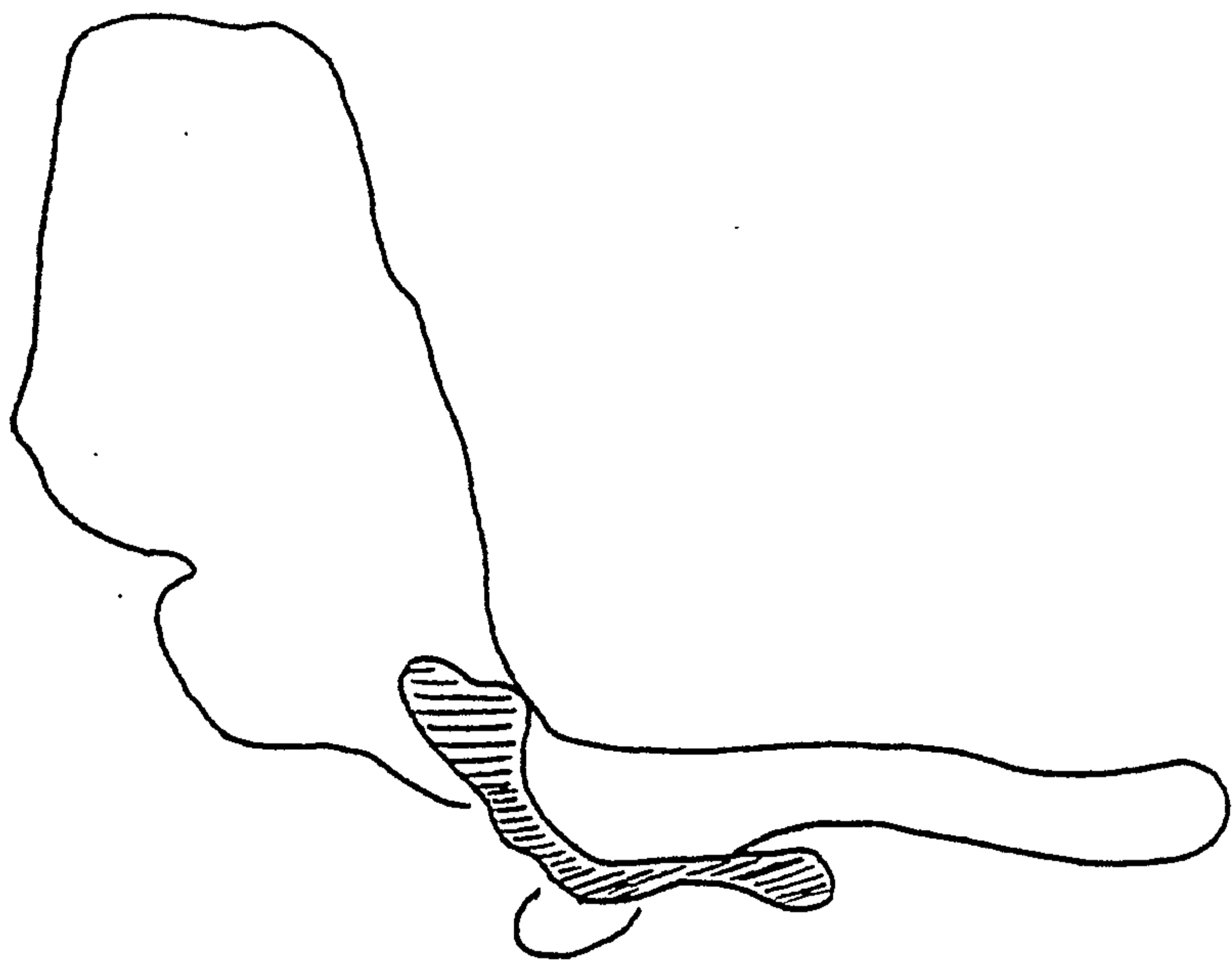
Stage 19

Stage 18



Figure 6.11

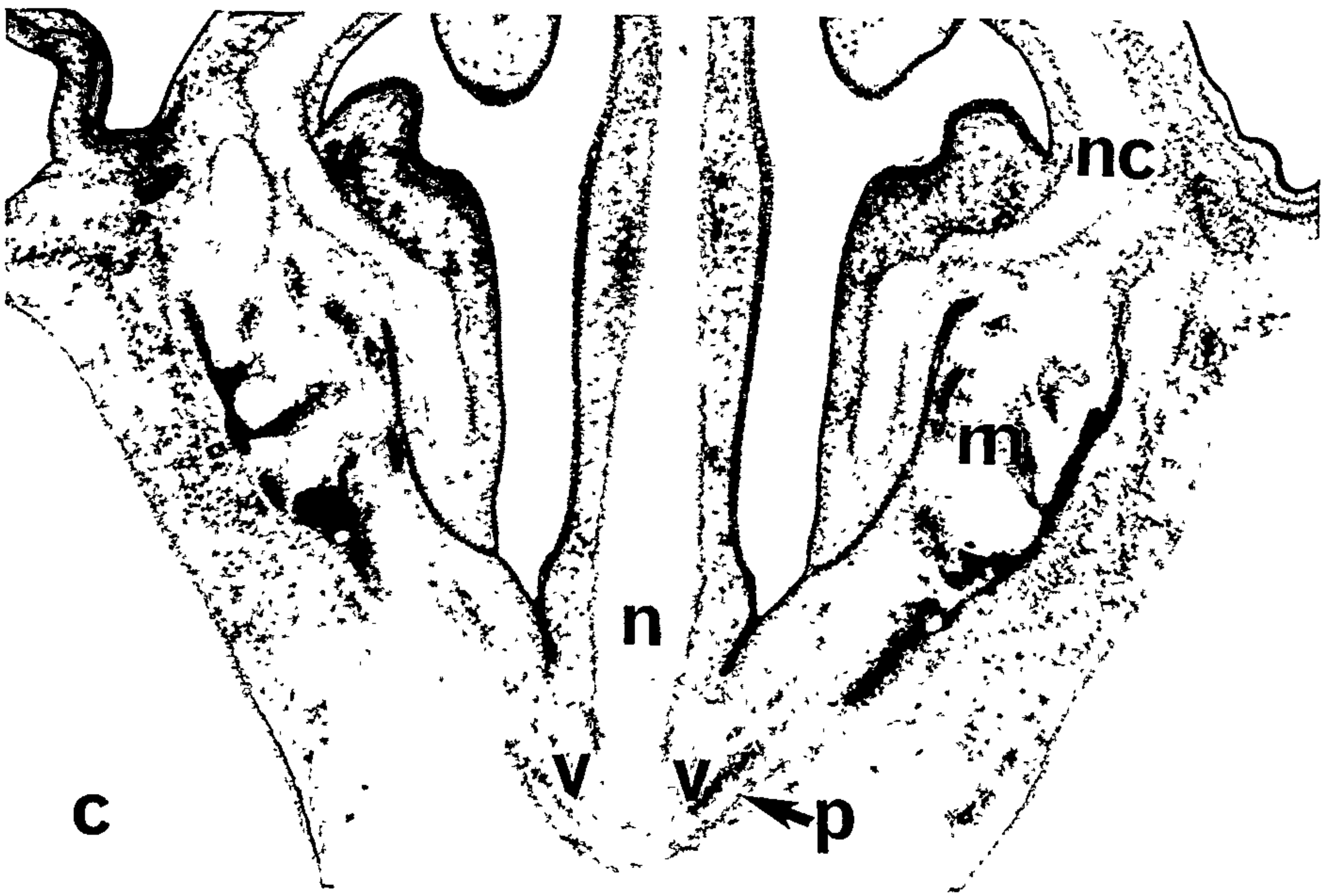
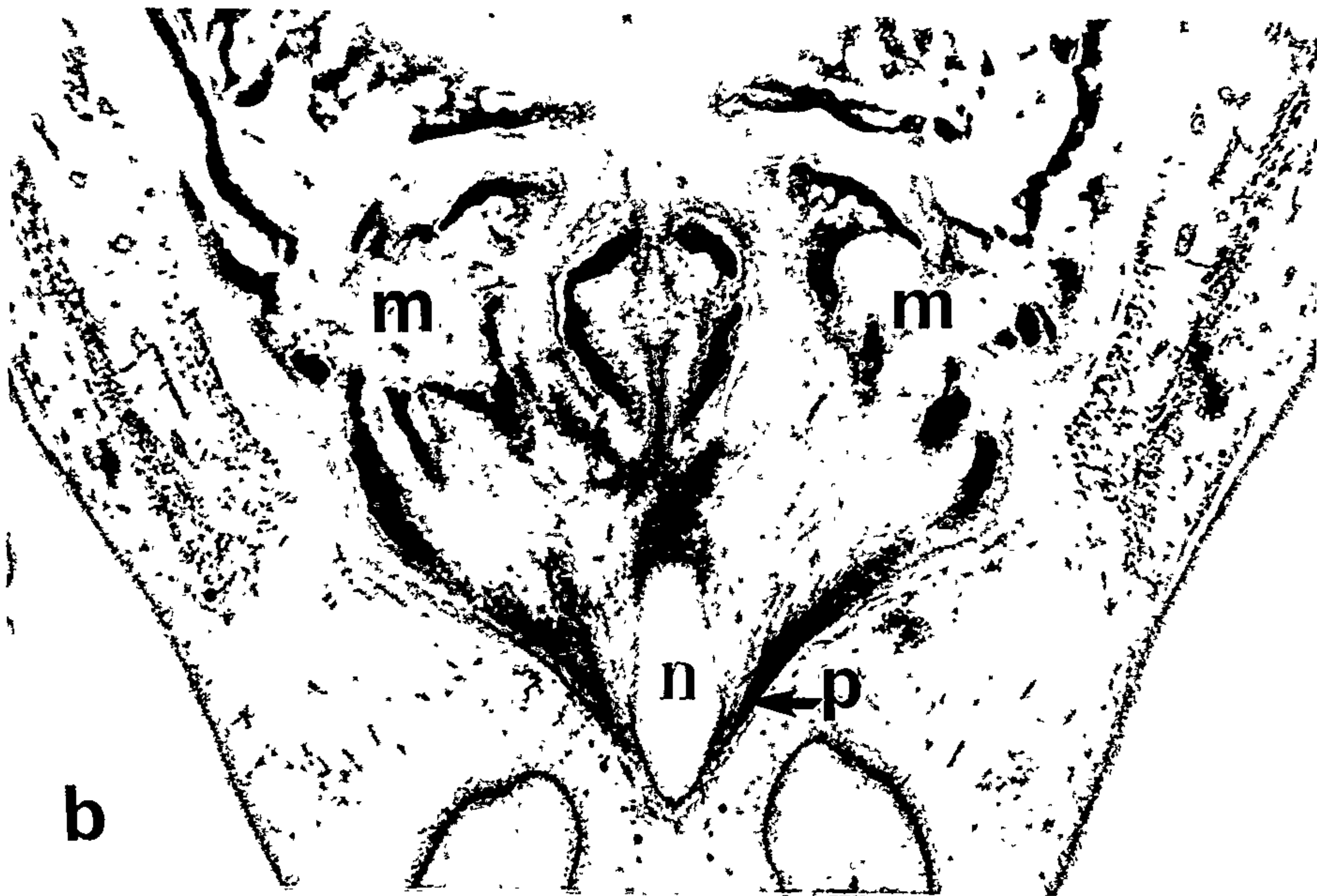
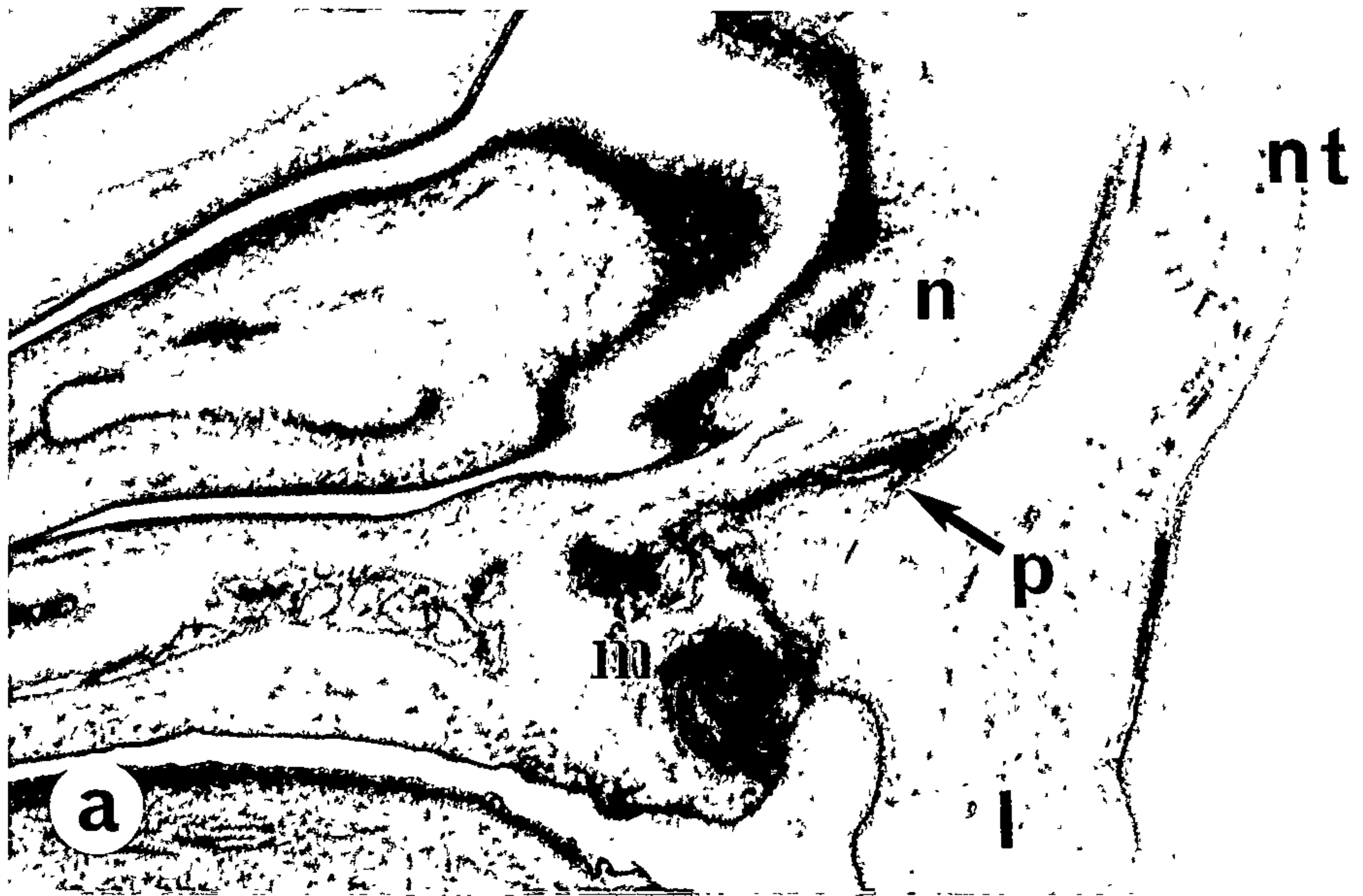
A tracing of a stage 18 nasal septum (hatched) superimposed on a 9 week nasal septum to emphasise the rapid increase in size and the change of shape over this period. Scale represents 1mm gradations.



This bundle of fibres has been described as the septo-premaxillary ligament. However, it appears to be the perichondrium of the nasal septum merging with the periosteum of the maxilla in the midline. In a horizontal section (Fig. 6.12b) showing the anterior border of the nasal septum the same perichondrium can be seen streaming laterally to join with the periosteum over the maxillae. In frontal sections (Fig 6.12c) the periosteum of the maxillae can be seen to meet in the midline inferior to the nasal septum which lies above the maxillae in the vomer. When viewed in a sagittal section in isolation the continuity is not apparent. It is of interest to note that the maxillae are moulded onto the lateral walls of the nasal capsule (Fig 6.12c).

Figure 6.12

- a A mid-sagittal section of a 45mm human embryo (number HH27)
l = upper lip m = maxilla n = nasal septum
p = perichondrial fibres (arrow) nt = nasal tip
- b A horizontal section of a 56mm human embryo (number D26).
m = maxilla n = nasal septum p = perichondrial fibres (arrow)
- c A frontal section of a 41.5mm human embryo (number 5622). The
maxilla can be seen to be embedded in the nasal capsule:
m = maxilla n = nasal septum nc = lateral cartilage of the nasal capsule
p = perichondrial fibres (arrow) v = vomer



6.4 DISCUSSION

The results from this study show two important correlations between the critical period of warfarin exposure for the fetus and the warfarin embryopathy. First, at 6 weeks the chondrocytes of nasal septum are differentiating and the nasal septum is forming. Warfarin should have no effect before this period. Second, the sensitive period (6-9 weeks) is a period of exceedingly rapid longitudinal growth of the nasal septum. When measured from the pituitary to the tip of the external nose there is a three-fold increase in length between days 44 and 63. A comparison of a 44 day septum and a 63 day septum (Fig 6.11) emphasises the extent of the growth. However, other parts of the embryo may be growing as rapidly at this stage as CR length increases from about 13-17mm to 39-41 mm over the same period. Other investigators have also measured growth of the nasal septum but none of the studies has examined embryos at 6-7 weeks. Ford (1956) reported that the nasal septum increased in length from 5.25mm at 8 weeks gestation to 11mm at 12 weeks. The 5.25 is close to the 4.9 mm recorded at the same age in this study. Ford also found that longitudinal growth declined with age so that a further doubling in length to 22mm was not achieved until 22 weeks gestation and the length at birth is about 35mm. In the present study the posterior cranial base grows at two-thirds of the rate of the anterior part, Ford (1956) and Burdi (1969) obtained similar results at a slightly later stage of development. Burdi concluded from his measurements of second and third trimester fetuses that growth of the human upper face during the last two trimesters followed a trend characterised by progressive enlargement of a relatively stable profile. In other words the face undergoes rapid change in profile during weeks 6-9 reaching a profile that is maintained until birth. From this information it seems likely that if an abnormal profile is present at 9 weeks gestation it will be carried through to birth.

The limits of the critical period for warfarin embryopathy following warfarin exposure have been questioned (Pauli, 1997) and three published cases of warfarin exposure restricted to the second and third trimester have been published (Harrod and Sherrod, 1981; Hill and Tennyson, 1984; deVries et al., 1993). It is likely that as the nasal septum is not growing as rapidly during this period the midfacial hypoplasia induced by vitamin K

deficiency would not be as distinct (as first trimester exposure) and may not seem as worthy of publication.

It is evident from examination of sagittal sections of 6-9 week human embryos that the outgrowth of the external nose and development of the facial profile accompanies the growth of the nasal septum. It would appear that the outgrowth of the nasal septum causes the outgrowth of the external nose but this statement is contentious and has been the subject of considerable debate as there has previously not been any appropriate model to examine the role of the nasal septum in prenatal facial growth.

Current theories of midfacial development.

There are two major theories on the mechanisms that govern pre- and postnatal growth and development of the human midface. The first, proposed by Scott (1953), suggests that the cartilaginous nasal septum is a primary growth centre which pushes or thrusts the midfacial bones downward and forwards. Latham (1970) in a modification of this theory suggested that the nasal septum acted as a starter mechanism pulling the premaxillae and maxillae forward via the so-called septo-premaxillary ligaments. It was proposed that this mechanism was largely confined to the prenatal period after which the maxillae acquired a capacity to carry on this downward and forward movement by their own intrinsic displacing growth. The second and rival theory (Moss et al., 1968) uses the theory of boxed structures (Badoux, 1966) and views the septal cartilage as a strut in the nasal cavity without a primary morphogenic role. Moss (1968) proposed the concept that function determines morphology and that mucosa and expanding cavities of the head influenced growth and that respiration, olfaction, speech, and mastication, act as functional matrices. He claims that the nasal septum (and all of the nasal cartilages) arise embedded within an orofacial capsule. As this epithelial lined and covered capsule expands volumetrically, to achieve adequate oro-nasal-pharyngeal functioning space the enclosed midfacial skeletal bones are passively translated in space (Moss et al., 1976). The skeletal elements simply support the mucosa and cavities and the nasal septum is secondary and compensatory to expansion of the nasal cavity.

Attempts to test these theories have centred around clinical studies of children with midfacial clefts, traumatic or congenital absence of the nasal septum, or experimental animal studies involving partial or complete ablation of the nasal septum. The results from these studies have been inconclusive mainly because they fail to isolate the nasal septal damage from damage and effects on the adjacent structures. For instance, although clefting may separate the septum from the palatal processes of the maxilla the nasal capsule is still continuous superiorly and posteriorly (Copray, 1986).

Moss and his colleagues (Moss et al, 1968) examined two infants with agenesis of the nasal septum and concluded that although they had small noses the midfacial development was normal. Hence he concluded the nasal septum was not necessary for midfacial growth. Although he referred to "agenesis" of the nasal septum this is highly unlikely and the photographs and clinical description of the children suggest that they could be classified as Binder syndrome, in which case the nasal septum is reduced in length rather than "absent". Furthermore, modern cephalometric examination of such children reveals considerable midfacial abnormality particularly when examined in the teenage years (Horsewell, 1987; Olow-Nordenram, 1987).

A number of authors have attempted to establish the role of the nasal septum in facial growth by full or partial removal of the septum in experimental animals. This has not been performed prenatally. Moss (1968) removed the nasal septum from 12 and 20 day rats by electric cautery and reported that 30 days later the facial skull had grown vertically, anteroposteriorly and in width to attain control values, although there was collapse of the dorsal surface of the facial skull. The number of animals and measurements were not given. Although other published work supports these findings (Moss, 1976) there is an equally large body of work that finds extirpation causes anteroposterior deficit (Johnston, 1976). Animal resection results have been criticised by Koski who concluded that factors such as animal size, age of the animal at the time of operation, site, size and composition of the extirpated portion, surgical damage to adjacent structures, nutritional conditions after the operation and the growth registration procedures underlie the controversial and contradictory results (Koski, 1968; 1975).

Hence, despite three decades of investigation the controversy over the role of the nasal septum in facial growth remains unresolved. It would seem difficult to argue that warfarin alters the functional role of the nasal cavity during the 6-9 week period of fetal development. Warfarin's effect has been shown to be on cartilage resulting in decreased growth and calcification. Neonates with severe warfarin embryopathy often require intubation of the nasal cavity as the nasal aperture is reduced and the hypoplastic nasal cartilages prevent normal breathing (Pauli, 1997). The midfacial hypoplasia seen in warfarin embryopathy results in not only the reduced nasal profile, but hypoplastic maxillae producing a pseudo-prognathism of the lower jaw. Therefore the warfarin rat model would seem to be more consistent with the theory of Scott that the nasal septum plays an important role in outgrowth of the nose and midface.

Warfarin embryopathy and midfacial development.

Newborn children with the warfarin embryopathy (Fig. 6.13a) have a midface that resembles the profile of a 7-8 week human fetus (Fig. 6.13b). The tip of the nose is elevated and the nares everted (Fig. 6.13c). There is also an interesting photograph of a 17-week human fetus (Fig. 6.13d) that was exposed to warfarin in the preceding weeks (Barr and Burdi 1976). Again the midface has not advanced from the normal 7-8 week profile with the nose sunken into the face. It is clear that the maxillonasal hypoplasia of the warfarin embryopathy is established at 17 weeks. Furthermore midfacial hypoplasia due to prenatal warfarin exposure does not "grow out" in adult life (Hosenfeld and Wiedemann 1989; Pauli, 1997) suggesting that prenatal septal development has a lasting effect on the growth of the midface.

The septo-premaxillary ligament.

Latham (1970) supported the theory of Scott (1953) and proposed the existence of a ligament which attached the nasal septum to the premaxilla. This ligament was thought to be responsible for transferring the force of the growing nasal septum to pull the maxillae downward and forward. He demonstrated this histologically by showing fibres extending from the tip of the nasal septum to the premaxilla (Fig. 6.14 a and b). He also

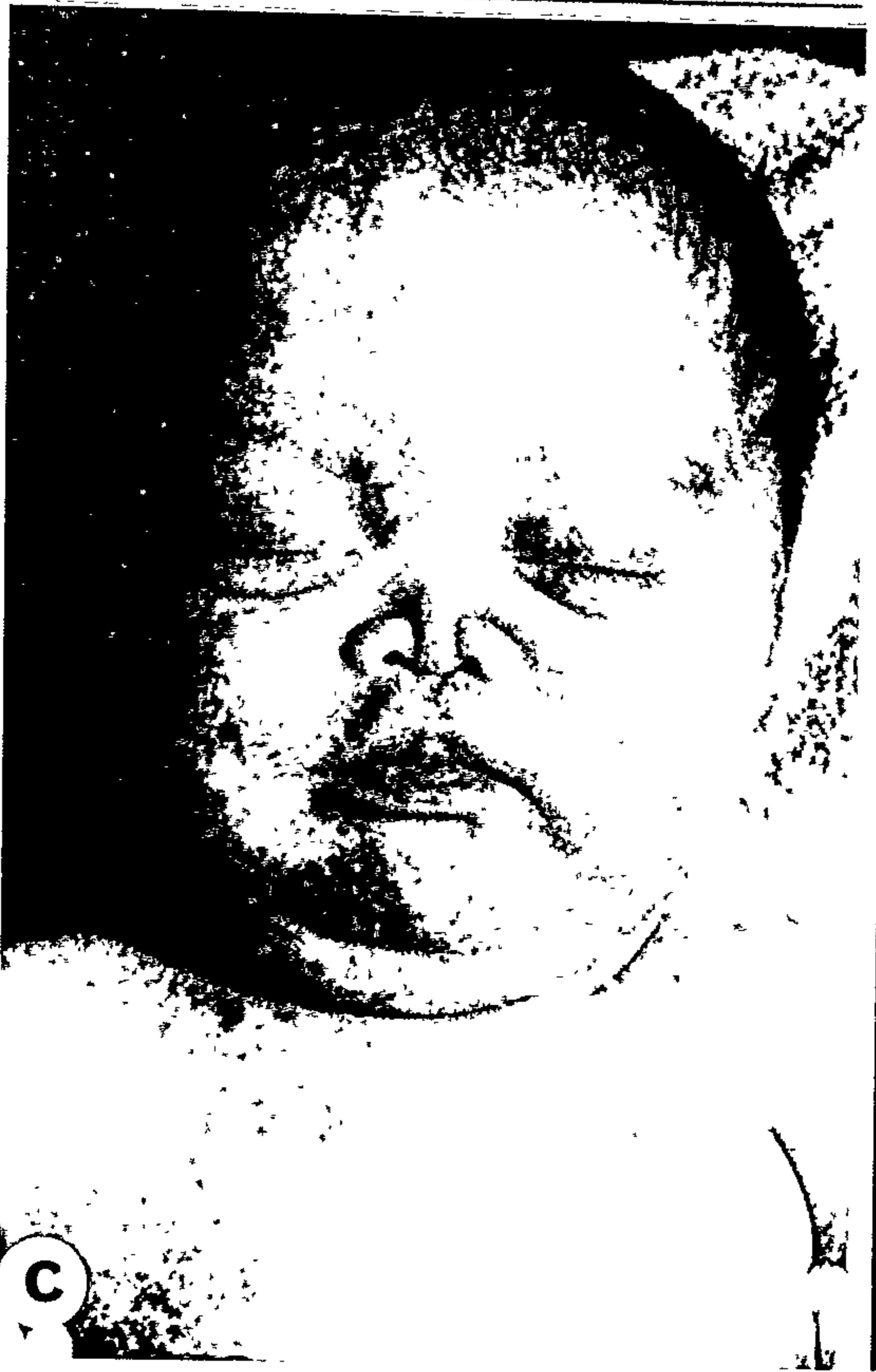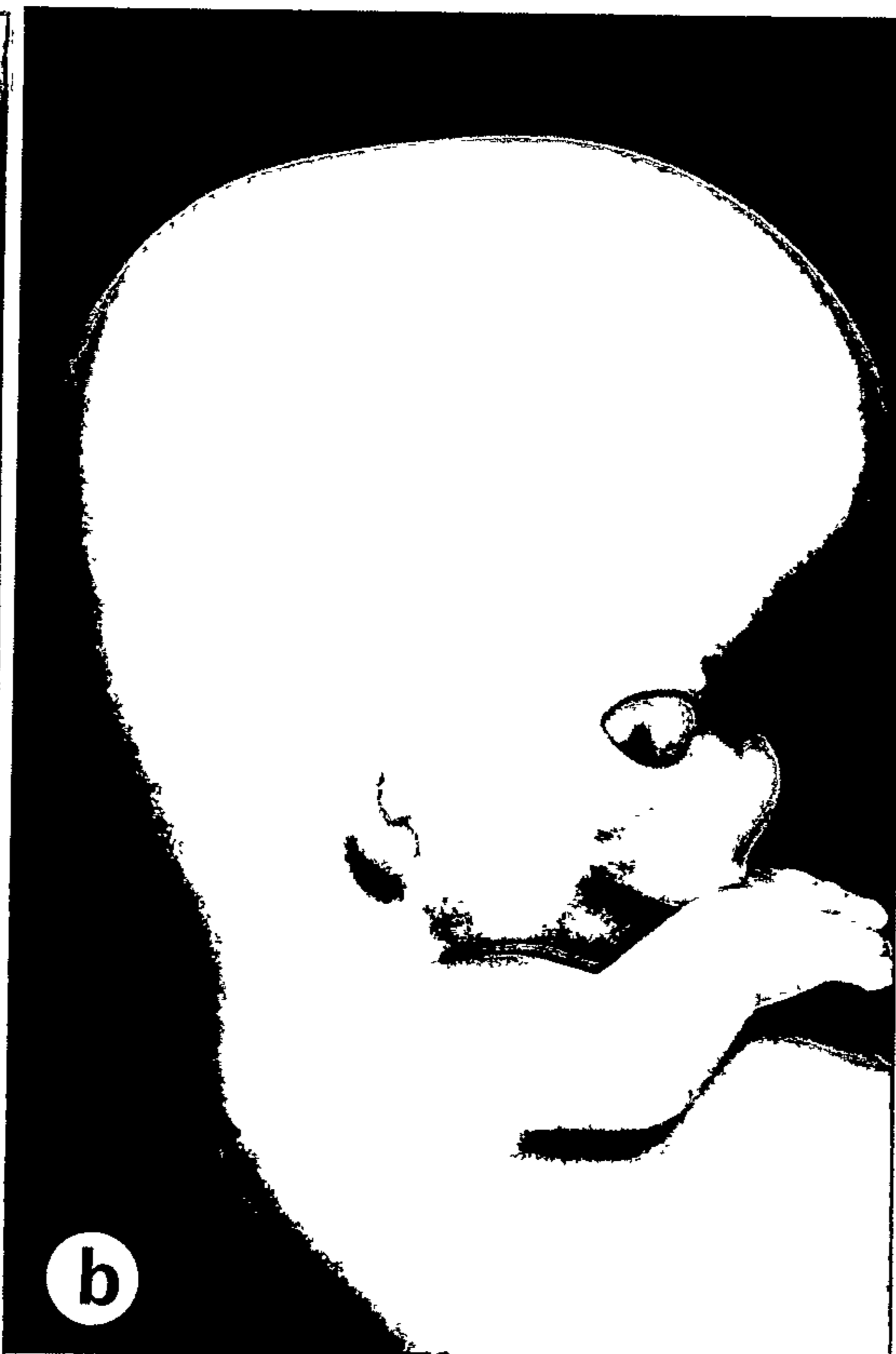

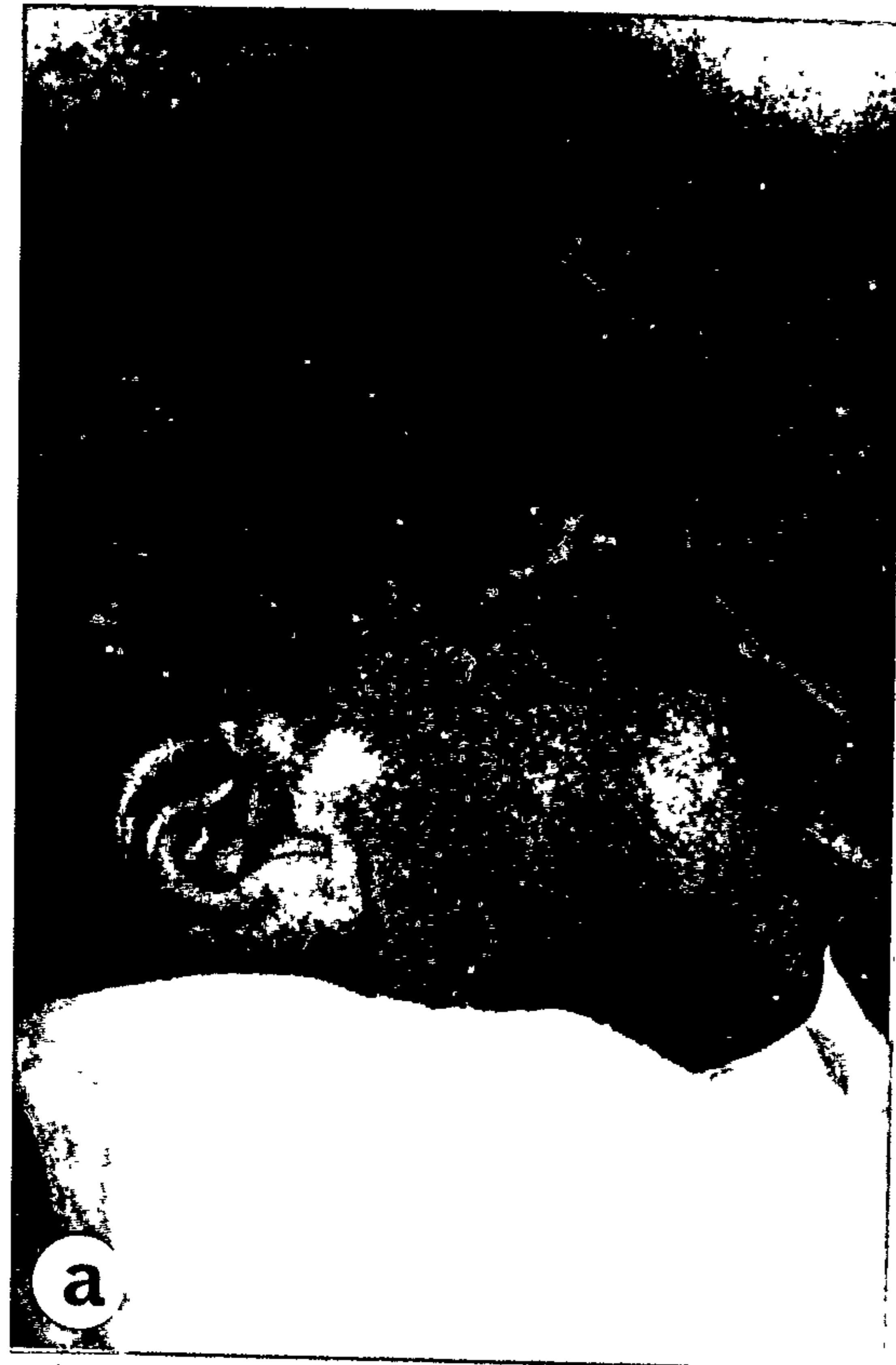
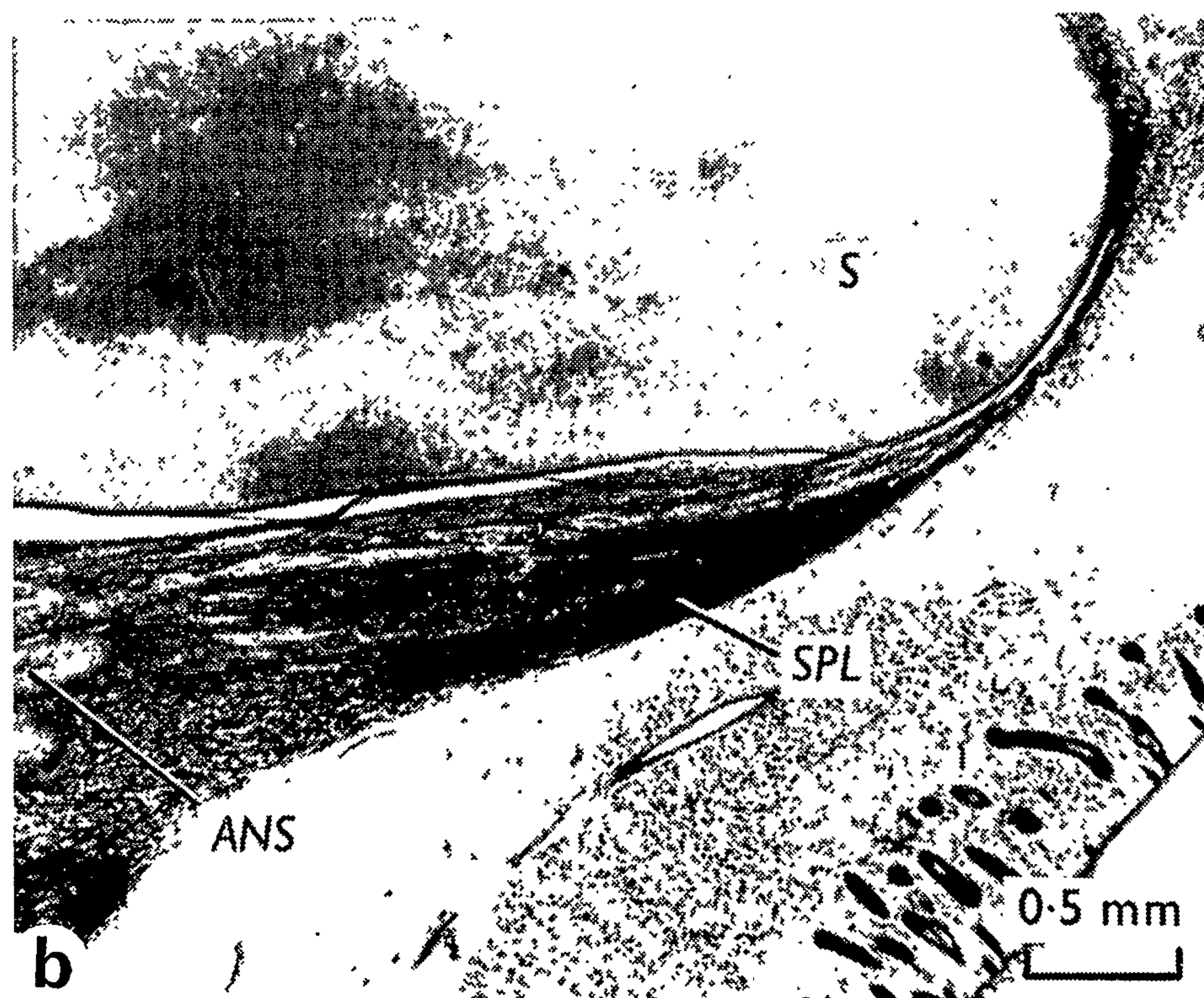
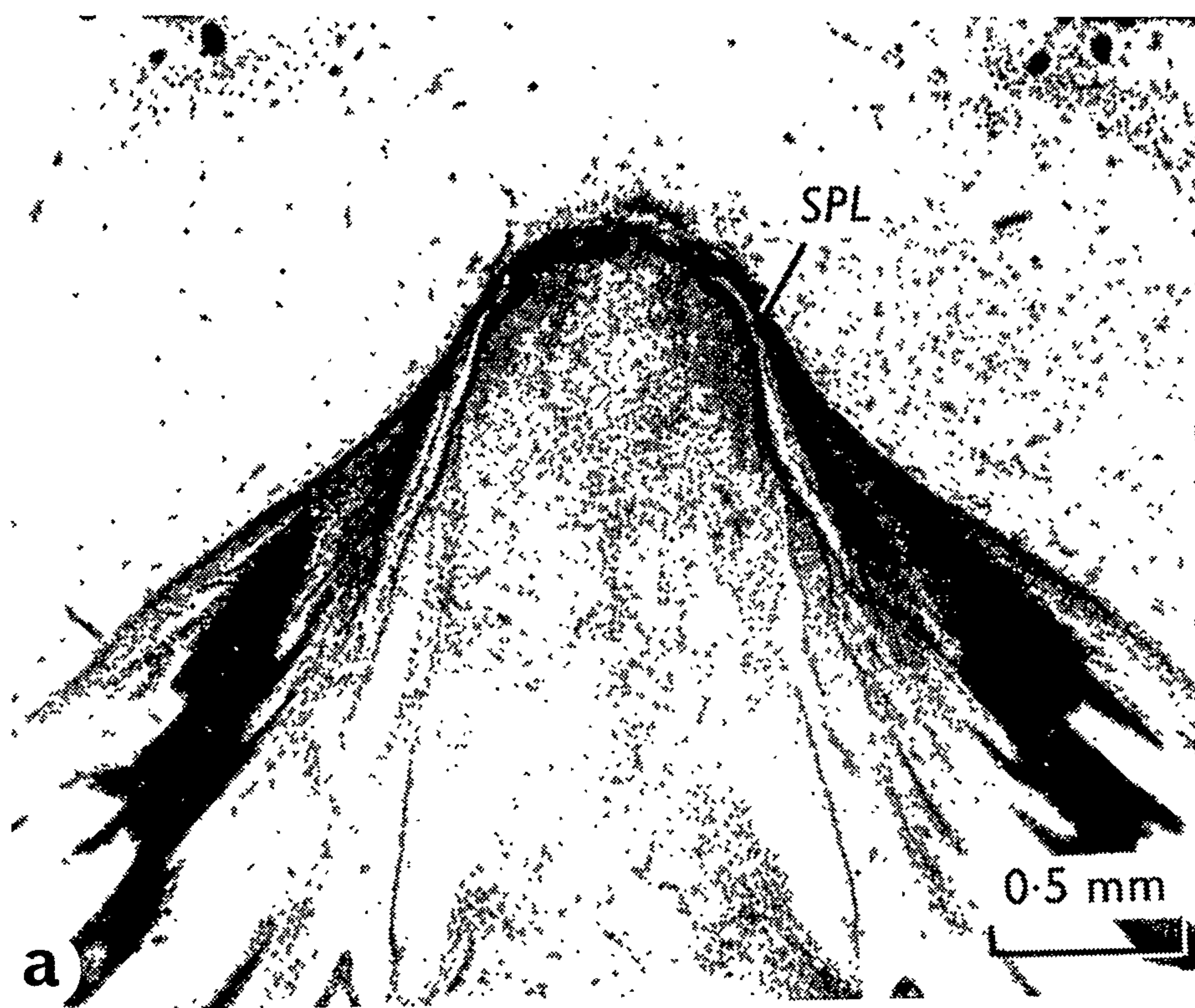
Figure 6.13

- a A lateral view of a newborn with warfarin embryopathy (Kerber et al., 1968)
- b A 6-7 week human embryo (number 441)
- c A frontal view of a newborn with warfarin embryopathy. Note the nasal hypoplasia (Pauli et al., 1976).
- d A 17-week abortus with warfarin embryopathy. Note the nasal hypoplasia (Barr and Burdi, 1976).

Figure 6.14

- a Photograph showing the septo-premaxillary ligament (SPL) as described by Latham (1970) in a horizontal section of a 12-week human fetus.

- b Photograph showing the septo-premaxillary ligament (SPL) as described by Latham (1970) in a 17-week human fetus.
ANS = anterior nasal spine of the maxilla s = nasal septum



represented this diagrammatically (Fig. 6.15). However, as shown in the results, the structure described as a distinct ligament is in fact part of an extensive perichondrial/periosteal capsule. Nonetheless the continuity of these fibres suggest that the outgrowing nasal septum would exert traction on the maxillae through this attachment as seen by the anterior protrusion of the nasal spine. This spine is noticeably underdeveloped in the warfarin embryopathy and may represent reduced forward movement of nasal septum. It should also be noted that the maxillae are enclosed/embedded in the lateral walls of the nasal capsule (Fig 6.12c and 6.16) and forward growth of the septum/capsule would necessitate forward movement of the maxillae.

6.5 Conclusions:

It would appear that the gestational 6-9 week period is critical in terms of lasting midfacial/nasal hypoplasia. The main reasons for this conclusion is the nasal septal cartilage undergoes its most rapid rate of increase in length during this period and that retardation of growth during this period cannot be overcome.

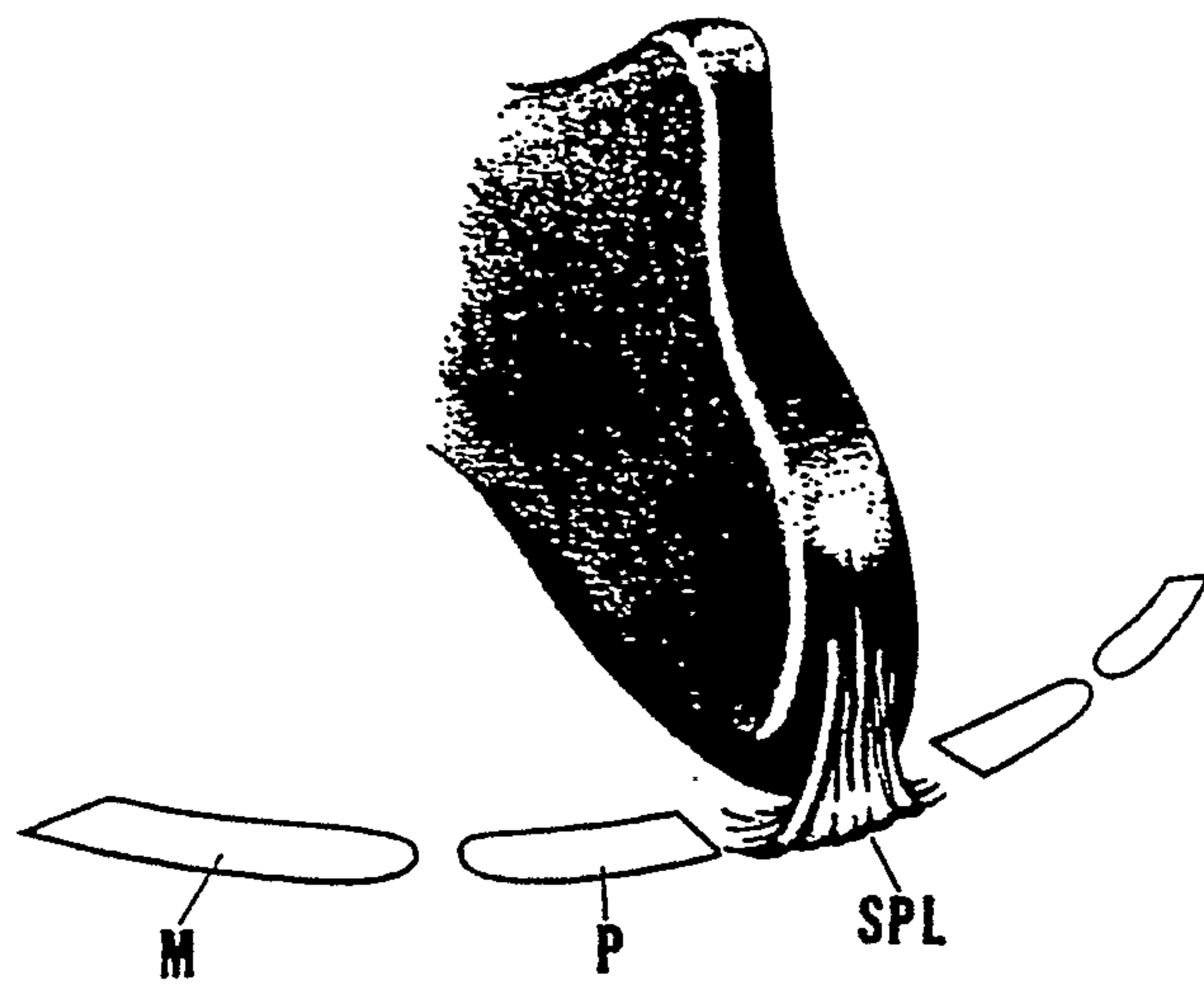


Figure 1. Diagrammatic representation of the septopremaxillary structures seen in 41d. human embryo. The maxillary (M) and premaxillary (P) ossification centers, very soon after their first appearance, are connected to the nasal septum by a septopremaxillary ligament (SPL). (From Latham, '70)

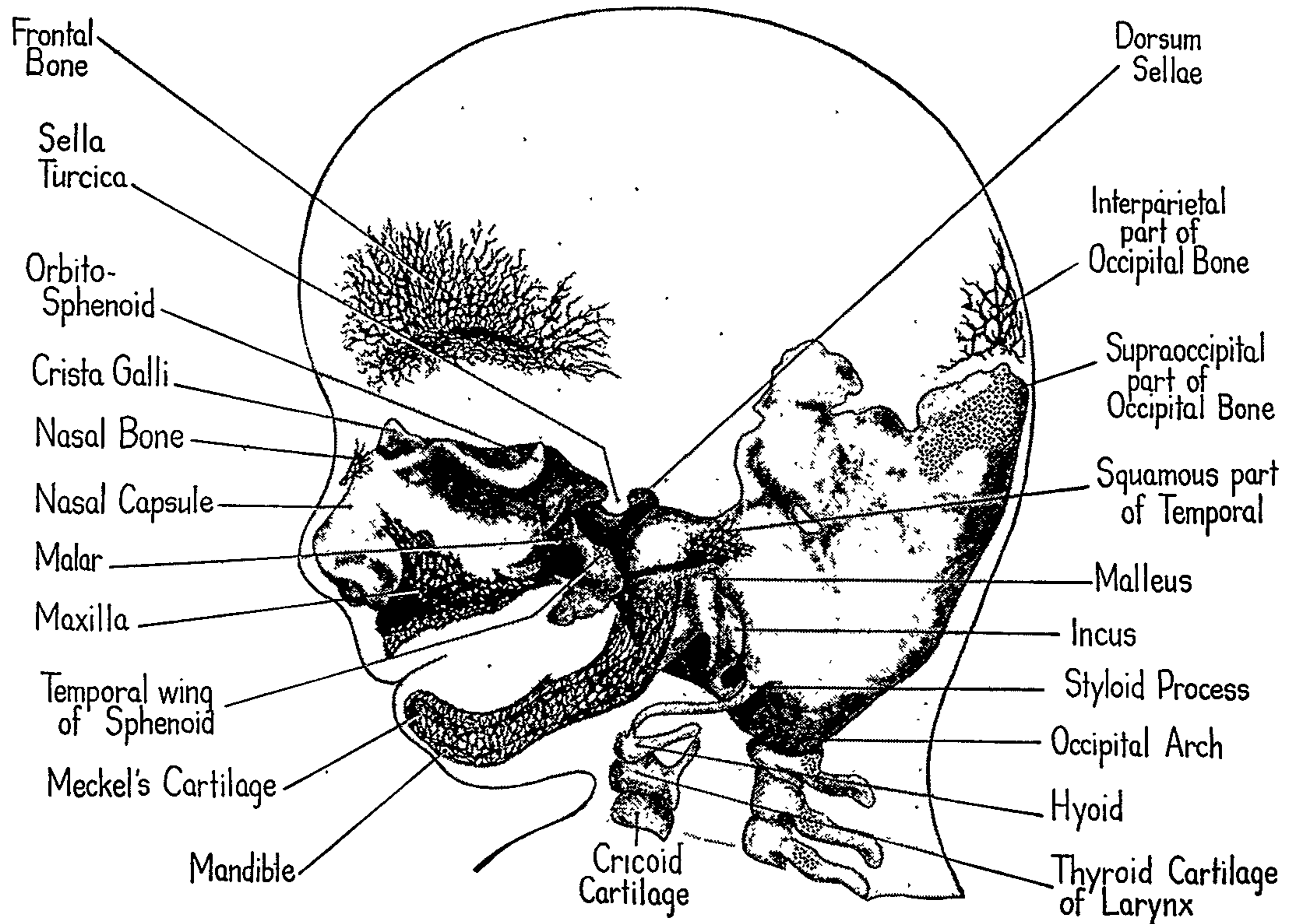


FIG. 166. The developing skull of a human embryo of about nine weeks (38-40 mm.). The drawing is a composite, based in part on the work of Macklin and in part on cleared preparations in the University of Michigan Collection. Cartilage is shown in gray wash; the locations of the endochondral ossification centers which have appeared at this age are indicated by superimposed stippling; the lacelike trabeculae of young intramembranous bone are shown in black.

CHAPTER 7

7.1 INTRODUCTION

In 1989 there was a report of a 32-year-old patient with severe midfacial hypoplasia, growth retardation and hypoplasia of the extremities (Hosenfeld and Wiedemann, 1989). He sought genetic counselling as his wife was expecting their first child. In early infancy he had been diagnosed as having chondrodysplasia punctata, later regarded to be the autosomal dominant form. Convinced of a high risk of recurrence of his disorder he vacillated between thoughts of suicide and his intention to have the pregnancy terminated. However, family history revealed that his mother had been treated with the oral anticoagulant phenprocoumon (a vitamin K antagonist) during pregnancy from the 6th to the 10th and 11th to 13th week of gestation. Thus at counselling the patients fears were dispelled and a healthy boy was subsequently born.

At about the same time that this report was published our group became aware of a late adolescent woman who had midfacial hypoplasia which had been diagnosed by a maxillofacial surgeon as Binder's syndrome. She had also sought genetic counselling and had been diagnosed as autosomal dominant mild-type chondrodysplasia punctata. She was also distressed about the high recurrence risk given and sought further advice. As described below it was established that her mother had been treated with phenytoin during pregnancy and this was the likely cause of her facial appearance.

These two cases emphasise the similarity in facial appearance in adulthood of warfarin embryopathy and fetal hydantoin syndrome (previously commented on by Hall et al., 1980) and the range of diagnostic classifications that adult patients with maxillonasal hypoplasia may be assigned. The misdiagnosis in each case is related to the diagnosis being made on the patient's clinical features without any consideration of the prenatal history.

In recent years, through the study of neonatal hemorrhage in the children of women receiving anticonvulsants during pregnancy, it has been suggested that phenytoin can cause severe vitamin K deficiency in the

fetus (Keith and Gallop, 1979). If both warfarin and phenytoin cause prenatal vitamin K deficiency it may explain the many common features seen in the respective embryopathies. Phenytoin undoubtedly has other biochemical effects and can cause other additional and severe abnormalities such that the abnormal facial features are often considered to be minor and unimportant. Little consideration has been given to the possibility that when the affected children become adults they may be very concerned about their facial appearance.

With these considerations in mind a series of investigations was initiated.

Study 1: Three cases of maxillofacial hypoplasia are presented. The relationship between the symptoms, their previous classification and their prenatal history are discussed.

Study 2: A study of 9 cases of maxillofacial hypoplasia, associated with prenatal phenytoin exposure, seen at a surgical craniofacial unit and two birth defects counselling units. This study was undertaken to determine the severity of facial dysmorphology and the diagnostic history.

Study 3: A prospective study of the vitamin K status at birth of normal newborn and newborn of women on phenytoin and other anticonvulsants. This was achieved by measuring des-carboxyprothrombin and normal prothrombin in cord blood at birth. These values are related to vitamin K levels in the fetus.

7.2.1 STUDY 1

7.2.1.1 Case sources

Three cases of maxillofacial hypoplasia, initially diagnosed as having a genetic basis, and subsequently reassessed due to significant prenatal history were obtained through contact with genetic counsellors at the Genetics and Dysmorphology Unit at Children's Hospital Camperdown, Sydney (cases 2 and 3) and the Murdoch Institute, Royal Children's Hospital, Victoria (case 1).

7.2.1.2 Case reports

Case 1: This male patient (Fig. 7.1a) attended a paediatric emergency department several times for upper respiratory tract infections in the first two years of life. At 30 months of age, because of his flattened nose (Fig. 7.1b) he was referred to a plastic surgeon. This was diagnosed as "absence of the nasal cartilage". The family history showed that he had one male sibling of normal appearance and there was no history of any similar nasal flattening in any other relative. The patient was seen again at age 5 due to his poor speech, and a school report suggesting deafness. Conductive deafness was confirmed resulting from congenital absence of the ossicles of the left ear. This was treated with an ossiculoplasty at age 7 years. He was referred to a craniofacial unit at the age of 5 and because of his facial appearance was diagnosed as Binder syndrome. He was treated at the age of 8 with a bone graft to raise the nasal bridge, with a good cosmetic result.

The patient was further evaluated at the age of 13 years as part of a study of Binder syndrome. At this visit a pregnancy history was taken and it was found that the mother had multiple venous thromboses and was treated with warfarin throughout her pregnancy with this child. He still had the facies of Binder syndrome with a shortened columella, maxillary flattening and absence to palpation of the anterior nasal spine of the maxilla. General physical examination was normal and he was on the 10th percentile for height. He had normal speech and attended year 8 at a normal school.

Case 2: The patient was diagnosed as Binder syndrome by a maxillofacial surgeon during early adolescence when she complained about her facial appearance. A class 3 malocclusion was treated orthodontically and she had plastic surgery to improve the appearance of her nose. Concern about her appearance prompted genetic counselling in late adolescence. She was distressed by the high recurrence risk given which was based on a diagnosis of autosomal dominant mild type chondrodysplasia punctata and she sought further advice.

In the subsequent counselling it was established that whilst pregnant with this patient the mother had ruptured a cerebral aneurism at 6 weeks gestation and was placed on intramuscular phenytoin 100 mg tds prior to neurosurgery. This medication was resumed in oral dose postsurgery and was continued throughout pregnancy. The patient was born at term and weighed 3100 g. There was no bleeding diathesis at birth, and she was given routine 1 mg vitamin K1. She was the last of 8 children. The family history showed the siblings and extended relatives were all of normal appearance. Pictures supplied by the patient reveal that the Binder syndrome facial appearance was evident during her infancy (Fig. 7.1 c and d). Growth and development has been normal and she is completing tertiary education. Her only other abnormality is bilateral hypoplasia of the 5th fingernail. The patient was advised that based on the maternal medical history her facial features were most likely to be a consequence of the phenytoin treatment during that pregnancy.

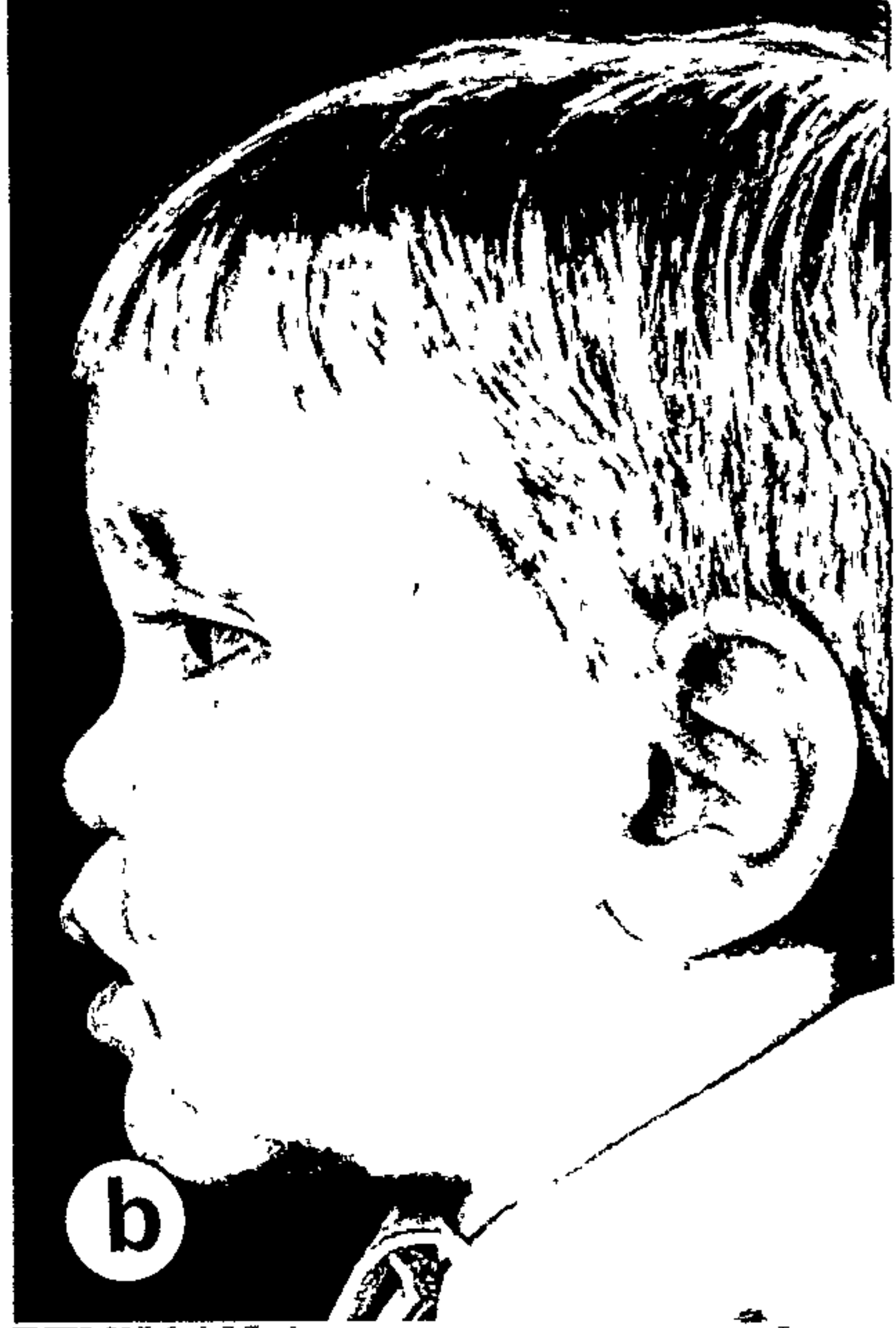Case 3: A male child aged 6 weeks with cystic fibrosis was referred from the Respiratory Medicine Unit to the Dymorphology Assessment Unit due to his facial appearance. The child was diagnosed as Binder syndrome on the basis of his facial appearance (Fig. 7.1e) which included maxillary hypoplasia and a small underdeveloped and upturned nose with a short columella. Skeletal X-rays showed punctate calcification in the knees and heels (Fig. 7.1f) which the radiologist described as chondrodysplasia punctata. The case is the first child of non-consanguineous parents and was born at 37 weeks gestation weighing 2130 g (3rd percentile), both his length and head circumference were on the 3rd percentile. Both parents had a medical history of alcohol abuse.

Figure 7.1

- a A frontal view of case 1. This photograph taken at 3 months of age shows the presence of the distinctive facial feature of a flattened nose with a rounded tip.
- b Lateral view of case 1 at 2 years 8 months of age. The nose is still short and flat with a rounded tip, the columella is short with a pouting upper lip.
- c and d Childhood pictures of case 2 prior to orthodontic and plastic surgery treatment. Note the short columella, short upturned nose and the appearance of a class III malocclusion due to the hypoplastic maxilla.
- e Lateral view of case 3 as a 10-week-old infant. Note the short columella, small upturned nose, depressed nasal bridge.
- f Radiograph of the foot of case 3 at 10 weeks. Note the punctate calcification in the heel of the foot.



a



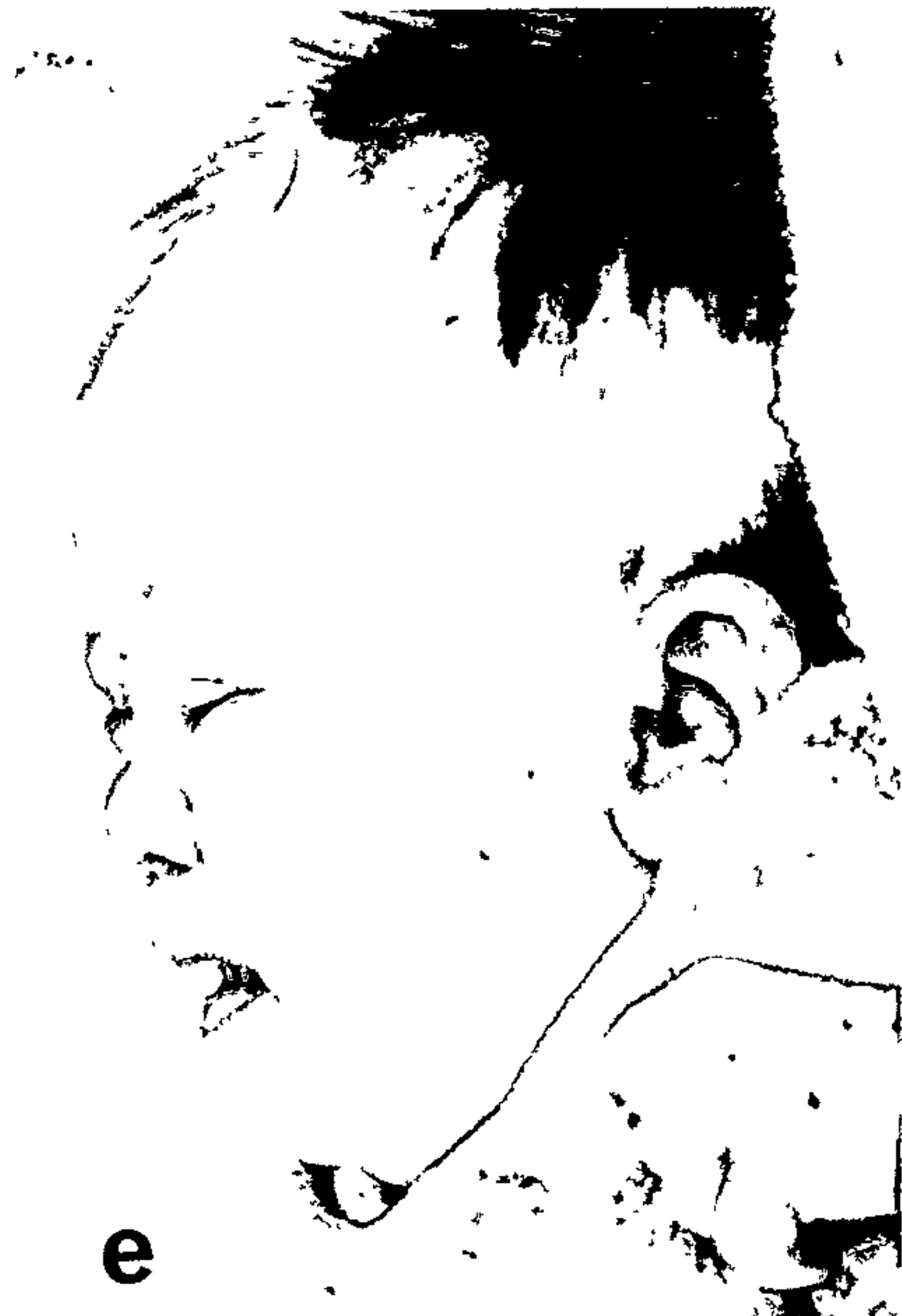b



c



d



e



f

7.2.1.3 DISCUSSION

The results of this study showed two interesting features; first that the features of maxillofacial hypoplasia were classified as either chondrodysplasia punctata or Binder's syndrome and second that maternal drug histories were not sought in considering the aetiology of the maxillofacial hypoplasia.

The first case shows the traditional confusion between warfarin embryopathy and hereditary chondrodysplasia punctata. This difficulty in classification is historical in origin. In 1971, after a review of the literature, Spranger and colleagues separated chondrodysplasia punctata into two types, the lethal rhizomelic type and the mild Conradi-Hunermann type (Spranger et al., 1971). There was evidence that these conditions were generally genetic in origin but many cases were sporadic and environmental causes were suggested. In 1975 two cases of the Conradi-Hunermann type were presented, the mothers of both patients had taken warfarin throughout pregnancy and it was suggested that this was the cause of the abnormal development (Becker et al., 1975). Subsequently, similar cases were reported by other investigators (Shaul et al., 1975; Pettifor and Benson, 1975; Pauli et al., 1976; Abbot et al., 1977;) and prenatal exposure to warfarin became an accepted cause of some cases of chondrodysplasia punctata or at least a phenocopy of chondrodysplasia punctata (Shaul et al., 1975; Hall, 1976; Raivio et al., 1977). The term warfarin embryopathy was gradually introduced for this phenotype and the expression "chondrodysplasia punctata due to warfarin exposure" has gradually disappeared (Holmes et al., 1972; Hall, 1976; Warkany , 1975; Hall et al., 1980).

A similar confusion is evident for phenytoin (Sheffield et al., 1976) and alcohol embryopathies (Badois et al., 1983; Leicher-Duber et al., 1990) since both can present with the chondrodysplasia punctata phenotype. If the maternal drug history is not obtained, or its significance is not appreciated, then the affected children may be diagnosed as chondrodysplasia punctata presumably of genetic origin.

The problem of classification is further compounded by the fact that some genetic counsellors still use the term chondrodysplasia punctata even

when there is a clear maternal history of exposure to phenytoin or warfarin (Sheffield et al., 1991). The real heterogeneity of chondrodysplasia punctata has been outlined (Pauli, 1988; Pozanski, 1994).

The confusion between chondrodysplasia punctata and Binder syndrome is a more recent development. Binder syndrome was first described in 1962 (Binder, 1962) as a condition characterised by a broad flat nose, horizontal nostrils, short columella, broad philtrum, pouting upper lip, marked groove at the nasiolabial junction and a concave profile. It is a diagnosis that has traditionally been used by orthodontists and oral surgeons because the hypoplastic maxilla leads to a class III malocclusion.

The diagnosis of Binder syndrome is now increasingly used by medical geneticists (Quarrell et al., 1990) following its inclusion in standard textbooks (Gorlin et al., 1976) and computerised data bases (Winter et al., 1984). It is generally considered to be a genetic disorder (Olow-Nordenram, 1987; Olow-Nordenram and Valentin, 1988) although some investigators (Delaire et al., 1970; Rival et al., 1974) mention medication during early stages of pregnancy as a possible cause.

The facial features of Binder syndrome are relatively non-specific and it is difficult to differentiate them from the facial features of chondrodysplasia punctata or any of its phenotypes due to maternal medication. Stippling is not described as a symptom, but this is not surprising because if the diagnosis is made by an orthodontist the child would be too old to show stippling.

It is hypothesised that Binder syndrome is not a separate entity but is the later presentation of chondrodysplasia punctata or its phenocopies. In one study of six patients who had been diagnosed in adolescence as Binder syndrome, five were found to have neonatal radiographs showing punctate calcification, the sixth patient had been exposed to warfarin prenatally and was assumed to have had stippling (Sheffield et al 1991). The three cases presented illustrate the interrelationship between Binder syndrome and chondrodysplasia punctata and the significance of the maternal drug history.

7.2.2 STUDY 2

7.2.2.1 Case sources

Patients with significant facial anomalies who had been exposed to phenytoin in prenatal life were obtained through contact with clinical staff at the Australian Craniofacial Unit, Genetics and Dysmorphology Unit at Children's Hospital Camperdown, Sydney, NSW and the Murdoch Institute, Royal Children's Hospital, Melbourne, Victoria.

7.2.2.2 Case reports (summarised in Table 7.1)

Case 1

This girl was the first child of non-consanguineous Caucasian parents. The mother was 25 years and the father 45 years of age at the time of birth. The mother has epilepsy and was treated throughout pregnancy with phenytoin, primidone, valproate and nitrazepam. Birth was at 37 weeks gestation by Caesarean section because of growth retardation. Birth weight was 1797g and Apgar scores were 4 at 1 minute and 8 at 5 minutes. There was respiratory distress requiring oxygen therapy for three days.

As well as being small for gestational age, the child had dysmorphic features comprising proptosis, a small flattened nose, hypoplastic finger nails and abnormal dermatoglyphics. Chromosome analysis showed a normal female karyotype. Skeletal radiographs demonstrated stippling and the child was diagnosed as chondrodysplasia punctata due to phenytoin exposure. Slow feeding was a problem in the first few weeks of life. A left inguinal hernia was repaired at 7 weeks of age.

She was referred to the Australian Craniofacial Unit at 5 years of age. Height, weight and head circumference were all less than the third centile. Craniofacial radiographs demonstrated a trigonocephalic skull with premature fusion of the coronal and sagittal sutures. The supra-orbital and infra-orbital margins were hypoplastic resulting in proptosis. The palpebral fissures were up-slanting and she had telecanthus and hypertelorism. The nose was flattened and broad with a short columella (Figs. 7.2 a, b and c). Mid-face hypoplasia was present and associated with class III malocclusion and an open anterior bite. Additional features

comprised a wide mouth, short neck, bilateral clinodactyly of the little fingers and terminal digital hypoplasia of all fingers with small fingernails. Developmentally she was functioning in the low/average range (IQ 80-89).

Case 2

This patient is the brother of case 1. He has mild craniofacial features consistent with chondrodysplasia punctata and terminal digital hypoplasia. The mother took the same anticonvulsants in his pregnancy as she had in case 1.

Case 3

The mother was on phenytoin (300 mg) and phenobarbitone (60 mg). The patient was a dizygotic twin and presented in the neonatal period with pulmonary atresia, patent ductus arteriosus and nail and terminal phalangeal hypoplasia (Loughnan et al., 1973). She failed to thrive and after radiological examination in the neonatal period was diagnosed as chondrodysplasia punctata (Sheffield et al., 1976). She had nasal hypoplasia and subsequently required plastic surgery. When she was reviewed at 17 years she still had a mild degree of facial flattening of a Binder type and obvious digital hypoplasia. She was less than 3rd percentile for height.

Case 4

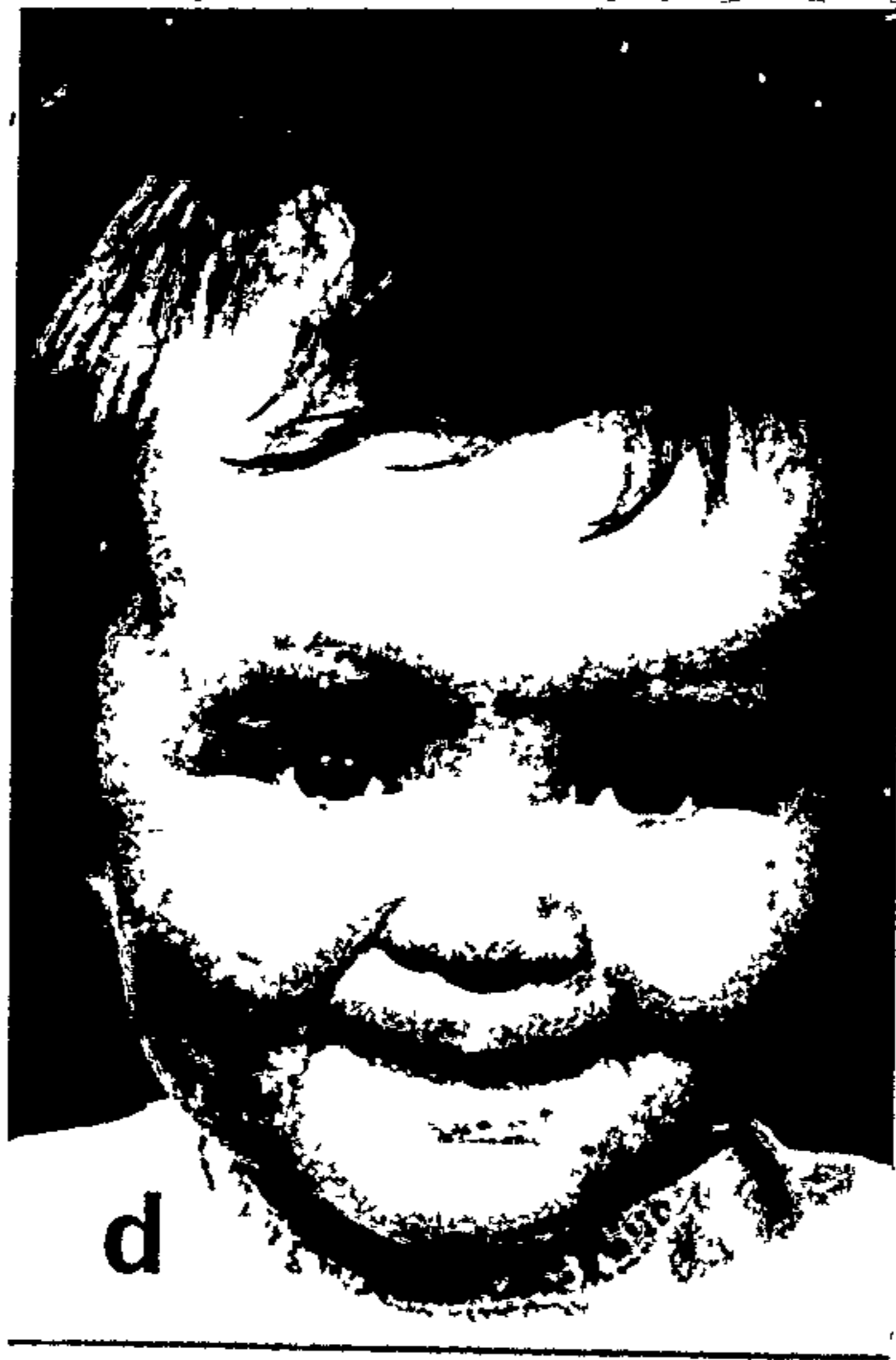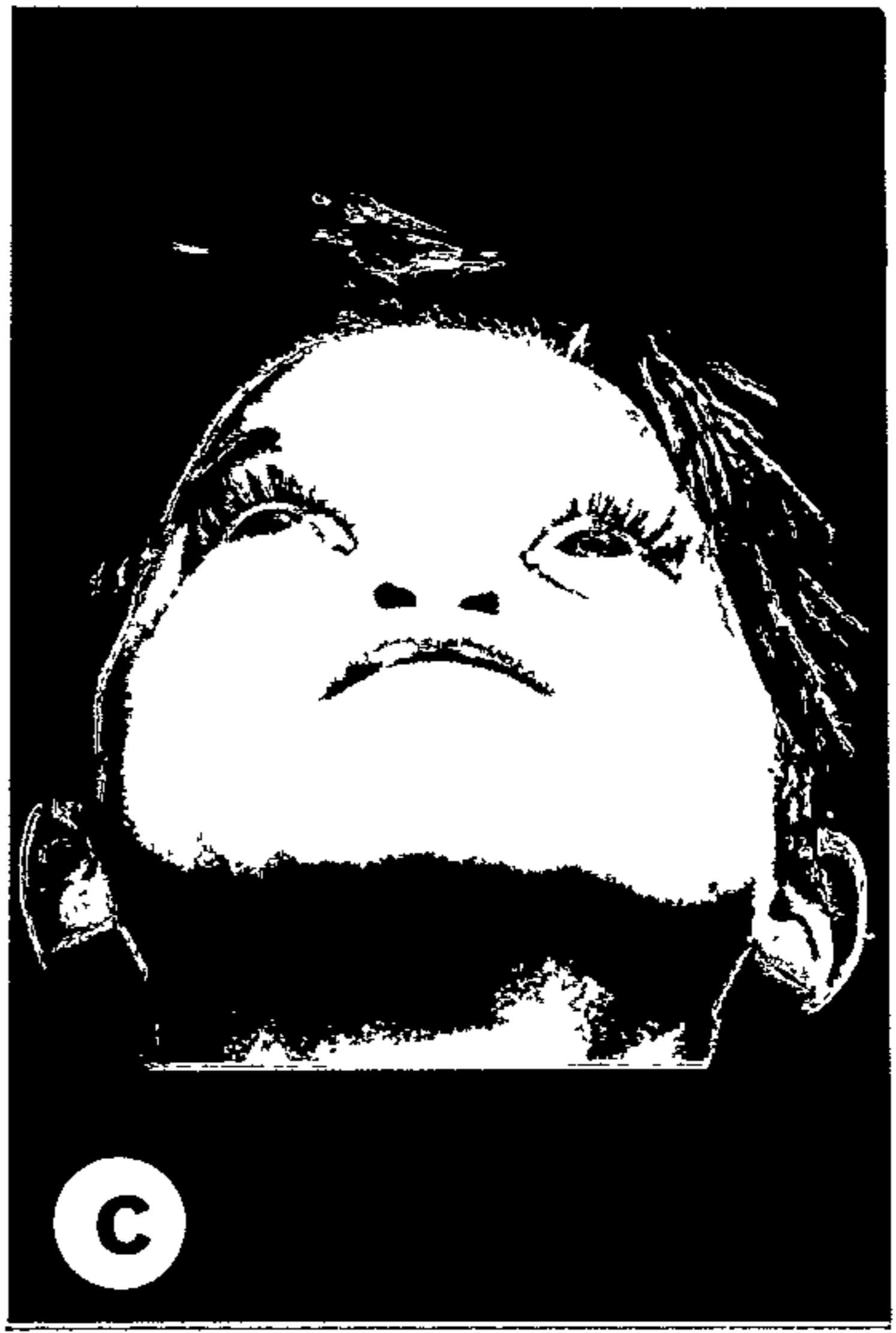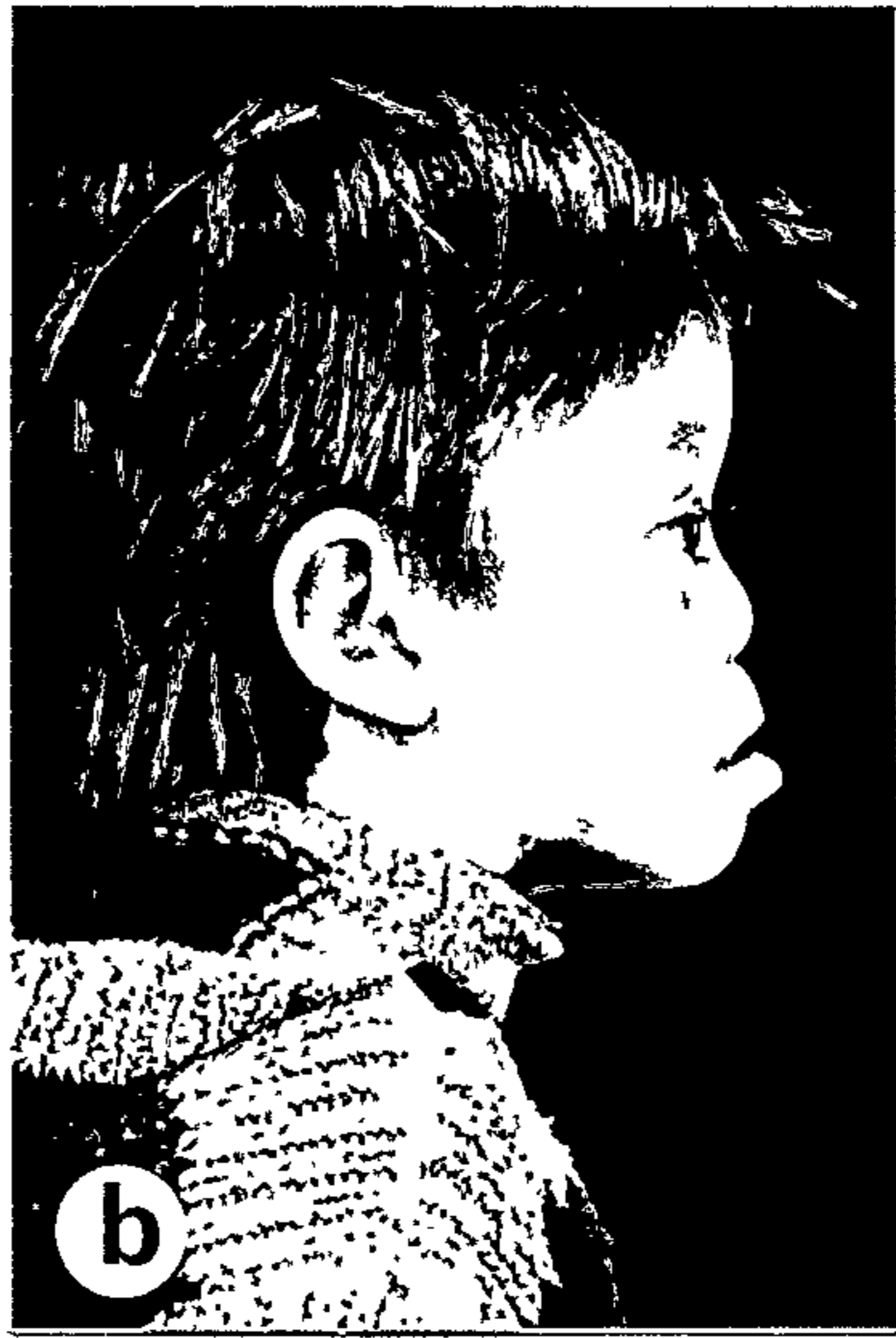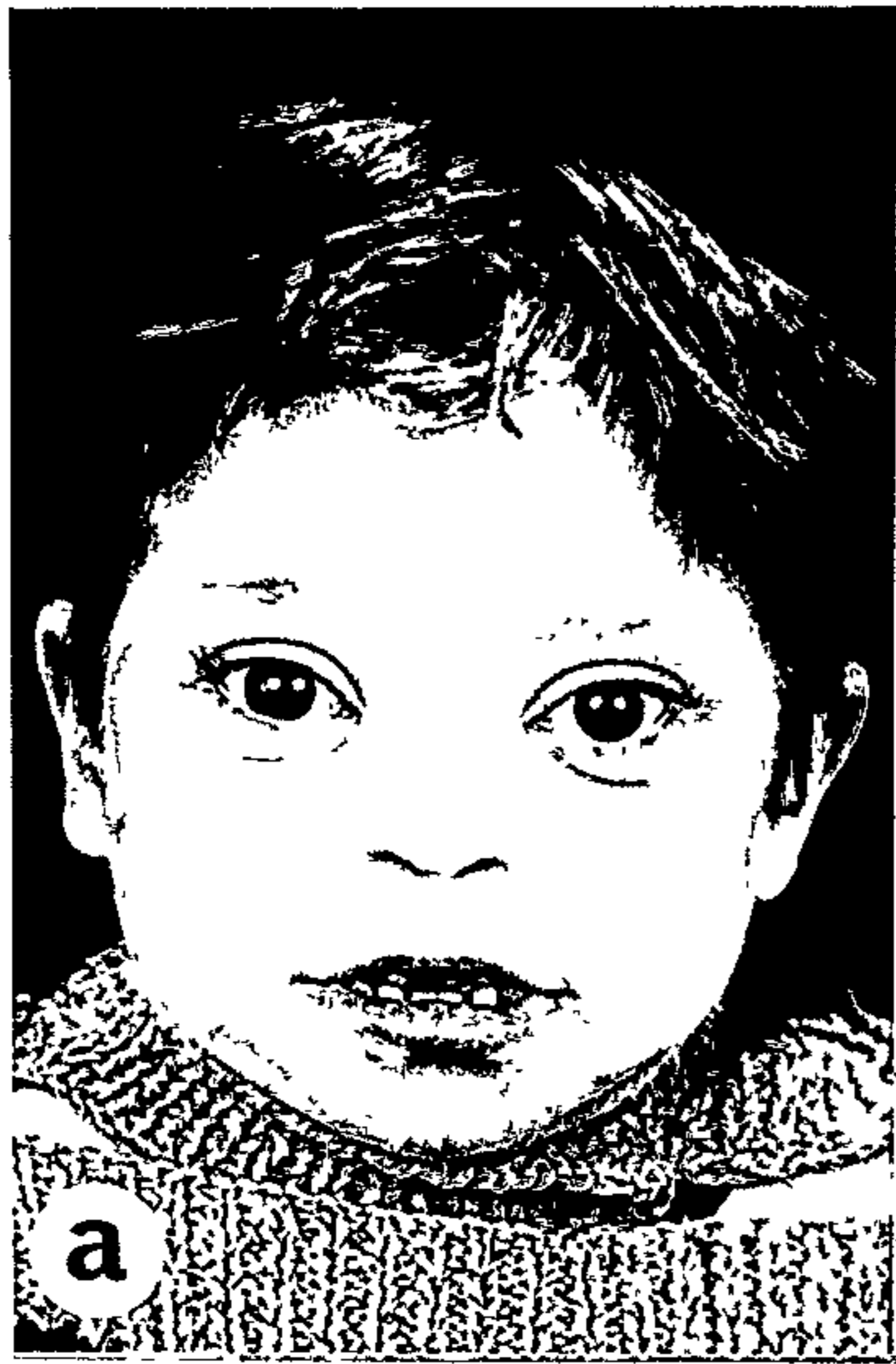This patient was the dizygotic twin sister of case 3. Unlike her sister she did not 'fail to thrive' and was not examined radiographically until 2 years of age. No stippling was observed. At this age she clearly had nasal hypoplasia and subsequently required plastic surgery. When she was seen at 17 years she still had mild facial flattening and patchy nail and digital hypoplasia. She was 10th percentile for height.

Case 5

Diagnosed as a baby as mild-type chondrodysplasia punctata (Fig. 7.2d) with digital hypoplasia (Sheffield et al., 1976) The mother received phenytoin, clonazepam and sulthiame during pregnancy. When the child was seen at 14 years age she had mild Binder changes (Fig. 7.2e). Her height was 25th percentile and she was at a normal school.

Figure 7.2

- a. - Case 1 age 5 years, apparent from the anterior view this child shows flat nasal bridge and apparent hypertelorism and mandibular prognathism.
- b. - Case 1 lateral view demonstrates the nasal hypoplasia, small columella and accompanying severe midfacial hypoplasia.
- c. - Inferior view of nose of case 4 showing the short columella.
- d. - Case 3 seen as an infant. Moderate nasal hypoplasia, extent of midfacial hypoplasia is not known as a lateral photograph is not available.
- e. - Case 3 seen at 12 years age. Lateral view at this age shows slightly hypoplastic nose, short columella and mild midfacial hypoplasia.
- f. - Case 9 seen at age 12 years. Lateral view shows mild prognathism, associated with a mild midfacial hypoplasia. The nose is short, upturned with a reduced columella.
- g. - Inferior view of the nose of case 9 showing the reduced columella and distortion of the external nares.



Cases 6-9

Three of the remaining four cases were diagnosed as chondrodysplasia punctata on the basis of their facial appearance and the radiological demonstration of punctate calcification. One was diagnosed on the basis of his facial appearance alone. All of these infants were seen as older children or adults and were noted to have the facial appearance of Binder's syndrome (eg. Figs 7.2 f and g show patient 9).

7.2.2.3 DISCUSSION

The facial features are only part of the phenytoin embryopathy and are considered by some investigators to be a minor feature of little consequence (Gaily and Granstrom, 1992; Delgado-Escueta and Janz, 1992). The 9 cases in the current study, show that prenatal exposure to phenytoin, either alone or in combination with other anticonvulsants, can result in significant facial appearance problems, some severe enough to require reconstructive surgery. Case 1 has nasal hypoplasia that is comparable in severity to the severest cases of warfarin embryopathy while the other cases would be classified as only moderate or minor hypoplasia. There is without doubt a similar range of severity amongst warfarin-exposed cases (eg. Wong et al., 1993) with only the most severe cases illustrated in the literature.

The incidence of maxillofacial hypoplasia following prenatal exposure to phenytoin is difficult to determine. In a cephalometric study of children aged 4 to 10 years who had been exposed to phenytoin prenatally, measurements showed that all of the children had reduction in the size of the nose and midface although the changes were not evident from external measurements (Van Lang et al., 1984).

It is proposed that maternal phenytoin therapy causes prenatal vitamin K deficiency resulting in symptoms of the warfarin embryopathy superimposed on other teratogenic effects of phenytoin (e.g. facial clefting, heart defects). The association between phenytoin and vitamin K deficiency was first emphasised by Keith and Gallop (1979). They suggested that phenytoin crossed the placenta and induced fetal

microsomal enzymes resulting in increased oxidative degradation of vitamin K, leading to a vitamin K deficiency.

The evidence for this hypothesis is firstly that prenatal phenytoin exposure can cause neonatal vitamin K-responsive hemorrhage. A number of reports had shown that maternal use of anticonvulsants during pregnancy caused a coagulation defect in about 50% of newborns (Mountain et al., 1970; Solomon et al., 1972; Bleyer and Skinner, 1976). Later studies confirmed this association (Srinivasan et al., 1982 Gimovsky and Petrie, 1986; Moslet and Hansen, 1992), and showed that phenytoin-induced hemorrhage is vitamin K-responsive (Deblay et al., 1982).

Further support for the hypothesis is that the phenytoin and warfarin embryopathies have common features of maxillofacial and digital hypoplasia and radiographic skeletal stippling. These features and neonatal hemorrhage were reported in a child with genetic vitamin K deficiency and no teratogen exposure (Pauli et al., 1988). Five of the phenytoin cases reported in this study (Table 7.1) had digital hypoplasia and stippling was present in the 6 cases which had neonatal radiographs.

Similarly to the cases reported in study 1 despite the medical history of phenytoin exposure, none of the patients was primarily classified as having phenytoin embryopathy and most were originally diagnosed as chondrodysplasia punctata.

7.2.3 STUDY 3

7.2.3.1 Case sources and materials and methods

Patients for this project were pregnant women at King George V Hospital, Camperdown, Sydney. Cord blood was collected from the placenta at the time of parturition from women who had received anticonvulsant therapy during pregnancy and from a similar number of women not receiving anticonvulsant therapy (controls). The histories of these patients were viewed to ascertain any drugs or condition which may affect vitamin K levels.

Blood was also collected from adult warfarin patients with known clotting times to examine the interrelationship between vitamin K deficiency and prothrombin. One adult control was also obtained.

A pooled sample of blood from 5 adults not receiving anticoagulant therapy was used as a standard.

Blood samples were collected in warfarinised glass tubes and stored at 4°C. The blood was subsequently spun at 3000 rpm for 10 minutes at 4°C and the plasma stored at -20°C.

Total prothrombin was measured by the method of Suttie published by Harauchi and colleagues (1985). The rationale of the assay is conversion of all prothrombin in the plasma into thrombin by activation with snake venom (*Echis carinatus*). The thrombin is then incubated with a chromogenic substrate and its activity measured with a spectrophotometer.

Method

Add 50µl of sample plasma to 0.8ml of 0.1 M Tris buffer with 0.2 % BSA (buffer A) and heat to 37°C. To this solution add 5µl of venom and incubate for 60 seconds at 37°C to convert the prothrombin and PIVKA to thrombin. One hundred µl Th-1, a chromogenic substrate specific for thrombin, is then added and the mixture was incubated for 120 seconds at 37°C. The amount of p-nitroaniline generated from the substrate was

measured spectrophotometrically at 405 nm against a water blank at 60, 90 and 120 seconds and the mean recorded.

Standard

Pooled plasma from 5 control adults was used as a standard and the amount of p-nitroaniline generated was regarded as 100 U/ml.

PIVKA

Serum PIVKA was measured by a commercially available enzyme immunoassay (Eitest MonoP-II Eisai Co., Ltd., 5-5, Koishikawa 5-chome, Bunkyo-ku, Tokyo 112-88 JAPAN) and has been used previously for the measurement of human PIVKA (Motohara et al., 1985).

Method

All solutions, standard prothrombin, PIVKA and antibodies are supplied in the kit as are the cups in which all reactions are performed.

Twenty-five μ l of 0.05 M tris-(hydroxymethyl)-aminoethane-buffer containing 10% rabbit serum solution was added to each supplied cup (the cups contain anti-PIVKAI mouse monoclonal antibody). To each cup 100 μ l each of the sample plasma was added and the cups were incubated in a moist box at 20°C for 2 hours. Following incubation the cups were washed with 0.9% saline containing 1% polyoxyethylene sorbitan monolaurate and the wash discarded. To the cups 100 μ l of enzyme-labelled antibody (anti-prothrombin polyclonal antibody labelled with peroxidase concentration 40E.U.) solution was added and the cups again incubated for 1 hour at 20°C in a moist box. Following incubation the cups were washed with 0.9% saline containing 1% polyoxyethylene sorbitan monolaurate and the wash discarded and 100 μ l of 3% hydrogen peroxide solution was added to each cup and again incubated for 1 hour at 20°C. Following incubation 100 μ l of the stop solution (2mM sodium azide) was added. The resultant 200 μ l were measured spectrophotometrically at 405 nm against a water blank. For PIVKA range 2-8 AU/ml reading were at 10 minutes and for PIVKA range 0-2 AU/ml reading were at 1 hour.

A standard curve was plotted using readings obtained from samples with a known PIVKA concentration. Samples were measured in duplicate, to a cup 100 μ l of each standard antigen solutions (lyophilized product of human plasma containing PIVKAI concentration of 8AU/ml, 2AU/ml, 0.5 AU/ml, 0.125 AU/ml and 0.065 AU/ml respectively) and a 100 μ l of blank solution (standard antigen solution diluent containing lyophilized product derived from 2 ml of normal human plasma) was added and the cups treated in the same manner as the cups containing the sample plasma.

The readings from the sample sera were read against the standard curve and the result expressed in arbitrary units (AU), 1AU corresponds to 1 μ g of purified prothrombin (Motohara et al., 1985a).

Statistics The results of control neonates and anticonvulsant neonates cord plasma were analysed by student's t-test, unpaired.

7.2.3.2 RESULTS

Cord blood samples

Total prothrombin and PIVKA were measured in cord plasma from 11 newborn infants whose mothers did not take anticonvulsant drugs during pregnancy (controls) (Table 2) and from 12 infants exposed to antiepileptic drugs during pregnancy (Table 3). Six of the control samples contained detectable PIVKA and 7 of the anticonvulsant group. The levels of PIVKA in controls ranged from 0.18 - 4.43 AU/ml and in the anticonvulsant group from 1.09 - 26.23 AU/ml. The mean level of PIVKA in the anticonvulsant group, excluding the valproate case, was 6.64 ± 8.44 and this was significantly greater than the levels in the controls (0.65 ± 1.30).

Total prothrombin ranged from 21-87 U/ml in the controls and in the anticonvulsant group from 17-51U/ml. The mean level of total prothrombin, excluding the valproate case, was 34 ± 8 . which was significantly less than the levels in the controls (48 ± 21).

Total prothrombin, PIVKA and prothrombin time (PT) were also measured in 9 adults receiving warfarin as anticoagulant therapy and in one control adult (Table 4). All of the warfarin samples showed high levels of PIVKA (mean 18.0). Total prothrombin was less than half (43) the pooled adult control value of 100 U/ml. Normal prothrombin time (PT) (blood clotting time) is about 12 seconds, the warfarinised plasma ranged from 28 to 76 seconds. The PT was not obviously directly correlated with either the PIVKA levels or total prothrombin.

Table 7.2 - Prothrombin and PIVKA concentrations in control cord plasma

Subject	Total Generated Prothrombin ¹ (U/ml)	PIVKA II ² (AU/ml)
1	29	ND*
2	50	ND*
3	42	0.46
4	30	4.43
5	33	0.37
6	40	ND*
7	21	ND*
8	76	0.18
9	60	ND*
10	87	0.68
11	58	0.85
Mean ± S.D.	48± 21	0.64±1.30

¹100U is the amount of prothrombin (normal and PIVKA) present in pooled control adult plasma

²1AU is an arbitrary unit equivalent to 1 µg PIVKA/ml plasma

* below the level of detection 0.13AU/ml

Table 7.3 - Prothrombin and PIVKA concentrations in cord plasma from the offspring of women receiving anticonvulsants during pregnancy

Case	Drug taken and dose when recorded	Total Generated Prothrombin ¹ (U/ml)	PIVKA II ² (AU/ml)
1	carbamazepine (100mg/2 days)	38	ND*
2	carbamazepine	30	15.18
3	carbamazepine	33	9.04
4	carbamazepine	38	ND*
5	carbamazepine phenytoin	29	1.84
6	carbamazepine	17	9.91
7	carbamazepine	32	26.23
8	carbamazepine (600mg/day) phenytoin (250mg/day)	35	ND*
9	phenytoin	32	ND*
10	phenytoin (250mg bd) sabril(1500mg bd)	46	9.74
11	phenytoin	42	1.09
12	valproic acid	51	ND*
	Mean±SD excluding case 12	34±8 ³	6.64±8.44 ³

¹100U is the amount of prothrombin (normal and PIVKA) present in pooled control adult plasma

²1AU is an arbitrary unit equivalent to 1 µg PIVKA/ml plasma

³Significantly different from control values in Table 7.2 P<0.05

* below the level of detection 0.13AU/ml

Table 7.4 - - Prothrombin and PIVKA concentrations in plasma from 1 control adult and 9 adults receiving warfarin anti-coagulant therapy

subjects	clotting time (PT) ³ seconds	Total Generated Prothrombin ¹ (U/ml)	PIVKA II ² (AU/ml)
control	12.1	87	ND*
warfarin 1	27.8	46	16.94
warfarin 2	27.8	46	16.94
warfarin 3	30.6	40	7.24
warfarin 4	31.7	44	18.50
warfarin 5	35.9	40	23.79
warfarin 6	36.4	44	18.63
warfarin 7	36.4	42	14.86
warfarin 8	40.5	43	21.50
warfarin 9	57.7	33	28.95
warfarin 10	75.7	51	18.03
warfarin mean \pm S.D.	40.1 \pm 15.2	43 \pm 5	18.00 \pm 6.01

¹100U is the amount of prothrombin (normal and PIVKA) present in pooled control adult plasma

²1AU is an arbitrary unit equivalent to 1 μ g PIVKA/ml plasma

³PT = partial prothrombin clotting time

* below the level of detection 0.13AU/ml

7.2.3.3 DISCUSSION

Compared with other fat soluble vitamins (A, D and E), plasma vitamin K levels in the human are extremely low, in the picogram range (Suttie, 1991). Levels in the fetus and newborn are 10-20 fold lower and in many instances are below the level of detection using the most sensitive analytical methods available (HPLC) (Cornelissen et al., 1993).

An alternative method for assessing vitamin K status is to measure the blood component known as PIVKA II. When prothrombin is first formed in the liver it contains 10 glutamic acid residues which need to be carboxylated to form fully functional prothrombin. As discussed previously this is a vitamin K-dependent process. In vitamin K deficiency the prothrombin either remains uncarboxylated or is only partially carboxylated and is known as PIVKA II (Protein Induced by Vitamin K Absence). The amount of PIVKA II in the blood is a measure of vitamin K deficiency. Prothrombin containing only 7 carboxylated residues had 4.4% of the activity of normal prothrombin and prothrombin with only 4 carboxylated residues had only 1% of normal activity (Esnouf and Prowse, 1977). Patients administered warfarin have prothrombin showing different degrees of carboxylation (Esnouf and Prowse, 1977; Friedman et al., 1977).

In the 1980s a Japanese group led by Prof. Motohara developed a monoclonal antibody that solely reacts with the abnormal form of prothrombin (PIVKA) and does not crossreact with normal prothrombin. Since there are 10 gla residues on prothrombin there can be many different forms of PIVKA ranging from 1 to 10 non-carboxylated residues. The antibody, which was used in the current study, was demonstrated to have a higher affinity for prothrombin possessing fewer carboxylated residues (Motohara et al., 1985). Hence the PIVKA value, which is expressed in arbitrary units, always underestimates the total amount of partially carboxylated prothrombin. One arbitrary unit corresponds to 1 µg of purified prothrombin (Motohara et al., 1985a).

PIVKA levels in control neonates

Normally PIVKA is not found in adult plasma but it does occur in a proportion of apparently normal neonates. In one study of 51 newborn blood samples from Japan, using the same assay as in the present study, 21.5% exhibited PIVKA ranging from 0.13 to 1 AU/ml (Motohara et al., 1985a). In another study from the Netherlands, again using the same assay, PIVKA was detected in 31% (5 out of 16 cord blood samples), the range was 0.22 to 3.86AU/ml (Widdershoven et al., 1988). In the current study PIVKA was detected in 54% of control newborn (6 out of 11 samples).

PIVKA levels in neonates from anticonvulsant exposed pregnancies

Seven out of 12 cord plasma samples from anticonvulsant exposed pregnancies showed PIVKA. This incidence was not significantly increased over controls. However, the amount of PIVKA was significantly increased with some values as high as those seen in adults treated with warfarin. Six of the anticonvulsant group were treated with carbamazepine alone and four showed high PIVKA levels (9.04 - 26.23). Two were treated with phenytoin alone, one showed a low level of PIVKA. One case was exposed to valproic acid alone; this case did not have detectable PIVKA. Three of the cases were exposed to two anticonvulsants and 2 of these showed PIVKA (phenytoin and sabril - 9.74 and carbamazepine and phenytoin 1.84). Neonates with PIVKA levels above 20 AU/ml are considered to be at risk of bleeding due to vitamin K deficiency (Motohara et al., 1987).

The results of the present study are similar to those obtained from a study in the Netherlands. Using the same PIVKA assay the investigators measured PIVKA levels in cord plasma from 24 anticonvulsant exposed pregnancies and 25 controls. PIVKA was detected in five of the control samples (0.14-0.28) and 13 of the anticonvulsant group (Cornelissen et al., 1993b). As in the present study the levels in the anticonvulsant group were much higher than those in the controls. The 6 cases exposed to carbamazepine alone had levels ranging from 0.14 - 4.54, 4 cases were exposed to phenobarbitone alone (0.1-1.02), 1 case was exposed to phenytoin alone (1.47). The investigators attempted to correlate PIVKA

levels with vitamin K1 levels in the cord plasma but vitamin K levels were below the level of detection in 12 out of 13 samples from the anticonvulsant group and 3 out of 5 control samples.

PIVKA levels and total prothrombin

The studies by Motohara and colleagues have concentrated on measuring PIVKA and in some instances have attempted to relate PIVKA levels to the risk of neonatal hemorrhage. Studies on warfarin-treated adults have shown that increased PIVKA levels are only one aspect of the prothrombin changes induced by vitamin K deficiency, total prothrombin levels can also be dramatically affected and this may be related to changes in clotting ability of the blood.

In 23 adults receiving warfarin, total prothrombin ranged from 39 to 87 $\mu\text{g}/\text{ml}$ (mean 64 ± 13) compared with 108 $\mu\text{g}/\text{ml}$ in controls (Blanchard et al., 1981). In another study of 15 adults receiving warfarin total prothrombin ranged from 50.1 to 112.4 $\mu\text{g}/\text{ml}$ (mean 80.5 ± 18.2) compared with 106 $\mu\text{g}/\text{ml}$ in controls (Motohara et al., 1985a). Hence warfarin-induced vitamin K deficiency appears to reduce the total prothrombin present in plasma as well as decreasing the amount that is carboxylated. These findings were confirmed in the current study of warfarin-treated adults where mean total prothrombin was only 43% of pooled-control levels. The relative contributions of reduced total prothrombin and PIVKA to blood clotting is not clear. In the warfarin-treated adults there is no obvious correlation between blood clotting time (PT) and total prothrombin, PIVKA or active prothrombin (total prothrombin minus PIVKA). The reason for this is likely to be the lack of sensitivity of the PT test for assessing vitamin K deficiency. In contrast a good correlation was noted between active prothrombin and F-II coagulant activity (Motohara et al., 1985a).

Total prothrombin in cord plasma sample

The 11 control cord plasma samples showed total prothrombin levels of only 48% of adult levels. This is in agreement with a figure of 40% reported in 18 normal neonates (Pietersma-de Bruyn et al., 1990) and 48% in 118 day one infants (Andrew et al., 1987). Adult prothrombin levels are

not reached until 2 - 12 months (Bleyer et al., 1971; Andrew et al., 1987). There appear to be two theories that account for these physiological low levels of prothrombin at birth, (1) that they are due to immaturity of the fetal liver or (2) they are caused by the relative vitamin K deficiency seen in the newborn as seems to be the case for PIVKA.

Studies in adult rats given a single dose of warfarin show that as the plasma and liver vitamin K levels drop, PIVKA levels increase and total prothrombin levels decrease (Yamanaka et al., 1990). These results suggest that PIVKA levels and prothrombin levels are vitamin K dependent.

In the anticonvulsant exposed newborn total prothrombin levels were significantly lower than newborn controls at 35% of adult levels. The six carbamazepine samples were at the lower end of the range. Since many of these anticonvulsant samples also had high PIVKA levels the amount of active prothrombin is particularly low. For instance cases 6 and 7 would have active prothrombin levels of 7 and 6 respectively compared with 48 in control cord plasma and 100 in control adult plasma.

This is the first report of total prothrombin levels in cord plasma following anticonvulsant exposure during pregnancy. The reduced level of total prothrombin combined with increased PIVKA would support the reports of increased risk of neonatal bleeding in children born to women taking carbamazepine (Mountain et al., 1970; Wajtl et al., 1974; Srinivasan et al., 1982) or phenytoin (Mountain et al., 1970; Solomon et al., 1972; Bleyer and Skinner, 1976; Srinivasan et al., 1982; Gimowsky and Petrie, 1986; Moslet and Hansen, 1992). The phenytoin-induced hemorrhage has been shown to be vitamin K-responsive (Deblay et al., 1982).

How do anticonvulsants cause vitamin K deficiency?

The reasons why carbamazepine and phenytoin cause vitamin K deficiency in the fetus are essentially unknown. It is known that both carbamazepine and phenytoin induce mixed-function oxidase enzymes in maternal and fetal liver. This may result in increased oxidative degradation of vitamin K, leading to vitamin K-deficiency in both the

adult (Davies et al., 1985; Cornelissen et al., 1993a, b) and fetus (Keith and Gallop, 1979; Cornelissen et al., 1993a, b).

Although only one case in this study was exposed to valproic acid the prothrombin level 0.51 U/ml and the absence of PIVKA confirmed the results of Cornelissen et al., (1993) and is in agreement with the fact that valproic acid does not induce mixed function oxidase enzymes (Perucca et al., 1984).

Vitamin K Supplementation

A number of investigators have proposed that pregnant women on anticonvulsants should receive vitamin K supplementation towards the end of gestation in an attempt to prevent hemorrhage in their offspring (Bleyer et al., 1976; Gimowsky and Petrie, 1986; Moslet and Hansen, 1992; Cornelissen et al., 1993). The possibility that supplementation might also prevent aspects of the phenytoin embryopathy (maxillonasal hypoplasia) was first suggested by Hall et al [1980] but seems to have gone unheeded. Vitamin K supplementation would not be expected to have any effect on the efficacy of anticonvulsant therapy. Second trimester oral supplementation with vitamin K1 (20 mg/day for 3 days) has been shown to increase cord blood vitamin K levels 30-fold and maternal blood levels 144-fold. The duration of this elevation was not determined (Mandelbrot et al., 1988). Since the critical period for nasal septum development is the second half of the first trimester; vitamin K supplementation would need to be started pre-pregnancy or immediately pregnancy is detected. Maxillonasal hypoplasia is not always a minor anomaly and attempts should be made to prevent its occurrence.

7.3 CONCLUSION

In conclusion although this study failed to confirm that phenytoin causes increased levels of PIVKA it did show that carbamazepine does increase PIVKA significantly and decreased total prothrombin levels in the newborn cord plasma. These findings are consistent with induced vitamin K deficiency. The midfacial hypoplasia seen in studies 1 and 2 of this chapter are the predicted result of phenytoin-induced vitamin K

deficiency in the first trimester. Similar facial features have been associated with prenatal exposure to carbamazepine (Jones et al., 1989). Vitamin K supplementation may prevent the maxillofacial hypoplasia as well as the hemorrhage seen in fetal exposure to phenytoin, carbamazepine and phenobarbitone.

CHAPTER 8

8.1 THE WARFARIN EMBRYOPATHY

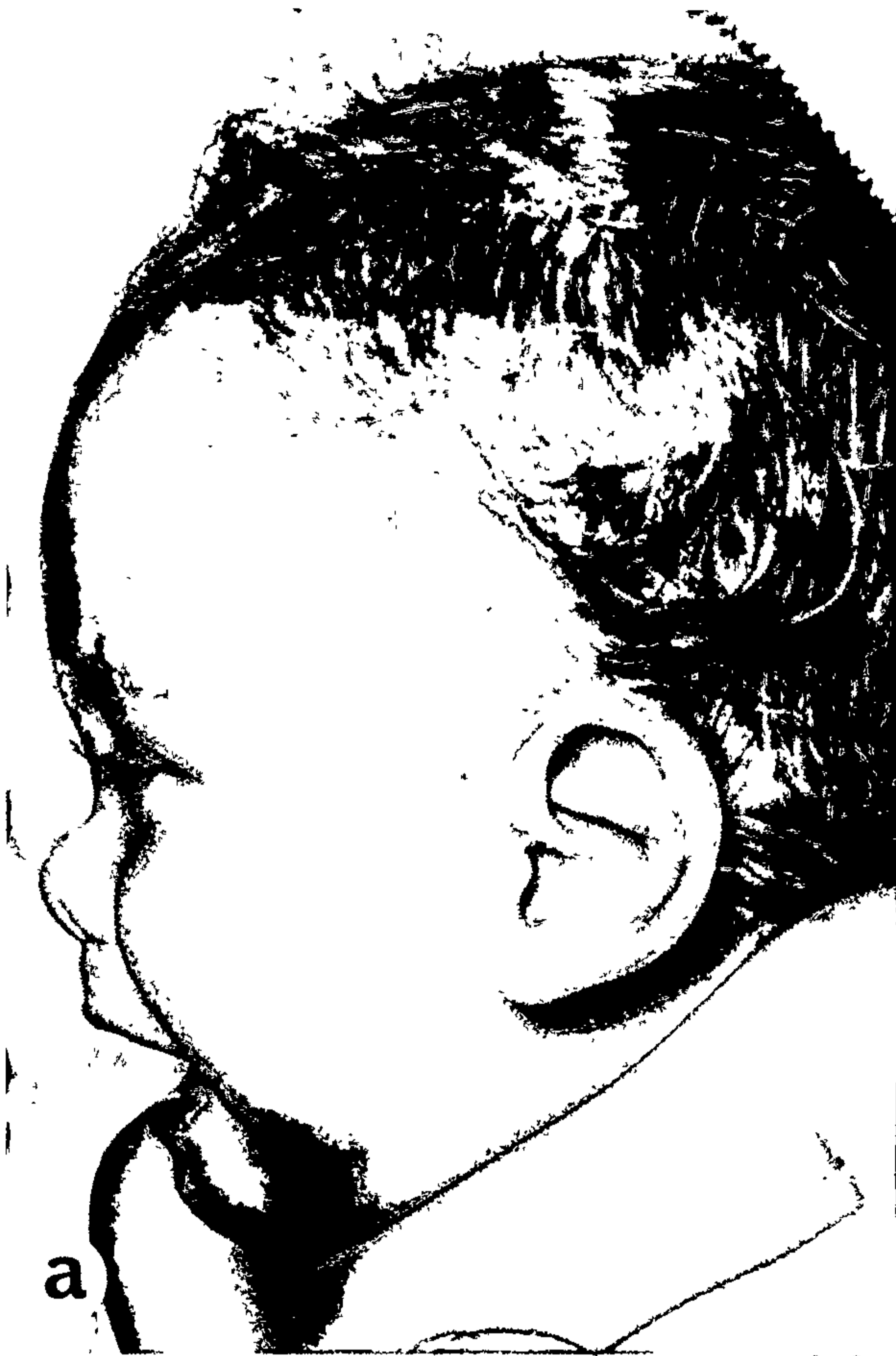
The animal model of the warfarin embryopathy presented in chapters 2 and 3 differentiated between the adverse effects due to bleeding and the skeletal effects. Exposure of pregnant rats to warfarin and vitamin K during the latter half of gestation reproduced the hemorrhagic features associated with second and third trimester exposure in the human. Similar treatment in the first 12 weeks of postnatal life reproduced the maxillofacial hypoplasia associated with first trimester exposure to warfarin.

Warfarin embryopathy has not previously had an animal model in which to examine the mechanism of its teratogenesis. Warfarin's teratogenesis has been established from clinical observation and the embryopathy has been associated occasionally with a range of congenital malformations (Schardein, 1993; Pauli, 1997). No other congenital abnormalities were seen following prenatal treatment despite a large number of treated-animals. This suggests that the isolated malformations reportedly associated with prenatal warfarin exposure are due to chance.

The consistent presence of nasal hypoplasia and ectopic calcification in the nasal cartilage of the postnatally-treated rats is strong evidence that interference with development of the cartilage of the nasal septum is the underlying pathogenesis of the dominant feature of warfarin embryopathy. In chapter 5 it was suggested that disturbed chondrogenesis caused the reduced growth of the cartilage and the subsequent calcification. Since matrix gla protein is the only known vitamin K-dependent protein in cartilage it is very likely that in its abnormal decarboxylated form it is the cause of this pathogenesis perhaps as indicated in chapter 5 by its involvement in chondrogenesis. The previous suggestion that bone gla protein (osteocalcin) may be involved (Hall et al., 1980) now seems very unlikely since it does not occur in cartilage and in genetically manipulated osteocalcin-deficient mice there was no skeletal-patterning defects and no ectopic bone formation (Ducy et al., 1996).

Figure 8.1

- a A 20-month-old child with the warfarin embryopathy.
- b Examined radiographically the same child (Fig. 8.1a) exhibits discrete ectopic calcification in the nasal cartilages (arrows). Extending from the bony nasal aperture there appears 'moth eaten' calcification, note the similarity with the alizarin stained rat nasal septum seen in figure 3.3b.



As shown in chapter 6 the developing human facial profile is dependent upon growth of the nasal septum, particularly during weeks 6 - 9 of gestation when it undergoes its most rapid increase in length. This is consistent with the calculated critical period of exposure for the development of the warfarin embryopathy (Hall et al., 1980).

Support for the validity of the animal model would be the demonstration of calcification in the nasal cartilages of neonates with the warfarin embryopathy. While 88% of such infants radiographed at the appropriate time show stippling in other parts of the body (Pauli, 1997) there has been only one previous case in which stippling in the nasal cartilages has been reported (Shaul et al., 1975) although Shaul and Hall (1977) implied they had seen nasal stippling in more than one case. The lack of reports of nasal stippling is probably due both to the failure to look for stippling in the nose and the difficulty in examining the nasal septum and alar cartilages in standard lateral X-ray films due to the nasal hypoplasia. There are no reports where stippling in the nose has been looked for but not found.

Recently our group (Howe et al., 1997) had the opportunity to examine a neonate who had been exposed to warfarin throughout pregnancy and had the warfarin embryopathy (Fig. 8.1a). Neonatal ultrasound examination suggested calcification in the nasal septum. When the child was examined radiologically at 20 months areas of calcification were visible in the septal and alar cartilages of the small external part of the nose (Fig. 8.1b). The location of this ectopic calcification is consistent with that seen in the animal model and provides support for the proposed pathogenesis.

In chapter 7 there were case reports showing that stippling and maxillonasal hypoplasia, similar to that seen in the warfarin embryopathy, were associated with prenatal exposure to phenytoin. It was proposed that phenytoin had this effect by causing a fetal vitamin K deficiency. This proposal was further investigated in a subsequent study in which vitamin K status in neonates, exposed to anticonvulsants during pregnancy, was assessed by measuring total prothrombin and PIVKA. The number of phenytoin cases examined was too small to provide much evidence of vitamin K deficiency but the study did provide strong evidence that carbamazepine causes severe deficiency.

8.2 IS THERE A VITAMIN K DEFICIENCY EMBRYOPATHY?

Warfarin has the sole pharmacological action of blocking vitamin K-reductase, which prevents vitamin K recycling and progressively lowers vitamin K levels. Low vitamin K levels in the mother and fetus as the cause of warfarin embryopathy have remained speculative. Firm support that vitamin K deficiency caused the warfarin embryopathy and not some other unknown property of warfarin came from a publication of a child born with what appeared to be warfarin embryopathy (stippling, nasal hypoplasia and digital hypoplasia) and vitamin K-responsive bleeding. The mother had not received anticoagulants or other vitamin K antagonists during pregnancy. The child was subsequently shown to have an inborn error of vitamin K-reductase which resulted in an effective vitamin K deficiency (Pauli et al., 1987). This genetic defect affected both hepatic and extra-hepatic vitamin K-reductase hence both the vitamin K-dependent blood clotting proteins and skeletal proteins would be non-carboxylated as occurs in the warfarin embryopathy. Five additional infants have now been recognised with this same reductase deficiency (Pauli, 1997).

Vitamin K status of the fetus.

Fetal levels of vitamin K are far lower than maternal levels and some authors have suggested that the fetus is constantly on the verge of deficiency (Israels et al., 1987). In women attending a prenatal clinic in Paris mean maternal plasma vitamin K levels were 565 pg/ml during midgestation (range 80 to 2,330) and 395 pg/ml at term (range 70 to 1780). Second trimester fetal blood samples gave an average concentration of 30 pg/ml and at birth the mean fetal blood level was 21 pg/ml (range 5 to 98) (Mandelbrot et al., 1988). In a second study pregnant women in Detroit had mean plasma levels of 102 ng/ml at term (range 1-1963) and fetal cord blood levels were 10 pg/ml (range 0-271) (Kazzi et al., 1990).

The reason for the large gradient between the maternal and fetal concentrations is unknown, but it appears to be physiological as, maternal vitamin K supplementation, while raising vitamin K levels, fails to

change the gradient (Mandelbrot et al., 1988; Kazzi et al., 1990; Cornelissen et al., 1993b).

The vitamin K status of the fetus is dependent on both placental transfer from the mother and its own ability to recycle vitamin K. For instance, the mother of the child with the vitamin K-reductase error (Pauli, 1988) presumably had normal vitamin K status and normal placental transfer. The pseudo-warfarin embryopathy in this child attests to the fact that recycling in the fetus is essential to maintain adequate vitamin K levels. Warfarin treatment affects maternal recycling and hence reduces the amount available for placental transfer as well as preventing recycling in the fetus.

Chondrodysplasia punctata has been reported in 3 infants whose mothers had malabsorption conditions. One mother had celiac disease, another short bowel syndrome following resection of the bowel and the third had jejuno-ileal by-pass for weight loss (Menger et al., 1997). The authors made the reasonable suggestion that the malabsorption resulted in vitamin K deficiency in the mother and subsequently the fetus.

Hence features of the warfarin embryopathy can be due to (a) vitamin K deficiency in the fetus alone (vitamin K reductase deficiency infant), (b) maternal deficiency with normal fetal recycling (malabsorption syndromes) or (c) fetal and maternal deficiency (warfarin).

Other possible causes of vitamin K deficiency.

As well as warfarin it appears that a number of other drugs can cause vitamin K deficiency. Most notably the anticonvulsants phenytoin, carbamazepine and phenobarbitone but not valproic acid. Other implicated drugs include rifampicin, isoniazid (Eggermont et al., 1976) and salicylates (Collins and Turner, 1975; Park and Leck, 1981). Antibiotics, possibly through their action on the microflora, in combination with a poor diet can produce vitamin K-responsive haemorrhage in adults (Pineo et al., 1973; Lipsky, 1983; Bechtold et al., 1984; Usui et al., 1990) and hence may also be risk factors in pregnancy.

Maternal alcoholism may also sometimes be associated with vitamin K deficiency either due to malabsorption or perhaps direct effects on epoxide reductase (Pauli, 1997). Vitamin K deficiency can also be caused by dietary restriction (Suttie et al., 1988) or bile production disorders (Poley and Humphrey, 1974; Corrigan, 1981; Penzias and Treisman, 1988).

More speculatively, the environmental pollutants polychlorinated biphenyls and dioxin have been suggested as possible causes of vitamin K deficiency (Koppe et al., 1989).

8.3 GENERAL CONCLUSION:

Since the features of the warfarin embryopathy are not unique to warfarin but may be seen after exposure to other drugs or conditions causing vitamin K deficiency it is proposed that the phenotype should be called vitamin K deficiency embryopathy when such an association is evident. This nomenclature would clearly identify the cause of this condition and emphasise its separation from the hereditary forms of chondrodysplasia punctata or Binder syndrome.

REFERENCES

Abbott A, Sibert JR and Weaver JB (1977) Chondrodysplasia punctata and maternal warfarin treatment. *Brit Med J*, 1:1639-1640.

American Academy of Pediatrics (1961) Vitamin K compounds and the water soluble analogues. Use in therapy and prophylaxis in pediatrics. *Pediatrics*, 28:501-507.

Andrew M, Paes B, Milner R, Johnson M, Mitchell L, Tollefsen DM and Powers P (1987) Development of the human coagulation system in the full-term infant. *Blood*, 70:165.

Badois C, Lavollay B and Bomsel F (1983) Maladie des epiphyses ponctuees (MEP) associee a une fetopathie ethylique (FE). *Ann Radiol*, 26:244-250.

Badoux DM (1966) Framed structures in the mammalian skull. *Acta Morphol Netherlando-Scandinav*, 6:239-250.

Baillie M, Allen, ED and Elkington AR (1980) The congenital warfarin syndrome: a case report. *Brit J Ophthalmol*, 64:633-635.

Barone L, Aronow MA, Lian JB, Stein GS and Tassinari MS (1991) Warfarin differentially alters the expression of vitamin K-dependent bone proteins during development in vitro. *Teratology*, 43:421.

Barr M and Burdi AR (1976) Warfarin associated embryopathy in a 17-week-old abortus. *Teratology*, 14:129-134.

Bechtold H, Andrassy K and Jahnchen E (1984) Evidence for impaired hepatic vitamin K1 metabolism in patients treated with N-methyl-thiotetrazole cephalosporins. *Throm Haemostasis*, 51: 358-361.

Becker MH, Genieser NB, Finegold M, Miranda D and Spackman T (1975) Chondrodysplasia punctata: is maternal warfarin therapy a factor? *Am J Dis Child*, 129:356-359.

- Beckman DA, Soloman HM and Brent RL (1982). Third trimester teratogenic effects of sodium warfarin in the rat. *Teratology*, 26:28A.
- Bergstrom S (1971) Abortion effect of 3-(acetylbenzyl)-4-hydroxycoumarin (warfarin) in mice. *Contraception*, 3:279-283.
- Binder KH (1962) Dysostosis Maxillo-nasalis, ein arhinencepaler Missbildungskomplex. *Dtsch Zahnarschr*, 6:438-444.
- Bingham JB, Meyer O and Pohle FJ (1941) Studies on the hemorrhagic agent 3,3'-methylenebis (4-hydroxycoumarin). I. Its effect on the prothrombin and coagulation time of the blood of dogs and humans. *Am J M Sc*, 202:563.
- Blanchard RA, Furie BC, Jorgensen M, Kruger S and Furie B (1981) Acquired vitamin K-dependent carboxylation deficiency in liver disease. *N Engl J Med*, 305:242-248.
- Bleyer WA, Hakami N and Shepard TH (1971) The development of hemostasis in the human fetus and newborn infant. *J Pediatr*, 79:838-853.
- Bleyer WA and Skinner AL (1976) Fatal neonatal hemorrhage after maternal anticonvulsant therapy. *JAMA*, 235:626-627.
- Brenner B, Tavori S, Ziivelin A, Keller CB, Suttie JW, Tatarsky I and Seligsohn U. (1990) Hereditary deficiency of all vitamin K-dependant procoagulants and anticoagulants. *Brit. J. of Haematol*, 75:537-542.
- Brodie AG (1941) On the pattern of the human head from the third month to a eighth year of life. *Am J Anat*, 68:209-262.
- Boivin G, Morel G, Lian JB, Anthoine-Terrier C, Dubois PM and Meunier PJ (1990) Localization of endogenous osteocalcin in neonatal rat bone and its absence in articular cartilage: effect of warfarin treatment. *Virchows Archiv A Pathol Anat*, 417:505-512.

Brighton C (1976) Structure and function of the growth plate. *Clin Orthop Relat Res*, 136: 22-32.

Burdi AR (1969) Cephalometric growth analyses of the human upper face region during the last two trimesters of gestation. *Am J Anat*, 125:113-122.

Campbell HA and Link KP (1941) Studies on the hemorrhagic sweet clover disease. *J Cell Biol*, 138:21-33.

Chong MKB, Harvey D and De Swiet (1984) Follow-up study of children whose mothers were treated with warfarin during pregnancy. *Brit J Obstet Gynaecol*, 91:1070-1073.

Collins E and Turner G (1975) Maternal effects of regular salicylate ingestion in pregnancy. *Lancet*, ii:335-339.

Cole DE and Hanley DA (1990) Osteocalcin. In: *Bone Vol 3* by Hall BK and Newman S Boca Raton Fla, CRC Press, 209-264.

Collins P, Olufs R, Kravitz H and Babakitis M (1977) Relationship of maternal warfarin therapy in pregnancy to chondrodysplasia punctata: Report of a case. *Am J Obstet Gynecol*, 127:444-446.

Copray JCVM (1986) Growth of the nasal septal cartilage of the rat in vitro. *J Anat*. 144:99-111.

Corrigan J (1981) Vitamin K-dependent proteins. *Adv Pediat*, 28: 57-74.

Dam H (1929) Cholestererinstoffwechsel in Huhnereiern und Huhnchen. *Biochem Z*, 215:475-92.

Dam H (1935) The antihemorrhagic vitamin of the chick. *Biochem J*, 29:1273-85.

Dam H, Schonheyder F and Tage-Hansen E (1936). Studies on the mode of action of vitamin K. *Biochem J*, 30:1075-1079.

Delaire J, Billet J, Le Diascorn H and Couturier JC (1970) Le syndrome de Binder (quatre observations). *Revue de Stomatologie*, 1:257-270.

Deblay MF, Vert P, Andre M and Marchal F (1982) Transplacental vitamin K prevents hemorrhagic disease of infants of epileptic mothers. *Lancet*, 1:12-47.

Delgado-Escueta AV and Janz D (1992) Consensus guidelines: preconception counselling, management, and care of the pregnant women with epilepsy. *Neurology (Suppl)*, 42:149-160.

Deshmukh W, Kline and Sawyer B (1976) Role of calcium in the phenotypic expression of rabbit articular chondrocytes in culture. *FEBS Lett*, 67:48-51

Deshmukh W, Kline and Sawyer B (1977) Synthesis of collagen by chondrocytes in suspension culture: modulation by calcium, 3'.5'-cyclic AMP, and prostoglandins. *Proc Natl Acad Sci USA*, 74:3864-3868.

DiSaia PJ (1966) Pregnancy and delivery of a patient with a Starr-Edwards mitral valve prosthesis. Report of a case. *Obst Gyn*, 28:469-472.

Donaldson HH (1924) The Rat. Data and Reference Tables for the Albino Rat and the Norway Rat. *Memoirs of the Wistar Institute of Anatomy and Biology*, 6:43-49.

Drury RAB and Wallington EA (1976) *Carletons Histological Technique*, London, Oxford University Press. 150-151.

Ducy P, Desbois C, Boyce B, Pinero G, Story B, Dunstan C, Smith E, Bonadio J, Goldstein S, Gunberg C, Bradley A and Karsenty G (1996) Increased bone formation in osteocalcin-deficient mice. *Nature*, 382: 448-452.

Esmon CT, Sadowski JA, and Suttie JW (1975 a) A new carboxylation reaction. The vitamin k-dependant incorporation of H14 CO₃- into prothrombin. *J Biol Chem*. 250:4744

Esmon CT, Suttie JW and Jackson CM (1975 b) The functional significance of vitamin K action. Difference in phospholipid binding between normal and abnormal prothrombin. *J Biol Chem.* 247:4095-4099.

Esnouf MP and Prowse CV (1977) The gamma-carboxy glutamic acid content of human and bovine prothrombin following warfarin treatment. *Biochim Biophys Acta*, 490:471-476.

Fanelli O, Mazzoncini V and Ferri S (1974) Toxicological and teratological study of 5-bromo-2-phenyllindan-1,3-dione, an uricosuric drug. *Arzneim-Forsch*, 24:1609-1613.

Fermont R and Jagendorf B (1957): Clinical observations in the use of warfarin (coumadin) sodium, a new anticoagulant. *JAMA*, 165:1381-1388

Ford EHR (1956) The growth of the foetal skull. *J Anat*, 90:63-72.

Franco B, Meroni G, Parenti G, Levilliers J, Bernard L, Gebbia M, Cox L, Maroteaux P, Sheffield L, Rappold GA, Andria G, Petit C and Ballabio A (1995) A cluster of sulfatase genes on Xp22.3: mutations in chondrodysplasia punctata (CDPX) and implications for the warfarin embryopathy. *Cell*, 81:15-25

Freeman DJ and Meyer OO (1954) Rectal administration of warfarin (coumadin) sodium, sodium [3 (2-acetylbenzyl)-4-hydroxycoumarin]. *Proc Soc Exper Biol & Med*, 92: 52.

Friedman PA, Rosenberg RD, Hauschka PV and Fitz-James A (1977) A spectrum of partially carboxylated prothrombin in the plasma of coumarin-treated patients. *Biochim Biophys Acta*, 494: 271-276.

Gaily E and Granstrom ML (1992) Minor anomalies in children of mothers with epilepsy. *Neurology*, 42 (Suppl 5):128-131.

Gimovsky ML and Petrie R (1986): Maternal anticonvulsants and fetal hemorrhage. *J Reprod Med*, 31:61-62.

Ginsberg JS, Hirsh J, Turner DC, Levine MN and Burrows R Risks to the fetus of anticoagulant therapy during pregnancy. *Thromb Haemost*, 61:197-203.

Gorlin R, Pindborg JJ and Cohen MM Jr. (1976) Binder's syndrome. In: *Syndromes of the head and neck*. 2nd ed. New York: McGraw-Hill, 463.

Greer F G, Mummah-Schendel LL, Marshall S and Suttie JW (1988) Vitamin K1 (Phylloquinone) and vitamin K2 (menaquinone) status in newborns during the first week of life. *Pediatrics*, 81:137-140.

Grote W and Gunther R (1971) Teratogenicity test of a coumarin-rutin combination by examination of fetal skeleton. *Arzneim Forsch*, 21:2016-2022.

Grote W and Weinmann I (1973) Examination of the active substances coumarin and rutin in a teratogenic trial with rabbits. *Arzneim Forsch*, 23:1319-1320.

Guillaumont MJ, Durr FM, Combet JM, Gueho AG, Fournier BM, Sann L, Leclercq MA and Frederich AH (1988) Vitamin K1 diffusion across the placental barrier in the gravid female rat. *Dev Pharmacol Ther*, 11:57-64.

Hale JE, Fraser JD and Price PA (1988) The identification of matrix gla protein in cartilage. *J Biol Chem*, 263:5820-5824.

Hall JG, Pauli RM and Wilson KM (1980) Maternal and fetal sequelae of anticoagulation during pregnancy. *Am J Med*, 68:122-140.

Hallett JJ and Holmes LB (1979) An in vitro model for warfarin teratogenesis. *Pediatr Res*, 13:486.

Hamulyak K, de Boer-van den Berg MAG and Thijssen HHW (1987) The placental transport of [³H] vitamin K1. *Brit J Haematol*, 65:335-338.

Harrod MJE and Sherrod S (1981) Warfarin embryopathy in siblings. *Obstet Gynec*, 57:673-676.

Hauschka PV and Carr SA (1982) Calcium dependent alpha-helical structure in osteocalcin. *Biochem*, 21:2538-2547.

Hauschka PV, Lian JB, Cole DEC and Gunberg CM (1989) Osteocalcin and matrix gla protein: Vitamin K-dependent proteins in bone. *Physiol Rev*, 69:990-1047.

Hill RM and Tennyson LM (1984) Drug-induced malformations in humans. In: *Drug use in pregnancy*. L Stern, ed. Adis Health Science Press, Salgwah, Australia, 99-133.

Hirsh J, Cade JF and Gallus AS (1970) Fetal effect of coumadin administered during pregnancy. *Blood*, 36:623-627.

Holmes LB, Mack C and Moser HW (1972) *Mental Retardation: an Atlas of Diseases With Associated Physical Abnormalities*. New York, Macmillan Co.

Holzgrevé W, Carey JC and Hall BD Warfarin-induced fetal abnormalities. *Lancet*, 2:914-915.

Horswell BB, Holmes AD, Barnett JS and Levant BA (1987) Maxillonasal dysplasia (Binder's syndrome): A critical review and case study. *J Oral Maxillofac Surg*, 45:114-122.

Hosenfeld D and Wiedemann H-R (1989): Chondrodysplasia punctata in an adult recognised as vitamin K antagonist embryopathy. *Clin Genet* 35:376-381.

Howe AM and Webster WS (1992): The warfarin embryopathy: a rat model showing maxillonasal hypoplasia and other skeletal disturbances. *Teratology* 46:379-390.

Howe AM, Lipson AH, de Silva M, Ouvrier R and Webster WS (1997) Severe cervical dysplasia and nasal cartilage calcification following prenatal warfarin exposure: Evidence for the pathogenesis of warfarin embryopathy and some types of chondrodysplasia punctata. *Am J Med Genet*, (in press)

Iannotti S, Naidu Y, Noguchi R, Hunt R and Brighton (1989) Calcium-induced matrix vesicle biogenesis. *Trans Orthop Res Soc*, 14:125.

Iturbe-Alessio I, Fonseca MC, Mutchinik O, Santos MA, Zajarias A and Salazar E (1986): Risks of anticoagulant therapy in pregnant women with artificial heart valves. *N Engl J Med*, 315:1390-1393.

Jones KL, Lacro RV, Johnson KA and Adams J (1989) Pattern of malformations in the children of women treated with carbamazepine during pregnancy. *N Engl J Med*, 320:1661-1666.

Johnson LE (1976) The Functional Matrix Hypothesis. Reflections in a Jaundiced Eye. In: McNamara J.A., ed. *Factors affecting the growth of the midface*. Ann Arbor: University of Michigan Press, 131-168.

Kaplan LC (1985) Congenital Dandy-Walker malformation associated with first trimester warfarin: A case report and literature review. *Teratology*, 32:333-337.

Kaufmann HJ, Mahboubi S and Spackman TJ (1967) Tracheal stenosis as a complication of chondrodysplasia punctata. *Ann Radiol*, 19:203.

Kazzi NJ, Ilagan NB, Liang KC, Kazzi GM, Grietsell LA and Brans YW (1990) Placental transfer of vitamin K1 in preterm pregnancy. *Obstet Gynecol*, 75:334-337.

Keith DA and Gallop PM (1979) Phenytoin, hemorrhage, skeletal defects and vitamin K in the newborn. *Med Hypothesis*, 5:1347-1351.

Kerber IJ, Warr OS and Richardson CJ (1968) Pregnancy in a patient with a prosthetic mitral valve. Associated with a fetal anomaly attributed to warfarin sodium. *J Am Med Ass*, 203:223-225.

Kimmel CA and Trammel C (1981) A rapid procedure for routine double staining of cartilage and bone in fetal and adult animals. *Stain Technol*, 56:271-273.

- Knake EJ and Vilmar E (1963) *Geburtsh u Frauenh*, 13: 421.
- Koppe JG, Pluim E and Olie K (1989) Breastmilk, PCBs, dioxins and vitamin K deficiency: discussion paper. *J Royal Soc Med*, 82: 416-419.
- Koski K (1968) Cranial growth centres: Fact or fallacies? *Am J Orthood*, 54: 566-583.
- Koski K (1975) Cartilages of the face. *Birth defects: Original Article series*, 9:7, 231-254.
- Kraus AP, Perlow A and Singer K (1949) Dangers of dicumarol treatment in pregnancy. *J Am Med Assoc*, 139:758-762.
- Kronick JN, Phelps NE, McCallion DJ and Hirsh J (1974) Effects of sodium warfarin administered during pregnancy in mice. *Am J Obstet Gyn*, 118:819-823.
- Kvinnslund S (1977) Regional variations in cell proliferation and matrix formation in the cartilaginous nasal septum of the rat. *Growth*, 41:85-93.
- Kvinnslund S (1988) In vitro growth of the nasal septal cartilage of the rat in a serum free culture medium. *Acta Anat*, 131:231-234.
- Lane P and Hatheway WE (1985) Vitamin K in infancy. *J Pediat*, 106:351-9.
- Latham RA (1970) Maxillary development and growth: the septo-maxillary ligament. *J Anat*, 107:471-478.
- Leicher-Duber A, Schumacher R and Spranger J (1990) Stippled epiphyses in fetal alcohol syndrome. *Pediatr Radiol*, 20:369-370.
- Lian JB (1988) Osteocalcin: Functional studies and postulated role in bone resorption. In: *Current Advances in Vitamin K Research*. Ed: JW Suttie, Elsevier Science Publishing Co, New York, 245-257.

Link KP (1945) The anticoagulant Dicumarol. Proc Inst Med Chicago, 15:370

Lipsky JJ (1983) Mechanism of the inhibition of the gamma-carboxylation of glutamic acid by N-methylthiotetrazole-containing antibiotics. PNAS, 81: 2893-2897.

Loughnan PM, Gold H and Vance JC (1973): Phenytoin teratogenicity in man. Lancet i:70-72.

Lucas PA, Price PA and Caplan AI (1988) Chemotactic response of mesenchymal cells, fibroblasts and osteoblast-like cells to bone gla protein. Bone, 9:319-323.

Luo G, D'Souza R, Hogue D and Karsenty G (1995) The matrix gla protein gene is a marker of the chondrogenesis cell lineage during mouse development. J Bone Min Res, 10,2:325-334.

MacCorquodale DW, Cheney LC, Binkley SB, Holcomb WF, McKee RW, Thayer SA and Doisy EA (1939). The construction and synthesis of vitamin K. J Biol Chem, 131:357-370.

Mallein-Gerin F, Kosker RA, Upholdt WB and Tanzer ML (1988) Temporal and spacial analysis of cartilage proteoglycan core protein gene expression during limb development by in situ hybridization. Dev Biol, 126:337-365.

Mandelbrot L, Guillaumont M, Leclercq M, Lefrere JJ, Gozin D, Daffos F, and Forestier F (1988) Placental transfer of vitamin K1 and its implications in fetal hemostasis. Thromb Haemostat, 60:39-43.

Maor G, Lewinson D and Silverman M (1985) The possibility of calcium involvement in the inhibitory effect of dexamethasone on DNA synthesis in cartilage. In: Current Advances in Skeletogenesis, Eds Ornoy A, Harrell A and Elsevier JS, Amsterdam, 105-112.

McCallion D, Phelps NE, Hirsh J, and Cade JF (1971) Effects of coumadin administered during pregnancy to rabbits and mice. Teratology, 4:235-236.

Menger H, Lin A, Torriello H, Bernert G and Spranger J (1997) Vitamin K Deficiency embryopathy- A phenocopy of the warfarin embryopathy due to a disorder of embryonic vitamin K metabolism. *Am J Med Gen*, (in press)

Meyer O (1959) Historical data regarding the experiences with coumarin anticoagulants at the University of Wisconsin Medical School. *Circulation*, 19: 114-117

Moslet U and Hansen ES (1992): A review of vitamin K, epilepsy and pregnancy. *Acta Neurol Scand*, 85:39-43.

Moss ML, Bromberg BE, Song IC and Eisenman G (1968) The passive role of the nasal cartilage in mid-facial growth. *Plast Reconstr Surg*, 41: 536-542.

Moss ML (1976) The Role of the Nasal Septal Cartilage in Midfacial Growth. In: McNamara J.A., ed. Factors affecting the growth of the midface. Ann Arbor: University of Michigan Press, 169-204.

Motohara K, Kuroki Y, Endo F and Matsuda I (1985a) Detection of vitamin K by use of an enzyme-linked immunosorbent assay for circulating abnormal prothrombin. *Pediatr Res*, 19/4:354-357.

Motohara K, Endo F and Matsuda I (1985b) Effect of vitamin K on acarboxy prothrombin (PIVKA-II) levels in newborns. *Lancet*, iii: 242-244.

Motohara K and Matsuda I (1987) Screening for late neonatal vitamin K deficiency by acarboxyprothrombin in dried blood spots. *Arch Dis Child*, 62:370-375.

Mountain KR, Hirsh J and Gallus AS (1970): Neonatal coagulation defect due to anticonvulsant drug treatment in pregnancy. *Lancet*, i:413.

Norback CR and Robertson GG (1951) Sequences of appearance of ossification centres in the human skeleton during the first five prenatal months. *Am J Anat*, 89:1-28.

O'Reilly RA (1976) Vitamin K and oral anticoagulant drugs. *Ann Rev* 11:245-261

Olow-Nordenram M (1987) Maxillonasal dysplasia (Binder's syndrome). A study of craniofacial morphology, associated malformations and family relations. *Swed Dent J Suppl*, 47:1-32.

Olow-Nordenram MAK and Valentin J (1988) An etiologic study of maxillonasal dysplasia - Binder's syndrome. *Scand J Dent Res*, 96:69-74.

Otawara Y and Price PA (1986) Developmental appearance of matrix gla protein during calcification in the rat. *J Biol Chem*, 261:10828-10832.

Patten BM (1968) *Human Embryology, Third Edition*, McGraw-Hill Book Company, New York.

Park BK and Leck JB (1981) On the mechanism of salicylate-induced hypothrombinaemia. *J Pharm Pharmacol*, 33:25-28.

Park AW and Nowosielski-Slepowron BJA (1985) Postnatal somatometry of the rat facial skeleton. *Acta Morphol Neerl Scand*, 23:1-33.

Pauli RM, Madden JD, Kranzler KJ, Culpepper W and Port R (1976) Warfarin therapy initiated during pregnancy and phenotypic chondrodysplasia punctata. *J Pediatr*, 88: 506-508.

Pauli RM, Lian JB, Mosher DF and Suttie JW (1987) Association of congenital deficiency of multiple vitamin K-dependent coagulation factors and the phenotype of the warfarin embryopathy: clues to the mechanism of the teratogenicity of coumarin derivatives. *Am J Hum Genet*, 41:566-583.

Pauli RM (1997) Anticoagulants. Drug toxicology in embryonic development ii. In: *Handbook of Experimental Pharmacology*, 124/11: 191-229.

Penzias AS and Treisman O (1988) Vitamin K-dependent clotting factor deficiency in pregnancy. *Obstet Gynecol*, 72:452-454.

Perucca E, Hedges A, Makki KA, Ruprah M, Wilson JF and Richens A (1984) A comparative study of the relative enzyme-induced properties of anticonvulsant drugs in epileptic patients. *Brit J Clin Pharmacol*, 18:401-410.

Pettifor JM and Benson R (1975) Congenital malformations associated with the administration of oral anticoagulants during pregnancy. *J Pediatr*, 86:459-462.

Pietersma-de Bruyn ALJM, van Haard PMM, Beunis MH, Hamulyak K and Kuijper JC, (1990) Vitamin K1 levels and coagulation factors in healthy term newborn till 4 weeks after birth. *Haemostasis*, 20:8-14.

Pineo GF, Gallus AS and Hirsh J (1973) Unexpected vitamin K deficiency in hospitalized patients. *CMA J*, 109:880-884.

Poley JR and Humphrey GB (1974) Bleeding disorder in an infant associated with anicteric hepatitis. *Clin Pediatr*, 13:1045-1047.

Pollock B (1955) Clinical experiences with warfarin (coumadin) sodium, a new anticoagulant. *JAMA*, 159: 1094-1097

Poznanski AK (1994): Punctate epiphyses: a radiological sign not a disease. *Pediatr Radiol*, 24:418-424.

Price PA, Otsuka AS, Poser JW, Kristaponis J and Raman N. (1976) Characterization of a γ -carboxyglutamic acid-containing protein from bone. *Proc Natl Acad Sci USA*, 73:1447-51.

Price PA, Epstein DJ, Lothringer JW, Nishimoto SK, Posre JW and Williamson MK (1979) In: Vitamin K metabolism and vitamin K dependent proteins (Suttie, JW. ed) University Park Press, Baltimore, 219-226.

Price PA and Williamson MK (1981) Effects of warfarin on bone: studies on the vitamin K-dependent bone protein of rat bone. *J Biol Chem*, 25:12754-12759.

Price PA, Williamson MK, Haba T, Dell RB and Jee WSS (1982) Excessive mineralization with growth plate closure in rats on chronic warfarin treatment. *PNAS*, 79:7734-7738.

Price PA, Urist MR and Otawara Y (1983) Matrix gla protein, a carboxyglutamic acid-containing protein which is associated with the organic matrix of bone. *Biochem Biophys Res Commun*, 117:765-71.

Price PA and Williamson MK (1985) Primary structure of bovine matrix gla protein a new vitamin K-dependent protein. *J Biol Chem*, 260:14971-14975.

Price PA and Kaneda Y (1987) Vitamin K counteracts the effect of warfarin in liver but not in bone. *Thromb Res*, 46:121-131.

Quick AJ (1946) Experimentally induced changes in the prothrombin level of the blood. *J Biol Chem*, 164:371-376.

Quarrell OWJ, Koch M and Hughes HE (1990) Maxillonasal dysplasia (Binder's syndrome). *J Med Genet*, 27:384-387.

Raivio KO, Ikonen E and Saarikoski S (1977): Fetal risks due to warfarin therapy during pregnancy. *Acta Paediatr Scand*, 66:735-739.

Rifkin MD and Pritzker HA (1984) Tracheobronchial cartilage calcification in children: case reports and review of the literature. *Brit J Radiol*, 57:293-6.

Rival JM, Gherga-Negrea A, Mainard R and Delaire J (1974) Dysostosis maxillonasale de Binder. A propos 10 cas. *J Gen Hum*, 22:263-268.

Robinson MJ, Pash J, Grimwade J and Campbell J (1978) Fetal warfarin syndrome. *Med J Aust* i:157.

Roll R and Baer F (1967) Effect of coumarin (o-hydroxycinnamic acid lactone) on pregnant mice. *Arzneim-Forsch*, 17:97-100.

Ruthnum P and Tolmie JL (1987) Atypical malformations in an infant exposed to warfarin during the first trimester of pregnancy. *Teratology*, 36:299-301.

Sanfeliu C, Zapatero J and Bruseghin L (1981) Toxicological studies of plafibrade. Part 3. Study of teratogenic activity in rats and rabbits. *Arzneim-Forsch*, 31:1831-1834.

Sawyer WT (1983) Warfarin *Applied Clinical Pharmacokinetics*, Raven Press, New York, 187-222.

Schardein JL (1985) *Chemically induced birth defects*, Marcel and Dekker Inc, New York, 87-106.

Schardein JL (1993) *Chemically induced birth defects*, Marcel and Dekker Inc, New York, 106-125.

Scott AK (1989) Warfarin can safety be improved? *Pharmac Ther*, 42:429-457

Scott JH (1953) The cartilage of the nasal septum. *British Dental Journal*, 95:37-43.

Searls JC (1975) A comparative radiographic study of chondrocytic proliferation in nasal septal cartilage of the 5-day-old rat, rabbit, guinea pig and beagle. *Am J Anat*, 154:437-446.

Shapiro S, Redish MH and Cambell HA (1943) *Proc Soc Exper Biol & Med*, 52:12

Shapiro S and Weiner M (1949) *Coagulation, Thrombosis and Dicumarol*. New York, Brooklyn Medical Press

Shapiro S and Ciferri F (1957) Intramuscular administration of anticoagulant warfarin (coumadin) sodium. *JAMA*, 165:1377-1380.

Shaul WL, Emery H and Hall JG (1975) Chondrodysplasia punctata and maternal warfarin use during pregnancy. *Am J Dis Child*, 129:360-362.

Shaul WL and Hall JG (1977) Multiple congenital anomalies associated with oral anticoagulants. *Am J Obstet Gyn*, 127:191

Sheffield LJ, Danks DM, Mayne V and Hutchinson LA (1976) Chondrodysplasia punctata - 23 cases of a mild and relatively common variety. *J Pediatr*, 89:916-923.

Sheffield LJ, Halliday JL and Jensen F (1991) Maxillofacial dysplasia (Binder's Syndrome) and chondrodysplasia punctata. *J Med Genet*, 28: 503-504.

Sherman S and Hall BD (1976) Warfarin and fetal abnormality. *Lancet*, 1:692.

Solomon GE, Hilgartner MW and Kutt H (1972) Coagulation defects caused by diphenylhydantoin. *Neurology*, 22:1165.

Solomon HM and Brent RL (1980) The effects of sodium warfarin on embryonic and fetal development. *Teratology*, 21:70A.

Spranger JWU, Opitz JM and Bidder U (1971) Heterogeneity of chondrodysplasia punctata. *Humangenetik*, 11:190-212.

Srinivasan G, Seeler RA, Tiruvury A and Pildes RS (1982): Maternal anticonvulsant therapy and hemorrhagic disease of the newborn. *Obstet Gynecol*, 59:250-2

Stahmann MA, Huebner CF and Link KP (1941) Studies on the hemorrhagic sweet clover disease. V. Identification and synthesis of the hemorrhagic agent. *J Biol Chem*, 538-527.

Starr A, Edwards ML and Griswold MH (1963) Mitral replacement: Late results with a ball valve prosthesis. *Progr Cardio Dis*, 5:298.

Stenflo J, Fernlund P, Egan W and Roestorff P (1974) Vitamin K dependent modification of glutamic acid residues in prothrombin. *PNAS*, 71:2730-2733.

Stevenson RE, Burton OM, Ferlento GJ and Taylor HA (1980) Hazards of oral anticoagulants during pregnancy. *JAMA*, 243:1549-1551.

Suttie JW, Mommah-Schendel LL, Shah DV, Lyle BJ and Greger JL (1988) Vitamin K deficiency from dietary vitamin K restriction in humans. *Am J Clin Nutr*, 47:475-80

Suttie JW (1991) Vitamin K In: *Handbook of Vitamins*. 2nd Edition Nutritional, Biochemical and Clinical Aspects. ed. Machlin LJ, Marcel Dekker, 145-194.

Taybi H and Capitanio MA (1990): Tracheobronchial calcification: An observation in three children after mitral valve replacement and warfarin sodium therapy. *Radiology* 176:728-30.

Tejani N (1973) Anticoagulant therapy with cardiac valve prosthesis during pregnancy. *Obstet Gyn*, 43:785-793.

Theander G and Pettersson H (1978) Calcification in chondrodysplasia punctata: relation to ossification and skeletal growth. *Acta Radiol Diag*, 19:205.

Tsao SW and Chuah MI (1988). Development of bone like substance in cartilaginous rat nasal septum under experimental conditions *Anat Rec*, 221:834-840.

Tuan RS (1991) Ionic regulation of chondrogenesis. In: *Cartilage Molecular Aspects*. Ed. Hall B and Newman S, Boca Raton Fla, CRC Press, 153-178.

Turnbull A, Tindall VR, Beard RW, Robinson G, Dawson IM, Cloake EP, Ashley JS and Botting B (1989) Report on confidential enquires into maternal deaths in England and Wales 1982-1984. *Rep Health Soc Surg Lond*, 34:1-166

Ulrich MMW, Knapen MHJ, Herrmann-Erlee MPM and Vermeer C (1988) Vitamin K is no antagonist for the action of warfarin in rat osteosarcoma UMR 106. *Thromb Res*, 50:27-32.

Usui Y, Tanimura H, Nishimura N, Kobayashi N, Okanoue T and Ozawa K (1990) Vitamin K concentrations in the plasma and liver of surgical patients. *Am J Clin Nutr*, 51:846-852.

van Lang QN, Tassinari MS, Keith DA and Holmes LB (1984) Effect of in utero exposure to anticonvulsants on craniofacial development and growth. *J Craniofac Genetics Devl Biol* 4:115-133.

Viljoen D and Beighton PB (1991) Epiphyseal stippling in acrodysostosis. *American Journal of Medical Genetics*, 38:43-45.

Villasanta U (1965) Thrombembolic diseases in pregnancy. *Am J Obstet Gynecol*, 93:142-160

Von Sydow G (1947) Hypothrombinemia and cerebral injury in an infant after dicumarol treatment of the mother. *Nord Med*, 34:1171-1172.

Vries de TW, vanderVeer E and Heijmans HSA (1993) Warfarin embryopathy: patient, possibility, pathogenesis and prognosis. *Br J Obstet Gynaecol*, 100:869-871.

Wallin R and Suttie JW (1981) Vitamin K-dependent carboxylation and vitamin K epoxidation. Evidence that the warfarin-sensitive microsomal NAD(P)H dehydrogenase reduces vitamin K1 in these reactions. *Biochem J*, 194:983-988.

Wallin R (1989) Vitamin K-dependent carboxylation in the developing rat: evidence for a similar mechanism of action of warfarin in fetal and adult livers. *Ped Res*, 26:370-376.

Waltl H, Mitterstieler G and Schwingshackl A (1974) Hamorrhagische diathese bei einem neugeborenen einer mutter mit antiepileptischer therapie. *Dtsch Med Wochenschr* 99:1315-1317.

Warkany J (1975) A warfarin embryopathy? *Am J Dis Child*, 129:287-288.

Warkany J and Bofinger M (1975) Le role de la coumadine dans les malformations congenitales. *Med Hyg*, 33:1454-1457.

Warkany J (1976) Warfarin Embryopathy. *Teratology*, 14:205-210.

Whitfield MF (1980): Chondrodysplasia punctata after warfarin in early pregnancy. *Arch Dis Child* 55:139-42.

Widdershoven J, Lambert W and Motohara K (1988) Plasma concentrations of vitamin K1 and PIVKA-ii in bottle-fed and breast-fed infants with and without vitamin k prophylaxis at birth. *Eur J Pediatr*, 148:139-142.

Winter RM, Baraitser M and Douglas JM (1984) A computerised data base for diagnosis of rare dysmorphic syndromes. *J Med Genet*, 21:121-123.

Wong V, Cheng CH and Chan KC (1993) Fetal and neonatal outcome of exposure to anticoagulants during pregnancy. *Am J Med Genet* 45:17-21.

Yamanaka Y, Yamano M, Yasunaga K, Shike T and Uchida K (1990) Effect of warfarin on plasma and liver vitamin K levels and vitamin K epoxide reductase activity in relation to plasma clotting factor levels in rats. *Thromb Res*, 57:205-214.

Zengal AE, Keith DA and Tassinari MS (1989) Prenatal exposure to phenytoin and its effect on postnatal growth and craniofacial proportion in the rat. *J Craniofac Genet Develop Biol*, 9:147-160.