THE ROTATED LOWER INCISOR

Leonard Mackey B.D.S. (Syd.)

A review submitted in

partial fulfilment of the degree of

Master of Dental Surgery

Department of Preventive Dentistry

Faculty of Dentistry

The University of Sydney

1987

ACKNOWLEDGEMENTS

I wish to acknowledge the help and encouragement afforded me in this project by Associate Professor K. Godfrey without whose patience this project would never have been completed.

To Mrs Simon, Librarian, Australian Dental Association, N.S.W. Branch, for photocopying assistance.

TABLE OF CONTENTS

LIST OF FIGURES AND TABLES

1 INTRODUCTION

The purpose of this treatise is to consider the lower incisors, their characteristics, and a review of the problems associated with retention of their rotational correction.

The general problem as stated by Peck and Peck[44] is that the four mandibular incisors are the teeth most prone to positional irregularity. They state that studies have shown this and that no clinical orthodontist will deny it.

Massler and Frankel[40] found that the most frequently maloccluded teeth were the lower central incisors followed by the lower lateral incisors.

Berger[7] states that:-

1) As the lower incisors are the first teeth to erupt, they may be the first sign of an incipient malocclusion.
2) The lower incisors are difficult to treat as they relapse easily.
3) That crowding of the mandibular incisors is the most frequent anomaly.

By means of the application of an orthodontic force the lower incisor tooth can be aligned within a very short period. It would seem that a tooth embedded in bone and only separated from it by the periodontal membrane should stay in this position

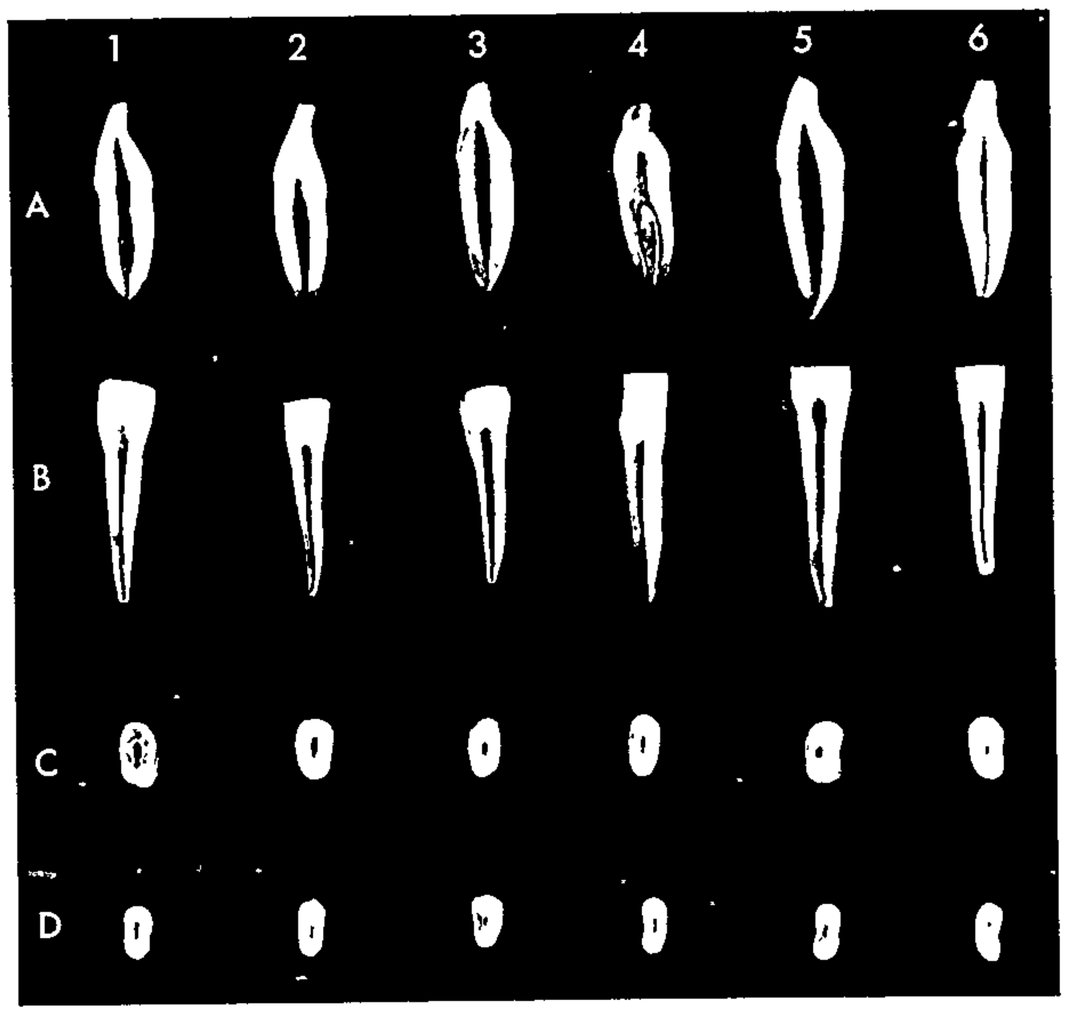

Figure 333. Mandibular central incisor—cross sections of natural specimens *A*, 1 to 6, Labiolingual sections This aspect does not show in radiographs *B*, 1 to 6, Mesiodistal sections *C*, 1 to 6, Cervical sections of root *D*, 1 to 6, Mid-root sections

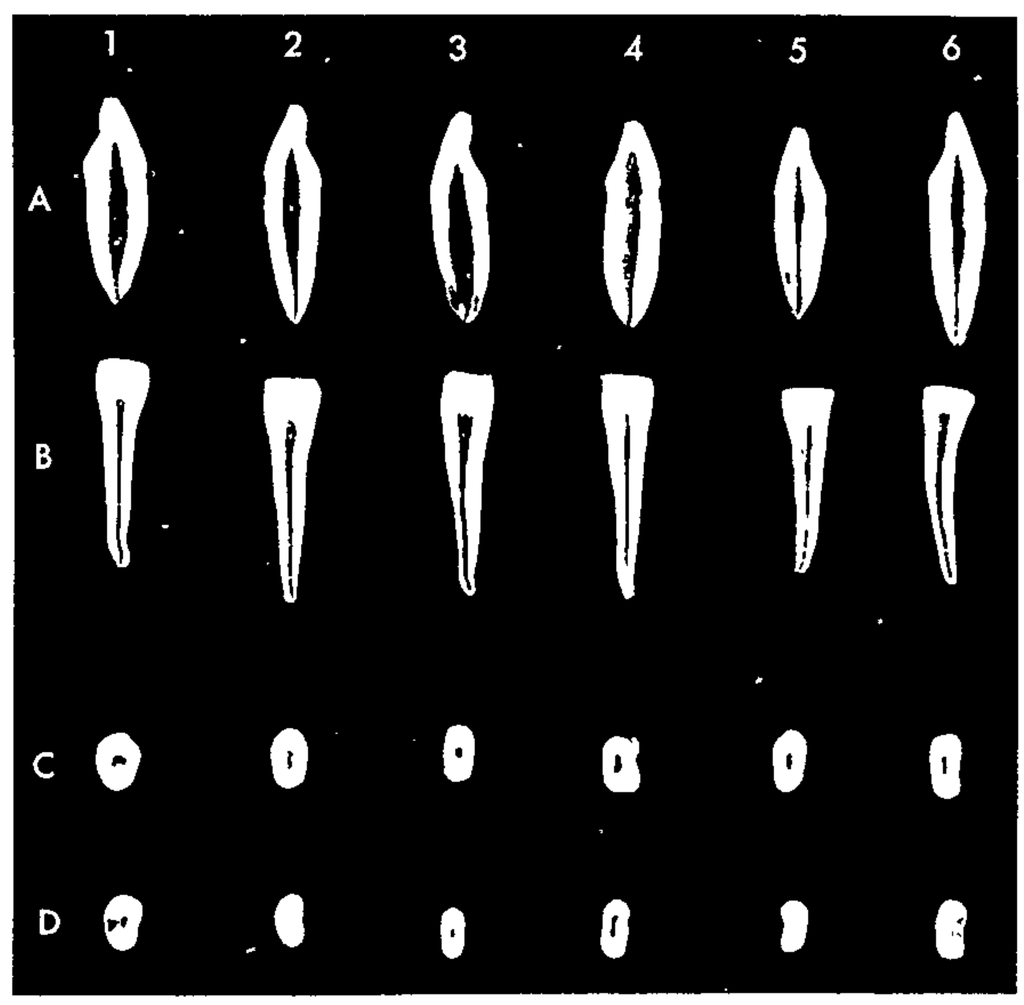

Figure 334. Mandibular lateral incisor—cross sections of natural specimens *A*, 1 to 6, Labiolingual sections This aspect does not show in radiographs *B*, 1 to 6, Mesiodistal sections *C*, 1 to 6, Cervical sections of root *D* 1 to 6, Mid-root sections

providing that no forces exist to return the tooth towards its original position.

The Figures 333 and 334 from Wheeler[51] show the lower incisors in both planes i.e., mesio-distal and labro-lingual and as well a cross sectional reproduction of the root at the cervical and mid-root sections.

Wheeler states that the mandibular incisors have smaller mesio-distal dimensions than any other teeth with the central incisor being smaller than the lateral incisor which is the reverse of the situation in the manillary arch.

The central incisor has a mesial root surface which is flat jut below the cervical line. Most have a broad developmental depression for most of the root length. This depression is usually deeper at the junction of the middle and apical thirds. The distal surface of the root developmental groove may be more marked with a deeper and more well defined developmental groove at its centre.

Sicher and De Boul[60] state that the root of the lower first incisor is flattened in a mesio-distal direction and is quite thin. Longitudinal grooves are present on its mesial and distal surfaces, the latter usually being deeper.

Examination of the cross section of the roots of these teeth show that they are of a shape which doesn't lend itself to easy

rotation in a fairly dense retentive medium and if they could be held in the desired position until the bone returns to normal they should really be quite stable.

It is common knowledge that this is not the case and that at times even after periods of quite prolonged retention have been undertaken quite significant relapse occurs.

Berger[7] shows the evolutionary change in human mandible size quoting a 30% reduction in the overall length of the mandible and points out that the change during evolution from Labidodonty (edge to edge bite) still found in Eskimos and Australian Aborigines to Psalidodonty regarded as the modern normal bite has produced the high frequency of mandibular incisor crowding. This has produced a change from well rounded upper and lower arches to a much flatter lower incisor segment.

Reitan[53] in histological studies of adult alveolar bone found that there are large cavernous spaces notably in the apical area on the lingual side of teeth. The bone walls of the middle and marginal regions are often quite dense with few narrow spaces. It is in this latter area that the bone changes will occur when tooth movement is initiated. Lack of marrow spaces implies that bone resorption takes more time.

Reitan showed microscopically in a section of the lingual wall of an adult tooth that the aloeolar bone is quite dense and devoid of any bone forming cells on its surface. There is, however, an

open cleft in the lone wall, an anatomic detail that is characteristic of human periodontal structures, notably in the young person. Bone resorption may start at the inside of this cleft, because there is no direct compression of the periodontal fibres in this area as the root is moved against the bone surface.

The bone wall in the young human usually contains large marrow spaces, open clefts and canals. He showed in young children characteristic large marrow spaces, canals and openings communicating with the periodontal ligament. In other words there was frequently a spongiosa extending even up to the alveolar crest.

Since tooth movement (i.e., the progress of bone resorption) is facilitated by the formation of resorptive cells, whose number again increases according to the number of marrow spaces, the anatomy can hardly be more favourable than in the supporting structures of the majority of young orthodontic patients.

Since the changes in tooth position, as well as maintenance of tooth position, depend upon conditions applying in the periodontal space supporting the tooth, it is necessary to review present knowledge of the biology of periodontal tissues.

2 THE GENERAL PERIODONTAL SUPPORT

Wheeler[74] lists the principal periodontal fibres as:-

1) Free gingival group
2) Transseptal group
3) Alveolar crest group
4) Horizontal group
5) Oblique group
6) Apical group.

Macphee and Cowley[39] state that the periodontal membrane consists essentially of groups of collagenous connective tissue fibres that are formed by fibroblasts. Between these bundles run vessels, lymphatics and nerves embraced in a loose connective tissue stroma. This stroma is further penetrated by a network pattern of epithelial cells, the cell rests of Malassez, which are established following disintegration of Hertwig's sheath.

They describe the principal fibres as:-

1) The alveolar crestal fibres, a condensation of fibre bundles which run from the cervical area of the root to the crest of the alveolar bone
2) The horizontal fibres, which run at right angles to the tooth and to the alveolar bone

3) The oblique fibres, which run in an apical direction from the alveolar bone to the cementum.

Sicher and De Brul[60] define the apical group as attached to the apical cementum and from here radiating in all directions toward the bone at the fundus of the socket.

Macphee and Cowley[39] feel that there is some question as to what extent such discrete groups of collagen fibres exist in vivo, since the histological appearance is partly governed by the process of tissue fixation and subsequent procedures involved in preparing the tissue for microscopy.

The collagen fibres of the periodontal membrane show a moderately high rate of amino acid turnover particularly on the alveolar bone side and that the tissue as a whole is capable of a high degree of functional adaptation.

Reitan[53] in a review of rotation asserts that correction of a rotated tooth is usually considered to be a fairly simple mechanical procedure. Histologically, however, the tissue transformation that occurs during rotation is largely influenced by the anatonic arrangement of the supporting structures. In experimental work on rotation of teeth one may distinguish between the marginal, middle and apical thirds of the root. In the marginal region most of the periodontal fibre bundles consist

of the free gingival and transseptal fibre group. Although the principal fibres of the middle and apical thirds are anchored to the root surface and the alveolar bone, the supra-alveolar fibres are connected to the whole fibre system of the supra-alveolar structures. This difference in the attachment of the fibre bundles has proved to be of great importance, particularly during the retention period. After rotation of teeth the stretch of free gingival tissue may cause displacement of collagen, elastic and onytalan fibres located even some distance from the tooth being moved.

3 THE STRUCTURE OF THE CEMENTUM

Orban[42] lists the function of the cementum as:-

1) To anchor the tooth to the bony socket by attachment of fibres
2) To compensate by its growth for the loss of tooth substance due to occlusal wear
3) To enable, by its continuous growth, the continuous vertical eruption and mesial drift of the teeth.

The continued deposition of cementum is of great biological importance. In contrast to the ever alternating resorption and new formation of bone, cementum is not resorbed under normal conditions.

The fact that cementum appears to be more resistant to resorption than bone renders orthodontic treatment possible.

When a tooth is moved by means of an orthodontic appliance bone is resorbed on the side of pressure and new bone is formed on the side of tension. On the side toward which the tooth is moved pressure is equal on the surfaces of the bone and the cementum hence resorption of both could be anticipated. However in careful orthodontic treatment cementum resorption if it occurs, is usually localised and shallow possibly because the cementum is covered as a rule by a continuous layer of cementoid tissue that is highly resistant to resorption.

Orthodontic tooth movement depends on bone resorption and bone formation stimulated by properly regulated pressure and tension. The stimuli are transmitted through the medium of the periodontal ligament. If the movement of the tooth is within physiological limits (which may vary with the individual) the initial thinning of the periodontal space on the pressure side is compensated for by bone resorption whereas the widening of the periodontal space on the tension side is balanced by bone apposition

Cellular and Accelular Cementum

Selvig[57] investigated whether cellular and accelular cementum are ultrastructurally similar to, or different from, alveolar bone, to determine by use of the electron microscope if the Sharpey's fibres in the human periodontium are uncalcified, partially calcified or completely calcified, and to compare the results with those derived from the observation of ground sections and microradiographs of the same specimens.

The similarity in histological appearance of the cementum and the alveolar bone has been pointed out in many investigations by optical microscopy and has been commented on in recent electron microscope studies by Dreyfuss and Frank in 1964 and by Herting in 1963. Freshly extracted teeth were obtained from individuals of different ages, some being removed by a surgical procedure with an attached intact portion of the periodontal membrane and alveolar bone. Most sections were fixed in a bufferred osmium tetroxide solution. Others were fixed in formalin to permit the

examination of the soft tissues by transmitted and polarised light. The specimens were embedded in resin and sections prepared at right angles and parallel to the long axes of the tooth.

Contact microradiographs were made of all specimens with good contact between the sections and the fine grained emulsion ensured by use of a vacuum cassette.

Silver-shadowed negative collodion replicas for optical microscopy were obtained from the surfaces of a few ground sections.

After microscopic examination of the ground sections and corresponding microradiographs regions of acellular cementum, cellular cementum and alveolar bone were dissected from the ground sections and re-embedded in resin.

Acellular Cementum

By transmitted light the thin acellular cementum in general appeared as a thin lamellated tissue, characterised by numerous incremental lines running parallel to the root surface. Near the cemento-dentinal junction the acellular cementum regularly contained a zone of radially oriented fibrous structures.

When observed in the electron microscope the acellular cementum showed bundles of densely packed fibrils arranged more or less at

right angles to the root surface being inserted into the cementum along most of the surface.

The cementum surface which showed as being smooth under the optical surface was characterised at higher magnifications by a serrated appearance due to protruding pyramids of calcified tissue. Each projection corresponding to the insertion of one collagen fibril.

Cellular Cementum

Cellular cementum appeared to be more varied in appearance under the microscope or microradiographically than did the acellular cementum and in general was less radio opaque. Layers of cellular cementum were separated by radiographically dense resting lines or by layers of acellular cementum.

In the electron microscope the principal fibres of the periodontal membrane were inserted into the cementum as Sharpey's fibres at varying intervals along the surface. Some of the fibres were heavily calcified while in other areas fibres which were not completely calcified could be traced into the calcified tissue.

In cross section the fibres appeared as distinct more or less circular structures separated from each other by calcified tissue containing more randomly arranged fibres.

The Sharpey's fibres consisted of an uncalcified irregularly shaped central core surrounded by a highly calcified peripheral part. Densely packed collagen fibrils were present in the cement as well as in the peripheral portions of the fibres.

In some sections of the cellular cementum the Sharpey's fibres were completely or almost completely calcified.

Alveolar Bone

Ground sections of alveolar bone always contained uncalcified structures extending from the periodontal membrane into the hard tissue, indicating the location of embedded periodontal fibres. The uncalcified channels had a width similar to those of the Sharpey's fibres in cellular cementum. At higher magnifications the Sharpey's fibres in bone, like those in cellular cementum, were seen to contain an uncalcified core of collagen fibrils surrounded by a peripheral layer at least as densely calcified as in the surrounding matrix.

The ac ellular cementum of human teeth contains mostly radially oriented fibres. This type of cementum seems to serve the primary purpose of anchoring the tooth in its alveolus through the medium of periodontal collagen. In the cellular cementum and the alveolar bone the Sharpey's fibres constitute only a portion of the collagen fibrils that make up the matrix. Most fibrils and bundles of fibrils are not directly engaged in attachment of the tooth but serve other functions within the tissue.

Sharpey's fibres could not generally be identified in microradiographs of ac ellular cementum. Electron microscopy of these tissues demonstrated that these fibres were indistinguishable from other fibres of the cementum matrix on the basis of difference in mineralisation and that they in fact made up most of the matrix of this tissue. In the cellular cementum and the alveolar bone the Sharpey's fibres formed distinct structures within the calcified tissue.

The reason why the central cores of the Sharpey's fibres within bone and certain regions of cementum often remain uncalcified while other matrix fibres of the same diameter calcified completely is not clear. The difference may be in the different development of these fibres. Since Sharpey's fibres are derived from periodontal fibres which are not ordinarily calcifiable, except maybe in the case of ankylosis, in their original location it would appear that these fibres will calcify after they have become embedded in bone and cementum only if they have acquired the concentration of inorganic ions and ground substance components required for calcification and if possible inhibiting substances have been removed.

This exchange must take place in the precementum and osteoid zones and would be most complete in regions where hard tissue formation was proceeding at a slow rate such as during the formation of accellular cementum.

In regions where the hard tissue deposition is rapid and the

fibres wide, such as on the surface of alveolar bone, the exchange of material may not be complete before the fibres become embedded and thus will leave uncalcifiable cores in the fibres.

This is supported by the observation that the Sharpey's fibres remained uncalcified in deep layers of the tissues and by the observation that all uncalcifiable fibres were radially oriented embedded periodontal (Sharpey's) fibres while fibres which most likely had been formed in the precementum and osteoid zones were completely calcified even though they were often as wide as the embedded periodontal fibres.

When the position of the tooth changes due to eruption, orthodontic, physiologic or pathologic tooth movement the periodontal fibres rearrange and new layers of bone and cementum may contain embedded fibres that are oriented at different angles to the surface than in deeper layers. The same fibre can be traced through several layers of calcified tissue. This indicates that the deposition of new hard tissue serves the purpose of providing a continuous attachment of the cementum to the existing periodontal fibres.

The total amount of cementum formed on the root during life of the individual is of the order of a few hundred microns. Since the embedded fibres in the cementum are partially or completely calcified it is unlikely that there is significant turnover of

collagen in these fibres. The bony walls of the alveolus on the other hand, constantly undergoes remodelling by resorption and new deposition through which new fibres become embedded in the calcified tissue.

It has been shown by Crumley[15] in 1961 and Stallard[65] in 1963 that there is more active collagen formation on the surface of alveolar bone than on the surface of the cementum. During protein deprivation alveolar fibres become lost and there is bone resorption while the fibres from the cementum still remain.

Embedded potions of the periodontal fibres, particularly those in the cementum, serve functional purposes over a long period of time suggesting also that these fibres become more inert with age. Rearrangement of the periodontal fibres following changes in tooth position must, to a large extent, be accounted for by changes within the periodontal membrane rather than at the bone or cementum surfaces.

The presence of an intermediate plexus has been reported in histological studies by Crumley and by Trott in 1962. However it seems reasonable that a gradual rebuilding of the collagen fibres can take place without presupposing the presence of a distinctive histologically recognisable intermediate plexus.

Erikson, Kaplan and Aisenberg[20] undertook a histological

interpretation of repair phenomena following the removal of first premolars with retraction of the anterior segment. They had observed that the character of contact of teeth approximated across an extraction site was mostly not as good as the contact between two naturally contacting teeth. Their work was to ascertain whether this was due to some difference in the structure of the transseptal fibres in the two differing situations.

The experiment also served to answer the question of what happens to the transseptal fibres when, in orthodontic treatment, wide spaces are opened temporarily between teeth which should normally be in approximation as when buccal segments are moved distally one tooth at a time.

Their experiment showed:

1) That transseptal fibres are remarkably persistent even when almost all bony support is lost
2) Transseptal fibres are being continally renewed. Evidence was presented to suggest that the alveolar crest fibres, together with the matrix of disappearing alveolar bone, furnish these new groups of fibres
3) Elongated transseptal fibres appear in the spaces created by tooth extraction
4) When teeth opposite such spaces are brought into approximation by mechanical appliances, the transseptal fibres relax, coil and then become compressed. They remain in the nature of scar tissue. It seems apparent that there

exists no physiologic process which shortens or removes the excess of these fibres after the teeth are approximated. When the teeth are brought together the compression of these scar-like fibres causes crushing injuries to the periodontal membrane and the alveolar bone. Resorption of bone cementum and dentine follow.

5) It is biologically unsound to expect good approximal contact to prevail between dental units after approximation through a space created by an extraction.

6) Possibly this explains why teeth fail to drift together completely after the removal of intervening teeth.

7) Evidence is offered to explain the tendency of approximal contacts to reopen after they have once been closed through a space created by an extraction.

8) Transseptal fibres are tough and can withstand some stretching. They pull the teeth to which they are attached in the direction of the force.

Thompson et al.[69] feel that development and maintenance of the proper alignment of the dentition involves three factors:

1) The process of bone resorption and of bone rebuildilng caused by the reactions of the bone and periodontal membrane to pressure and tension.

2) The muscle balance and the harmony arrived at by the varying pressures of lips, tongue and cheeks. Because the muscle tissue cannot be altered permanently arch width is somewhat fixed and teeth have to be accommodated in this arch size.

3) The connective tissue is superior to the alveolar bone, that is, the transseptal and gingival fibres.

Skillen[62] in 1940 felt that the periodontal membrane and the bony socket were easily repaired but that the gingiva did not repair as easily.

Skogsborg[63] in 1932 described a case in which a rotated tooth relapsed but with septotomy after a second rotation no relapse occurred.

Thompson felt that the transseptal fibres tend to maintain the original position of the tooth when the fibres were formed and to resist any change. Without any complicating factors or gingivectomy, which they used in their experiments, tension would be placed on these fibres by tooth movement. Uncontrolled, these fibres would tend to return to their original conformation and carry with them the teeth which they surround and to which they are attached thus causing relapse. They felt that a gingivectomy might release this tension and then new fibres would form without tension, thus mitigating the tendency for relapse.

Koumas and Mathews[32] studied the effects of pressure on the formation of collagen in the periodontal ligament in experiments with guinea pigs. They used eleven animals with one used as a control. A helical "torsion loop" was used to apply force to two banded lower incisors at right angles to the long axis of the tooth.

In a previous study by Carneiro and De Morales[11] they showed a constant renewal of periodontal collagen by means of radioautography in the unstressed periodontium in the mouse. Koumas and Mathews[32] felt that as the periodontium is involved in the clinical movement of teeth, further studies should be made on these tissues under orthodontic forces.

Each day of their experiment, animals were given H^3Proline intraperiotoneally and were killed the next day.

Sections of the anterior portion of the mandible were taken in a frontal vertical plane along the long axis of the incisors in an attempt to show both incisors with bone and connective tissue interproximally. Thin sections were prepared with nuclear track emulsion, processed and viewed under a light microscope to determine the distribution of iostope. Ultra-thin sections were made and examined under the electron microscope.

Their results showed that in the control animal, which was free of orthodontic movement, there was no evidence of significant new collagen formation.

Since hydroxyproline is a major constituent of collagen, it was believed that the greater number of photographic grains observed represented the incorporation of the isotopically labelled amino acid into collagen. In the course of the experiment, the presence of grains increased with time, indicating the onset of new collagen formation. This presumably being the result of the externally applied tension upon the collagen of the periodontium.

At the fifth day on both the pressure and the tension sides the site of new collagen formation in the periodontal ligament was always near the alveolar bone.

Grain distribution in the tension side at five days showed isotope grains primarily adjacent to the rapidly forming bone. On the contrary, the pressure side showed a wider distribution of the grains throughout the ligament. It was interesting to note that while collagen formation was seen at random on the pressure side in the five day specimen the situation was reversed by the thirteenth day and all collagen formation was then on the tension side.

This study supports the work of Crumley[15] who found that collagen formation is higher near the alveolar bone than near the cementum. Stallard[65] in 1963 claimed that the principal fibres of the periodontal ligament can be traced between the cementum and bone without a break in their continuity.

Koumas and Mathews[32] however felt that the "intermediate plexus" phenomenon is a result of the directional differences in the fibre bundles as they course from the alveolar bone to the cementum thus giving the appearance of an "intermediate plexus". Although the load on the 014" wire spring used was greater, produced a more rapid than usual movement, no inflammation, cementum resorption, or loss of teeth were noted.

The use of the electron microscope permitted more precise evaluation of the nature of the attachment of the ligament fibres into the bone and cementum during orthodontic manipulation. In the study by Boase[10], the maintenance of Sharpey's fibres in the cementum during manipulation was clearly established giving further evidence that the cementum side was essentially unaffected by the experimental procedure. Cemental fibres were seen in well organised bundles between cementoblasts into the cementum matrix. On the other hand, the Sharpey's fibres on the bone side were disrupted and discontinuous and showed evidence of reorganisation.

4 THE ROLE OF FIBROBLASTS

Ten Cate, Deporter and Freeman[67] examined the role played by fibroblasts in the remodelling of the periodontal ligament during physiological tooth movement and state that to most orthodontists tooth movement is usually considered as its translocation through bone and it is on this biologic basis that until recently, most orthodontic therapy has been conceived. The resorption and deposition of bone, i.e., bone remodelling, can be easily demonstrated in tissue sections by conventional histological methods and with the aid of various bone seeking labels such as the tetracyclines. Thus the bone responses during tooth movement have been fairly easy to analyse. On the other hand the remodelling of the soft connective tissue invervening between the bone and the tooth cannot be demonstrated by conventional histology.

To explain how the periodontal ligament is remodelled during physiological tooth movement, especially during tooth erutpion, Sicher[59] advanced the theory of the "intermediate plexus" within the periodontal ligament. In this plexus the dissolution and reformation of collagen fibres supposedly occurred thus permitting tooth movement. Although this could explain eruption and rotation, it is not adequate to explain how the ligament remodels during movement of the tooth in a mesial or distal direction.

Considerable debate has taken place as to whether this exists at all and Edwards[16], in a review of the literature, concluded that there is no such structure.

Edwards offered the following mechanism to explain the remodelling of the periodontal ligament in response to tooth movement.

1) Progressive osteogenic activity (and cementogenic activity to a far lesser degree) played an active role in the shortening of extended fibres and the reattachment of new fibres developed during tooth movement.
2) That the stretching of the wavy collagen fibres and reorientation of their directional morphology could permit a certain amount of tooth movement.
3) That the existence of a type of intermediate plexus might allow an elongation of fibre bundles by slippage of the fibres over one another and subsequent reorientation of the fibres in a new position.

Edwards felt that the final return of the slow metabolising connective tissue fibres to their original and stable relationship to the tooth and each other depended on remodelling of the osseous tissue. A real problem is that collagen is generally considered to be a very stable protein and some collagen in the body, e.g., in tendon, is relatively inert. However, experiments by Carneiro and de Morales[11], using radioactive proline, indicate that there is a high rate of collagen turnover in the periodontal ligament, probably higher than any other site in the body.

With bone, two cell types, osteoblasts producing bone and osteoclasts destroying bone, acting in conjunction is well understood. However the dissolution and synthesis of collagen in an orderly and controlled fashion during physiological tooth movement creates a problem. If two types of cell for synthesising and degrading of collagen were shown it would be no problem explaining how connective tissue remodelling would occur.

Ten Cate et al.[67] claim that they can demonstrate a cellular mechanism involved in collagen remodelling and that, unlike the bone analogy, where two different cell types are involved, this is achieved by a single cell, the fibroblast. In other words, the fibroblast is capable of both synthesising and degrading collagen at any one time.

Ten Cate et al. reviewed the work from their laboratory which led to this concept, introducing some new support for this concept, its application to tooth movement, be it physiologic or therapeutic.

They feel that there is a parallel between macrophage function and fibroblast function and they review the series of events that occur when a macrophage ingests foreign material which is a well understood and therefore undisputed physiological phenomenon. It has also been demonstrated that the macrophage can on occasions ingest and degrade collagen.

The classical situation where this occurs is in uterine involution after pregnancy where macrophages achieve the rapid removal of collagen from the uterine wall by ingesting collagen and degrading it intracellularly.

Can macrophages act in a similar manner to bring about remodelling of the periodontal ligament? When the periodontal ligament is examined with the electron microscope no macrophages can be demonstrated in its cell population. The bulk of the cells in the normal functioning periodontal ligament are fibroblasts and this prompts the question whether or not the fibroblasts may have a phagocytic action similar to that of the macrophage.

They demonstrate evidence that the fibroblast may act as a macrophage using the standard technique of demonstrating the occurrence of using phagocytosis at the fine structural level by the intravascular injection of an electron-dense material such as thorium dioxide. This marker rapidly leaves the vascular system and enters the intracellular compartment where it is picked up by scavenger cells in the immediate vicinity.

Fig. 2. Electron micrograph of part of a fibroblast which has been exposed to thorium dioxide injected intravenously 8 hours previously. The thorium dioxide (seen as electron-dense particules) has been taken up by the fibroblast and sequestered in a phagolysosome (arrowed).

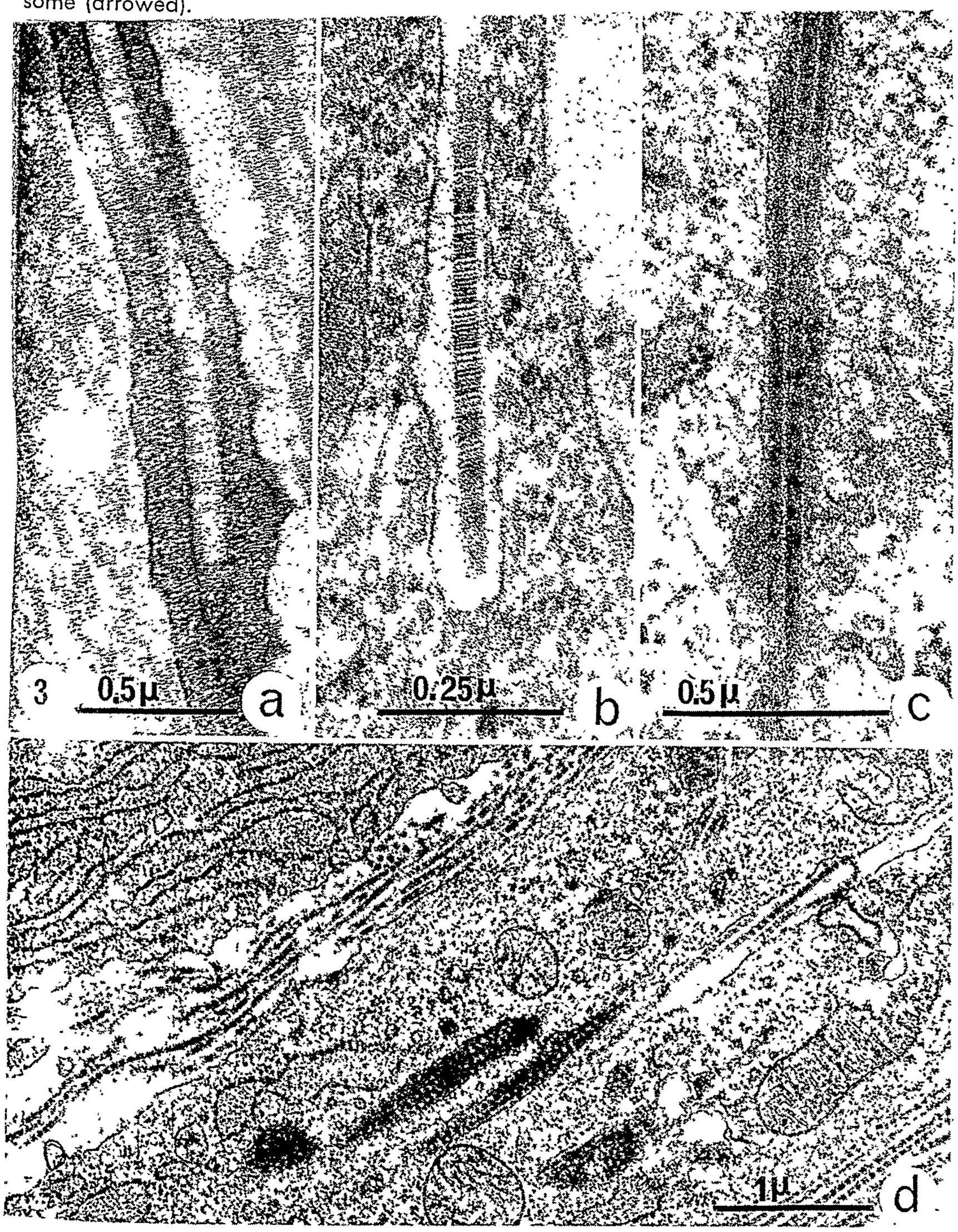

Ten Cate, Deporter & Freeman[67]

Fig. 3. A series of pictures indicating the phagocytosis of collagen by the fibroblast. **3, a** demonstrates the actual phagocytosis of collagen and corresponds to **A** in Fig. 1. **3, b** illustrates collagen within a phagosome and this corresponds to **B** in Fig. 1. **3, c** illustrates the development of a phagolysosome (**C** in Fig. 1), and **3, d** illustrates residual bodies in which banded collagen fibrils are still discernible. A phagolysosome containing collagen is also present in this cell.

Figure 2 shows that there is an accumulation of thorium dioxide within a phagolysosome which is clear evidence that phagocytosis has occurred. This shows that there can be no doubt that the fibroblast is capable of ingesting foreign material. The key question is however whether the fibroblast can ingest its own product collagen or not?

Figure 3 appears to show the phagocytosis of collagen by ligament fibroblasts.

This assumption is strengthened by the demonstration of acid phosphatase activity within the collagen containing vesicles or phagolysosomes. However as strong as this may appear, it is possible that the appearance of collagen partly within and partly outside the fibroblast can be caused by the plane of section.

Ten Cate and Deporter[68] have suggested the following equation:

$$\text{Amino Acids} \underset{\text{Degradation}}{\overset{\text{Synthesis}}{\rightleftharpoons}} \text{Collagen}$$

so that if the rate of degradation and synthesis are equal then the amount of collagen should remain steady. If this equation holds good for the rapidly remodelling collagen in the periodontal ligament, it should be possible to predict an overall loss of extracellular collagen if its synthesis is arrested without interference with the phagocytic action of the fibroblast.

There are two ways whereby the synthesis of the collagen can be halted:

1) By depriving the cell of vitamin C.

Vitamin C has a specific action on a particular sequence in the several steps of collagen synthesis. In the assembly of the collagen molecule the amino acid proline is first incorporated, with other amino acids, at a ribosomal site. The collagen precursor molecule formed here is then transferred from the ribosomes to the cisternae of the rough endoplasmic reticulum.

On the unit membrane of the rough endoplasmic reticulum the proline is hydroxylated to hydroxyproline and this step involves enzyme activity dependent upon ascorbic acid. Thus in the absence of ascorbic acid enzyme activity ceases and hydroxylation of the proline cannot occur. As hydroxylation is essential for the stability of the classical triple helical structure of collagen, collagen does not form and instead precursor material accumulates within the cisternae of the rough endoplasmic reticulum. This is seen at the fine structural level as a dilation and rounding of the profiles of rough endoplasmic reticulum as collagen precursor accumulate within them.

2) By depriving the cell of the basic amino acids. Protein deficiency halts collagen synthesis by withholding the basic building materials for collagen from the fibroblasts.

Thus if periodontal ligament remodelling involves phagocytosis of collagen, a loss of intracellular collagen should be expected in both scorbutic and protein deficient animals.

Figure 4 shows a scorbutic fibroblast and its cytoplasm is characterised by the classic dilated cisternae of rough endoplasmic reticulum. It can be inferred then that collagen synthesis by this fibroblast has ceased. Another feature of this cell is the presence of many intracellular collagen profiles which indicate a continuance of collagen degradation and this is confirmed by the lesser amounts of extracellular collagen.

Fig. 4. A scorbutic fibroblast (guinea pig). This cell is characterized by dilated profiles of rough endoplasmic reticulum (er). Note also the accumulation of collagen within this cell.
Fig. 5. A fibroblast from the periodontal ligament of a mouse maintained for 4 days on a protein-deficient diet. There is a loss of extracellular collagen fibrils and an accumulation of intracellular fibers. As there is no accumulation of intermediary collagen products, the endoplasmic reticulum cisternae are not dilated in this cell.

A similar picture is seen in the periodontal ligament of the protein deficient animal.

There is again a marked loss of extracellular collagen and an accumulation of banded collagen within the fibroblasts. The only difference is that in the protein deficiency fibroblasts no dilation of the cisternae of the rough endoplasmic reticulum occur as collagen synthesis has never begun.

Ten Cate et al. have also been able to demonstrate the occurrence of collagen phagocytosis by the fibroblast. The results of their paper could be interpreted in two different ways: firstly, that two colonies of fibroblasts exist, one which synthesises and one which degrades, or secondly, that the cells of the ligament are capable of synthesising and degrading collagen simultaneously. They interpret their results to indicate that the fibroblast is capable of both functions. Not only do the protein and vitamin C deficiency experiments indicate that both processes are occurring simultaneously but there is also strong supportive evidence from autoradiographic studies at the fine structural level. They quote Weinstock in a personal communication as having shown that collagen-containing vesicles in ligament fibroblasts are not labelled with H^3Proline thirty minutes after injection of the isotope but that the cell organelles associated sequentially with the pathway of collagen synthesis are. Not only does this finding indicate that the collagen containing vesicles are not associated with collagen synthesis but also that both processes of synthesis and degradation are occurring at the same time.

Although this work started by using the periodontal ligament as a model system they have been able to show that the ability of the fibroblast to degrade collagen is a widespread occurrence and is not limited to the ligament.

Ten Cate and Deporter in experiments on the repair of skin wounds indicate the fibroblasts may be switched on to degrade collagen by some change in the local environment and they feel that indicates that some means of control may be possible.

There seemed to be random distribution of fibroblasts engaged in collagen degradation across the width of the periodontal ligament. They have not observed collagen-containing profiles in bone cells lining the socket walls or in cementoblasts but have observed processes of fibroblast extensions interposed between cementoblasts which contain collagen profiles and this suggests that the collagen fibre bundles may be remodelled right up to their insertions into the cementum. Thus there is no evidence of an intermediate plexus and if the fibroblast's role in collagen remodelling is accepted then there is no need to require such a plexus in the ligament during tooth movement.

Significant numbers of fibroblasts synthesising and degrading collagen have been noted within the transseptal ligament confined to the cells in the apical part.

Ten Cate and Deporter's experiments feature the fibroblast in the ligament of teeth undergoing physiological movement and so it

should be possible to utilise this function to bring about orderly remodelling of the periodontium during therapeutic tooth movement. Even with light forces this is not so.

Edwards[16], Boase[8] and Parker[43] have worked on the effects of tooth rotation and retention. Edwards observed that "throughout the literature pertaining to the collagenous bundles of the periodontium, one observation is consistent - the supracrestal connective tissue fibres whose length and direction are not altered by an ever changing osseous attachment, are extremely slow to adjust to orthodontic movements of the teeth".

5 THE OXYTALAN FIBRE NETWORK

In 1958 Fullmer and Lillie[22] were able to demonstrate by way of a selective histochemical technique, the instance of a certain connective tissue fibre in locations formerly believed to contain only collagen. Because of its resistance to acid hydrolysis, the newly discovered fibre was named oxytalan, i.e., acid enduring. These fibres were first distinguished histochemically from collagen by peracetic - Gomori's aldehyde fuchsin staining reaction. Oxone was later substituted for the peracetic acid oxidation. Oxytalan fibres will then stain with Gomori's aldehyde fuchsin whereas the collagen fibres will not. The oxytalan fibres are thereafter coloured by Holmi's counterstain. Elastic fibres stain with aldehyde fuchsin without the oxidation step being necessary.

Oxytalan fibres appear round, elliptical or flattened on cross section varying in length from 0.5 to 3 microns in diameter and may exceed 2 mm in length. They are composed of many fine filaments with an amorphous interfibrillar material both approximately 100 A° in diameter. It is interesting to note that oxytalan fibres are consistently found in tissue continually subjected to mechanical stress.

There appears to be a relationship to elastic tissue and Fullmer has suggested that oxytalan is a pre-elastic or specially modified elastic fibre.

Hallett[26] found the periodontal ligament richer in oxytalan fibres after teeth had been rotated 90° by the immediate rotation method.

Fullmer, Sheetz and Narkates[23] reviewed the oxytalan connective tissue fibres and state that oxytalan fibres are a separate and distinct fibre type which cannot be distinguished by histochemical means from pre-elastic fibres but that the two fibre types are readily distinguished by electron microscopy. Fullmer and Lillee found that the enzyme elastase is capable of digesting elastic tissue but could not digest Oxytalan fibres unless they were pre-oxidised which they did with peracetic acid.

Oxytalan fibres have never been observed to progress through cementum into dentine although sometimes oxytalan fibres progress for great distances into cementum they always terminate before or at the cemento-dentinal junction. Focal aggregations around blood and lymphatic vessels are common.

The observation that more and larger oxytalan fibres are observed around the necks of teeth and around teeth used as bridge abutments permits the suggestion that they are physiologically responsive to demands placed upon the teeth. This implies that the cells in the adult periodontium are capable of producing oxytalan fibres of increased size and number in response to increased functional stress.

Fullmer feels that although Selvig in 1968 attempted to relate

Table 1. Comparison of oxytalan fibers to other fiber types

Fiber type		Oxytalan fibers
Collagen:	Birefringent	Non-birefringent
Collagen:	Acid soluble	Resists acid solution
Collagen:	Identified by collagen stains	Not identified by collagen stains
Reticulum:	Stain	Unstained
Nerve:	Morphology	Morphology dissimilar to nerves
	Distribution	Distribution dissimilar to nerves
	Stain (silver)	Unstained
	(myelin)	Unstained
	(cholinesterase)	Unstained
Elastic:	EM morphology	Dissimilar to elastic fibers
Elastic:	Stain	Unstained
Elastic:	Stain with aldehyde fuchsin after oxidation	Stain with aldehyde fuchsin after oxidation
Elastic:	Animal periodontal membrane distribution	Similar oxytalan fiber distribution in periodontal membrane of man and monkey to elastic fibers in animals
Pre-elastic:	Stain with aldehyde fuchsin after oxidation	Stain with aldehyde fuchsin after oxidation
Pre-elastic:	Stainable component removed by β-glucuronidase after oxidation	Stainable component removed by β-glucuronidase after oxidation
Pre-elastic:	EM morphology	Similarities and dissimilarities

oxytalan fibres to degenerating collagen no evidence has been found to establish any relationship between oxytalan fibres and collagen in any form or state.

Milton Sims[61] has carried out a lot of work on oxytalan fibres and investigated its reconstitution during orthodontic tooth movement. He describes the histological appearance of the oxytalan fibre system in the periodontal ligaments of normal and orthodontically moved human premolar teeth and details the reconstitution of the system.

His work was carried out using maxillary first premolars and their attached buccal periodontium which required extraction for orthodontic purposes. Those on the right side were moved buccally or palatally with continuous force for periods ranging from three to twenty eight days. Controls were provided by the periodontium of the untreated left side. Fragments of periodontal ligament adhering to the cementum of experimental and control maxillary premolars and the mandibular first premolars provided additional histological information

Sims found that when a light continuous force was applied for 28 days the oxytalan system was maintained throughout the periodontal ligament including the regions subjected to maximum tension and compression. On the tension side the coronal third of the periodontal ligament appeared to be undergoing extensive remodelling of the collagen and vascular structures. However a reforming oxytalan fibre system remained clearly defined and

associated with the moving tooth. Large numbers of oxytalan fibres extended from the cementum of the tooth apically towards the periodontal vessels. Nearby, in the midportion of the ligament, the disappearance of oxytalan and elastic fibre remnants of the former periodontal ligament was seen to be occurring in the remodellling tissue. As the tooth was relocated away from the alveolar bone, the incorporation of periodontal vessels into the reforming alveolar wall was accompanied by the loss of the oxytalan staining fibres associated with these vessels. Reforming oxytalan-vascular units when viewed transversely were readily identified within the periodontal ligament in Figure 1 and a control section of normal periodontal ligament shown in Figure 2.

Slightly apically to the crestal region of tension the reconstituting oxytalan fibre system showed the customary orientation and arrangement. Fragments of the former oxytalan fibre system were present within the contiguous portion of the periodontal ligament and adjacent to the advancing front of the reforming alveolar wall.

Oxytalan-vascular units sectioned transversely demonstrated the typical oxytalan fibre association with principal vessel groups in which the oxytalan fibres not only were related to the walls of individual vessels but also surrounded the total vessel complex.



Fig. 1. A composite photomicrograph of the tension side of the periodontal ligament adjacent to the buccal alveolar crest after 28 days of light force application. The oxytalan system has been reconstituted to maintain a relationship between the cementum and nearby blood vessels. Oxytalan and elastic fiber remnants at the site of the original periodontal ligament are undergoing dissolution. As vessels become enclosed in new bone, they lose their oxytalan fibers. **AB,** Old alveolar bone; **ABN,** new alveolar bone; **BV,** blood vessels; **C,** cementum; **D,** dentine; **EL,** elastic and oxytalan fiber remnants; **OX,** reconstituted oxytalan system; **PL,** re-forming periodontal ligament. The large arrow indicates the direction of movement of the maxillary first premolar. (Monopersulfate, aldehyde fuchsin, light green. Magnification, ×250.)



Fig. 2. Oxytalan fiber system on the buccal side of an unmoved maxillary premolar opposite the alveolar crest. Control section for Fig. 1. **AB,** Alveolar bone; **C,** cementum; **D,** dentine; **OX,** oxytalan fiber system; **U,** Oxytalan-vascular unit. (Monopersulfate, aldehyde fuchsin, light green. Magnification, ×250.)

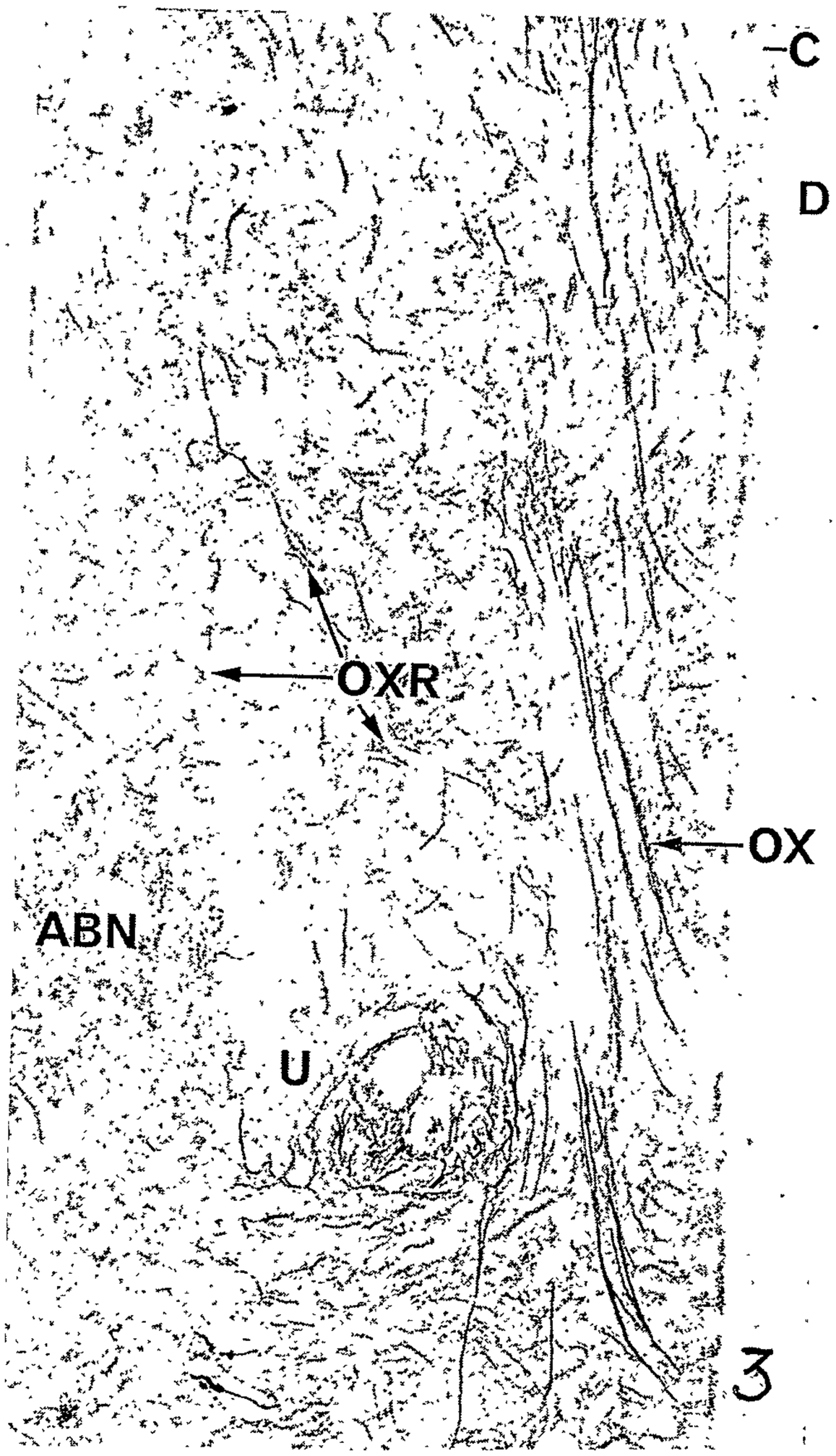

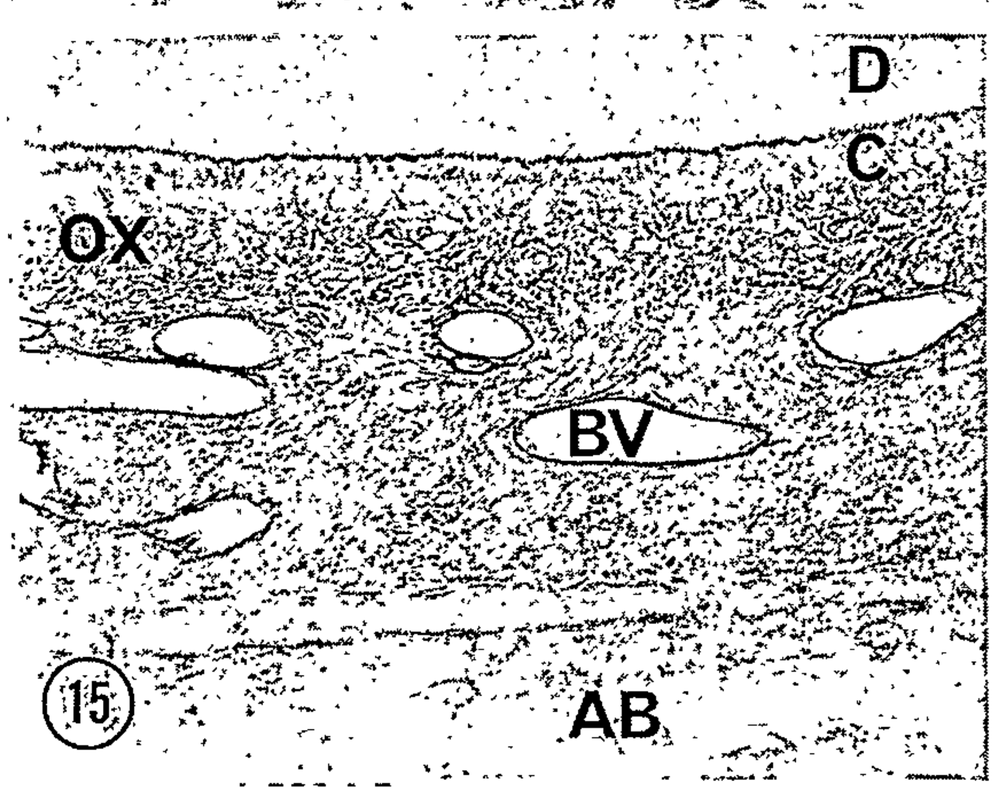

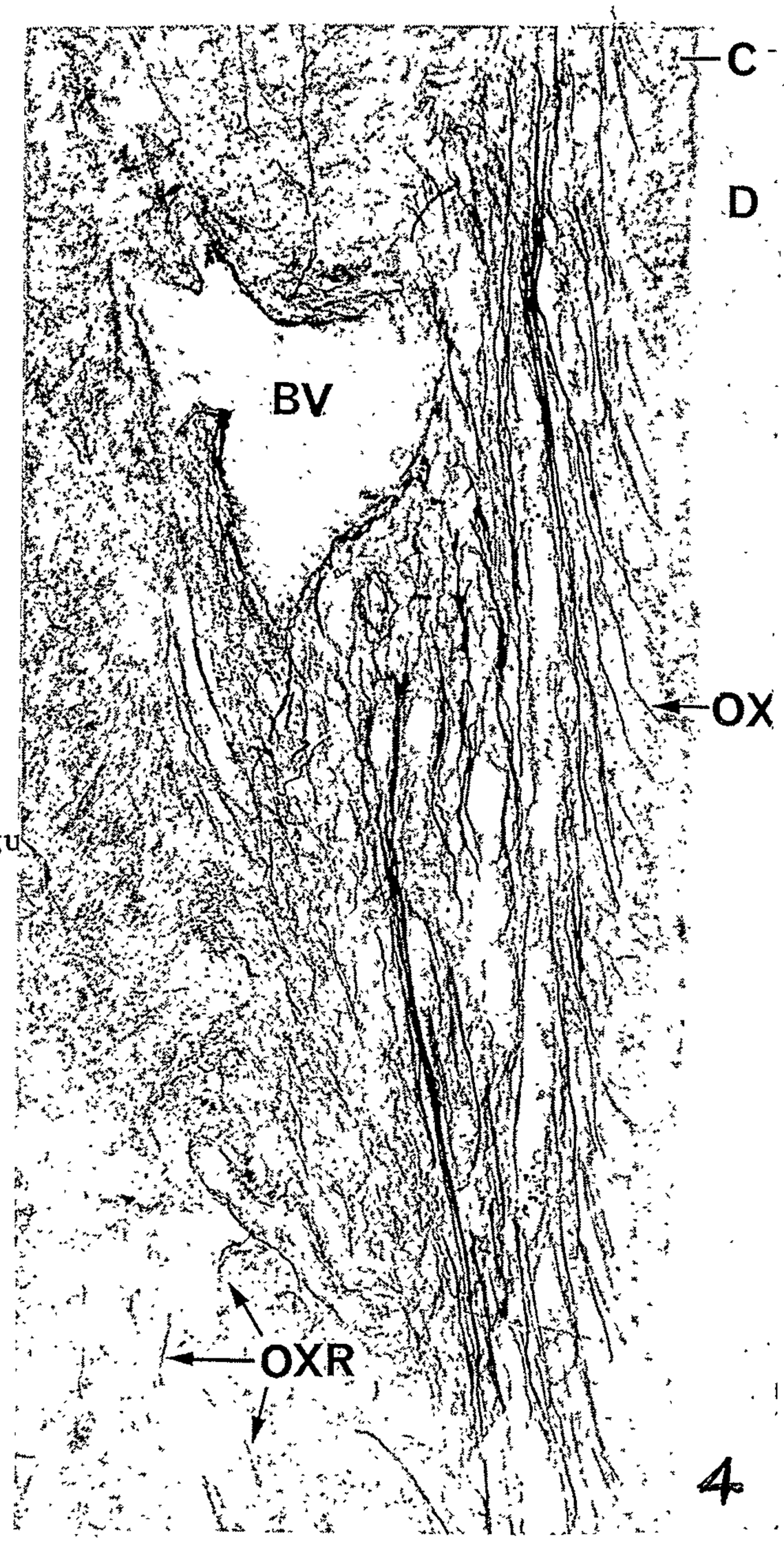

Figu

Sims61

Fig. 3. Tension side of the periodontal ligament slightly apical to the area illustrated in Fig. 1. The oxytalan system is undergoing reconsititution. Numerous remnant oxytalan fibers exist between the advancing front of new alveolar bone and the reconstituting oxytalan fiber system. An oxytalan-vascular group is seen in cross section. **ABN**, New alveolar bone; **C**, cementum; **D**, dentine; **OX**, oxytalan fibers; **OXR**, remnant oxytalan fibers; **U**, oxytalan-vascular unit. (Monopersulfate, aldehyde fuchsin, light green. Magnification, ×250.)

Fig. 4. On the apical side of the specimen presented in Fig. 3, the oxytalan fiber system shows less disturbance. The fibers are more numerous between the cementum and vessels. **BV**, Blood vessel; **C**, cementum; **D**, dentine; **OX**, oxytalan fiber system; **OXR**, remnant oxytalan fibers. (Monopersulfate, aldehyde fuchsin, light green. Magnification, ×250.)

Fig. 15. Horizontal section of the buccal periodontal ligament in the coronal third of a control premolar. Major oxytalan fibers, seen in cross section as dark-staining dots, are mainly located between the cementum and the blood vessels in the middle of the ligament. **AB**, Alveolar bone; **BV**, blood vessel; **C**, cementum; **D**, dentine; **OX**, oxytalan fibers. (Monopersulfate, aldehyde fuchsin, light green. Magnification, ×250.)

At the junction of the normal and middle thirds of the periodontal ligament there was less disturbance of the tissues and the oxytalan fibres were present in greater numbers.

Sims claims that when a localised heavy force of around 80 gms was applied to the periodontal ligament for 28 days localised destruction of the oxytalan fibres system occurred and could not be demonstrated opposite the alveolar crest region on either the tension or pressure side. In both these locations the periodontal ligament was devoid of normal histological structure when compared with control sections. Adjacent to the apical side of these disorganised pressure zones the customary oxytalan fibres system could not be detected. However an occasional thick oxytalan fibre could be seen attached to the cementum. Three millimetres from the alveolar crest the reconstituting oxytalan fibre system could be identified and traced as far as the apical region.

Generally the oxytalan and elastic fibres appeared to have a similar arrangement and orientation and to be associated with single vessels or multiple vessel groups. Horizontal sections through control teeth revealed that the oxytalan fibre system was predominantly located between the cementum and the periodontal vessels and not between the vessels and the alveolar walls.

In all the experimental and control sections of Sims the oxytalan fibre system exhibited a comparable pattern of distribution. This included a cemental component extending from the dentinocemental junction to the cementum surface. A fine plexus ensheathing the cementum surface and fibres which curved apically toward the periodontal vessels as simple fibre arrangements or aggregations of fibres described as fibre tracts. In addition to linking the tooth to the periodontal vessels, the oxytalan fibre system also connects the vessels to each other.

Sims feels that his work verifies the assertion of Fullmer that the oxytalan fibre is a distinct type of connective tissue component and a normal constituent of the periodontal ligament of Man.

The maintenance of an oxytalan fibre system between the cementum and the periodontal vessels after 28 days of orthodontic movement with light continuous force demonstrated that the oxytalan system was being continually reconstituted within the relocating periodontal ligament.

This finding contrasted with the loss of the oxytalan fibre system, without simultaneous reconstitution in patients who had zones of excessive orthodontic pressure or tension adjacent to the alveolar crest. Thus during the abnormal conditions produced by active orthodontic treatment the oxytalan fibre system indicated a rapid rate of turnover, especially where reconstitution of the oxytalan meshwork was necessary to maintain

the customary relationship of the meshwork between the moving tooth and the vessels of the remodelling periodontal ligament. Another feature of significance was the disappearance of oxytalan and elastic staining structures as their related blood vessels became involved in newly forming alveolar bone. This observation also provided evidence to suggest that rapid oxytalan and elastic fibre turnover could accompany an anatomic change in vascular environment and function.

Sims work supports the findings of Fullmer that under abnormal circumstances, it is the collagen fibres of the periodontal ligament which appear to undergo destruction before the oxytalan fibres which demonstrate greater permanence. It is considered that under normal circumstances both oxytalan and elastic fibres have a low turnover.

Within the periodontal ligament, multiple anastamoeses existed between the various branches of the occluso-apically orientated vascular complex. This system of vascular intercommunication was ideally arranged to permit the rapid topographic differentiation of vascular flow according to the physiologic requirements of masticatory function. Since the dense meshwork of oxytalan fibres linked the vascular complex to the tooth cementum, it is believed that the anastomosing vessel complex may respond to complex functional patterns of axial and non-axial tooth movement via the oxytalan fibre system.

Sims in several thousand sections failed to demonstrate oxytalan

fibres attached to alveolar bone and he feels that the isolated fibres sometimes enclosed in bone are actually remnants of the oxytalan fibre system which has been reconstituted in a new location as the teeth have moved horizontally and occlusally during the normal process of physiologic migration.

Sims' investigations have shown discrepancies between his work and other authors. He found the largest oxytalan fibres opposite the middle and apical thirds of the tooth and not in the cervical region.

He demonstrated fibres inserting into the cementum of the permanent teeth and found that both in the experimental and control material in this study revealed numerous elastic-staining fibres throughout the coronal half of the ligament. He feels it is significant that Fullmer reports that when elastic fibres are present in the periodontal ligament they always appear to be related to vascular structures as was the case with both oxytalan and elastic fibres in this study.

Sims feels that the nature of the oxytalan fibre remains incompletely determined as does its functional role. He quotes Rannie[49] who felt that the oxytalan fibre system may prevent overstretching of the collagen fibre system and obliteration of the vascular channels. Rannie's concept is obviously related to the belief that the oxytalan fibres are embedded in bone as well as cementum. Edwards and others conclude that the oxytalan fibres play an important role in the relapse of orthodontically

related teeth. Sims however feels that his study demonstrates that the human oxytalan system is capable of reconstitution and he feels that this makes hypotheses which attribute orthodontic relapse to the oxytalan fibre system untenable.

Sims has shown that with the use of light orthodontic forces the oxytalan fibre system was constantly being remodelled and maintained a characteristic cementum-vascular relationship even when teeth were moved a significant distance in alveolar bone.

6 THE PERIODONTIUM DURING ROTATION

Reitan[50] states that various factors are involved in the rotation of teeth. These are anatomical factors and mechanical factors.

The anatomical factors are primarily related to the position of the tooth, its form and size. With the exception of the upper central incisor, and to some extent the lower first and second premolars, most roots when seen in cross section have an oval form. Because of this form a parallel movement between the root surface and the inner alveolar bone surface takes place chiefly on the buccal and lingual sides of the root. Another anatomical detail to be mentioned is the arrangement of the periodontal fibres. It is well-known that the major group of the periodontal fibre bundles run from the root surface to the inner alveolar bone surface. The free gingival fibres, however, are attached in the gingival soft tissues and the periosteum. The variation in the attachment of the fibres plays an important part during the retention period.

The mechanical factor primarily influences the degree of rotation.

Reitan experimented applying a rotational force to the labial and

to the lingual, some teeth being rotated through 50-70°. Reitan divided the root into three sections, namely apical, middle and marginal. In the free gingival fibre group of the marginal region, a marked displacement and stretching of fibrous structures were observed in all cases. Because the free gingival fibres are continuous with the whole fibre system of this area, stretching will cause displacement of fibrous structures at some distance from the rotated tooth. This was seen especially in the fibre group located adjacent to the lingual and labial surfaces of the root. It was even found that tension had been exerted on the epithelial processes which were inclined as a result of traction by subjacent fibrous structures.

In the middle region usually bone resorption had taken place in two pressure areas while there was stretching of periodontal fibres and bone formation in two corresponding tension areas. Great variation existed in the degree of tissue response on the pressure sides. Frequently, direct bone resorption was observed in areas where the root moved parallel to the bone surface or in areas where the pressure was moderated because the tooth moved contacted the proximal tooth. In several experiments, direct bone resorption and compressed cell-free fibre bundles were found in one pressure area and direct bone resorption was found in the lingual area and indirect resorption starting in the labial pressure area. The indirect resorption starting as a result of the cell free area created in the periodontal space usually

lasted from 2-3 weeks. Because of this extensive resorptive process, a portion of the cementum and dentine of the root would be resorbed as well. Such after effects of an indirect bone resorption were found in several cases, and represents a typical reaction following rotation of teeth. In a few instances resorbed areas of the root were already repaired by cellular cementum.

The changes taking place on the tension sides were greatly influenced by the traction exerted on fibre bundles. A demarcation or resting line was observed between old and new bone layers. New bundle bone and osteoid tissue were found to be arranged in tongue-like spicules along the stretched fibres. Hence apposition of new bone is stimulated by the traction exerted on fibre bundles. This traction will also stimulate formation of cellular cementum on the root matrix.

In some cases a marked increase in the thickness of the cementum layer was found on the tension side. Very little cementum had been deposited on the pressure side.

In the apical region the supporting fibres were arranged obliquely. A moderate increase of new bone layers was observed in certain areas of the inner bone wall.

It has been shown that, following rotation, extensive tissue changes take place in the alveolar bone. There was a marked elongation of fibre bundles in all regions of the periodontal

membrane; in addition stretching and displacement of the gingival fibres were observed. It is obvious that the rotated tooth must be retained while rearrangement of these structures takes place.

Edwards[16] investigated the periodontium during the orthodontic rotation of teeth and asserted that it is not the active movement of the teeth but the retention of the teeth in their new positions that creates the difficulty in treatment. That the more conscientious the orthodontist the more difficult the retention problem and although there is much to be learned about tooth movement there is probably even more to be learned concerning maintenance of the teeth after they have been moved.

He feels that retention is one aspect of the overall orthodontic treatment, that relapse of orthodontically treated teeth should not be viewed as a pathological or abnormal phenomenon but as an unwanted or undesirable symptom of normal oral physiology. A logical search for an answer to relapse of orthodontically treated teeth in general and orthodontically rotated teeth in particular might be directed toward a more basic and comprehensive understanding of the supporting tissues of the teeth.

In addition to the fact that orthodontically rotated teeth relapse so frequently his study of the periodontium during orthodontic therapy has concerned itself with the investigation

of only the rotational movement of teeth for the reason that factors related to relapse, which are not intrinsic to the periodontium, can be more easily eliminated during rotations of teeth than during other types of orthodontic movement.

Labial, lingual, intrusion and extrusion, movements of teeth are more intimately associated with factors related to orthodontic relapse which are extrinsic to the alveolar structures - growth and neuromuscular changes - than are rotational movements of teeth.

Edwards noted one common observation by workers reviewing the collagen bundles of the periodontium that being the supracrestal connective tissue fibres whose length and direction are not altered by an ever changing osseous attachment are extremely slow to adjust to orthodontic movements of the teeth.

Edwards in his review undertook an investigation to determine the causes of rotational relapse and to acquire a better understanding of the alteration in the periodontal structures during rotation.

It was the purpose of his investigation to rotate teeth under controlled forces and to observe the effects of the rotational movements on the periodontium both macroscopically and microscopically and he posed the following questions.

1 Can actual gross alteration in the soft tissues of the periodontium be observed which coincides with the histologic reports of fibre straightening and displacement during tooth movement?

2 Does an intermediate plexus in the periodontal ligament become more apparent during orthodontic rotational movement?

3 Are there any noticeable changes in the structure or orientation of a possible elastic component (Oxytalan) of the periodontal tissues during rotation of teeth?

Edwards conducted an experiment with six young dogs orthodontically rotating their maxillary lateral incisors using the other anterior teeth as controls.

A shallow line was etched into the enamel of the lateral incisor close to the gingiva and this line was continued as a series of black dots tattooed in the gingiva.

The appliances were inspected on a weekly basis and every four weeks the elastic tension was checked and adjusted as necessary.

As the quantitative degree of rotation was not required rotational movement was recorded subjectively as

a) no rotation

b) slight rotation (5°-10°)

c) moderate rotation (10°-35°)

d) large rotation (>35°)

Fig. 1



Fig. 2

Fig. 1. Tattoo marks on gingiva before rotation of tooth.

Fig. 2. Tattoo marks on gingiva show deviation in direction of rotational movement of tooth.

Photographs above were taken before and after movement showing the tattooed line.

After varying periods of rotation and retention the animals were killed and sections prepared. Each series of sections was stained with four different stains.

1 Weigert's iron haematoxylin and eosin/phloxine mixture.

2 Weigert's resorcin-fuchsin elastic stain.

3 Gomori's one-step trichrome stain.

4 Selective staining for oxytalan fibres as described by Fullmer and Lillie with oxone replacing peracetic acid oxidation.

An attempt was made to establish whether the gross changes of the soft tissue surrounding rotated teeth as demonstrated with the experiment using the dogs could be demonstrated with humans.

Four volunteers had their gingiva tattooed with sterile India Ink injected into the gingiva with a 29 gauge needle.

It was observed in both humans and dogs that the amount of deviation between the tattoo marks coincided consistently with the amount of rotational movement of the tooth. The attached gingiva and to some extent the mucosa did follow in the direction of rotation. Moreover the gingiva surrounding the rotated tooth did not reorientate itself as shown by the deviated tattoo marks even after as long a retention period as five months.

In the free gingival fibre groups of the marginal region a marked displacement and apparent stretching of the fibrous structures were routinely observed. The most obvious displacement of the supracrestal fibres appeared to be located on the labial and lingual surfaces of the roots. The transseptal fibres of the rotated teeth also showed a consistent displacement. While the collagenous fibre groups in the transseptal region of a rotated tooth extended obliquely from the experimental tooth, the same transseptal fibres attached to the proximal tooth ran in the normal perpendicular direction. The periodontal fibres of the middle and apical regions of the root were likewise seen to be taut and disoriented in a direction parallel to the rotated root's surface.

Two weeks of retention following ten weeks of active rotation appeared to accomplish very little towards reorganising the periodontium to the new position of the tooth. After five months, however, the fibrous bundles of the periodontal ligament as well as the transseptal fibres closest to the crest of the alveolar septum appeared completely adapted to the new rotational position of the tooth. Well defined bone spicules could be observed forming along lines that coincided with the oblique direction of the periodontal fibres under tension.

Fig. 4. Bone spicules forming as tooth is rotated. Arrow on tooth shows direction of rotation. (Magnification, ×64.)

Edwards[16]



Reitan[51]

Fig. 17. Bone spicules forming along stretched collagen bundles during rotation. (From Reitan: Angle Orthodontist 29: 105-113, 1959.)

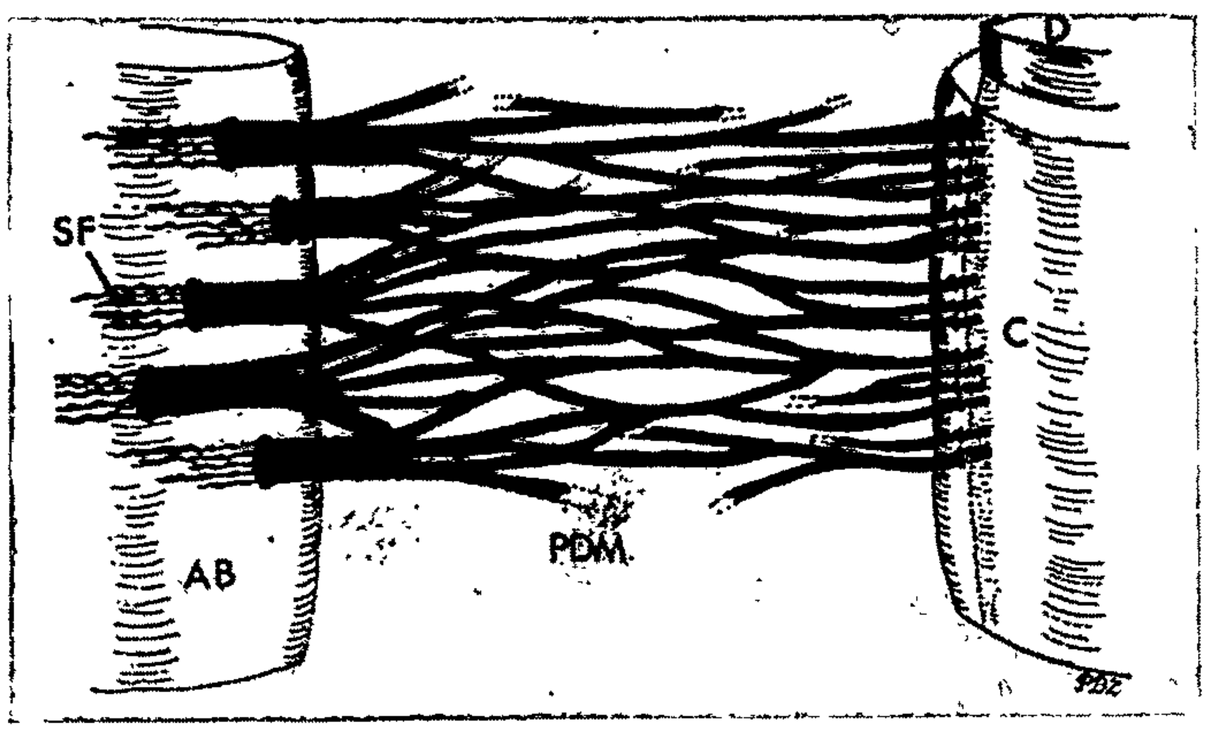

Fig. 15. Periodontal ligament in mouse. (From Zwarych and Quigley: Journal of Dental Research 44: 381-391, 1965.)

After five months of retention the osseous growth around these initial bone spicules had given the periodontal ligament a normal histological arrangement with the fibre bundles running perpendicular to the cementum instead of parallel to the root surface. The normal waviness of the connective tissue fibres of the ligament was once again evident. Only the supracrestal transseptal and gingival connective tissue fibres were still disoriented in direction.

The periodontal ligament of the dog was seen to consist of collagenous fibres organised into the classical principal fibre bundles and indifferent fibrous tissue. Blood vessels, lymphatic vessels, ground substance and nerves were abundant in the interstitial spaces of the ligament.

Edwards confirmed the work of Zwarych and Quigley[77] that in mice the fibre bundles attached to the alveolar bone were greater in diameter and fewer in number than those bundles attached to the cementum.

The loosely packed fibres making up the alveolar bundles were observed to become more loosely arranged as they passed from the bone to the middle of the periodontal space. The original bundle arrangement was lost as the individual fibres took separate courses. Some of the fibres from each of the alveolar bundles joined with fibres from adjacent alveolar bundles as they coursed into the periodontal space. These fibre bundles now increased in number but containing fewer fibres continued toward and became

attached to the dental cementum. Many fibre bundles from both control and rotated teeth were traced from the alveolar bone across the periodontal ligament to the cementum without any interruption in their continuity.

With the exception of straightening out the usual waviness of the periodontal fibres and reorientating their positions to the rotated teeth, the orthodontic rotation of dog's teeth produced little change in the periodontal ligament. Orthodontic rotation does not make an "intermediate plexus" apparent in the periodontal ligament of the dog.

Oxytalan fibres presented variable configuration and distribution in different areas of the periodontal tissues. All of the specimens contained an accumulation of oxytalan fibres that run parallel to the free group of collagen fibres. These fibres were observed to have a wavy appearance as they extended superiorly to merge with the subepithelial connective tissues of the marginal gingiva and interdental papilla. These oxytalan fibres attached to the tooth just inferior to the gingival epithelial attachment.

Other groups of oxytalan fibres attached to the neck of the tooth and extended into the transseptal groups of collagen fibres. None of the oxytalan fibres in the transseptal region could be traced from one tooth to the next. As the transseptal groups of collagenous fibres approached the crest of hte interdental septum, the oxytalan fibres running with them became markedly reduced in number. The centre half of the transseptal area was

Fig. 5. Periodontal ligament appears stretched and deviated during tooth rotation. No intermediate plexus is seen. *T*, Tooth. (Magnification, ×120.)

Fig. 6. Collagen bundles of periodontal ligament of rotated tooth show no intermediate plexus. (Magnification, × 120.) *T*, Tooth; *B*, bone.

completely devoid of oxytalan fibres in both the control and experimental periodontiums.

Although Fullmer claims to having seen oxytalan fibres insert into the crest of the alveolar bone it was not observed in Edwards' study. Numerous slender oxytalan fibres were seen within the circular collagen groups in the free gingiva. Beneath the transseptal region very few oxytalan fibres were observed and practically none of them extended in a horizontal direction from tooth to bone.

In the middle third of the periodontal ligament the oxytalan fibres again became more numerous.

Goggins[25] reported flat bands or ribbons of oxytalan fibres in the middle regions of the root supposedly oriented in an apico-occlusal direction. In Edwards' study these flat wide oxytalan fibres were observed as weaving in and out in a direction perpendicular to, but in the same plane with, the collagen fibres of the ligament and inserting into neither cementum nor bone.

In Edwards' study very few oxytalan fibres were observed in the apical regions of the periodontal ligament although both Fullmer and Goggins claim the existence of oxytalan fibres in these areas.



Fig. 11. Fine-diameter oxytalan fibers in transseptal region of nonrotated tooth. (Magnification, ×360.)

Fig. 12. Very large and distinct oxytalan fibers in transseptal area of rotated tooth. Fibers are deviated in direction from rotation of tooth. *T*, Tooth. (Magnification, ×320.)



Fig. 13. Dense aggregation of oxytalan fibers in transseptal area of rotated tooth. *T*, Tooth. (Magnification, ×320.)



Fig. 14. Arrows indicate oxytalan fibers running perpendicular to collagen bundles in mid-region of root. Longitudinal section of root. (Magnification, ×340.)

Edwards felt that a particularly significant observation was the fact that oxytalan fibres particularly in the supracrestal areas were already more numerous and more clearly defined in the periodontiums of rotated teeth than those in the control teeth.

The periods of retention did not eliminate this preponderance of oxytalan in the gingival tissues of the rotated teeth. In serial sections of the entire length of the root, the oxytalan fibres were more numerous in the buccal and lingual areas of the attachment apparatus which Reitan believes are subjected to the most tension during rotation.

The final return of the slow metabolising connective tissue fibres to their original and stable relationshp to the tooth and each other depends on the remodelling of the osseous tissue. The supracrestal fibres, of course, do not have the plastic osseous tissue to eliminate their distortions after tooth movement and so remain in a taut and deviated position for long periods of time.

The fact that oxytalan fibres were more prevalent in the areas of the periodontium most subjected to mechanical stress, i.e., the free gingival margin and the transseptal regions. They apparently increase in number and definitiveness during orthodontic treatment might indicate that they have an anchoring effect which would prevent overstretching of the tissue in certain areas. The preponderance of oxytalan fibres embedded in the cementum suggests an attempt to prevent the disastrous tearing of the connective tissue from the tooth during periods of

stress. Edwards states that periodontics recognises the fact that it is less harmful to the integrity of the periodontium for a mechanical force to tear connective tissue fibres away from bone or to tear the fibre bundle itself than to tear them away from the cementum especially at the region of the epithelial attachment.

Edwards feels that particular significance should be made of the observation on "elastic" oxytalan fibres suggesting an anatomic explanation for the relapse tendency of orthodontically rotated teeth.

Reitan[51] stated that the mechanical precedure of rotating malposed teeth has seldom been considered a problem in orthodontics. On the other hand it is well known that the rotated tooth frequently shows a tendency to move back towards its original position after removal of the appliances. This occurs especially in cases where the respective tooth has been rotated rapidly and by a considerable amount.

Various factors are involved in the movement of rotation and Reitan reviews the anatomical and mechanical factors involved.

Since rotation causes extensive changes in the alveolar bone, with elongation of the fibre bundles in the periodontal membrane as well as stretching and displacement of the free gingival

fibres, it is obvious that the rotated tooth must be retained while rearrangement of these structures takes place. In experiments on retention one should be able to observe the length of time required for a rearrangement of the structures involved.

During retention an examination of the supporting structures of retained teeth may be applied to the same areas as previously mentioned with two kinds of tissue being of special interest, the fibre bundles of the periodontal membrane and the newly formed bone tissue.

Fibrous Tissue

As shown in Table 1, six teeth were retained for periods varying from 15 to 232 days.

Rearrangement of fibrous tissue means that the periodontal fibre bundles are again running more or less perpendicular from the root surface, as seen in the supporting structures of the control teeth.

In Table 1, the marginal region comprises the areas of the gingival free and transversal fibres. No rearrangement had occurred after periods of 15 and 28 days and it was noted that the fibre bundles attached to the labial and lingual sides of the root were still under tension. The free fibre bundles of the teeth retained for 147 and 232 days still remained stretched in accordance with the previous movement of rotation. This once again particularly applies to the fibre bundles attached to the labial and lingual surfaces of the root.

In the middle third of the root complete rearrangement was found after periods of 147 and 232 days and in the apical third rearrangement was found even earlier.

Bone Tissue

In all regions very little rearrangement was observed after a period of 15 days with partial rearrangement after 28 days new bone being formed along the stretched fibre bundles. This tongue-like bone formation was observed in the experiments on retention after periods of 15 days. After retention for 28 days new bone had been added between these first bone spicules. After periods of 147 days and 232 days retention still more complete organisation of bone tissue had taken place.

Reitan concludes from his experiments, having noted differences between the gingiva of dogs and humans, that the persistence of stretching and displacement of fibre bundles in the marginal region indicates that complete rearrangement of the supporting structures requires a longer period of retention than 232 days.

Why free gingival fibres remain in a stretched position may be explained by the fact that they are attached to a movable fibrous system which to some extent may be displaced even at some distance from the tooth moved. In addition, the supra-alveolar structures contain elastic fibres which may yield to traction during rotation. The result of this will be a tissue that will remain stretched during the retention period. Forces leading to contraction of these fibre bundles will enter into action at the moment the tooth is released, by which relapse of the tooth moved may occur.

Reitan recommends that:

1 Over-rotation would seem desirable in order to ensure a correct tooth position after the retention period.

2 That transsection of the stretched fibres would be an advantage.

3 Early correction of a rotated tooth position would prevent relapse of the tooth moved because new fibre bundles, formed in the apical regions, would assist in retaining the rotated teeth.

Reitan[52] feels that it has been customary to regard changes that occur in the supporting tissues following orthodontic tooth movement as being primarily related to the active treatment period but that account must also be taken of not only the period of active treatment but of the retention phase as well.

He stresses the need of light forces and has shown that resorption does not occur all along the pressure side until the cell-free area has been eliminated by undermining bone resorption. If the initial hyalinised zone is small, the underlying bone is readily eliminated by resorption. These small hyalinised zones can be only created by light forces. If fairly rapid tooth movement is to be achieved the hyalinised zones must be avoided or kept as small as possible.

Reitan states that if muscle imbalance is absent, well established interdigitation will greatly assist in maintaining the end result of tooth movement. However, not even the most precise

intercuspal relationship will prevent relapse if muscular imbalance ensues. In the anterior segment this is further affected by the contraction of stretched and displaced fibrous structures of the alveolar process, i.e., the effect of post-treatment tissue reaction. He felt that there is always a tendency towards post-treatment contraction of fibrous tissue and that the fibre bundles, notably the supra-alveolar structures, tend to rearrange themselves according to the original growth pattern.

Reitan has shown that during rotation, rearrangement of the alveolar fibres occurs much sooner than that of the supra-alveolar fibrous system. Shortly after treatment there is no marked difference in the arrangement of the supra-alveolar fibres as compared with those of the middle and apical thirds of the root, yet it is shortly after the removal of active appliances that relapse movement begins to occur.

Reitan found that the supra-alveolar fibres react differently from the other support tissue. The tissues covering the alveolar process constitute a continuous fibrous system. The effect of the stretched supra-alveolar tissue contraction is observed particularly following rotation. These tissues have been moved into imbalance.

Rearrangement of Fibrous Tissue

Tooth	Retention	Marginal Region	Middle Region	Apical Region
+2	15 days			
2+	28 days		++	++
+2	57 days	+	++	++
2+	83 days	+	++	+++
+2	147 days	+	+++	+++
2+	232 days	+	+++	+++

Table I + indicates partly, ++ fairly well, and +++ completely rearranged fibrous tissue after retention.

Rearrangement of Bone Tissue

Tooth	Retention	Marginal Region	Middle Region	Apical Region
+2	15 days			
2+	28 days		+	+
+2	57 days	+	++	++
2+	83 days	++	++	++
+2	147 days	++	++	+++
2+	232 days	++	+++	+++

Table II + indicates partly, ++ fairly well, and +++ completely rearranged bone tissue after retention.

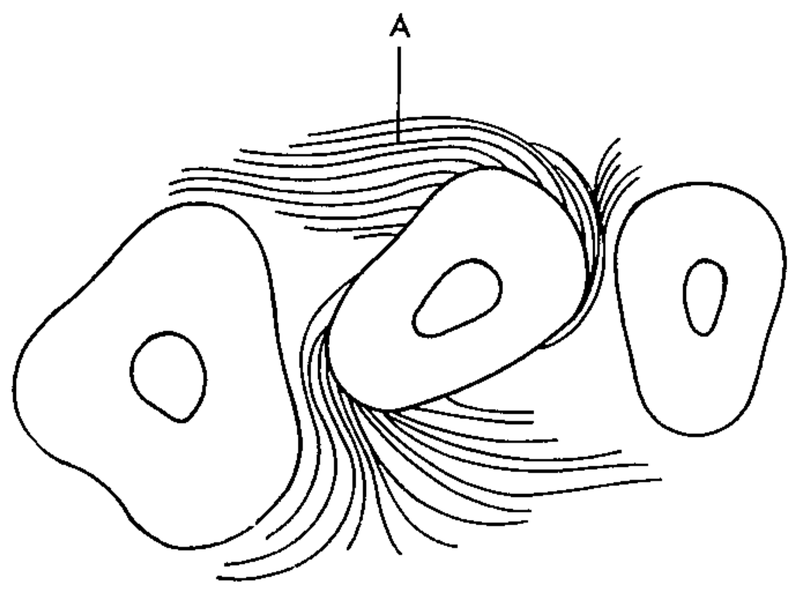

Fig. 25. Rotated tooth, animal experiment. *A*, Major part of the supra-alveolar fibers will remain stretched, even following a long retention period.

Reitan[51]

Fig. 26. Area shown in Fig. 25. *A*, Cross section of tooth. *B* and *C*, Displaced and stretched fiber bundles continuing into fairly distant areas of the supra alveolar structures. Dark line parallel to root surface represents folding of tissue frequently observed in the dog.

Reitan[52]

Figure 26 shows that stretched fibres are found even at a considerable distance from the rotated tooth. These stretched fibres interlace with the surrounding tissues. Retention of rotated teeth illustrates the duration of displacement of supra-alveolar tissues. Rearrangement of the bone and principal fibres in the middle and apical regions may occur after a fairly short retention period. After a retention period of 232 days there was still displacement of the supra-alveolar structures.

Over-rotation may partly solve this retention problem and extended retention may overcome the problem when a well adjusted retainer is used.

7 INTERCANINE WIDTH MAINTENANCE

Lewis[35] states that orthodontists generally consider that arch width in the lower canine area should be the same at the conclusion of treatment as it was in the original malocclusion this being generally governed in great part by the architecture of the supporting skeletal bone.

Expanded lower arches, especially in the anterior region, can be held in a state of expansion by retainers for an extended period of time, but the lower teeth will move back toward their original position, in most instances, on removal of the retainer.

At the conclusion of treatment, the curvature of the dental arch at the incisal should follow the same general curvature that existed in the original malocclusion. This is almost as fundamental as the rule of intercanine width.

Careful attention should be paid to the lower teeth at all times but particularly as the time for retention approaches. Not only should the intercanine width be maintained, but premolar and canine-lateral incisor relations should also be restored to normal. In the haste to get the bands off and retain the case, it is much too easy to fail to notice whether lateral incisors and canines are still related and whether canines have been expanded or made too narrow in their relation to the premolars

and to the lateral incisors. It is easy to correct these small but highly important irregularities. Retention is much simpler and stability is much greater if these corrections can be made before, rather than after, the bands have been removed.

Lewis advocates marking the buccal cusps of the lower molars and premolars with a soft pencil, and continued on the cutting edges of the canines and incisors, it is easy to note whether any of these teeth are out of line with the remaining teeth. These pencil marks will also show slight rotations quite effectively.

Lewis points out also that variations in tooth form exist on the lower incisors and sometimes on the upper incisors as well and these are of great interest to the orthodontist at the time of retention. One such anomaly has been called "dog ears". This term is applied to the knobs or bumps of enamel that occur occasionally on the mesial and distal surfaces near the incisal edges of the incisors. The sum total of this additional thickness of enamel may be quite small but, even so, they are a hazard to successful retention, particularly in the lower arch. Not only is there an additional thickness of enamel to consider in these cases, but the ball point contacts that result from these knobs of enamel create an unstable situation because the lower incisors constitute the weakest or most vulnerable segment in the dentition. They are generally the first to collapse when the occlusion starts to slip.

He recommends stripping which removes the ball point contacts and

changes them to flatter contacts. This ensures greater stability for the lowr incisors during and after retention as it is one of the most important and susceptible areas in the patient's mouth and it is the six lower anterior teeth where so many relapses occur.

Lewis advocates the use of a lower canine to canine retainer with the ideal position of the wire to be just below the contact points of the four incisors. It is the best location to prevent a recurrence of rotations, for the lingual surfaces are broad and relatively flat in this area.

Bellardie[6] supports the view of Lewis and found that if the intercanine width was increased by 2 mm or more then relapse would occur. Mischler and Delivanis[41] state that maintenance of arch dimensions during treatment and retention is essential for the stability of orthodontic treatment. Ronnerman and Larson[56] conducted a study of 23 patients before, immediately after, 3 and 10 years after the completion of active treatment. They found that there wqs, in most cases, some increase in intercanine distance which occurred during active treatment. A decrease in intercanine width occurred when examined at the three-year control and all patients showed a decrease which had become aggravated at the ten-year period. Some of their results may have been clouded by having the width of banding material to contend with. They found that a reduction of space in the

mandibular incisor segment seems to continue despite the fact that growth should have been completed.

Riedel[54] states that in almost every instance manidibular intercanine width tended to return to, or maintain, the original dimension after all retaining devices have been removed for several years. This subsequently caused relapse of crowding and rotation of the lower incisor.

Williams[75] states however, that the old concept, that lower intercanine width cannot be increased permanently is only true some of the time. After treatment, the newly acquired lower intercanine width will be maintained without retention if the lower cuspid crowns are moved distally into a wider part of the jaw and if their apices are moved buccally so that they are at least under the crown. If the apex is not moved buccally along with the crown while distalising the cuspid, lingual relapse of the crown into the incisor area is likely.

8 SURGICAL INTERVENTION

Transsection of fibrous tissue to overcome the problem of rotational relapse has been suggested and in animal experiments has been demonstrated by Wiser.[76]

Wiser conducted an experiment by orthodontically rotating dog second maxillary incisors. The rotations ranged from 29° to 60° and the duration of appliance therapy extended from six to ten weeks.

Localised gingival surgical procedures designed to excise the supra-alveolar fibres of the periodontal ligament and gingiva were performed in the area of the maxillary right second incisors. The maxillary left second incisors served as non-surgical controls.

Before and after tracings were made to illustrate the degree of regression that had occurred in the control group and the surgical sample.

In every instance the non-surgical control incisors demonstrated a regression tendency four times greater than those treated surgically.

Serial transverse histological sections were made to show the

changes that had occurred in and about the cervical areas of the rotated teeth.

Wiser feels that the histological explanations for the differences in the regression tendencies of the control and the surgical incisors is based on the presence of localised degenerative changes that occurred in the periodontal fibres of the pressure areas surrounding the surgically treated rotated teeth. The surgical interference appears to have produced degeneration of the cervical fibres due to the loss of vascularity that resulted from the incision of the gingival vessels in the operative field. The transitory degenerative areas were replaced with osseous tissue that originated from the alveolar bone where the blood supply was not surgically depressed to the same degree.

The degenerative histological changes were absent in the non-surgical control group, where rapid reorganisation of the cervical fibres resulted in a mean regression of 43.8% as compared to a mean regression of 11.2% in the surgically treated incisors.

Begg[5] advocates over-rotation as the method of choice in the orthodontic treatment of rotated teeth and the holding of the teeth affected in their new positions by the use of offset bends in the archwire. He feels that having rotated the teeth in this position will allow it with the usual amount of relapse to be restored to its normal position.

Edwards[17] reviewed relapse and its prevention and states the well accepted point that precise tooth movement is easily achieved but retention of the tooth in its altered position is another matter and of course stability of the final result after the completion of active orthodontic therapy is a major requisite.

He feels that knowledge of the retention phase of treatment is empiric and retention procedures are largely arbitrary.

Edwards feels that a pragmatic search for an implement to alleviate the relapse of orthodontically treated teeth must be developed with a comprehensive understanding of normal oral physiology.

Edwards reviewed in this paper the effect of tooth movement across and so closing extraction cases and the relapse problems involved. He found even in cases where treatment was meticulously carried out so as to provide tight approximation of the teeth adjacent to the extraction area and where the roots were properly paralleled before the commencement of the retention phase that in a short time the teeth adjacent to the extraction space began to separate. This space opening varied from a fraction of a millimetre to a number of millimetres.

This loss of contact then allows food impaction and subsequent trauma to the gingival tissues. Additionally the separation causes alteration to the ocelusal forces and additional trauma to the periodontium.

Edwards points out that it is accepted by most oral anatomists that teeth are retained in the alveolar arches by three groups of supportive fibres:

1 The alveola-dental fibres (periodontal ligament) connecting the alveolar bone to the cementum

2 The interdental (transseptal fibres) running just superior to the alveolar crest and directly connecting adjacent teeth

3 The gingival fibres originating in the cementum and terminating in the connective tissue of the gingiva.

The final return of the slow metabolising connective tissue fibres to this original and stable relationship to an orthodontically moved tooth and to each other depends on the remodelling of the osseous tissue to a large extent. It is apparent that such reorganisation of the periodontal ligament and adjacent alveolar bone is a fairly rapid process.

The supracrestal (gingiva and interdental) fibres do not have the plastic osseous tissue to eliminate their distortions after tooth movement.

Atherton[2] was one of the first to document closely the changes in the gingival tissue as teeth moved through an extraction area. His work showed a piling up of gingival tissue between the two teeth that had been approximated and demonstrated that the approximated teeth apear to displace the gingival tissue more than move through it.

Boase[8] and Edwards both believe that the displaced gingival tissue creates possibly the most persistent force towards relapse of rotated teeth.

Edwards was able to demonstrate that the oxytalan fibres present in the gingival tissues appears to increase in density during rotation of teeth and that this change in oxytalan density does not disappear even after one year of retention. Boase confirmed the findings of Edwards.

Edwards carried out an investigation using an extraction site on one side as the experimental site and the opposing side as a control site. Teeth were approximated and two months prior to the normal time for appliance removal the bands were removed to ascertain if any relapse tendency existed. These were observed and recorded and the teeth rebanded and once again the teeth were approximated. One week prior to band removal a surgical procedure was carried out on the experimental side to remove the excess gingival tissue in the interdental space. Retention appliances were fitted as normal when the orthdontic bands were removed.

Critical appraisal was given for treatment deficiencies which would commonly cause opening o fthe extraction sites.

1 Poor paralleling of the roots of the teeth adjacent to the extraction sites.

2 Improperly fitted retainers.

3 Occlusal dysfunction which would tend to open the extraction sites.

4 Obvious imbalance between intraoral and extraoral musculature.

Edwards found that, in all patients, the tooth that was retracted distally appeared to displace the gingival tissue rather than moving through it with the result that the displaced gingiva began to accumulate or pile-up distal to the moving tooth. In rapidly moved teeth a triangular area with little keratinisation (Atherton's red patch) formed on the mesial surface of the gingiva of a distally moving tooth.

After final closure of the extraction site the gingival tissue which had accumulated between the approximated teeth appeared divided into a buccal and a lingual papilla. A vertical cleft in both buccal and lingual gingiva was observed in all but one case. In many cases the cleft extended incisally to disappear into the papilla of accumulated gingiva and to exit in a tunnel-like manner at the margin of the gingival papilla.

A clinical review of dozens of properly treated extraction cases demonstrated not one case in which the teeth adjacent to the extraction site had moved apart during retention and did not show evidence of a crease or groove in the gingiva between the approximated teeth. Moreover the cases which did not show any signs of relapse in the old extraction areas invariably did not

Fig. 7. Normal gingiva following interproximal surgery. Note absence of any gingival groove or papillae No relapse-spacing between teeth (8 months after appliance removal)

Fig. 8. Control side Note relapse-spacing between teeth, persistent gingival groove and papillae are present

show the slightest gingival groove or crease between the teeth. Such observations would indicate a possible relationship between such gingival distortions and relapse phenomena in extraction cases.

In none of Edwards' controls did the gingival groove and the excess gingival papilla completely disappear after nine months of retention (17-19 months after initial closure) although the piled-up excess gingival tissue which resulted from the approximation of the teeth seemed to dissipate where reopening of the extraction site occurred.

Edwards felt that his apparent success in reducing the relapse of approximated teeth by the surgical removal of the excess gingiva suggested that the folded tissue played an important part in the reopening of extraction sites after orthodontic treatment. It seems that the unattached gingival tissue is slowest to adapt to orthodontic movement and that such tissues are probably the most persistent relapse force in the periodontium.

Edwards[18] in 1970 states that many orthdontists evaluate the retention phase of orthodontic treatment as the most difficult problem of therapy. In fact, the more conscientious the orthodontist, the more he might regard retention as the problem in treatment. It is far easier to summarise the ideals of a successful retention programme than to accomplish them during actual treatment.

His investigation was an attempt to develop and study the efficacy of a simple surgical technique to lessen the problems that arise during retention of orthodontically rotated teeth.

Edwards reiterates that the supracrestal (gingival and interdental) fibres do not have the plastic osseous tissue to eliminate their distortions after tooth movement.

As previously stated Reitan was one of the first to report that the collagenous supporting tissue fibres of the gingiva appear histologically taut and directionally located after tooth rotation and this fibre alteration does not appear to lessen in the supracrestal tissues after even long periods of retention. Edwards with his tattooing technique demonstrated that the attached gingiva, particularly the marginal gingiva, is pulled along with the tooth as it is rotated. Thus the fibres of the gingiva do remain attached to the tooth during orthodontic rotation which results in a displacement of the gingiva in the direction of tooth movement.

Techniques of Retention

A number of popular philosophies have evolved for retention of rotated teeth.

1 Rotations must be corrected by overrotation of the tooth in the opposite direction.

2 Rotated teeth must be retained over an especially long period of time preferably with a fixed retainer.

3 Treatment of rotated teeth must be performed at an early age.

4 Any rotational technique which produces sufficient amounts of osteoid tissue in the root area will aid in the retention of the rotated tooth.

5 A properly equilibrated occlusion will practically eliminate retention worries.

Edwards states that while it is true that osteoid tissue will not resorb as readily as mature bone, it has now been shown that any retentive effect of an osteoid layer surrounding a rotated tooth is effective for a matter of only a few days as osteoid is transformed into new bundle bone, a type of bone more resorbable than mature cancellous bone. Thus since osteoid tissue cannot be relied upon to hold a rotated tooth in position some mechanical type of retention must be used in every case. Moreover, despite the hope that a properly equilibrated articulation of opposing teeth will alleviate rotational relapse Boase[8] has shown that all too frequently clinical observations seem to indicate that occlusion is a secondary factor in determining relapse patterns.

Reitan, among others, has advocated the use of early rotation to lessen relapse. He feels that such early treatment will ensure stability since there will be formation of new and stronger ligamentous fibres as the apical portion of the root completes

its growth after the tooth has already been rotated to its proper position.

To Edwards such a postulation is surprising since Reitan himself was the first to report that alterations in the fibres and bone attached to the root of the tooth rapidly reorganise and adapt to the new position of a rotated tooth. Apparently there exists little evidence that the periodontal ligament and its alveolar tissue play any significant part in rotational relapse after 2-3 months of mechanincal retention.

Boase, among others, has demonstrated that even the value of over-rotation and prolonged retention in previously rotated teeth produce questionable degree of increased stability.

Boase, Edwards, Reitan and Thompson have in their separate investigations shown that the major relapse pull on a rotated tooth appears to be located somewhere in the supracrestal fibres.

In an attempt to alleviate the pull on rotated teeth various surgical treatments have been suggested. One was immediate torsion with surgical forceps which proved less than successful and had a problem of pulpal degeneration. Septotomy has been tried as has removal of the buccal and lingual cortical plates. These radical treatments would not seem to be wise in these days of 'instant' litigation!

Thompson and Boase removed all the attached gingiva leaving only the mucosa and reported a significant reduction in relapse.

Edwards has devised a technique intended to reduce relapse of the rotated tooth significantly but not to damage the periodontium.

He has used his tattooing technique to evaluate the results in releasing the pull which the periodontal fibres have on the rotated tooth.

Edwards experimented using both anterior and posterior teeth which were rotated. The rotated teeth varied in extent of deviation from 20° to 90°. All patients had a series of ink dots tattooed as a vertical ine on the gingiva. Photographs of these lines were taken during active rotation and retention.

Rotational correction was carried out and in no case was overcorrection of the rotated teeth carried out. The teeth were retained for two months and then the retainers were removed. Over a three month period any relapses or alteration to the tattoo markings were recorded. These teeth were then realigned and the surgical procedure carried out by vertically inverting a blade into the gingival sulcus and severing all fibrous attachments surrounding the tooth to a depth of approximately 3 mm below the crest of the alveolar bone. No excision of attached or marginal gingiva was undertaken.

Sulcular depth was measured with a periodontal probe before and after the procedure as well as after healing. Photographs were

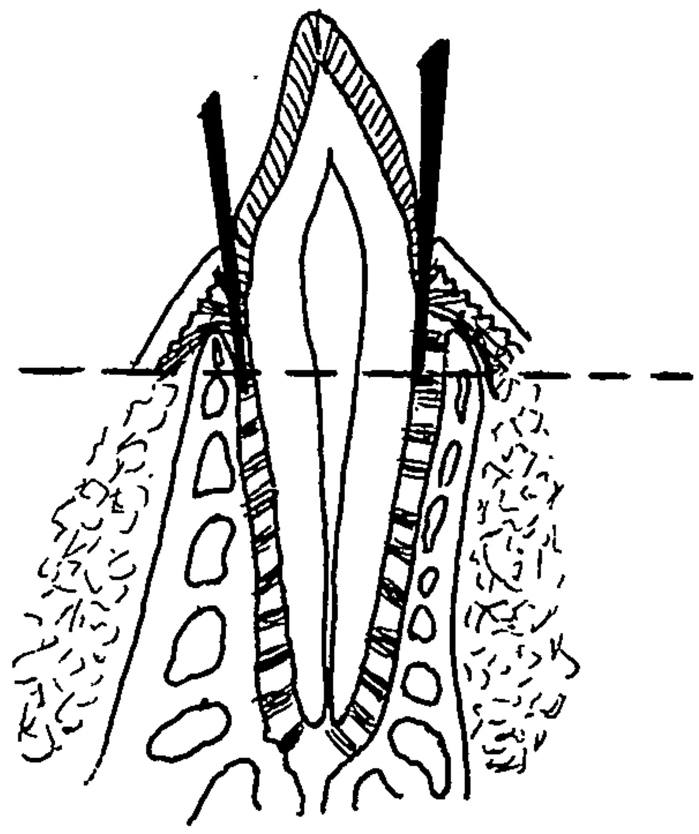

Fig. 2. Level approximately 2 to 3 mm. below alveolar crest to which incision is extended.

Fig. 3

Fig. 4

Fig. 5

Fig. 6

Fig. 3. Tooth following orthodontic rotation.

Fig. 4. Deviated tattoo line on gingiva following rotation of tooth

Fig. 5. No. 11 Bard-Parker blade entering gingival sulcus to sever supracrestal fibrous attachment around circumference of tooth

Fig. 6. Periodontal probe showing normal sulcular depth one week after surgical procedure Note that tattoo marks have reverted to original vertical alignment

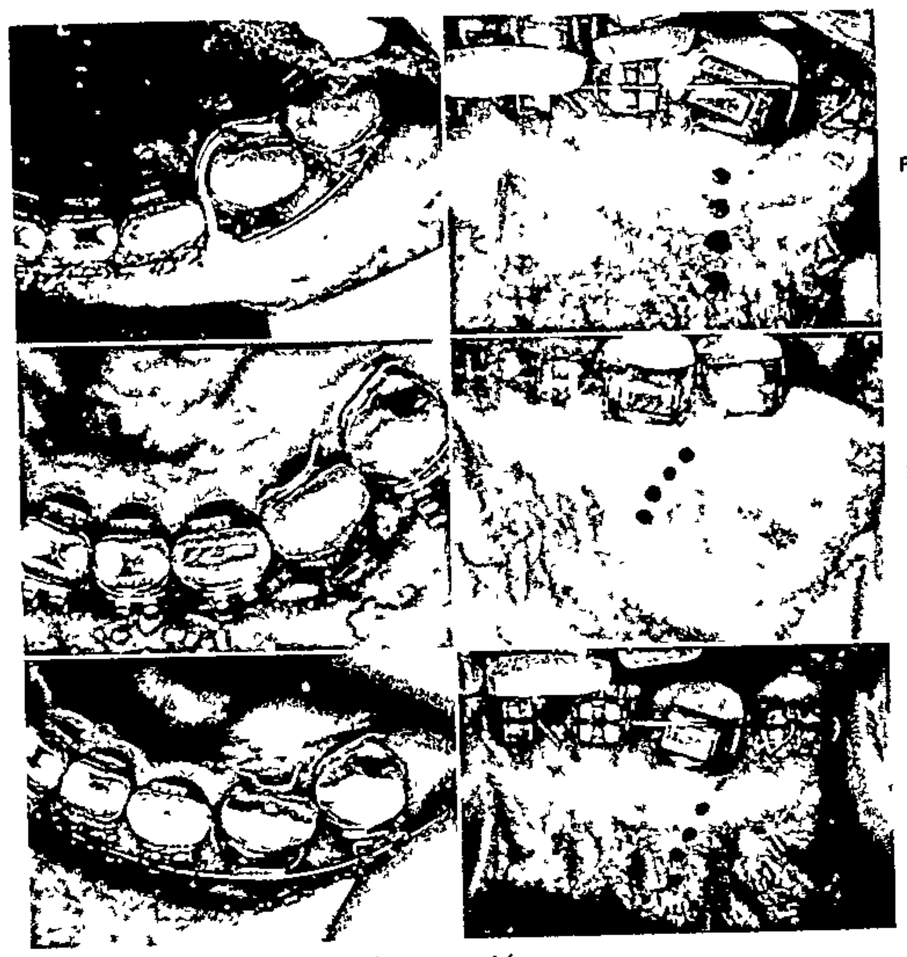

Fig 7

Fig 8

Fig 9

Fig. 10

Fig 11

Fig 12

Fig 7. Malaligned canine tooth under rotational forces

Fig 8. Vertical tattoo line on gingiva before rotational correction

Fig 9. Incisal view of canine tooth after rotational correction

Fig 10. Deviated tattoo markings in direction of tooth rotation Note accumulation of gingival tissue distal to rotated tooth

Fig. 11. Canine has relapsed approximately 20 degrees in 2 months following full rotational correction

Fig 12. Tattoo marking has also relapsed toward vertical arrangement as tooth relapsed

Fig. 13

Fig. 14



Fig. 13. Surgical blade severing fibrous attachments around tooth to a depth below alveolar crest, surgical procedure followed correction of rotational relapse.

Fig. 14 Periodontal probe showing 6 mm. sulcular extension following surgical procedure. Note that tattoo markings are still deviated.

Fig. 15



Fig. 16

Fig 15 Probe showing normal sulcular depth 10 days after surgical procedure Tattoo marks are now in original vertical alignment

Fig. 16 Incisal view showing no rotational relapse 3 months following surgical procedure No mechanical retention was employed postoperatively

made of the tattoo during the surgical procedure and after dressing removal. The degree of rotational relapse was again recorded after a three month period following the surgical procedure and no mechanical retention was used during this final observation period following surgical intervention.

In all instances the amount of deviation between the original vertical line of tattoo marks coincided consistently with the amount of rotational movement of the teeth. The attached gingiva and to some extent the mucosa apparently did follow in the direction of rotation. It was often observed that in cases of large rotational movement gingival tissue appeared to accumulate in a piled up fashion in the interdental area toward which the tooth was rotating.

During the previously described surgical procedure the deviated tattoo markings were not seen to revert immediately to a vertical configuration. Within 20-40 hours all tattoo marks with one exception were observed to be again in a vertical plane parallel to the long axis of the tooth. The tooth whose tattoo markings failed to alter after the surgical procedure was subjected to additional surgical intervention with special emphasis on deepening the incision below the marginal crest. Within 28 hours after the second surgical procedure, the tattoo marks were observed to have become vertically aligned. Thus the initial failure of the gingival markings to realign themselves was

apparently due to insufficient severing of the fibrous attachment of the tooth to a depth below the alveolar crest.

In no instance was an irreversible defect in the epithelial attachment found as a sequel of the surgical intervention. Sulcular depth as measured with the periodontal probe was recorded to have remained unchanged before the surgical intervention and after healing. Tissue repair was clinically complete in 5-7 days following the surgical intervention. Edwards used an orahesive dressing after surgery. The zone of attached gingiva neither increased nor decreased following the surgical procedure.

During the 3-month post-operative period, when no mechanical retention device was used, negligible rotational relapse occurred even in the case of teeth that were earlier observed to have relapsed.

Edwards concludes that this simple procedure does appear to overcome the problem of rotational relapse and that with so few complications it could easily become part of every orthodontist's retention therapy.

Pinson and Strahan[47] reviewed the effect of the surgicial division of the gingival fibres around rotated teeth as a means of reducing the amount of relapse that would otherwise occur.

In their study they measured the amount of relapse in a group of patients in which the gingival fibres had been sectioned following the alignment of rotated teeth and the result with that of a group in which there was no surgical intervention after tooth alignment.

They point out that after rotation and while the tooth is retained in its new position rearrangement of the stretched fibres of the periodontal ligament gradually takes place. The displacement of the gingival fibres persists for a much longer time.

They furthered their work of 1970 when they found that in a group of four patients who had the gingival fibres sectioned, and then were retained for a period of between 8 and 18 weeks, that they had a mean rotational relapse of 10°.

This study carries this further by having a larger number and group of controls.

They feel that the surgical division of the gingival group of periodontal fibres is a simple procedure causing the patient a minimum of discomfort. They found even using a thin blade that they could not emulate the instruction of Edwards to extend into the periodontal ligament for 3 mm beyond the alveolar crest.

They used a piece of carbon steel razor blade in a Barraqueur blade breaker in preference to a scalpel blade feeling that it can be used in narrower section and is much thinner and flexible enabling the incision to be kept close to the cementum.

They found that under local anaesthesia a vertical incision could be made through the gingival crevice of the aligned tooth down to the level of the alveolar crest. Keeping the blade vertical and close to the cementum this incision is extended around the full periphery of the tooth and is then repeated so ensuring that at all places it extends down to bone thus severing all the gingival fibres.

For both groups of their patients, study models at the beginning and end of active treatment, at the end of retention and at least one year post-retention were prepared. Measurements were made at the beginning as to the amount of rotation and the amount of relapse after at least one year post retention.

By projecting an image of each study model on a copy scanner, enlarged tracings of the dental arches were made. Prior to tracing the study model was clamped onto an adjustable stand so that it could be orientated to a constant plane. The chosen plane was a horizontal one through the incisal edge of a selected incisor and the mesiobuccal cusps of the first molars. Dots on the study models made mesially and distally on the incisal edge of the rotated tooth were transferred to the tracing and then joined by a line which was extended to the margin of the tracing paper.

To determine the amount of rotation and relapse for each tooth, successive tracings were superimposed and the angles between the incisal edge lines were measured. The superimposition was made on the basis of the best fit of the dental arch tracings taking into consideration the tooth movements that had been carried out.

In this study the teeth were examined at follow-up appointments after pericision and the inability to detect the amelocemental junction on pocket probing was interpreted as a successful reattachment of the severed gingival fibres.

The amount of relapse was measured in each group at least one year after the end of retention.

In the pericision group the mean relapse for the group was 8.5° which represented 25.5° of the original rotation.

The mean relapse of the control group was 16° which represented 56.5° of the original rotation.

On the basis of the length of time that the rotated tooth had been retained it was found that there was a greater reduction in those cases where retention was continued beyond 16 weeks but there was no further reduction in the amount of relapse when retention was extended beyond 28 weeks.

They found that even when accompanied by pericision the alignment of rotated teeth is still followed by a measurable amount of relapse which in most cases is not clinically significant.

Walsh[73] reviewed the published work on pericision and its effect on relapse and investigated whether:

a) If the surgical transsection of the supra-crestal periodontal fibres followed by varying periods of retention reduced the amount of rotational relapse
b) If the procedure could be readily adapted to routine clinical practice.

The investigation involved 23 patients with 31 rotated maxillary incisors. Study models before and after active therapy, and at least four months after all retention was discontinued were made. Pericision was carried out immediately the appliances were removed and fixed retainers were fitted without delay. Some teeth were not retained at all and some were retained with removable retainers and as well varying periods of retention were used. All the orthodontic and surgical procedures were carried out by the same operator and the depth of the gingival crevice was measured and compared with the same tooth on the opposite side of the arch as a control.

After the surgical procedure, patients were advised to take a mild analgesic if much discomfort was felt after the anaesthetic had worn off but none found it necessary to do so. Walsh followed Edwards' technique and used a scalpel blade unlike Pinson and Strahan. His technique of measurement and evaluation was as used by Pinson and Strahan.

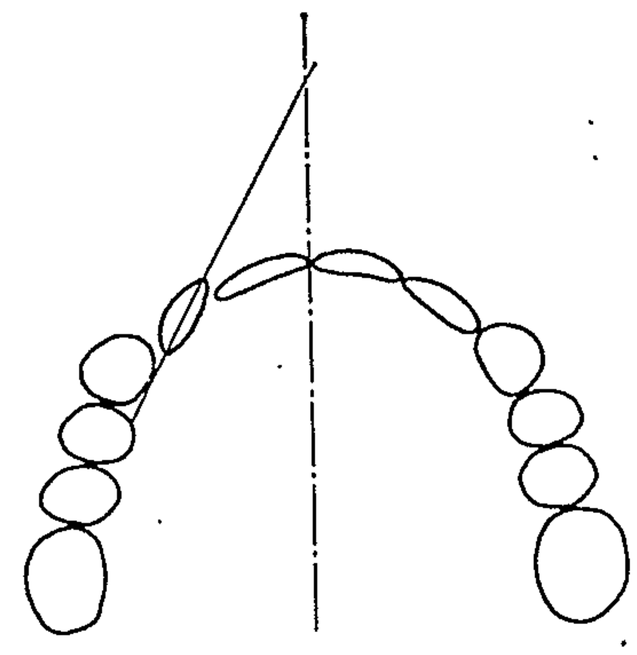

(a) Pre treatment

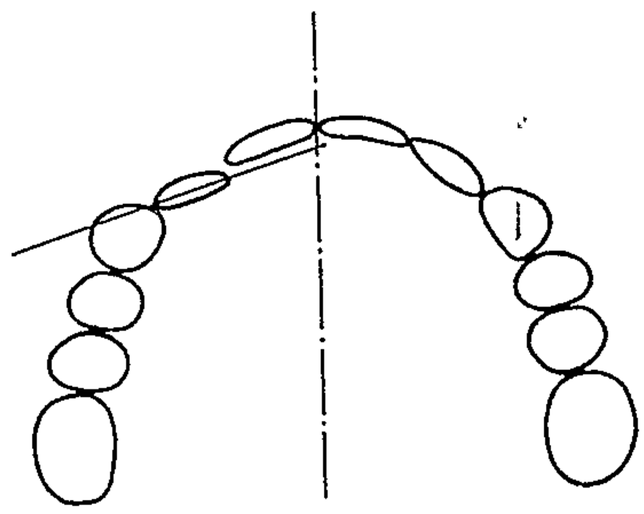

(b) Post rotation

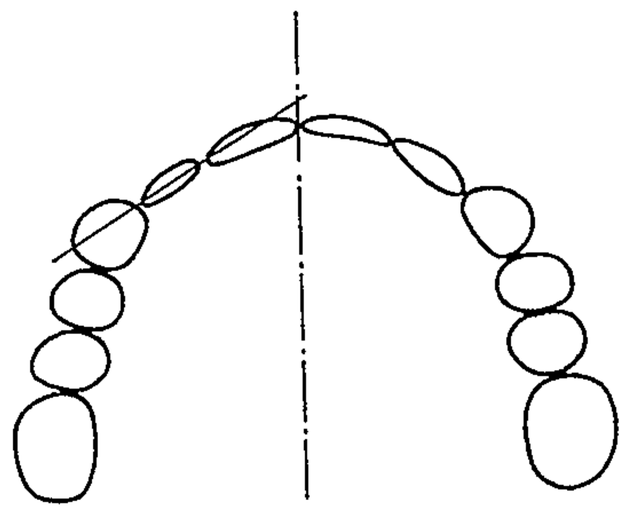

(c) Last observation

Fig. 2. Method used for measuring amount of rotation and relapse.

His study supported Pinson and Strahan's findings that pericision used as an adjunct during retention provides considerably improved results. He found no difference in the depth of the gingival crevice in treated and non-treated teeth and suggests that the procedure which is simple with minimal after-effect has a definite place in clinical practice.

Crum and Andreasen[14] investigated the results of gingival fibre surgery and attempted to quantify and analyse the return in rotation of orthodontically rotated maxillary and mandibular teeth in teeth surgically treated and those used as a control. The post-treatment changes are considered to be due to the distorted gingival tissue under tension and more specifically to either the collagen or the elastic-like oxytalan fibres.

Boase[8] described two phases affecting the orthodontically rotated tooth and causing post-treatment change:

1 The first phase exists primarily during the first four weeks following orthodontic rotation when a significant proportion of relapse is caused by the stretched principal fibres of the periodontal ligament. This greatly diminishes in 4-8 weeks when alveolar bone remodelling provides new attachments for the principal fibres of the periodontal ligament.

2 After 8 weeks post-treatment relapse is caused by the supra-alveolar fibres and this phase of change continues until a position of soft tissue and tooth equilibrium is reached. Since the cemental attachment of the transseptal

fibres remains unchanged this phase is infrequently and probably insignificantly affected by mechanical retention.

Crum and Andreasen utilised patients with bilateral rotations of anterior teeth. One side selected randomly was used as a control and its opposite used as a surgical site. Like Edwards they used a periodontal dressing after the completion of the surgical procedure. They found that both in degree and percentage change that the teeth treated surgically had less post-retention rotation and that an improvement in tooth stability occurred.

As a result of their work, Crum and Andreasen recommend this treatment to reduce the return in rotations of anterior teeth thereby resulting in an improvement in aesthetics and stability of the orthodontic result post-retention. The advantage in maintaining physiologic contact points between the teeth and in maintaining a healthy periodontium may be of equal importance.

Crum and Andreasen recommend the following:-

1 Ideal alignment must be accomplished prior to performing the gingival surgery and all rotations corrected. This is to allow the supracrestal fibres to heal and reestablish themselves in a position free from tension or distortion with the teeth in the desired position.

2 Pericision should be performed when oral hygiene is well controlled and gingival inflammation and hypertrophy are eliminated.

3 An adequate period of retention must be undertaken to allow

adjustment of the principal fibres of the periodontal ligament and to allow remodelling of the alveolar bone.

They feel that this treatment is a simple surgical procedure to perform. The patient is free from pain and discomfort both during and after the surgery and it is readily accepted by the patient when the benefits to be expected are explained.

No noticeable change in the level of the attached gingiva results from the surgical procedure, as determined from clinical observation, nor is the depth of the periodontal sulcus altered.

Relapse, however, in rotated teeth is not solely caused by the distorted supracrestal fibres. Other factors such as jaw growth, labial and lingual musculature, tooth morphology and incisor function may have an influence.

Relapse is reduced by relieving the tensile forces of the supracrestal fibres thus allowing them to reattach in a position free of tension and the retention period allows adjustment of the principal fibres of the periodontal ligament and remineralisation of the alveolar bone.

Kaplar[29] surveyed the clinical experience with supracrestal surgery as an adjunct to lessening rotational relapse. He felt it would be of interest to ascertain to what extent the technique as described by Edwards has been accepted and prescribed clinically by specialist orthodontists. Also it was intended to

identify what, if any, problems have been experienced by those orthodontists who use the procedure.

Kaplan mailed 1000 randomly selected orthodontists in the United States with a second mailing to non-respondents.

The covering letter asked:

"1 In your orthodontic practice have you ever used the technique of surgical division of the supracrestal periodontal fibres in order to minimise rotational relapse of teeth?

2 In approximately what percentage of your patients have you used the procedure?

3 Who performs the procedure?

4 In your opinion has the procedure improved the stability of the treatment result?

5 Have you experienced any problems with the technique or undue sequelae of the procedure?"

The questionnaire resulted in 846 usable returns and of these 208 or 24.6% have used the technique while 638 or 75.4% have not. A number of negative responses indicated that they do intend to use the technique and of these some had only recently started practice and had not treated cases in which such a technique might have been warranted. A few negative responders indicated that they wre reluctant to use the procedure because of the possibility of periodontal damage and because of the fact that no long term results of the treatment are available.

Table II. Have you ever used the technique of surgical division of the supracrestal periodontal fibers?

Region	Yes		No	
	Number of responses	*Per cent*	*Number of responses*	*Per cent*
A. Between regions				
Rocky Mountain	22	10.6	13	2.0
Pacific Coast	70	33.6	104	16.3
Midwestern	30	14.4	55	8.6
Southwestern	19	9.1	74	11.6
Great Lakes	17	8.2	73	11.4
Southern	22	10.6	104	16.3
Middle Atlantic	11	5.3	74	11.6
Northeastern	17	8.2	141	22.2
	208	100.0	638	100.0
$\chi^2 = 86.08$	$P < 0.005$			
B. Within region				
Rocky Mountain	22	62.9	13	37.1
Pacific Coast	70	40.2	104	59.8
Midwestern	30	35.3	55	64.7
Southwestern	19	20.4	74	79.6
Great Lakes	17	18.9	73	81.1
Southern	22	17.5	104	82.5
Middle Atlantic	11	12.9	74	87.1
Northeastern	17	10.8	141	89.2
	208		638	
Per cent of total responses		24.6		75.4

Year	Yes		No	
	Frequency	*Per cent*	*Frequency*	*Per cent*
C. According to the year of completion of orthodontic training				
≤ 34	1	.5	11	1.7
35 – 39	4	1.9	13	2.0
40 – 44	5	2.4	29	4.6
45 – 49	7	3.4	57	8.9
50 – 54	14	6.7	70	11.0
55 – 59	18	8.7	95	15.0
60 – 64	29	13.9	124	19.4
65 – 69	64	30.8	133	20.8
70 – 74	66	31.7	106	16.6
	208	100.0	638	100.0
$\chi^2 = 44.61$	$P < 0.005$			

Table III. In what percentage of your patients have you used the procedure?

Percentage of patients	*Frequency*	*Per cent*
< 1	56	26.9
1 < 3	52	25.1
3 < 5	15	7.2
5 < 10	29	13.9
10 < 20	24	11.5
20 < 50	13	6.3
50 < 70	10	4.8
70 – 100	9	4.3
	208	100.0

Table IV. Who performs the procedure?

Operator	*Frequency*	*Per cent*
1. Orthodontist	72	34.6
2. Periodontist	51	24.5
3. Oral surgeon	18	8.7
4. General dentist	14	6.7
5. Periodontist and general dentist	13	6.3
6. Oral surgeon and general dentist	10	4.8
7. Periodontist, oral surgeon, and general dentist	8	3.8
8. Other combinations	22	10.6
	208	100.0

It was evident that of affirmative responses a majority have not used the procedure to any great extent. More than 50% have used it in less than 3% of cases. Those who use the technique in more than 50% of appropriate cases tend to have more recently completed their specialist orthodontic training.

More than one third carry out the surgery themselves and approximately 25% refer the patient to a periodontist. Some expressed the opinion that the orthodontist should carry out the treatment as they know what is required and why; cost and convenience to the patient were also mentioned.

A majority found the treatment improved stability while Kaplan felt that unsuccessful results were possibly due to ineffective surgical technique.

Of those who use the technique 88.9% have not experienced any problems and a number commented on its simplicity and the freedom from problems.

Of identified problems six reported loss of attachment and gingival recession in some of their cases. Two reported that this occurred on lower incisors and one encountered it on maxillary canines.

Two respondents reported that gingival tissue was removed by oral surgeons to whom they had referred patients and one reported problems with postoperative infection in patients with poor oral

hygiene. (The first would be due to unfamiliarity with the technique as espoused by Edwards while the second would be expected of any gingival interference in such a case.)

Five reported relapse had still occurred.

Four reported excessive postoperative pain. One referred to patient apprehension. Another felt that it would be easier to carry out the procedure under relative analgesia.

One reported that he had observed in adults oedema and slow healing.

Two rep orted difficulty in convincing patients of the necessity for the procedure.

Of the twenty respondents who have had problems with the technique only six performed the surgery themselves.

Tuncay and Killiany[70] demonstrated an acceleration of tooth movement in rats in which gingival fibreotomy had been carried out and they felt that the gingival tissues resisted remodelling and this resistance was a rate limiting factor in orthodontic tooth movement.

Bellardie[6] studied rotational relapse and focussed on the long term effects of pericision. He found that the greater the degree of rotation the greater was the degree of relapse with or without

pericision. Bellardie felt that teeth which had incomplete root development relapsed less after pericision than did a normally developed tooth. This finding would tend to suggest that the apical root section and its fibres have a larger part in control than the work of other authors and in particular the work of Reitan. Bellardie felt that pericision was of little value in controlling rotational relapse as was the use of removable retainers for this purpose.

9 REPROXIMATION

Peck and Peck[44] feel that there are many potential factors in the aetiology of lower anterior crowding and that tooth size variation is one of them. A relationship between crown dimension and the presence or absence of crowding is generally recognised and this study examined and compared crown dimensions, mesiodistal and faciolingual, of the lower incisors. They attempted to answer the question "Do naturally well aligned mandibular incisors possess distinctive dimensional characteristics?"

Their study involved the mandibular incisors of two groups of young white female adults aged 17-27 years from one area. One group of 45 subjects were designed as the group with perfect incisor alignment.

Selection in this group was made upon the following criteria:

1 Complete mandibular dentition.

2 No orthodontic treatment received.

3 Proximal contact present among the mandibular incisors.

4 The absence of overlapping in the mandibular incisors.

5 Minimal rotational deviation from the arch form in the mandibular incisors.

A subjective evaluation administered by both investigators

independently was utilised which proved effective in setting the limit of tooth rotation for the perfectly aligned sample.

The control group was of a similar age group and ethnic background but otherwise were an unselected group of 70.

For each subject in each group the maximum mesiodistal and faciolingual crown diameter was measured directly in the mouth with a .05 mm readout Helios dial caliper whose tips had been specially pointed to facilitate accurate measurement.

The maximum mesiodistal diameter is usually found at or near the incisal edge while the maximum facio-lingual diameter occurred subgingivally in most cases.

Each measurement was made twice to minimise error and the right and left tooth of the same category were pooled in accordance with accepted odontometric methods.

The mean mesiodistal crown diameters for the mandibular central and lateral incisors were smaller in the perfect alignment sample than in the control population sample. In contrast the mean faciolingual crown diameters for the mandibular central and lateral incisors were larger in the perfect alignment sample than in the control population sample.

MANDIBULAR INCISOR CROWN DIMENSIONS OF FEMALES

I. Group with perfect mandibular incisor alignment

Tooth	Dimension	N	Mean	SE_m	SD	CV	Range
I_1	MD	90	5.16	0.03	0.28	5.42	4.37–5.78
I_2	MD	90	5.68	0.03	0.30	5.28	5.00–6.65
I_1	FL	90	5.84	0.04	0.34	5.82	5.10–6.75
I_2	FL	90	6.29	0.04	0.35	5.56	5.46–7.36

II. Control population group

Tooth	Dimension	N	Mean	SE_m	SD	CV	Range
I_1	MD	130	5.39	0.03	0.29	5.38	4.67–6.07
I_2	MD	130	5.91	0.03	0.34	5.75	5.27–7.10
I_1	FL	130	5.72	0.03	0.34	5.94	4.90–6.57
I_2	FL	130	6.11	0.03	0.35	5.73	5.45–7.20

All dimensions expressed in millimeters.

I_1 = mandibular central incisor
I_2 = mandibular lateral incisor
MD = mesiodistal tooth diameter
FL = faciolingual tooth diameter

N = number of teeth
SE_m = standard error of mean
SD = standard deviation
CV = coefficient of variation

Peck and Peck[44]

The findings of this study show that there appears to be overwhelming evidence pointing to the presence of distinctive dimensional characteristics for naturally well aligned mandibular incisors.

Apparently lower incisors conducive to good alignment are significantly reduced mesiodistally and significantly enlarged faciolingually when compared with average population tooth dimensions.

Likewise it is quite reasonable that a similar relationship would exist among the opposite conditions. An enlarged mesiodistal dimension and a reduced faciolingual dimension should be characteristic of crowded mandibular incisors. However tooth size deviation is only one of several conditions which may lead to lower incisor irregularity.

The finding that naturally well aligned mandibular incisors possess mesiodistal and faciolingual dimensions which are significantly different from the population averages carries with it at least one notable implication. It appears that tooth shape, ie., mesiodistal and faciolingual dimensions, is a determining factor in the presence or absence of lower incisor crowding.

Peck and Peck[45] state generally the faciolingual dimensions of teeth are not considered as orthodontists are mainly interested in mesiodistal tooth widths or the summation in relation to the available jaw space.

Tooth size measurements obtained either from the mouth or from plaster casts play an important role in orthodontic diagnosis. Orthodontists use them primarily in the spatial analysis of existing or potential malocclusions.

Each diagnostic analysis utilising tooth size data is designed to serve at least one of three functions:

1 Prediction of unerupted tooth size

2 Assessment of tooth size-arch size compatability in the same arch

3 Assessment of tooth size compatability between the two arches.

It is worth noting that all these diagnostic procedures require only mesiodistal tooth measurements in their construction. No currently used clinical analysis employ or even takes into consideration the faciolingual tooth dimension.

An index incorporating both mesiodistal and faciolingual dimensions would seem ideally suited for orthodontic tooth size analysis at least of the lower incisors.

The index proposed is as below and is confined to the lower incisors:

$$\text{INDEX} = \frac{\text{Mesiodistal Crown Diameter in mm}}{\text{Faciolingual Crown Diameter in mm}} \times 100$$

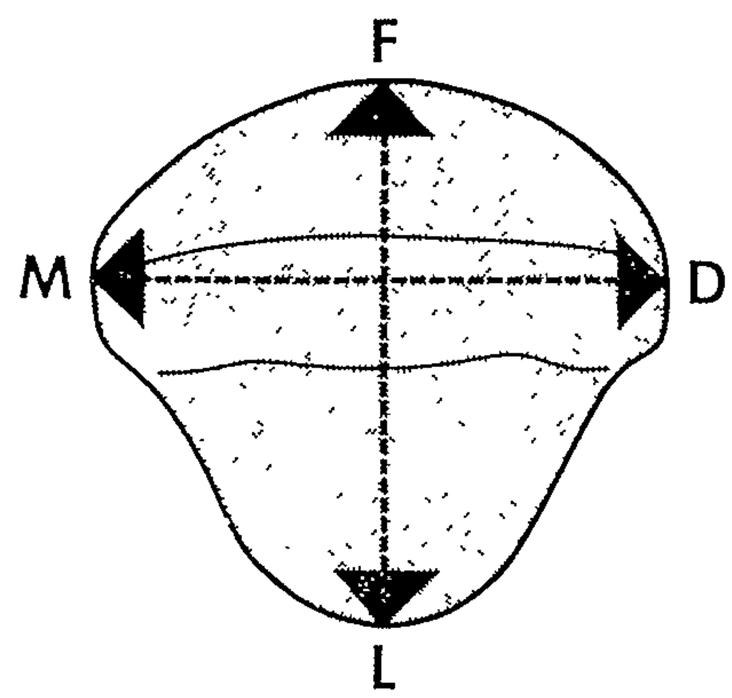

Fig. 1. A mandibular central incisor showing the mesiodistal (MD) and faciolingual (FL) crown diameters. The MD/FL index (MD/FL X 100) is a numerical expression of the crown's shape as seen from the incisal aspect. For the incisor shown, the MD diameter approximately equals the FL diameter, yielding an MD/FL index of 100. If the MD diameter of this tooth were greater than its FL diameter, the index would be greater than 100. Similarly, if the MD diameter were less than the FL diameter, the index would be less than 100.

Peck and Peck[45]

Peck and Peck found that the well-aligned mandibular central and lateral incisors possess remarkably distinctive crown shapes as expressed by this index. Their studies showed that well-aligned mandibular central incisors have an index of 88.4 ± 4.3 while well-aligned mandibular lateral incisors have an index of 90.4 ± 4.8.

From this data they have employed the following clinical guidelines for the maximum desirable index for the lower incisors as:

Mandibular Central Incisors 88.92

Mandibular Lateral Indisors 90.95

Lower incisors within these ranges or below are considered favourably shaped. Above these ranges is considered to have a crown shape which may influence or contribute to the crowding phenomenon.

This may not always be the case and we are dealing with four teeth when mandibular incisor crowding is discussed. Good alignment is often present with various combinations of favourably and unfavourably shaped teeth. For instance, lateral incisors with an index of 97 may be well aligned in a mandibular arch with central incisors that have an index of 86.

An index in excess of 100 for any of the lower incisors represents a severe shape deviation, characteristic of existing or potential tooth irregularity.

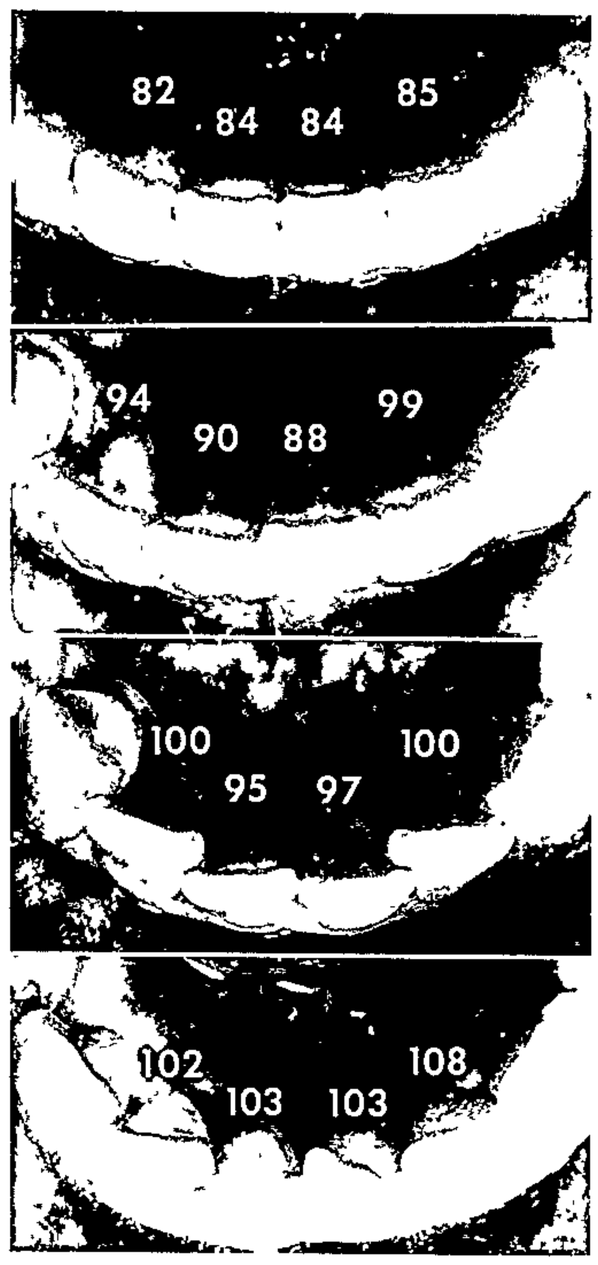

Fig. 3. Variations of mandibular incisor shape Pictured are the lower incisors of four adults, untreated orthodontically The number lingual to each tooth is its MD/FL index value. From studying the photographs, one may readily gather that (1) incisor shape is highly variable, (2) incisor shape and incisor alignment are closely related variables, and (3) low MD/FL index values are characteristic of well-aligned incisors, while high MD/FL index values are characteristic of crowded incisors

Tooth	MD	FL	MD/FL Index	MD/FL Index Standards
$\overline{2}\rceil$	6.0	6.3		90 – 95
$\overline{1}\rceil$	5.4	6.0		88 – 92
$\lceil\overline{1}$	5.1	5.8		88 – 92
$\lceil\overline{2}$	6.1	5.9		90 – 95

Fig. 5. Table for clinically recording MD and FL crown dimensions. These measurements are used in computing the MD/FL index for each lower incisor. Sample measurements (in millimeters) are written in.

Peck and Peck[45]

From their control population sample they have deduced that approximately 15% of the population has an index greater than 100 for one or both mandibular central incisors and about 25% of the population exceed an index of 100 for their mandibular lower incisors.

The average orthodontic practice contains a high concentration of these people.

Patients with indices above these ranges may well benefit from the removal of some mesial and/or distal tooth substance in conjunction with orthodontic therapy.

Peck and Peck use the term reproximation which they define as follows:

> Tooth reproximation is a clinical procedure involving the reduction, anatomic recontouring, and protection of the mesial and/or distal enamel surfaces of a permanent tooth. By protection they mean the use of topical fluoride.

The observed relationship between lower incisor shape and alignment may alter some present concepts of retention. Post treatment retention in orthodontics is a valuable ingredient of successful therapy. Most orthodontists would agree that a provision for retention should be included routinely in orthodontic treatment planning.

As noted previously, the most worrisome area for the orthodontist during the retention phase of treatment is the lower incisor segment of the dentition. Over the years this has led to wide acceptance of "prolonged retention" or "indefinite retention" for these teeth. A canine to canine retainer is often used for this purpose and is frequently left in for some years as an "insurance" against the "indeterminable" causes of incisor relapse.

However in the light of their findings Peck and Peck feel that prolonged retention seems more a postponement of the problem than a solution. They contend that most of the cases presently requiring prolonged retention for the lower incisors probably require instead judicious reproximation because of tooth shape deviations. Post-retention lower incisor crowding is often observed even in the presence of residual extraction space. In these cases of CL1 crowding it is usually clear that there is a generalised excess in the mesiodistal dimension of all teeth. Although the premolar extractions nicely eliminate the arch length discrepancy, the crown shape of the remaining teeth is still exaggerated. The mandibular incisors are often markedly wide and fan-shaped with indices approaching or in excess of 100. Incisors of these proportions are destined to recrowd in time, no matter how perfect the post-treatment occlusion and alignment may appear to be.

Peck and Peck admit that there are many potential factors surrounding the aetiology of lower incisor crowding.

Other dominant variables such as occlusion, habits, supra-alveolar fibres and early deciduous tooth loss are capable of upsetting any alignment stability conferred by tooth morphology alone. Dental crowding may also be a natural aging phenomenon; even the best-shaped, best-aligned incisors may inevitably crowd with age.

Within the framework of clinical orthodontics, however, can any degree of mandibular incisor alignment or stability be achieved without some consideration of crown dimensions, tooth shape and the mesiodistal/faciolingual index?

Reproximation demands that there be some taper to the crown of the tooth otherwise a ledge at the gingival edge will remain if the tooth has mesial and distal sides which are approximately parallel.

Peck and Peck[46] feel that the Bolton anterior index which is constructed by dividing the sum of the mesiodistal widths of the six mandibular anterior teeth by the sum of the mesiodistal widths of the six maxillary incisor teeth and multiplying by 100 (range 74-81%) has a role in clinical orthodontics as an important diagnostic guide in preventing anterior intermaxillary discrepancies from being created by an injudicious incisor extraction or by overzealous reproximation. They report studies which show that this index is otherwise not significantly related to treatment outcome.

The dental models of seventy-seven orthodontically treated patients were evaluated to determine the contribution of lower incisor tooth dimensions to their alignment many years after treatment by Puneky, Sadowsky and Be Gole.[48]

A number of variables have been considered important in contributing to the problem of irregularity of the mandibular incisors which frequently occurs following orthodontic therapy. Among these are conditions unique to orthodontic therapy such as:

1 Excessive intercanine expansion.

2 Length of retention time.

3 Uprighting of incisors after excessive advancement.

4 Effects of supracrestal fibres.

However a number of possible explanations include response to normal growth and development such as:

1 The eruption of third molars.

2 Muscle dysfunctions.

3 Mandibular growth patterns.

4 The continued decrease in mandibular arch length even after eruption of all permanent teeth.

They point out that Boase advocated the use of the Peck and Peck index as a guide to interproximal stripping in conjunction with pericision as a means of enhancing the stability of the lower incisors after orthodontic therapy.

In contrast they state that Kuftinec[33] evaluated orthodontic

cases approximately six months into retention and reported that, while anterior tooth alignment relapsed more than the average amount in cases with unfavourably high Peck and Peck ratios, many cases with favourable ratios relapsed as well. They therefore questioned the importance of interproximal stripping to produce lower incisors of a more ideal form in an attempt to enhance their stability.

The results of the study by Puneky et al. would appear to contradict the work of Peck and Peck although they acknowledge that a different sample methodology and study design were used.

Barrer[3] and Boase[9 10] support the work of Peck and Peck and their contention that the shape of these teeth is important in protecting the integrity of the lower incisor segment after orthodontic therapy.

Boase performed interproximal stripping and pericision in his study to gain minimal relapse without the need of lower retention but Puneky et al. wondered how much was contributed individually by the reproximation and how much was due to the pericision. Boase, of course, also attributed some of his success to the mechanical buttressing provided by the flattened contacts.

Puneky et al.'s study claimed to agree with the conclusion of Kuftinec and did not support the contention that interproximal stripping should be performed in order to produce an ideal incisor shape.

Kuftinec's[32] work showed that sometimes findings were in agreement with Peck and Peck and sometimes were not.

Kuftinec suggested that the Peck and Peck ratios be calculated, in addition to other diagnostic criteria, as they seem to contribute to one's ability to predict the relapse tendency.

He did not recommend that the Peck and Peck idea of reproximation be undertaken where large indices existed. The author felt that other things came into the decision such as:

1 The Bolton anterior tooth correlation index

2 The interincisal relationship.

Kuftinec showed that there was a moderately high correlation between anterior crowding and relapse of the intercanine position. The more correction that took place, the more readily expanded canines would relapse.

Lombardi[36] feels that the experienced orthodontist can move teeth efficiently and achieve a great deal of stability, However, there are cases that are found to be unstable even with prolonged retention. He showed that intercanine width increase was not wholly retained. He found that the coefficient of crowding expressed as:

$$\frac{\text{Amount of tooth material}}{\text{Arch length}} = 1$$

must be as close as possible to this value. There seems to be a direct relationship between the degree of stability and the proximity to this value. If at the beginning of treatment this value is exceeded then tooth reduction should be carried out.

Smith, Davidson and Gipe[64] feel that the work of Peck and Peck leave at least two questions unanswered. Firstly, the Peck and Peck studies were based on crowding in untreated cases. It may be that the reasons for pretreatment crowding are different from the reasons for post-treatment relapse. Secondly, although it is known that greater incisor mesiodistal dimensions can contribute to lower anterior crowding, the biologic significance for the labiolingual measurement is not clear. Peck and Peck did not address the question of whether or not their ratios were more useful than simply measuring mesiodistal widths.

Smith et al. concluded that the use of tooth size measurements as a guide to clinical procedures is an oversimplification of a complex problem. Yet it would seem that figures not expressed as a ratio as suggested by Peck and Peck would be meaningless unless viewed in conjunction with the available arch length between the lower canines.

The study by Gilmore and Little[24] examined 164 cases of completed orthodontic treatment which were at least 10 years post-retention. Measurements were taken from study casts and serial cephalometric films.

Most previous studies have used samples which were untreated orthodontically, or, if treated, the measurements were made from pretreatment casts. This ignores the effects of orthodontic treatment as well as the possiblity that treated patients may represent a unique population. The subjects in previous studies have been very young, and it is possible that well aligned dentitions at this age may be crowded later.

They point out that Peck and Peck (1972) recommend mesio-distal reduction of incisors to place them in the desired range and so prevent future crowding, although no treated cases were narrowed and assessed later. Boase has suggested the combination of reshaping of incisor contact plus fibreotomy to prevent crowding. However, no patient in this study had undergone this treatment.

They found that measurements taken on study casts were quite accurate and that there was less difference between the mean MD/FL ratios of the well-aligned and crowded subgroups in this sample than in the Peck and Peck study. Ratios for central and lateral incisors were significantly different between the well-aligned and crowded cases in the Peck and Peck study, while only lateral incisors showed this trend in the present study. The two studies were similar in mean MD/FL indices, as well as in minimum and maximum values, lower for the well-aligned incisors than for crowded incisors.

The lack of more significant difference between the well-aligned

and crowded subgroups in the present study may possibly be attributable to the more objective assessment of incisor alignment, the older age of the subjects or to the effects of orthodontic treatment and not to differing methodology.

This study found that mandibular incisors that are more labially inclined pretreatment are associated with less long-term crowding.

They conclude that while there is a tendency for incisors with a greater mesiodistal dimension to be associated with crowding, the association is so weak that reduction of the widths of incisors to fit a specific range cannot be expected to produce a stable alignment. Many other factors are involved in the phenomenon of incisor crowding and biologic variability may confound even the most careful study.

10 OBSERVATIONS ON RETENTION

Riedel[54] states that one of the most irritating types of relapse is the tendency for a previously rotated tooth to attempt to rotate to its former position. He further states that over-rotation has not often been carried out, and there is no evidence to indicate that it is successful in preventing return to the former position. It is often possible to prevent anterior teeth from erupting in a rotated position by providing space for them to erupt unimpeded, either by orthodontic appliances or by the early extraction of deciduous teeth. The principle is that if a tooth has never been rotated it would certainly have little tendency to rotate at some later time.

Riedel states there is hope for increased stability of corrected rotations following gingival surgery as espoused by Boase, Edwards and others.

Bone and adjacent tissues must be allowed time to reorganise around newly positioned teeth and some type of fixed or rigid appliance or an appliance only inhibitory in nature and not dependent on the teeth should be used. Histological evidence shows that bone and tissue around teeth which have been moved is altered and considerable time elapses before complete reorganisation occurs.

These suggestions are based on the presumption that mature bone will assume greater stability for the teeth. Present-day orthodontic concepts, however, regard bone as being a plastic substance and consider tooth position to result from an equilibrium of the muscular forces surrounding the teeth. The placement of retention appliances, then, is an admission of inadequate orthodontic correction or of a predetermined decision to place teeth in relatively unstable positions for aesthetic reasons. Whether stability increases with prolonged retention is one of the most interesting points of discussion in regard to retention planning, and is a phase of stability about which we know least.

Riedel asserts that mandibular arch form cannot be altered by appliance therapy, molar width and cuspid width are of such an uncompromising nature as to be established as fixed quantities.

Riedel[55] points to a multiplicity of factors which cause relapse; the musculature, differential growth and the periodontal fibre apparatus. He is unclear as to the part played by erupting third molars but feels no large part is played but that they may cause occlusal change which could provide disruptive influences to periodontal stability.

Riedel feels that there is no documentation linking the length of treatment with post-retention stability and that prolonged treatment would be more likely to show up in root resorption, periodontal destruction, decalcifications and caries.

Riedel tries to achieve normal occlusion and intercuspation and supports the ideas of Lewis regarding intercanine width.

His assessment of overcorrection is that it is a kind of orthodontic safety valve but suggests that it is not the perfect answer for many problems that occur after the correction of malocclusion particularly those related to growth.

In severely crowded mandibular incisor cases he believes that removal of one or more lower incisors is the only logical technique which will enable stability of the lower arch to be attained without continued retention and that extraction of 4x4 leaves in these cases an unstable result.

Riedel believes that interproximal stripping should be used where tooth size discrepancy exists if it will produce a more harmonious tooth size with a limit of about 3 mm maximum for the mandibular anterior teeth if problems of discolouration and sensitivity are to be avoided.

In rotated cases Riedel is surprised that more orthodontists don't avail themselves of Edwards' technique of fibreotomy but has some doubts on stability.

Riedel would recommend a positioner in patients where there has been an anterior open bite in which case the positioner would act as a screen for the tongue and lips. The positioner is only useful for cooperative patients and he recommends against its prolonged use.

Swanson, Riedel and D'Anna[66] conducted a post-retention study on rotated teeth and investigated the incidence of rotational relapse. Swanson states that in recent years substantial attention has been directed to transsection of the supra-alveolar fibres. He points out that most studies are small and deficient in control sample size. In addition the relationship between growth effects, extraction versus non-extraction treatment, and the severity of original malocclusions on post-treatment stability of orthodontically rotated teeth has not attracted sufficient consideration. The purpose of this study by Swanson et al. is to examine these questions in a large sample of orthodontically treated malocclusions not less than ten years out of retention.

Each tooth was categorised before treatment and post-retention according to the amount of angular change that would be required to rotate it into a proper contact relationship with the adjacent teeth. Mild 0°-10°, moderate 10°-20° and severe > 20°. Most pretreatment rotations were mild and at the end of the ten year postretention period the majority of teeth were mildly rotated regardless of the severity of the rotational correction required during orthodontic treatment. They found that as a result of their study certain teeth have a greater tendency to undergo rotational relapse than others. This tendency is unaffected by sex, age at the end of treatment, classification, bicuspid contractions, arch length changes and the growth of jaws but is very likely to be influenced by the amount of rotational correction experienced by the tooth during orthodontic treatment.

Swanson et al. found that the incidence of individual tooth rotation in typical malocclusions demonstrates that cuspids are the most commonly rotated teeth, in both arches, in the pretreatment and the postretention periods. Another finding of clinical significance is that the amount of relapse experienced by an orthodontically rotated tooth is directly proportional to the amount of rotational correction applied during treatment.

Although their mild category accounted for most of the relapse for all teeth in both arches, possibly because most of the sample fell into the mild class, there were a few initially mildly rotated teeth that relapsed into a moderate or severely rotated post-retention category. The authors suspect that the pull of mesial forces within the arch in arches which are not fully corrected or that are overcorrected could cause a further turning of the tooth away from an ideal contact relationship with adjacent teeth.

Reitan was one who favoured the early correction of rotated teeth to enhance stability but this study did not have any support for this theory. This study also failed to find any correlation between rotational changes and growth in arch dimensions as suggested by some authors either during the treatment or post-retention periods.

The authors state that the fibres of the periodontium have been cited in the literature as a cause of relapse of orthodontically rotated teeth. Various methods of enhancing the stability of

these teeth have also been studied and the one perhaps showing the most promise is Edwards' sulcular incision technique.

Most of the subjects in this study were held in retention for over a year and even though some were retained for over three years there was a high incidence of mandibular cuspid relapse. In view of the fact that reorganisation of periodontal fibres is a slow process the conclusion could be reached that surgical intervention and long term retention are the best clinical tools currently available for enhancing the stability of orthodontically rotated teeth.

Andrews[1] in a study of 120 casts with normal occlusion found that there were six keys common to normal occlusion. These were:

1 Molar Relationship

The distal surface of the disto-buccal cusp of the upper first permanent molar made contact and occluded with the mesial surface of the mesiobuccal cusp of the lower second molar. The mesiobuccal cusp of the upper first permanent molar fell within the groove between the mesial and middle cusps of the lower first permanent molar. (The canines and premolars enjoyed a cusp embrasure relationship buccally and a cusp form relationship lingually.)

2 Crown Angulation (Mesio-distal tip)

This refers to the angle of the crown not necessarily that of the whole tooth. The gingival portion was distal to the incisal portion.

3 Crown Inclination (Labio-or Bucco-Lingual)

The inclination of all crowns had a consistent scheme.

a Anterior teeth

Upper and Lower incisor crown inclination was sufficient to resist over-eruption of the anterior teeth and sufficient to allow the proper distal positioning of the contact points of the upper teeth in their relationship to the lower teeth permitting occlusion of the posterior crowns.

b Upper Posterior Teeth - canines to molars

A lingual inclination existed inthe upper posterior crowns. It was constant and similar from canines to the second premolars and slightly more pronounced in the molars.

c Lower Posterior Teeth

The lingual crown inclination in the lower posterior teeth progressively increased from the canines to the second molars.

4 No Rotations

5 No Spaces

6 Occlusal Plane

Generally flat to a slight curve of Spee.

Barrer and Barrish[4] carried out a study to determine if identifiable differences exist between the landmarks read from cephalograms and models of stable and unstable Begg-treated cases, and if this information can be incorporated into treatment procedures to improve stability. Evaluation of the data indicated that relapse could not be specifically classified and divided as to computerise such information on an individual basis.

They concluded from evaluation of their data that Begg mechano-therapy is a positive technique. It can move teeth effectively, treatment response is favourable with good dental, skeletal and soft tissue changes and there are inherent relapse factors. This conclusion breaks no new ground in 1986 but may have in 1975 when published. Cases long out of treatment are

successful and not distinguishable from those treated by other full banded techniques.

They showed that mandibular intercanine width shows a small increase in all their samples during treatment but a comparatively sharp decrease post-retention. The decrease in their sample, indicating this change tendency as a positive relapse factor related to the commonest form of failure, crowding and rotation of mandibular incisors.

Huggins[27] states that retaining appliances, fixed or removable, aim to stabilise teeth against soft tissue and occlusal forces during the period when reorganisation of the periodontal tissue is taking place. Further movement may occur after retention, and this may be referred to as either settling of the occlusion or relapse depending on the degree of movement. When teeth are moved to a position of occlusal and soft tissue balance, retaining appliances can be shown to be unnecessary. Although Huggins feels that this does not apply to rotated teeth. In cases where prolonged retention has been prescribed, the action of the soft tissues and consequent relapse are merely being postponed.

Shields, Little and Chapko[58] conducted a study in which they examined cases at least 10 years post-retention to search for clinically significant predictors and associations of value among the dental cast and cephalometric data with particular emphasis on mandibular anterior alignment.

Cephalometrically they found no great indicators of irregularity but there seemed to be some connection with higher SNA as well as having had the mandibular incisors slightly uprighted during treatment.

Post-retention changes in intercanine width failed to show any clinically significant association with any of the head film variables.

They found that neither axial inclination nor bodily position of the mandibular incisors at any of the time periods studied was associated with post-retention mandibular anterior irregularity.

Fastlicht[21] studied the degree of crowding of the anterior teeth and compared the results of treated and untreated cases to see if treatment produced a lasting change in crowding and attempted to clarify the causes of mandibular crowding.

He found that crowding was more prevalent in the mandibular incisors of untreated than treated cases and that the mesiodistal widths of incisors was directly related to crowding. Both results are as would be expected.

He also found no causal relationship with erupting third molars and the reduction in intercanine width which produced increased crowding. Williams[75] also states that removal of third molars does not eliminate the mesial pressure derived from first and second molars which can cause displacement of lower incisor contacts.

11 SUITABLE RETAINERS

Lee[34] studied the results obtained in a survey of 46 cases in which a bonded lower retainer was used.

He fabricated his retainers using a lingual wire which terminated as eyelets bonded to the lingual surface of the lower canines with the use of a locating matrix to stabilise the retainer whilst it was bonded.

His study covered those cases in which prolonged retention of the lower incisors was considered necessary.

Indications for such retention were:

1 Severe pre-treatment lower incisor crowding or rotation

2 Deliberate alteration in the lower intercanine width

3 Following advancement of the lower incisors during active treatment

4 After non-extraction treatment in mildly crowded cases

5 Following correction of deep overbite.

In six cases the retainer used was from lateral-lateral incisor, in 33 cases the wire was 0.7 mm round wire and in 13 cases 0.015 x 0.036" ribbon arch wire was used.

Lee found no evidence of demineralisation but there was a

calculus and plaque build up on the unattached incisors. He found that the retainer did not prevent axial inclination changes of the lower incisors and recommended the use of rectangular ribbon arch wire for the control of corrected rotations.

Barrer[3] found that 100% of the responding orthodontists in a survey used some form of retention on the mandibular anterior teeth to offset post-treatment irregularity. A surprising 33% reported using lower canine to canine retainers for extended time periods.

Relapse

According to Barrer relapse is closely related to the size and shape of the teeth, the width of the arches, the axial inclinations of the posterior and anterior teeth, the occlusion, the depth of the bite, habits, and the dynamics of natural tooth movement. In a few cases enough of these factors may be involved to indicate full retreatment but more frequently, dental migration and tooth size discrepancies are the prime factors of relapse and these can be dealt with quite successfully using removable appliances suchas Crozat appliances, positioners etc. Each has its own advantages and disadvantages in relation to patient acceptance, complexity of fabrication and ability to perform. The prime factors for success are patient acceptance and good corrective performance. Usually these appliances are used after interproximal stripping to provide space to relocate the teeth.

Interproximal stripping

Barrer advocates stripping of the incisors by a technique which he calls "Keystoning" which involves reshaping of the interproximal surfaces of the teeth to produce broad adjacent plates of contact.

Barrer feels that corrective techniques work best when they simulate nature and that this method produces broad adjacent planes that are antagonistic to the forces of displacement, because of the resistance created by interproximal friction, the inertia of a stable tooth against a nonstable one and the active force produced by the contacting planes of the tooth as they move in opposition to each other. This artificially established complex of resistance to displacement can be used to oppose relapse of the incisors.

Spring Retainer Appliance

This appliance designated an aligner or retainer he recommends for repositioning or maintaining satisfactory positions after keystoning.

The appliance is capable of moving the teeth in the directions necessary to position them in the desired arch form and it can also align the interproximal surfaces to best resist the forces of relapse in accordance with the keystoning procedure.

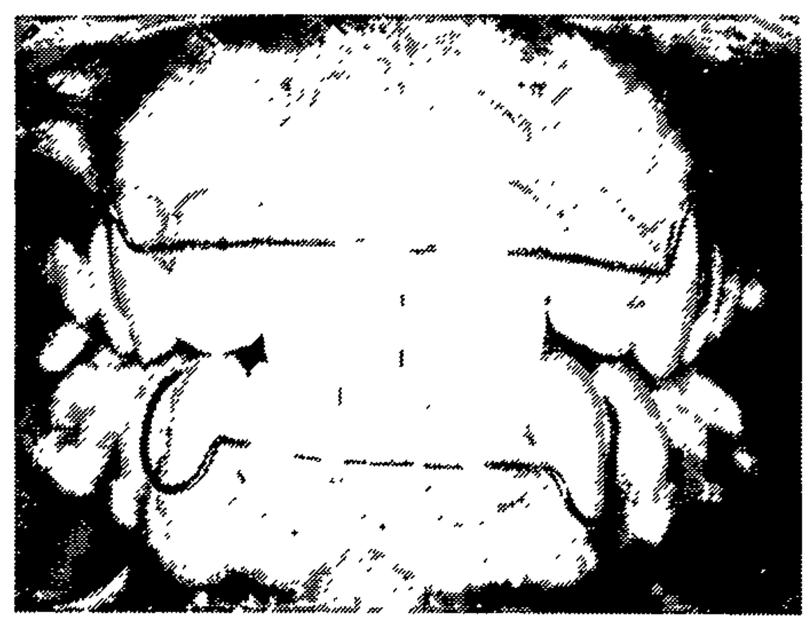

Fig. 2 Standard Spring Aligner.

As a retainer the appliance is constructed straight on to a model or as an aligner on a model which has had the teeth moved to the desired position.

Keystoning Procedure

The keystoning of the teeth is not carried out until the appliance has been constructed. He uses a power handle with double sided cutting strips to reduce both contacting sides together so that a straight cut is made at the predetermined angle required.

Barrer points out that the amount of space which can be gained depends on the outline of the tooth when viewed from the labial. The more the tooth tapers towards the neck the more reduction can be carried out whereas a tooth of nearly parallel dimension enables a much lesser reduction to take place, if any.

Kesling[31] advocated the use of the positioner as a retainer appliance constructed on correctly articulated upper and lower models which have had the teeth set to optimal positions in wax.

This appliance should be placed immediately after the removal of conventional appliances. At this time the teeth are unstable from active treatment and are susceptible to the gentle forces of the tooth positioning appliance.

If the appliance is worn as directed, slight rotations will be

corrected, spaces will be reduced, and arch form and axial positioning of the teeth will approach that of the predetermined pattern in 3-4 weeks. At this time it will be necessary to decide whether the patient is to wear the positioner as a retainer for a few weeks or whether it is a case that is going to require prolonged retention. If it is the latter, a conventional type of retainer should be constructed and coordinated with the positioner.

Chiappone[12] is even more meticulous with correct occlusal relations. He constructs the positioner on an adjustable articulator with models mounted to receive settings for protrusive path, the or: biting condyles and the immediate Bennett side shift.

He advocates the setting of the lower anteriors at 90° to the tangent coming off the hinge axis. This will allow the lower anteriors to be set in a position that will make the forces of occlusion truly distributed down their long axis.

Mischler and Delivanis[41] showed that there is often significant differencein the mandibular intercanine width between the control and the prefinisher models. They state that the intercanine width should be rechecked on the models before the positioner is constructed.

Kesling[30] uses positioners routinely feeling that not only are they the best post-treatment retention appliance but that they

are also the best form of working retainer. Kesling feels that it is possible to obtain more accurate final tooth positions generally and more accurate occlusal relations with tooth positioners than with any other orthodontic appliance now employed. He feels that it is impossible to position teeth with archwires as accurately as can be done by the post-treatment use of a positioner.

Having set the teeth in the desired position Kesling then contours the gum area to normal form after changing the teeth. It would seem that opportunities exist here for conflict between the natural gingival shape and the artificially contoured area.

Kesling states that one must be realistic in the corrections that can be achieved. The positioner can only achieve the perfection possible in the set up when that perfection has been approached in the mouth with conventional treatment.

Cottingham[13] conducted a study presenting the advantages of using a clear plastic positioner made gnathologically to complement the active treatment of malocclusion.

He states that the positioner provides a mechanical means of improving tooth positions following appliance treatment before retention is commenced. In some patients it will attain a high degree of perfection, whereas, in others its usefulness may be limited. It can close band spaces, stimulate circulation in the gingiva and place each tooth where it will be in optimum function with its opponents.

He advocates long term retention and if a retainer is lost or broken then the positioner is worn until a new retainer is made.

Lorentz not only used the positioner as a retainer but as a functional appliance using multiple positioners in conjunction with vestibular screens with an integral bite plane. The treatment was usually initiated in the early mixed dentition.

Joondeph and Riedel[28] state that the positioner in retention planning appears to be particularly beneficial in recovering normal tissue tone and firmness where gingival hyperplasia has occurred during treatment. The advantages of the positioner are that it is clean, is unlikely to be broken, tends to stimulate tissue tone and works constantly for the improvement of tooth position.

Its disadvatnages are its limited time of wear (since the patient can neither eat nor talk with the positioner in place) and the possibility that it may keep the teeth loose by producing intermittent forces contrary to natural muscle balance. The positioner is probably contraindicated in patients who have a tendency to a blocked nasal airway.

It has been said that the positioner creates deep overbites. However, Joondeph and Riedel believe that it tends rather not to prevent the recurrence of a deep overbite, because of the limited

time it is generally used. If a positioner is to be used on what has been a deep overbite malocclusion then it is expedient to construct a maxillary retainer with a bite plane to be used when the patient is unable to wear the positioner. It may even be desirable to place a positioner over a fixed appliance for example a mandibular lingual wire.

Positioner set up and fabrication should be done on an adjustable articulator after a face bow transfer. This will allow the patient to function into the positioner without distraction of the condyles.

McNamara, Kramer and Juenker[38] advocate what they call invisible retainers which are made of heat moulded plastic template with a pressure former. This can be either used at the end of orthodontic treatment or it can be used as a transitional retainer between certain stages of treatment such as prior to an orthopaedic phase of treatment. Tooth repositioning, carried out on the model, should be limited to one tooth per quadrant and the retainer trimmed to just cover the maximum tooth length.

Their treatment sequence is:

1 2-3 months before appliance removal the need for pericision is evaluated and this is carried out if needed. Such a procedure enhances the stability of teeth that have been rotated during alignment.

2 One month before debanding or debonding, the upper and lower archwires are removed and alginate impressions are taken over the fixed appliances. These models are used to fabricate a positioner to be delivered at the time of appliance removal.

3 One week before appliance removal, the upper and lower archwires are removed and the teeth are ligated in serpentine fashion from second premolar to second premolar. This allows setting of the occlusion without opening of any interdental spacing. They instruct the patient to show gum as much as possible during the following week.

4 At the time of appliance removal, the bands or bonds and ligature wires are removed. After prophylaxis the patient is given the positioner and told to wear it full time for 24 hours except during meals, as much as possible for the next five days and then four hours a day plus night time for six weeks.

5 Two weeks later a lateral head film and OPG are taken and the fit of the positioner is checked.

6 Four weeks later the patient is recalled. If the positioner wear has been satisfactory and acceptable occlusal results have been achieved, upper and lower impressions are taken for the fabrication of invisible retainers. Impressions are taken every 6-8 weeks and new invisible retainers are fabricated until ideal tooth position is achieved. Usually only 1-2 sets are required.

7 Long-term retention is carried out with an upper Hawley and lower 3-3 retainers.

Elsasser[19] found that the major advantage of the positioner is its simplicity of design. It was originally intended that the positioner be used for the whole period of retention. It has been found however that it is an elastic appliance and so is an active appliance each time it is slipped over a tooth which does not conform to the positioner's pattern. It is common to use a positioner for six to eight weeks prior to normal retention.

Elsasser reviewed common objections to the positioner. There was a tendency to close the bite after only a few weeks of use but a lot of this criticism is due to faulty positioner construction. IF rotations are not properly corrected in setting up the positioner, they will not be properly corrected in the finished occlusion.

It is common to open the bite by the amount of the desired freeway space on the articulator. Any opening beyond this point puts the muscles supporting the mandible in tension. If the positioner is made so that tension exists then this provides a depressing action and ultimately leads to bite closure.

Patient co-operation is essential.

12 CLINICAL USE OF REPROXIMATION AND PERICISION

Boase[9] states that stability has always been the key objective in orthodontic therapy and that without stability ideal function and/or ideal esthetics may be lost.

He presented material covering a four-nine year period and the purpose of his work was to evaluate the long-term effectiveness of fibreotomy and reproximation on the post-treatment stability of previously crowded arches which had undergone orthodontic treatment. In addition an attempt was made to evaluate the periodontal health of those tissues associated with the fibreotomy and reproximation procedures.

Boase recommends transsection of the displaced supra-alveolar fibres after band removal since then there is usually a decrease in gingival inflammation and subsequently a marked improvement in tissue tone following debanding. In addition surgical access is much easier following removal of appliances.

Following surgery he notes an increased mobility of the treated teeth due to the cutting of the transseptal fibres that splint tooth to tooth. This usually decreases in a 2-4 week period.

Boase states that significant factor in relapse in surgically treated patients is failure to completely correct the rotation

prior to surgery. If normal contact point relationship cannot be produced before surgery, a degree of relapse is inevitable and recommends a slight overcorrection of a rotated tooth beforehand.

Boase feels that reproximation as advocated by Peck and Peck has two main benefits:

1 It provides a broader contact area thus providing greater contact stability.

2 Increases the available space in the mandibular anterior area.

Boase cautions that orthodontists should be aware of the inherent dangers:

1 Reproximation is obviously not a reversible process and should be carried out only after the lower incisors have been completely aligned because it is impossible to be both conservative and precise in establishing broad new contact areas if the teeth are still malposed.

2 Overreduction greater than half an enamel width may lead to caries or hypersensitivity.

3 Excessive reproximation may reduce the amount of transseptal bone between the lower incisors which may predispose the periodontal breakdown.

Timing of Reproximation

Boase feels that this falls into three phases:

1 Most reproximation is done as soon as alignment of the

mandibular incisors has been accomplished. This will allow for good lower incisor shape early in treatment and allow for ideal overbite correction which can be maintained after appliance removal.

2 The second phase of reproximation, if no retention is used, takes place shortly after band or bond removal. If the intercanine width has been expanded or basic arch form significantly altered, a periodic check of the mandibular anterior segment with dental floss will often reveal an increase in contact point pressure. This is observed in both extraction and non-extraction cases. Some degree of reproximation is usually performed serially over a 4-6 month period following band removal; at each maxillary retention visit the contact points of the lower anteriors are evaluated. If some movement appears to be taking place or contact points become extremely tight, reproximation is performed.

3 The timing and degree of third phase reproximation is related to any significant change in lower anterior arch form and to the amount and direction of mandibular growth. Usually little reproximation is necessary after the first six months except sometimes where uprighting of the incisors, seen in the terminal phase of growth,is producing secondary crowding.

Boase[10] reviewed 40 patients with crowded mandibular arches all of which had had fibreotomy and reproximation to varying degrees.

He found on investigation that the mandibular arches which had never been retained and observed over 4-9 years after treatment showed dramatic evidence of stability in the mandibular anterior segment even though cephalometric studies showed that 20 of the 40 cases had recorded further growth.

Severe rotations that were present originally had not relapsed during this period in contrast to Riedel's study where fibreotomy was not carried out.

Most pretreatment incisors had extremely poor crown shapes based on the standards of Peck and Peck but after reproximation were brought into a more suitable range.

Boase felt that the broad contact and the space generated enabled treatment to be carried out in the confines of the original arch form and that the broad contacts provide a mechanical buttress resisting the forces generated during the terminal phases of mandibular growth.

Since no retention was used the lower incisor segment was able to move and post treatment changes did occur, but the incisors tended to move as a unit rather than as individual teeth.

Boase felt that while maintenance of the original intercanine width appeared to be a useful guide in treatment planning, maintenance of original arch form was the rule especially in the mandibular anterior segment.

His study revealed no periodontal problems. The tissues had normal colour, good morphology and stippling.

There was no evidence of generalised gingival recession on any of the mandibular incisors and the recession that did occur in some canine areas was always located on labial sites associated with thin cortical bone and little attached gingiva. Fibreotomy was never performed in this study on the mid portion of the labial gingiva of any lower incisor or canine.

Radiographic examination of the interproximal bone before and after treatment and on review showed no bone loss.

Boase felt that the practice of not using any lower retention played a critical role in the stabilisation of the lower anterior segment. Lower retention eliminates the need for reproximation since it postpones natural arch length loss, prevents any compensatory lower incisor movement and allows for a build up of forces during the retention period. The decision not to use lower retention will allow for natural arch length loss which occurs gradually and can be dealt with immediately. Boase claims that many authors state that fixed retention should be continued until all growth has been completed to prevent secondary crowding of the lower incisors; this implies that growth is the major factor in post-treatment crowding. It should be noted that of the 19 cases which required most reproximation nine were nongrowers; obviously the denture adjustment which was made possible without retention was not dictated by mandibular growth.

Boase concludes that we should not look on fibreotomy and reproximation as a panacea for all our treatment problems but rather as an embellishment of sound treatment principles and good orthodontic therapy.

Wallman[72] states that the work of Peck and Peck indicates that a significant factor in the resistance of rotation of lower incisor teeth, is the relationship between the mesiodistal and faciolingual dimensions of each tooth.

The object of the reproximation technique is to reduce the mesiodistal dimensions of potentially unstable teeth, to allow the MD/FL index to approach the standards of Peck and Peck. Periapical radiographs are used to indicate the thickness of interproximal enamel.

During the early stages of fixed appliance treatment, the lower incisors are separated for 7-10 days with .016" soft brass wire. A Dome stripper is used first to increase the interproximal spacing and so reduce abrasive disc binding. The majority of the reduction and shaping of interproximal enamel is carried out with a 3/4" Horico coarse abrasive disc, in a disc guard, and with a loosend drive from the dental engine. The enamel is polished using a 3/4" fine cuttle disc and acidulated phosphate fluoride solution is applied topically for 4 minutes.

If the brass wire separation has been insufficient a thin Horico Superdraflex No.539/200 disc will increase the initial spacing.

As a result of reproximation and pericision in early retention, Wallman finds that he no longer finds it necessary to use fixed lower canine to canine retention.

Vickers[71] reviewed the effect of the roughness produced as a result of interproximal stripping and quotes Waerhaug in a survey of enamel surfaces roughened with a diamond bur in which he found that the roughened enamel surface collected more plaque than smooth control surfaces. It was also noted that when regular tooth brushing was carried out on the teeth no apparent difference was noted in the gingival condition of both groups. This confirmed that the roughness itself does not cause irritation and inflammation but that it is the increased plaque accumulation which causes the problem.

Vickers states that the importance of leaving the enamel surface as smooth as is practically possible after proximal stripping cannot be over emphasised. If not polished, a rough enamel surface will increase the amount and rate of plaque accumulation, make it more difficult to remove the plaque, decrease the resistance of the surface to decalcification, be more likely to collect stain and discolouration and be less natural in appearance.

Zachrisson in an unpublished study in 1978 has shown, by electron microscopy, the value of smoothing the enamel surface with polishing strips, after carrying out proximal stripping procedures with flexible diamond discs and steel abrasive strips.

Vickers experiments on surface roughness found that polishing of the stripped surface with 3M "Soflex" discs of medium and fine grit produced a very smooth surface. These were more likely to produce a smoother surface than the use of polishing strips.

Vickers also points out that various teeth in the mouth experience different rates of caries susceptibility. The lower incisors which are continually being washed by the saliva from the submandibular gland are less susceptible to decalcification, and so, carrying out proximal stripping on these teeth is less likely to lead to decalcification than carrying out proximal stripping on posterior teeth.

Williams[75] has, over a period of twenty-one years, studied stability in the lower arch and observed what had to be achieved to create post-treatment stability in the lower incisors. He found six treatment keys which emerged as being essential if lower retention is to be eliminated.

Williams' six treatment keys were:-

1 The incisal edge of the lower incisor should be placed on the A-P line or 1 mm in front of it. This also creates an optimum balance in the lower third of the face. The angulation of the lower incisors has not proven to be relevant to their stability. An angulation of 90° to the mandibular plane may be aesthetically appropriate for those having optimal Northern European skeletal configuration but perhaps not for other ethnic groupings.

If the lower incisor is advanced too far beyond the A-P line, relapse and crowding will occur. Similarly lower incisors which have been overly proclined can only be maintained in such an untenable position with a fixed retainer. When the retainer is removed, the incisors will move lingually and become crowded.

2 The lower incisor apices should be spread distally to the crowns more than is generally considered appropriate and the apices of the lateral incisors more so than the central incisors. Williams states that the Begg system is geared to achieve the necessary progressive spreading but none of the current straightwire systems provides adequate lower incisor slot angulation to bring about sufficient progressive spreading of the lower incisor apices. If the apices are left convergent or parallel the crowns will tend to bunch up.

3 The apex of the lower canine should be positioned distal to the crown using the occlusal plane as the positioning guide. This position reduces the tendency of the cuspid crown to tip forward into the incisor area thus causing the incisors to crowd up even if their roots are spread and the incisal edge on or +1 mm to the AP line. This is easily accomplished by both Begg and straightwire systems.

4 All four lower incisor apices must be in the same labiolingual plane. Williams feels that this is difficult to control when round wires are used during the spreading process because these forfeit labiolingual control. An edgewise sectional auxiliary is useful in conjunction with

the main round wire and uprighting springs and is easily controlled with rectangular wire.

5 The lower canine root apex should be positioned slightly buccal to the crown apex. If the other angulation occurs the crown can easily be moved by the forces of occlusion so that it moves toward the space reserved for the lower incisors. Prolonged retention will not prevent this, once the retainer is removed, relapse will occur. Until the advent of straightwire brackets with built-in torque there was a tendency for the old edgewise bracket to move the lower cuspid apex lingually when rectangular wire was used. With a simple auxilliary, Begg treatment can easily torque the lower canine apex buccally.

6 Reproximation to produce a buttressing effect. Lower incisors that have sustained no proximal wear have small round contact points which are accentuated if the apices have been spread for stability. Consequently the slightest amount of continuous mesial pressure can cause various degrees of collapse in the lower incisor segment.

SUMMARY AND CONCLUSIONS

The problem of the rotated lower incisor and its treatment have been reviewed.

Edwards has suggested a surgical technique for the sectioning of the supracrestal fibres which, as Rietan has pointed out, are so slow in returning to their unstressed state. These tissues remained stressed long after the other investing dento-alveolar tissues have stabilised themselves so as to be relatively stress free.

The surgery involved is relatively simple and can easily be carried out. It has been shown that no increase in the depth of the gingival crevice occurs and that there is no damage to periodontal health.

Peck and Peck advanced a theory of reproximation with a very easily calculated ratio which would indicate whether the tooth would be stable or not when treated. This would appear to be the answer to the orthodontists' prayers. However, doubt has been cast upon their work and just how effective reproximation is.

Boase found in his studies that the technique of fibreotomy used in conjunction with reproximation enabled him to dispense with the need for lower canine-canine retention. This work has been

supported by Waelman and a system of six treatment keys to produce this result has been put forward by Williams.

One advantage of the reproximation technique which has been commented on by Boase is the buttressing effect produced by the flat interproximal contacts which have the same effect of stabilisation as the stones of a Norman arch.

Barrer advocates cutting the tooth at a different angle again but it would be difficult to understand how his keystoning effect would not in fact produce the opposite effect, that is to facilitate one tooth slipping over the other due to the tendency to mesial migration. In other words encouraging arch collapse.

Various types of retaining devices have been examined. Some used have been overtaken by time and in this regard the modern day canine-canine retainer with mesh retaining pads for bonding onto the canines has superceded the retainer with the soldered band attachment which needed some degree of parallelism of the canines to be successfully seated. Also retention would be greater with the mesh pads than with the bent eyelets used by Lee.

Mention should be made of the spring aligner/retainer recommended by Barrer. While it is difficult to go along with his technique of keystoning, this appliance is certainly very effective as either a corrective appliance or as a retainer.

Riedel points out some of the problems associated with the use of

the tooth positioner. It requires a high degree of cooperation from the patient for its successful use and is useful only if the needs of retention can be satisfied in a short period. They have the same drawbacks as dentures or Hawley retainers on the oral mucosa if they are used for long periods and absolutely strict oral hygiene procedures are not carried out.

The need for preserving the intercanine width as espoused by Lewis is generally accepted and it is interesting to note that Riedel feels that extraction of one or more lower incisors is often the technique of choice in cases of severe rotational crowding in the anterior segment. In a talk he presented in Sydney some years ago concerning long term relapse in the anterior region, he advocated this as a form of simple retreatment.

The tooth support system has been examined with particular reference to its association with rotation and a simple technique suggested as an aid to successfully achieving a stable long term result. It would appear from the available literature that this simple procedure is a combination of pericision and the buttressing effect produced by reproximation. As well as the precise positioning of individual incisor teeth within their mandibular alveolar process, as advocated particularly by Williams, are the remaining factors if stabilisation ofer which the orthodontist should have effective control. The techniques advocated by Boase, Wallman and by Williams seem to have more hope than the technique put forward by McNamara et al.

BIBLIOGRAPHY

1 Andrews, L.F., 1972 — The six keys to normal occlusion. A.J.O., 62:296-309.

2 Atherton, J.D., 1970 — The gingival response to orthodontic tooth movement. A.J.O., 58:179-186.

3 Barrer, H.G., 1975 — Protecting the integrity of mandibular incisor position through keystoning procedure and spring retainer appliance. J.C.O., 9:486-494.

4 Barrer, H.G., and Barrish, D.I., 1975 — An evaluation of stability post Begg therapy. Trans 3rd Int. Orth. Congress. Ed. J.T. Cook: Crosby, Lockwood and Staples, London.

5 Begg, P.R. and Kesling, P.C., 1977 — In Begg orthodontic theory and technique. W.B. Saunders, pp.237 & 651.

6 Bellardi, H., 1985 — Effect of pericision on the relapse potential of rotated upper incisors. B.J.O., 12:49.

7 Berger, H., 1959 — The lower incisors in theory and practice. Angle Orthodontist, 29:133-148.

8 Boase, L.R., 1969 — Increased stability of orthodontically rotated teeth following gingivectomy in "Macaca Nemestrina". A.J.O., 56:273-290.

9 Boase, L.R., 1980 — Fibreotomy and reproximation without lower retention nine years in retrospect. Part I. Angle Orthodontist, 50:89-97.

10 Boase, L.R., 1980 Fibreotomy and reproximation without lower retention. Nine years in retrospect. Part II. Angle Orthodontist, 50:169-178.

11 Carneiro J. and De Morales, B.F., 1965 Radioautographic visualisation of collagen metabolism in the periodontal tissues of the mouse. Arch. Oral Biology, 10:823-845.

12 Chiappone, R.C., 1980 Constructing the gnathologic set up and positioner. J.C.O., 14:121-133.

13 Cottingham, L.L., 1969 Gnathological clear plastic positioner. A.J.O., 55:25-31.

14 Crum, R.E. and Andreasen, G.F., 1974 The effect of gingival fibre surgery on the retention of rotated teeth. A.J.O., 65:626-637.

15 Crumley, P.J., 1964 Collagen formation in the normal and stressed periodontium. Periodontics 2:53-61.

16 Edwards, J.G., 1968 A study of the periodontium during orthodontic rotation of teeth. A.J.O., 54:441-461.

17 Edwards, J.G., 1971 The prevention of relapse in extraction cases. A.J.O., 60:128-141.

18 Edwards, J.G., 1970 A surgical procedure to eliminate rotational relapse. A.J.O., 57:35-46.

19 Elsasser, W.A., 1950 Some observations on the history and uses of the Kesling positioner. A.J.O., 36:368-374.

20 Erikson, B.E., Kaplan, H., and Ausenberg, M.S. 1945 Orthodontics and transseptal fibres. Am. J. of Orth. & Oral Surgery, 31:1-20.

21 Fastlicht, J., 1970 Crowding of mandibular incisors. A.J.O., 58:156-163.

22 Fullmer, H.M. & Lillie R.D., 1958 The oxytalan fibre: a previously undescribed connective tissue fibre. J. Histochem & Cytochem, 6:398

23 Fullmer, H.M., Sheetz, J.H. & Narkates, A.J. 1974 — Oxytalan connective tissue fibres - a review. J. Oral Path., 3:291-316.

24 Gilmore C.A. & Little, R.M., 1984 — Mandibular incisor dimensions and crowding. A.J.O., 86:493-502.

25 Goggins, J.F., 1966 — The distribution of oxytalan connective tissue fibres in periodontal ligaments of deciduous teeth. Periodontics, 4:182-186.

26 Hallett, G.M., 1956 — Immediate torsion. A preliminary report of twenty three cases. D. Practitioner, 7:108-110.

27 Huggins, D.G., 1963 — Functional retention. Trans. Br. Soc. Study. Orth., 77-80.

28 Joondeph, D.R. & Riedel R.A., 1985 — Retention. In Graber and Swain, Orthodontics - Current principles and techniques. C.V. Mosby, 857-898.

29 Kaplan, R.G., 1976 Clinical experiences with circumferential supra crestal fiberotomy. A.J.O., 70:146-153.

30 Kesling, P.C., 1977 In Begg Orthodontic Theory and Technique. W.B. Saunders, 654-656.

31 Kesling, H.D., 1946 Co-ordinating the predetermined pattern and tooth positioner with conventional therapy. A.J.O., 32:285-293.

32 Koumas, H. and Mathews, J.L., 1969 Effects of pressure on the formation of collagen in the periodontal ligament. A.J.O., 56:604-612.

33 Kuftinec, M.M., 1975 Effect of edgewise treatment and retention on mandibular incisors. A.J.O., 68:316-322.

34 Lee, R.T., 1981 The lower incisor bonded retainer in clinical practice - a three year study. B.J.O., 8:15-18.

35 Lewis, P.D., 1973 Arch width, canine position and mandibular retention. A.J.O., 63:481-493.

36 Lombardi, A.R., 1972 Mandibular incisor crowding in completed cases. A.J.O., 61:374-383.

37 Lorentz, H., 1973 Treatment with preformed positioners. Trans-Euro. Orth. Soc., 207-213.

38 McNamara, J.A., Kramer, K.L. and Juenker, J.P., 1985 Invisible retainers. J.C.O., 19:570-578.

39 Macphee T. & Cowley, G. 1969 Essentials of Periodontology and Periodontics. Blackwell Scientific Publications, pp.4-5.

40 Massler, M. & Frankel, J.M., 1951 Prevalence of malocclusion in children aged 14-18 years. A.J.O., 37:751-768.

41 Mischler W.A. & Delivanis, H.P., 1984 Comparison study between three tooth positioners. A.J.O., 85:154-158

42 Orban, B.J., 1980 Oral Histology and Embryology.
C.V. Mosby: 180-202.

43 Parker, G.R., 1972 Transseptal fibres and relapse following early extraction of teeth: a histological study.
A.J.O., 61:331-344.

44 Peck, S. & Peck, H. 1972 Crown dimensions and mandibular incisor alignment.
Angle Orthodontist, 42:148-153.

45 Peck, H. & Peck, S. 1972 An index for assessing tooth shape deviations as applied to the mandibular incisors.
A.J.O., 61:384-401.

46 Peck, S. & Peck, H. 1975 Orthodontic aspects of dental anthropology.
Angle Orthodontist, 45:95-102.

47 Pinson, R.R. & Strahan, J.D., 1973 The effect on the relapse of orthodontically rotated teeth of surgical division of the gingival fibres.
B.J.O., 1:87-91.

48 Puneky, P.J., Sadowsky, C. & Be Gole E.A., 1984 — Tooth morphology and lower incisor alignment many years after orthodontic therapy. A.J.O., 86:299-305.

49 Rannie, I., 1963 — Observations on the oxytalan fibre of the periodontal membrane. Trans. Eur. Orth. Soc., 127-137.

50 Rietan, K., 1958 — Experiments on rotation of teeth and their subsequent retention. Trans. Eur. Orth. Soc., 34:124-140.

51 Reitan, K., 1959 — Tissue rearrangement during retention of orthodontically rotated teeth. Angle Orthodontist, 29:105-113.

52 Reitan, K., 1967 — Clinical and histologic observations on tooth movement during and after orthodontic treatment. A.J.O., 58:721-741.

53 Reitan, K., 1985 — Biomechanical Principles and Reactions. In Graber & Swain, Orthodontics - Current Principles and Techniques. C.V. Mosby, 101-192.

54 Riedel, R.A., 1969 Retention.
In Current Orthodontic Concepts and Techniques. Vol.2.
T.M. Graber (ed.), W.B. Saunders, 875-917.

55 Riedel, R.A., 1976 J.C.O. Interviews Dr Richard A. Riedel on retention and relapse.
J.C.O., 10:454-472.

56 Ronnerman, A. & Larson, E., 1981 Overjet, overbite, intercanine distance and root resorption in orthodontically treated patients.
Swed. Dent. J., 5:21-27.

57 Delvig, K.A. The fine structure of human cementum.
31-Acta Odont. Scand. 23:423-441.

58 Shields, T.E., Little, R.M. & Chapko, M.K., 1985 Stability and relapse of mandibular anterior alignment: a cephalometric appraisal of first premolar extraction cases treated by traditional edgewise orthodontics.
A.J.O., 87:27-38.

59 Sicher, H., 1942 Tooth eruption. The axial movement of continuously growing teeth.
J. Dent. Research, 21:201-210.

60 Sicher, H. & De Brul, E.L., 1970 — Oral Anatomy. C.V. Mosby, 208-209 & 255.

61 Sims, M.R., 1976 — Reconstitution of the human oxytalan system during orthodontic tooth movement. A.J.O., 1:38-58.

62 Skillen, W.G., 1940 — Tissue changes as the result of artificial stimuli and injury. J.A.D.A., 27:1554-1563.

63 Skogsborg, C., 1932 — Septotomy in connection with orthodontic treatment. Int. J. Orth., 18:1044-1057.

64 Smith, R.J., Davidson, M. & Gipe, D.P., 1982 — Incisor shape and incisor crowding - a reevaluation of the Peck and Peck ratio. A.J.O., 82:231-235.

65 Stallard, R.E., 1963 — The utilisation of H^3proline by the connective elements of the periodontium. Periodontics, 1:185-188.

66 Swanson, W.D., Riedel, R.A. & D'Anna, J.A., 1975 — Post-retention study: incidence and stability of rotated teeth in humans. Angle Orthodontist, 45:146-153.

67 Ten Cate, A.R., Deporter, D.A. & Freeman, E., 1976 — The role of the fibroblasts in the remodelling of periodontal ligament during physiologic tooth movement. A.J.O., 69:155-168.

68 Ten Cate, A.R. & Deporter, D.A., 1975 — The degrative role of the fibroblast in the remodelling and turnover of collagen in soft connective tissue. Anat. Rec., 182:1-14.

69 Thompson, H.E., Myers, H.I., Waterman, H.M. & Flanagan, V.D., 1958 — Preliminary macroscopic observations concerning the potentiality of supra-alveolar collagenous fibres in orthodontics. A.J.O., 44:485-497.

70 Tuncay, O.C. & Killiany, D.M., 1986 — Effect of gingival fibreotomy on tooth movement. A.J.O., 89:212-215.

71 Vickers, D., 1982 — Proximal stripping and enamel surface roughness. M.D.Sc. Thesis, Sydney University.

72 Wallman, R.H., 1980 Using the Peck and Peck analysis in reproximating lower incisor teeth. Aust. Orth. J., 6:198.

73 Walsh, E.A., 1975 Pericision: an aid to the reduction of rotational relapse in clinical practice? An assessment. B.J.O., 2:135-140.

74 Wheeler, R.O., 1965 A textbook of Dental Anatomy and Physiology. W.B. Saunders 145-155, 306-307.

75 Williams, R., 1985 Eliminating lower retention. J.C.O., 19:342-349.

76 Wiser, G.M., 1966 Resection of the supra-alveolar fibres and retention of orthodontically rotated teeth. A.J.O., 52:855-856.

77 Zwarych, P.D. & Quigley, M.B., 1965 The intermediate plexus of the periodontal ligament; history and further observations. J. Dent. Res., 44:381-391.