

CHAPTER 6.THE STRUCTURE OF THE TEMPOROMANDIBULAR MENISCUS AT 72 YEARS
OF AGE.SPECIMEN No. 5.

The specimen consists of a temporomandibular meniscus, perichondrium of the condyle and portion of the spheno-meniscus muscle inserting into the pes menisci. The insertion of lateral pterygoid into the periosteum of the pterygo-fiducias of the condyle was not procured. Therefore the pterygo-condylar area cannot be described. The meniscus was removed from a female cadaver aged 72 years. Cause of death was carcinoma. Description will follow pattern of preceding chapters.

Lateral third of the Meniscus. (fig. 202.)

No inserting fibres of the spheno-meniscus muscle or the lateral pterygoid muscle can be observed.

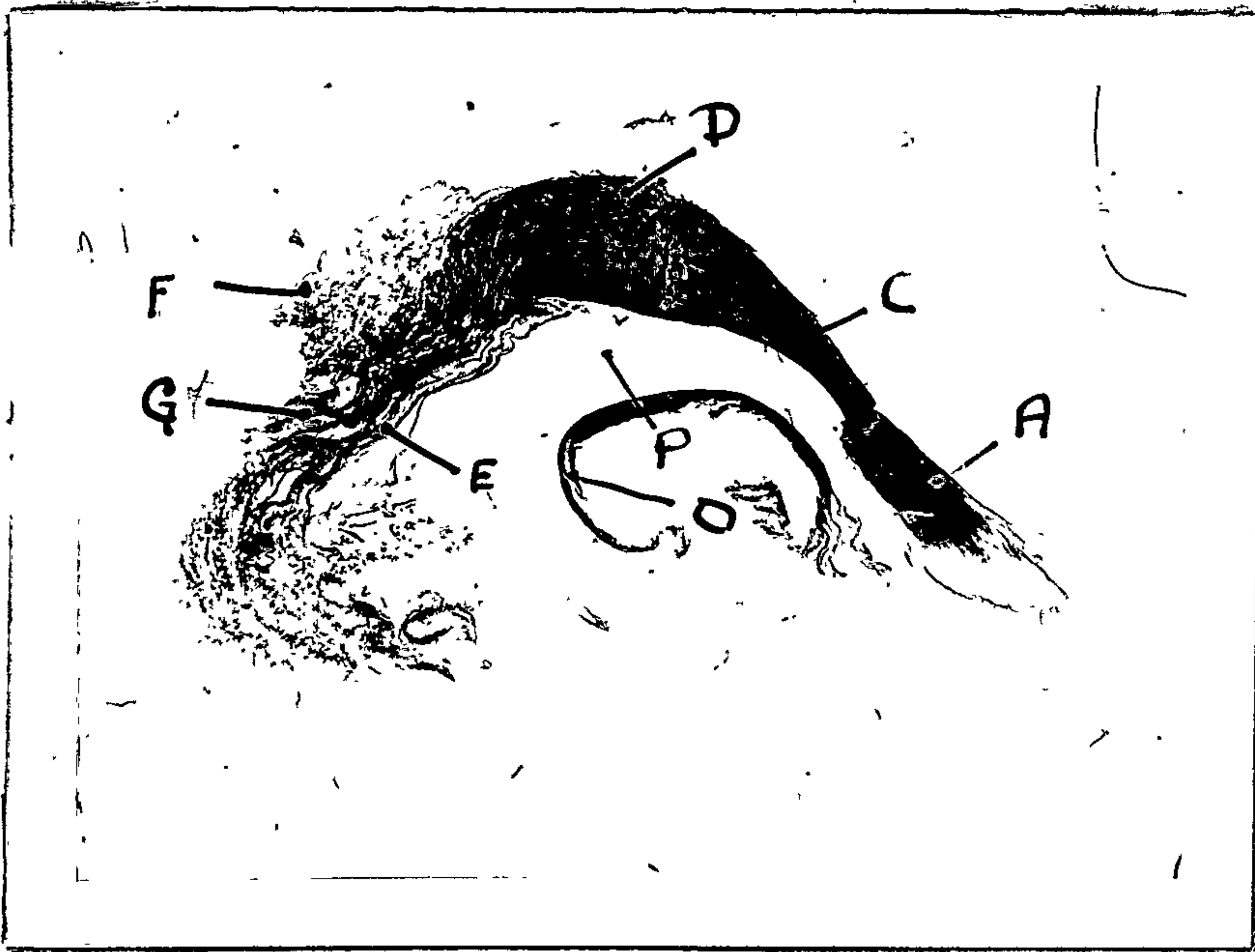


Fig. 202.

Specimen no. 5 - 72 years.

Sagittal section X 5 lateral third temporomandibular meniscus.

- A. Pes Menisci.
- B. Pars Gracilis Menisci.
- C. Pars Posterior Menisci.
- D. Inferior Stratum.
- E. Superior stratum.
- F. Bilaminar zone.
- G. Perichondrium.
- P. Inferior Joint Cavity.

Perichondrium of the Head of the Condyle. (cf. fig. 202.)

The superficial layer of the perichondrium is relatively acellular and the surface cells consist of flattened chondrocytes, which are widely spaced. Indeed the overall appearance of the perichondrium is marked by its appearance of acellularity and such cells which are present are chondrocytes. The chondrocytes are usually grouped in rows, and are for the most part oval, although in the deepest layer flattened chondrocytes can be observed.

The collagenous fibres of the perichondrium are unmasked and they appear to run obliquely towards the surface. There is no definite line of demarcation of the perichondrium from the articular cartilage of the head of the condyle.

A few elastic fibres can be demonstrated in the perichondrium and they appear to be orientated at random. Perhaps the division between perichondrium and articular cartilage can be discerned by a relatively acellular layer in which can be seen groups of flattened chondrocytes. Beneath this layer there is again a relatively acellular layer in which can be seen fairly large oval chondrocytes.

Beneath this layer is a zone of hypertrophic and degenerative chondrocytes between which there is a calcified cartilage matrix. The hyaline cartilage is unmasked and it exposes collagenous fibres which appear to be orientated in the main to the curvature of the head of the condyle.

At its periphery the perichondrium is continuous on one hand with the synovial membrane of the anterior and inferior joint cavities and on the other with the periosteum of the non articular part of the condyle. (figs. 203, 204, 205, 206.)



Fig. 203.

Perichondrium. Head of the condyle. (X 270 of. fig. 202.)




Fig. 204.

Superficial layer of the perichondrium. Head of the condyle.
(X 900 of. fig. 202.) Note: Chondrocytic nature of cells.




Fig. 205.

Intermediate layer of the perichondrium. Head of the condyle. (X 900 cf. fig. 202.)

.....

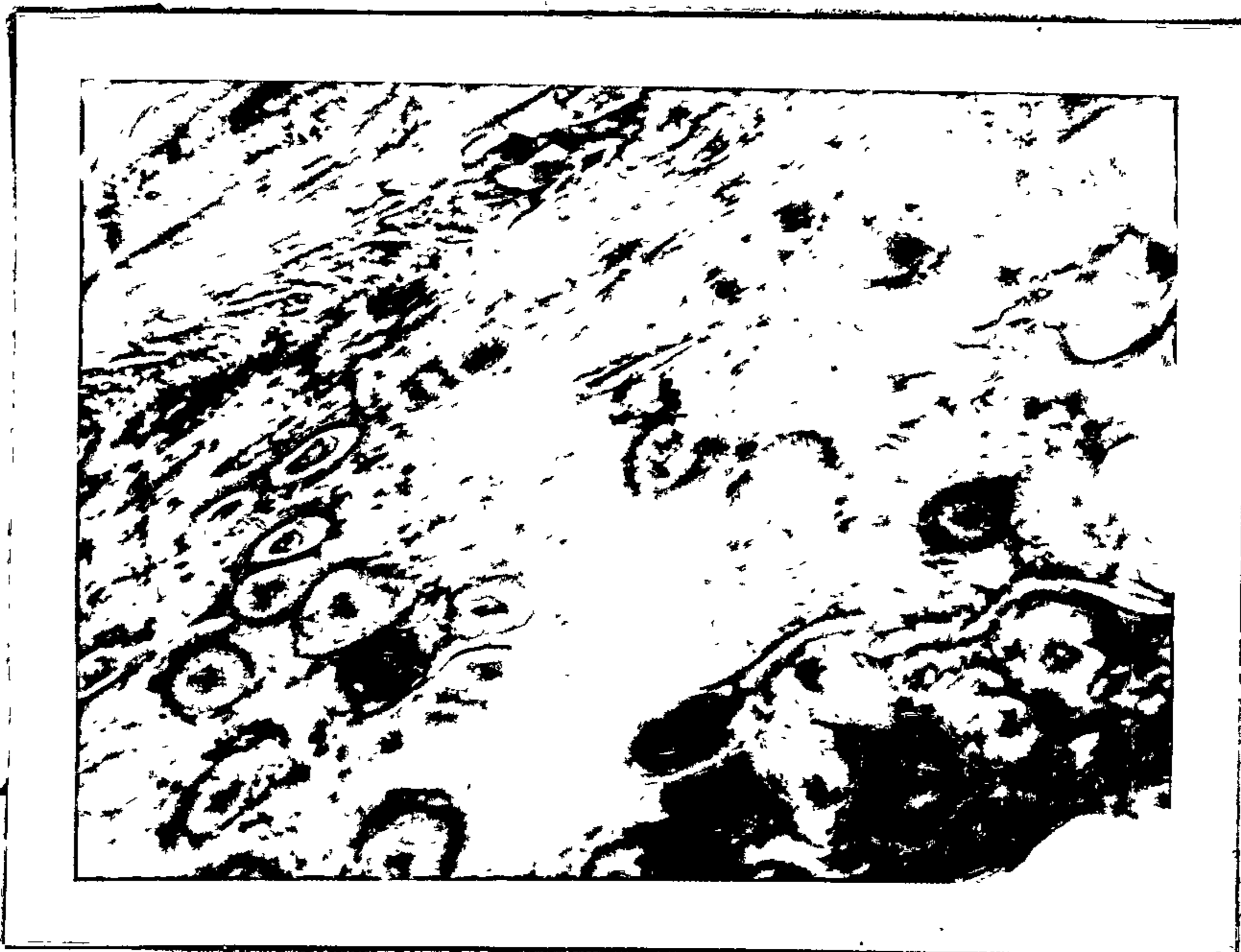

Fig. 206.

Cartilage. Head of the condyle. (X 900 cf. fig. 202.)

Note: Cytomorphosis of cartilage cells.

.....

Pes Menisci. (cf. fig. 202.)

Consists of collagenous fibres orientated mainly parallel to each other. A few fine elastic fibres orientated in the main randomly are among the collagenous fibres. The helix of the pes menisci consists of collagenous and elastic fibres randomly orientated. Both the helix of the pes menisci and the pes menisci are very acellular. An extension of synovial membrane can be seen beneath the

hela of the pes menisci which consists of a layer of fibroblasts about 2 cells thick beneath which is an extensive zone of loose vascular connective tissue.

Pars Gracilis Menisci. (cf. fig. 202.)

It is quite thin, very acellular and avascular. The identity of the cells in its central part cannot be identified with confidence, but the periphery consists of chondrocytes arranged in rows and the synovial membrane is of a fibrous type. There are many clefts in the pars gracilis menisci suggesting dissolution of the ground substance. (fig. 207.)



Fig. 207.

Pars gracilis menisci showing dissolution of ground substance.
(X 900 cf. fig. 202.)

.....
Pars Posterior Menisci. (cf. fig. 202.)

It is also relatively acellular and avascular. The collagenous fibres are randomly orientated and at its superior surface definite fibrillation of the fibre cartilage has occurred. (fig. 208). Bundles of collagenous fibres are unmasked and no synovial membrane can be said to exist. Its inferior surface consists of chondrocytes, some of which are hypertrophic and the synovial membrane is of a fibrous type.




Fig. 208.

Pars posterior menisci showing fibrillation or dissolution of ground substance. (X 900 cf. fig. 202.)

.....

Inferior Stratum. (cf. fig. 202.)

This stratum exhibits the ligamentous nature observed in the other preceding specimens although its elastic component is more marked and more definite thickening of the elastic fibres seems to have occurred. (fig. 209.) The synovial membrane of the inferior stratum is of the fibrous type and as such, differs from that of the previous specimen suggesting that compression has occurred in this region. (fig. 210.)




Fig. 209.

Inferior stratum showing elastic fibre component. (X 270 cf. fig. 202.)

.....




Fig. 210.

Synovial membrane beneath inferior stratum. (X 270 cf. fig. 202.) Note: Sub synovial connective tissue is densely fibrous.

Superior stratum. (cf. fig. 202.)

Consists of collagenous fibres and elastic fibres which in this section appear to be randomly orientated above which there is a synovial membrane of the areolar type. Some of the blood vessels beneath this synovial membrane have very thick walls. The elastic fibres in certain parts are very thick giving the impression of hyper elastosis. (figs. 211, 212.)




Fig. 211.

Superior stratum showing thick elastic fibres. (X 80 cf. fig. 202.)

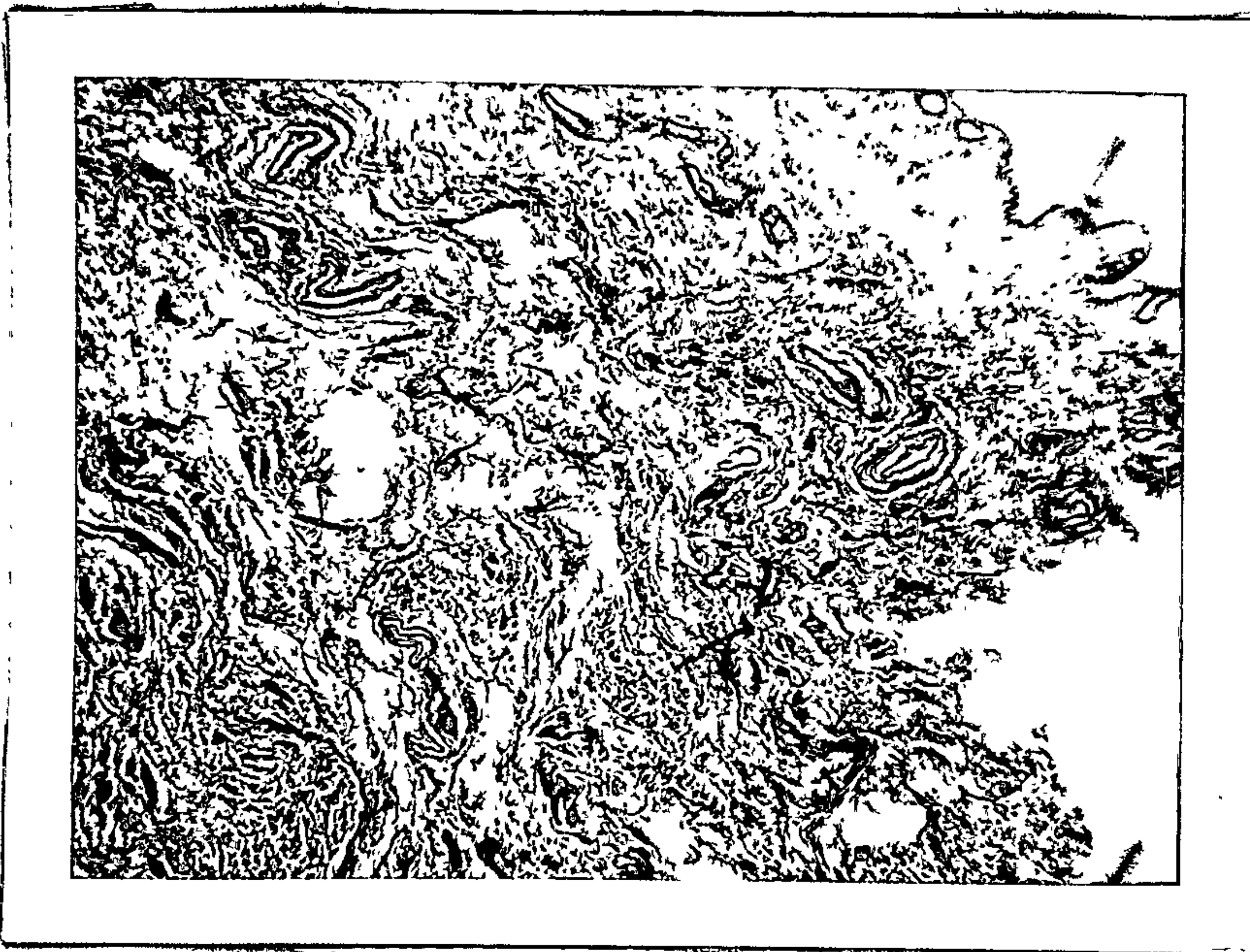


Fig. 212.

Synovial membrane above the superior stratum. (X 80 cf. Fig. 202.) Note: Extensive loose sub synovial connective tissue.

Bilaminar Zone. (cf. fig. 202.)

This zone is much more fibrous than the preceding specimens and here again numerous thick elastic fibres can be observed which indicates hyper elastosis in this region. The zone is essentially neuro-vascular connective tissue of varying density. (fig. 213.)

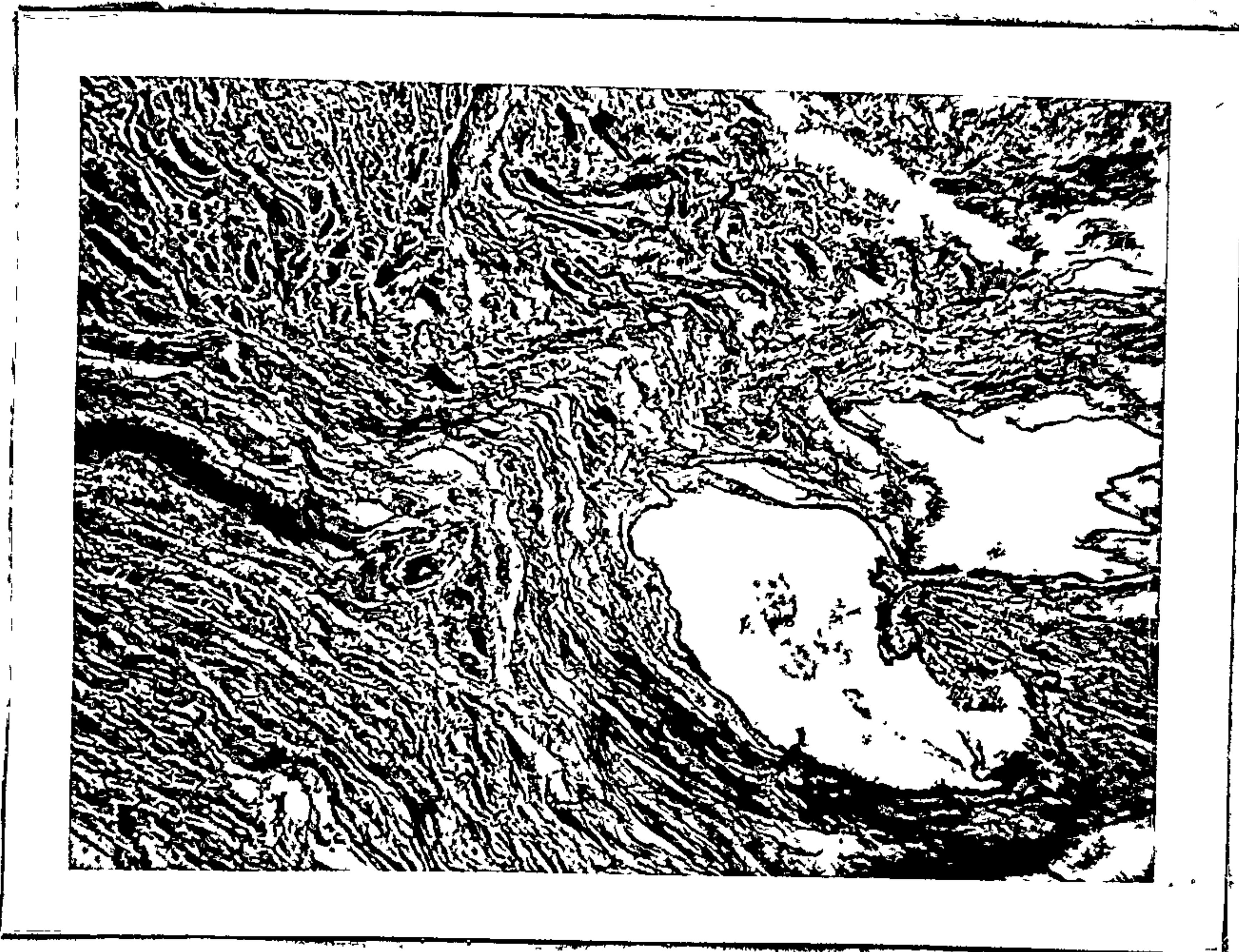


Fig. 213.

General field of the bilaminar zone. (X 80 cf. Fig. 202)

Middle third of the Meniscus. (cf. fig. 214.)Perichondrium of the Head of the Condyle.

As in the preceding section, no definite line of demarcation between perichondrium and articular cartilage can be observed. All the cells are chondrocytes and all the stages of cytomorphosis of chondrocytes can be observed. The collagenous fibres are unmasked and appear to be in the main in a plane corresponding to the curvature of the head of the condyle.

At the periphery the perichondrium is continuous on one hand with the synovial membrane of the anterior and inferior joint cavities, and on the other hand, with the periosteum covering the pterygoid fovea of the condyle. In this region, the insertion of the lateral pterygoid muscle into the periosteum can be observed. The insertion is of a fleshy and tendinous nature. Where it is of a fleshy nature, the sarcolemma of the striated muscle fibres merge with the collagenous fibres of the periosteum. (figs. 215, 216.) Where it is of a tendinous nature the sarcolemma of the muscle fibres appears to be continuous with the connective tissue sheath of the tendon. The sub synovial connective tissue of the anterior and inferior joint cavities is remarkably well preserved in this specimen and consists of a surface layer 2 to 3 cells thick and extends inferiorly to be reflected beneath the anterior surface of the head of the pes menisci. Beneath this is an extensive layer of very vascular sub synovial connective tissue in which there are arterio-venous-anastomoses and small glomus bodies. The glomus bodies appear to be encapsulated in a dense fibrous tissue sheath and in its substance are arterioles, venules and epithelioid type arterio-venous-anastomoses.

At the antero-inferior extremity of the inferior joint cavity a spear shaped villus projects into the joint cavity. This villus is attached to the synovial membrane by a fairly long thin narrow strip of dense connective tissue, which widens as it curls into the joint cavity. Arterioles and

venules can be observed in its substance. (figs. 217, 218, 219, 220, 221, 222.)

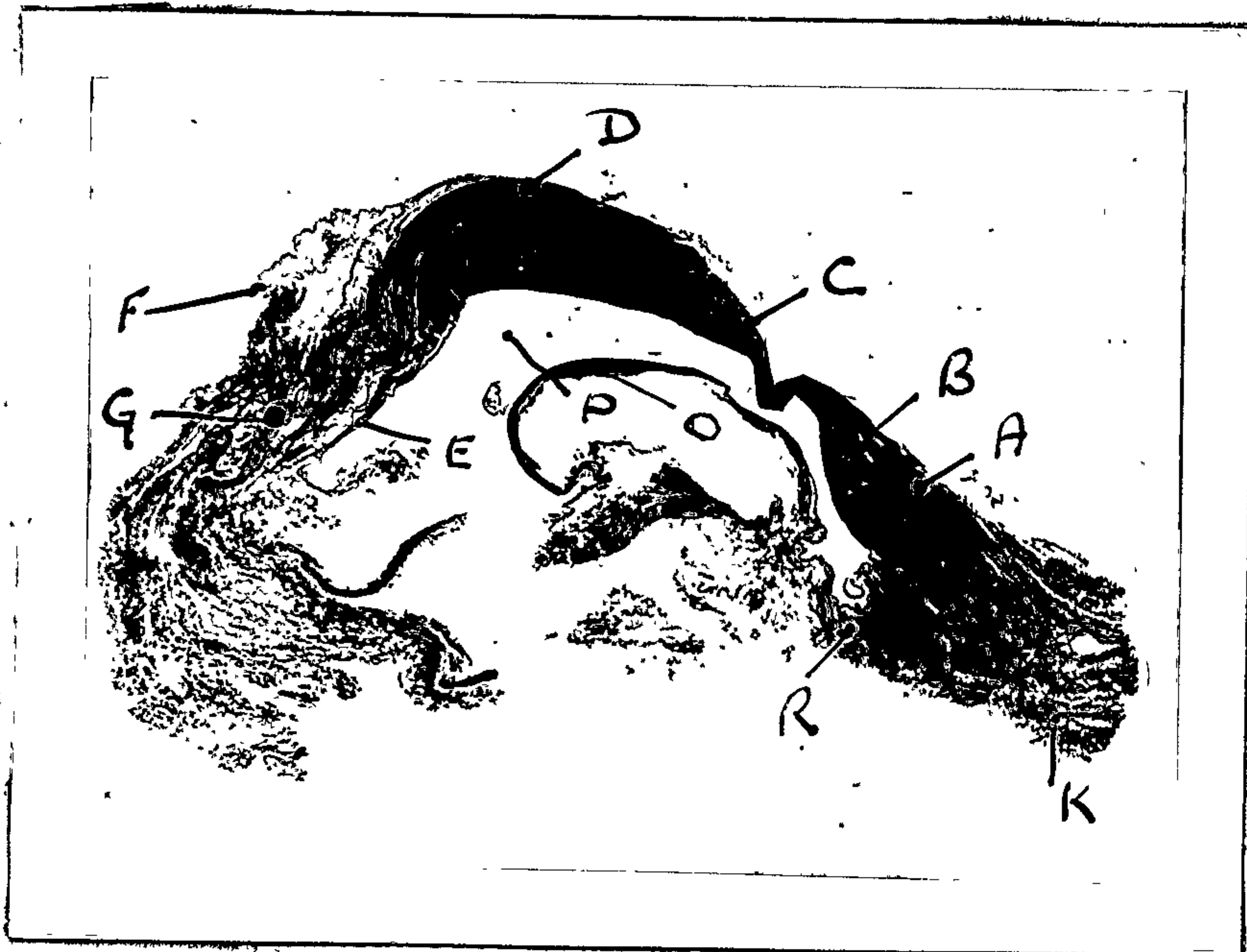

Fig. 214.

Specimen no. 5 - 72 years.

Sagittal section X 5. Temporomandibular meniscus.

- A. Pes menisci.
- B. Head of the pes menisci.
- C. Pars gracilis menisci.
- D. Pars posterior menisci.
- E. Inferior stratum.
- F. Superior stratum.
- G. Bilaminar zone.
- K. Lateral pterygoid muscle.
- O. Perichondrium.
- P. Inferior joint.
- R. Periosteum.



Fig. 215.

Insertion of the lateral pterygoid muscle into the periosteum of pterygoid fovea. Head of the condyle. (X80 cf. fig. 214.)



Fig. 216.

Insertion of the lateral pterygoid muscle into periosteum of pterygoid fovea. Head of the condyle. (X 270 cf. fig. 214.) Note: Appears to be mainly a fleshy insertion.

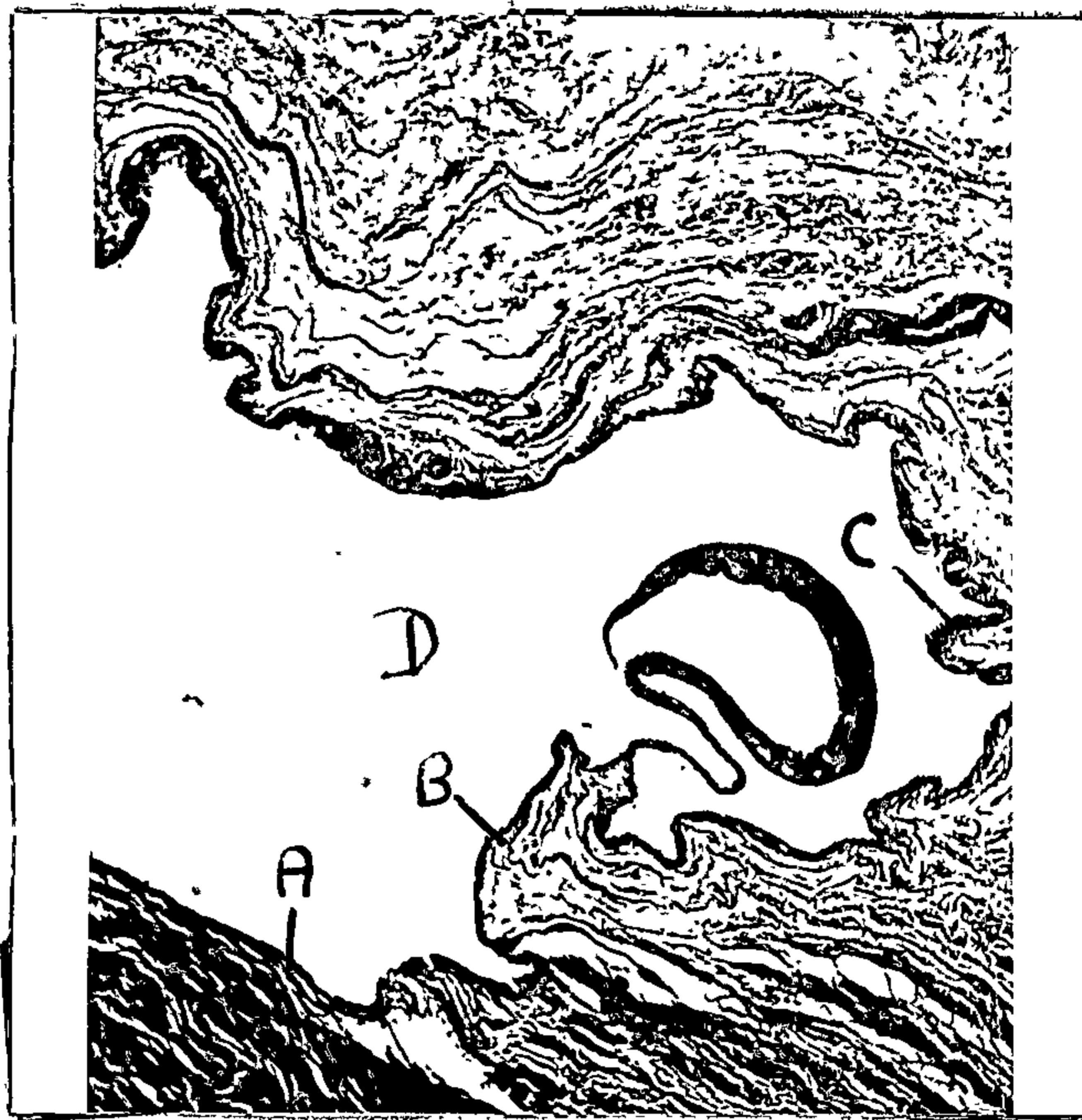


Fig. 217.

Reflection of the synovial membrane and blood vessels. (X 80 cf. fig. 214.) Head of the condyle.

- A. Perichondrium.
- B. Synovial membrane.
- C. Area of reflection.
- D. Antero-inferior joint cavity.



Fig. 218.

Glomus body in the pterygo-condylar area. (X 270 cf. fig. 214.)

- A. Arteriole.
 - B. Succet-Hoyer canal.
 - C. Vein.
- Note: How it is encapsulated.




Fig. 219.

Succet-Hoyer canal showing epithelioid cells. Pterygo-condylar area. (X 900 cf. fig. 214.)

- A. Lumen.
- B. Epithelioid cells.






Fig. 220.

Villus projecting into the antero-inferior joint cavity.
(X 270 of. figs. 214, 217.)

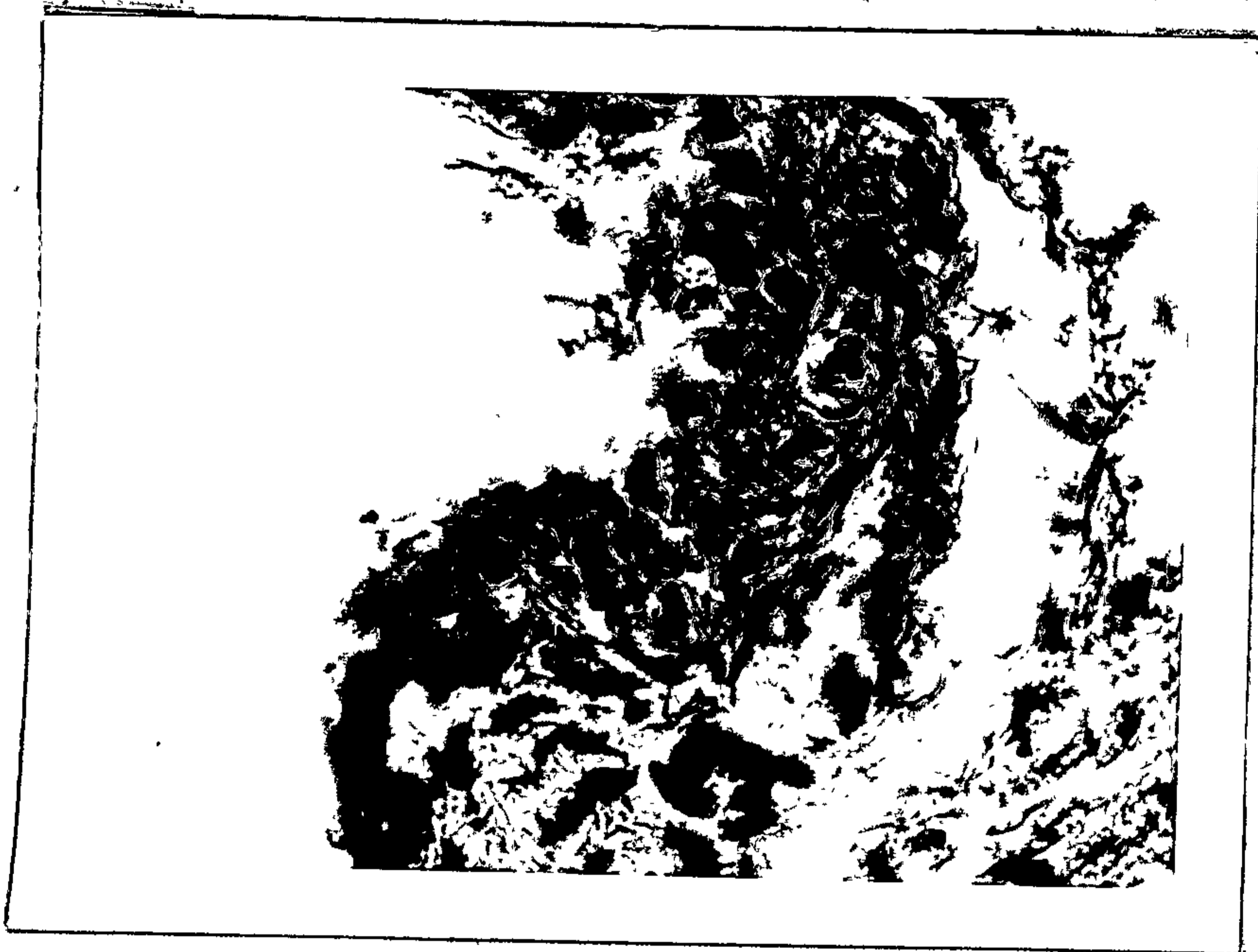

Fig. 221.

Synovial membrane approximately 2 cell layers thick. Antero-
inferior joint cavity. (X 900 of. fig. 214.)



Fig. 222.

Blood vessels in the sub synovial connective tissue of the antero-inferior joint cavity. (X 900 of. fig. 214.)

.....

Pes Menisci. (cf. fig. 214.)

Consists of collagenous fibres orientated in the main, parallel to each other between which there are a few fine elastic fibres. Small arteries and veins of normal structure can be observed in its substance. The hela of the pes menisci consists of unorientated collagenous fibres in which a few sparse elastic fibres can be observed.

Pars Gracilis Menisci and Pars Posterior Menisci. (cf. fig. 214.)

These structures are similar in appearance to those described in the preceding section.

Inferior Stratum. (cf. fig. 214.)

This stratum, again is similar in appearance to that in the preceding section except that its elastic component is not so conspicuous.

Superior Stratum. (cf. fig. 214.)

This stratum consists of collagenous and elastic fibres orientated in the main parallel to each other, above which is a synovial membrane of the areolar type.

Bilaminar Zone. (cf. fig. 214.)

This zone is similar in appearance to that described in preceding section.

Medial third of the Meniscus. (fig. 223.)Perichondrium of the Head of the Condyle.

This exhibits fibrillation covering the posterior articular slope of the condyle. Its anterior extremity was not procured.




Fig. 223.

Specimen no. 5 - 72 years.

Sagittal section X 5. Medial third temporomandibular meniscus.

- A. Pes menisci.
- B. Hela of the pes menisci.
- C. Pars Gracilis menisci.
- D. Pars posterior menisci.
- E. Inferior stratum.
- F. Superior stratum.
- G. Bilaminar zone.
- O. Perichondrium.
- P. Inferior Joint cavity.
- R. Periosteum.

Pes Menisci. (cf. fig. 223.)

Consists of collagenous fibres which have been sectioned obliquely transversely among which are elastic fibres. The hela of the pes menisci consists of unorientated collagenous fibres and beneath its inferior surface is synovial membrane which approximates a fibrous type.

Pars Gracilis Menisci and Pars Posterior Menisci. (cf. fig. 223.)

These structures are, again similar in appearance to those described under the Lateral third of the Meniscus.

Inferior Stratum. (cf. fig. 223.)

Again similar in appearance to the preceding section except that the elastic fibre component is much less conspicuous.

Superior Stratum. (cf. fig. 223.)

Consists of collagenous fibres orientated in the main parallel to each other and indeed having a ligamentous appearance. Only a few elastic fibres can be demonstrated. The synovial membrane above the superior stratum is of the areolar type with a very extensive sub synovial connective tissue zone.

Bilaminar Zone. (cf. fig. 223.)

The connective tissue of this zone is not so dense as in the preceding sections and its elastic tissue component is reduced as compared with preceding sections.

SUMMARY.

The meniscus is remarkably reduced in thickness when compared with other specimens and exhibits in a more marked degree the phenomenon of fibrillation of the fibro cartilage of the meniscus and perichondrium of the articular cartilage. Small glomus bodies and epithelioid type arterio-venous-anastomoses can be observed in the sub synovial connective tissue. The meniscus exhibits very thick elastic fibres in some of its parts. The sub synovial connective tissue inferior to the inferior stratum differs from the sub synovial connective tissue of other specimens, suggesting that a degree of compression has occurred in this area.

In this particular meniscus thrombosis (figs. 224, 225.) of a pterygoid branch of the maxillary has been previously reported and the suggestion had been made that fibrillation could have been due to occlusion of the anterior articular arteries to the meniscus. (21)

Genu Vasculosis Menisci.

Possibly, owing to atrophic changes in the meniscus of this specimen, the canal was not observed.

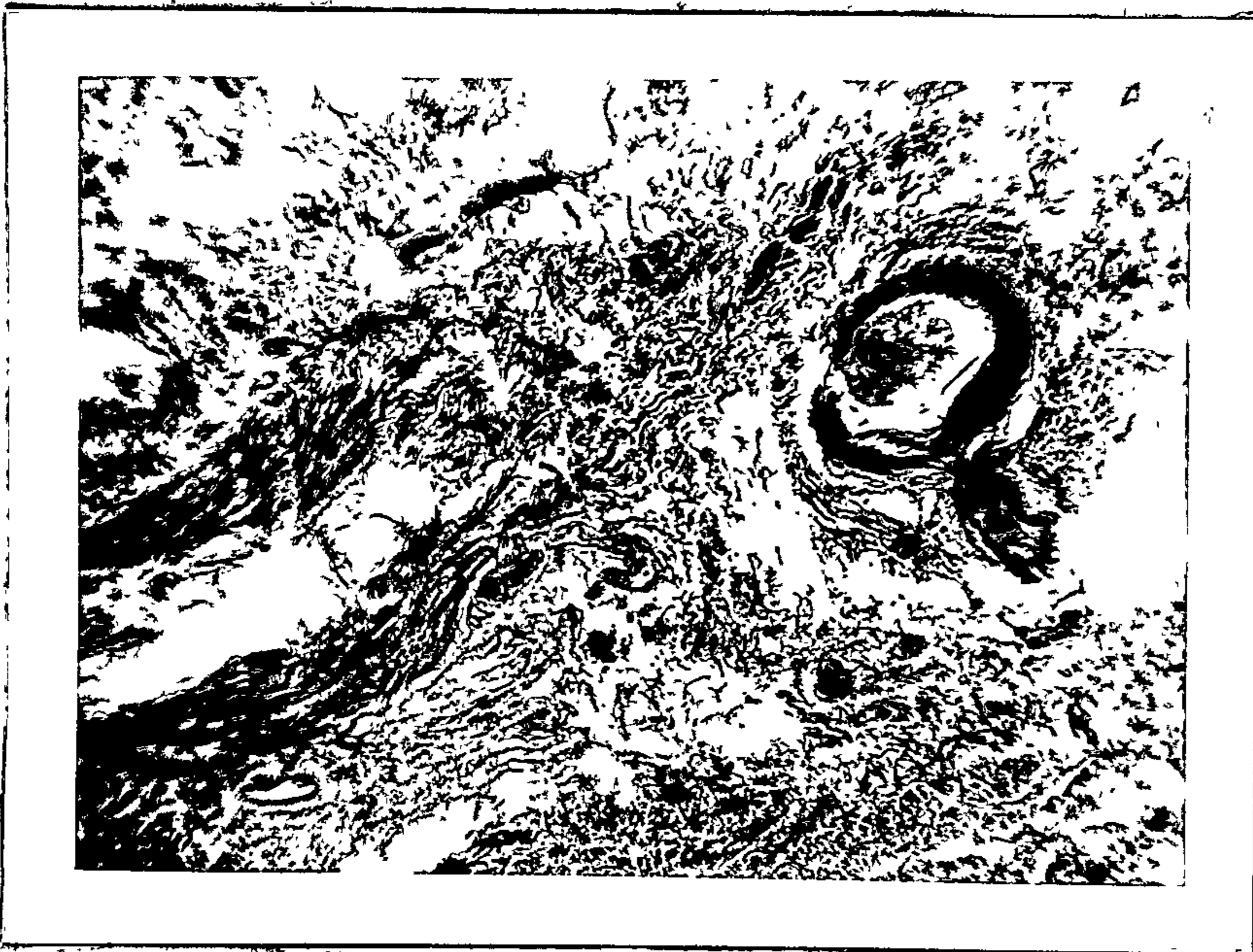


Fig. 224.

Thrombosis articular branch pterygoid arteries just anterior to attachment of pes menisci to articular eminence. (X 80 of. fig. 223.)

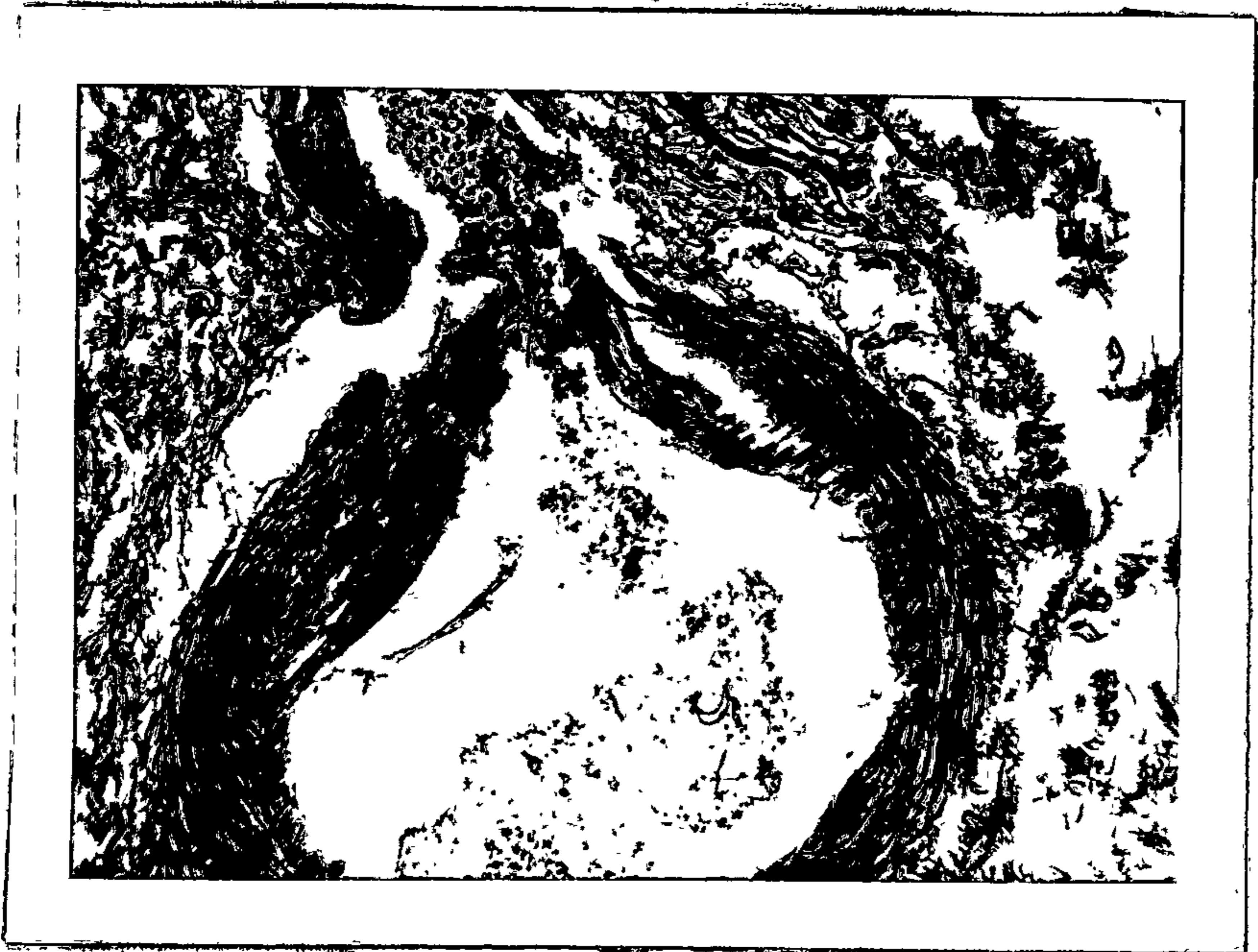

Fig. 225.

Thrombosis articular branch pterygoid arteries. (X 540 of. fig. 223.)

CHAPTER 7.THE STRUCTURE OF THE TEMPOROMANDIBULAR MENISCI AT 18 YEARS OF AGE.SPECIMEN No. 6.

The specimen, in coronal section, consists of a temporomandibular meniscus and the head of the condyle removed from a male cadaver aged 18 years. Cause of death was a medullo blastoma involving the cerebello pontine angle. Coronal sections through the pes menisci, the pars gracilis menisci, and the pars posterior menisci were only procured. The sections can be orientated medio-laterally since the medial pole of the condyle projects more over the ramus of the mandible than the lateral pole.

Coronal Section through the Pes Menisci. (fig. 226.)Structure of the Head of the Condyle. (cf. fig. 226.)

The head of the condyle consists of a thin cortical layer of compacta beneath which is coarse cancellous bone and above which is articular cartilage. (fig. 227.)

Superficial to the articular cartilage is fibro cartilage or fibrous tissue. At the periphery the fibro cartilage is continuous, on the one hand, with the periosteum on either side, and on the other hand with the synovial membrane of the inferior joint cavity. (figs. 228, 229.)

The cortical compacta does not form a complete layer to the articular surface of the condyle and is interrupted in places by fairly large bays of vascular osteogenic tissue. (fig. 230.) It is separated from the articular cartilage by a zone of calcified cartilage. The chondrocytes in the calcified cartilage are hypertrophic and degenerative. Superficial to the calcified cartilage is a zone of round and flattened chondrocytes. Above this again is a zone of small round chondrocytes, and above this is a zone of randomly orientated collagenous and elastic fibres. The most superficial layer, that is the layer in contact with the synovial fluid, consists of fibroblasts widely spaced. In the cortical compacta a few formed Haversian systems can

be seen and also Haversian spaces. The endosteum is not well preserved, thin walled blood vessels can be observed in the Haversian canals. Trabeculae of bone beneath the cortical compacta are orientated at right angles to the surface. (fig. 231.) Between the trabeculae very thin walled blood vessels and fat cells can be recognised. Perichondrium of the articular cartilage is continuous with the periosteum covering the medial and lateral poles of the condyle and a fibro-elastic and cellular layer of periosteum can be recognised. (figs. 232, 233.)

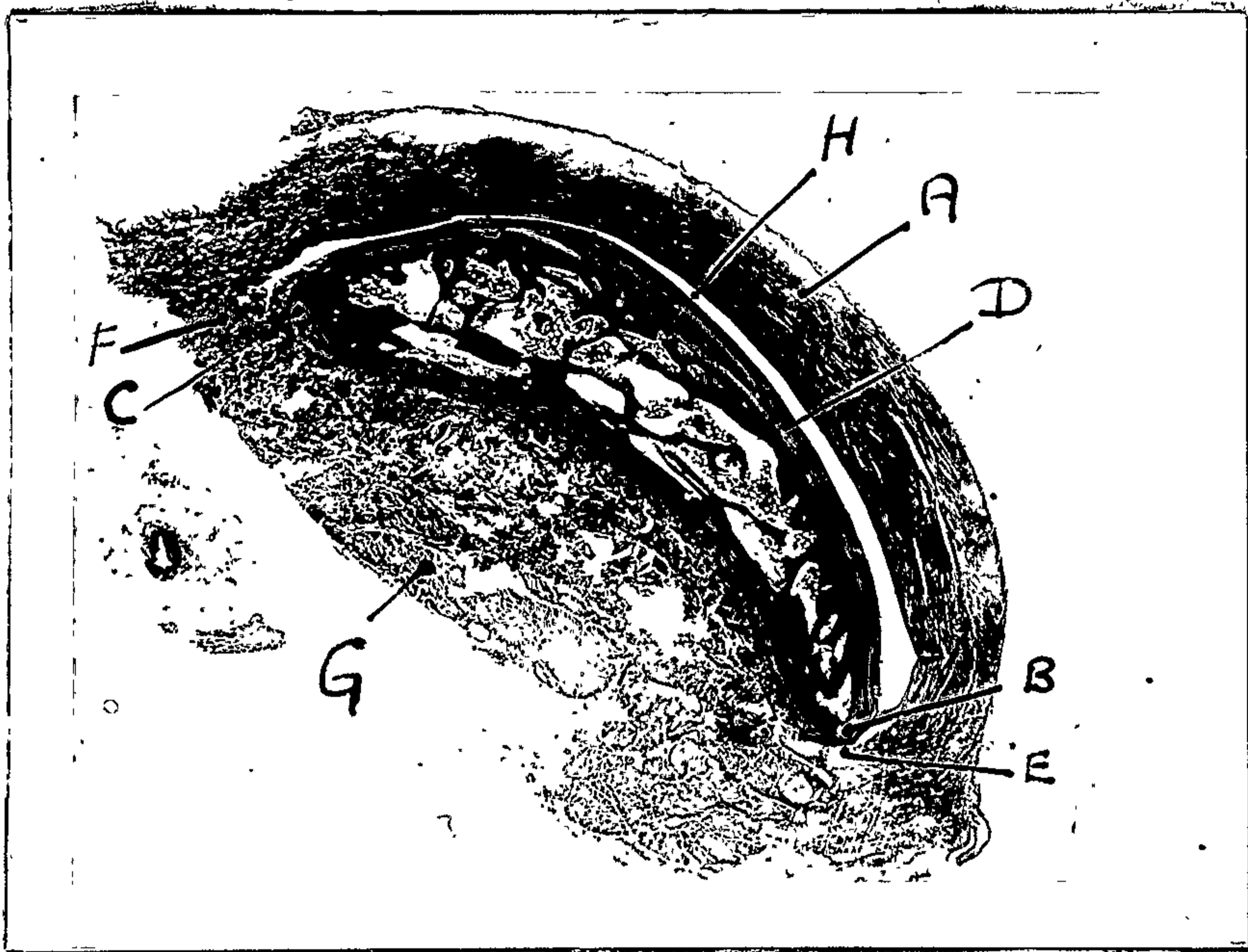


Fig. 226.

Specimen no. 6 - 18 years.

Coronal section X 5. Pes menisci.

- A. Pes menisci.
- B. Medial pole of condyle.
- C. Lateral pole of the condyle.
- D. Perichondrium.
- E. Attachment of meniscus to medial pole of condyle.
- F. Attachment of meniscus to lateral pole of condyle.
- G. Lateral pterygoid muscle.
- H. Inferior joint cavity.

.....



Fig. 227.

Head of the condyle. (X 80 cf. fig. 226.)

- A. Perichondrium.
- B. Fes menisci.
- C. Inferior joint cavity.
- D. Cartilage. Head of condyle.
- E. Cortical compacta.



Fig. 228.

Periosteal - perichondral junction at the medial pole of condyle. (X 80 cf. fig. 226.)

- A. Junction of perichondrium and periosteum.
- B. Perichondrium.
- C. Periosteum.



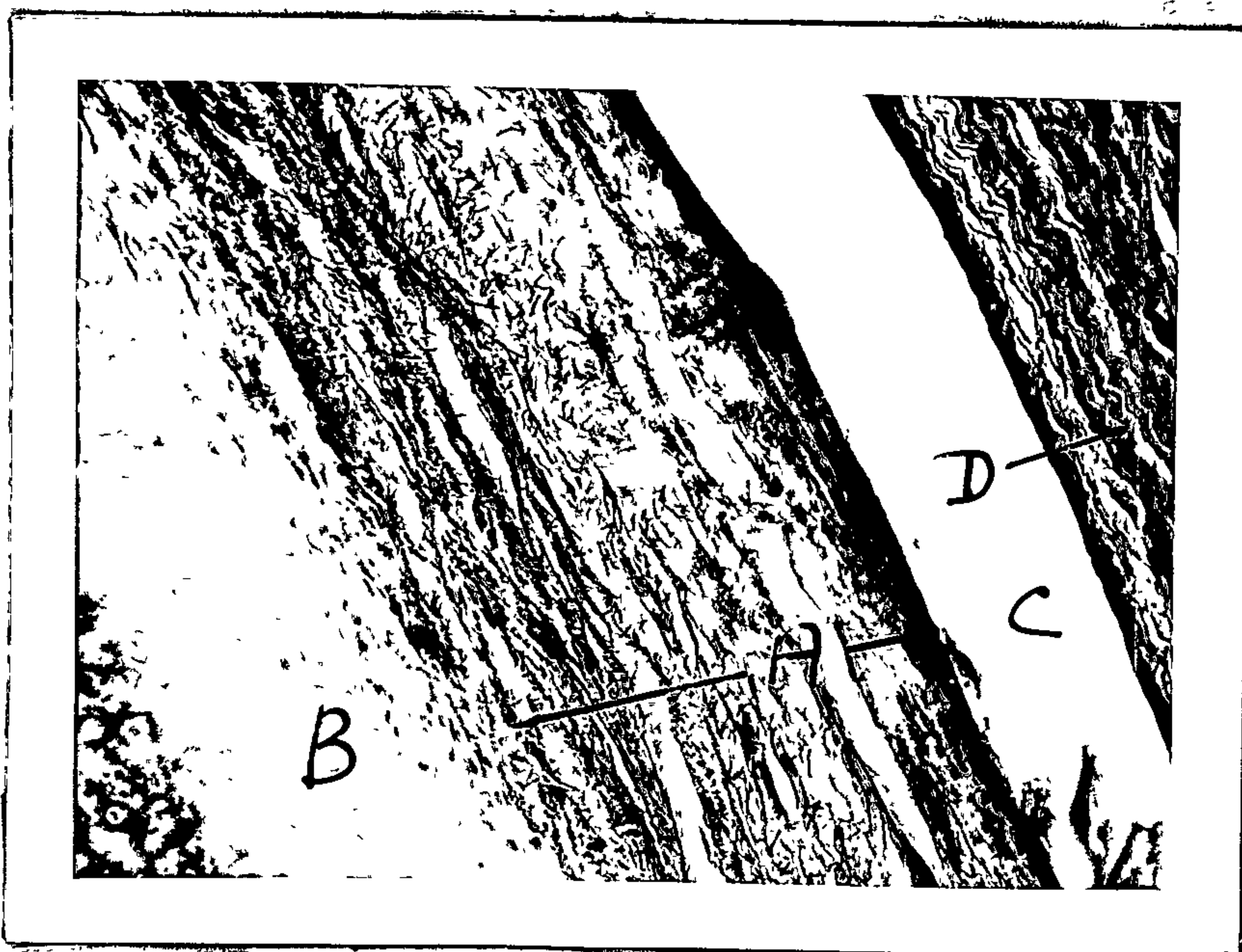


Fig. 229.

Perichondrium showing the superficial, middle and deep layers. (X 270 of. fig. 226.)

- A. Perichondrium.
- B. Cartilage. Head of condyle.
- C. Inferior joint cavity.
- D. Pes menisci.

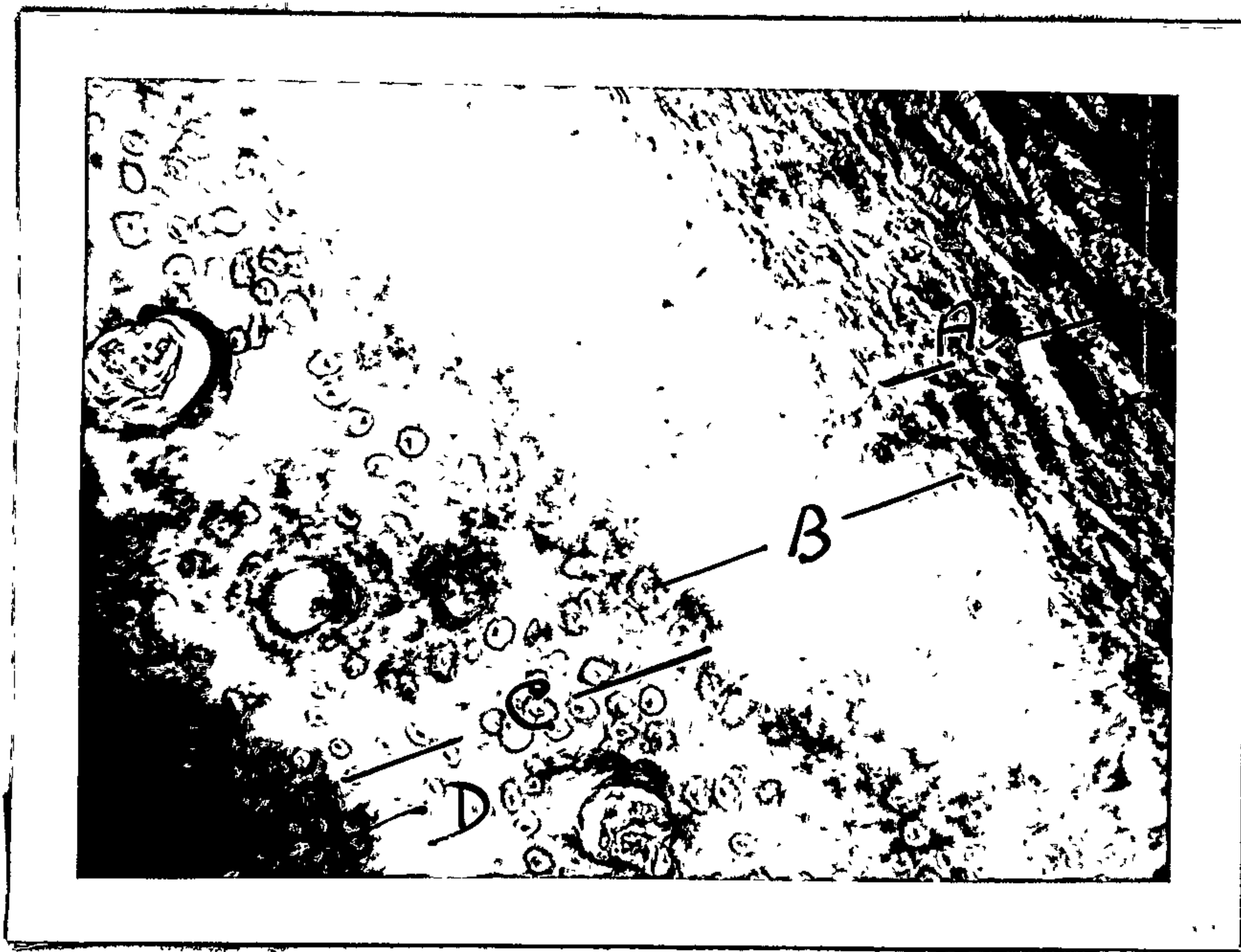


Fig. 230.

Hyaline or articular cartilage. Head of condyle. (X 270 of. fig. 226.)

- A. Perichondrium.
- B. Cartilage. Head of condyle.
- C. Cytomorphosis of cartilage cells.
- D. Calcified cartilage. (Line Zone.) (11).



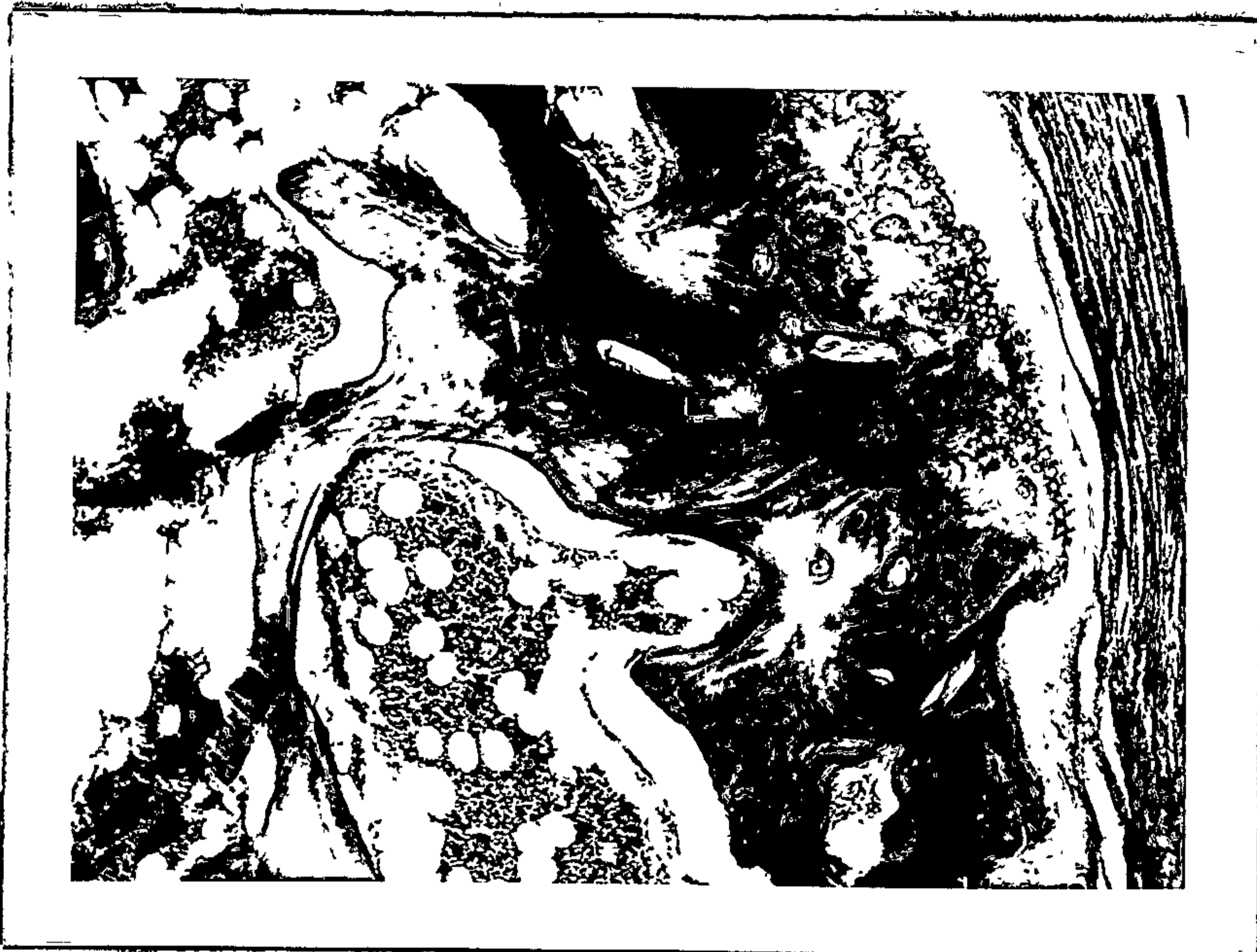

Fig. 231.

Cortical compacta and cancellous bone. (X 80 of fig. 226.)



Fig. 232.

Cortical compacta. (X 270 of fig. 226.)

A. Haversian systems and spaces.





Fig. 233.

Fibro-elastic and cellular layer of periosteum. Head of condyle. (X 270 cf. fig. 226.)

.....
Attachment of the Meniscus to the Medial and Lateral Poles of the Condyle. (cf. fig. 226.)

Medially and laterally the meniscus is attached to the medial and lateral poles of the condyle. At the medial pole the collagenous fibres are in the main sectioned transversely and they appear to merge with the fibrous layer of the periosteum. The elastic fibre component is not so marked at the medial pole. (fig. 234.) A similar method of attachment occurs at the lateral pole (fig. 235.) Here the elastic component is well marked. Apart from this the collagenous fibres of the meniscus medially and laterally become incorporated in the fibrous capsule. The medial part of the capsule consists of loose connective tissue and the meniscus merges with this loose connective tissue. (fig. 236.) The lateral margin of the meniscus consists of dense collagenous tissue with a very marked elastic component. (fig. 237.) A synovial villus can be seen projecting into the superior joint cavity in its medial aspect.

At its lateral attachment the meniscus is incorporated in the lateral ligament, the tissue is quite dense and the elastic fibre component in this region is quite marked.

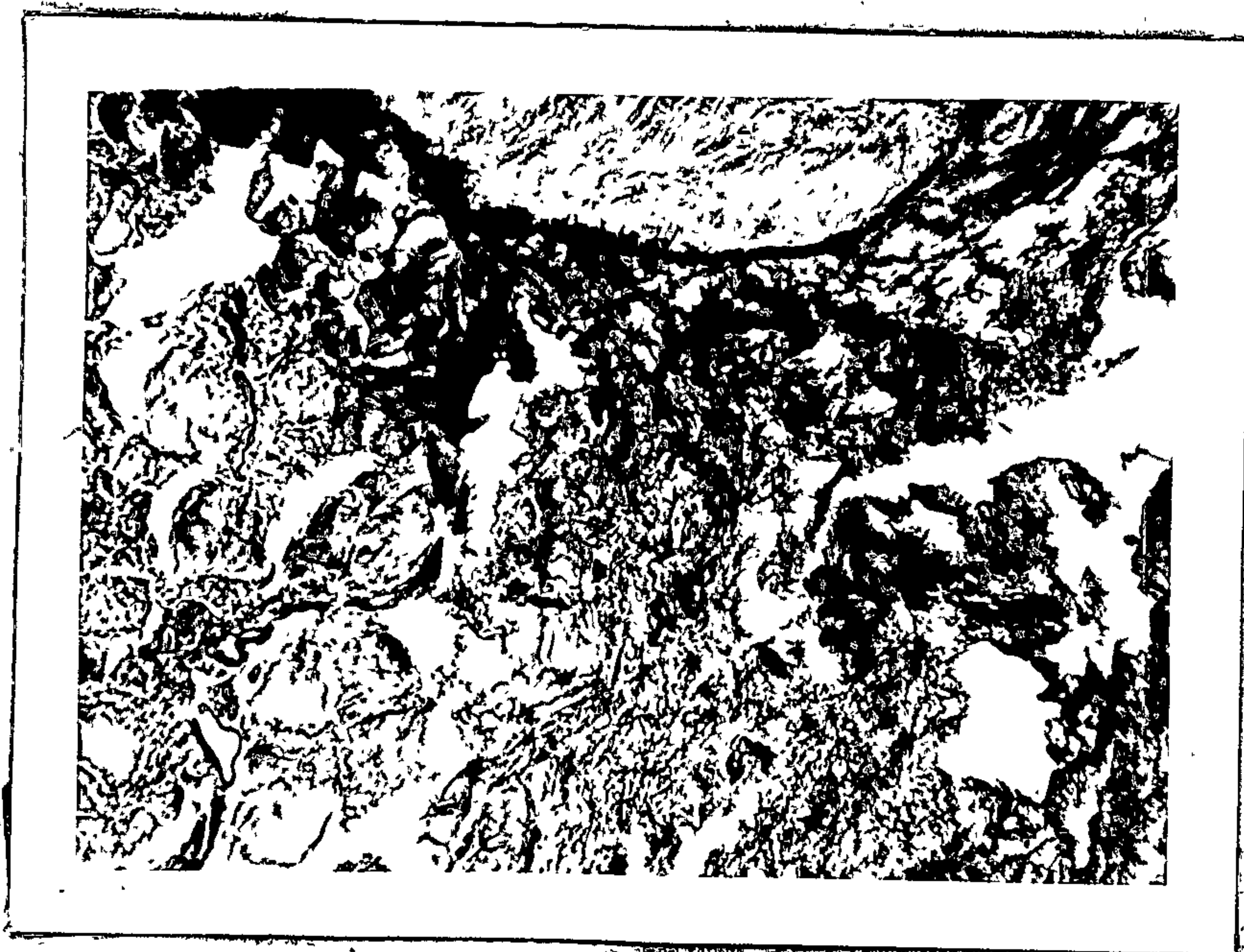


Fig. 234.

Medial attachment of the meniscus to the medial pole of the condyle. (X 80 cf. fig. 226.)




Fig. 235.

Lateral attachment of the meniscus to the lateral pole of the condyle. (X 80 cf. fig. 226.)

- A. Cortical compacta. Head of condyle.
- B. Meniscus.




Fig. 236.

Medial part of the capsule. (X 80 cf. fig. 226.)

.....



Fig. 237.

Lateral part of capsule. (X 80 cf. fig. 226.)

.....

The Body of the Meniscus at the Pes Menisci. (cf. fig. 226.)

The substance of the pes menisci in this region consists of collagenous fibres cut obliquely and fine elastic fibres which form a three dimensional network. The elastic fibres are much more numerous in its inferior half than its superior half. Collagenous fibres are seen in transverse section in its superior half whereas they are sectioned more longitudinally in its inferior half. (fig. 238.)



Fig. 238.

Body of meniscus at pes menisci. (X 80 of fig. 226.)

.....

The Pars Gracilis Menisci. (fig. 239.)

Head of Condyle.

The features are similar to those described in the preceding section.

The Medial and Lateral Attachments of the Meniscus.

The features are similar in appearance to those already described in the preceding section.

The Body of the Meniscus at the Pars gracilis Menisci.

The substance of the pars gracilis menisci and elastic fibre component is not so marked and the majority of the collagenous fibres are out in transverse section. (fig. 240.)

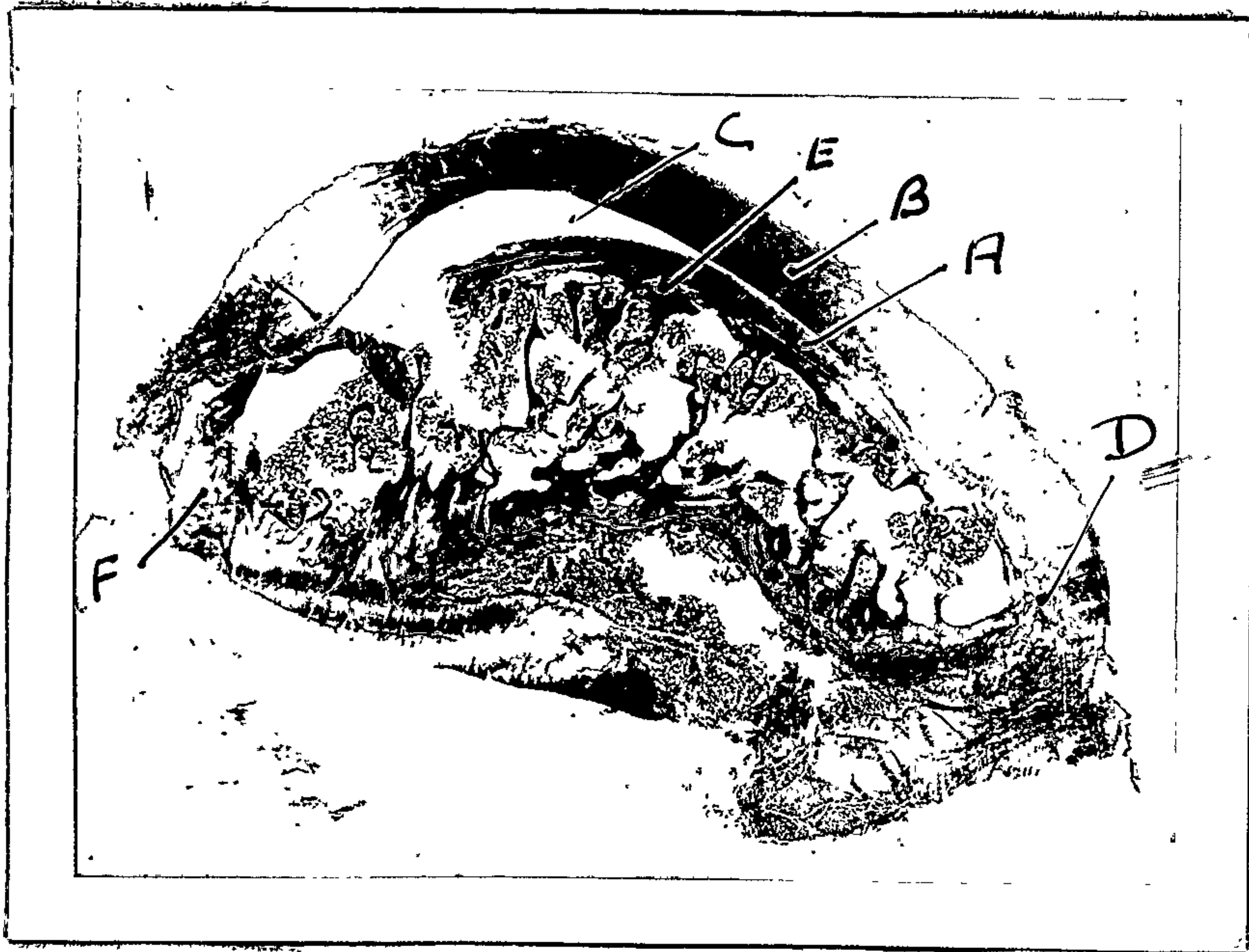


Fig. 239.

Specimen no. 6. - 18 years.

Coronal section X 5. Pars gracilis menisci.

- A. Perichondrium.
- B. Pars gracilis menisci.
- C. Inferior joint cavity.
- D. Medial pole.
- E. Cortical compacta.
- F. Lateral pole.

.....




Fig. 240.

Body of meniscus at pars gracilis menisci. (X 80 cf. fig. 239.)

.....

The Pars Posterior Menisci. (Fig. 241.)

Head of the Condyle.

Again, the features appear to be similar to those already described in the previous section.

The Medial and Lateral Attachments of the Meniscus.

Again similar in appearance to the preceding section.

The Body of the Meniscus at the Pars Posterior Menisci.

The substance of the pars posterior menisci consists of dense unorientated collagenous fibres. (fig. 242.)

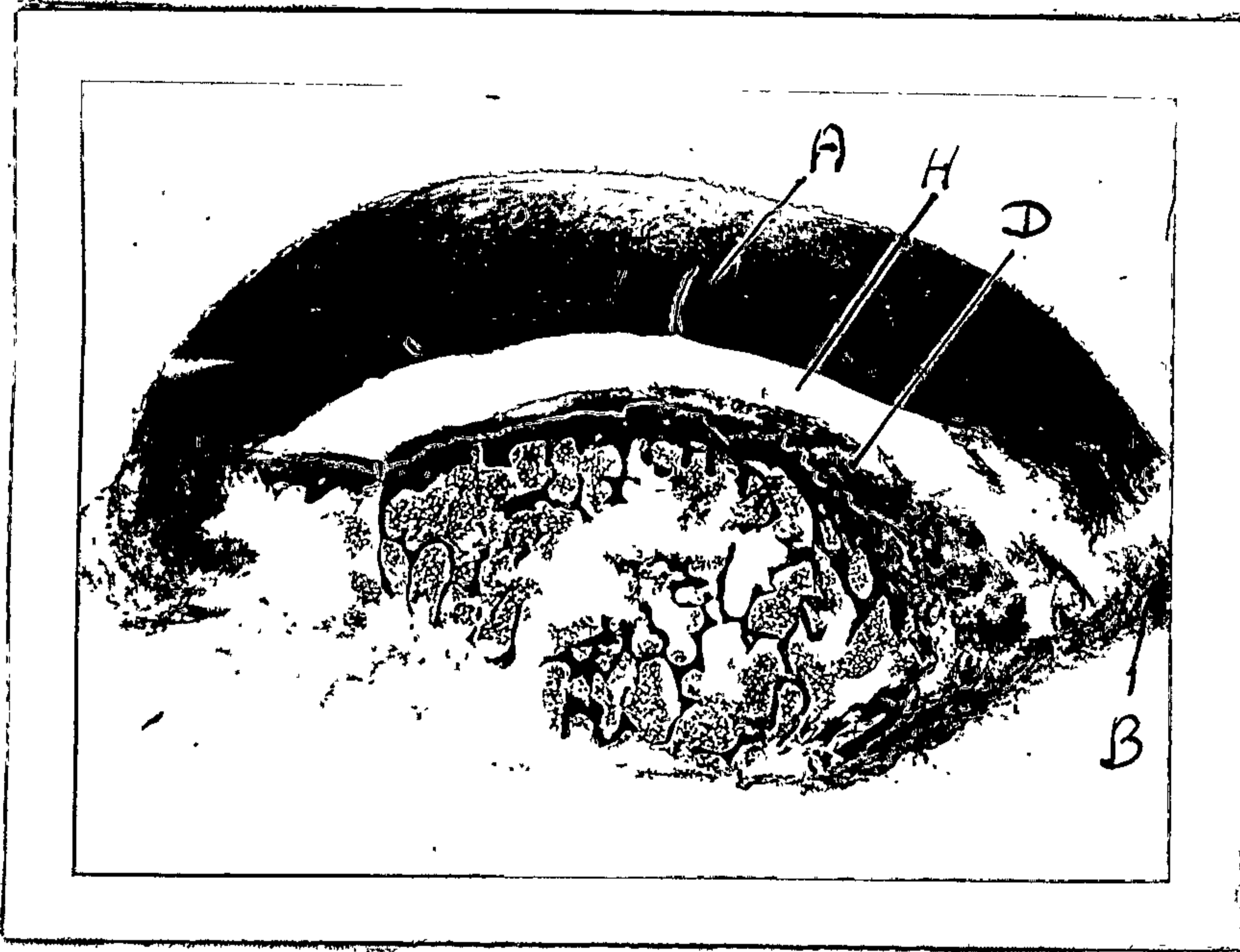


Fig. 241.

Specimen no. 6. - 18 years.

Coronal section X 5. Pars posterior menisci.

- A. Pars posterior menisci.
- B. Medial pole.
- D. Perichondrium.
- H. Inferior joint cavity.

.....



Fig. 242.

Body of meniscus at pars posterior menisci. (X 80 cf. fig. 241.)

.....

SUMMARY.

One cannot comment upon the cellular components of the meniscus from these coronal sections but they elucidate to a certain extent the orientation of the fibre components. In the pes menisci the fibres in the superior half are orientated predominately in the sagittal plane whilst they are orientated medio-laterally in its inferior half.

In the pars gracilis menisci the fibres are for the most part orientated in the sagittal plane whilst in the pars posterior menisci they are unorientated.

At its medial margin the meniscus is attached to the loose medial fibrous capsule and its elastic fibre component is quite marked. The main orientation of the elastic fibres appear to lie in the sagittal plane. At its lateral margin the meniscus is incorporated in the lateral ligament and here again the elastic component is quite marked.

The articular surface of the condyle is covered by fibrous tissue which has a marked elastic component in its deepest layers. The hyaline cartilage terminates abruptly at the medial and lateral poles of the condyle.

CHAPTER 8.SUMMARY OF OBSERVATIONS AND COMMENTS FROM CHAPTERS 2 TO 7.Pes Menisci.

The structure and function of the pes menisci would seem to be associated with the insertion of the spheno-meniscus muscle in its substance. This insertion is tendinous and the insertion of the tendons into the fibrous tissue of this structure is its main morphological feature.

In the specimen at 19 months of age the musculo-tendinous junction of the spheno-meniscus muscle can be observed. It can be seen that a single tendon may receive several fibres of the spheno-meniscus muscle thus concentrating its pull over a small area. The sarcolemma of the muscle fibre is continuous with the fibrous covering of the tendon and the cone shaped extremity of the muscle fibre appears to lie in small grooves on the tendon. Apart from this, the perimysium of groups of muscle fibres is incorporated with the collagenous fibres of the tendon. The fibroblasts in the tendon are arranged in flattened rows and the tendon sheath consists of loose connective tissue. Between the tendon sheaths are spaces which are said to contain a mucinous fluid similar to synovial fluid. (1)

Especially notable in the 19 months old specimen were tendinous patches in the spheno-meniscus muscle approximately where it would pass inferior to the articular eminence. It has been stated that these patches develop in "friction" areas. (1) The tendons ultimately become incorporated in the fibrous tissue of the pes menisci. Although this is the main form of insertion of the spheno-meniscus muscle into the pes menisci some of the muscle fibres are inserted directly into the fibrous tissue of this structure. The elastic tissue component of the pes menisci varies. In the main it consists of sparse elastic fibres forming a three dimensional network.

The vascularisation of this part of the meniscus is from articular branches of the pterygoid and masseteric

arteries from the first part of the maxillary artery. Its innervation is via the masseteric nerve from the mandibular branch of the trigeminal nerve. These blood vessels supply the pes menisci, the tendons of the spheno-menisus muscle and the synovial membrane superior and inferior to the pes menisci and the anterior part of the periosteum and perichondrium of the head of the condyle.

Here and there glomus bodies and epithelioid cell type arterio-venous-anastomoses can be observed, also thin walled veins and arterioles. The hela of the pes menisci does not exhibit the same orientation of collagenous fibres as that part which receives the spheno-menisus muscle and this may be the reason why the orientation of the inferior half of the collagenous fibres observed in the coronal section of the pes menisci, runs in the main, medio-laterally.

The blood vessels of the pes menisci, as stated above, reach the synovial membrane at its superior and inferior surfaces and may extend for some distance into the anterior part of the pars gracilis menisci. In the latter instance vascular canals lined with fibro-cartilage exist. The blood vessels in the sub synovial connective tissue are thin walled capillaries venules, arterioles, thick walled veins, lymphatic vessels, and epithelioid cell type arterio-venous-anastomoses. The synovial membrane is 2 to 3 cell layers thick. It is a synovial membrane of the areolar type. The lymphatic capillaries of the synovial membrane can only be assessed on circumstantial evidence. That is to say, vascular capillaries are filled with erythrocytes and those which do not exhibit erythrocytes in their lumen may be lymphatic capillary vessels.

Larger lymphatics in the anterior part of the pes menisci can also be inferred to exist, again on circumstantial evidence, although more conclusively when the vessel is followed through serial sections. They contain no erythrocytes and form tortuous blind ending polygonal vessels, which are in close proximity to the synovial

membrane, mainly at the anterior extremity of the inferior and superior joint cavities. In the substance of the pes menisci myelinated and amyelinated nerve fibres can be observed.

Pterygo-Condylar Area.

The pterygo-condylar area consists of neuro-vascular connective tissue and a large vein which runs medio-laterally, arteries, arterioles, venules, capillaries, lymphatic capillaries, myelinated and amyelinated nerve fibres can be recognised also epithelioid cell type arterio-venous-anastomoses and small glomus bodies.

The small glomus bodies are an encapsulated structure containing an afferent artery and epithelioid cell type arterio-venous-anastomoses and a connecting vein and they approach very closely the surface of the synovial membrane. The lateral pterygoid muscle has a tendinous and fibrous insertion into the periosteum of the pterygoid fovea of the condyle.

Perichondrium of the Head of the Condyle.

The superficial surface of the head of the condyle consists of flattened fibroblasts and here and there collagenous fibres embedded in the matrix which contains elastic fibres. The deeper layer consists of collagenous and elastic fibres which appear to be orientated in respect to the curvature of the head of the condyle. This deep layer of the perichondrium receives collagenous fibres from the hyaline cartilage of the articular surface of the condyle. Three zones can be recognised in the hyaline cartilage of the head of the condyle. (1) The most superficial zone consists of small round cartilage cells; (2) The intermediate zone consists of flattened chondrocytes which are orientated in respect to the articular surfaces. (3) Deepest layer consists of hypertrophic and degenerative chondrocytes and the matrix between the cells is calcified.

Beneath this is a thin layer of cortical compacta, in the foetus at term active ossification occurs in this area. Similar zones can be recognised in the 58 and 72 year old specimens. At the periphery the perichondrium is continuous with the synovial membrane of the antero-inferior and postero-inferior joint cavities.

Pars Gracilis Menisci.

This part of the meniscus consists of fibro-cartilage and longitudinally orientated collagenous fibres between which are chondrocytes and fibroblasts. Its synovial surfaces consist of flattened fibroblasts and chondrocytes widely spaced and it is relatively avascular. Evidence of cartilage matrix can be seen when aldehyde fuchsin is used as a stain. Elastic fibres are sparsely distributed throughout its substance.

Pars Posterior Menisci.

This part of the meniscus consists of unorientated fibro cartilage. Except for its thickness and unorientated fibro component it is similar in all respects to the pars gracilis menisci.

Inferior Stratum.

This stratum is ligamentous in nature except at its medial and lateral margins. It is continuous posteriorly with the perichondrium and periosteum of the posterior slope of the condyle. The synovial membrane inferior to it is usually of the areolar type and exhibits the same vascular component as described in respect to the pars menisci. The elastic fibre component of the stratum is not marked.

Superior Stratum.

This stratum consists of collagenous fibres which run in the direction of the squamo-tympanic fissure. The fibres are not as well orientated as the fibres of the inferior stratum and appear to run medially, laterally and longitudinally. They appear to splay out near its attachments or termination in the loose connective tissue

in the superior part of the fissure, whilst it is continuous medially and laterally with the fibrous capsule of the temporomandibular joint. In the foetus at term the principal fibres appear to run through the squamo-tympanic fissure and the petro-tympanic fissure to become associated with the loose connective tissue in the superior part of these fissures, whilst some of the fibres merge with the fibres covering of the squamo-temporal bone and petrous temporal bone.

The elastic fibre component is marked at its medial and lateral margins and these fibres appear orientated mainly in the sagittal plane. The synovial membrane is of the areolar type and contains the same type of blood vessels as mentioned previously.

Bilaminar Zone.

This zone consists of loose neuro-vascular connective tissue. The afferent blood supply is derived from the superficial temporal artery and the first part of the maxillary artery. The anterior tympanic artery traverses the substance of the bilaminar zone on its way through the squamo-tympanic fissure to the tympanic membrane. The veins are exceedingly thick walled and epithelioid type arterio-venous-anastomoses can be noted in its substance. Large bundles of myelinated and unmyelinated nerve fibres can be noted. In the posterior region there is a venous plexus.

A constant morphological structure, the ganglionic vasculosis menisci, and significant specialised blood vessels associated with it has been observed in all the menisci examined except for the atrophic meniscus of the 72 years old specimen.

Articular Surface of the Temporal Bone.

In the foetus at term the articular surface of the temporal bone was observed and it consists of a perichondrium and hyaline cartilage similar to that of the condyle.

CHAPTER 9.DISCUSSION.

The purpose of this investigation has been to indicate the fairly constant morphology of the respective parts of the meniscus and to correlate their structure with function. It can be said with some confidence that various parts of the meniscus are reasonably constant in their structure and such structural variations as seen are probably associated with malfunction and age factors.

The unique part of the temporomandibular meniscus is the fact that it moves in accordance with the movements of the mandibular condyle and since such is the case it is probable that only a certain part of the meniscus is concerned with the articular surfaces of the condyle.

It is reasonable to infer that the different structural features of the meniscus are in the main concerned with articulation. The fact that its anterior and posterior portions usually consist of fibrous tissue whilst its central portion, that is the pars gracilis menisci and the pars posterior menisci, consists in the main of fibro cartilage suggests that the central portion is the articular part of the meniscus. Further evidence to substantiate this fact is that the synovial membrane covering the peripheral portions is mainly of the areolar type (22) whilst the synovial membrane of the central portion is of the fibrous type, indicates again that the articular and non articular parts of the meniscus are structurally different. (6)

Again the structural differences between the strata of the bilaminar zone appear also to be significant. As far as the superior stratum is concerned it fixes the meniscus to the squamo-tympanic fissure and the other fixed part being its attachment to the articular eminence. Although of course, medially and laterally, it is continuous with the connective tissue of the fibrous capsule of the joint. The connective tissue of the fibrous capsule is dense

laterally since it is reinforced by the lateral ligament and receives some of the fibres of the masseter and temporalis muscles. (4) Medially the fibrous capsule consists of loose connective tissue.

The dense connective tissue constituting the lateral capsule of the joint would seem to restrict its movement laterally whilst the medial and lateral aggregations of elastic fibres in the medial and lateral margins of the superior stratum would seem to permit forward transitory movement of the meniscus. In addition the attachment of the meniscus through the squamo-tympanic fissure also allows this type of movement. On the other hand, the inferior stratum is ligamentous in nature and it also, when taut, would tend to restrict forward transitory movement. In this respect when examining the lateral roentgenograms of the temporomandibular joint in opening of the mouth one sees an initial antero-inferior movement of the mandibular condyle and at the same time the condyle presents a narrower lateral shadow after some 6 m.m. of opening the jaws. This latter appearance indicates that the lateral pole of the condyle is in the same plane as the medial pole so that a rotary movement has occurred.

As a result of this one sees a change in the temporo-condylar relationship. It could be assumed that the more inferior relationship of the mandibular condyle to the temporal bone after 6 m.m. of opening would not only put the superior stratum at stretch but would also contribute to the tautening of the lateral ligament and the inferior stratum. Again, also with this phase the mandibular condyle comes into close relationship with the articular eminence. It may be that this changed relationship induces hinge movement of the condyle, that is, tautness of the lateral ligament and the inferior stratum, plus stretch of the superior stratum and the articular eminence as a fulcrum. The late entry of the digastric muscle (23) in opening the mouth and the fact that some authorities consider that

the digastric muscle is concerned with hinge movement. (24)
The hyoid bone being steadied with infra hyoid group of muscles seems to support this contention.

In lateral excursion the movement of the condyle on the working side is said to be postero-lateral and antero-medial on the non working side, and to effect centric occlusion the condyle on the working side moves medio-anteriorly, whilst the condyle on the non working side moves postero-laterally. The lateral pterygoid and spheno-meniscus muscles relaxing and contracting alternatively on the working and non working sides respectively. The mandible being stabilised in relation to the skull by a sustained contraction of the masseter and temporal muscles. This manoeuvre effects the shearing out of mastication. (25)
It would seem that during these reflex masticatory movements of the condyle that portion of the spheno-meniscus muscle (26) located inferior to the articular eminence would be susceptible to pressure and friction and this seems to be verified by the fact that tendinous patches in the spheno-meniscus muscle are seen in this location. The fluid between the tendinous sheaths being of a mucinous nature minimises the effects of friction or pressure and permits the tendons to move more freely. (1)

Thus it seems that the structural modification of the meniscus is associated with permissible movements of the condyle during mastication.

Collagen and Elastin.

The main component of the meniscus is collagenous fibres among which is a variable amount of elastic tissue.

The chemical composition of elastin compared with collagen may be seen from Table 1. From this table it can be seen that the amounts of hydroxy proline, hydroxy lysine, glutamic acid, aspartic acid and lysine are much less than in collagen. It is apparent that the elastic fibre chemically is quite different from a collagen fibre.

Table 1.

Comparison of amino-acid composition of mammalian collagen and elastin.

	Collagen		Elastin	
Glycine	26.5	- 27.2	25.7	- 29.4
Proline	14.8	- 15.1	15.2	- 15.6
Tyrosine	0.3	- 1.1	0.25	- 1.4
Cystine			0.2	- 0.6
Arginine	8.5	-	0.3	- 1.1
Histidine	0.7		0	- 0
Lysine	4.5	- 4.6	0	- 0.5
Aspartic Acid.	6.3	- 6.7	0	- 0.6
Glutamic Acid	11.3		2.7	- 3.3
Hydroxy Proline	14.0	- 14.5	0	- 2.0
Hydroxy Lysine	1.1	- 1.2	0	- 0

The values are given as G. amino-acid / G. dry protein. This table is compiled mainly after Tristram (27) and Bower and Kenton, (28) and modified after Newberger. (29) It is probable that this chemical difference accounts for the different physical properties of the fibres.

Collagenous fibres are inextensible whereas elastic fibres are extensible. The property of extensibility in elastic fibres endows them with the property of transferring strain energy into potential energy and this potential energy thus acquired can be readily converted into kinetic energy. Thus in any tissue subject to tension and stress the elastic component in the tissue would readily assist in reverting the tissue, once relieved of tension, to its resting state. (30) The collagenous fibres of the meniscus as a rule are orientated in the direction of the plane of pull or tension. Since the initial movement of the meniscus is as a rule essentially a forward translatory movement the majority of the fibres are orientated in the sagittal plane. The exception of course being the pars posterior menisci.

Here the fibres splay out and are unorientated. It may be that anchoring of the fibres is achieved in this fashion.

As was mentioned before, concentration of the spheno-meniscus muscle is achieved by its tendinous insertion into the meniscus. These tendons in certain cases run for

a fair distance into the pes menisci before becoming associated with the collagenous fibres of the meniscus. These latter fibres are in turn associated with the collagenous fibres of the pars gracilis menisci and the pars posterior menisci.

As was stated previously collagen essentially is inextensible. It should be noted that the tensile strength of a collagenous fibre incorporated in a tendon of a cadaver is 8,700 to 18,000 lbs. per square inch. (1) Freedom of movement of groups of collagenous fibres would seem to be related to the amount of intercellular substance between the fibres. Thus where they are freely moveable, e.g. groups of collagenous fibres such as tendons, they are separated from each other by a relatively extensive amount of mucinous fluid. Where they are closely packed together such as in ligaments and fibre cartilage the intercellular substance between the fibres is not marked. So that on this basis, in forward translatory movement of the condyle, the meniscus must move in toto. When the antero-inferior movement of the meniscus occurs the fixed posterior portion, that is, the inferior stratum, must be stretched and its collagenous component must move. Movement of the collagenous component of the superior stratum is permissible due to its peculiar mode of attachment through the squamo-tympanic fissure.

The principal fibres of the superior stratum, elastic and collagenous fibres, run parallel with each other through the squamo-tympanic fissure but are not attached directly to temporal bone or the tympanic bone proper. However the attachment is formed by the fibres splaying out into and terminating in the loose connective tissue in the superior part of the fissure. This form of attachment permits maximum movement. (30) The marked elastic fibre component of the medial and lateral margins of the superior stratum no doubt is concerned with this stretch. So that the attention by Barry (31) that the

meniscus does not move is not supported on histological grounds.

Elastic tissue can be detected in all areas of the superior stratum and probably imparts a degree of resiliency to otherwise a relatively non-resilient structure. The elastic fibre component of the superior stratum apart from the fact that it is associated with stretch of the structure must be of considerable importance in repositioning the meniscus during masticatory movements. Since apart from its attachment to the condyle and incorporation of its lateral margin to the lateral capsule of the joint, no other structure imparts pull in a postero-superior direction. When elastic fibres are stretched they attain potential energy which when the stretching factor is released, in this case the spheno-menisus muscle, is converted into kinetic energy and no doubt the kinetic energy is of utmost importance in repositioning the meniscus in reflex masticatory movements.

Elastic tissue.

In some specimens examined the elastic fibre component appeared to be more numerous and thicker than others and this may be a functional adaptation to stress and strain throughout life. In the fetus at term no thick elastic fibres are seen except in the vicinity of the squamo tympanic fissure. It may be that in the process of ageing some of the collagenous fibres are replaced by elastic fibres and within limitations an increase in elastic fibre component is compatible with increased mechanical efficiency. The fact that collagenous fibres can be replaced by elastic fibres to an extreme degree is illustrated in Ehler-Danlos syndrome (32) where the collagen is replaced by elastin creating the so called "Indian rubber man." But as stated above a limited increase in elastic tissue need not be harmful or disadvantageous. However, in one specimen, the distribution of elastic fibres in the superior stratum of the bilaminar

zone was of such a degree as to be considered almost pathological (Ca. 5 Spec. 4 - 58 years.) and one could designate that hyper-elastosis was occurring in this area. Griffin and Sharpe (30) suggested that this condition be termed hyper-elastosis menisci. It is possible that this hyper-elastosis could interfere with function and certain cases of excessive movements of the mandible may be associated with hyper-elastosis of the mandibular menisci. Griffin and Sharpe (30) further suggested that hyper-elastosis of the menisci is an aetiological factor in certain cases of excessive excursive movements of the mandible and it is diagnosed by the clinical phenomenon of occlusal rebound. The striking elastic component of the meniscus is in the region of the squamo-tympanic fissure. It is fairly certain that in this area the elastic fibres are concerned with the retraction of the meniscus when closing the mouth. Since, apart from these fibres the only structure assisting in retruding the meniscus is a backward movement of the condyle. The retraction of these elastic fibres is probably very important in returning the meniscus to its resting position. It is almost certain that the dislocation of the mandibular meniscus is initially associated with an avulsion of the collagenous and elastic components of the superior stratum of the bilaminar zone of the meniscus from the squamo-tympanic fissure. Lansing (33) has shown that the elastin of the old is not the same as the elastin of the young. Usually with age elastic fibres fray and fragment, and develop an increased affinity for calcium salts. Indeed the difficulty of conservative treatment of traumatic dislocation of the mandibular meniscus is due to the difficulty in ensuring that reattachment of these fibres occurs in an acceptable anatomical position. Although this may be achieved sometimes by splinting the jaws. From a clinical point of view "clicking noise" (34) associated in certain patients when opening and closing the jaws may be of significance in the treatment of temporomandibular

joint dysfunction, whilst in other patients it seemingly has no significance since they do not exhibit symptoms. However in temporomandibular joint dysfunction when the dentition is corrected "clicking noise" disappears or is appreciably less. The explanation of "clicking noise" has been that the condyle and the meniscus move in disharmony and that the "noises" are caused by an abrupt translatory movement of the meniscus in opening and closing the jaws. This would mean that in the initial phase of mandibular depression the meniscus lags behind the condyle and similarly in the initial phase of elevation the meniscus lags in front of the condyle. Griffin and Sharpe (30) suggested that the terminology for this condition be strepitus menisci. In order to rationalise this statement it would be necessary to accept the proposition that the lateral pterygoid muscle is really two separate muscles. The superior fibres arising from the infra temporal crest of the sphenoid bone and inserting into the articular disc which has already been named in this thesis as the sphenomeniscus muscle. The inferior fibres arise from the pterygoid plate of the sphenoid bone and are inserted into the pterygoid fovea of the condyle. Then the explanation would be that these groups of muscle fibres are not acting synergistically. So that in opening the mouth contraction of the sphenomeniscus muscle is late. On the other hand in closing the mouth, relaxation of the muscle is delayed so that the elastic fibres of the superior stratum of the bilaminar zone of the meniscus can only assert their potential when this relaxation occurs. Thus strepitus menisci would be explicable on the basis of asynergy of the sphenomeniscus muscle and the lateral pterygoid muscle and this is no doubt due to a disturbance of proprioception. The asynergy referred to here is not to be confused with normal asynchrony of muscle fibres but means disharmonious action of two associated muscular masses.

Articular Cartilage.

The articular cartilage beneath the fibrous perichondrium of the condyle is somewhat unique. In most diarthrodial joints articular cartilage is freely exposed to the surface. It is alleged that articular cartilage wears gradually and that mitotic figures (35) are rarely observed and that wounds made in the articular cartilage do not heal for a considerable time; also it has a metabolic rate of the anaerobic type (36) and thus a low oxygen consumption which decreases with age. (37) So that it does not appear to possess a compensatory mechanism for wear.

Ham (38) thinks that the compensatory mechanism for wear is an increase in the intercellular substance associated with a relative proportion decrease in the number of cells and this of course could be the case in regards to the head of the condyle. Elliott (35) postulates a compensatory mechanism by amitosis. However it has been noted in this thesis at least part if not the whole of the articular cartilage is present up to old age and it is difficult to concede that cytomorphosis of cartilage cells which one observes is not evidence of growth phenomenon although at a very slow rate and the fact that wounds in articular cartilage do heal indicates at least some proliferative capacity. Again as regards the mandible there is a phenomenon of continuous vertical eruption of teeth and though this may be compensated by attrition never the less it also may mean that growth of the mandibular condyle occurs at a very slow rate throughout life. This may be the reason why a perichondrium is present and cartilage cells are not shed into the synovial fluid as occurs in other diarthrodial joints and a continuous though slow growth of bone persists throughout life.