TISSUE PRESSURE TECHNIQUE FOR THE RECOVERY OF PALATALLY IMPACTED CANINES

BY

D W EASTHOPE, B.D.S.

Department Preventive Dentistry
Faculty of Dentistry
University of Sydney
New South Wales
Australia

1985

COMPENDIUM

This thesis reviews the development of various techniques to recover palatally impacted canines and restore them to a normal eruptive position in the arch. Leading on from this is described a method not previously reported for palatal canine recovery, whereby pressure is applied to the soft tissue overlying the crown of the embedded tooth thus causing it to move intraosseously and erupt into the line of the arch.

This thesis is submitted as a requirement for the degree of Master of Dental Surgery and represents an original work of research into the subject of unerupted maxillary canines.

D W Easthope

ACKNOWLEDGEMENTS:

I would like to express sincere appreciation to Associate Professor Graham Craig for his initial encouragement to press on with this investigation and then the Australian Dental Research and Education Trust for financial assistance with the work on pressure measurement.

Grateful acknowledgement is also due to Professor N D Martin, Dean of Faculty of Dentistry Sydney University who encouraged me to present this thesis for the Degree of Master of Dental Surgery and Associate Professor Keith Godfrey for his continuous assistance in all aspects of its preparation.

Very valuable assistance has also been received from the management of "Applied Measurements Australia Pty Ltd" for their help in the selection of equipment suitable for my work on pressure measurement, and appreciation and mention is here expressed for their contribution to this section.

The preparation of this manuscript has been the work of Miss Julene Plahn to whom I direct sincere appreciation for her patience and skill.

Finally, but not least, my wife Marjorie and family have provided that necessary motivation when energies seemed to be flagging and the tasks insuperable.

DEDICATION

To my Mother and late Father

CHAPTER HEADINGS

1. Introduction

2. The Nature and Scope of Problems associated with Palatally Impacted Canines
   (a) History
   (b) Differential Diagnosis
   (c) Prevalence
   (d) The Need for Treatment
   (e) Classification of Impacted Canines

3. Mechanism of Tooth Eruption

4. The effect of applied force on teeth and supporting structures
   (a) Junctional Gingival Zone
   (b) Periodontal membrane and related structures
   (c) The mechanism of bone remodelling initiated by external pressure

5. Methods of Recovery of palatally impacted canines

6. The Statement of the Theme

CHAPTER HEADINGS

CHAPTER 1

INTRODUCTION

INTRODUCTION

Palatally impacted canines have been recognised for many years and have been positively diagnosed with the advent of radiographs. There are all degrees of impaction from the slightly crowded loss of space to horizontally placed or even inverted (Harris 1882, 420, discovered during medical dissection of a skull.)

Many methods of recovery have been practised and each has an application in certain degrees of impaction. Another approach is presented as the main theme for this Thesis and is referred to as the "Tissue Pressure Technique".

The cause for such malplaced canines has not been clearly defined. In fact there is considerable confusion as, on the one hand, loss of space is an apparent cause, yet, on the other, impactions are frequently associated with peg laterals which should give rise to more space (Chapman 1983). It is none-the-less true that adequate space is a prerequisite for successful alignment.

The mechanism by which the "Tissue Pressure Technique" functions cannot be stated with certainty and several suggestions are made. Further research is necessary to elucidate the process, although it is probably no different from other orthodontic forces.

Newton's Second Law of Motion states that "a body continues in a state of rest or uniform motion in a straight line unless acted on by some external force." If the eruptive force is considered to be the prime mover then orthodontic pressure is that "external force" which changes the direction of eruption.

One cannot help but feel an element of elation when a previously palatal canine emerges into the mouth in correct relation to its fellows, without the need for physical attachment to the crown.

Modification of the initial "Tissue Pressure Technique" is also suggested with two cases already completed whereby the impediment to eruption has been moved rather than direct force on the tissue overlying the canine.

To date several other practitioners have used the "Technique" with success and it is hoped that another contribution to the art and practice of Orthodontics has been made.

CHAPTER 2

THE NATURE AND SCOPE OF PROBLEMS ASSOCIATED WITH PALATALLY IMPACTED CANINES

(a) History

(b) Differential Diagnosis

(c) Prevalence

(d) The Need for Treatment

(e) Classification of Impacted Canines

(a) HISTORY

In dealing with this particular technique, it is of more than passing interest to look back into history of diagnosis and treatment. Angle in 1906 (161, Skiagraph), makes significant comment on the use of radiographs in diagnosing unerupted canines and of course this is equally true with all other covered phenomena either normal or pathological. His reference to surgical interference to facilitate the eruption of a single tooth, (Angle 1906, 566) by removal of bone or by bodily transport or retraction of a tooth carries the overtone of disapproval quoting as he does, the French author J Lefoulon (1841), who holds similar convictions. Angle did not single out actual palatal impactions for consideration, and one can only deduce his attitude as one of inactivity until eruption into the mouth, then movement by mechanical means to their appropriate position. (Angle 1906, 354).

Moving back twenty years or so to another author, Harris (1882, 420-453) we find no reference to the orthodontic recovery of palatal canines even though he has a long chapter on Orthodontics. One catches the stirrings of exploration into the fairly new field of tooth movement by the application of introduced external forces.

Barnes, writing in 1923, describes an excellent technique which varies little from present day methods using space opening, surgical exposure, packing, attachment by a unique inlay, and movement using a fixed lingual appliance. He had been using this method since 1918 and prior to this for the past twenty or so years he has used a cemented pin into the exposed canine. So it seems that about the turn

of the 20th century, palatally impacted canines were being successfully recovered by the methods differing little, if any, from those used now. In fact he cites two cases of labially placed incisors erupting nasally and these were torqued 160° and brought into occlusion using his 1918 method. One cannot but admire the skill of these practitioners and be made aware of their ingenuity in the face of more limited diagnostic facilities, and fewer materials such as direct bonding of attachment. (Gension & Strauss 1974).

Actual surgical transplantation of the impacted canine has been practised for many years. Phillips (1969) records the work of John Hunter (1771) describing his heterograft implant of a human tooth into a cock's comb, and also the allogeneic implant of a tooth from person to person. Phillips also records an autogenous transplant remaining vital after surgery. It seems as though this latter transplant is the only method being practised today.

Finally the technique of "tissue pressure" is a method reported by Easthope (1982) for recovery of certain palatally impacted canines, and is the subject of this Thesis.

(b) DIFFERENTIAL DIAGNOSIS

The prolonged retention of a deciduous canine is often the first indication of a malplaced maxillary cuspid although with regular radiographic examination the problem can be detected much earlier. Accurate diagnosis is essential to allow correct treatment planning. (Mulick 1981).

Palpation is perhaps the first diagnostic procedure using the tip of the forefinger to feel for an enlargement on the palate. (Williams 1981). The patient can frequently feel a tooth in the palate if firm pressure is used on the overlying soft tissue. This bulge can be detected as early as eight years of age. (Williams 1981).

Besides intra-oral palpation, the close inspection of a model is very useful to detect abnormalities of form. (Johnston 1969).

It is important to examine also the buccal sulcus remembering that the temporary canine has an eminence. If there is an obvious permanent canine eminence high up in the sulcus then of course the tooth is lying buccally not palatally.

Radiography has added a new dimension to the diagnostic field and in reading early literature one senses the frustration of guesswork (Harris 1884, 421) changing to the excitment of clear conviction, (Angle 1906, 161) with the introduction of this equipment. Now with more advanced equipment we can be even more sure of this diagnosis.

The simple intraoral periapical film can demonstrate the canine with an abnormal long axis angulation. Add to this a "tube shift technique" Fig 1, (either horizontally or vertically), and one can decide if the canine is nearer the film (palatal) or nearer the tube (buccal) than the bicuspid. When the tooth appears to move in the same direction in which the tube has been moved then the tooth is lying palatally to the adjacent teeth, and if moving in the opposite direction to the tube then it is lying buccally. (Bishara, McNeil and Osterle 1976), (Moore, Gillbe 1968).

When the film is placed in close contact with the palatal mucosa so that a palatally placed tooth is approximating the film surface, then in a tube shift exposure, the palatal canine appears stationary and a buccal one would appear to move provided the second film is located precisely where the first one was.

Using the larger occlusal film, a vertical exposure will demonstrate the canine lying palatally or buccally in relation to the first bicuspid and lateral. Hitchin (1956) stated that the vertex occlusal projection is the most useful in this technique, as opposed to the anteroocclusal and the true occlusal. Fig 2.

Anteroposterior extraoral view shows the angulation of the long axis relative to the lateral and central incisors and also the relation between the crown of the canine and the apices of the central and lateral. This combined with a lateral head radiograph taken at a 45° oblique angulation demonstrates the anteroposterior angulation of the canine. (Williams 1981).

The orthopantomograph (OPG) is of value to demonstrate anterior posterior angulation but is of no value to determine buccal or palatal location. (Mulick 1981).

The laminagraph, details the tooth with greater clarity, but this equipment is not necessary for diagnosis.

The ultimate diagnosis is made when the tooth is visible on exposure or eruption. However, the whole object of the investigation is to establish this pre-eruptively.

When visualising the tooth on a model, it has been found helpful to view the OPG X-ray upside down because it then corresponds to the upper model which is itself upside down when being examined.

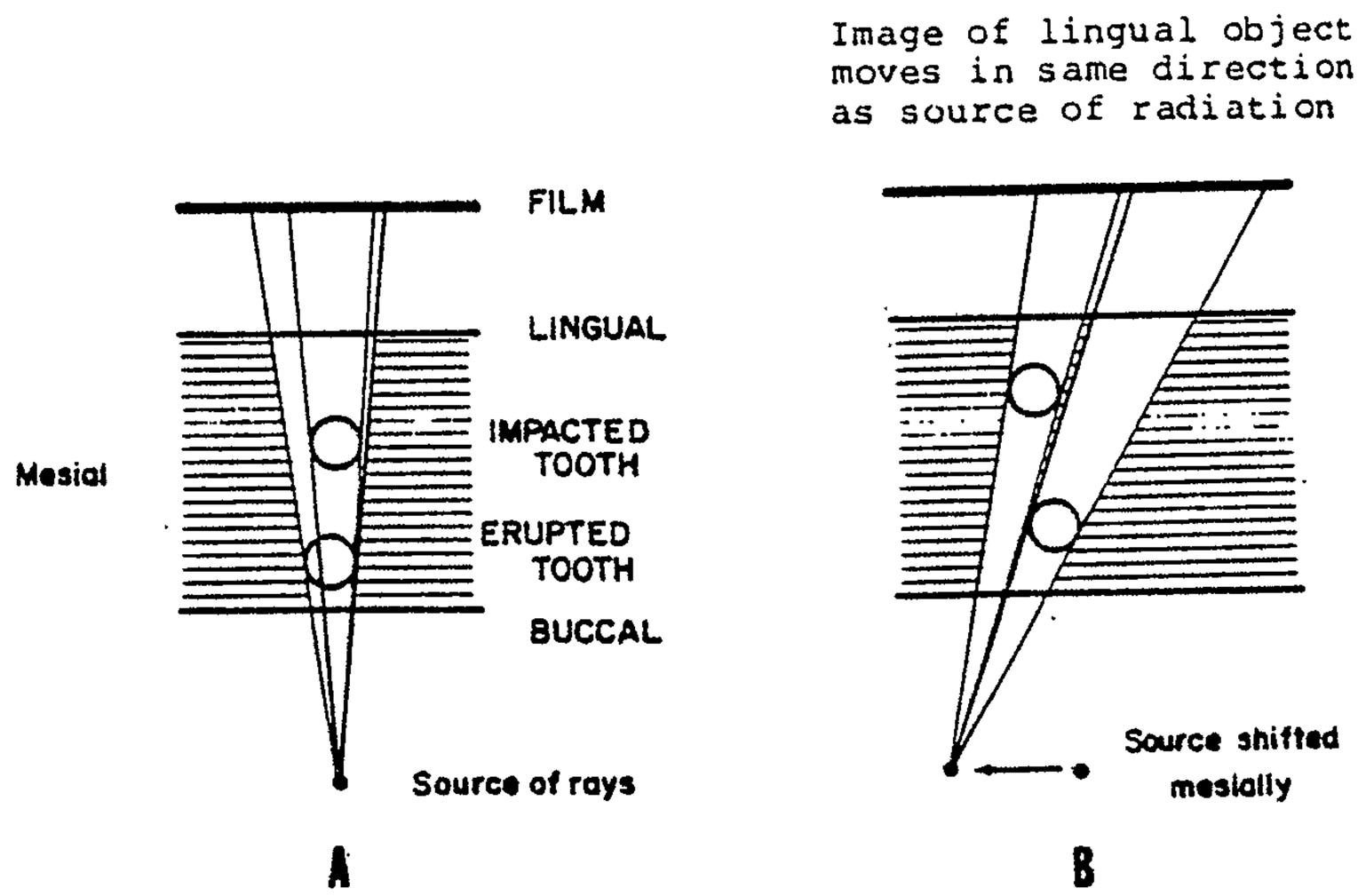

Fig. 1. Tube-shift technique to localize the buccolingual position of an impacted tooth.

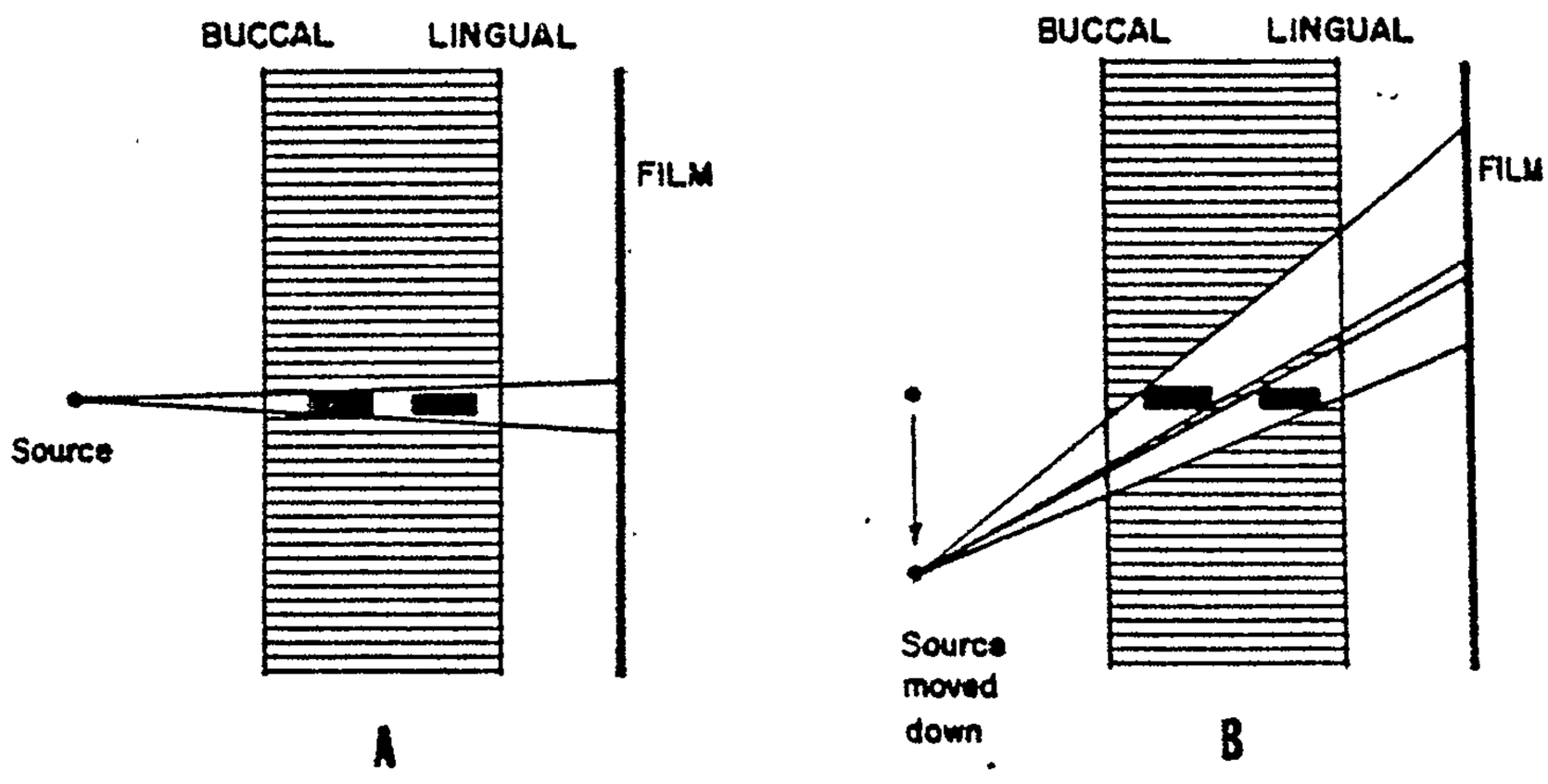

Fig. 2. Buccal-object rule to localize the buccolingual position of an impacted tooth.

FIGURE 1

(Bishara S E et. alia. 1976)

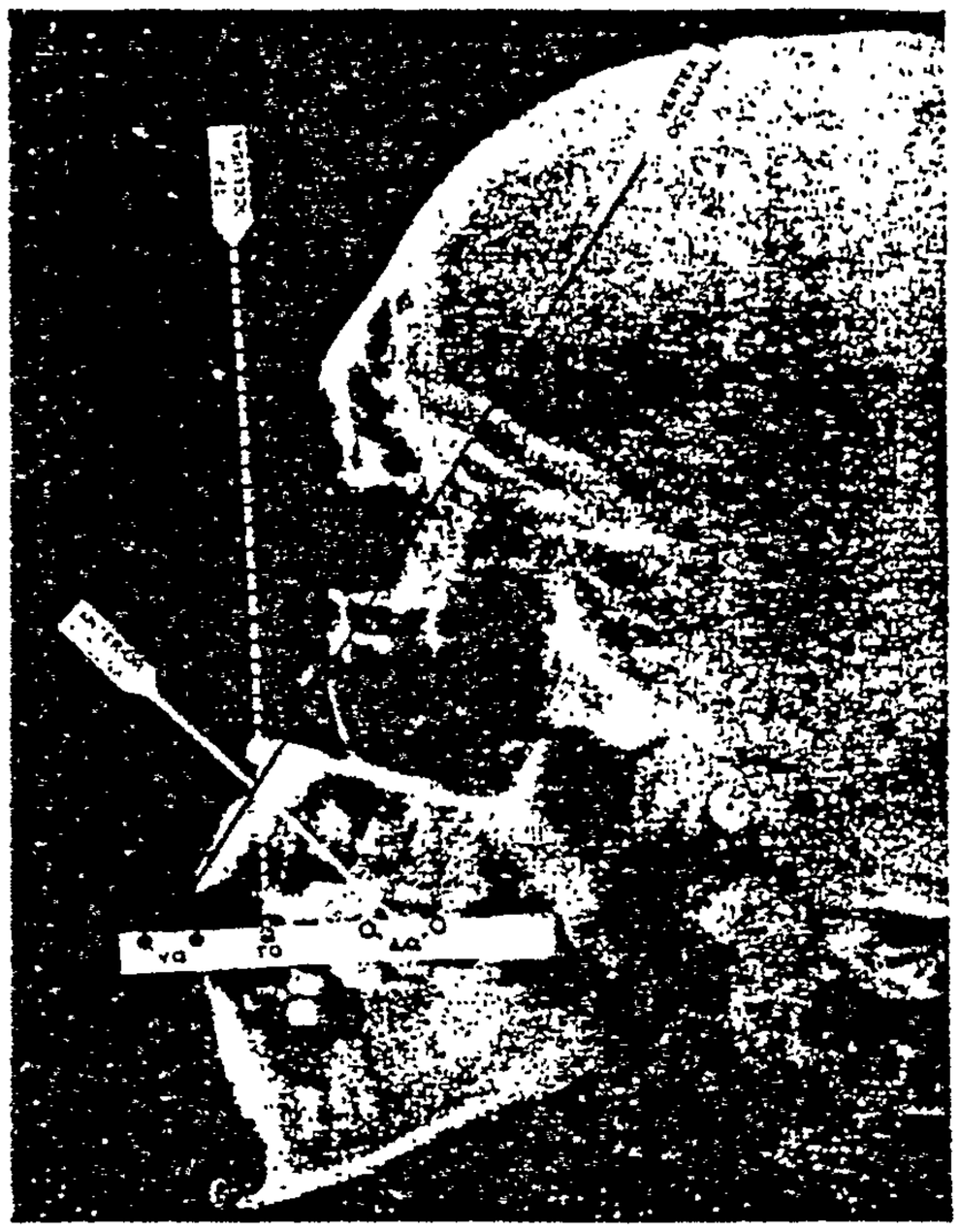

FIG. 1.—Lateral skull radiograph taken with intraoral cassette in the mouth. Two hypothetical bodies are shown as white circles, one being labial and one palatal to the maxillary incisors. Anterior occlusal beam—Two separate shadows both palatally placed = A.O. True occlusal beam—Similar shadows = T.O. Vertex occlusal beam—Shadow of labially placed body *labial* to plan of incisor and shadow of palatally placed body *palatal* to plan of incisor.

FIGURE 2, ILLUSTRATION OF VERTEX OCCLUSAL

View of upper anteriors used in deciding the buccolingual position of anteriors. (Hitchin A D 1956)

(c) PREVALENCE

Estimates of the incidence of impacted maxillary canines vary from 2% of 3,000 cases by Rhorer (1928) to 1.5% of 12,000 cases by Rayne (1969) and to 2.5% of 7,100 cases by McKay (1978).

Racially, impactions appear to be greater in those of Caucasian birth than those of Asiatic and a figure of 10 to 1 is quoted by Monteleus (1932).

The maxillary canine impactions exceed mandibular by ten to one. (Mulick 1981).

Seventy three percent of cases were found to be female and 27% were male. (McKay 1978).

Johnston (1969) states a ratio of 3:1 female to male and 50:1 palatally to labially impacted. He makes an interesting comment when he states: "I have never seen an impacted canine where serial extraction has been employed".

Salzmann further observes that "when the premolars and the permanent second molars erupt before the canines, the latter may become impacted." (Salzmann 1957, 258).

(d) THE NEED FOR TREATMENT

To treat or not to treat is a decision which must be made for there are certain situations suggesting non-interference. These would be the older patient with normal dental aesthetics, with no resorption visible in Xray and no soft tissue inflammation. (Moore and Gillbe 1968). It is possible for the upper first bicuspid to have erupted into the canine position and to have remained so without symptoms for many years. (Easthope 1982).

Patient selection will also colour decisions of this nature and this is further discussed under a separate chapter heading "Indications of Co-operation ". The recovery of impacted canines requires a degree of patience on the part of the operator, and co-operation from the patient so that instructions are intelligently followed.

In most cases the impacted canine presents a symptomless situation. Very occasionally slight pain has been reported (Angell, Wassow and Meister 1974) and (Azaz and Shteyer 1978) but this is met with infrequently. In the cases cited by Angell et. alia., an otherwise edentulous ridge had two unerupted and palatal canines meeting in the midline. Apparently the "burning sensation" was caused by pressure on the anterior palatine nerve toward which both canines seemed to be erupting.

In the younger patient it seems desirable to induce a normal eruption of a palatal canine because a retained deciduous tooth will not retain its aesthetics or usefulness, as a permanent one would, so that in the long term the patient is benefited by the orthodontic procedure.

One must not overlook the posibility of pressure resorption and Azaz et. alia. state that 14% of impacted canines or adjacent teeth experience resorption. This would add weight to a decision to attempt normality, if at all possible, using orthodontic procedures.

(e) CLASSIFICATION OF IMPACTED CANINES

Several descriptive analyses have been suggested to differentiate varying degrees of impaction and angulations of canine teeth.

The purpose for classification is to establish a prognosis which has the potential for success with a particular technique selected.

(a) Moyers (1973) makes a very simple breakdown into just two groups:

1. Impacted
2. Ectopic and impacted

He limits these to the following definitions:

Impacted is used to describe those canines lying in their true position in the arch but with insufficient room for them to erupt.

Ectopic describes all other abnormal positions of the unerupted cuspid.

The "tissue pressure technique" is applicable to group 1 above (Easthope 1982).

(b) Acherman and Field (1935) use the following:

1. Horizontally (a) Palatal
   (b) Mid alveolar
   (c) Labial
2. Vertically (a) Above apex of adjacent teeth
   (b) Below apex of adjacent teeth

(c) Howard (1972) classifies impacted canines into four groups with particular relation to incisor resorption. Four Xray views are used to assess location; and proceed to classification using these Xrays.

1. Intra Oral
2. Vertex Occlusal
3. Cephalometric lateral skull film
4. Posteroanterior skull film

Using these Xray pictures the following four groups are designated:

Group 1: Vertical - the canine approximates the vertical in all films;

Group 2: Horizontal - canine approaching horizontal in all films;

Group 3: Lateral Horizontal Group - lateral film shows vertically placed canine. Antero-posterior film shows horizontal inclination.

Group 4: Unallocated group - not clearly 1 or 2.

Note: Group 3 shows those canines in correct antero-posterior inclination but malplaced sagittally.

The tissue pressure technique would be successful in Howard's Group 1 and would be questionable in Group 3. It would not be applicable in Groups 2 and 4, the reason for this is the need for the crown of the canine to be in line between the advancing pad of the appliance and the space in the arch between the second bicuspid and the lateral incisor, or in the case of extraction, between the second bicuspid and the lateral incisor.

(d) Hitchin (1956) describes seven locations as distinct for the abnormal canine:

1. Cuspid palatal near the gingival margin.
2. Cuspid palatal away from the gingival margin.

3. Cuspid labiobuccal.
4. Cuspid in the arch of the roots.
5. Cuspid with the crown palatal and the apex buccal or above the buccal roots of the bicuspids.
6. Rare impactions.
7. Edentulous cases.

The "tissue pressure technique" would be applicable in Group 1 above.

(e) Rayne (1969) includes a treatment suggestion in this classification dividing the tooth into three regions. (Fig 3)

1. The tip of the crown.
2. Junction of crown and root.
3. Apex of the root.

Further, he lists a degree of severity between 1 and 4 for each of these three regions.

RAYNE'S GRADING OF SEVERITY

1. Position of Root Apex

Grade 1 Vertically above the first premolar root

Grade 2 Vertically above interdental space between first and second premolars

Grade 3 Vertically above second premolar

Grade 4 Posterior to Grade 3 or anterior to Grade 1

2. Height of Cusp of Canine

Grade 1 At level of necks of incisor teeth

Grade 2 Between Grades 1 and 3

Grade 3 At level of apical of incisor roots

Grade 4 Above incisor roots

3. Obliquity

Grade 1 60-85 degrees to occlusal plane

Grade 2 45-60 degrees to occlusal plane

Grade 3 30-45 degrees to occlusal plane

Grade 4 0-30 degrees to occlusal plane

4. Buccal Displacement

Grade 1 Related to lateral incisor

Grade 2 Not applicable

Grade 3 As Grade 1, but above reflection of sulcus

Grade 4 Cusp approaching midline

5. Palatal Displacement

Grade 1 Related to lateral incisor

Grade 2 Related to central incisor

Grade 3 As Grades 1 and 2, but high in the alveolus

Grade 4 Partial transposition

Proposed Treatment

Grade 1 Exposure without traction sufficient

Grade 2 Provision of silver cap and light traction

Grade 3 Traction with screw or wire snare

Grade 4 Traction not indicated; either remove the canine tooth or leave in situ

Using Rayne's classification, the contraindication for orthodontic recovery is suggested when the apex of the root lies over the roots of the first molar (Fig 3). In applying the "Tissue Pressure Technique", the cut-off point would be at Grade 2, because the crown is not accessible in Grade 3 and 4 from the lingual, and pressure on the crown would be negated by impaction against the lateral or central incisor roots.

One purpose for classification is to help the clinician to diagnose and than decide on the course of treatment appropriate to the case and to be confident to obtain predictable results. Further comment will be made when amplifying the "Tissue Pressure Technique" which is the subject of this paper. This technique, as with other procedures, has certain limitations and the cut-off point can be established by using classification to indicate potential success or failure.

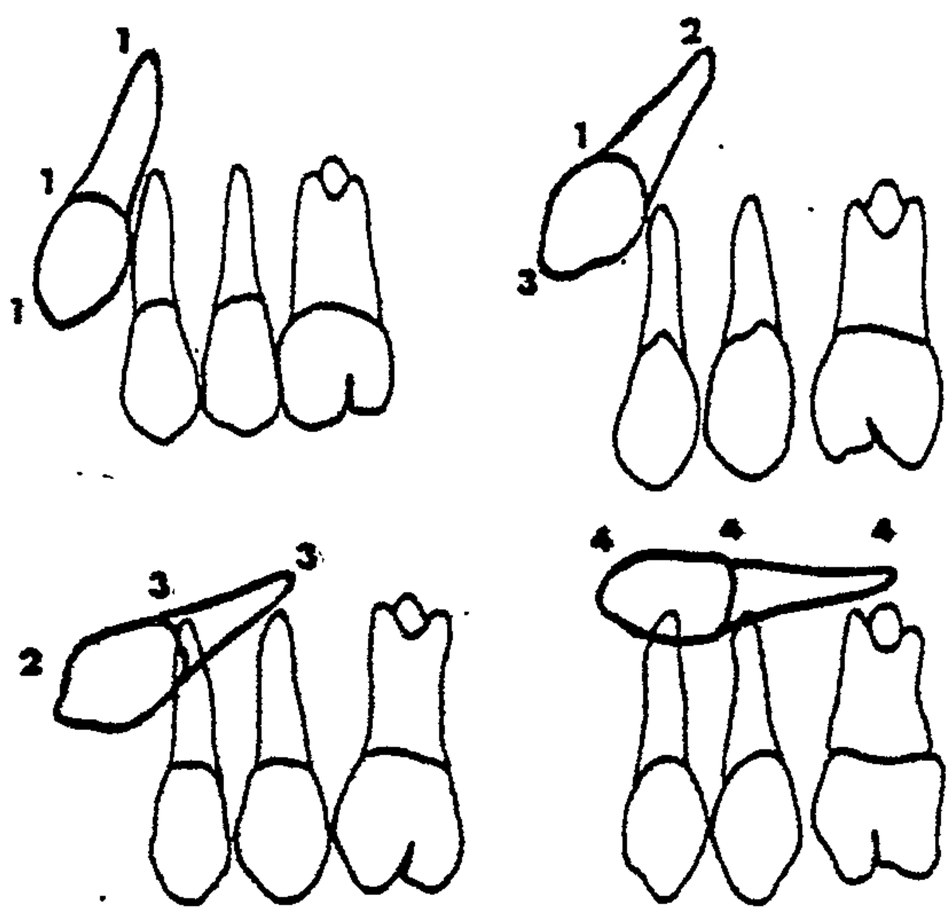

Fig. 5.—Lateral diagram of arbitrary grades of severity. The numeral at the apex refers to the grade of apical position; the numeral at the neck of the tooth refers to the grade of obliquity; the numeral at the cusp refers to the grade of cusp height.

FIGURE 3

Varying positions of malplaced canines with degrees of severity numbers 1 - 4.
(Rayne 1969)

CHAPTER 3

MECHANISM OF TOOTH ERUPTION

MECHANISM OF TOOTH ERUPTION

The cause of and the force producing eruption has so far eluded researchers and still remains somewhat a mystery. That there is more than one mechanism seems to be evident (Massler and Schour 1941). Again writing in 1967 Melcher and Beersten state that "the nature of the force(s) that are responsible for moving the teeth axially during eruption are not clear."

The word "eruption" needs to be understood for it can mean the appearance of a tooth into the oral cavity, although this is usually referred to as "emergence" or more broadly it can mean the movement of the tooth both intra-osseously before appearance and afterwards throughout life as antagonist loss and attrition allow continued movement.

"Unimpeded eruption" is that movement of a tooth toward occlusion but prior to contact with the antagonist in the opposing arch. "Impeded eruption" on the other hand is that movement which occurs after contact with the antagonist, this movement is greatest in continuously erupting teeth.

Growth of the tooth must be distinguished from eruption, being confined to the laying down of the cellular elements and its calcification. (Massler and Schour 1941). Eruption, on the other hand, brings the calcified tooth into occlusion with its fellows to produce a masticatory mechanism.

Six stages of eruption are described by Massler et. alia. (1941):

1. Preparatory stage (opening bony crupt)
2. Migration toward oral epithelium
3. Emergence of crown tip into oral cavity
4. First occlusal contact
5. Final occlusal contact
6. Continuous eruption

Berkovitz (1975, b 102, 103, 114) describes three phases of eruption:

1. Pre-eruptive
2. Pre-functional
3. Functional

To explain the mechanism of eruption Massler et. alia. 1941 (554) lists seven potential sources of force which may or may not contribute to tooth movement.

1. Growth of the root
2. Growth of the dentine or pulpal constriction
3. Growth of periodontal tissues
   (a) Periodontal membrane
   (b) Alveolar bone
4. Pressure from muscular action on alveolar process
5. Resorption of alveolar bone
6. Pressure from cellular proliferation
7. Pressure from vascular bed
   (a) Pulp
   (b) Periapical tissue

Of these only the last two have some serious evidence for their existence. Evidence for this last theory is shown by measurable differences in intra-pulpal blood pressure and the supra coronal blood pressure. (Van Hassel & McMinn 1972).

This emphasises the fact that there are two forces, an eruptive one and a retardative one. When the second is greater than the first no eruption takes place. (Berkovitz 1975, b). Using a rat and a rabbit as study animals, the retardation force necessary to prevent eruption was 5gms. and 7gms. respectively. (Berkovitz 1975, b).

One other factor mentioned by Massler and Schour (1941) is the relationship between Vitamin A deficiency and magnesium deficiency, both having a delaying effect on eruption. This of course does not explain the force mechanism for they are extrinsic factors as with hormonal changes from the anterior pituitary gland. (Kusner, Machaeli and Weinreb 1973).

Looking more closely at the periodontal membrane, two factors are evident. The first is the role of collagen, and its potential for contraction within the periodontium. (Berkovitz 1975, b). This theory presupposes a high turnover rate, demonstrated by Magnusson (1968), and Berkovitz (1975, b) and a high contraction of collagen in the periodontal ligament. The force is produced by crosslinking of the macromolecules (Thomas 1967 and Berkovitz 1975, b). An interruption of this process does reduce impeded and unimpeded eruption (Shoshan and Finkelstein 1968, Berkovitz 1974).

Vitamin C is also essential in the process of eruption (Barnes and Kodicek 1972, Berkovitz 1975, b) and the ascorbutic animal does demonstrate a reduced impeded and unimpeded eruption rate. (Berkovitz 1974)

The second factor involves the tension within the ligament produced by the contraction of fibroblasts, (Ness 1967, Berkovitz 1975, a). Ness (1970) also states that more fibroblasts are produced at the base of the erupting tooth than at the oral end.

The gubernacular cords joining the follicles of teeth to the oral mucous membrane have also been considered as potential sources of force to erupt the tooth. During eruption these cords reduce in length and increase in width with a formation and widening of a central canal. (Scott and Symons 1971). An association with the degeneration of connective tissue overlying the eruptive tooth could reduce the retardation force thus allowing the eruptive force to produce tooth movement. (Berkovitz 1975, b).

Cell proliferation also has significant evidence to support its involvement in tooth eruption:

1. Increase mitosis at the apex (Sicher 1942)
2. Circadian rhythm of cell proliferation combined with circadian eruption of teeth (Mantell 1973)

This force presupposes a base on which to operate so as to prevent bone resorption and it is postulated that a "cushioned hammock ligament" satisfies this, a fact claimed to be demonstrated by Scott (1953). Further when tooth eruption was prevented concertina-like folds were evident in the enamel and subjacent dentine of the basal region (Schour and Van Dyke 1932) thus suggesting force from beneath from cell proliferation.

Irradiation of the root apex cells causing reduced proliferation also results in a reduced eruption rate. However, irradiation could affect other tissues and thus other factors could be involved. (Medak 1952).

Vascularity and tissue fluid pressure have been suggested even as early as 1900 (Constant) and by Bryer (1957). However, the measurement of the exact change of pressure following sympathectomy and severance of the inferior dental nerve has not been demonstrated, so results of change in eruptive rate are inconclusive. (Berkovitz 1975, b).

It must be noted, however, that there is a measurable movement of teeth pulsating with the arterial pulse rate, a movement in the order of 0.4 um. (Korber 1970).

Turning now to the "Functional Phase" of eruption, it is seen that when a human tooth reaches occlusion rapid eruption either ceases or is prevented. But when the antagonist is removed, eruption again usually proceeds. This eruptive phase does seem to be associated with increase in cementum formation. (Boyle 1955). Again it is difficult as in all other theories of eruption to separate cause from effect.

Mesial drift must also receive attention and is seen in the early stages of eruption when the crypt moves laterally with bone resorption and bone deposition on the appropriate lateral walls. (Manson 1968, Brash 1928). There could be a bio-electric effect in this process (Bassett 1971).

The post-eruptive mesial (usual) migration of upper human canines and molars has been recorded as 3.07mm and 3.95mm respectively (Lebret 1967). Occlusal force and surrounding musculature have been suggested as causes but these appear to play little part in the movement, as teeth still drift when these forces are removed. (Moss and Picton 1970), and a third force is suggested, ie; the contraction of the trans-septal fibre system.

Another cell is described, the "Myofibroblast" (Deporter 1980) one exhibiting many of the charactaristics of smooth muscle such as contractile filaments and crenated nuclei, and the ability to produce a contractile force. These cells are present in wound repair and it is postulated that they exist in periodontal ligament. However, their existence still awaits final confirmation. It seems as though this would explain tooth eruption better than other theories which have been suggested.

To sum up, it seems clear that no single theory completely satisfies all evidence of tooth eruption and even if one or more factors are removed eruption continues albeit at a different rate. One major difficulty is in separating cause and effect and much of the research seems to exhibit conflicting results. (Berkovitz 1975, b).

CHAPTER 4

EFFECT OF APPLIED FORCE ON TEETH AND SUPPORTING STRUCTURES

(a) Junctional Gingival Zone

(b) Periodontal Membrane and Related Structures

(c) The Mechanism of Bone Remodelling Initiated by External Pressure

THE EFFECT OF APPLIED FORCE ON TEETH AND SUPPORTING STRUCTURES

(a) JUNCTIONAL GINGIVAL ZONE

The periodontal membrane is composed of cells and extracellular ground substance and fibres. The principal cell is the fibroblast with its fibres of collagen embedded in the ground substance. The fibroblast is capable of both production and degradation of collagen. As well, there are osteoblasts and osteoclasts associated with bone and cementoblasts associated with cementum. The osteoid cells and the fibroblasts are fundamentally involved in tooth movement which necessitates bone removal and deposition and collagen degradation and synthesis. A third group of cells not obviously involved in tooth movement, are epithelial cell rests of Melazzez, macrophages and undifferentiated mesenchymal cells. (Squire and Hill 1980, 381-3).

The periodontal membrane is the primary supporting tissue of tooth and associated with this is the gingiva particularly at the gingival crest. The mucosa can be divided into two distinct types: the attached gingiva covering the teeth from neck to apex, characterised by keratinized squamous epithelium and dense collagenous lamina propria attached firmly to periosteum, (Fig 4) and secondly, the alveolar mucosa with no keratinized epethelium and loose collagen bundles with many elastic fibres and no firm connection to periosteum. Of particular importance is that part of the gingiva which emerges with the periodontal membrane, the so-called "Junctional Gingival Zone."(Fig 5).

It would seem that this zone is formed by the union between the oral and the odontogenic epithelia on emergence of the tooth into oral cavity. (Ten Cate 1980, 258).

This junction of the two diverse types of tissue, ie; periodontal membrane and gingival epithelium, seems to be the area most affected by surgical interference, a necessary practice on occasions in the recovery of buried canines. Not all canines can be accessed without first exposing but where this can be avoided it is an advantage in the establishment of healthy gingiva.

Surgical exposure of buried teeth to facilitate eruption is carried out in two different ways, radical and conservative (Heaney and Atherton 1979). The former is characterised by the complete removal of the soft (and hard) tissue covering the tooth, while the second has the tooth exposed for the purpose of mechanical attachment and then recovered by the flap of tissue, the connection being brought through the mucosa to join onto some external anchorage.

Radical exposure of a tooth with the loss of follicular tissue leaves a tooth more susceptible to periodontal problems because of the absence of the junctional gingival zone, formed only by the fusion of follicular tissue and attached gingiva so that the tooth exhibits three distinct pathological conditions.

1. Gingival recession
2. A narrow and non-functional buccal gingiva zone
3. Chronic inflammatory response in the affected oral mucosa.

This problem is much more frequent than when the second and more conservative exposure technique is practised (Odenrick and Modeer 1978), although even here there is usually elongation of the tooth, and the flap scar tissue is always visible. (Heaney and Atherton 1979).

In fact, Heaney suggests that excision should be confined to palatal exposures although Odenrick et. alia. (1978) consider that even these are exposed to higher risk of pathological change than with the flap technique exposures. (Wisth, Morderval and Bie 1975).

Periodontal involvement is a natural outcome of the situation initiated by the loss of junctional gingival zone along with the deposition of plaque in the trough.

More extensive supportive change has been reported including ankylosis, discolouration , devitalization, periodontal membrane hypertrophic response, with 50% loss of periapical fibres. (Mulick 1981).

It is now considered that anykylosis and possibly resorption are more likely to occur when vigorous elevation of the canine within the socket is carried out. Such procedures are now not practised. (Personal communication Dr P Mouser, Dept Oral Surgery, Faculty of Dentistry Uni Syd).

However, it would seem that such acute situations are not the norm and with reasonable procedures, well-managed and well-observed, they would be avoided.

If surgical exposure can be avoided there is reduced risk of periodontal involvement. The tissue pressure technique described in this thesis maximises, at least for some palatally placed teeth, the chance for normal eruption, and reduces the need for surgical interference, with its consequent potential gingival pathologies.

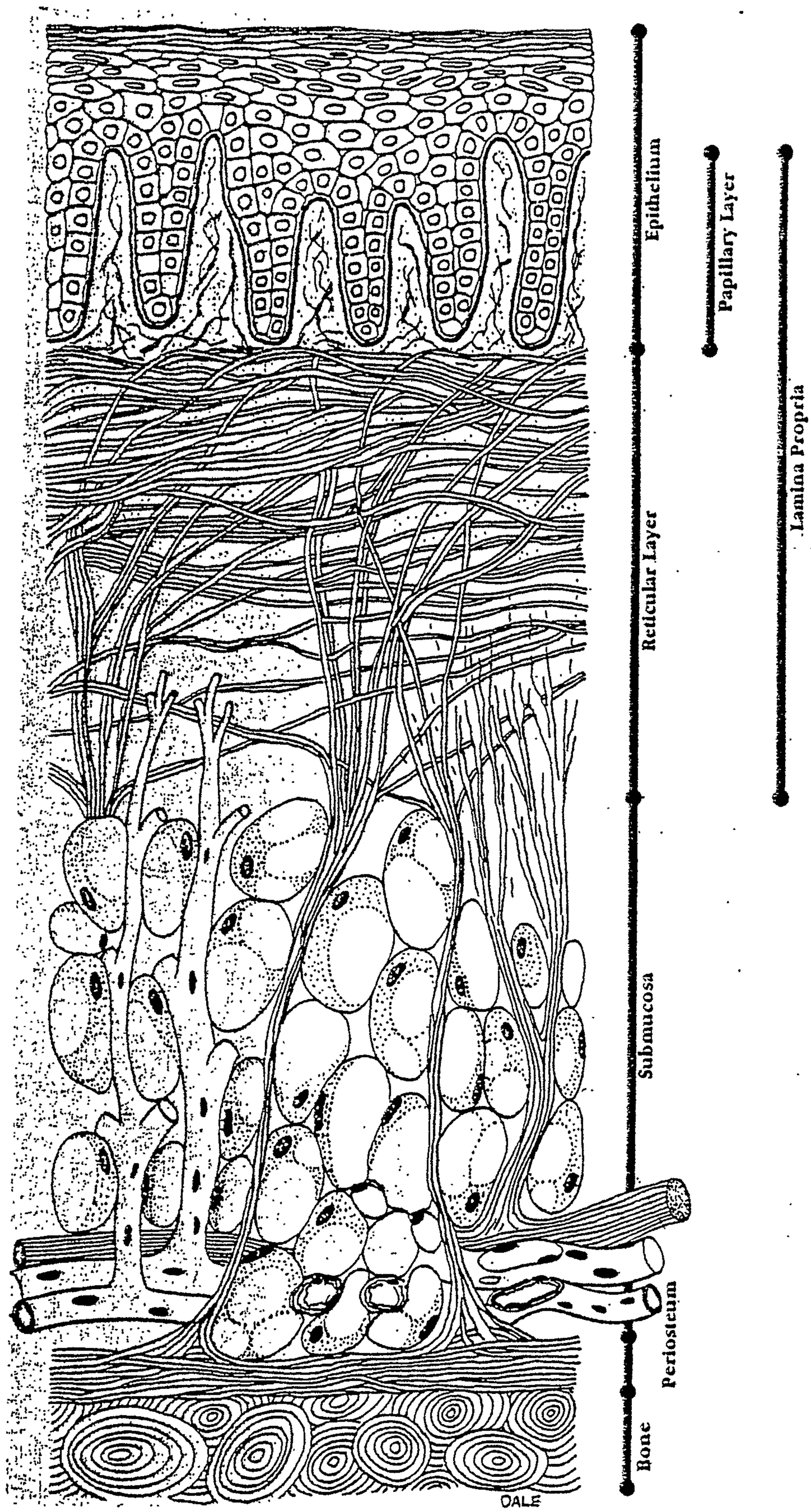

FIGURE 4

Squamous Epithelium firmly attached to periosteum by dense collagen fibres (Ten Cate 1980, 345)

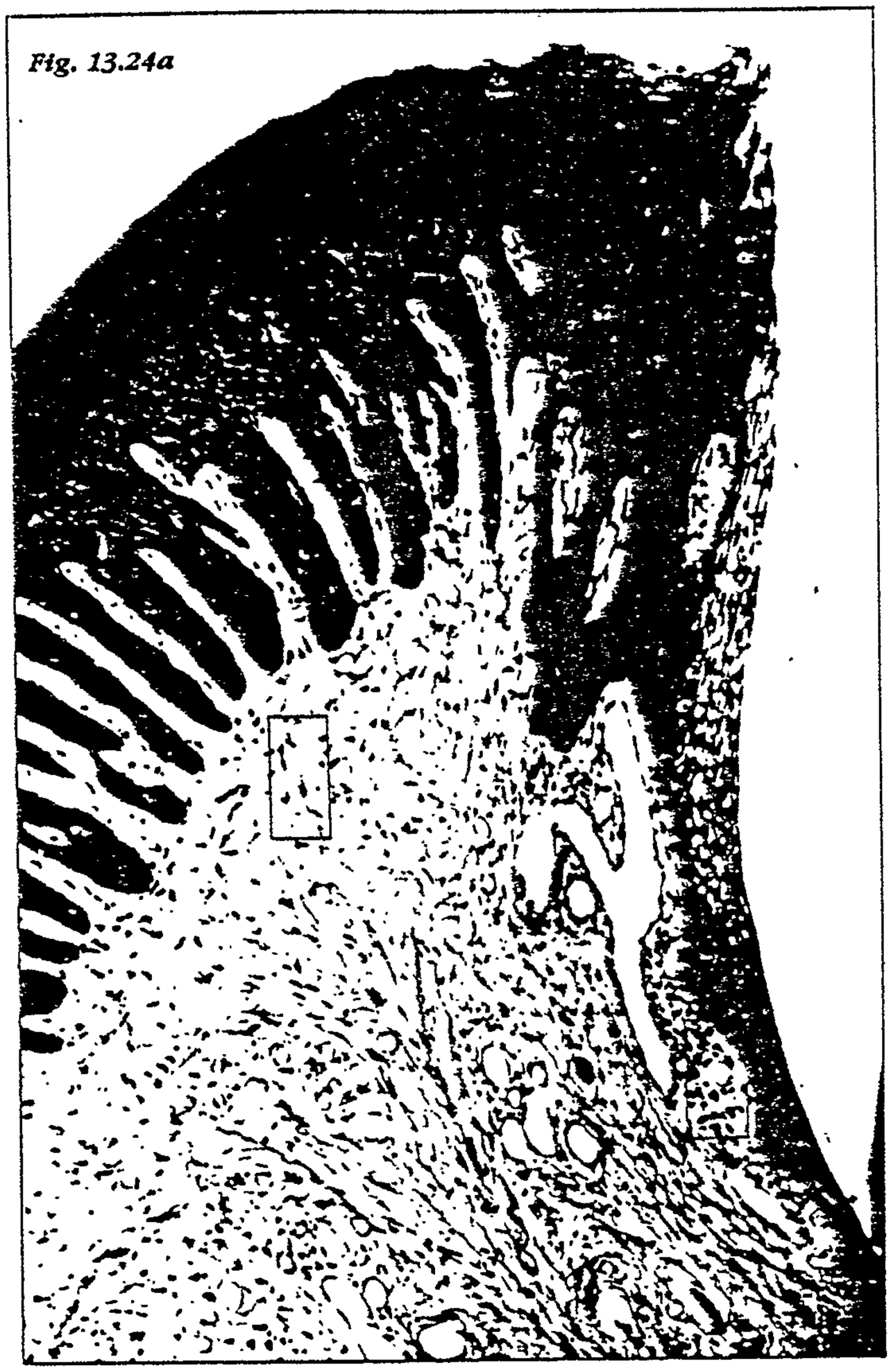

FIGURE 5

Junctional Gingival Zone

(Ten Cate 1980, 262)

(b) PERIODONTAL MEMBRANE AND RELATED STRUCTURES

When forces are placed on teeth the initial response is compression of the periodontal membrane. This of course happens during mastication and in the normal dentition no tooth movement results, ie; no movement which could be said to be orthodontic.

Slight tooth movement has been demonstrated and very nicely described by Bayliss, (1918) when he wrote: "Vital phenomena being essentially dynamic, the study of physiology consists in the investigation of changes".

Orthodontic movement, on the other hand, repositions a tooth or group of teeth beyond this physiologic change. The minimal force required to produce displacement is shown to be between 0.9g to 1.2g (Lear, Decou and Ng 1974). However, the optimum force for tooth movement according to Burstone and Groves (1960) is 50 to 75gms per quadrant, representing 13 gms/mm^2. The amount of movement in a 27 day period varied from 0.0 to 3.3mm.

Following periodontal compression on the leading face and tension on the following face there appears bone resorption and bone deposition respectively. Continuous pressure on the periodontal membrane produces a cell-free zone which prevents the work of the osteoclasts in their bone resorption process, and this delays tooth movement until this hyalinized tissue has been removed. (Reitan, 1964). This process is known as undermining resorption, and because of this, light forces are more to be desired than heavy ones. In fact, it has been demonstrated that within physiological limits the variation in force did not give variation in movement except that with very heavy forces (above 400g) no movement resulted.

(Reitan, 1964. Burstone and Groves,1960)

Looking more closely at the bone on the side opposite to the applied force and the applied force side, it is found that besides resorption on the former there is deposition on the latter. (Utley 1968). This deposition of bone on the advancing surface demonstrates the evidence of an intact lamina dura during orthodontic tooth movement. The same author describes a rearrangement of bony trabeculae deeper in the bone when varying forces are applied to the teeth, a phenomenon postulated by Wolff in 1892. This law states "the structure and shape of a bone become progressively adapted to the sum of all the changing mechanical forces exerted on it" (Moyers 1973, 96)

Forces even as light as 50gms are sufficient to cause small tooth resorption on the pressure side, a resorption which does not regenerate. (Reitan 1969, 197)

FIGURE 6

(Ten Cate 1980, 273)

(c) THE MECHANISM OF BONE REMODELLING INITIATED BY EXTERNAL PRESSURE

Bone remodelling requires the loss of bone in areas of pressure and its deposition in areas of tension. To allow a tooth to move through the alveolar process, orthodontic force applied to teeth is transmitted to bone via the periodontal membrane and this force bends the bone, with the resultant production of electric charge, positive resulting in bone removal, and negative or neutral, in bone formation. It is thought that osteoblasts are attracted to negative charges and osteoclasts to positive. (Mostafa, Weaks-Dybuig and Osdoby 1983). This application of electric current to bone actually accelerates orthodontic tooth movement. Thus it seems that piezoelectric response to bone bending as a result of applied orthodontic force may be the cellular first messenger. (Davidovitch, Finkelson and Steigmen et alia 1980)

In all orthodontic movement the transmission of force is via the periodontal membrane making the mechanical connection between the tooth and the bone. However, in the "tissue pressure technique", the subject of this paper, force is applied to the surface of the mucous membrane and transmitted through the periosteum to the bone. The clinical evidence fits the above description, for bone is removed on the buccal plate of the alveolar process and laid down on the lingual plate subsequently forcing the capsule of the unerupted tooth away from the target area. This is indicated by a depression in the alveolar process caused by the advancing plastic pad covering the target area. This apparently produces hydrostatic pressure within the capsule or actual pressure on the

surface of the unerupted crown, thus transmitting a force to the labial aspect of the alveolar process. Up to this date, no experimental work appears to have been done to measure any variation of pressure within the dental crown capsule. Not only may electricity be involved in bone remodelling but there seems also to be a chemical mechanism stimulating cell activity or rather marshalling appropriate cells to either remove or lay down bone. Davidovitch et alia (1980) report that cyclic adenosine monophosphate (CAMP) concentration is measurably higher in alveolar bone extracts taken from orthodontically treated cats, than in their untreated fellows. This increase in CAMP could be secondary to the inflammatory process produced by orthodontic pressure and is a result not cause.

A second effect of increased CAMP level is increased collagenase activity, an enzyme known to dissolve collagen in connective tissue.

The diagram set out by Mostafa et alia (1983) illustrates the two mechanisms which could explain bone remodelling during tooth movements. (Diagram 1)

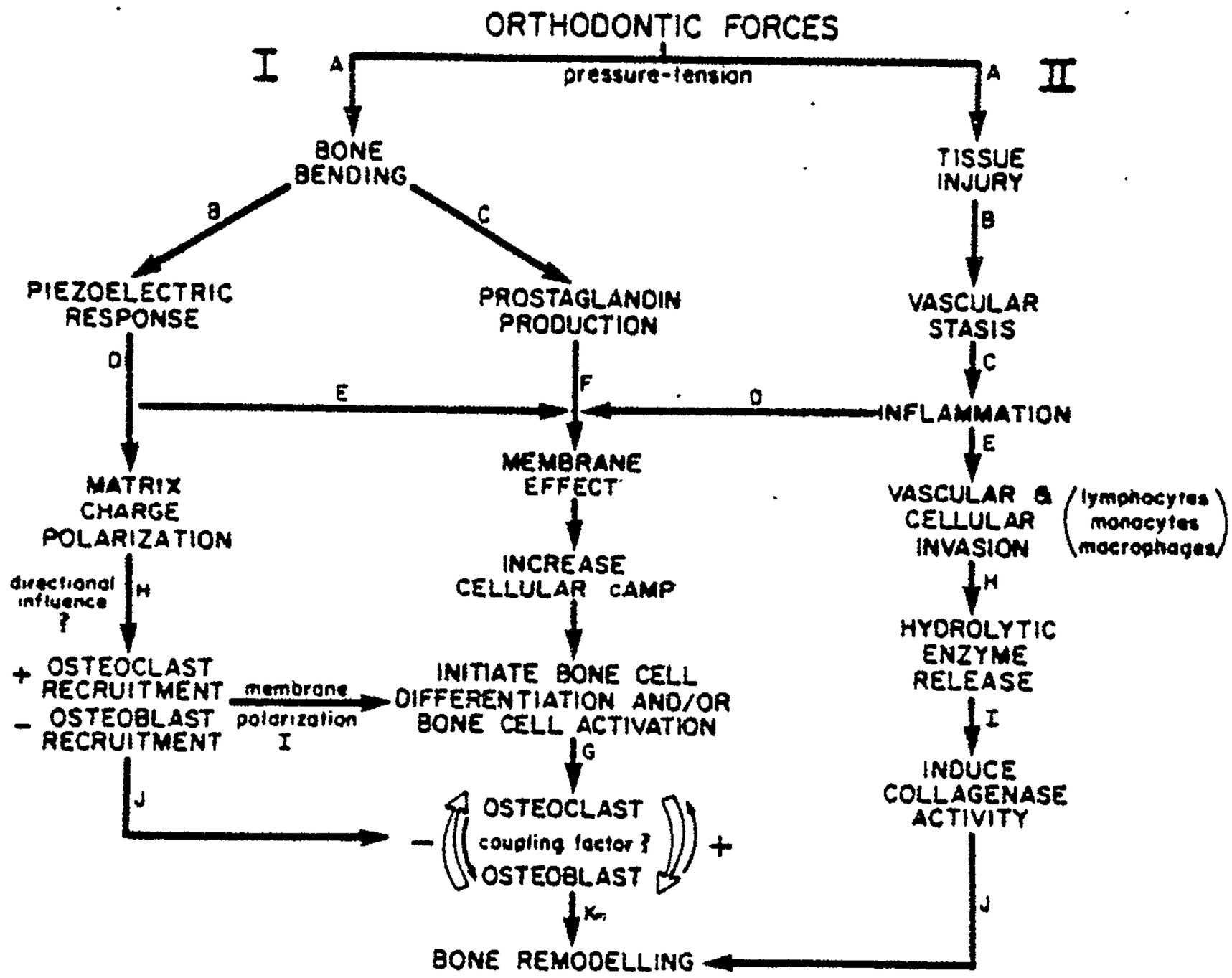

Fig. 2. Flow chart depicting two possible biologic pathways generated by orthodontic forces. Pathway I represents what we believe to be the major biologic response to orthodontic force; pathway II represents a secondary effect. See text for specific details.

DIAGRAM 1

(Mostafa, Weaks-Dybung and Osdoby 1983)

CHAPTER 5

METHODS OF RECOVERY OF PALATALLY IMPACTED CANINES

METHODS OF RECOVERY OF PALATAL CANINES

There are three distinct methods of recovery.

1. Those methods relying on physical attachment to the tooth in question, with emphasis on the word "attachment". This presupposes that the crown of the tooth is accessible to the operator to make the attachment which he considers appropriate under the circumstances. This availability is either after eruption into the oral cavity or as a result of surgical exposure by the removal of soft tissue or both soft tissue and bone.

2. Passive removable appliances which act as space maintainers after surgical exposure and intended to facilitate natural eruption.

3. A technique which brings pressure to bear on the soft tissue overlying an unerupted (into the oral cavity) tooth and thus inducing the tooth to move intra-osseously and in the direction which will allow it to erupt into the line of arch in normal occlusion, designated by this author as the "tissue pressure technique". (Easthope 1982)
   It is to be noted that in this method there is no physical attachment to the tooth as such, although it is evident that a force is transmitted to the tooth by virtue of its contact with the overlying soft tissue or bone.

GROUP 1 - MECHANICAL ATTACHMENT TO TEETH

5.1.1. Wire ligature passed around the gingival margin beyond the point of maximum diameter, twisted together and tied to an arch wire. (Angle 1906, 354).

This method is supported by Bishara et alia (1976), but opposed by Mulick (1981) who points out that damage can occur to the periodontal membrane.

5.1.2. Jack-screw attached reciprocally to the canine on the opposite side and anchored to a lateral on the same side by a wire extension. This will move the palatal canine but is only applicable after emergence (Angle 1906, 582).

5.1.3. Orthodontic band cemented onto the crown of the surgically exposed cuspid with a previously attached hook or eye to which a wire or a gold chain can be attached to transmit force from an arch wire utilising a wire attached on the lingual of molar bands by tubes. This lingual arch (0.5mm) has a large omega shaped loop which when tied back to the molar tube tends to move the anterior section away from the soft tissue thus pulling on the buried cuspid to which it is tied. Becker and Zilberman (1978) describes a modification of this technique using a removable upper bite-opening appliance prior to the eruption of the canines.

5.1.4. An eyelet can be attached to the crown by drilling a hole into the enamel and screwing in a self-tapping screw-eye. This can then be tied to a labial arch extension coming from the distal of the molar tube and carried through the canine space onto the palatal. This will elevate the cuspid and then move it labially into the arch. (Begg and Kesling 1971)

5.1.5. A bracket attachment is cemented to the crown, using an etch bonding system and then tied by means of stainless steel or gold chain to an arch wire. (Rubin 1976).

5.1.6. Removable appliance to move a palatally erupting cuspid by means of activated springs pressing on the lingual of the tooth. (Salzmann 1966, 825)

5.1.7. Cuspid crown exposed and a crown form cemented onto the crown and allowed to remain until the tooth has erupted sufficiently to move into the arch with conventional methods. (Salzman 1966, 823).

5.1.8. Removable appliance with an expansion screw appropriately angulated to effect movement of an already emerged cuspid. (Gizewska, Kaliyowski and Micheewicz 1973)

5.1.9. Stangle (1976) describes a technique combining extra-oral traction to maintain incisor stability. As well, a cantilever wire is attached to the

two upper molar bands which are joined themselves by a 1.0mm palatal wire to prevent rotation. This cantilever wire has an eye at the frontal end through which an elastic ligature is passed from a lingual button cemented with Durabon cement to the surgically exposed crown of the cuspids and to the first molar brackets. Thus an occlusal and buccal force can be applied to the unerupted cuspids. This is a similar technique as described by Begg and Kesling (1971, 624-647) and further modified by Taylor (1978).

5.1.10. Bishara et alia (1976) describes another variant in force application to the palatal cuspid by using elastic bands between the cuspid and a lower banded arch. This gives both vertical and horizontal components a force resulting in favourable movement of the canine.

GROUP 2 - NO POSITIVE ATTACHMENT

5.2.1. Observation has been suggested as an alternative to aggressive treatment, but is not recommended. (Mulick 1981)

5.2.2. An extension of the passive approach is to surgically expose the tooth, and pack the wound to retain patency of crown access, until a removable type appliance with a plastic extension down into the exposure can be constructed. (Hovell 1966, 197). This needs to be trimmed back as the canine erupts. Three criteria are cited:

1. Adequate surgical exposure (up to, but not damaging, the adjacent teeth)
2. Maintain the patency of the exposure
3. Adequate space in the arch to allow eruption

5.2.3. To assure eruption, Clark (1971) suggests the luxation of the canine with a gouge elevator to free the tip of the crown from its impaction site using the apex of the tooth as the fulcrum of rotation. This practice is not recommended because undesirable side effects can result as recorded in the chapter "Effect of orthodontic procedures on the periodontal membrane" (Personal communication P Mouser).

5.2.4. Salzmann (1957, 337) quoting Hawley suggests, a bite plate over the unerupted canine to stimulate its eruption much in the same way as a teething ring is used by a baby. The approach is unpredictable and of questionable value in the opinion of Salzmann.

GROUP 3 THE TISSUE PRESSURE TECHNIQUE.

5.3.1. The Tissue Pressure Technique approach to palatally impacted canines uses a Hawley type plate with an expansion screw set at an appropriate angle (to be described later) such that the soft tissue overlying the canine can be subjected to pressure from the advancing screw. The canine is induced to move intra-osseously and erupt spontaneously into its normal position. (Easthope 1982)

CHAPTER 6

THE STATEMENT OF THE THEME

THE STATEMENT OF THE THEME

The theme of this thesis is to record the discovery and application of a technique to encourage some palatally impacted canines to erupt normally into the arch without surgical exposure or orthodontic attachment.

In the first instance an attempt was being made to expand the upper arch of a twelve year old patient with bilateral posterior cross bite and who had, beside this, bilateral palatally impacted canines.(Fig 7). The retained temporary canines had been removed two years previously and a Hawley type space maintainer fitted to hold the space and hopefully allow the canines to erupt into their normal position. However, they failed to move and a decision was made to expand the lingually locked first permanent molars using a split removable appliance with an expansion screw set in the midline. Movement was effected at 0.2mm/week and at the end of four months when the molar relationship had been almost corrected the canines emerged in their correct position in the arch and continued to erupt uneventfully. It was then realised that pressure on the palatal soft tissue covering the crowns of the canine had in fact caused them to move within the bone and erupt normally.

The method was applied deliberately to two other cases with similar results. Then a 49 year old woman presented with a palatal canine and an ectopic first bicuspid in the canine position. The bicuspid had a fractured crown due to caries and it was decided to remove the roots and move the canine into its rightful position using pressure on the tissue overlying the lingual aspect of the crown. Again its eruption into the line of the arch allowed normal development toward occlusion.

It seemed by this stage that a principle had been established. Stated simply it is: a tooth can be induced to move intra-osseously when pressure is brought to bear on the overlying soft tissue and the crown is not impeded by adjacent tooth roots.

A modification of this approach has been used to increase the space between the laterals and the first bicuspid in a bilateral palatal canine case. This increase in space is obtained with an expansion screw set laterally in a removable type Hawley plate and the pressure placed on the soft tissue lingual to the central and lateral incisors and also just covering the crowns of the impacted canines. Because of the shape of the movable portion on the plate there is a lateral component of force as well as an anterior one, so that besides space improvement there is also lateral canine movement into the arch.

As with every situation, there are limitations to the application of this method. Adequate space in the arch, expressed so early in canine orthodontics (Barnes 1923), is an absolute prerequisite, obtained either by antero-posterior expansion or by extraction. It being recognised that extraction, carries with it a risk of space closure if there is failure with the canine recovery. A trial period of say three to four months to assess the canine response before extraction of any teeth, temporary or permanent, is probably wise in those cases where the canine is lying in a less accessible position.

Patient co-operation with full time wearing of the appliance is essential, and in those children who do this success is usually assured.

Case selection is critical, ruling out those with the crown lapping on the root of the lateral or the tooth lying at less than 45° to the vertical.

One must not allow emotions to become involved with such a serious subject as orthodontics, but one cannot help reacting with slight elation when the incisal tip of a previously palatal canine emerges into the mouth in its correct spatial relation to its fellows.

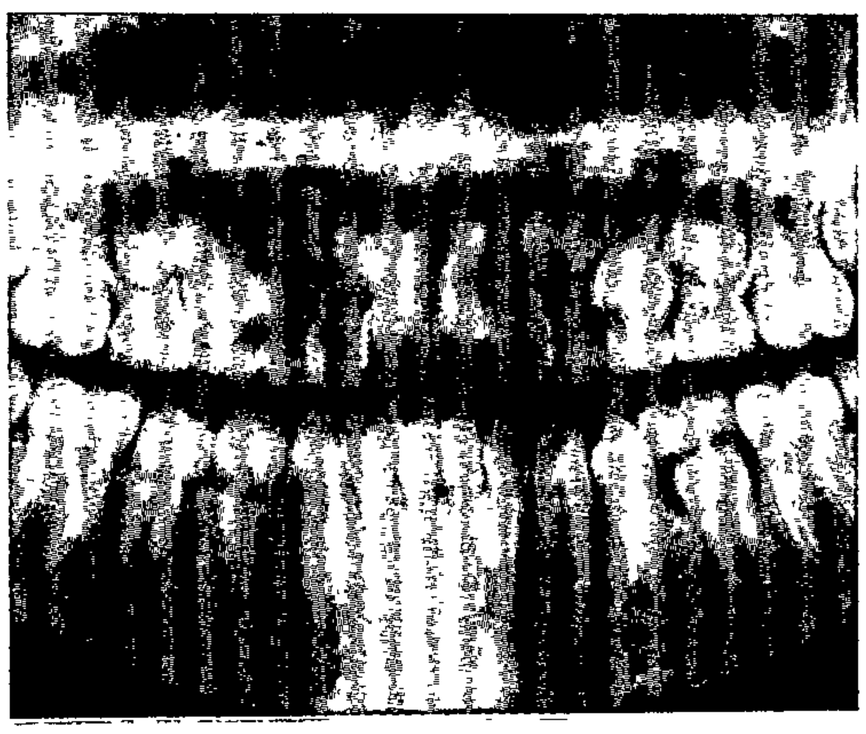

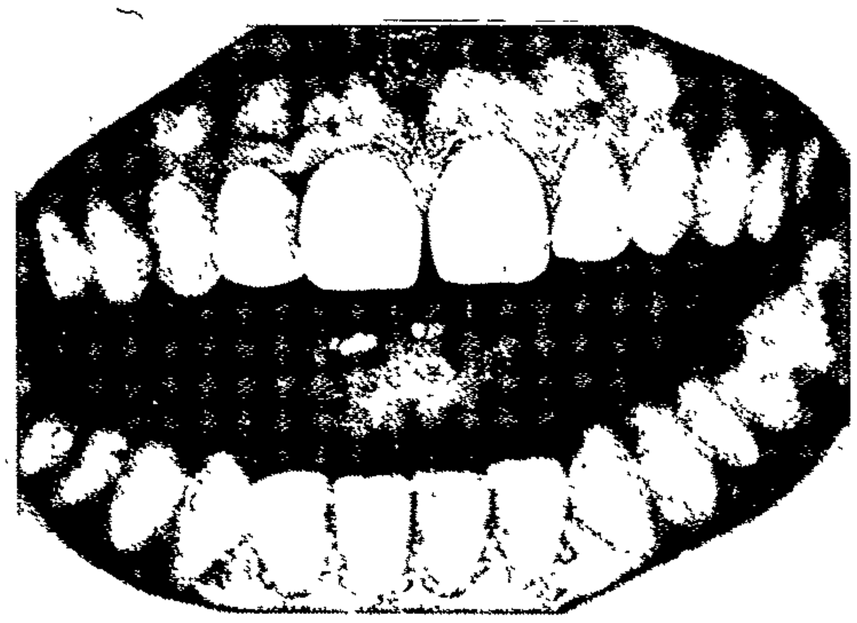

FIGURE 7

Bilateral impacted canines

(Easthope 1982)

CHAPTER 7

TIMING AND SELECTION, FOR THE TREATMENT OF PALATALLY IMPACTED CANINES

TIMING

There is a time for everything under the sun (Solomon Ecclesiastes 3:1) so wrote the wise man and orthodontics is no exception.

Moyers (1973, 449-450) states the following: "So different are the strategy and tactics for early vs. late treatment that the question of timing is asked first. Must the therapy for a case take into account facial movements neither greatly aided nor hampered by growth? Early treatment is arbitrarily defined as treatment during the most active growth. Orthodontic treatment during very active growth sometimes capitalizes on growth and sometimes is handicapped thereby."

In view of the fact that we are dealing with a tooth needing an eruptive force it seems evident that early diagnosis is desirable so that early treatment can be instituted, while eruptive forces are at maximum. For it must be remembered that we are not primarily applying vertical forces onto the canine but mostly horizontal ones and any vertical movement will come almost entirely from inherent eruptive forces.

It must, however, also be said that the force applied to the canine is a tipping one and the crown would finish nearer to the occlusal plane than it was previously even without any vertical force.

Early diagnosis is not as broadly carried out as might be hoped simply because these cases rarely exhibit an orthodontic need until retained 53, or 63 is noted by

an observant practitioner. Routine mass O.P.G. X-ray would tend to solve the problem but this is scarcely a rational alternative. (Williams, 1981, Andreason 1971). Andreason states a technique of great value in early diagnosis when he emphasizes the examination of the canine bulge in the mixed dentition stage. Any lack of a canine prominence should be investigated and treatment commenced in the form of extraction and space retention. It is the contention of this author that such early use of a tissue pressure technique would be admirably suited to produce canine movement toward the line of the arch and the primary canine might be assisted to exfoliate without extraction. However, retention of the appliance in a mouth with few undercuts on molar teeth presents a functional problem thus limiting its early use.

The experience to date has been confined, almost exclusively to the early post-mixed dentition stage ie; 13, 14, 15 years of age, and while we could say that this is still a growing period, it has to be recognised that jaw growth is almost complete. Of course eruptive growth is still in evidence, and when the canine is given the opportunity to erupt (movement away from impaction) it mostly does do this, if not ankylosed. (Easthope 1982).

SELECTION

In Chapter 2b, "Differential Diagnosis", a decision is being made as to the position of the malplaced canine and singling out only the palatal impactions. Now it becomes necessary to further categorize these palatal canines as to their response to the T.P.T. approach to normality.

In Fig 8 there are three cases where the T.P.T. has failed and in Fig 9 and 10 there are seven cases of success. There are at least three factors to consider:

1. Angulation: The successful cases have angulations greater than 45° to the horizontal as opposed to the failures which have angles of 45° or less. Rayne's classification places 60° - 85° as class 1, and 45° - 60° class 2. The line of demarcation is somewhere between 45° and 60°.

2. Cusp tip of the canine: In the failures this cusp tip lies lingual to the distal edge of the central incisor, whereas the successful cases have the cusp tip of the canine lying distal to the lateral incisor, or in the case of the point lying distal to the central, the axial angulation is greater than 45° and in fact is probably greater than 60°.

3. The height of the crown above the alveolar crest: Those cases approximating the alveolar crest with low angulation, can be accepted as potentially successful, but when lying high above the crest even with a greater axial angulation to the occlusal plane, success will not be achieved using T.P.T., and some other method will be needed to bring the canine into the line of the arch.

In deciding the accessibility of a particular palatal canine, the age of the patient must be considered, for in the young patient, say 10 years and under, the canine may not have erupted sufficently for the T.P.T. to be of use, whereas at an older age with more occlusal eruption it could be successful.

31



34

FIGURE 8

Three palatally impacted canines which failed to respond to T.P.T.

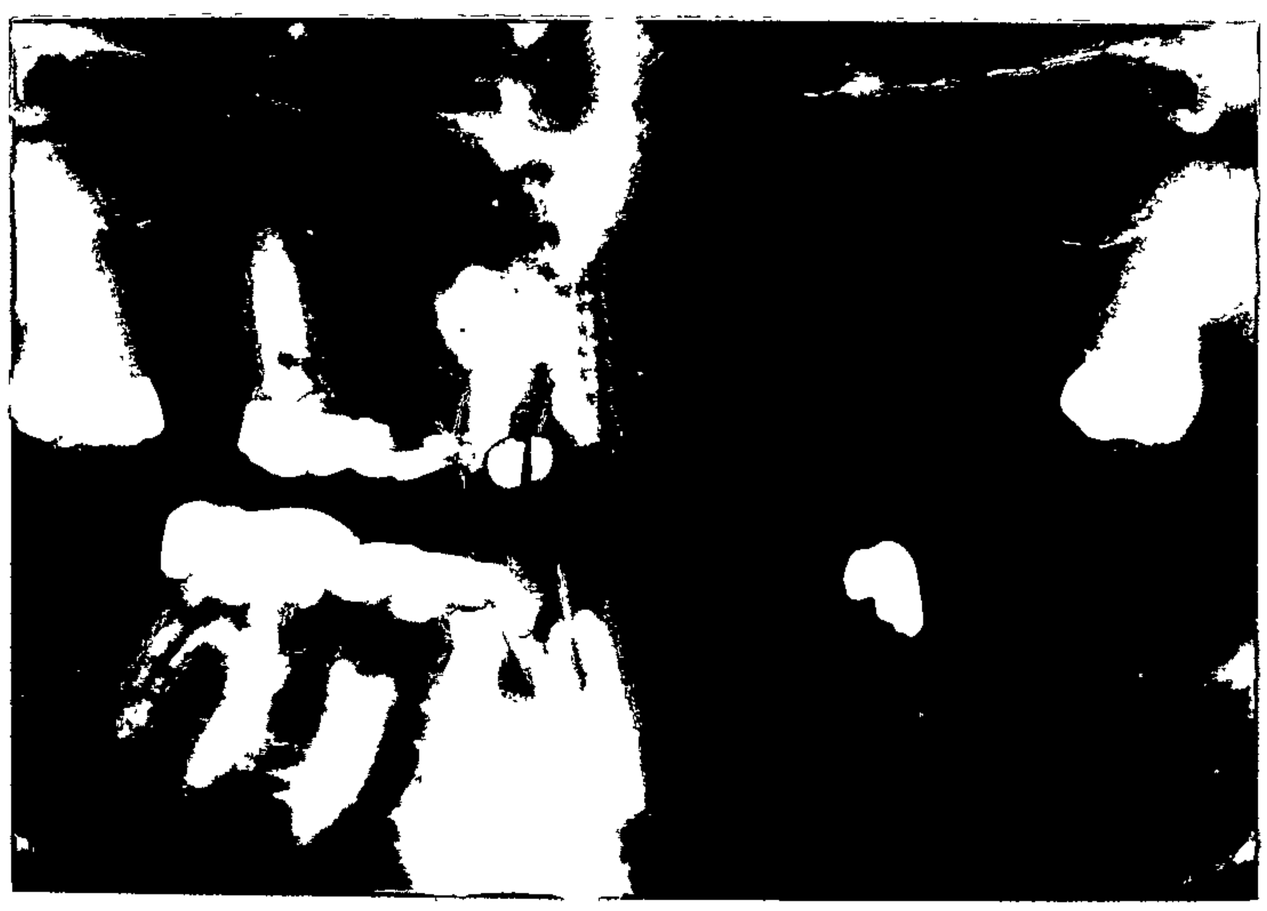

FIGURE 9

Three palatally impacted canines successfully treated by T.P.T.

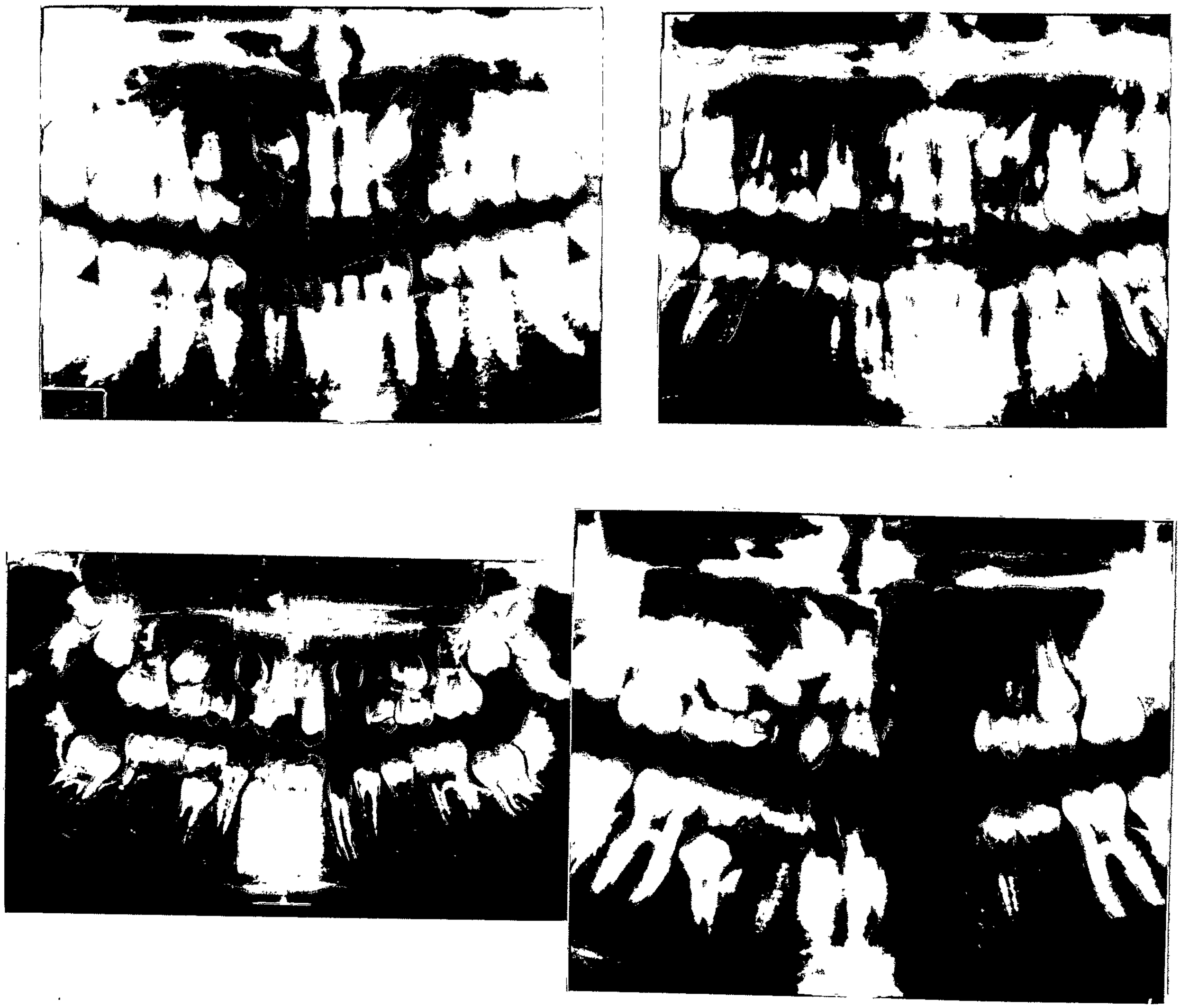

FIGURE 10

Four palatally impacted canine cases
successfully treated by T.P.T.

CHAPTER 8

THE APPLICATION OF THE TISSUE PRESSURE TECHNIQUE

THE APPLICATION OF THE TISSUE PRESSURE TECHNIQUE

The wearing of the appliance presents no more difficulty than any other plate of the Hawley variety. The 0.2mm expansion per week does not produce breakdown of the surface epithelium, although there is sometimes an area of inflammation particularly around the periphery of the target area. This is why it is important to round the edges of this target area plastic so as to minimise the shearing action on the soft tissue. Consistent tooth brushing extended to include the palate and using hot water as the lubricant has been effective in keeping these cases under control. It may even be necessary to bevel the edges to prevent tissue discomfort.

Retention is of vital importance (see Table 5) because the effectiveness of the appliance is negated by insufficient or poorly adjusted clasps. Three clasps are theoretically enough. However, it has been found better to use five or six retentive areas as this gives very positive control of the expansion screw and pressure pad. If open-ended clasps are used then they should face distally if possible, or if mesially then they should finish adjacent to an Adams crib. (Fig 11)

If there is not adequate space for the canine (or canines) to fit into the arch then anterior expansion should be accomplished first and then if necessary direct pressure over the crown of the canines to move them buccally. Bilateral cases can be moved concurrently with two small expansive screws such as Dentarum 622-020 or consecutively as in Fig 12, 13, 14 and 15.

The time involved can vary from four months to eighteen months, depending on the depth below the surface of the unerupted canine. It would seem that besides the buccal movement effected by the expansion screw there is also a dependence on normal eruptive forces. It may be felt advisable to expose the crown when the canine eminence has become obvious in the buccal sulcus. Fig 20 and 21.

Provided the canine has sufficient room in the arch so that there is no impediment to its movement, then it is easier to move before emergence into the mouth. It seems that movement laterally through the mucous membrane presents more resistance than movement through bone.

It is sometimes possible to gain space while applying tissue pressure. Fig 22. Here there is a mid line drift to the right with consequent loss of space in the 14 area . The spring on the distal of 13 effectively increased space for 14. In this case 15 and 25 have been removed and 14 is lying palatally. Fig 22 shows a typical applicance.

In almost every case the canines have erupted in the correct rotational position and have not needed further adjustment.

Finally Fig 23 a, b and c show the movement of a canine over a period of 17 months from the plate to a normal buccal position.

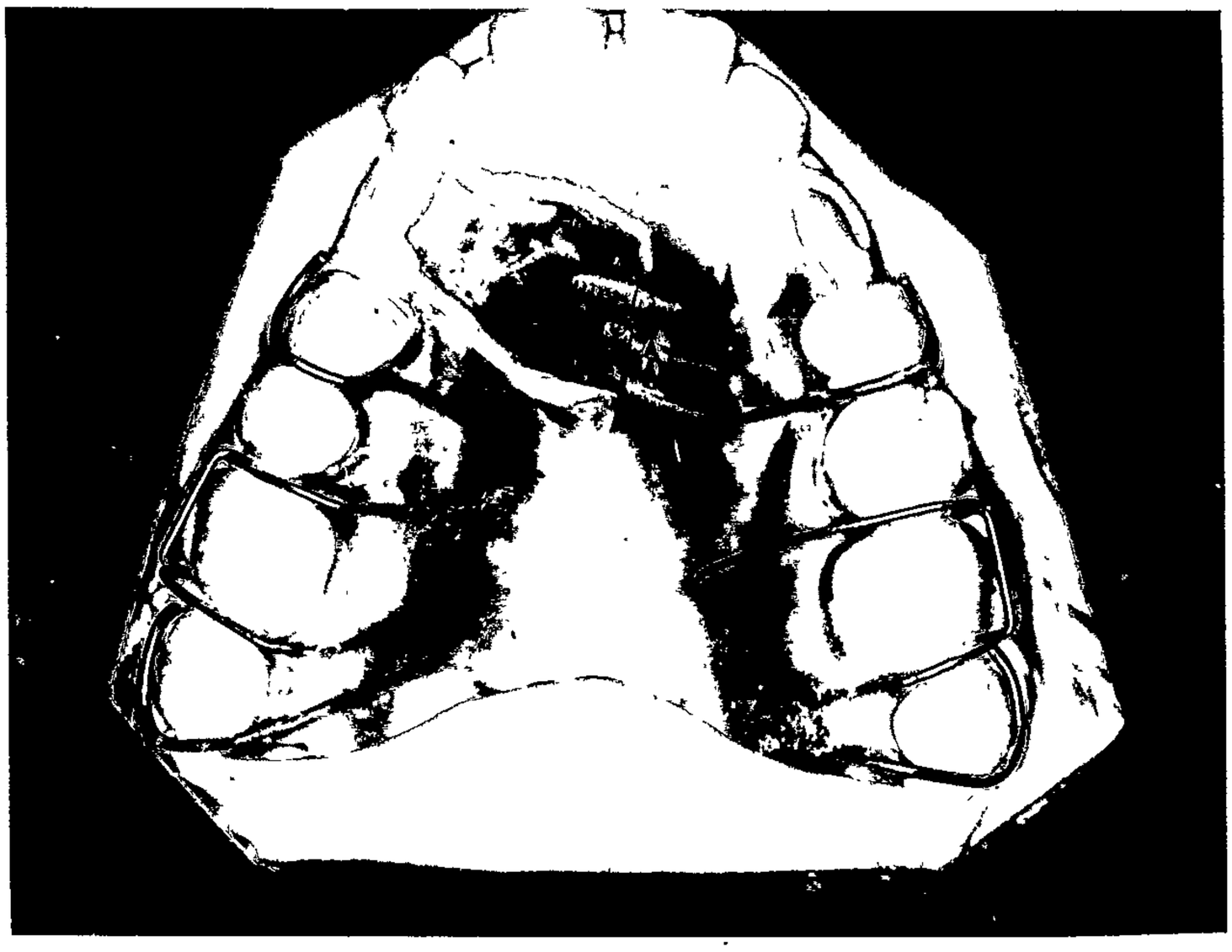

FIGURE 11

A completed appliance with retentive clasps on 14, 16, 17, 24, 26 & 27

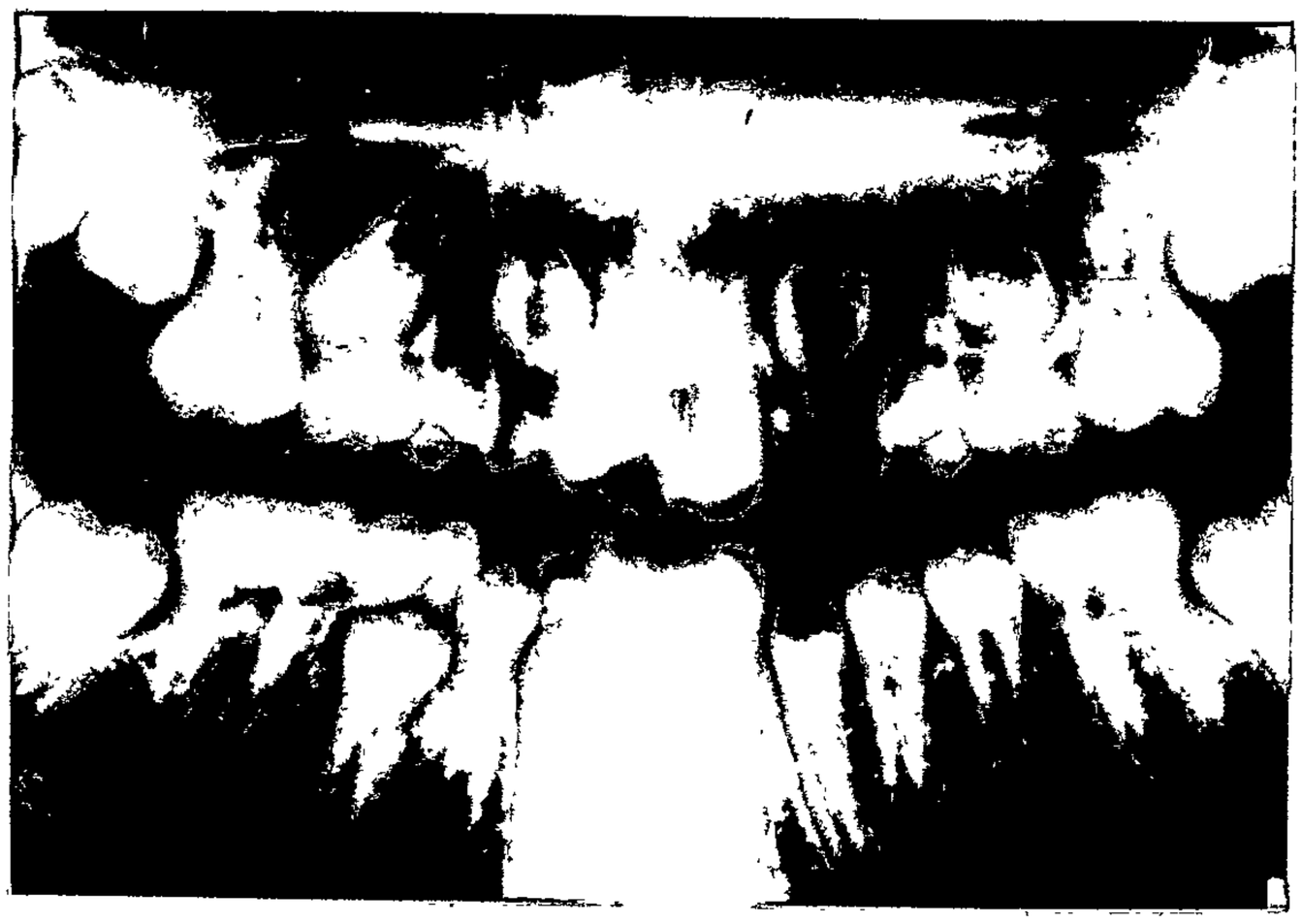

FIGURE 12

Bilateral palatal canines shown in radiograph
This case is pictured in the next three photographs

FIGURE 13

Bilateral palatal canines. Left hand model tissue pressure complete and 23 about to emerge and then commencement of pressure on 13. Right hand model tissure pressure complete, 13 emerging and still waiting 23.

FIGURE 14

Photo of mouth at the time of second model in Fig 16 Both canines have now erupted. The final result in the following photograph.

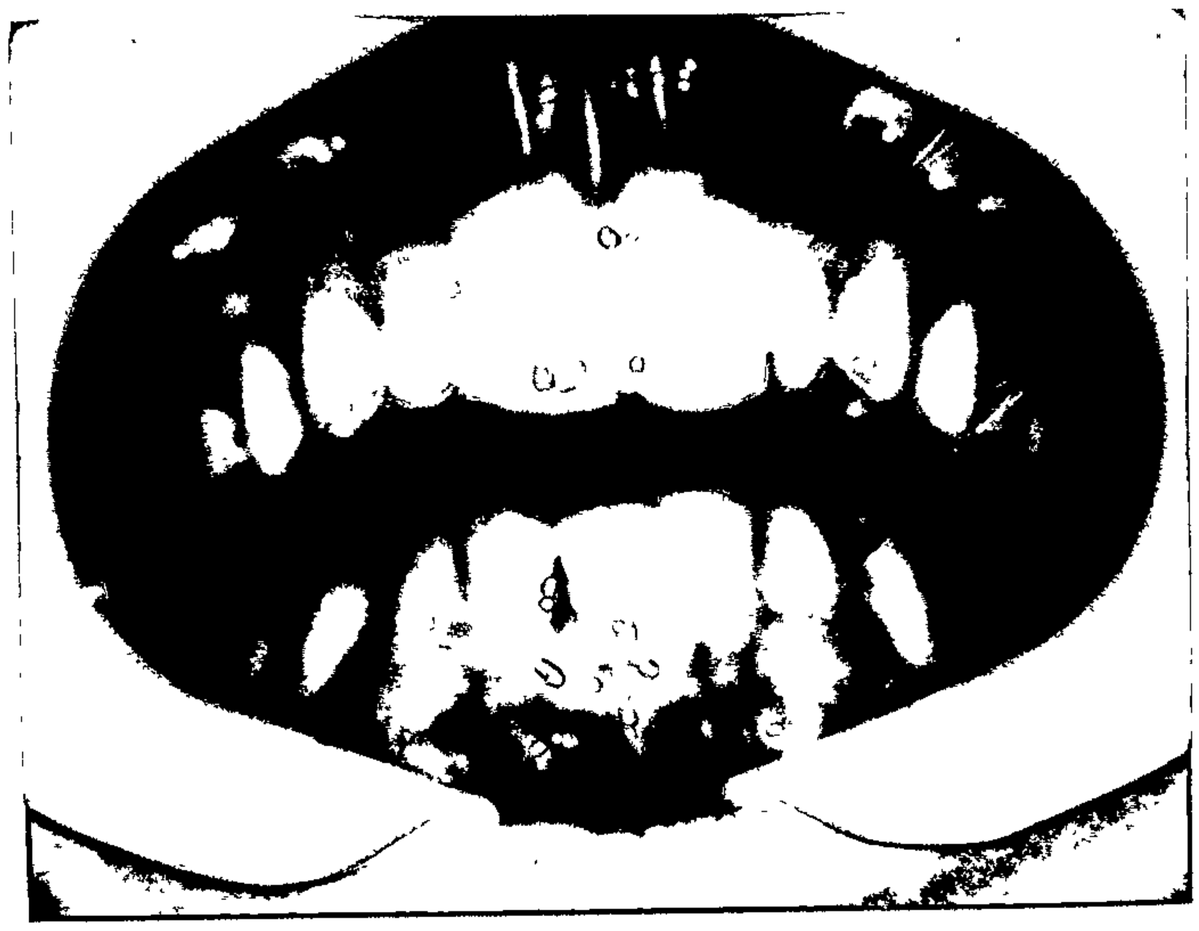

FIGURE 15

Final result of case shown in the previous photograph



FIGURE 16

Another case showing canine movement and the appliance in the next photograph

FIGURE 17

Appliance in the mouth. Note in this case a labial arch is used to improve retention. Same case as Fig 16

FIGURE 18

Same case as Fig 16 showing emergence of 23 into the mouth

FIGURE 19

Palatal canines moved to buccal position and exposed to hasten eruption. (see Fig 20 & 21)

FIGURE 20

Canine eminence now visible after treatment.

FIGURE 21

Exposure of 23 once it has been moved to a normal buccal position by tissure pressure.

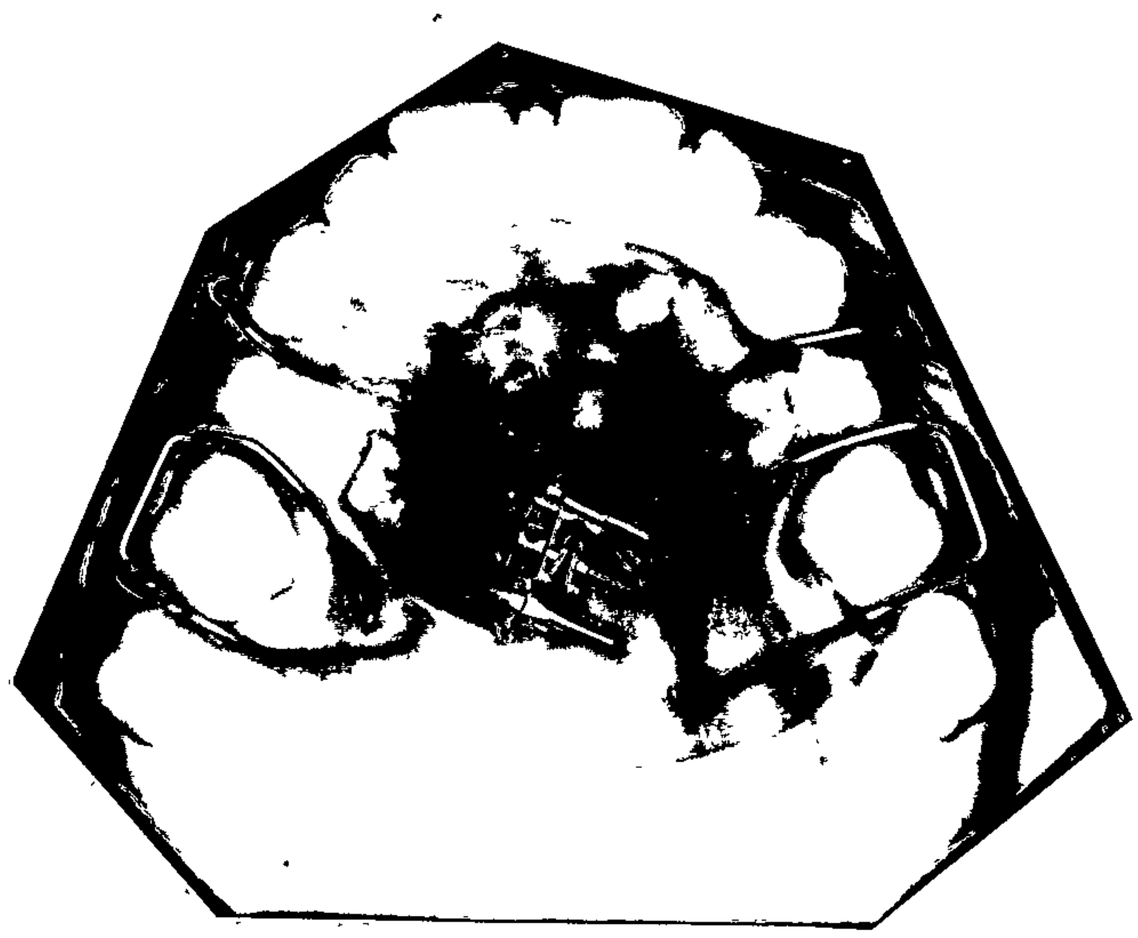

FIGURE 22

This illustrates a palatal second bicuspid with some loss of space.

The finger spring distal to the canine is used to gain space by mesial movement of 11, 12 and 13 as well as tissue pressure on 14 exerted by the expansion screw.

FIGURE 23a, b, c

Movement of canine over a period of 17 months

CHAPTER 9

METHOD OF TREATMENT AND TECHNIQUE OF MANUFACTURE

METHOD OF TREATMENT AND TECHNIQUE OF MANUFACTURE

Simply stated, the method of treatment using T.P.T.is the bringing of pressure to bear on the soft tissue covering the crown of the palatally impacted tooth, and this force directed toward the position which the tooth in question should occupy. The appliance used to produce this force is a removable one, of the Hawley type, clasped adequately onto already erupted teeth and with an expansion screw to activate the plastic pad covering what has been designated the "Target Area". (Fig 25,27,28)

From an impression which has covered all teeth and also the buccal and labial sulci, a model is poured and on this the appliance fabricated. The model can also be used to confirm the diagnosis by palpation of the crown bulge in the palate, and to compare the normal with the abnormal side in a uni-lateral case.

When studying the model it is helpful to view the O.P.G. X-ray upside down, for this is the way the model is being studied, and worked on. In this way, a better mental picture of the exact location of the tooth is formed.

Outline the target area on the model in pencil, (Fig 25, 27, & 28) outlining the crown of the impacted tooth but not the roots of the adjacent teeth. This pencil mark will be transfered to the appliance after curing and this facilitates cutting the pressure pad from the body of the appliance.

Form the clasps to suit the supporting teeth, choosing those teeth with adequate undercuts. While three units are theoretically sufficient, it has been found more satisfactory to utilize five or six retentive units including in many cases, a labial arch wire and clasps on 17 & 27, as well as the Adams cribs on 16 & 26. In the younger patient, 25 or 55 and 64 or 65 have also been used when 17 & 27 have not erupted. These clasps are now luted onto the model with wax, leaving the palate free and clean. (Fig 24b).

The expansion screw is then located on the model, and again holding it in place with a small amount of wax on its plastic insert. The angulation is such that there is a buccal and slightly occlusal (approx. 5°) movement of the target area pad, and in line with the space in the arch where the canine will finaly erupt. When premaxillary expansion is used then the angulation is forward toward the central and lateral incisors and slightly occlusially (approx 5°). Fig. 25 shows a negative occlusal angle, however our present practice is to use a positive setting and it would seem that this gives an eruptive component to the applied force (Fig. 26)

After curing, remove the appliance from the model, and the upper plastic insert from the expansion screw. Finish with acrylic burrs and buffing. The palatal surface will have taken up the lead pencil mark from the model, so using a no.6 tungsten carbide flat fissure burr, cut around the target area carrying the cut through to the expansion screw. It will be necessary to buff again and to round the peripheral edges of the target area to minimise tissue discomfort. The appliance is now ready for oral fitting at which time retention is established and the first movement of the screw commenced.

While this disertation relates specifically to canines it is equally applicable to any tooth which is in suitable unerupted position (Fig.22)

For uni-lateral and anterior expansion cases the Dentaurum no. 600-010 has been found effective, this giving approximately 8.0 mm movement before the need for reactivation. In bi-lateral cases the smaller expansion screw (Dentaurum no. 600-012) allows two screws to operate concurrently, thus reducing the overall time of treatment.

It has been found that a quater turn per week is sufficient to accomplish movement , but not enough to cause tissue discomfort. This gives 0.2 mm of linear movement, with each quater turn.

The wire used in the appliance is hard drawn stainless steel, 0.9mm for the labial arch wire and clasps, and 0.7mm for the Adam's cribs.

A typical appliance is shown in Fig 24f & 33.

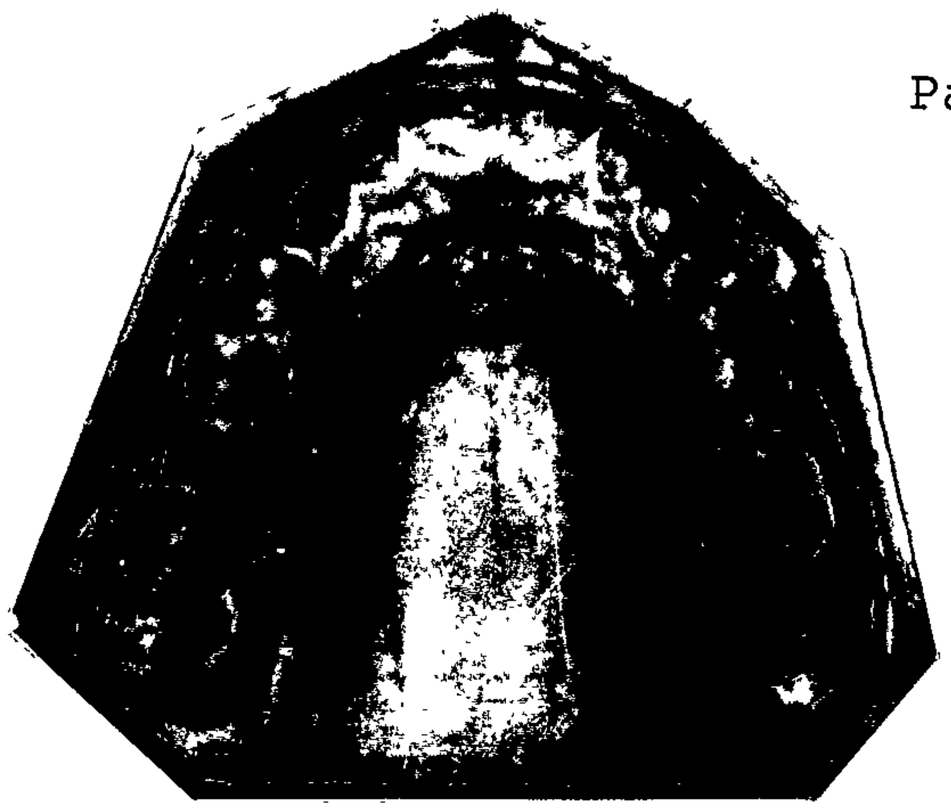

a. Model



b. Clasps and expansion screw attached

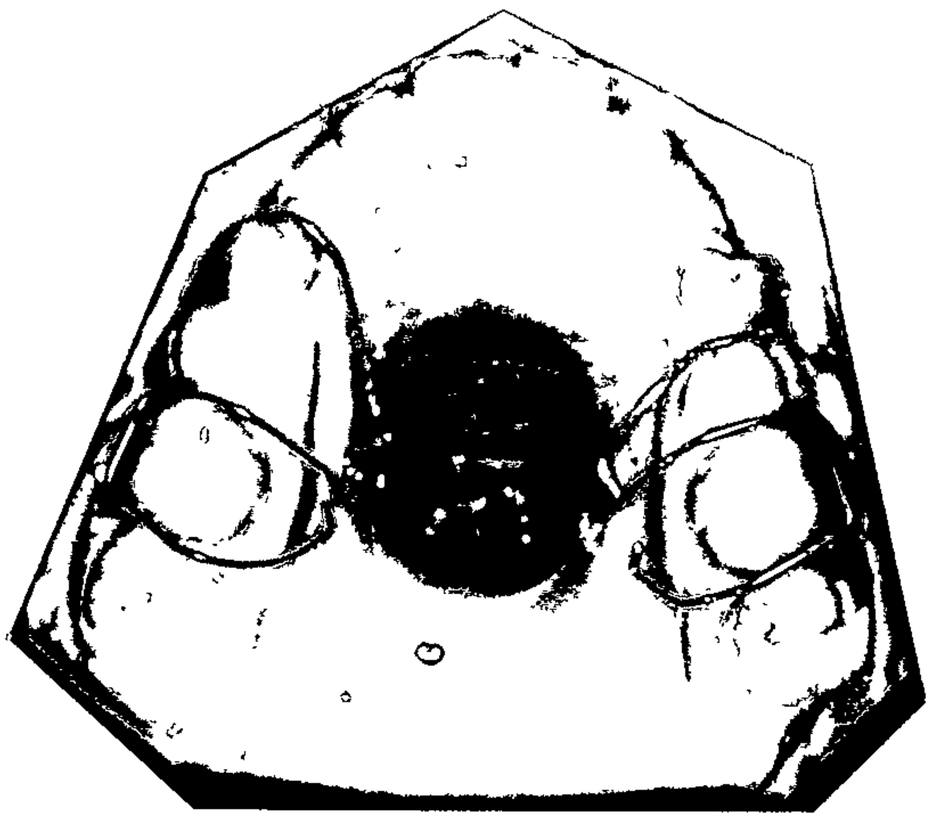

c. Acrylic liquid placed under expansion screw and then powder added.

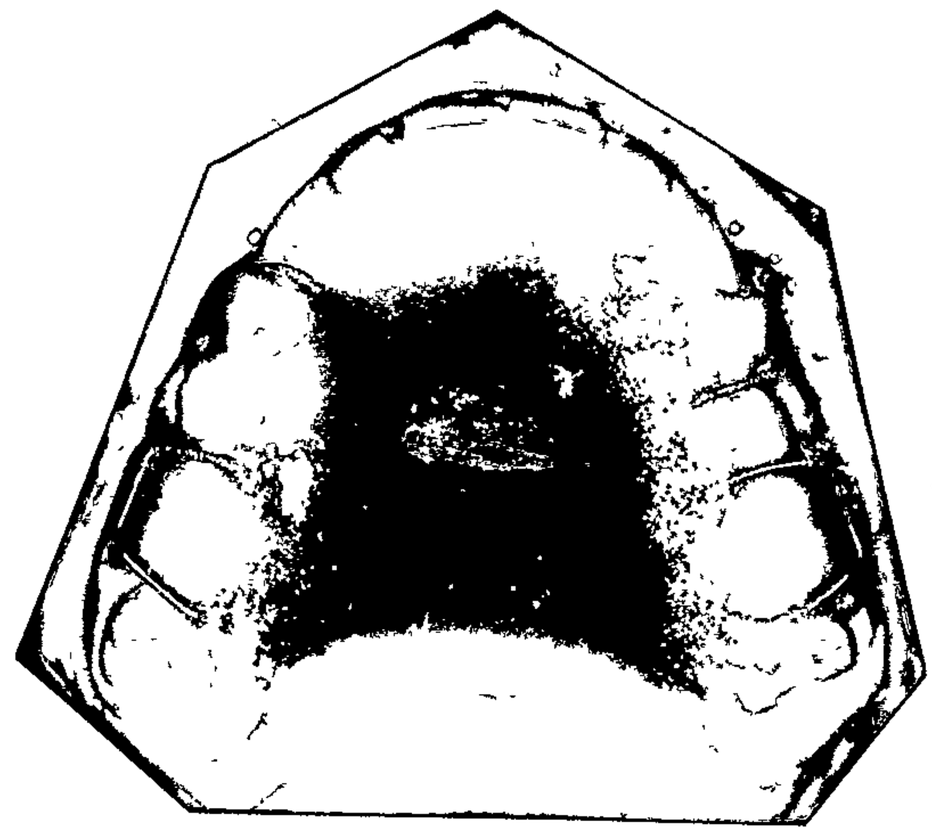

d. Completed acrylic buildup

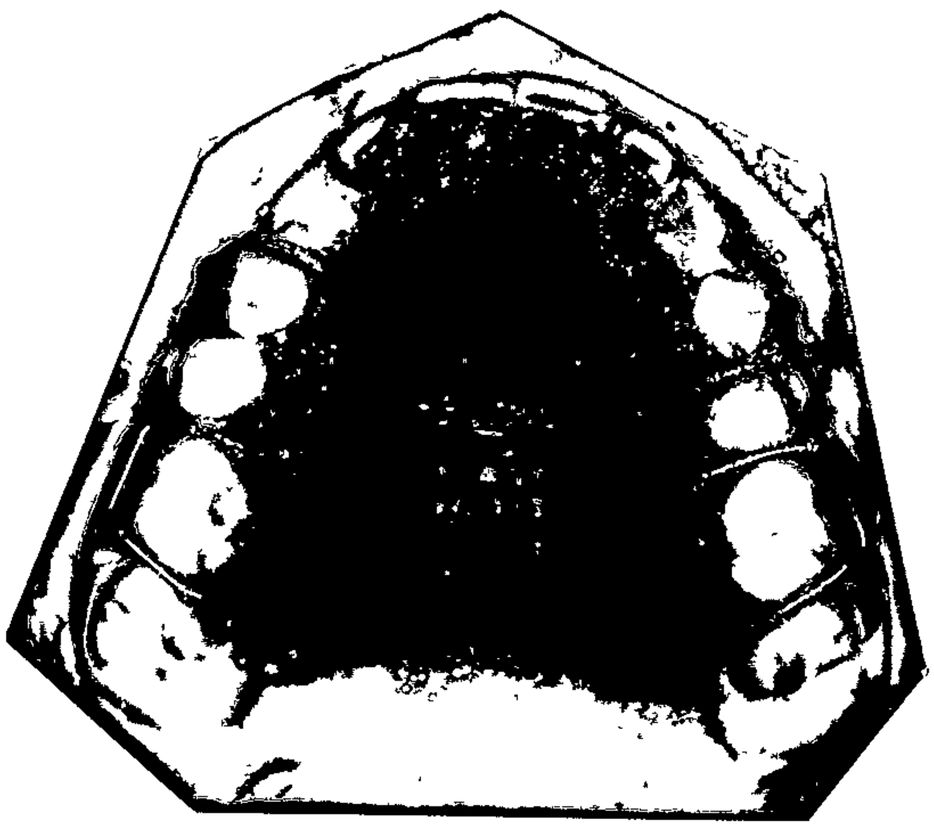

e. Processed in "hydro flask"

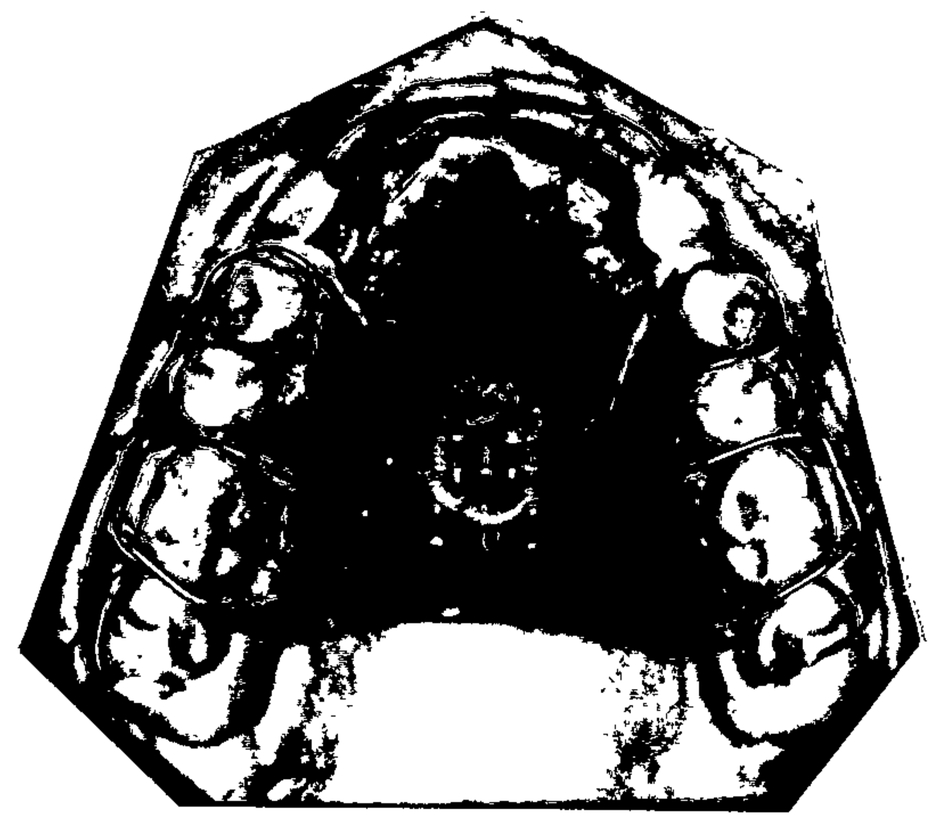

f. Polished and target area sectioning completed

FIGURE 24

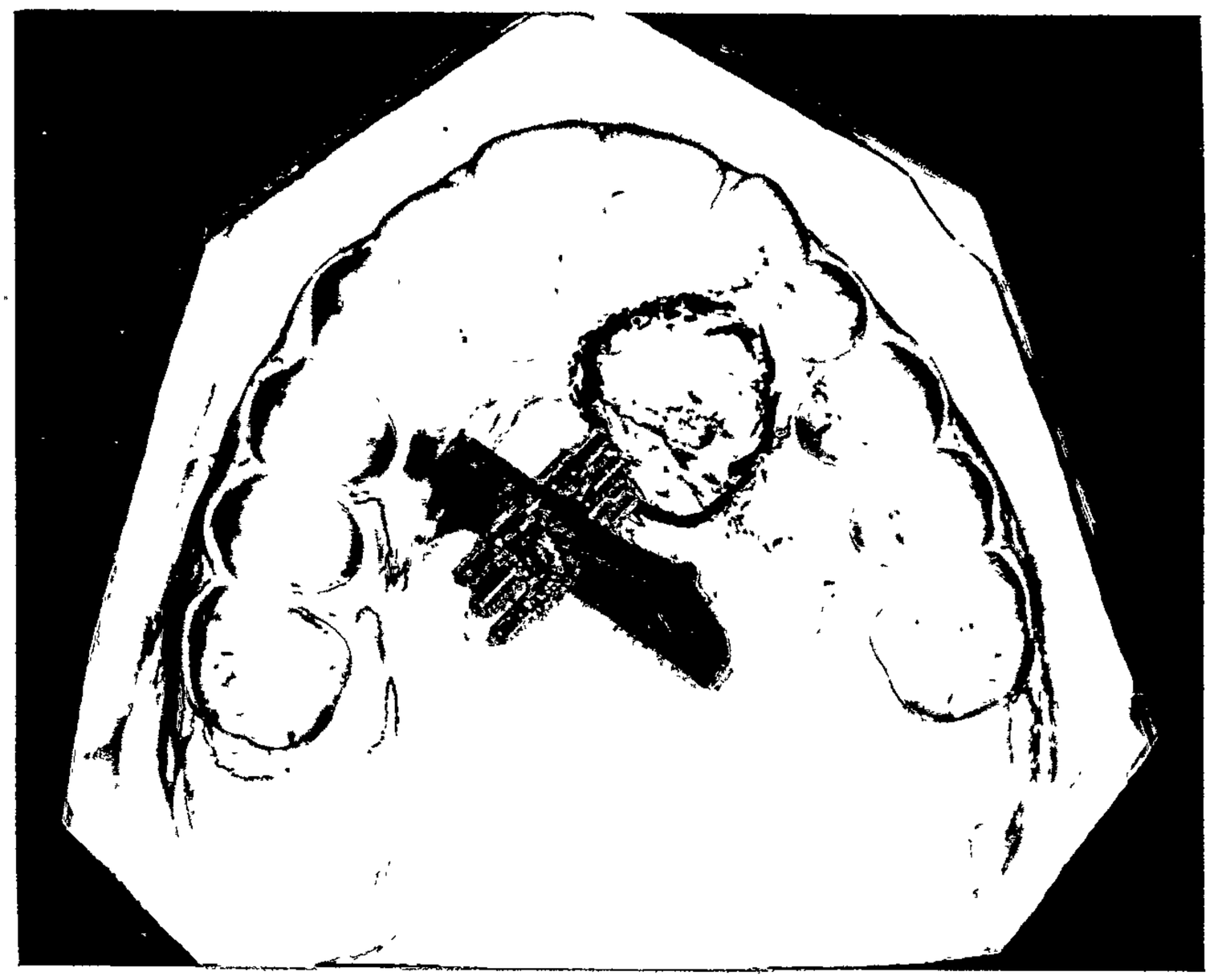

FIGURE 25

The angulation of the expansion relative to the target area. The screw in this illustration has a negative angle to the occlusal plane. Present practice is to set the screw with a 5° positive angle. (see Fig 26)

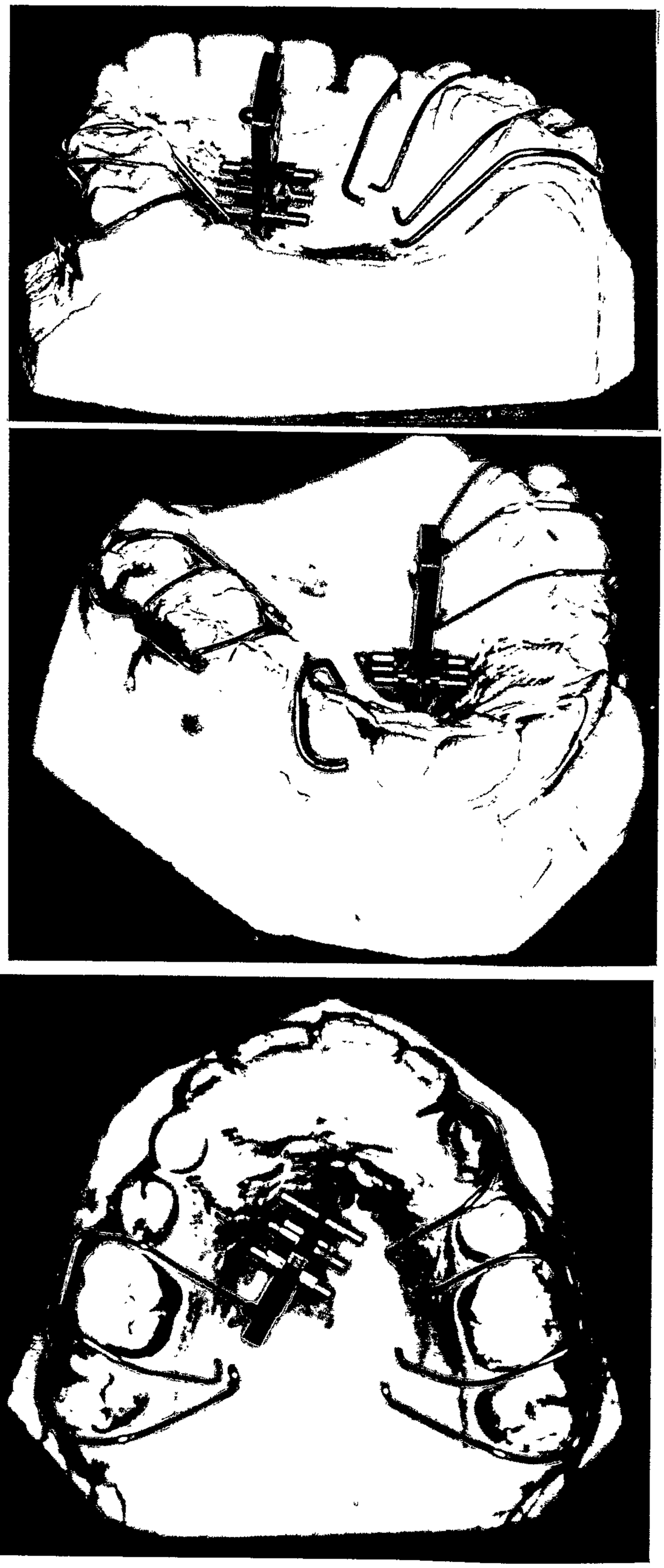

FIGURE 26

5° positive angle of the expansion screw to the occlusal plane.

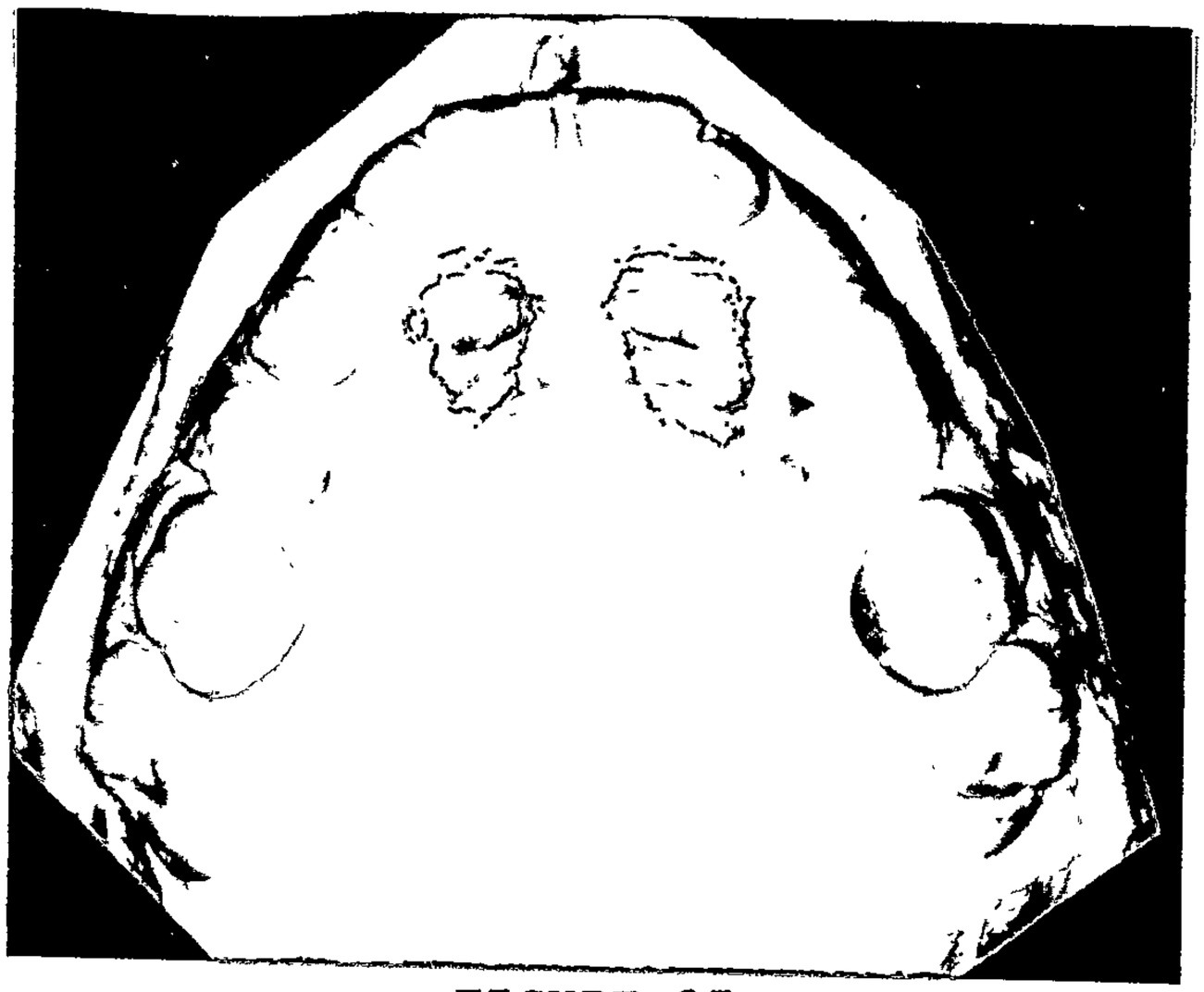

FIGURE 27

Target area outlined in pencil.

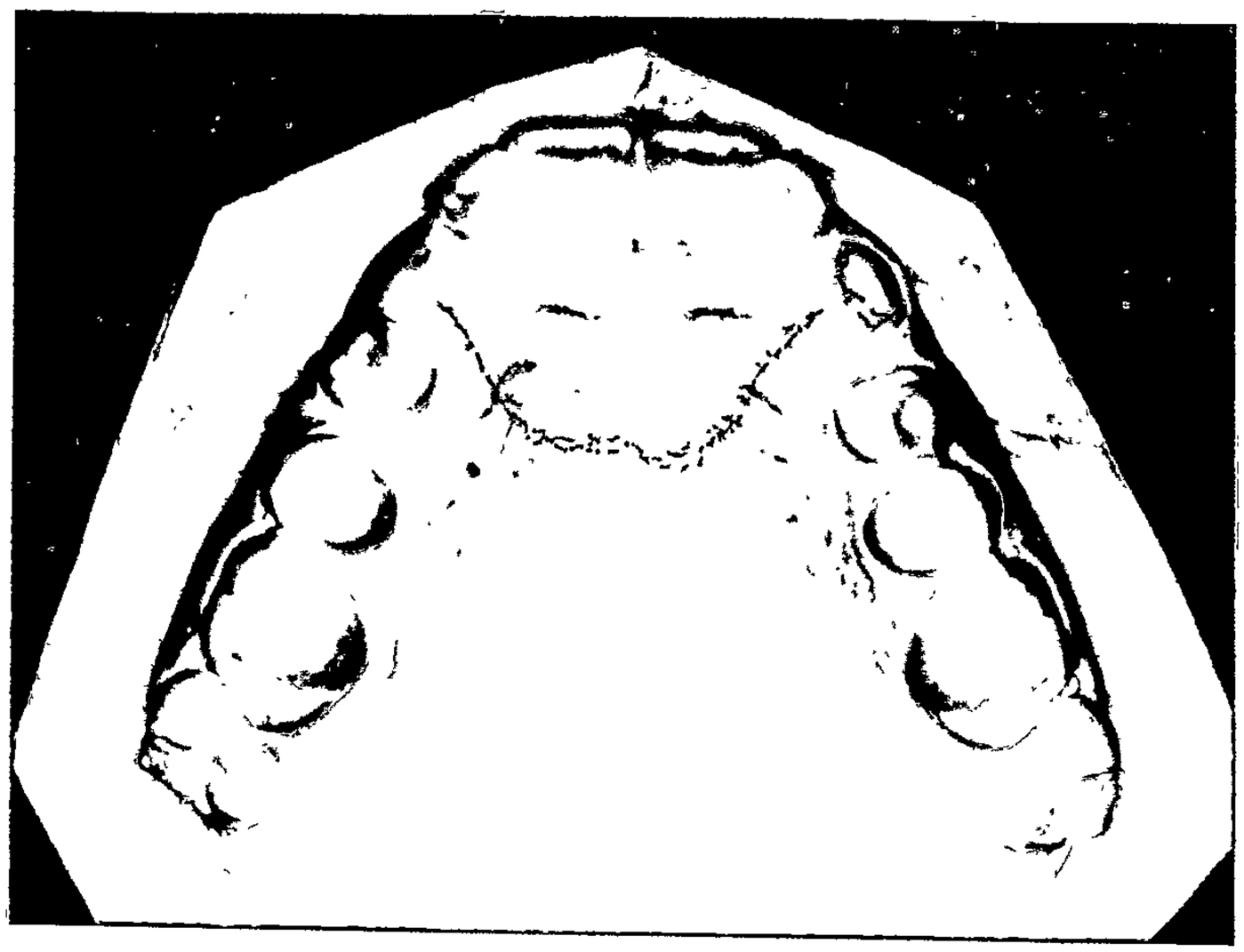

FIGURE 28

Target area for canine space improvement and some lateral movement on the canines. This is the end of treatment with the canines emerging into the oral cavity. Initially the target area had commenced just mesial to the first bicuspids.

CHAPTER 10

INDICATIONS OF CO-OPERATION

INDICATIONS OF CO-OPERATION

After a person has been accepted as a patient, it is important to accurately assess the co-operative response in wearing the appliance. While one would not presumptuously assess a person to be lying, it is important to establish independently the fact of co-operation.

The following evidences of continuous wearing have been helpful in assessing patient's veracity during the course of treatment.

By the use of clear acrylic it is possible to see the soft tissue while the appliance is in the mouth. An appointment should be made to fall on the day before the next expansion screw advancement is to be made. Immediately after the screw movement there is a visible blanching of the soft tissue due to the slight pressure on the mucosa. This change disappears after 24 hours, so that if it is still present six days later it is fairly evident that inconsistent wearing is being practised.

The distal margin of the appliance, when worn faithfully, will always produce a line of indentation into the palate of those patients, who have been faithful in their attempt to wear the device, so that if this is absent, it is sure evidence of intermittent wearing. This line should be clearly evident one month after insertion of the appliance.

Just as the distal margin of the appliance produces a visible indentation in the palate, so the target is even more indented, for over this area we have continuing

and advancing pressure from the expansion screw. If this is not visible then non-co-operation should be suspected. Some discomfort is to be expected during the course of treatment and when a person reports no problems even over a long period of time (3 to 4 months), then again patient attitude needs very close scrutiny.

Early diagnosis was considered in Chapter 7 above, and without a doubt this has many advantages. However, some patients find the intrusion of any orthodontic device at an early age, something that cannot be tolerated. Not that they overtly refuse to try, but that results are just not forthcoming and one is forced to conclude that they are not ready for orthodontics. It has been found that some children are unable to accept treatment until 14 or 15 years of age and at this age react to treatment in a totally acceptable way, whereas at an earlier age have all the symptoms of non-compliance. This highlights the need for personalized assessment and treatment, and the ability to exhibit almost infinite patience, if the broadest number of children are to benefit from the service.

We have found that the age of 9 years and 3 months is an average starting age for removable appliances, although exceptions occur as in all situations. This age is very acceptable for the use of the technique described with growth still in an active stage and intra-osseous eruption of the canines also at maximum. (Moyers 1973, 185 and 102, 3)

CHAPTER 11

INTRA-ORAL MEASUREMENT OF SOFT TISSUE PRESSURE

INTRA-ORAL MEASUREMENT OF SOFT TISSUE PRESSURE

The measurement of force exerted by the soft tissue, ie tongue, lips and cheek, have been reported on by several writers (Feldstein 1950, Gould and Picton 1963 and Becker et alia 1979).

Two methods of measuring pressure have been used. One is a rubber diaphragm covering a fluid-filled capsule and connected to a manometer. This could measure a force as low as 0.31 of a gram. (Feldstein 1950). The second method utilised pressure sensitive transducers or strain gauges attached to a pad on which the soft tissue could rest. This pad was set so that it protruded not more than 2mm beyond the line of the teeth. Subjects with a missing tooth where chosen so that the device utilised this space. In a prior study (Gould et alia 1962) the device was cemented onto the labial face of anterior teeth, again with maximum thickness of 1.5mm so as to record as nearly normal as possible the force of soft tissue on the teeth. Forces ranging from 30gm/cm^2 to 430gms/cm^2 were registered in various acts of swallowing and speaking.

In this present study, pressure measurement is made of the force produced by the orthodontic appliance when the expansion screw is advanced, thus moving a pad onto the soft tissue, rather than the measurement of normal pressures exerted by the oral musculature, as reported above.

CHAPTER 12

MEASUREMENT OF PRESSURE PRODUCED IN THE MOUTH BY THE TISSUE PRESSURE TECHNIQUE - METHODS, FINDINGS, AND RESULTS

MEASUREMENT OF PRESSURE PRODUCED IN THE MOUTH BY THE TISSUE PRESSURE TECHNIQUE - METHODS, FINDINGS & RESULTS

The equipment chosen for pressure measurement is a system of four strain gauges (120 Ω) cemented to two stainless steel beams set between the expansion screw mechanism and the target area, (Fig 29). The advancement of the screw deflects the beams and thus activates the gauges producing a readout on a digital Wheatstone bridge.

The gauges were set facing each other and wired as per diagram 2. Two alternate gauges were under tension and the other two under compression.

Calibration has been done by means of balance weights placed on the target area and this result is shown in table 1. Weights range from 2gm to 20gm and the degree of linearity is.16gm in 20gms.

Measurements were then commenced with the appliance attached to the model. However, no consistency was possible when the appliance was relying only on the clasps, probably because the plaster model becomes damaged and retention is not effective. To overcome this, a clamp was constructed (Fig 31) to hold the appliance on the model with constant force and then readings were taken with ¼, ½ and 3/4 turn of the expansion screw. These readings are shown in Table 2.

The strain gauges were purchased from Applied Measurements Aust Pty Ltd of Melbourne (Catalogue number N11-MA-1-120).

Moving then to the mouth, a reading was taken with no clasp adjustment and it is to be noted that ¼ turn produced no recordable pressure (Table 5) emphasising the need for adequate clasp adjustment. With the clasps functional then a measureable pressure was produced on the ¼ turn movement and increasingly so with ½ and 3/4, (Table 6). This increase was not linear as the greater compression of the soft tissue receives greater resistance and thus greater strain on the gauges, (Table 9).

A measurement was then taken of the pressure fall-off over time and these readings are shown in Table 7 for a 2 hour period. It has been observed that after advancement of the screw, pressure is felt for about 2 hours, after which there is no sensation of force. The reading demonstrates a 50% fall in 2 hours.

The Wheatstone bridge dating from 1833, (Encyclopaedia Britannica 1951) is a convenient way to measure resistance and when resistance can be varied with pressure as is the case in a strain gauge then the instrument can be calibrated in units of force. In this case we have used grams as the unit and measurements are shown in grams on the readout.

Diagramatically the bridge is shown in diagram 3 and the actual circuit construction shown in diagram 2.

The instrument circuit is also included in diagram 4. When the beams are flexed, resistances A and C are reduced and resistances B and D are increased.

This means that more current will flow through C and then through the galvinometer to complete the circuit through A. A reverse flexion will give a negative reading.

Reference must also be made to the variation of pressure between different readings with the same expansion and it would seem that the variant is the firmness with which the appliance is seated in the mouth. The human element, it seems, is the cause of this inconsistancy.

The area of the pressure pad has been estimated using a polar planimeter. The result of this measurement is 1.65 cm^2 (mean) (SD .116 SE .021). Thus the force per unit area for ¼ turn of the expansion screw is 4.47gms/ cm^2, which equals 0.1618 kilopascals.

Much more work remains to be investigated in the area of pressure measurement. However, thus far, it has been shown that pressure as low as 4.47gms/cm^2 is sufficient to stimulate the eruption of a palatally buried canine. The physical layout of the equipment and its positioning in the mouth are shown in Fig 30a & b. Appreciation is expressed for the willing co-operation of the patient during the time taken for pressure measurement.

Finally Fig 32 shows the emerging left canine on the patient who co-operated in this section of the paper, and on the right is a normal canine eminence just prior to emergence and the type of appliance used. (Fig 33). The O.P.G. of this case is also submitted.

It has been a satisfaction to record the actual pressure produced in the T.P.T. and clinically it has been found that an expansion of two ¼ turns per week does not produce mucous membrane damage but beyond this there is evidence of irritation.

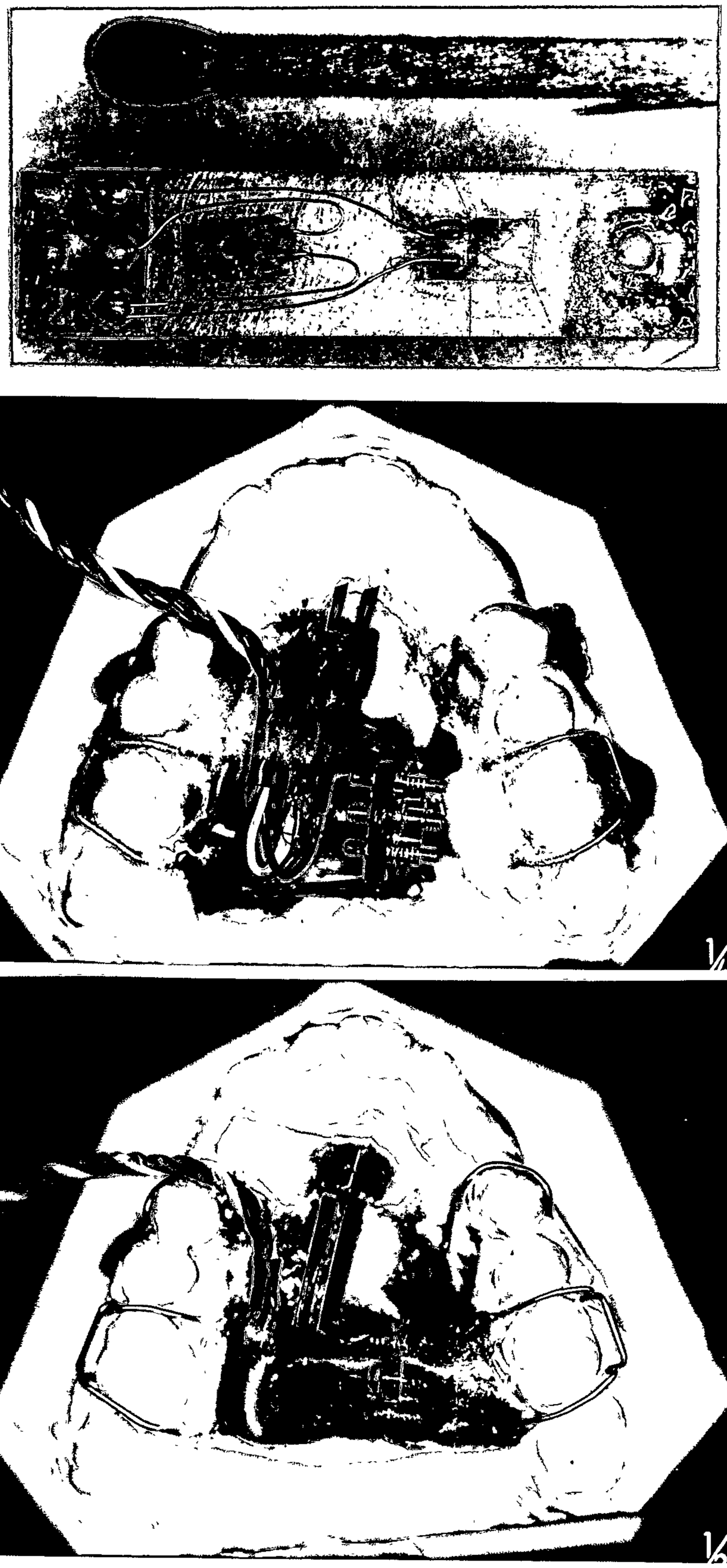

FIGURE 29a, b & c

Magnified view of one beam with two strain gauges attached. Construction detail of the pressure measuring appliance.

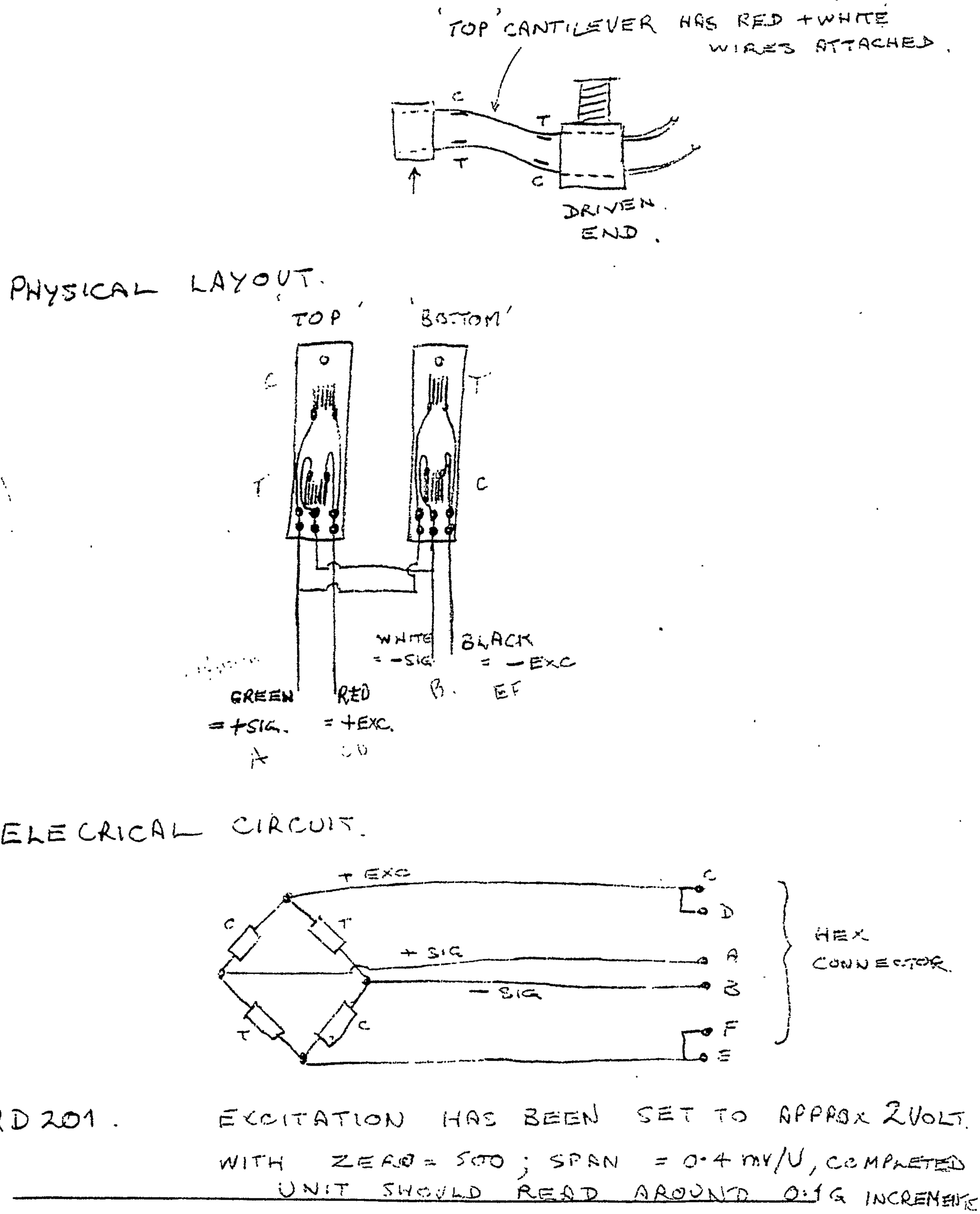

DIAGRAM 2

Wiring diagram of strain gauges cemented to steel beams.

Hand drawing supplied by Applied Measurements Aus. Pty Ltd.

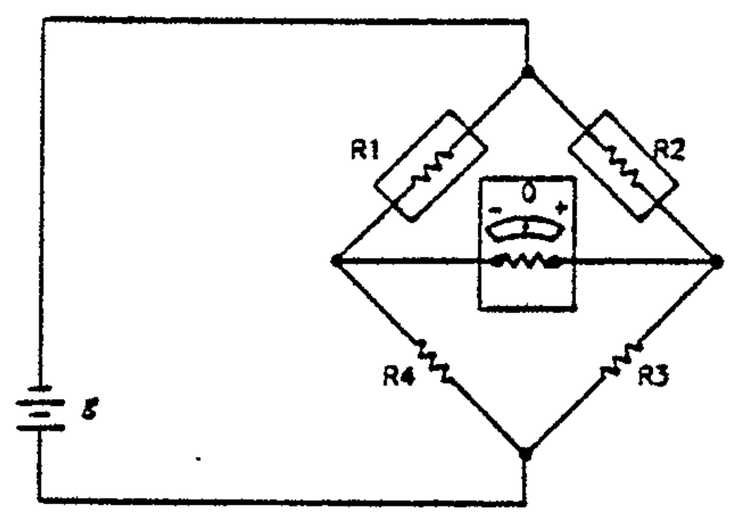

Measuring bending strain with Wheatstone bridge.

DIAGRAM 3

Techtronic Inc. Beaverton Oregon

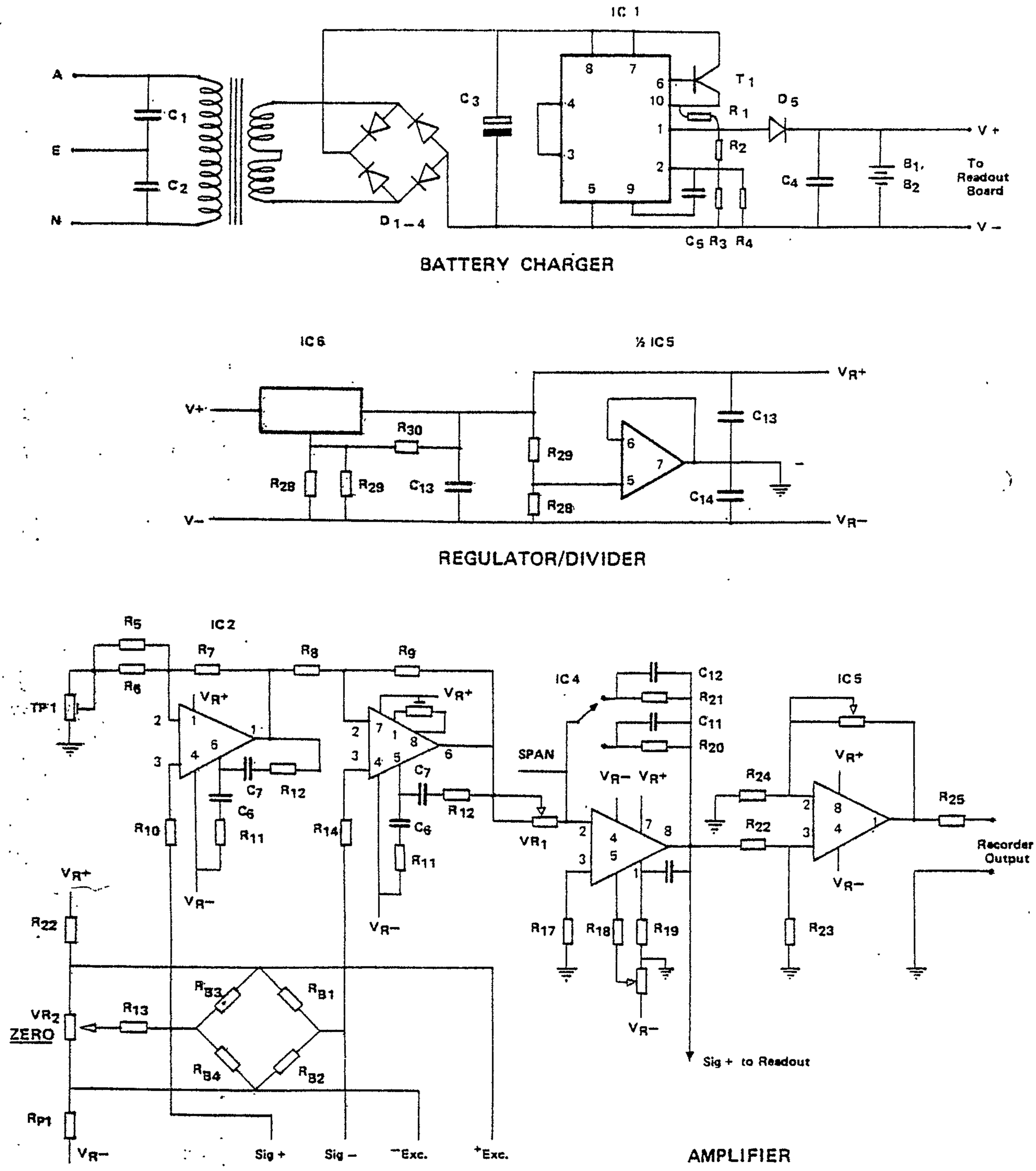

DIAGRAM 4

Circuit diagram of digital readout
(Applied Measurements Aust. Pty Ltd)

FIGURE 30a & b

Readout showing ¼ turn with appliance in the mouth
Close up of appliance in the mouth

FIGURE 31

Appliance clamped to model to give constant relation to model after expansion screw has been advanced thus deflecting the stainless steel beams

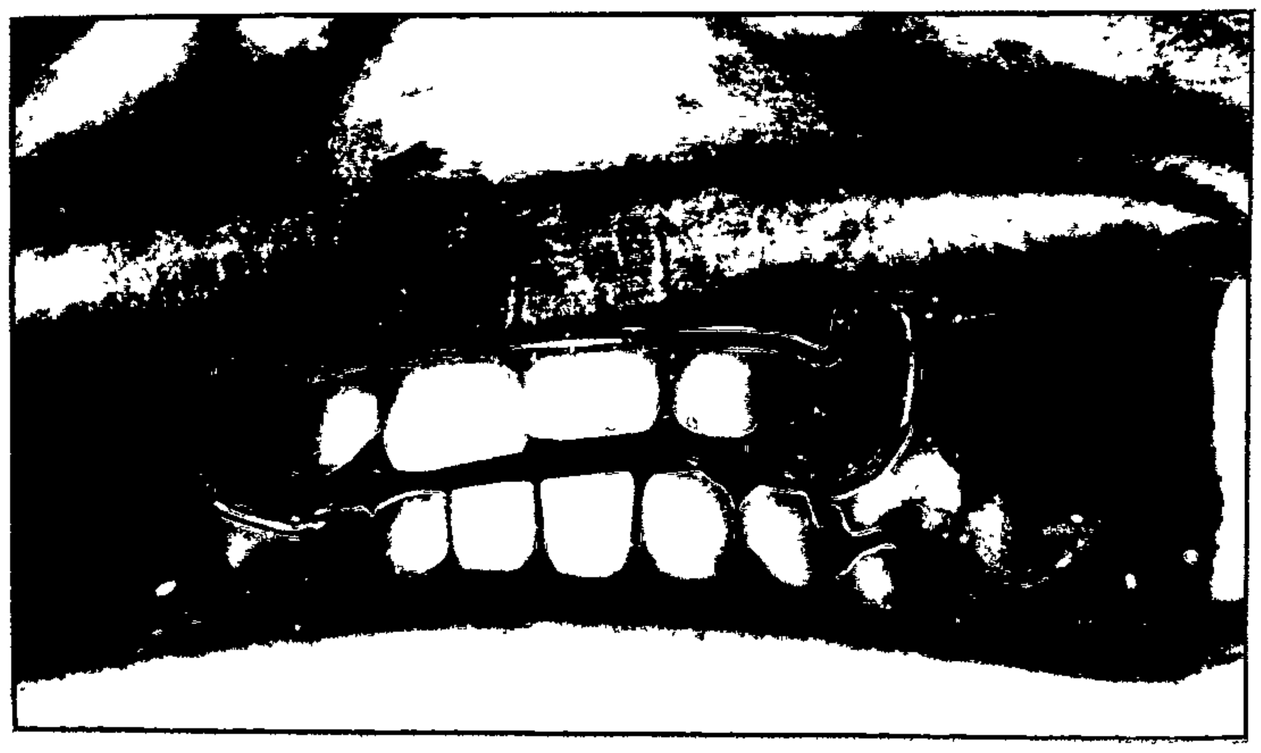

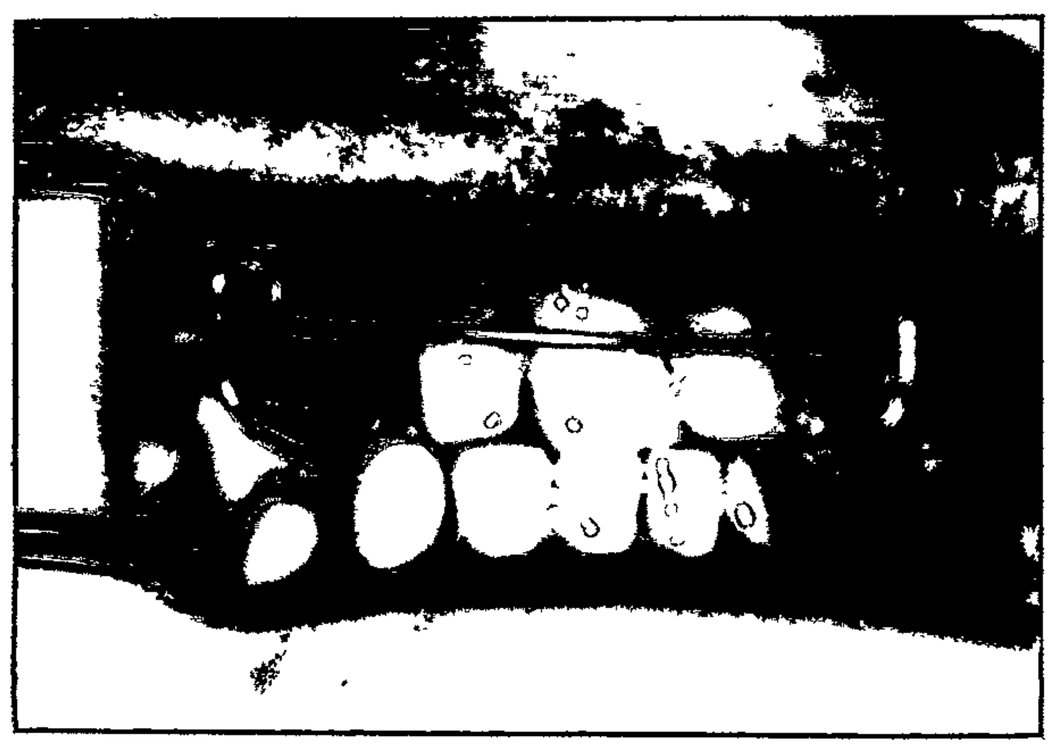

FIGURE 32a, b & c

Canines on emergence and radiograph of patient who volunteered for pressure tests

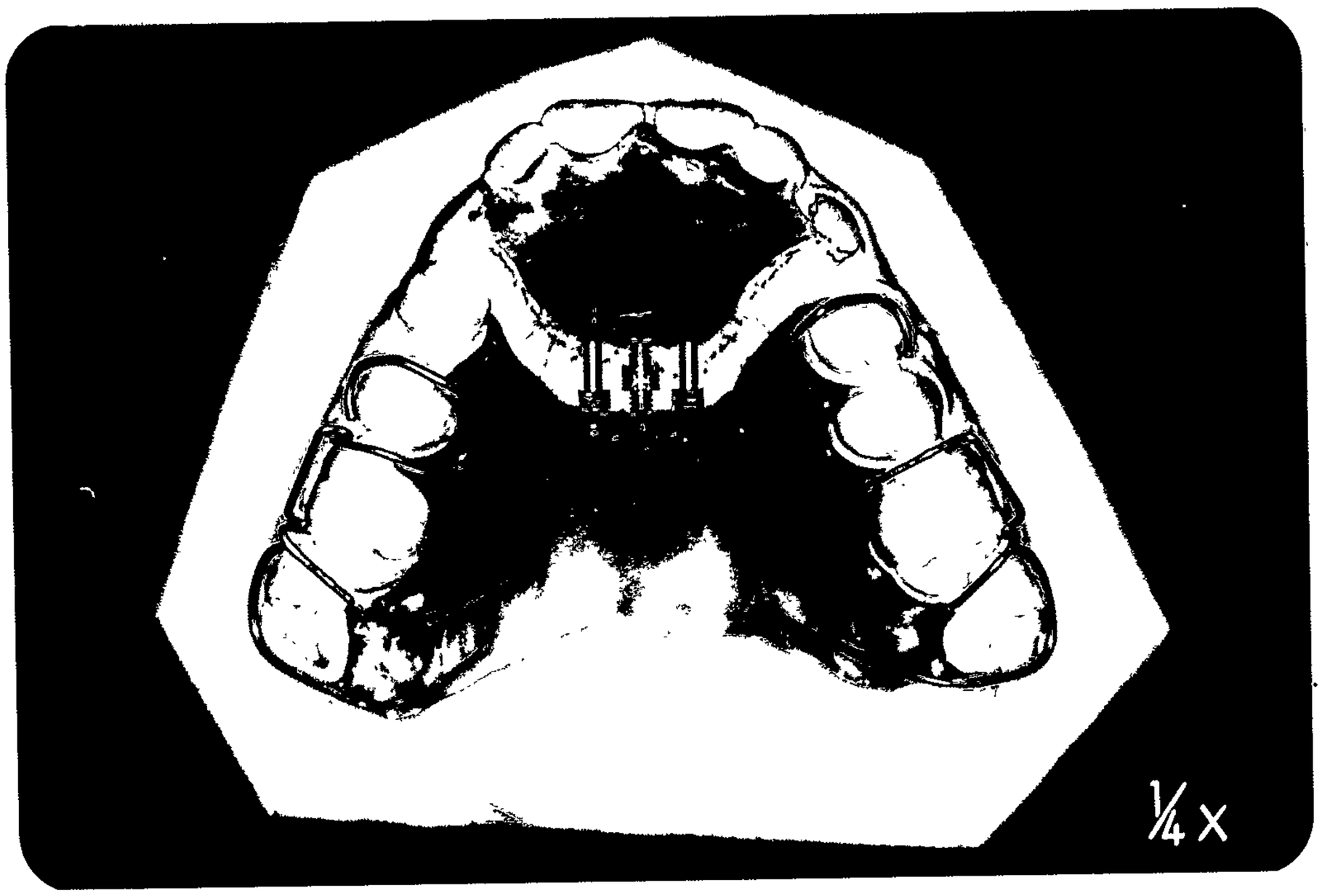

FIGURE 33

Appliance used in the above case to stimulate bilateral canine eruption

Calibration of the equipment using standard balance weights.

ZERO	2 gm
N = 12	N = 12
$\bar{X}$ = .03	$\bar{X}$ = 2.03
SD (n-1) = .05	SD (n-1) = .05

ZERO	5 gm
N = 12	N = 12
$\bar{X}$ = .17	$\bar{X}$ = 5.03
SD (n-1) = .26	SD (n-1) = .05

ZERO	10 gm
N = 12	N = 12
$\bar{X}$ = .09	$\bar{X}$ = 10.08
SD (n-1) = .09	SD (n-1) = .08

ZERO	20 gm
N = 12	N = 12
$\bar{X}$ = .14	$\bar{X}$ = 20.91
SD (n-1) = .09	SD (n-1) = .16

The "t" tests for the above readings are as follows: 95% confidence level the 2gm and 10gm reading was found to be accurate but some drift is evident in the 20gm increments; however, this is beyond the range in this present application.

2gm "t" = 0.438
10gm "t" = 0.495

TABLE 1

ZERO

N = 9

$\bar{X}$ = 11.49

SD (n-1) = .24

¼ TURN

N = 9

$\bar{X}$ = 22.38

SD (n-1) = .21

½ TURN

N = 9

$\bar{X}$ = 36.33

SD (n-1) = 1.05

3/4 TURN

N = 9

$\bar{X}$ = 55.02

SD (n-1) = .55

Force in grams as recorded on the instrument.

TABLE 2

Force measurement on the model.

Force gradient with advancing screw.

¼ TURN	½ TURN	3/4 TURN
22.38	36.33	55.02
11.49 -	22.28 -	36.33 -
10.89 gms	13.95 gms	18.69 gms

Average force in grams on the model.

N = 3 $\bar{X}$ = 14.52 gms SD (n-1) = 3.93

TABLE 3

Actual Pressure

¼ TURN	½ TURN	3/4 TURN
22.38	36.33	55.02
11.49	11.49	11.49
10.89 gms	24.84 gms	43.53 gms

TABLE 4

Unclasped ¼ turn	Unclasped ½ turn
0	N = 14
	$\bar{X}$ = 12.25
	SD (n-1) = 1.25

Force in grams in the mouth (unclasped.

TABLE 5

In mouth ¼ turn (clasped)	In mouth ½ turn
N = 15	N = 14
$\bar{X}$ = 7.05	$\bar{X}$ = 18.37
SD (n-1) = 1.44	SD (n-1) = .83

In mouth 3/4 turn

N = 11

$\bar{X}$ = 36.25

SD (n-1) = 1.39

Force in grams in the mouth (clasped)

TABLE 6

Force in gms, fall-off over time.

TIME	FORCE
8.30am	29.00 gms
9.00	27.7
9.30	19.0
10.00	10.4
10.30	14.5

TIME	FORCE
11.00	28.00 gms
11.30	20.5
12.00pm	21.9
12.30	16.3
1.00	11.7
1.30	16.00

TABLE 7

Force reading over time using standard weight 20 gms.

ZERO = 3.7	TIME	WEIGHT
	9.00am	23.4 gms
	9.30	23.8
	10.00	24.00
	10.30	24.00
	11.00	24.1
24 hrs later	11.00	24.3

TABLE 8

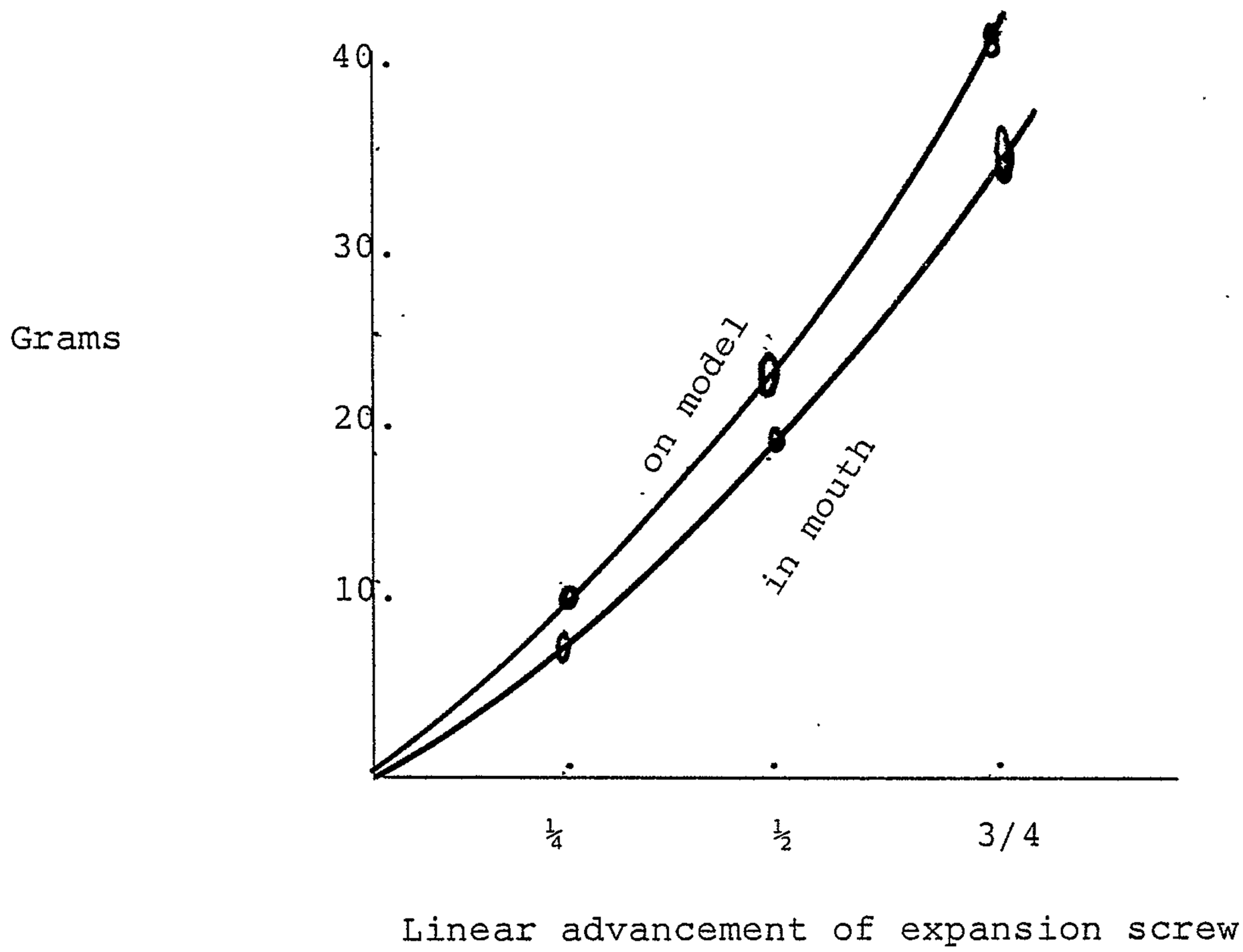

¼ turn	.2mm	7.38 gms	SD 0.72	SE 0.19
½ turn	.4mm	18.37 gms	SD 0.86	SE 0.25
3/4 turn	.6mm	36.25 gms	SD 1.39	SE 0.42
				95% confidence

Force Measurement in the Mouth in gms.

TABLE 9

¼ turn	.2mm	10.89 gms	SD .21	SE 0.07
½ turn	.4mm	24.85 gms	SD 1.05	SE 0.35
3/4 turn	.6mm	43.53 gms	SD .55	SE 0.18

Force Measurement on the model in gms.

TABLE 10

CHAPTER 13

DISCUSSION

DISCUSSION

A new technique must have something other than uniqueness to recommend it for acceptance. Let it first be said that the TISSUE PRESSURE TECHNIQUE does not have universal application in all palatally placed canines; differential diagnosis and acceptable screening must separate the potentially successful from all others. Then a degree of determination must be exercised by the operator even if only to encourage the wearer in full-time co-operation.

Those cases which are so close to erupting and yet fail to do so attract the T.P.T. approach with a fairly certain knowledge of success. Further, it has been noted that many patients prefer to avoid surgery and, in fact, have such a fear of it that treatment would be declined. The T.P.T. approach is readily accepted by these people and the final result usually satisfactory.

More research is needed to determine the optimal angulation of the expansion screw, several suggestions have been made and present thinking favours a force, which tends to stretch the gubernaculum dentis.

Expansion of the anterior maxillary dental arch has also proved successful in several cases and here research must continue.

Orthodontics by its very nature is a slow process and much time must pass before conclusions can be drawn. However, it seems now certain that palatal pressure on the soft tissue over-lying certain palatal canines will induce them to erupt into the dental arch.

The tissue changes that take place under the T.P.T. pad have not been investigated, and one can only conjecture as to the mechanism involved. The force used in approximately 4.47gms/cm² and this must be transmitted through the soft tissue and bone to the soft tissue of the capsule surrounding the crown of the tooth. There needs to be study of the pressure within the capsule during this treatment.

Finally, Table 11 shows the time factor involved in the treatment of 14 cases.

Time factor using T.P.T.

CASE	TIME TO EMERGENCE	TOTAL TIME	SEX
1	10 mths	17 mths	F
2	16	29	F
3	23	43	F
4	18	33	F
5	6	not returned	M
6	12	17	F
7	10	19	M
8	23	incomplete	F
9	3	not returned	F
10	5	20	F
11	14	19	F
12	4	26	M
13	5	11	F
14	14	19	M

TABLE 11

CHAPTER 14

FUTURE DEVELOPMENT

FUTURE DEVELOPMENT

After having used the Tissue Pressure Technique for 5 years it is now becoming evident that primary emphasis should be placed on providing adequate space. This has of course been stated over many years and is really self evident.

There are two ways of obtaining space: the first is extraction - usually the first bicuspid is the tooth of choice. However, as mentioned previously one has to remember the need for space closure if there is failure to recover the canine.

The second way to gain space is to move the incisor segment forward by using a tissue pressure appliance with the target area covering the alveolar process lingual to the central and lateral incisors. It has been found that this movement alone is often sufficient to induce the palatal canine to move into a buccal position and then continue its eruption unimpeded by its previous palatal impaction. In other words there is not need for pressure directly on the canines although they do receive some force because there is a lateral component produced due to the curved face of the target area. I rather think that this approach will prove more effective than the first one described.

Angulation of the expansion screw is also of significance. It was first postulated that the screw should be set at right angles to the tangent of the plane of soft tissue covering the lingual aspect of the crown of the unerupted tooth (Easthope 1982). However, we have had results

when the screw is set so that its line of action is at approximately 5° to the occlusal plane. It could be that this force stretches the gubernaculum in the direction of the occlusal plane thus stimulating the tooth to erupt. (Cahill & Sandy, 1980).

Early diagnosis would seem to advantage early intervention with less chance of impaction but it would be unlikely if total radiographic screening of the population is warranted to detect 1.5% - 2.5% of patients with this problem (Rohrer 1928, Rayne, 1969, McKay 1978). Age does not seem to place a barrier on success, even with the tissue pressure technique (Easthope 1982). It seems desirable to await the eruption of 17 to 27 to improve retention of the appliance when using this approach. So one wonders if there is an advantage with early intervention in the mixed dentition stage.

A further study is the use of soft tissue acrylic liner on the target area. While tissue discomfort is not experienced when the edges of the target plastic are chamfered it could be that the soft acrylic may induce better results than normal hard acrylic. This has not been tried.

Further research yet remains in studying the pressure (if any) produced within the capsule of the unerupted tooth. Tension within the gubernaculum dentis also needs to be investigated thus providing some evidence to explain the mechanism of tooth movement.

The subject has been introduced by this Thesis and it is to be hoped that further investigation will be continued.

CHAPTER 15

CONCLUSION

CONCLUSION

Discovered by accident and now developed into a predictable procedure, the "Tissue Pressure Technique" is an effective and easily workable procedure to recover certain palatally impacted canines. It is submitted to the Dental profession as an addition to the knowledge of Orthodontics.

There is a justifiable sense of elation when a previously impacted canine presents itself at the point of emergence normal to the line of the arch. It was thought that I may have been alone in this reaction until I received a letter from a fellow practitioner who had tried the method with success, and I refer to the enclosed letter. (Newman Original Communication)

It is my hope that others will try the method and with continual refinement it will become more widely applicable to palatally impacted canines.

APPENDIX 1

Materials

1.1 Clasp Wire .9mm
.7mm
Remanit hard drawn stainless steel
Source Rudolf Gunz Pty Ltd

2.1 Rapid cure plastic Orthocryl
Pink or clear
Source Rudolf Gunz Pty Ltd

3.1 Dental Plaster
Source Dental Supply Houses

4.1 Expansion Screws Dentaurum 600-611
Source Rudolf Gunz Pty Ltd

5.1 Strain Gauge
Source Applied Measurements Australia Pty Ltd

6.1 Read-out equipment RD 201A
Source Applied Measurements Australia Pty Ltd

7.1 Hydroflask
Source Dental Supply Houses

APPENDIX 2

Personal Communication

21-2-84

All Communications to be addressed to The Secretary.

In reply please quote this Number:

Dental Clinic
Hospital
Walker St.
Maryborough 4650

Dear Dr Easthope,

ages & ages ago I wrote and asked about moving some palatal 3's in a kid who was 14 or 15 at the time and had retained C's.

Well - there's good news to report. The 3's are through, in their right spots, in good rotation and if you didn't know that something was wrong in the first place you'd never guess.

So thanks, you're a genius.

I'd have written sooner except that the kid left school had a job kept a very low profile and I haven't seen him for a year at the surgery.

I saw him in a shop 6 mths ago and made him open his mouth. The $\overline{3|}$ was half erupted and the $+^3$ not visible, he complained of 'problems' there. I doubt he's work his plate in 9 mths.

At the moment the $^3+$ is fully erupted and the $+^3$ about 3/4 down. So I'm really happy.

Thought I'd pass on the good news. & Thanks

Yours faithfully
McNeuman.

APPENDIX 3

Calibration of pressure measuring appliance using standard balance weights. 0-10mv/v Span 4.75.

2 gm	5 gm	10 gm	20 gm
2.0	4.9	9.9	20.6
2.0	4.9	9.9	20.7
2.1	4.9	10.0	20.7
1.9	4.9	10.0	20.8
1.9	4.9	10.0	20.8
1.9	4.9	10.0	20.9
1.9	5.0	10.1	20.8
2.1	4.9	10.0	20.8
2.0	5.0	10.1	20.8
2.0	5.0	10.1	21.0
2.0	5.0	10.0	20.3
2.1	4.9	10.0	21.0
$\bar{x}$ 1.99 gms	$\bar{x}$ 4.933 gms	$\bar{x}$ 10.008 gms	$\bar{x}$ 20.76 gms
S.D. 0.079	S.D. 0.049	S.D. 0.067	S.D. 0.187
S.E. 0.022	S.E. 0.014	S.E. 0.019	S.E. 0.054

APPENDIX 4

Force measurement on the model.

Zero	¼ Turn	½ Turn	3/4 Turn
11.9	22.7	38.4	54.9
11.9	22.3	37.4	54.2
11.5	22.3	36.7	55.5
11.4	22.6	36.1	55.8
11.4	22.4	35.8	54.7
11.3	22.6	35.0	55.6
11.4	22.2	35.5	55.3
11.3	22.2	36.4	54.6
11.3	22.1	35.7	54.6
N = 9	9	9	9
$\bar{X}$ = 11.49 gms	22.38 gms	36.33 gms	55.02 gms

Actual force Increments.

22.38	36.33	55.02
11.49 -	22.38 -	36.33 -
10.89 gms	13.95 gms	18.69 gms

APPENDIX 5

Force Measurement in the Mouth Clasped.

¼ Turn	½ Turn	3/4 Turn
9.0 gms	18.7 gms	35.6 gms
6.8	19.5	38.3
8.4	19.9	37.3
7.9	19.3	36.3
7.4	18.1	38.3
7.2	18.1	34.2
7.3	19.0	34.1
7.1	18.1	35.7
7.3	17.8	36.7
7.5	17.5	36.1
6.3	17.2	36.2
7.8	17.7	
6.6		
6.7		
N = 14	N = 12	N = 11
$\bar{X}$ = 7.38 gms	$\bar{X}$ = 18.4 gms	$\bar{X}$ = 36.25 gms
SD (n-1)= .72	SD(n-1)= .86	SD(n-1)= 1.39
SE = 0.19	SE = 0.25	SE = 0.42
95% confidence	95% confidence	95% confidence

APPENDIX 6

Area of Pressure Pad - in cm^2.

1.6	1.8
1.7	1.4
1.7	1.7
1.6	1.6
1.6	1.6
1.7	1.7
1.6	1.7
1.6	1.7
1.9	1.7
1.6	1.6
1.7	1.6
1.6	1.8
1.6	1.6
1.6	1.7
1.6	1.7
1.6	1.7
1.7	

Total: N = 31

$\bar{x}$ = 1.65 cm^2

S.D. = 0.116

S.E. = 0.021

BIBLIOGRAPHY

Acherman J.L. and Field H.J. (1935) Quoted by Mulick K. (1981) op. cit: 825.

Andreasen G.F. (1971) A review of approaches to treatment of impacted maxillary cuspids. J. Oral Surg. 31: 479-484.

Angell D.M. Wazzow G.C. and Meister F. jnr. (1974) Palatal pain associated with bilaterally impacted cuspids.J. Oral Surg. Oct: 382.

Angle E.H. (1906) Malocclusion of the Teeth. Mosby Co. St. Louis:161.

Ibid. 354.

Ibid. 566.

Ibid. 582.

Azaz B. and Shteyer A. (1978) Resorption of the crown in impacted maxillary canine. Int. J. Oral Surg. 7:167-171.

Barnes M.J. and Kodicek E. 1972 in Berkovitz (1975A) Op. cit:19.

Barnes V.E. (1923) Orthodontic eruption of impacted cuspids and incisors. J. Am Dent. Assoc. 10:1167-1175.

Bassett C.A.L. (1971) Biophysical Principles Affecting Bone Structure. In Bourne G.M. (ed.) Biochemistry and Physiology of bone Vol. 3. Development of Bone 2nd Ed. London Academic Press:1-76.

Becker A. and Zilberman Y. (1975) Combined fixed - removable approach to the treatment of impacted maxillary canines. J.C.O. 9:162-169.

Becker W. and Hensel S. (1979) Method of measuring soft part pressure in the oral cavity. Zahn. Mund. Keiferheilkd. 67:497-506. (Translation by Mrs Lisetotte Szlavek, Newcastle University).

Begg P.R. and Kesling P.C. (1971) Begg Orthodontic Theory and Technique. Philadelphia W.B. Saunders & Co. 2nd Ed.:629-647.

Berkovitz B.K.B. (1974) The effect of Vitamin C deficiency diet on eruption rates for the guinea pig lower incisor. arch. Oral. Biol. 19(a):807-811.

Berkovitz B.K.B. (1975a) Theories of Tooth Eruption in the Eruption and Occlusion of Teeth. Poole D.F.G. and Stack M.V. (Eds.). Proceedings of the 27th symposium of Colston Research Society, Butterworth, London. 193-201.

Berkovitz B.K.B. (1975b) in Lavelle C.L.B. Op. Cit:108-109.

Bishara S.E., McNeil M.H. and Osterle L.J.O. (1976) The management of impacted canines. Am. J. Orth., 69:371-386.

Boyle P.E. (1955) Kronfelds Histopathology of the Teeth. 4th Ed. Kimpton London:335.

Brash J.C. 1928 The growth of the alveolar bone and its relation to the movement of teeth including eruption. Int. J. Orth. 14:196-223.

Bryer L.W. (1957) An experimental evaluation of the physiology of tooth eruption. Int. Dent. J., 7:432-478.

Burstone C.J. and Groves M.H. (1960) Threshold and optimum force values for maxillary anterior teeth movement. J. Dent. Res., 39:695.

Cahill D.R. and Sandy G.M. (1980) Tooth eruption: Evidence for the cental role of the dental follicle. J. Oral. Path., 9:184-200.

Chapman R. (1983) M.D. Sc. Thesis Sydney University.

Clarke D. (1971) The management of impacted canines free physiological eruption. J. Am. Dent. Assoc., 82:838.

Constant T.E. (1900) The eruption of the teeth. Int. Dent. Congress 2:180-192 cited by Berkovitz (1975b):108.

Davidovitch Z., Finkelson M.D. Steigman S. et. alia. (1980). Electric curents, bone remodeling, and othodontic tooth movement. Am. J. Orth., 77(1):14-47.

Deporter D.A. (1980) Chap. 6 Oral Mucosa, in Ten Cate A.R. (1980) op. cit:104.

Easthope D.W. (1982) Presurgical recovery of palatally impacted canines. Aust. Dent. J., 27:94-97.

Encyclopaedia Britannica (1951) Vol 23:565.

Feldstein L. (1950) An instrument for measuring muscular forces acting on the teeth. Am. J. Orth. 36:856-859.

Freeman E. (1980) In Ten Cate A.R. (Ed.) Op. Cit.,:240.

Gensior H.M. and Strauss R.E. (1974) The direct bonding technique applied to the management of maxillary impacted canines. J. Am. Dent. Assoc., 89:1332-1337.

Gizewska G., Kuligowski W. and Michiewicz I.K. (1973) Use of a cut orthodontic screw for repositioning of a single permanent tooth. Protetyka Stomatologiczna, 23:36-42 English abstact.

Gould M.S.E. and Picton D.C.A. (1962) A method of measuring forces acting on the teeth from lips, cheeks and tongue. Brit. Dent. J., 112:235-242.

Ibid (1963) An evaluation of a method of measuring forces exerted by the tongue on the teeth., Brit, Dent. J., 114:175-180.

Harris G.M. (1882) Principles and Practic of Dentistry. Austen P.H. (Ed) Blackiston and Sons. Co., Philidelphia:420-453.

Heaney G. and Atherton J.D. (1979) Periodontal problems with surgical exposure of unerupted teeth. Brit. J. Orth., 3:79-85.

Hitchen A.D. (1956) Impacted maxillary canine. Brit. Dent. J., 100:1-14.

Hovell J.H. (1966) In Walther D.P. (1966) Op. Cit., 197.

Howard R.D. (1972) The displaced maxillary canine positional variations associated with incisor eruption. Dent. Prac., 22:279-287.

Hunter J.M. Quoted by Phillips W.H. (1969) Op. Cit., 35:267.

Johnston W.D. (1969) Treatment of palatally impacted canines. Am. J. of Orth., 56:590-596.

Korber K.H. (1970) Periodontal Pulsation. J. Periodont., 41:686-708.

Kusner W., Michaeli Y. and Weinreb M.M. (1973) The role of attrition and occlusal contact in the physiology of the rat incisor. Impeded and unimpeded eruption in hypophysectomised and magnesium deficient rats. J. Dent. Res., 52:65-73.

Lavelle C.L.B. (1975) Applied Physiology of the Mouth. John Wright and Sons, Bristol.:103, 108-109.

Lear C.S.C., Decou R.E. and Ng D.H.P. (1974) Threshold levels for displacement of human maxillary central incisors in response to lingually directed forces. J. Dent. Res., 53:942.

Lebret L.M.L. (1967) Quoted by Berkovitz B.K.B. (1975b) Op. Cit.:115.

Lefoulon J. (1841) Quoted by Angle E.H. (1906) Op. Cit:566.

Magnusson B. (1968) Tissue changes during molar tooth eruption. Transactions of the Rogal School of Dentistry. Stockholm and Umea. 13:1-122.

Mantell P.A. (1973) Circadian rhythm of mitotic activity in incisor pulp and the cornea of Rattus Norvegicus. Arch. Oral. Biol., 18:403-407.

Mansen J.D. (1968) Quoted by Berkovitz B.K.B. (1975b) Op. Cit.:104.

Massler M. and Schour I. (1941) Studies in tooth development theories of eruption. Am. J. Orth., 27:552-576.

Medak R., Weinreb M. & Sicher H. et alia (1952) The effect of single doses of irradiation upon rat incisors. J. Dent. Res., 31:559-574.

McKay C. (1978) The unerupted maxillary canine. Brit. Dent. J., 145(7):207-210.

Melcher A.H. and Beersten W. (1977) The biology of occlusal development. Monograph No. 7 Craniofacial Growth Series Centre for Human Growth and Development. Uni. of Michigan McNamara J.A. (Jun) (Ed) Ann Arbor Michigan:1-17.

Monteleus G.A. (1932) Quoted by Rayne (1969) Op. Cit. :195.

Moore J.R. and Gillbe G.V. (1968) Oral Surgery procedures in general practice. Brit. Dent. J., 125:550.

Moss J.P. and Picton D.C.A. (1970) Mesial drift in adult monkey, (Macaca Irus) when forces from the cheeks and tongue had been eliminated. Arch. Ora. Biol., 15:979-986.

Mostafa Y.A., Weaks-Dybuig M. and Osdoby P. (1983) Orchestration of tooth movement. Am. J. Orth., 83(3):245-250.

Moyers R.E. (1973) Hand Book of Orthodontics 3rd Ed. Year Book Medical Publisher. Chicago:102-103.

Mouser P. (1985) Dept. Oral Surgery Faculty of Dentistry Sydney University Sydney N.S.W.

Mulick J.F. (1981) Impacted canines. Can. Dent. Serv. Bul., 13:824-826.

Ness A.R. (1967) In Theories of Eruption. Berkovitz B.K.B. (1975a) Op. Cit.:18.

Ness A.R. (1970) In Theories of Eruption. Berkovitz B.K.B. (1975a) Op. Cit.:19.

Odenrick L. and Modeer T. (1978) Periodontal Status following surgical orthodontic alignment of impacted teeth. Acta Odontol. Scand., 36:233-236.

Phillips W.L. (1969) Organ Transplant. New York St. Dental. J., 35:267-71.

Rayne J. (1969) The unerupted maxillary canines. Dent. Pract., 19:194-198.

Reitan K. (1964) Effects of force magnitude and direction of tooth movement on different alveolar bone types. Angle Orthod., 34:244-255.

Reitan K. (1969) In Walther D.P. (Ed) Op. Cit.:197.

Rohrer A. (1928) Displaced and impacted canines. Internat. J. Ortho.,15:1003.

Rubin R.M. (1976) Management of impacted canines. J. Clim. Orth., 10:922-923.

Salzmann J.A. (1957) Orthodontics Principles and Prevention. J.B. Lippincott and Co. Philadelphia :337.

Ibid (1966) Practice of Orthodontics Vol. 2. Lippincott and Co. Philadelphia:823-825.

Schour I. and Van Dyke M.B. (1932) Changes in the teeth following hypophysectomy. Changes in the incisors of the white rat. Amer. J. Anat. 50:397-433.

Scott J.H. and Symons N.B.B. (1971) Introduction to Dental Anatomy 6th Ed. Livingston, London:101.

Scott J.H. (1953) How Teeth erupt. Dent. Pract.,3: 345-350.

Shoshan S. and Finkelstein S. (1968) Studies in collogen cross linking in vivo, Biochimo Biophys. Acta., 154:261-263.

Shoshan S., Pisanti S. and Sciaky I. (1967) The effect of hypervitaminosis D on the periodontal membrane collagen in Lathyritic rats. J. Periodont. Res., 2:121-126.

Sicher H. (1942) Tooth eruptions, axial movement of tooth with limited eruption. J. Dent. Res., 21:395-402.

Squire C.A. and Hill M.W. (1980) in Ten Cate A.R. (Ed).Op. Cit.:381-383.

Stangle D.P. (1974) Conservative treatment of palatally impacted canines. Am. J. Orth., 69:328-334.

Storey E. (1972) Nature of tooth movement. Am. J. Orth., 63:292-314

Taylor G.S. (1978) Simplified sectional arch to align palatally displaced maxillary canines. J. Clin. Orth., 13:847.

Ten Cate A.R. (1980) Oral Histology Development Structure and Function. The C.V. Mosby Co. St. Louis.

Thomas N.R. (1967) The properties of collagen in the periodontium of an erupting tooth. In the mechanism of tooth support. John Wright, Bristol, 102-106. Quoted by Berkovitz (1975a) Op. Cit.

Utley R.K. (1968) The activity of alveolar bone incident to orthodontic tooth movement as studied by oxytetracycline induced fluorescence. Amer. J. Orth., 54:167-201.

Van Hassel H.J. and McMinn R.C. (1972) Pressure differential favouring tooth eruption in the dog. Arch. Oral. Biol. 17:183-190.

Walther D.P. (Ed) (1969) Current Orthodontics. John Wright and Sons. Bristol.

Williams B.H. (1981) Diagnosis and prevention of maxillary cuspid impaction. Angle Orth. 51:30-39.

Wisth P.J., Mordeval K. and Bie O.E. (1975) Comparison of two surgical methods in combined surgical orthodontic correction of impacted maxillary canine. Acta. Odont. Scand., 34:53-57.

Zilberman Y. (1978) Palatally impacted canines, a new approach to treatment. Am. J. Ortho., 74:422-428.