

AN ANALYSIS AND REVIEW OF CLEFT LIP

AND CLEFT PALATE PROBLEMS

(ORIGINAL COPY.)

John Cumming Jnr. B.D.S.

(Sydney University.)

Original Copy for Professor A. J. Arnott,  
Dean of the Faculty of Dentistry (University  
of Sydney).

This thesis is presented as part fulfilment of the requirements for the  
degree of Master of Dental Surgery in the University of Sydney, and  
contains both original material and a critical survey of available literature.

John Cumming Junr. B.D.S.

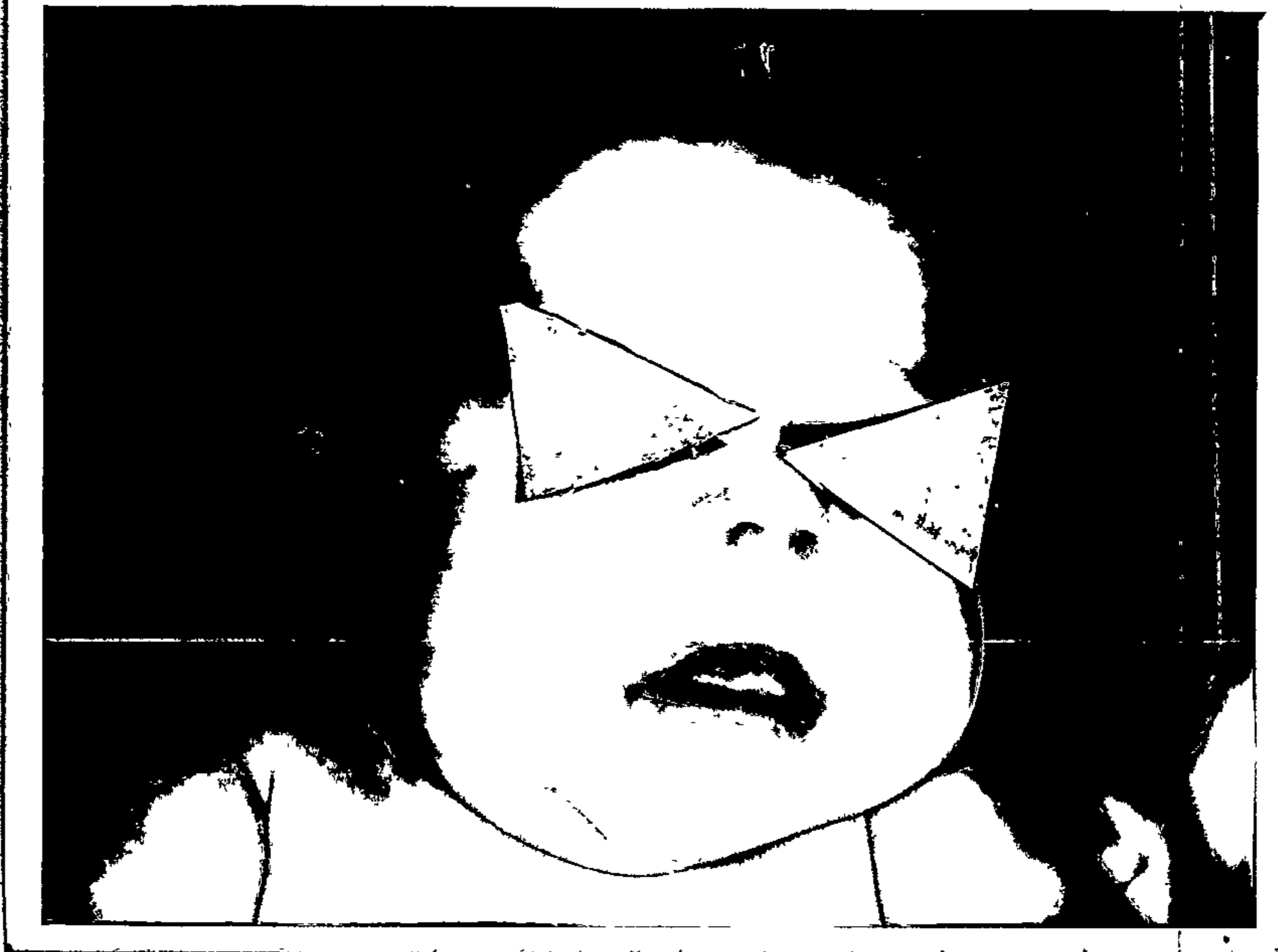
<u>PART I</u>	<u>Page 1 - 136.</u>
<u>Part II</u>	<u>Page 137 - 236</u>
<u>Part III</u>	<u>Page 237 - 283.</u>
<u>BIBLIOGRAPHY</u>	<u>Page 284 - 292.</u>

PREFACE.

I am deeply indebted to those associated with the Royal Alexandria Hospital for Children, who have assisted the production of this review of material, both clinical and literature, over the past four years.

PART I

	<u>Page</u>
CHAPTER I - Aetiology	4.
CHAPTER II - Hereditary and its influence on clefts.	
CHAPTER III - A short history of cleft lip and cleft palate surgery.	
CHAPTER IV - Embryology and pathological histology of clefts.	
(a) Classical theory	
(b) Mesodermal penetration theory	
(c) Discussion on embryology and pathology	
(d) Summary.	
CHAPTER V - Surgery and oral surgery.	
(a) Introduction	
(b) Surgery, its aims and limitation.	
(c) Surgical anatomy and physiology	
(d) Classification and surgical pathology	
(e) Surgical technique	
Clinical assessment	
Nasal cleft	
Macrostomia	
Unilateral cleft lip - surgical repair	
Bilateral cleft lip - surgical repair	
The cleft palate - repair.	
CHAPTER VI - Variations in the Teeth.	
CHAPTER VII - Feeding Problems . . .	
CHAPTER VIII - Radiography	
CHAPTER IX - The "Group System" treatment.	



The Anterior View of - The Normal Child at Birth

Figure I

The Normal Child at Birth



Figure II

The Anterior View of

The Cleft Lip and Cleft Palate Child at Birth

This abnormality presents a unilateral cleft lip, alveolus, with a cleft hard and soft palate.

Intra oral examination will show the communication between the oral and nasal cavities with anatomical destruction of the normal oronasal pharyngeal communication posterior to the soft palate.

The distortion of the left nares is visible with rotation of the



premaxilla to the normal side.

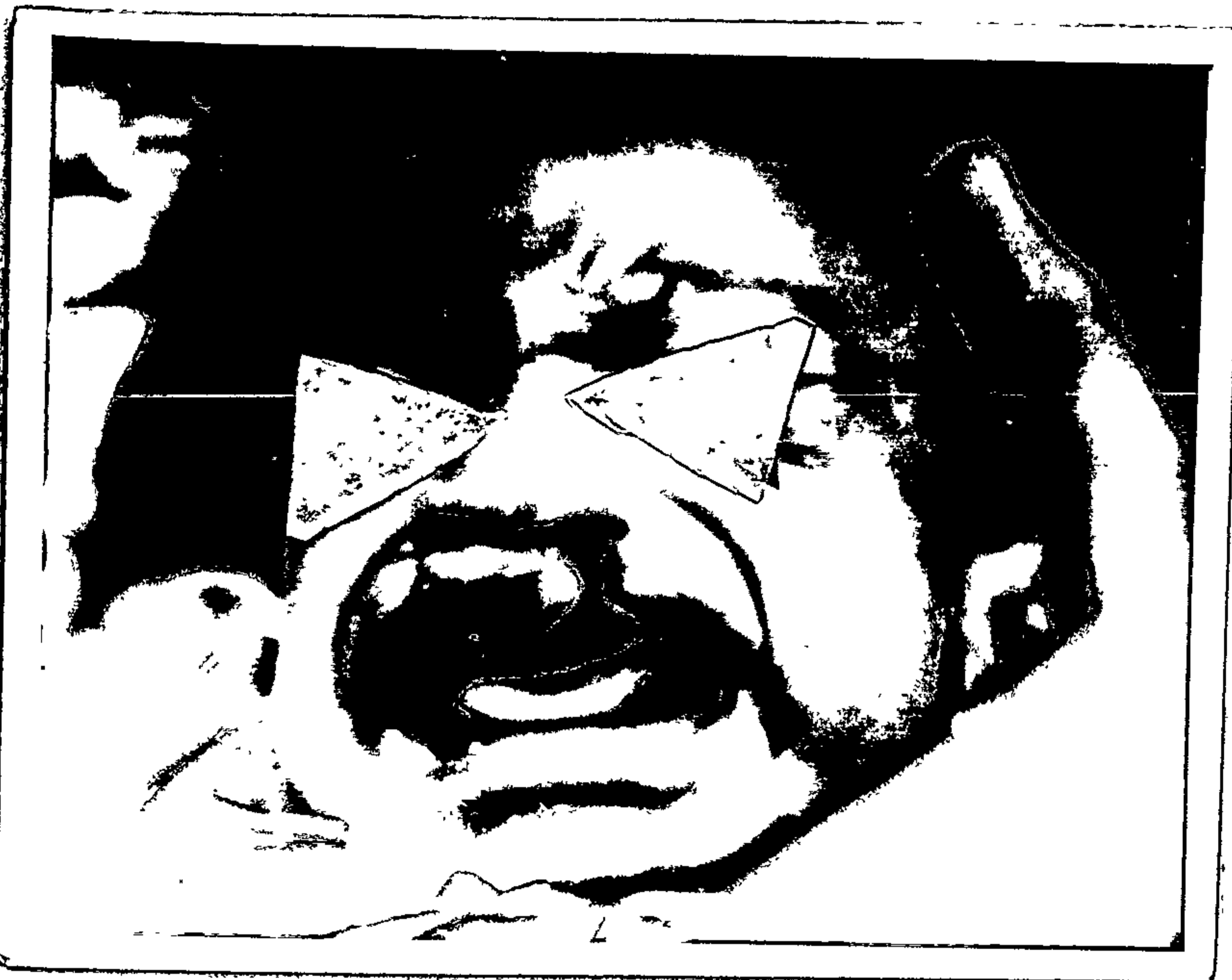

Figure 3.

The anterior view of -

a similar condition before surgical intervention showing the deviation of the nostril to the unaffected side.

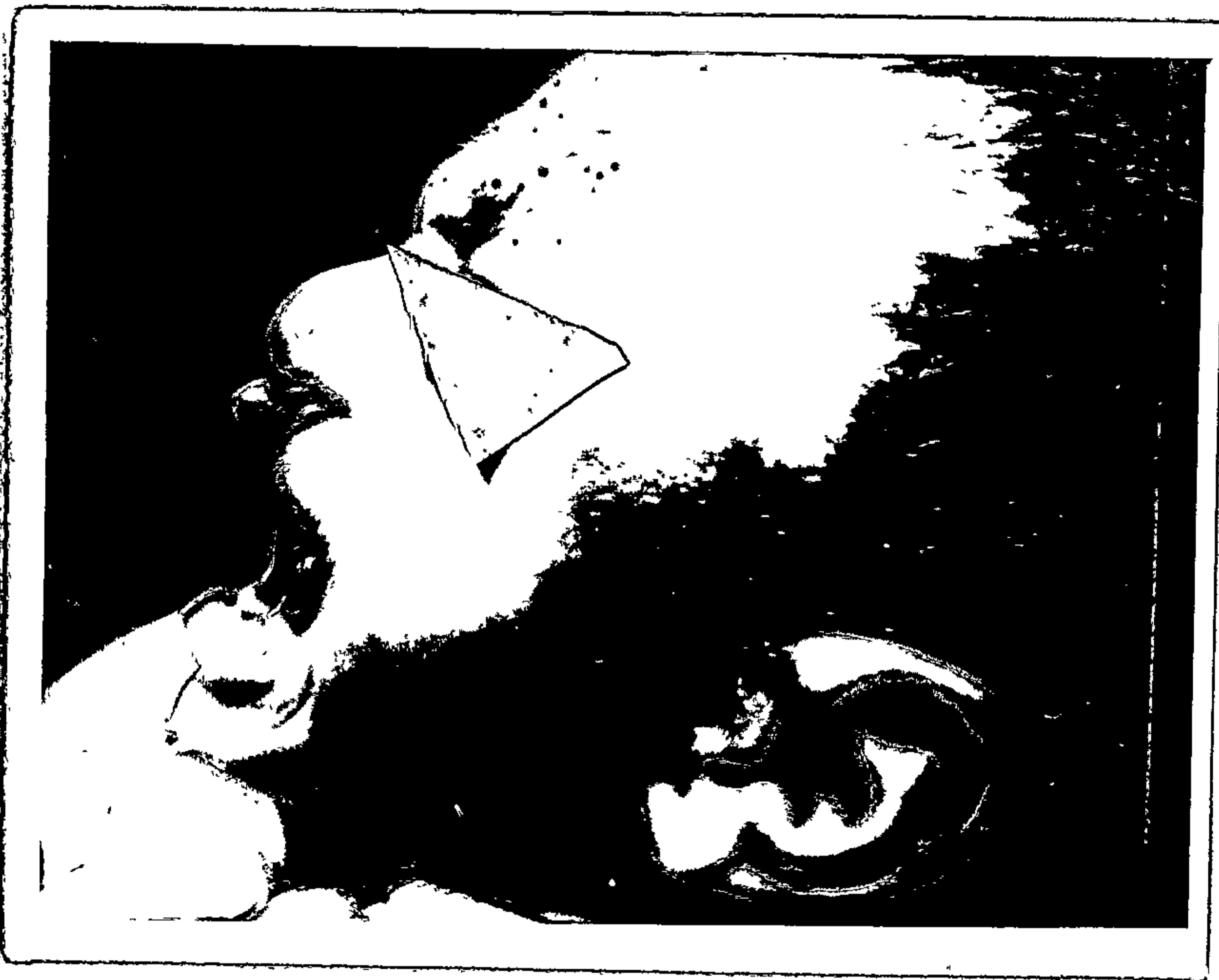

Figure 4.

A Lateral Profile of -

The same condition as in the previous photograph. Here may be seen the "flung" premaxillary element and the short drawn columella resulting in flattening of the alar nasal cartilages and distortion of the lower half of the nose.

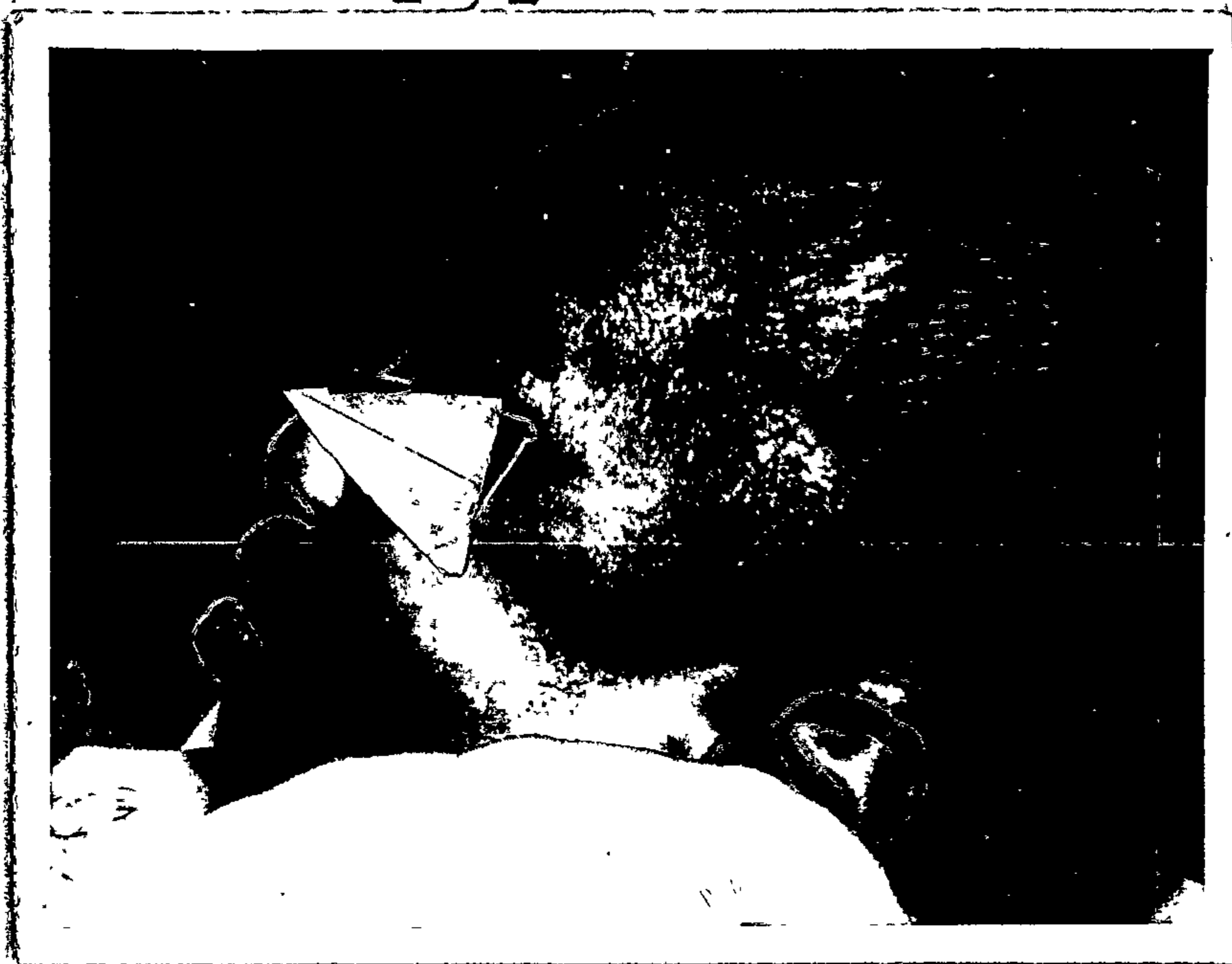

Figure 5.

A lateral profile of the previous case following surgical repair.

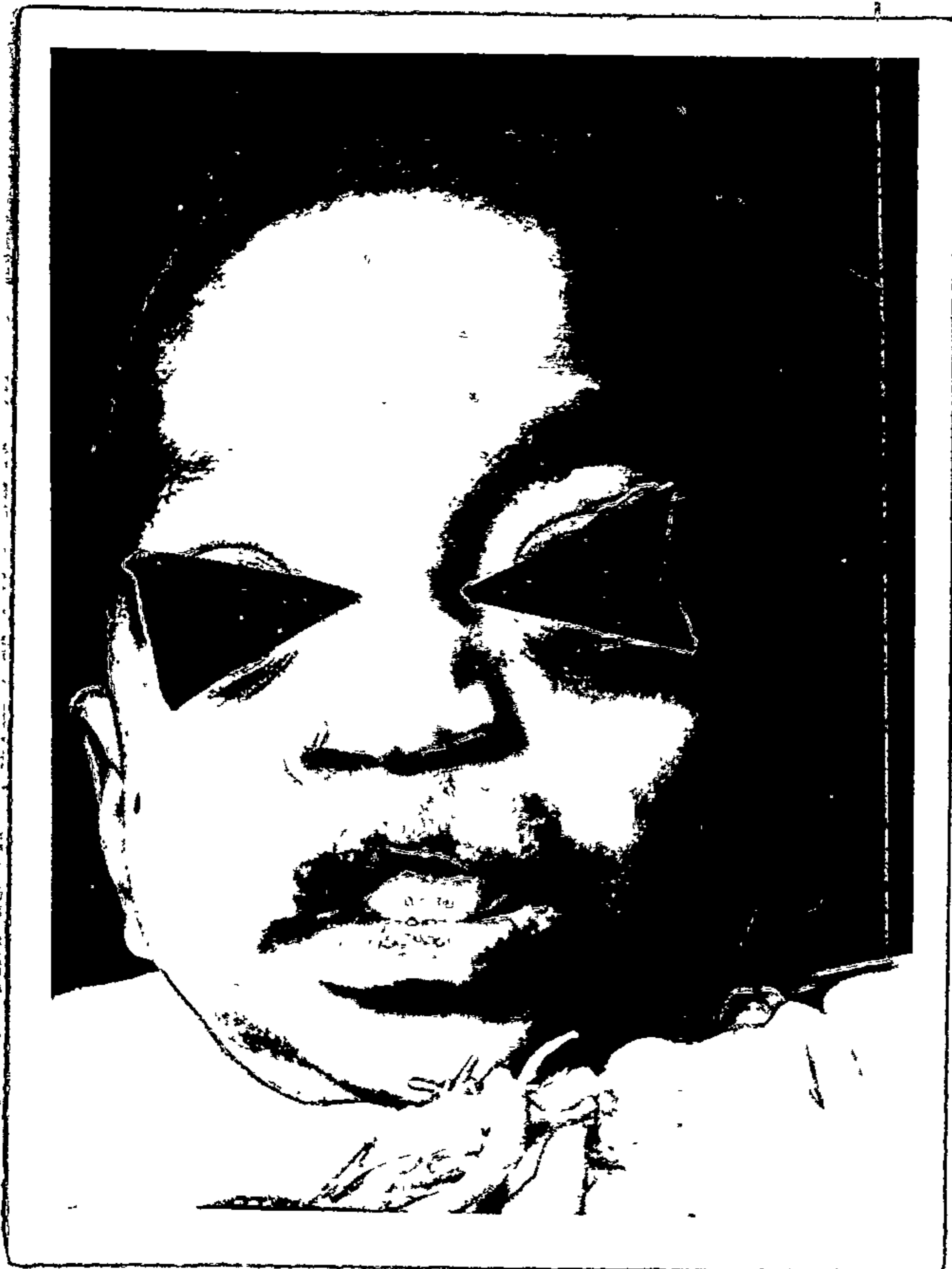

Figure 6.

The change from the previous photograph is dramatic and the mother's reaction psychologically to this improvement in appearance and function in suckling is well comprehended.

Anterior view of the previous case following surgical intervention and repair of the maxillary lip. The defect here is on the right side. Here may be viewed the slightly flattened nostril and often short columella that frequently follows this surgery. These factors require secondary repairs in later years, when the facial tissue has further developed and the nostrils are more elevated.



A E T I O L O G Y

Aetiology: May be described as the search for the initiation of clefts of the face, lips, alveolar process and hard and soft palates. The study has been based upon pathological findings and interest has increased in this field. It is hoped to obtain a full understanding of the aetiology, for it is fully appreciated that prophylactic and rational therapeutics are the modern scientific weapons, and as yet are unused.

Treatment today is empirical and symptomatic and the clarification of aetiology will open the doors to medicine.

A wide diversity of antecedents suspected have been investigated and have only indicated, to date, the complexity of the situation. Aetiological causes may be divided into primary factors known as initiating, exciting or immediate. Secondary factors are contributing or predisposing and stand in contrast to the initiating cause.

It is realised that the initiating agent largely determines the pathological and clinical forms, whilst the contributing cause decides incidence, variation and extent. The initiating causes are still unknown, and many theories have been proposed and fallen by the way side. What has applied to experimental animal has not applied to man and has only tended to further cloud the issue. Counter measures to the cleft condition do not appear to exist and the literature explored does not seem to assess any method for its prevention. No doubt the incidence per 1,000 population in society is small and its priority of investigation and economic backing low in the scale. However to the individual affected, its handicaps are often a tragedy with far reaching psychological affects.

The clinical manifestations common to a large proportion of affected individuals are obscure and inconsistent and the aetiology remains a mystery.

Murphy<sup>34A</sup> has stated that the birth of a malformed child is preceded by a period of relative sterility, more often than is the birth of a normal sibling, and that Vitamin A deficiency, particularly in the rat has caused anophthalmia. Brophy<sup>33</sup> stated that the predisposing causes of clefts were -

- (1) Hereditary
- (2) Supernumery teeth
- (3) Intervening mucosa
- (4) Antenatal diet and nutrition.

Endocrine disorders of the thyroid, parathyroid, pancreas and suprenal gland have been fully investigated in relation to this subject and no correlation or association has yet been found. However, at Royal Victoria Hospital (America)<sup>34C2</sup> the research unit did find that congenital defects including cleft palate can be produced in the offspring of pregnant mice by the injection of cortisone for 3 - 4<sup>36</sup> days.

The application of the above to the human pregnancy has been substantiated by Harris & Ross<sup>48</sup> who submitted observations of Cleft Palate (Veau Class II palate<sup>83</sup>; the non genetical group<sup>34</sup> following Cortisone<sup>67-48-83</sup> therapy commenced at the 38th day. In the case cited 100 mgn Cortisone and 400 mgn totazoline were administered daily for dissiminated Lupus Erythematosus,<sup>115-116-117</sup> the aetiology of which is unknown.

The information although indicative is not conclusive, the number of cases examined being too low to establish a definite relationship. Further incidence with detailed research will clarify the position.



Oldfield, in an appraisal of the article by Harris & Ross, claims that the defect which occurred with cortisone therapy during the period of palatal development is merely a lack of fusion and not a lack of soft tissue in the midline of the foetus.

It may be added that a similar occurrence was found with malaria in mice.

Abnormal conditions, such as weight loss, haemorrhage and attempted abortion during pregnancy were not influencing factors.<sup>34</sup> Menstrual irregularity prior to pregnancy was found to have no predisposing influence towards initiating cleft lip and palate in the unborn child.

Boedecker of Berlin postulated that in the formation of the teeth the mucosa dips deeply down into the sub-mucosa giving an epithelial lamina, later contracting into an epithelial cord from the distal end of which the enamel organ arises. Retention of this epithelial lamina associated with the force exerted by the tongue and mandible upon the palate of the foetus in the flexed position during periods of muscle tension, may pertain to cleft palates.<sup>87</sup>

<sup>33</sup> Brophy as early as 1923 claimed that the cleft palate and pharynx were wider at birth than normal, a fact substantiated today by Cephalometry.<sup>100</sup>

The tongue has been shown to fill the mouth at the 2nd and 3rd months and lies between the two maxillae.<sup>57-87-96</sup>

After birth it is constantly being elevated into the cleft condition with a thrusting movement.<sup>100-115-17.</sup> This elevating movement brings a further lateral pressure to bear upon the maxillary gum

pads through the upward displacing force of the mandibular gum pads. The force is spring like and transitional and may be an influencing factor.

33

Professor Warnekoss is credited with producing one of the first substantial articles on supernumery teeth in cleft conditions in 1899. He claimed that clefts were frequently due to rudiments of supernumery teeth associated with failure of union. However, little has followed this hypothesis and it has fallen from view.

36-102

The late Professor His was of the opinion that cleft of the palate resulted from irregular and inco-ordinated growth of the three elements which form it, followed by irregular fusion of these three parts in the latter month of foetal life. Little to date has been presented in the literature to disprove this assumption, the only change being the theory of embryogenesis.

The factor of shock during pregnancy causing a cleft appears to be groundless. Most mothers when questioned cannot remember any phase or accident severe enough to attribute to pre-natal disturbances.

Intra uterine causes suspected of predisposing to clefts have been recorded as disturbances of the amniotic fluid, foetal position, maternal health and nutrition, and varied abnormal biochemical concentrations.

34a

Chapple and Davidson in 1941 concluded that deviation of the jaws, torticollis and club foot may be induced by abnormal foetal positions.

34a

Straus Olson, Hale and Evans in experimental animal nutrition were able to show that vitamin deficiency, if severe enough could result in cleft palate as well as other developmental anomalies.



Acute infectious diseases (german measles) were shown by

34A

Swan of South Australia to produce malformations in children.

Cleft palate was amongst these defects. Diabetes in the pregnant

woman produced multiple malformations in children. Endocrine

imbalance was suspected of preceding the Diabetic phase.

Frequently found associated with cleft lip or palate are:

1. Mental impairment.
2. Club foot and dermoid cysts.
3. Syndactyly, & Polydactylism of the hands and feet.
4. Interventricular Septal defect and other congenital heart defects.
5. Impaired hearing.
6. Inarticulate speech.
7. Spina Bifida.
8. Inguinal Hernia.
9. Hydrocele.
10. Cervical ribs.
11. Pierre Robins syndrome, displaying - Cleft palate, Micrognathic mandible, Glossoptosis.
12. Klippel - Feil Syndrome (short immobile neck).

Oro Facial disturbances are -

1. Supernumery teeth.
2. Benign Fibrous Tumours of the Palate.
3. Cross Bite Malocclusion.
4. Flattened Facial appearance.

My own observations derived from the cleft palate clinic of the Royal Alexandria Hospital for Children, Sydney, indicate an apparent increase in the caries susceptibility and caries rate of the cleft child with great incidence in defective enamel formation.

133

The incidence of chronic otitis media was found by the otolaryngologist at the clinic to be quite high within this selected group.

The hearing defect very common with cleft palate and cleft lip may be of two types -

1. Neurological transmission derangement.
2. Ossicle, tympanic membrane or cochlear disturbances.

This condition occurs very frequently, as high as 45.9% cases.<sup>34a</sup>  
<sup>34a</sup> Anoxia, produced in mice resulted in such Oro facial clefts.

It is known, too, that the rapidly advancing differentiating.  
<sup>113</sup> tissue of the embryo is more vulnerable to anoxia than resting  
full differentiated tissue, accordingly this may be a predisposing  
<sup>115</sup> factor. Anaemia may be important also, as sites of localized  
cellular damage may result.

### I N H E R I T A N C E.

<sup>34A</sup> Fogh Anderson has stated that a notable percentage of occurrence of clefts follows Mendelian laws of transference in dispersion of the "seed", and frequent reference will be made to this factor.

The rat has proved a useful animal for examination of inheritance,<sup>34c</sup> and has been tried for this abnormality. Previous examination by research workers of the grey lethal and screw-tail<sup>53</sup> mouse which are recessive mutants, displayed failure of bone resorption in response to stimuli exerted by the growing tooth germ. The gene responsible donates this primary affect and secondarily results in malformation of the crown and root and failure in eruption.

This is given to illustrate that genetic defects may appear as primary or secondary and must not be confused with the results of a recessive gene abnormality that may appear.

<sup>115</sup> Cleidocranial Dysostosis, a rare mesodermal syndrome inherited as a Mendelian Dominant factor comprising non eruption of the teeth with malformation of the crown and roots due possible to partial failure of the bone resorption mechanism is frequently associated with cleft palate.



36

Weiss points out that - "Morphogenetic aberration excess or deficiencies can be traced to individual excursions beyond the normal range of variability of some of the immediate conditions that regulate closing time and spacing of developmental activities.

Mutations are an important expression and should one occur, the suppression of a normal developmental process may occur, or even in-complete suppression resulting in deflection in the wrong direction.

The fact that different abnormal genes produce the same malformation, has been recorded in the literature.

36

Canick states that exact phenocopies (a phenocopy is an abnormality closely resembling a certain hereditary trait but produced by an influence on the individual himself and not his genetic constitution) of hereditary abnormalities may be produced by the agent affecting the tissues of the individual and not his genes. It was found also that hereditary factors may be influenced by skipped generations and where the anomaly of one type in the parent occurs, it may present anomalies of different types in the offspring.

The incidence of hereditary influence and association has not been assessed. <sup>34c P.8</sup> Figures varying from 15% to 55% have been recorded by various clinics and nothing substantial has yet been decided. There appears then a small percentage controlled by genetical influences.

Dietary deficiency it was noted may also be a contributing <sup>34AP.7</sup> cause but most unlikely an initiating one.

The abnormality within this selected genetical influenced group, like all such abnormalities will follow the same pattern as any other factor of inheritance, and will depend upon its selected

occurrence for a group of genes or one in particular on the chromosomes.

The passing of such characteristics from generation to generation follows Mendelian laws, affected only by imitations of the gene. The characteristic of the gene as illustrated previously may vary from complete dominance to complete recessiveness.

Since the somatic cells contain the diploid number and the re-productive cell the haploid number, every somatic cell will contain homologous chromosomes (one from each parent). A Homozygous condition applies where they are both dominant or both recessive. Heterozygous where one of each kind occupies the same locus on two chromosomes.

Cleft palate and cleft lip occurrence is said to be inherited as a conditioned dominant sex limited (male) abnormality with a recessive factor and that hereditary plays a part only in certain cases. It may or may not be the initiating factor and may be only a contributing factor of occurrence.

34A

Fogh Anderson claimed that the ratio of occurrence was 2.1 : 1.5 male to female. (range 1.1 to 2.1 has been quoted at times.)

Observations of clinical material over the last four and a half years at Royal Alexandria Hospital for Children, have indicated that the above facts are relatively correct.

The occurrence of the cleft palate lip abnormality was found to vary widely in the literature. The substantial results published were -

Davis (America)	-	1 in 915.
Fogh Anderson (Denmark)	-	1.5 in 1,000 born (some children born died during childhood)
Peron (Paris)	-	1 in 940



The incidence was found to vary between 1 in 750 and 1 in 950 of the recordings listed.

34A

In 1902 Garrod began research into the question of inheritance of Biochemical and metabolic abnormalities followed later by Harris and Haldane. These people have presented the inheritance of biochemical and metabolic disturbances, a field as yet little explored. No doubt with the greater strides occurring in biochemistry, new and enlightening facts will gradually unfold the story of tissue metabolism in all its complexities, both normal and abnormal growth patterns being understood biochemically.

Investigation of the electrolytic balance during the early months of pregnancy, have been conducted in women who have previously carried cleft lip and/or cleft palate children. These were done with little result, the electrolytic balance of the blood being within a normal range.

TABLE 1.

EXTRACT CLEFT PALATE BULLETIN

May, 1954

FREQUENCY OF CLEFT LIP AND/OR CLEFT PALATE

<u>YEAR</u>	<u>NAME</u>	<u>COUNTRY OR STATE</u>	<u>INCIDENCE AND PER 1,000</u>
1943	GRACE	PENNSYLVANIA	1:800 1.25
1950	IVY	DO	1:750 1.33
1949	OLDFIELD	ENGLAND	1:600 1.66
1946	HANBART	ZURICH	.8
1942	FOGH ANDERSON	DENMARK	1:665 1.5

---

The problem of hereditary and cephalo-facial growth are possibly two of the most important basic standard yet to be established in cleft palate research.

Hereditary can only be assessed by serial familial studies and comparison of group results as suggested by Payling Wright.<sup>113</sup>

Whilst there are many groups investigating these problems one of the most advanced is that working under the title of "Growth Centre" at the Graduate School of Medicine University of Pennsylvania. Their results are recorded.

The subdivisions of groups for genetic investigation had been many and varied.<sup>34A</sup> That proposed by Fogh Anderson is possibly one of the best and for its simplicity, is included.

Subdivision into two groups:

- A. Those where inheritance plays a part.
- B. Those where inheritance plays no part.

Group "B" refers to the clefts of the soft and hard palate group only, which appears to have a group without genetic control, a separate entity.

The "Growth Centre" Pennsylvania, produced, using a group of, (a) 39 boys average age 6 years 3 months with a range, 0 years 5 months to 18 years, (b) 21 girls, average age 8 years 4 months, range 2 years 6 months to 16 years 10 months, a recording that is published and quoted from their article "Cleft Palate Bulletin".<sup>34A</sup> Their classification was that of a Modified Dorrance (1933) and Fogh Anderson (1942), as follows:

- 1. Cleft Lip. (a) Lateral. (b) Bilateral.
- 2. Cleft Palate. (a) Velum alone.
- 3. Cleft lip plus alveolar process. (a) lateral. (b) Bilateral.
- 4. Cleft lip plus cleft palate. (a) Lateral (b) Bilateral.



5. Submucous clefts. (a) Velum only. (b) hard palate.  
(c) Velum plus hard palate.

Submucous clefts in the hard palate are detectable by X-ray, and in the soft palate by palpation. Consequently the errors introduced are governed by the experience and aptitude of the operators.

Fogh Anderson noticed that where inbreeding occurred, the incidence rose, and the frequency rose four times that of other regions. An extract from the previously cited article is included. This illustrates the incidence of occurrence.

TABLE II.

From Growth Centre - Graduate School of Medicine Pennsylvania.

Recorded: Cleft Palate bulletin. 1954.

	<u>Centre at Philadelphia</u>		<u>W. B. Davis</u>		<u>Danish Series Fogh Anderson</u>		<u>British Series</u>	
	<u>No.</u>	<u>%</u>	<u>No.</u>	<u>%</u>	<u>No.</u>	<u>%</u>	<u>No.</u>	<u>%</u>
Cleft Lip	6	10.9	133	14.3	138	22.1	88	17.6
Cleft Lip and cleft palate	28	50.9	606	64.6	360	57.6	245	49.0
Isolated cleft Palate	21	38.1	198	21.1	127	20.3	167	33.4
	55	99.9%	937	99.9%	625	100%	500	100%

Summarised the occurrence is -

	<u>Approx.</u>
1. Cleft Lip	25%
2. Cleft Lip and cleft palate	50%
3. Isolated cleft palate	25%

Unilateral cases were reported to be far more common than Bilateral cleft cases. Unilateral cleft ratio to Bilateral cleft was found to be approximately 3:1.

According to Danish statistics which were very close to those produced by the Philadelphia centre, isolated unilateral cleft lip occurred 6 to 7 times more frequently than bilateral Cleft lip. The frequency of occurrence of Unilateral Cleft lip and Palate compared to bilateral Cleft lip and palate varied from 3:2 to 1.2 to 1.0.

Fogh Anderson's data was from the best controlled, screened and selected material, and his classifications and statistical data well presented, being drawn from Danish patients mostly at Diakonissestiftelsens' Hospital, Copenhagen and patients from the Institute for speech defects.

The Philadelphia series suggest a single recessive gene with variable expressibility as the genetic inherited factor.

The total series comprised some 708 patients. <sup>34a</sup> W. B. Davis established that the incidence amongst negroes was low, being half that of American whites.

From observations it appears that the combined lip and palate condition has the highest frequency, a fact not supported by all. It has been observed that the other types, 1 and 3 are less severe expressions of this single abnormality.

Genetically it could be postulated that these three variations are separate phenotypic expressions of the same condition, a single gene being involved, and recent data appears to substantiate this hypothesis.

Should complete genetical control exist (but does not appear to) then a definite distribution map could be formed. Further examination indicated that the mildest and severest forms, cleft



lip, cleft palate and cleft lip occurred more frequently in the male whilst the cleft palate was found by Fogh Anderson to occur more in the female. British Studies did not substantiate this claim early, but have lately. (Oldfield)<sup>83</sup>

Findings proved conclusively in all groups and at the Royal Alexandria Hospital for Children that the incidence of Cleft lip either alone or associated with the palate abnormality was greater on the left side than on the right side, nearly twice as high an incidence. A similar circumstance exists in mice and dogs.<sup>34a</sup>

The frequent association with such conditions as syndactylism and club foot, etc. indicate that it appears to occur in families with a previous history of above abnormalities.<sup>115-34A</sup>

This manifestation of various congenital malformations amongst members of a family has been noted universally.

Fogh Anderson claimed the familial disposition (occurrence amongst kindred for same anomaly group) to be 27% in the cleft lip group, 41% in the cleft lip and palate group and 19% in the isolated cleft palate, but in Oldfields sample of 500, a familial disposition of only 11% was noticed for isolated cleft palate.

To substantiate that hereditary is aetiological factor<sup>34a</sup> Fogh Anderson found that in a survey of 131 pairs of twins, 26 from his own series, greater concordance of occurrence existed amongst monozygotic than amongst di-zygotic twins.

The twin material indicated also that isolated cleft palate is an independent genetic entity. His twin material, he claimed, indicated that a substantial number of cases he considered were due to non hereditary causes. Penetrance for cleft palate and cleft

lip was found to be less than 50% and that penetrance may be incomplete.

<sup>115</sup> Saunders in 1934 claimed a hereditary role transmission of the malformation of 44.5% of cases whilst <sup>115</sup> Schroeder (Munster surgical clinic) found hereditary in 42.7% of cases with 25% dominant gene and 75% recessive gene.

Where affected parents have produced offsprings 0.14% - 2% of the children carried the defect whilst in unaffected parents 0.11% of their children did likewise.

<sup>115</sup> Adair, in examination of identical twins noted that mirror image condition existed. At our own clinic there exists a similar case in identical twins.

Twins have always proved good examinable material.

<sup>33</sup> Brophy in 1923 recorded that in a case of identical twins, one had a cleft palate whilst the other did not.

<sup>33</sup> Shearer reported three cases of cleft palate twins, including identical twins in which one pair had identical clefts.

The conclusions reached by Fogh Anderson are -

1. Cleft palate with cleft lip, and cleft lip are genetically independent of isolated cleft palate.
2. The former two are in majority in incidence in inherited cases.
3. Inheritance is in the form of conditioned incomplete dominance with sex limitation to males and reduced penetrance exists. Consequently in most genetic milieu the gene behaves recessive but under favourable circumstances even the heterozygotic bears the defect.
4. The isolated cleft palate is however, seldom inherited.

Penetrance as defined refers to regularly and orderly effects of a gene producing its characteristics amongst individuals who have the gene in either its homozygous or its heterozygous forms. It



must be considered that the resulting clinical cases may be due to more than one gene or the pleiomorphic appearance and effects of a single gene.<sup>34a</sup>

It has also been stated that the homozygous state may produce the severe form whilst the heterozygous state the cleft lip or cleft palate a milder entity.<sup>34a</sup>

The fact exists that penetrance was highest amongst males for types 1 and 2 whilst penetrance for cleft palate alone (Group III) was greatest amongst females.

If the manner of inheritance is that of conditioned or incomplete dominance, then in most cases the gene appears recessive with sex limitation to males and reduced penetrance.

Where the isolated cleft palate (19% - 25% inherited group) exists, transmission is by simple dominance with sex limitation to females and reduced penetrance with possible solitary cases showing mutations.

The Philadelphia Centre claims simple recessive inheritance with variable expressivity, but the Statistical Analysis has not to date substantiated these claims.

In reviewing the literature the evaluation of Fogh Anderson has presented the best genetical progress construction of use to the pregnant mother. His results showed that if the parent is affected the children are rarely affected. In his sample observed only three out of 154 cases occurred where the child and parent were affected. Should the first child of an affected parent inherit this abnormality the chances are, somewhat greater for additional offsprings from such parents.<sup>34a</sup> Davidson stated "should a mother have one affected child, the chances are 1:8 that the following offspring

will be affected compared with the usual incidence of 1:213."

34a-36  
Murphy in 1947, wrote that should an affected child occur the chances of a similar result were about 25 times greater than if the first child were not. The Danish figures indicate an increased risk of 4-5%. No substantial data has been recorded and only approximations can be made and assessed.

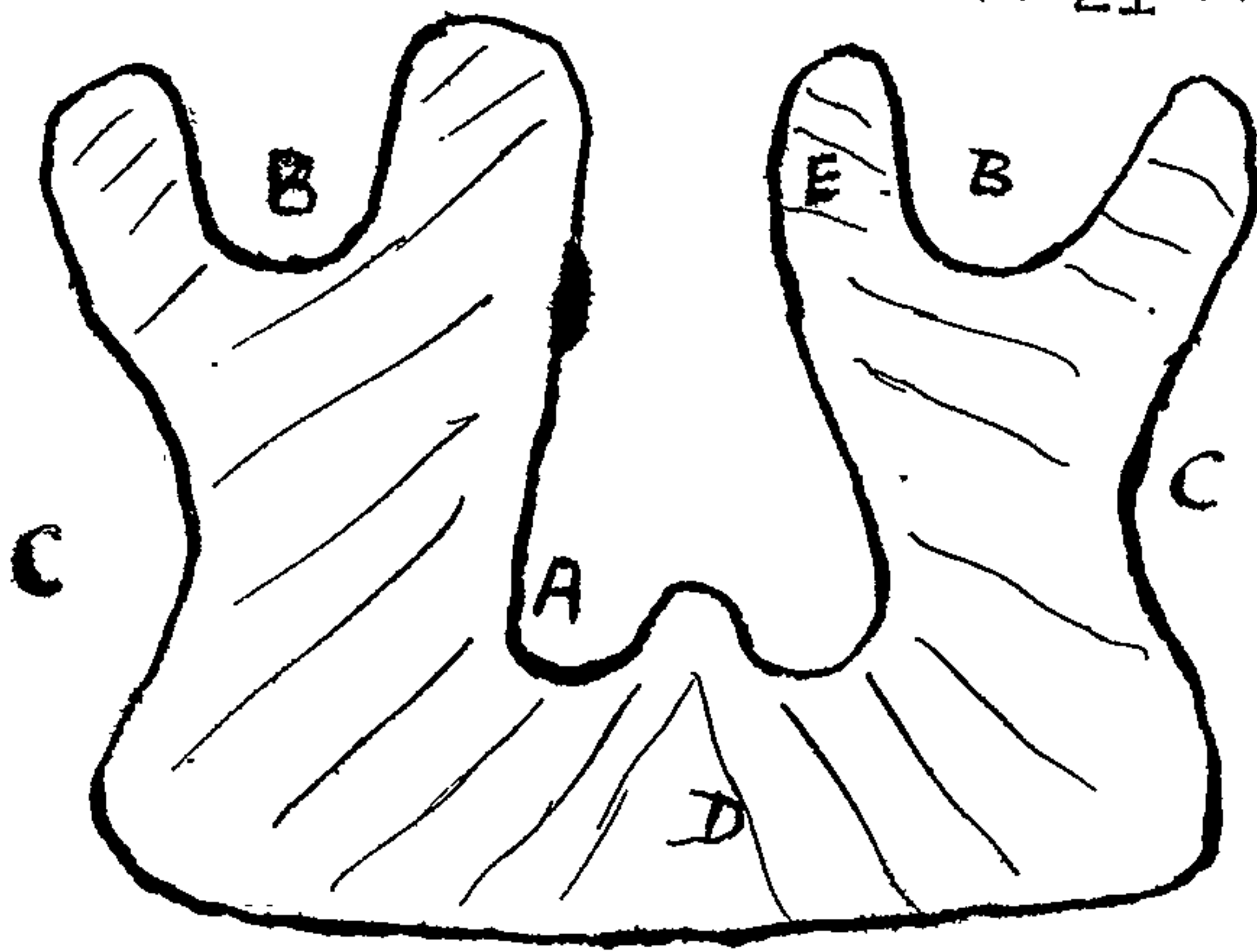
A normal individual with a relative that is affected, to produce normal children should avoid marriage with cleft palate or hare lip partners in life.

As previously stated cleft palate may occur through no inheritance factor at all. The rate of this occurrence was found to be approximately 11%. Should this occur, or any other cleft condition of the face, marriage between cousins in an affected family should be discouraged.



The Embryology of

CLEFT LIP AND CLEFT PALATES.



- A: Globular Process
- B: Lateral Nasal Process
- C: Maxillary Process
- D: Oral Pit
- E: Olfactory Pit.

FIG No 7

Introduction to Embryology, Pathology.

According to the classical theory the front nasal process divides into -

- A: Median Nasal process from which develop the globular Processes (2)
- B: Lateral nasal processes (2)

The median and lateral nasal processes bound the developing nares, and fusion of the lateral nasal process, the maxillary and the mandibular processes form the cheek. The palatal process forms from the maxillary process and unites with the globular process Antero - posteriorly. The union of these elements occurs during the 5-6th and the 9-11th weeks and by this date the uvula has formed, the last anatomical structure.

Cleft lip and palate are formed by a failure of union of these processes. The lateral incisor tooth germ may be situated medial or lateral to the cleft and moreover an accessory incisor tooth germ occasionally develops.

The importance of this condition is well understood when it is realised that in bilateral cleft lip cases in the early part of the century, death occurred due to failure of feeding. To-day, science has greatly reduced this mortality rate.

The classical theory presented in the 19th century on dev-



elopment and growth of the maxillo-facial complex was challenged in the 20th century. New theories were propounded and presented for the classical did not meet, nor explain the wide variations existing in cleft lip and cleft palate abnormalities. To-day three theories are presented and accepted concerning the embryogenesis of cleft lip and palate.

1. Classical theory.
2. Mesodermal penetration theory.
3. A theory which is the combination of 1 and 2.

Biologically the oral cavity is the beginning of the digestive tract with refinement by evolution and function. The vocal cords were primarily designed for protection of the trachea and have become modified in evolution for function in speech. The teeth in lower mammals are a feature and means of defence whilst in man this function has been replaced by the arms and hands.

Early in embryogenesis there is close association of the digestive and respiratory tubes, both developing from the same structure.

Within this basic development of a tube system sphincters gradually form -

- (a) The lips
- (b) The soft palate and posterior pharyngeal wall.

The pharynx remains as the same communication for both the oesophagus posteriorly and the Larynx anteriorly, thus providing two functions for the one passage. viz. the passing of both air and food.

With evolution in man the simple peristaltic and sphincter movements have been masked by progress in phylogenetic changes.

Where there is a cleft of the lip or palate the sphincters are affected and abnormal communication of cavities, oral, nasal and pharyngeal results in destruction of normal vegetative functions of eating and respiration. Upon these vegetative functions in man, speech has been superimposed and its neuromuscular function is dependent upon the inherent sphincter mechanism.

9-12-14-16.

Ballard states that the antagonistic musculature balance and the resulting forces produced normally mould and shape the developing bony framework of the palate and pharynx. It is obvious that should a break occur in the sphincter arrangement, the aberrant muscle forces induced would act to displace tissue and expand the defect even wider during growth and development.

There is a wide spectrum of individual variations in the abnormality, however, the classification recognises four basic disturbances -

1. A disturbance in adequacy or inadequacy of tissue.
2. Spatial configuration of anatomical segments, either normal or abnormal.
3. Deformation of bony and cartilagenious structures, in some cases due to aberrant muscular forces acting both in prenatal and postnatal development periods.
4. A palato pharyngeal disturbance with either normal or abnormal approximation and relationship.

The displacement of tissue is the most commonly encountered defect and the resulting structures are often basically adequate ~~but~~ merely mal-posed. This may be said to indicate that the embryonic disturbance occurred in the induction period of tissue differentiation simply been maintained in growth and development.

The muscular forces that act on the bony scaffolding of the palate and pharynx begin very early in uterine life, and the picture at birth is due mainly to antenatal moulding in growth and development



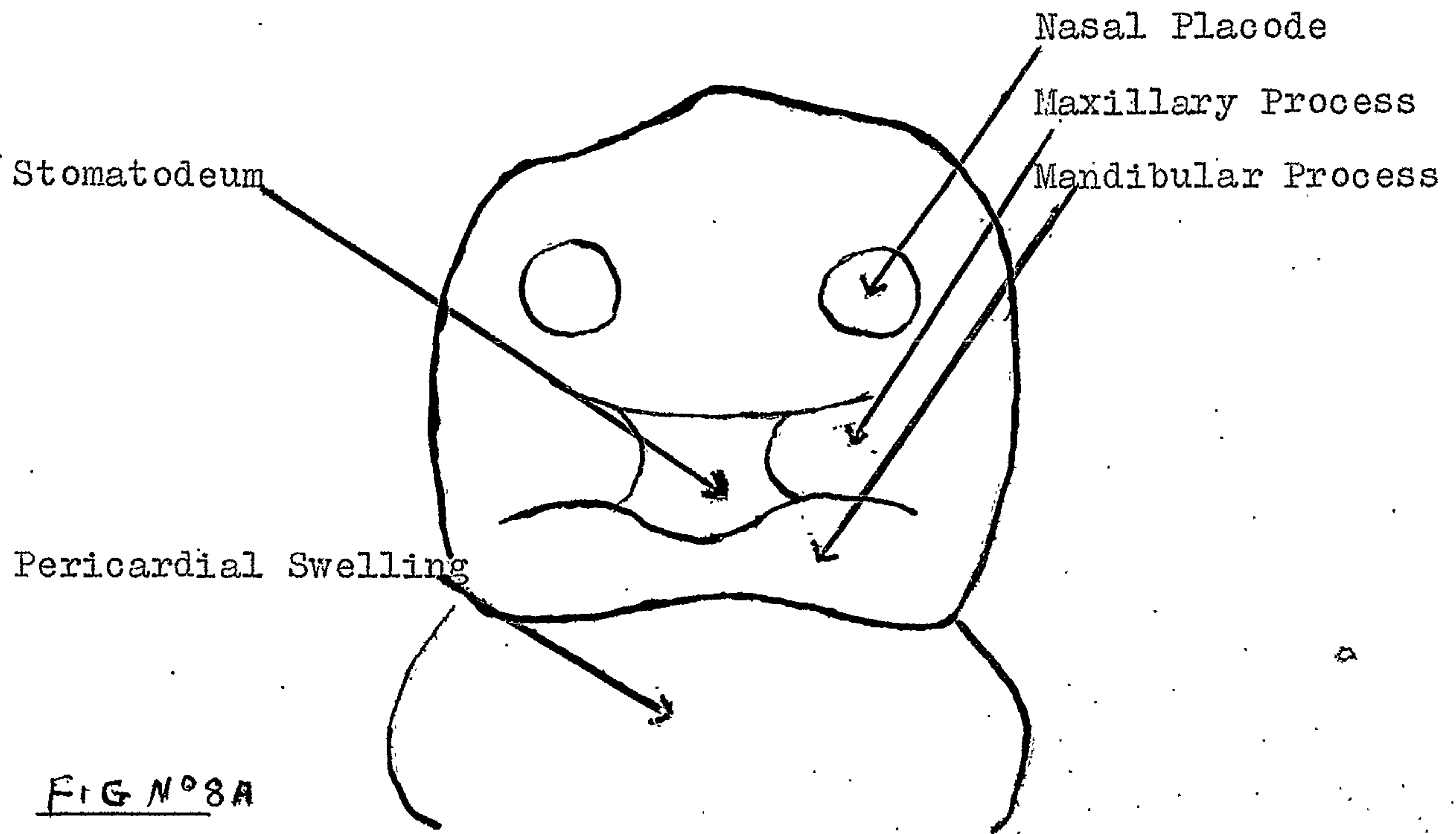


FIG N°8A

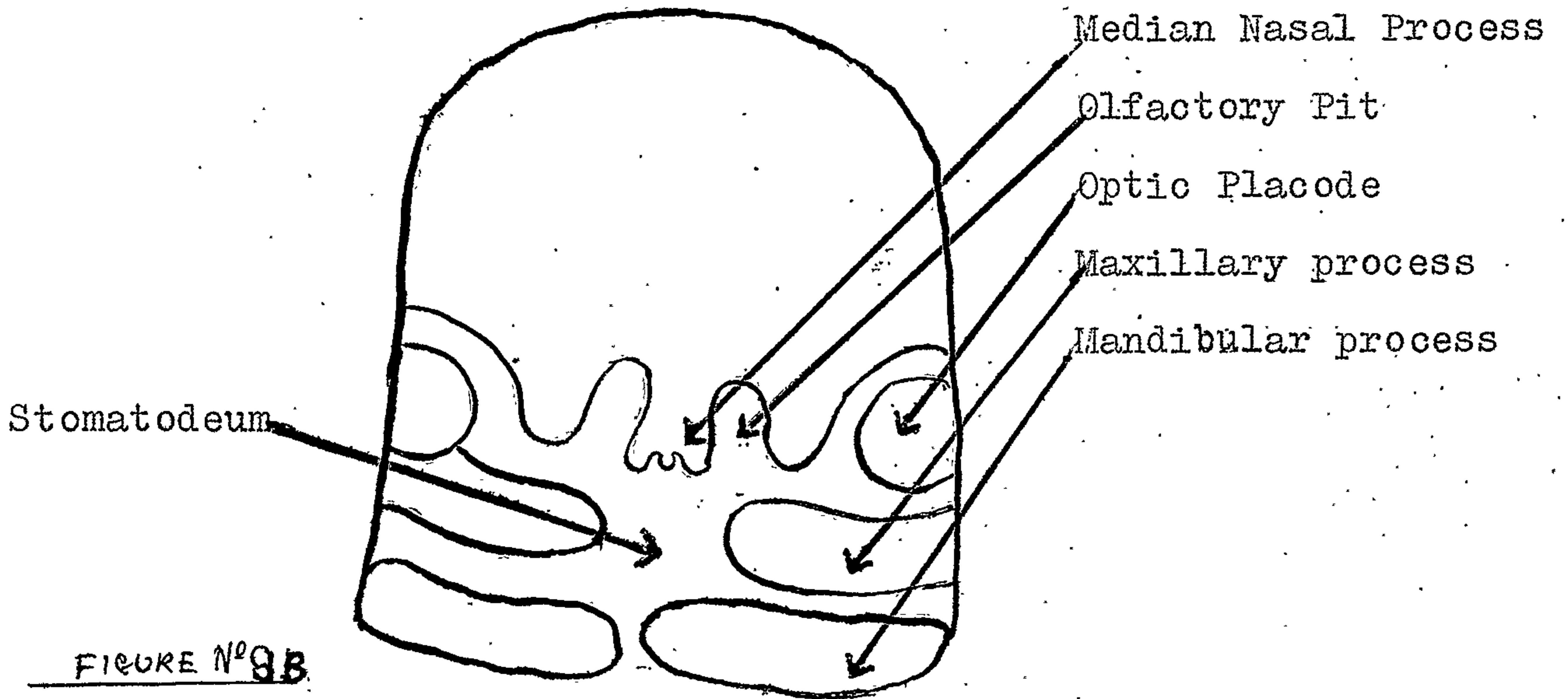


FIGURE N°8B

The evaluation of tissue disturbance or misplacement is important surgically, for correct diagnosis of this fact results in correct treatment.

83

Oldfield writes - The Class II Veau palate is "U" shaped and displays a wide gap in the anterior part of the cleft and occurs more in females than in males (Ratio 3:2). The type associated with Class I, Class III, and Class IV Veau is "V" shaped and occurs more in males.

Oldfield feels that of these classifications class II clefts may have no deficiency of soft tissue similar to that found in the Class I clefts which have a correct degree of soft tissue but in which it is misplaced.

The class II type is more difficult to repair, but mobilisation, claims Oldfield, with correct suturing in layers nasal Epitheleum to nasal, epithel muscle to muscle, oral mucosa to oral mucosa, will frequently produce an active satisfactory soft palate.

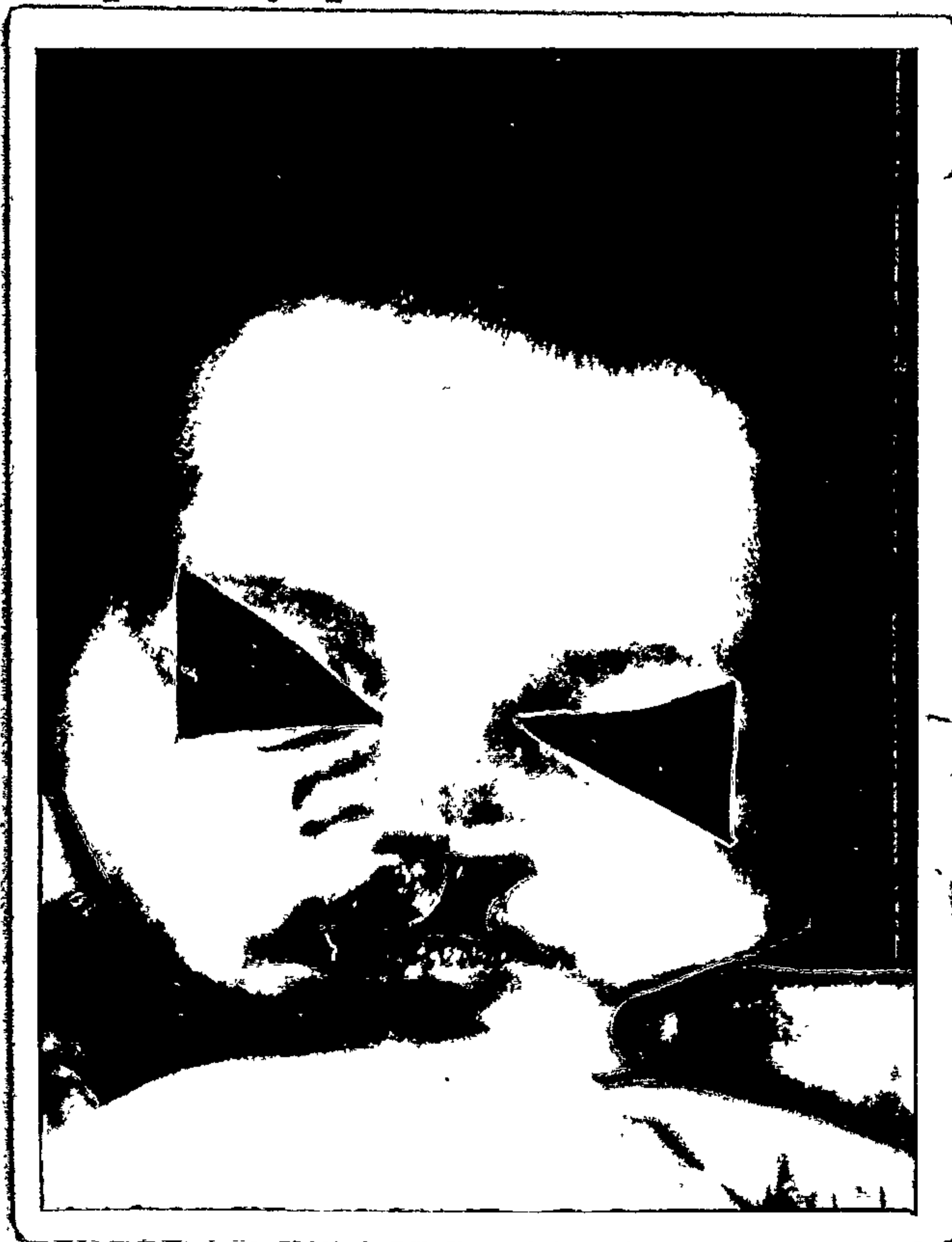

Figure 4.

A photograph illustrating the condition at birth, the result of embryological disturbance.



The Growth Pattern of the Embryo

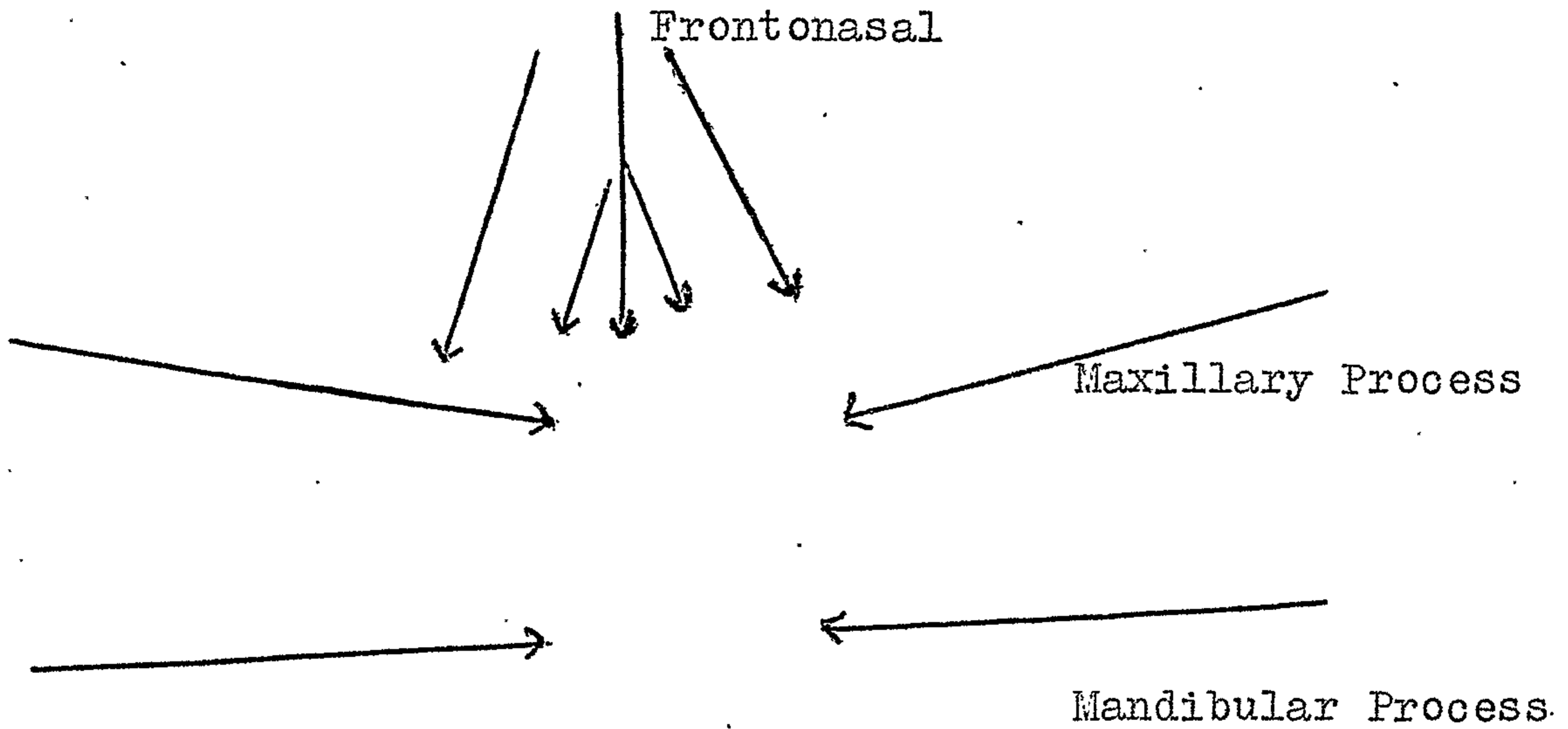


FIG N° 10

The DYNAMIC EMBRYOLOGICAL  
FORCE. GROWTH. PATTERN.

EMBRYOLOGY

Part A. The classical theory of facial development. The development of the central 1/3 of the face cephalad to oral cavity, premaxilla to soft palate, is explained fundamentally according to branchial Arch System.

57  
At the 10 somite stage the closure of the neural fold has progressed anteriorly. The anterior and posterior neuropores still exist as the head fold becomes more marked and the mandibular arch swelling occurs, (produced by the underlying branchial mesoderm) and at this stage lies as an inferior boundary to the stomatodeum, the primitive oral cavity.

57  
The amnion passes to the ventral aspect by a reduction at its line of attachment.

The maxillary and mandibular processes grow to form the boundary of the stomatodeum, and the 2nd pharyngeal arch (Hyoid arch) lies at this stage, inferior to the first Branchial groove, which is bounded superiorly by the mandibular arch. Above the stomatodeum the olfactory placodes appear on either side of the front of the head and gradually sink to form the olfactory pits. This occurs due to proliferation of the surrounding mesoderm which gradually forms the medial and lateral nasal folds.

By the 4 mm. stage the stomatodeum has developed, surrounded by the five processes -

1. The fronto nasal process which is median.
2. The maxillary processes laterally.
3. The mandibular processes infra-laterally.

102  
Gradually the mandibular processes with Meckel's cartilage grow towards the midline as the olfactory placodes form the olfactory pits.



The lateral nasal fold is thus seen separating the olfactory pit from the developing lens placode.

The mandible is formed as one unit by the five MM stage, the anterior extremities of the mandibular processes fusing. Should fusion fail at the 5mm stage, mandibular cleft, a rare but occurring cleft, witnessed once myself, will occur.

Early, the stomatodeum is limited by the buccopharyngeal membrane. Later a diverticulum, Rathes Pouch, grows from the stomatodeal roof towards the diencephalon. At the 20 somite stage the buccopharyngeal membrane ruptures and the two developments; the stomatodeum and foregut, become continuous. Beyond the buccopharyngeal membrane the pharyngeal or branchial arches have developed and each mesodermal condensation develops cartilagenous tissue and musculature.

By biological comparisons, Hamilton Boyd and Mosman found that the musculature of each arch is supplied by a special visceral efferent nerve and the endoderm by a special visceral afferent nerve. <sup>57</sup>  
<sup>125</sup>

Each arch has an artery, the branchial artery.

Higher vertebrates do not obtain the complete division of the gill pouch and the 2nd, 3rd and 4th endodermal pharyngeal pouches are partially divided into ventral and dorsal portions.

The roof of the stomatodeum has gradually assumed a gothic V.

The maxillary process grows then from the dorsal portion of the corresponding mandibular arch in an anterior and medial direction and fuses ultimately with the lateral edge of the lateral nasal process.  
<sup>33</sup>

It continues to grow bounding the olfactory pit inferiorly to meet and fuse with the median nasal process and eventually meets

and fuses with its fellow of the opposite side in front of the lower portions of the median nasal process.

This then has formed the anterior and posterior nares and the deeper portions gradually grow posteriorly to form the primitive palate and gradually the nasal pits have formed the nasal cavity.

The downgrowth in the median line of the fronto nasal process forms the nasal septum.

Gradually during the second month the primitive mouth is expanding internally in size. In the early stages it is merely a cleft between the maxillary and mandibular processes which gradually fuse.

Failure in this process or overactivity results in macrostomia or microstomia. The tecto septal expansion grows medially and upwards in the anterior plane, fusing with its fellow of the opposite side forming the projection distal to the fronto nasal process, and becoming continuous with the primitive nasal septum forming the definitive nasal septum.

57

The naso lacrimal furrow extends from the anterior angle of the developing eye to the angle of the mouth. Its failure in closure is claimed to form the facial oblique cleft by the classical group philosophers. Other grooves are claimed to disappear after the 30 mm. stage but may remain and exist as deep furrows.

The olfactory pit has gradually grown deeper and deeper forming the primitive nasal cavity. The division between the fronto nasal process and the frontal bone regions occurs at the 16 mm stage forming the true nose which is decidedly formed by the end of the second month.



As well, the other processes are forming simultaneously and continuously, the maxillary process as a mesodermal processes uniting with the posterior margin of the primitive palate, each other and the nasal septal lower edge from anterior to posterior. Since the posterior soft palate is the last area to fuse, it is the first area affected in cleft palates. This fusion is the formation of the oral and nasal cavities. One of the most important features is that at 10-12 mm period of this fusion the tongue had occupied a position between the maxillary processes, but now it descends in association with this fusion. The tongue does not descend in the cleft palate but remains situated between these processes, an important feature in research and in treatment of speech.

Membraneous ossification converts the primitive palate to the premaxilla. The horizontal processes of the maxilla and palatine bones form the true palate (hard), the most posterior portion forms the soft palate. Between the maxillary palatal processes and the primitive palate the naso-palatine canal forms and the conchae develop in the nasal cavity. The cartilaginous and bony elements differentiate in the mesoderm lateral and anterior to the nasal cavity, and the maxillary and frontal sinuses gradually extend.

It would follow then, that failure of union of the maxillary horizontal process with the nasal septum and with each other or with the posterior margin of the primitive palate will result in a variety of cleft palates depending upon the position and degree of failure. Bilateral cleft lip and palate is associated with failure of fusion of all segments such that the premaxilla and vomer are usually mobile and the anatomy of the nasal cavities visible from the palate.



One horizontal process may unite with the nasal septum, whilst the other fails to do so and will produce a unilateral cleft condition of the palate. As previously stated by comparative anatomy it has been established embryologically that each arch is supplied by a pretrematic and post trematic nerve, i.e. special visceral efferent which supplies motor impulses to the musculature and the endoderm by the special visceral Afferent fibres (post trematic)<sup>57</sup>.

As well as this nerve supply, the branchial arch receives a branchial artery. This system is similar to the system in gill functioning vertebrates with clefts. Five successive arches form from the foregut endoderm bounding the pharyngeal pouches.

Hamilton Boyd and Mosman declare that -

"The ectodermal grooves (except the first) become continuous with the corresponding endodermal pouches by rupture of the intervening branchial membrane and thus the definitive gill clefts are established. In higher types, however, such rupture never normally occurs as a layer of mesoderm becomes interposed between the ectoderm and endoderm and the endodermal pouches become modified to form structures as diverse as the middle ear cavity, tonsillar fossa and the parathyroid and thyroid gland".

In higher vertebrates these 2nd, 3rd and 4th endodermal pharyngeal pouches show a partial division into ventral and dorsal portions.

3

Rathke's pouch is an important landmark, the site of the junction of endoderm with stomatodeal ectoderm. This ectoderm forms the important anterior pituitary gland and the gland has to pass via the cranio pharyngeal canal through mesodermal tissue to the region of the future pituitary fossa where it approximates



the posterior pituitary gland and its attachment to the hypothalamic region by the stalk like extension from the diencephalon.

The development of the tongue is important as well as the previously described structures in order to comprehend its influence and control during speech and its relation to the cranial base and the pharyngeal wall during cephalometric Roentgen appraisals with Lipoidal Tracer.

The tongue is divided into an anterior 2/3 and a posterior 1/3, purely an arbitrary anatomical division. The anterior 2/3 is developed from the Tuberculum Impar and adjacent regions of both mandibular arches laterally, which are said to grow gradually forward and over the Tuberculum Impar.

The posterior 1/3 has a mixed origin and is said to arise from the ventro medial ends of the 2nd Hyoid arch bilaterally which gradually fuse anterior to the hyobranchial eminence to form a single swelling - the copula to which the 3rd arch mesoderm later contributes.

The tongue is said to arise from -

1. Pharyngeal Endoderm
2. Branchial mesoderm
3. Occipital myotomes.

The nerve supply to the tongue may be explained as follows:-

1. Mandibular lingual branch of the Trigeminal or 5th Cranial nerve which is the post trematic branch to anterior 2/3 of the tongue.
2. The chorda tympanic of the facial or (7th) Cranial nerve or 2nd arch nerve is the pre trematic nerve to anterior 2/3.
3. The 3rd arch nerve or glossopharyngeal supplies the epithelium of the posterior 1/3. Many writers claim that this epithelial overgrowth over the 1st and 2nd pharyngeal grooves is only partial and that the post 1/3 may derive some nerve supply from this area and the 4th arch nerve (superior laryngeal).

57

Comparative embryology indicates that migration of the 3 - 4 occipital myotomes gives the junction of striated lingual musculature, i.e. the junction of post 1/3 to anterior 2/3 and is indicated by the sulcus terminalis. The nerve supply to the tongue is thus derived from the 5th, 7th, 9th, 10th, 12th cranial nerves, the epiglottis is derived from the hypo branchial eminence.

The structure of the maxillary lip is not agreed upon by all workers in this field. It is claimed to be formed from -

1. Laterally the maxillary processes.
2. Medially the frontonasal process.
3. It is, however, considered that the maxillary processes contribute to the deeper portion of the lip, and the philtrum is formed by heaping up of the maxillary mesoderm on either side of the mid-line and appears to be absent in bilateral hare lips observed clinically.

Migrations of mesoderm from the 2nd branchial arch contribute the musculature of the upper and lower lips (i.e. Hyoid arch mesoderm) which is consequently supplied by the appropriate nerve, viz. the VII cranial (e.g. orbicularis oris and buccinator muscle).

The epithelium of the lip and gum is ectodermal in origin and the cheeks are formed by progressive fusion of the upper and lower lips.

Cleft lip and cleft palate according to this theory are formed by failure of union of these processes. Since the maxillary process fuses with and overgrows the frontonasal process first (at 5 - 6 mm) failure of fusion is said to occur at this size and to precede failure of fusion of the palate, which is said to occur at 9 - 11 mm stage approximately.

A midline cleft of the maxilla due to growth failure of the fronto-nasal extension, the globular process is rare, as is a mid-



line cleft of the mandible, but these do occur, with greater frequency in the mandible.

Should the maxillary process fail to fuse with the lateral nasal process and fronto nasal process, an oblique facial cleft would result. This is probably one of the hardest clefts to restore. One case examined at the Royal Alexandria Hospital for Children was associated with a unilateral cleft lip and palate, syndactylism dermoid cysts, and marked failure in formation of the Fronto nasal process.

With reference to the formation of the philtrum and premaxillary lip region not all embryologists are in agreement.

Dursey states, and is supported by His, fundamentally -  
102  
"The formation of the palate follows the formation of the medial and lateral nasal folds and the establishment of the nasal pit. In this period of development the forward growth of the maxillary processes and development of the fronto nasal processes gradually establishes the medial 1/3 facial form. As each maxillary process grows medially forming the nasal pit by junction with the median nasal fold and then extension to the middle line, it divides the fronto nasal portion into a superficial and deep portion."

This appears quite feasible and consequently the fronto-nasal process and extension, the globular process, will form the philtrum superficially, and columella whilst the deeper portion will form the primitive palate. The fronto-nasal process will form also the primitive nasal septum anteriorly and the tecto-septal expansion which is an extension from each maxillary process, forms the roof of the nasal cavity and the primitive nasal septum. This is all in co-ordination with clinical observations of bilateral cleft lip

and palatal cases.

The vomer nasal septum, premaxilla, philtrum and columella are usually all one mobile mass.

Refer - Figure (82.36a) Orthodontia section.

Figure (41.) Surgical section.

This growth pattern is said to have formed by 11 - 14 mm with formation of the face and oral cavity by 20 mm.

During the development of the palatal processes from the maxilla they are said to grow mesially at the level of the primitive palate and then fuse with the posterior margin of the primitive palate which is actually the deepest portion of the frontonasal process.

24-31

Brodie has stated that their growth is not horizontal as the tongue occupies this stomatodeal cavity.

As the tongue descends to the floor of the mouth the palatal processes grow mesially over the tongue and fuse just behind the premaxilla with the primitive palate anteriorly, the definitive nasal septum, and the other maxillary process.

This theory capably would explain complete clefts of the palate but not incomplete clefts nor one case witnessed that exhibited bilateral cleft lip complete on one side and incomplete on the other with a continuous alveolar arch and incomplete cleft palate with a free midline vomer and nasal septums.

The primitive palate and 2/3rds of the palatal process maxilla are said to form the hard palate by membranous ossification, whilst the soft palate and uvula are formed from the maxillary mesoderm of posterior 1/3rd of palatal process.



The mandibular lip is formed initially from the mandibular process by formation and division by the lip furrow band. The linguo-dental groove lies posteriorly and parallel.<sup>57</sup>

The musculature of the lower lip is said to be derived from the hyoid arch mesoderm and its nerve supply is the facial nerve of the 2nd branchial arch.

The gums are developed from their respective processes.

The above process of development is standard. The material for examination available is small and scientifically does not completely substantiate this theory. Stages have been established by comparative anatomy utilising the chick, rabbit and rat.

Careful experimental observations have shown that embryological development is not as simple as illustrated. The classical theory is based upon comparative embryology and many of the stages have not been witnessed. Material, human embryos present at the embryology and Histology Dept. Sydney University, show some of these formative stages, but the complete picture is still clouded and far from established. Personal observations of embryological material favour this theory, but feel that the stages in development are far from completely explained or proved.

#### The Mesodermal Penetration Theory.

Early the stomatodeum is merely a shallow ectodermal depression and the bucco pharyngeal membrane is merely endoderm and ectoderm in contact.<sup>57</sup> A similar situation exists at the primitive cloaca and consequently due to no mesodermal supporting tissue, rupture occurs in both situations. There is failure of mesodermal penetration and the mesoderm is necessary for nutrition and support. Veau in 1930<sup>102-36</sup>

proposed that an ectodermal hood developed covering the oral cavity adjacent to the primitive nostrils. This, however, has not received general agreement.

These ectodermal tissues are invaded by mesoderm with the formation of the appropriate lip, cheek muscle, teeth, bone cartilage, etc. <sup>102</sup> Veau has presented the concept of attachment of the primary and secondary palate with the primary palate attached to the pharyngeal membrane by an epithelial membrane, the naso-buccal membrane, forming the primitive choanae. These concepts were based upon ~~Bohlman's~~ <sup>36-102</sup> earlier theory of mesodermal penetration in 1910. The classical theory of the existence of facial processes was further challenged by Hochpleiter <sup>102</sup> in Vienna, Murier <sup>102</sup> and Hoepke in Heidleberg and supported the Pohlman theory previously expressed similar to formation of the definitive limb bud.

<sup>102</sup> The oral cavity states Hoepe, invaginates and the oral membrane disappears, without the formation of clefts or processes within the central 1/3rd of the face, and the nasal pits form and deepen remaining separated from the mouth by the bucco-nasal membrane, and the rupture of this early membrane proceeds the primitive choanae. According to this theory the primitive palate is an epithelial wall into which the mesoderm penetrates from each side to complete normal development of the central 1/3rd face. <sup>102</sup> It was claimed by Veau that this epithelial wall exists from inception of development.

<sup>34a</sup> Failure to complete mesodermal penetration into the epithelial provides a deficiency of mesoderm thus causing this epithelial wall to break into two or more components parts, which process provides the clefts.

<sup>102</sup> Veau feels that epithelial bands are the epithelial remnants



bridging a cleft resulting from degeneration of the epithelial wall, which has been incompletely penetrated by mesoderm during the formative period.

102

Maurer & Hoepe of Hiedelberg have inferred that the facial processes do occur during normal development of the middle 1/3rd face. Should a pathological cleft occur because of interrupted fusion the body makes an effort to later heal the cleft. This it attempts to accomplish by mesodermal penetration of this interrupted fusion. During this penetration by mesoderm, it must occur completely and evenly, such that epithelial plugs do not remain. The result of incomplete penetration in healing is the "Simonarts bands" the Achilles heel of the classical theory. These tube like connections may occur across any cleft condition but appear to maintain a preponderance for the cleft lip. This is the mixed theory which most workers agree is the most commensurate with our present knowledge.

Veau feels "that these bands are epithelial remnants bridging a cleft resulting from degeneration of the epithelial wall which has been incompletely penetrative by mesoderm".

102

These arguments for and against could not convince Stroer or Holland that a typical stream of mesenchyma could penetrate and repair the defect of the cleft in the lip and palate. He and others maintained that the prolabium premaxillary region was the dynamic centre of growth and development. Should inadequate supply of mesoderm or improper proliferation occur, then incomplete or complete cleft of tissue would result.

Thus the facts to date indicate a relationship between cleft lip, mesodermal proliferation, and the dynamic centres of growth.

The corollary to this basis is that an embryo develops a cleft lip or palate where mesoderm is deficient on the affected side. This was shown in microscopic examination. The mesodermal anal<sup>A</sup>ge is arranged in several masses along the antero-posterior axis of the facial structure and microscopically may be found as late as 36 mms.

Veau's conception is that in the simple cleft a thin partition of epithelial cells exists on a level with the posterior part of the primary palate where the bone will form and a thicker epithelial partition on the level of the future soft parts.

As the intermaxillary segment advances he states that the thin partition erupts and the bone then fuses almost normally. However, the maxillary processes will not be pushed forward by the intermaxillary segment.

At the lip level the thick epithelial wall remains which is in keeping with the persistent muscular deficiency. Concerning the cleft lip with a band communicating, he states that a complete defect exists except for a soft tissue band where the muscular wall is deficient and the thickness of the epithelial wall posteriorly explains the alveolar arch defect and occurrence.

The evolution of the initial epithelial wall creates the variety of cleft lips and not the intrinsic nature of the malformation.

#### Discussion on Embryology.

##### Congenital Fissures in the lower lip.

33

Sir Arthur Keith wrote in his monograph on "congenital abnormalities of the palate, face and neck," that bilateral cleft of the upper lip was frequently associated with a curious malformation of the lower lip in which two fistula or recesses open on the lower lateral surface opposite the cleft in the upper lip.



Similar conditions were observed by Brophy and Thoma. By comparative anatomy Brophy found that a similar condition existed in sharks and stingrays, but these were found to be mucous canals and were connected to nerve endings. However, further investigations have failed to prove anything and the comparative anatomical studies of Selachian and Thoma have dropped from view. Brophy in examination of his patients claimed to find twelve such occurrences of nipple like projections.

Sir Keith's definition of the cleft palate was -

"A congenital deformity characterised by a fissure or fissures of the palate due to arrested development".

33-102

Brophy stated that the deformity was not the result of congenital deficiencies of the parts in question nor arrested growth of the palate. He claimed that all the children who have congenital cleft palate with rare exception have in the palate at birth the normal amount of tissue. This statement was made in 1923 and since this date this view has not completely fallen from favour, e.g. Oldfields views on cleft palates.

102

Veau, who firmly believed in the mesodermal penetration theory, showed that the vomer may exist from a well developed structure to rudimentary. Clinical observations have indicated that this may apply to many anatomical structures affected by the abnormality. The degree of tissue present varies with the individual case and observations do not substantiate Brophy's claims. Clinical observations have indicated this wide spectrum of individual variations and four basic types have become established depending upon the severity, as previously stated:-

1. Adequacy or inadequacy of tissue.
2. Normal or abnormal spatial configuration of anatomical segments.



3. Deformation of bony and cartilaginous structures, in some cases, due to aberrant muscular forces acting both in prenatal and postnatal developmental periods.
4. A palatal pharyngeal relationship and approximation either normal or abnormal.

Cases examined at birth may indicate displacement of tissue. The composite structures as indicated by Brophy, Veau, His and Pruzansky are sometimes intrinsically adequate but merely mal-posed indicating that the disturbance must have occurred at a certain period and since that time has just been maintained in growth and development.

32      13/9      89/90a & b  
Brodie, Ballard and Pruzansky indicated that the muscular forces that act on pharynx begin early in uterine life and are far reaching. The picture at birth is due mainly to antenatal moulding in growth and development.

Since the classical theory has failed to stand against scientific argument much stress has of late been thrown upon the "mesodermal penetration theory".

At the time of gastrulation known inductors occur. These have been shown to consist of diverse kinds of substances and tissue, and when transplanted experimentally, e.g. inductors of the optic cup of early gastrular under the belly epidermis of another gastrular, the result is the induction of a piece of brain with eyes in the foreign location.

This was shown to occur at the stage before the neural plate receives emanation from the layer of cells just under it, the Archenteric roof. The inductor is the potential for forming nervous tissue and before its application only non specific cell formation was possible by the tissue.

The dominance of inductors or organisers determining the



pattern of formation is now provided and Touraine has described three types -

1. Hyper Inductors
2. Hypo Inductors
3. Disinduction

He states "Development is determined by a hereditary plan by means of induction so that dysplasias may become of hereditary nature too. In many cases they may be acquired by external influences according to the point of attack. External agents attack the cytoplasm, whilst hereditary influences work through the nucleus."

It is seen then that the basis of pathological formation is a theory of how two factors may influence the developing abnormality for neither agent can stand alone as the initiation.

<sup>36</sup>  
Weiss, who is also well known in this field of embryogenesis, has also examined the multiplicity of developmental agents and claims "The harmony of their co-operation, the preformation of the differentiating potencies of the cell and the universality of the principle of progressive determination are the fundamental tenets of embryogenesis."

Examination of dog and mouse embryos indicated that complete cleft lip may originate as so called cysts, and that these cysts break through secondarily to the nasal and oral cavities.

Observations of cases within the clinic by surgeons and orthodontists have not enlightened the confused picture, but only added further problems unexplained by present day theories. The occasional presence of Simonarts bands in various sizes and the flaring of the nostril and alveolar segments do suggest a remnant of tissue resulting from traction on tissue in an area where tissues are pulling apart rather than a picture of fusion. This was ~~clear~~ →

ically observed in Figure No. (18). Indeed, examination of the widths of the maxillae and pharynx have substantiated these claims. Cases exhibiting Rhinolalia Operata, typical of patients with cleft palate suggest an intrinsic defect of neuro-muscular development and control.

33-102

Of seven embryos recorded in the literature, five displayed mesodermal deficiency, and where mesoderm was defective on one side a cleft occurred on that side, and when this deficiency occurred bilaterally a cleft occurred bilaterally.

Microscopic examination of cleft areas in embryos showed that in spite of epithelial approximation on both sides of the cleft, fusion had failed to occur.

There was complete lack of mesoderm on the side of the cleft in the areas of the lip and premaxilla in the embryos examined. It is generally accepted that the prolabium and premaxilla appear to be the most active centre of growth and development of the central 1/3rd of the face and that the deficiency observed was not in accordance with normal growth.

The polarity of mesenchyme and presence of mitoses indicated and suggested that these activities take place if the prolabium and premaxilla are stretched or placed under tension.

Growth in the prolabium of bilateral cleft lip and cleft palate cases was observed clinically, especially where placed under tension through the surgical procedure of repair of the lip.

102

Observations of Stark on an embryo displayed the same feature just quoted (in relation to the premaxillary development) and he claimed that this lack of mesoderm in the cleft palate may account for an anatomically perfect palate with imperfect speech.

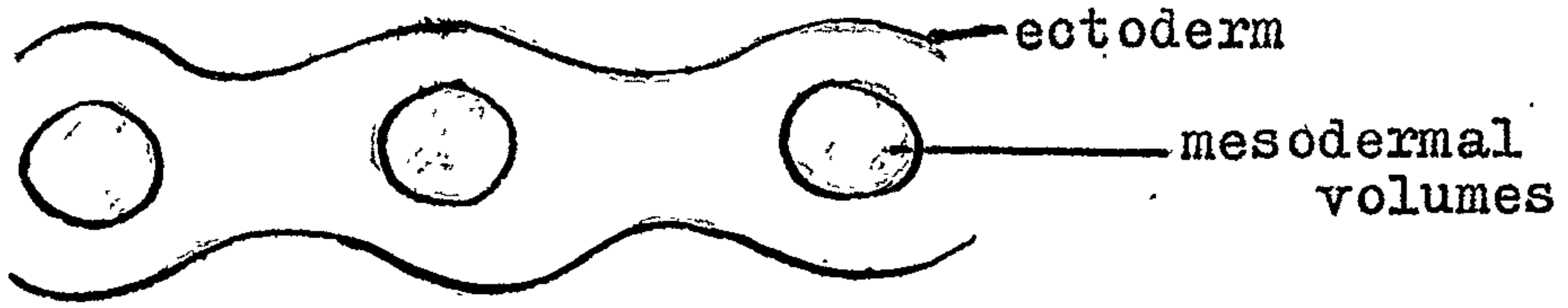


This would indicate then that surgery, no matter how perfect, cannot restore the normal functioning soft palate to provide the perfect speech, under which circumstances, speech no longer should be used to alone determine the result of a surgical technique, for surgery may not be capable of supplying the desired result.

Veau, Pohlman, Stark and others were able to indicate that the epithelial analge of the middle  $\frac{1}{3}$ rd of the face contained three masses of mesoderm. This may still be in accordance with the modified classical conception. They claimed that variations in one, both or all three of these analages and mesodermal contents resulted in cleft lips, for without support, the ectoderm ruptures as in the cloacal imperforate anus theory. The explanation may be applied to the palatal development and its musculature. An Epithelial wall occurs initially as the analage of the upper lip and is supported by three mesodermal volumes. Figure (II).


Figure 11.

(A)



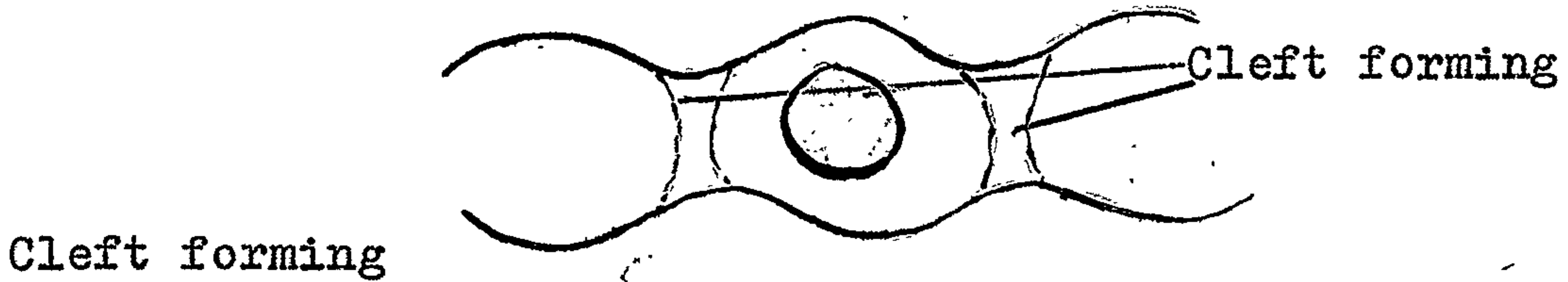
Normal Lip

(B)



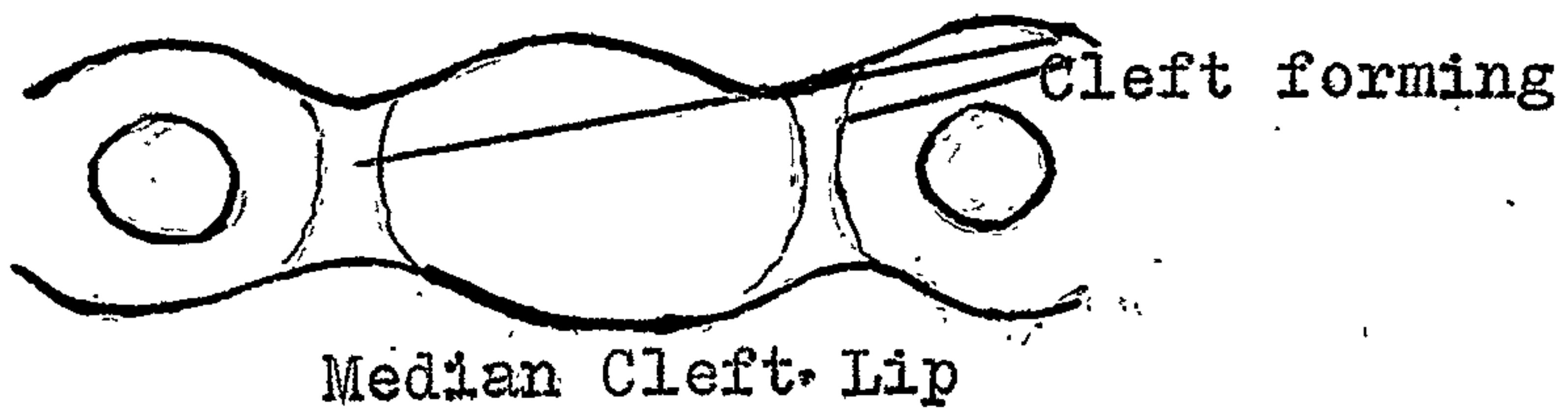
Unilateral Cleft Lip

(C)



Bilateral Cleft Lip

(D)



Median Cleft Lip



These gradually grow and fuse providing the normal upper lip and premaxilla with incisor teeth. Absence of these mesodermal volumes as in figure 11, B, C and D. provide the variations occurring, such as -

- A. A patient with a cleft lip, without affect on the alveolar process and not possessing a lateral incisor on that side.
- B. Rare occurrence of the median cleft lip in the maxilla accounted for by median mesoderm volume lack - hard to explain by the classical conception.
- C. Simonarts bands or their remnants which are also hard to explain by the classical conception.

A relative lack of mesoderm rather than a complete absence, does appear to account for the presence of some mesoderm in the cleft palatal areas of all the embryos examined.

Histologically, in a microscopic section examined at the level of the posterior function of premaxilla and anterior palatine process maxilla in a cleft lip and cleft palate embryo, it was seen that mesodermal volume was present but fusion had not occurred.

Mitotic activity was seen on the side of the non-cleft, thus suggesting that the cleft side was a waning process with the disintegration of the epithelial wall.

Most of these observations were conducted upon embryos under 30 mm. length. Histological findings showed the absence of mesoderm co-existed with the cleft palate and cleft lip abnormality and that the volume of mesoderm decreased accordingly in the appropriate order -

1. Normal side
2. Unilateral cleft lip or palate
3. Unilateral cleft lip and palate
4. Bilateral cleft lip and palate.

33-36

Brophy in 1923 stated that cleft palate may occur due to the

following circumstances -

1. Misplacement of the developing anatomical structures.
2. Mistiming in growth.
3. Failure in union.
4. Break down of union due to lack of mesoderm.



SUMMARY:

Two theories have been presented and a discussion on the failure of these theories to satisfy the characteristics of the clinical material examined. The three fundamental types examined in clinical material available were -

1. Simple clefts where there is an isolated cleft of the lip or palate.
2. Complete clefts of palate, hard and/or soft, hard tissue involved and clefts of the lip combined.
3. Incomplete where there exists a bridge between both edges of the cleft.

Pohlman and co-workers, as early as 1910 after examining such conditions, did not feel that the classical theory of facial embryogenesis could explain all existing abnormalities and clefts, for it could explain the complete cleft, but not the incomplete and simple partial cleft of the lip.

For the fusion theory to occur, it would have to arise selectively for no other organs have been similarly affected in the embryos studied.

102

Fleischman stated that the mesodermal failure may occur for two reasons -

1. Prevention by the epithelium.
2. Failure of the mesoderm to penetrate.

A Short History of Cleft Lip and Cleft Palate Surgery.

It is credited to the dental profession that the first operation for closure of the cleft palate was proposed and attempted in 1764 by a dentist, La Monier, a Frenchman.<sup>33</sup>

His method divided the operation into four stages -

1. Paring the edges of the cleft.
2. Introduction of sutures.
3. Approximation of the freshened edges with fixation.
4. Relieving the tension on the sutures.

<sup>33</sup>  
In 1819 Rour of Paris and Warren of Boston conducted similar operations utilizing similar techniques. Further variations were introduced by Graif, Dieffenbak and Sir William Ferguson.<sup>33</sup>

Classification of this abnormality appeared impossible at first due to the wide variation encountered, until Brophy, with the experience of others before him, introduced a classification which is, fundamentally, still used to-day. His classification of the cleft palate has been included and indicates the stress placed upon the degree of tissue involved and the anatomical structures included in each type.

Classification of Cleft Palates.

1. Cleft Uvula.
2. Partial cleft of the soft palate involving fibres of the tensor palati and levator palati muscle.
3. Complete cleft of the soft palate from the uvula to the posterior border of the horizontal plates of the palatine bones.
4. Cleft of the soft and hard palate.

Brophy introduced many techniques for surgical approaches for Flap operations and post operative treatments that have not withstood the test of time and have since been substituted.

His techniques utilised such materials as the lead plates, silver wires and horse hair sutures to produce and maintain con-



traction of the maxillary segments, a technique little used to-day. These sutures and wiring techniques were claimed to resist the tension applied by the tongue, but to-day are obsolete.

Many pages of this book are spent justifying his claims that the technique of approximation of the palatal segments including both hard and soft structures was correct. At no time did the writers, surgeons of this period, refer to the occlusion of the teeth nor assess the change that occurred in the occlusion before and after surgery. The orthodontist of this day was but an infant in the knowledge of growth and the order of the day was prosthetic restorations.

Not until a later era, where comparisons were made of normal growth and the growth of "handicapped" clefts, did modification in surgery and understanding in occlusal changes occur.

33

Brophy and co-workers claimed that the molar buttress was the rotation point for the maxillary units during his "compression" technique. To-day the reverse procedure is the rule in orthodontia where restoration of the collapsed arch is undertaken.

It is interesting to note that the rotation point or line in expansion of the maxillary segments has not yet been accurately assessed in this orthopedic movement. No doubt in time, the cephalometric laminography technique will solve this and many other associated problems. To-day it is realised that collapse due to absence of the palatal buttress may occur either unilaterally or bilaterally in cleft palate and cleft lip cases following surgical intervention. With the growth of knowledge in such spheres as "speech therapy, orthodontia and otolaryngology the far reaching

affects of this collapse are fully understood and the resulting complications. All effort is made to-day to restore function to normal and consequently the last thirty years have seen revolutions in techniques and approaches, with criticism of techniques not providing improvement in function.



PART I.

SURGERY AND ORAL SURGERY.

Introduction.

Cleft palate and cleft lip surgical techniques over the period of years have varied widely. Basically they are divided into two groups, depending upon the embryological formation and development of the tissues.

33

Brophy and his disciples and followers believed the condition to be due to failure of union of the normally developed processes, and their approach to the surgical problem (pressure as early as possible after birth) was based upon this Hypothesis. The results of this procedure have presented wide variations in the malocclusions that have followed, poor cosmesis and distorted middle third facial bone structures, so consequently has fallen into disuse.

70.95.18

The second approach introduced was the Von Langenbeck technique which is based upon the belief that clefts are the result (especially in the palate) of arrested development at appropriate stages in uterine development and an inherent lack of tissue develops in many cases.

This philosophy to-day holds sway amongst most surgeons in the majority of cases and their techniques are based upon utilising and maintaining most soft tissue available. Where gross arrested development occurs the addition of grafts or employment of such operations as the "V" switch (Abbé) Eslander operation adds to this deficient soft tissue.

18.54.128

The physiology, function and anatomy of the soft palate has been closely evaluated and surgical repairs have been modified through time to replace and restore, rather than distort and destroy normal function and speech.

Observations at clinics have shown that, although great strides have been made, the results are far from satisfactory, speech being a judge of palatal surgical results and aesthetics and facial form the judge of lip surgical repairs.

Surgery: Its Aim and Limitations.

Surgery is performed to aid the individual to perform tasks normally and to restore the normal appearance of body contours. Sherry in 1940 and 1945, showed that tendon and nerve crosses were possible in monkeys and man, but not in rats. In man these operations are performed to aid and help the individual overcome a disability but here again the power to adapt is dependent upon long training and a great deal of conscious effort.

It is stated that the new patterns of activity that may be produced do not replace the endogenous ones but merely control them from a higher cerebral level and that in a moment of stress and quite often in sleep the primary inherent patterns may re-appear even after many years. Cleft palate and cleft lip cases are often rehabilitated to normal by surgery and speech training. However following the introduction of a new episode in life, such as marriage, conscious effort has decreased and the speech has reverted to the nasal affected cleft palate speech.

Patterns of activity of musculature exist for mastication and speech, built up over the period of years, and involving the tongue facial musculature soft palate, and pharynx and innervated by the special visceral efferent, general visceral efferent and general somatic efferent nerve supply as described by Ballard in 1953.

The toxic neck reflex is important in posturing the infant at the breast but the child is dependent upon further normal



functioning reflexes and balanced co-ordinated muscle function for feeding. Surgery is aimed at providing these normal functioning tissues for these basic patterns.

8.10

Darwin realised the importance of behaviour in its wider sense, "Natural Selection" but the work of Tin-Bergen (1950-1951) and Lorenz (1950) enabled behaviour to be defined as -

8.10

- "1. Co-ordinated patterns of motor activity endogenous with the central nervous system.
2. The environmental stimuli which reflexly calls forth the specific complex patterns of activity which are composed from endogenous co-ordinating patterns".

The introduction of surgical repair for a palate does not mean that the soft palate will later function the same as a normal unaffected palate. The cleft condition appears to establish a breach in function that only carefully planned surgery associated with speech therapy and often orthodontic therapy over a period of years will restore to normal.

Surgical Functional result is frequently limited by the low intelligence and non co-operation of both the patient and the parents and early assessment of resulting function hazardous.

10

Weiss in 1941, in the field of experimental biology demonstrated the principle of myotypic (muscle-specific) response, which discounts the ideal of trial and error learning. On stereotyped nervous development, producing patterns of motor activity in the individual, Weiss states:-

"Co-ordinated patterns are determined centrally and that the central patterns through reinforced normally proprioceptive reflexes, take precedence over the latter under complicating circumstances."

In conclusion it may be again stated that approximation of abnormally developed segments of a palate or lip will not necessarily restore normal control and function and consequently normal speech function does not always result. Speech however, still remains the "yardstick" of determining the efficiency and result of surgery.

Surgical Anatomy and Physiology - including the Physiology and Anatomy of Suckling.

The function of suckling in an infant is an inherent factor of survival. The reflex of sucking continues until the 18th month and measurements have indicated that a negative pressure of 5-15 cm. of mercury occurs in the oral cavity. <sup>30-32</sup>

The muscle concerned may be divided into three groups -

(a) oral, (b) pharyngeal, (c) intermediate soft palate.

(a) The oral musculature are those of sucking.

1. Orbicularis - a sphincter like muscle which contacts the Alveolar segments.
2. Buccinator - which aids the buccal pad of fat and connects the orbicularis oris and the superior constrictor.

(b) The pharyngeal group is mainly the superior constrictor and salpingopharyngeus, which at the Passavant's cushion level may aid closure of the naso pharynx by contact with the soft palate.

(c) The intermediate group is the soft palate which is described fully in this section. The approximation of the soft palate to the post pharyngeal wall prevents the regurgitation of milk whilst feeding.

The buccinator muscle may either compress the cheek or blow them out when the vermillion margin of the orbicularis oris approximate tightly and the soft palate approximates to the posterior pharyngeal wall, an important factor in explosive speech.

During suckling a negative pressure may be established by



approximation of the tongue to the palate to create a vacuum and by movement of the buccinator muscle.

This reflex function, due to neuro-muscular entity and balance, and the swallowing wave, is progressive from the orbicularis oris to the pharynx. During the phase of deglutition the respiration ceases. In a child, however, often this cessation of respiration is not so marked, and air becomes incorporated in the mother's milk.

The normal swallowing reflex as outlined by Ballard is in the order of -

1. Approximation of the labial musculature.
2. Position of the tongue to the palate.
3. Closure of the oro-naso pharyngeal communication by approximation of the soft palate to Bassavants cushion.
4. Cessation of respiration.
5. Function of the kinetic chain of muscle.
  - (a) Buccinator
  - (b) Superior constrictor
  - (c) Middle constrictor and inferior constrictor,

in that order.

The cleft lip and cleft palate introduce rupture in the two sphincter like areas, the lip and soft palate. This failure in development prevents approximation of the lip properly to the nipple during feeding for the orbicularis oris, the anterior sphincter is attached to the horizontal fibres of the buccinator. Contraction of either muscle can only result in further splaying of the anterior cleft segments.

When the milk passes to the palate, the nasal communication results in nasal passage of milk. The cleft palate destroys the posterior pharyngeal wall approximation so that respiration and

deglutition result together. The neurological reflexes cannot function normally, but may do so to a degree, following surgical intervention and repair.

The anatomical structures affected directly are in order -

1. Orbicularis oris
2. Premaxilla and Alveolar process
3. The maxilla and alveolar process
4. The palatal process premaxilla and maxilla and mucosa.
5. Musclature soft palate depending upon the extent of the cleft.

These are -

- |     |                   |                                |
|-----|-------------------|--------------------------------|
| I   | Levator palate    | } and mucous membrane covering |
| II  | Tensor palate     |                                |
| III | Palato-Glossus    |                                |
| IV  | Palato-Pharyngeus |                                |
| V   | Musculus Uvulae   |                                |

These are the structures affected directly by the cleft and during palatal and lip repairs, the ideal is to restore normal anatomical structure without cicatrical tissue resulting. Such a procedure results in normal forces playing upon the bony segments.

The tissue of the cleft areas are usually supplied by the divisions of the 5th, 7th, 9th, 11th, 12th cranial nerves. The accessory nerve normally supplies branches to the pharynx. In cases following surgical intervention the nerve supply response is often slow and the gag reflex subdued.

Arterial supply at birth is fairly rich, enough to supply flaps and bony underlying tissue in lip operations. The palate at birth is very small and surgical operations difficult, due to the approach, unless attempted before the lip surgery. The arterial supply is better developed at a later date and will donate a greater blood supply and develop collateral circulation quicker.

Indirect results of cleft of the lip and palate were recorded by <sup>100.</sup> Psaume and <sup>106-77</sup> Wardmill in 1928. They, using the hamular process and Pterygoid plates as landmarks established that the pharynx was



wider (when measured at the inter hamular process distance) than the normal for that age and sex.

By Laminagraphy, a body sectioning radiographic technique, J. Daniel Subleny<sup>100</sup> substantiated these claims and showed that during the second year of life a levelling off in growth of the nasopharyngeal width occurs. Measurements were conducted bihamulat. All cleft types except Veau type IV he claimed showed wider nasopharyngeal dimensions than were displayed in normal subjects. They found too, an increase in the angulation of the medial pterygoid plates.

The Bizygomatic measurement in this series was found to be normal so that only an abnormally wide pharynx exists in cleft palate cases.

The vomer was found to be affected indirectly, mostly in unilateral cases and deviated from the side of the cleft.

The medial pterygoid plate has been used for 50 years as a means of measuring pharyngeal width. This important structure is the supporting element for the Superior Constrictor and the Buccinator muscles. The Hamular process, is frequently removed during palatal surgery and the importance of this region cannot be underestimated.

The muscle centre of ossification for the medial pterygoid appears in the 2-3rd month of intrauterine development and fuses with the greater wing of the sphenoid at 4th month. But this does not join to the body of the sphenoid till 12-14 months postnally. Thus an open suture exists until the period nearly of levelling off in development of the pharynx.

Aberrant muscle forces transmitted by the Orbicularis oris through the buccinator and superior constrictor will undoubtedly

influence this angulation during the most important phase of embryological development and early infancy.

A cleft of the soft palate will be an important factor in moulding pharyngeal growth for the tensor palate is distinguishable at 14 mm and definitely functioning before birth.

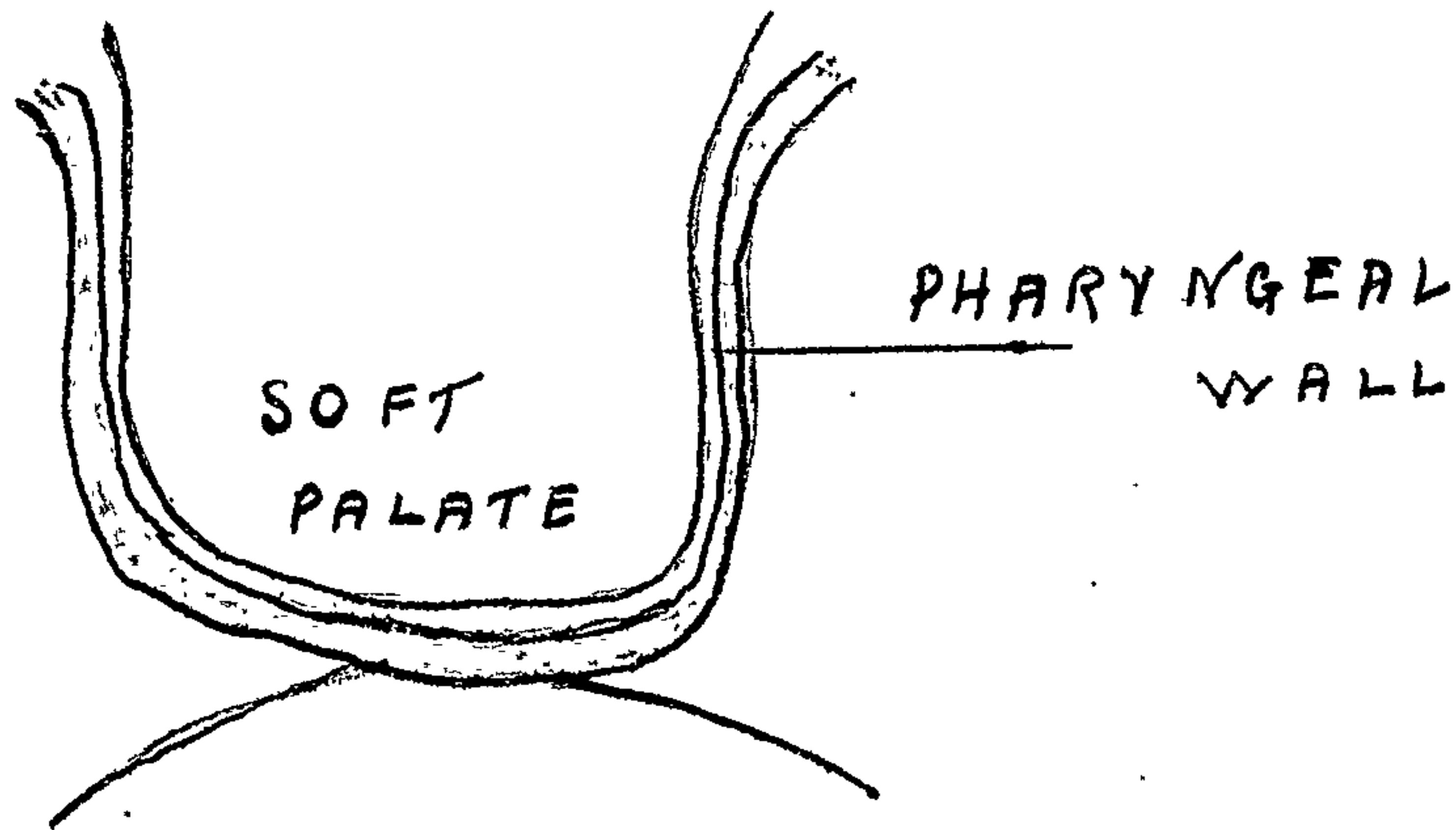
The tensor palati arises from -

1. Scaphoid Fossa
2. Spine sphenoid
3. The lateral part cartilaginous Eustachian tube.



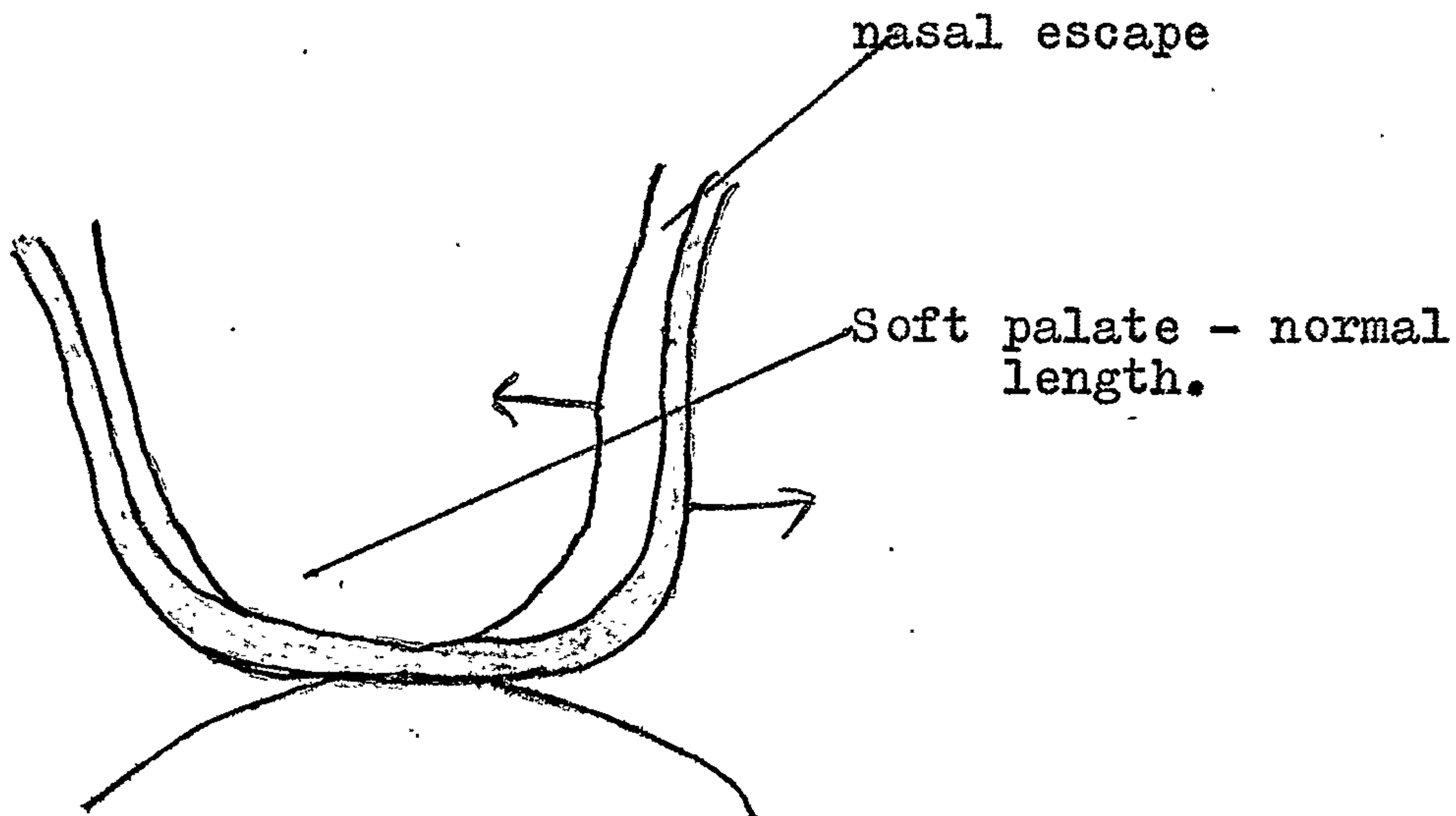
TYPE 1. Normal Soft Palate.

Approximation to the pharynx.



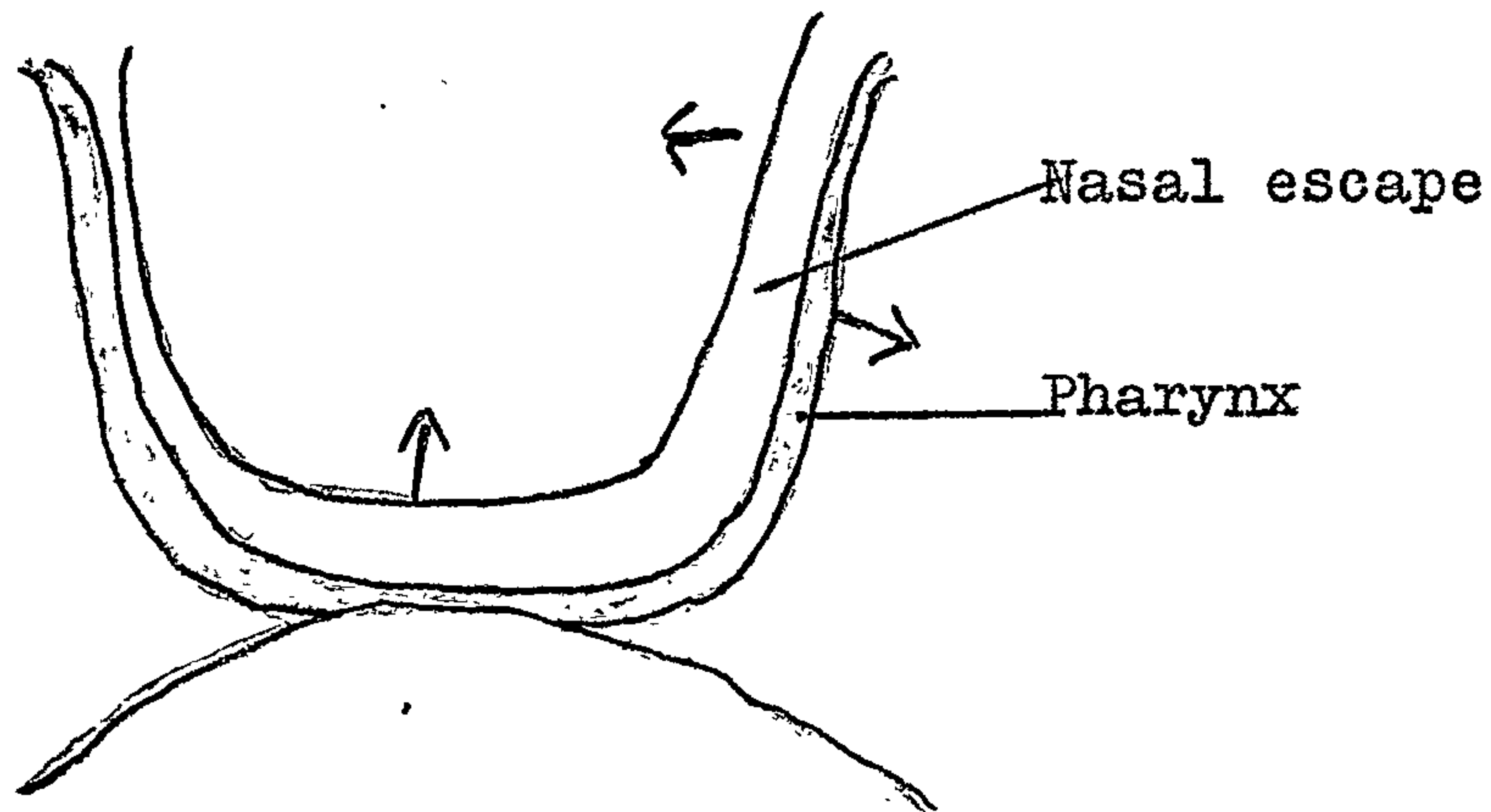
TYPE 2.

(a)



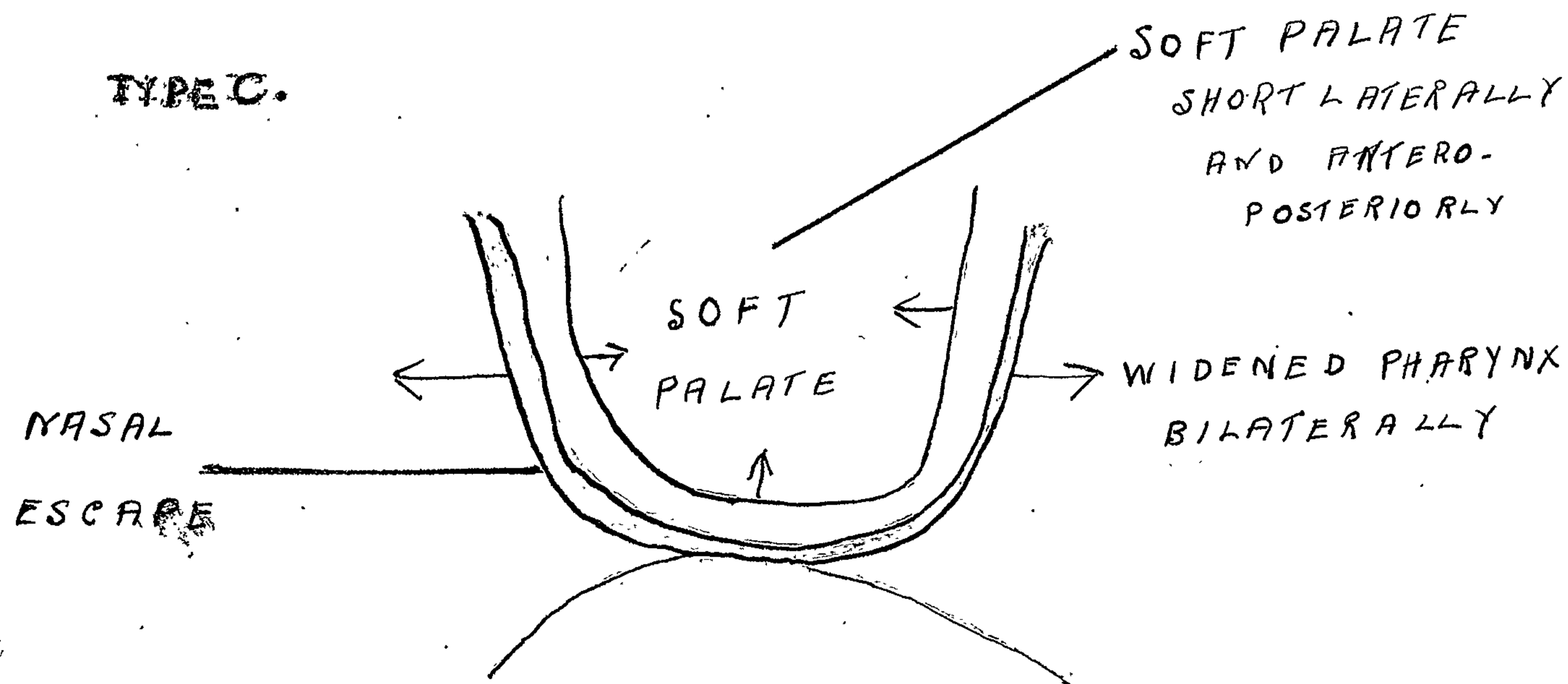
Normal length soft palate with slight widening unilaterally of the pharynx due to the expansion of a medial pterygoid plate in unilateral cleft lip and cleft soft and hard palate.

(b)



1. Soft palate in unilateral cleft palate where there is slight shortening of the soft palate, it will not contact 100% efficiently and the degree of nasal escape may be more marked than in type (a).

**TYPE C.**



Bilateral Cleft Lip and Palate.

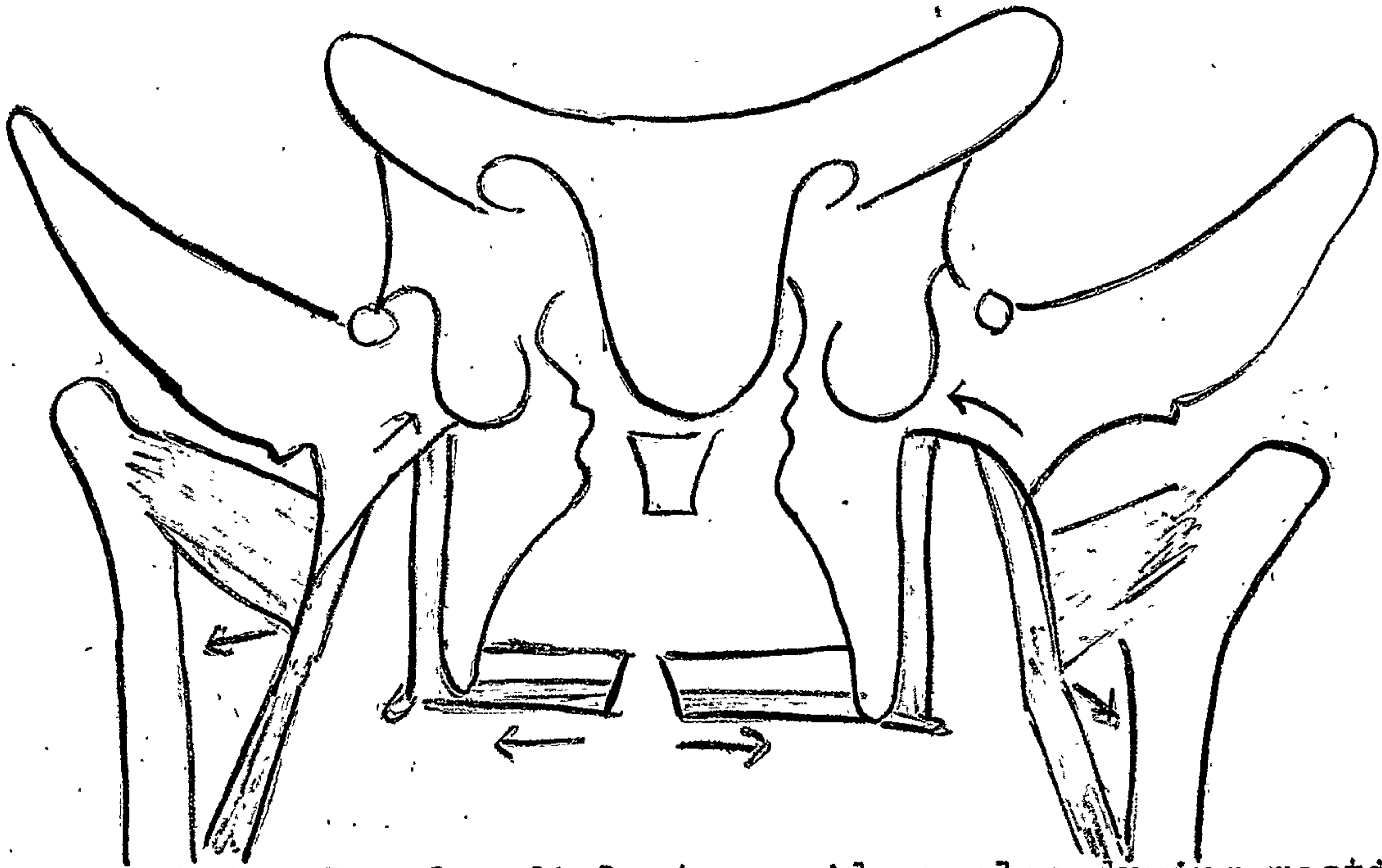
Here the soft palate is deficient in length and width and is associated with the bilateral enlarged pharynx.

Nasal escape during speech may be extensive.



Tensor Palati Muscle passes inferiorly in the superior side wall of the pharynx to pass around the hamular process and gain insertion into the palatal aponeurosis superior level, by a long tendon. It is also claimed that some fibres gain insertion into the horizontal plate of the palatine bone. Contraction when unopposed spreads the medial pterygoid plates laterally.

Fig. 13.



The lateral and medial pterygoid muscles during mastication and movement of the mandible are exerting their pressure influence upon the lateral pterygoid plate which in turn are passed by trajectories through the bone to the medial pterygoid plates; a composite unit. The tensor palati then has possibly acted as a stabilising bar, the same as the hard palate, preventing spread of the pharynx during embryological development. The destruction of their continuity has produced this increased width by unopposed tension. This bilateral spreading may be further accentuated by

the posturing of the tongue in the cleft area.

When observing a cleft palate child cry in a clinical examination, where the cleft is unrepaired, the segments of the soft palate retract laterally quickly. This divergence and convergence may be witnessed also in the phonation of AH.

Examination of the pharynx of bilateral cleft palate and lip cases usually exhibits a wide naso pharynx. This, along with the knowledge that most of the progressive width is established by the age of 2 years supports the importance of Hynes' operation, a pharyngoplasty being conducted at the same time as the soft palate repair. This type of operation will tend to oppose this abnormal spread of the naso-pharynx.

Nasal escape has been noticed to occur in many cleft palate cases in speech. Much has been written about the shortness of the palate but little importance has so far been placed upon the width of the pharynx in relation to the soft palate.

Frequently the palate may be nearly normal in size with the pharynx slightly larger, or as in bilateral cleft palate and lip cases, the soft palate slightly short, but accentuated by an ever wider than normal naso-pharynx. Nasal escape cannot then fail to occur, as there are two opposing factors. These factors indicate that pharyngoplasty is by far the best approach to the problem. There does not appear to be any indication for late surgical intervention, i.e. 10 years, but rather at 2 to 4 years, the period that the soft and hard palate, is repaired surgically. The divergence of the pterygoid plates that results from the unopposed tension (where the balance of the antagonistic musculature is destroyed by



the cleft palate) will be influenced during the formative years by such a procedure.

The factor of tongue spreading into the nasal cavity must not be forgotten and the sooner it is returned to its correct anatomical position, the earlier speech correction will follow when attempted.

Growth studies following surgery of the lip have shown that early repair has resulted in approximation and moulding of the bone segments whilst a full potential still exists for growth of this bony framework when refined surgery is used. However, different complications resulted with surgical repairs of the soft and hard palate. Surgical repair does not limit bone growth directly. The cicatricial tissue that results may be a limiting factor whilst surgery directly may result in increased collapse of the segments.

Should the bony elements be wired together, clinical material and literature indicate that bone growth in most cases will be retarded.

It is obvious that a normal environment is required as early as possible for development of responsive neuro-muscular patterns, the fundamental essential for speech.

As previously stated, normal function does not necessarily follow. It is preferable in most cases to close the velum (although it may not be possible to close the hard palate) and restore some normal musculature forces.

The time of closure is still a problem and may be found to vary with each individual case. A search of the literature has found a variation from 9 months to 5 years.

Early closure is imperative in the lip. The palate exhibits different problems. Many claim that the palatal closure should be left as long as possible, whilst others claim that 4 years old is usually the ideal age. This has arisen from the fact that early closure, especially in bilateral cases, has provided marked collapse resulting in malocclusion and has not produced marked improvement in speech production and articulation. With later surgical intervention the malocclusion produced has not been quite so severe, but the neuro-muscular patterns of speech have formed in musculature distorted and cleft.

The intelligence of the individual and his or her response to therapy may be an indication to the time of palatal repair, but as yet this problem is unsatisfactorily answered.

Care at surgery must be made to the following factors -

1. No unnecessary fracturing, wiring or removal of bone
2. No undue introduction of scar tissue
3. No severance unnecessarily of blood supply.

Surgical technique may be varied according to -

- I Width of the cleft.
- II Character of the tissue adjoining the defect.
- III Length and mobility of the velum before and after surgical intervention.

Following surgical palatal intervention further growth and development of the palate and pharynx now follows the pattern imposed by the new united muscles in functions. The degree of growth is an inherent factor and usually little limited by surgery.

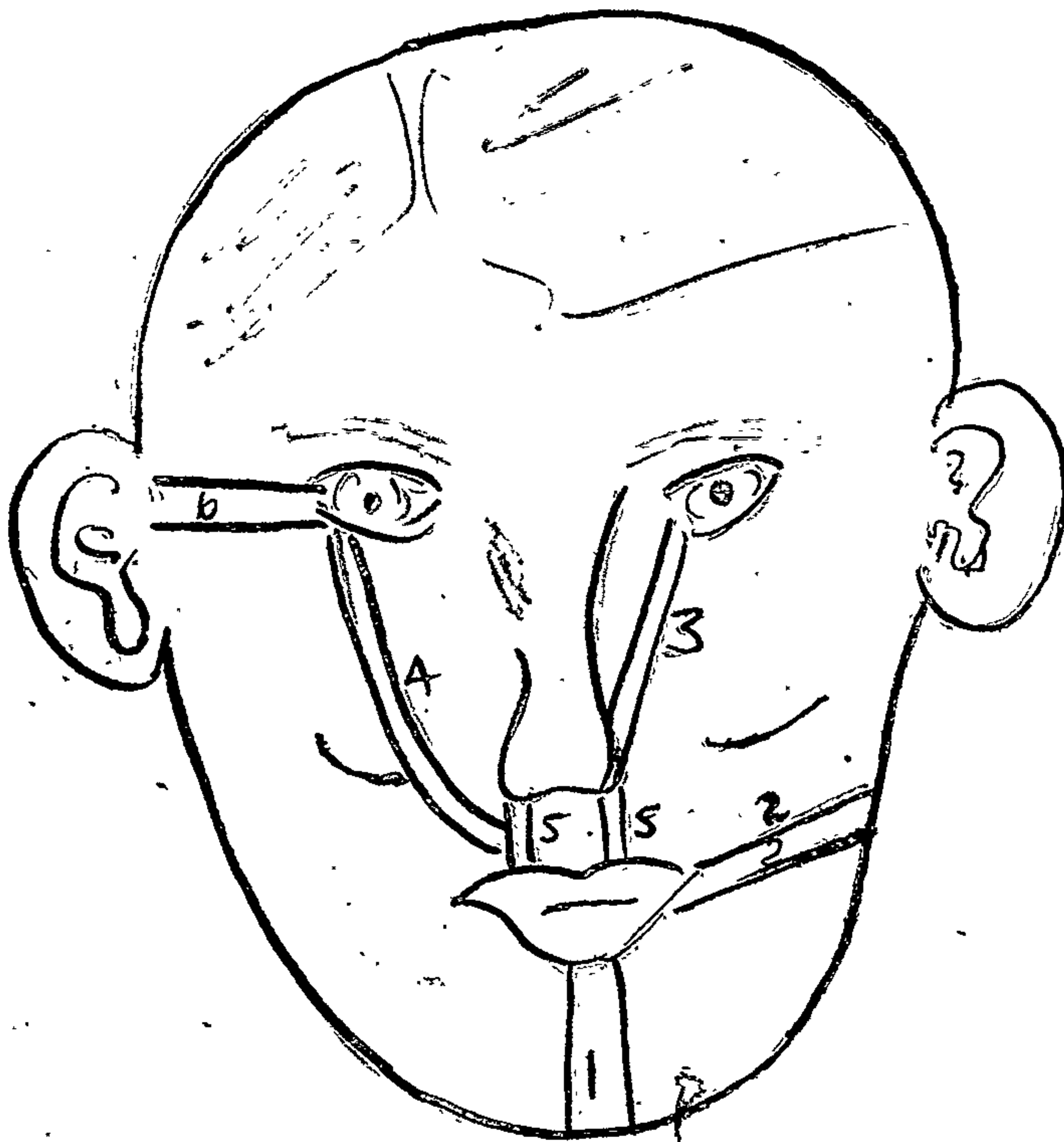
With reference to the literature the variety of cases presented seems only to indicate and emphasise our inability at



present to prescribe a rigid formula for timing the surgical repair of the palate.

INTRODUCTION OF TYPES OF CLEFTS

Figure 1A-A



AFTER THOMA.

### Surgical Classification.

A cleft as previously explained may exist in three forms:- (1) simple, (II) complete, (III) incomplete. Veau's classification into four types depending upon the anatomical structure disturbed does not cover all types of clefts. Veau's classification may be compared to Kurt Thomas' which is complete for most types of facial clefts occurring. <sup>115</sup> Thomas' classification is based upon embryological development.

#### Classification A.

1. Median Nasal Cleft.
2. Median Labial Cleft. (a) upper lip. (b) lower lip.
3. Lateral nasal cleft.
4. Lateral cleft upper lip. (a) unilateral (b) bilateral.
5. Oblique facial clefts. (a) ora facial cleft. (b) Colom-bonia facialis.
6. Transverse facial cleft.
7. Combination of 1 - ,6.

Veau's classification covers most cases occurring clinically, whilst Thomas' classification gives a complete picture of disturbances of the facial soft tissue. Oblique facial clefts are rare but one case treated at the Royal Alexandria Hospital for Children illustrated clearly the marked disturbance occurring where a right oblique facial cleft was associated with a bilateral cleft maxillary lip and cleft soft and hard palate. Thomas' further classification completes the picture.

#### Classification B.

1. Median palatal cleft (a) hard palate (b) soft palate and Uvula.
2. Alveolar Process. (a) unilateral (b) bilateral.
3. Medial cleft mandible.
4. Combinations of 1 - ,3 plus 1 - 6 as above.

Such a diagnosis and classification is important but in no way indicates the tissue lost by the cleft. This requires



clinical examination of the individual case with assessment.

Where the lip alveolar process and palate are involved, there may be a small or wide separation of the palatal shelves with wide variations between these two. In some cases the palatal segments were seen to overlap shortly after birth. This becomes more marked following lip surgery.

Tilting and rotation of anatomical elements occurs due to abnormal development and muscle pull; the palatal element in cleft palate may tilt medially and inwards.

Deviation of the vomer from the midline and the existence of a suture line between the vomer and premaxilla are important factors that may influence surgical treatment.

18

The classification of Arthur Joseph Barsky is more appropriate to the clinical problems present. This is a modified Richie classification.

#### Group I.

Prealveolar cleft - lip cleft only - alveolar process - normal.

1. Unilateral. (a) complete (b) incomplete.
2. Median - rare.
3. Bilateral (a) complete (b) incomplete.

#### Group II.

Post alveolar cleft is a palatal cleft, alveolar process normal.

1. Soft palate extent in 1/3rds.
2. Hard palate extent in 1/3 rds.

#### Group III.

Alveolar process cleft.

1. Unilateral associated with -

Lip unilateral }  
bilateral } complete or incomplete.  
median }

2. Median - rare - complete or incomplete.

3. Bilateral.

Process - (a) complete (b) incomplete.

Lip - (a) complete (b) incomplete.

This classification does assess to a finer degree the tissue absent, an important factor in surgical repair and an influence on the technique used.



SURGICAL TECHNIQUES OF CLEFT LIPS  
AND CLEFT PALATES.

Clinical Assessment.

Early surgical intervention in cleft lip presents a relatively normal lip tone to the alveolar arch, an important feature. An associate widening and flattening of the nostril on the side affected results in a dropping of the alar region and results also in most cases deflection of the septum.

Faulty nutrition, due to the lip cleft, frequently occurs and the birth weight may be rapidly lost, and is often slow to regain. The method of feeding these children is discussed in the appropriate chapter. It is sufficient to say that the child, when presented for surgery, should now show dehydration nor electrolytic imbalance and must stand a fair chance of survival, otherwise the case is better deferred until better health resumes.

33

Brophy and previous workers considered that where palatal surgery was contemplated, this procedure was better completed before an associated lip closure, due to the increased access. This technique is no longer utilised and the palate is left till a later age.

An examination should be made for respiratory infections, of blood groups, coagulation time, bleeding time and other medical problems that may influence surgery.

SURGICAL PROCEDURES FOR CLEFT REPAIRS

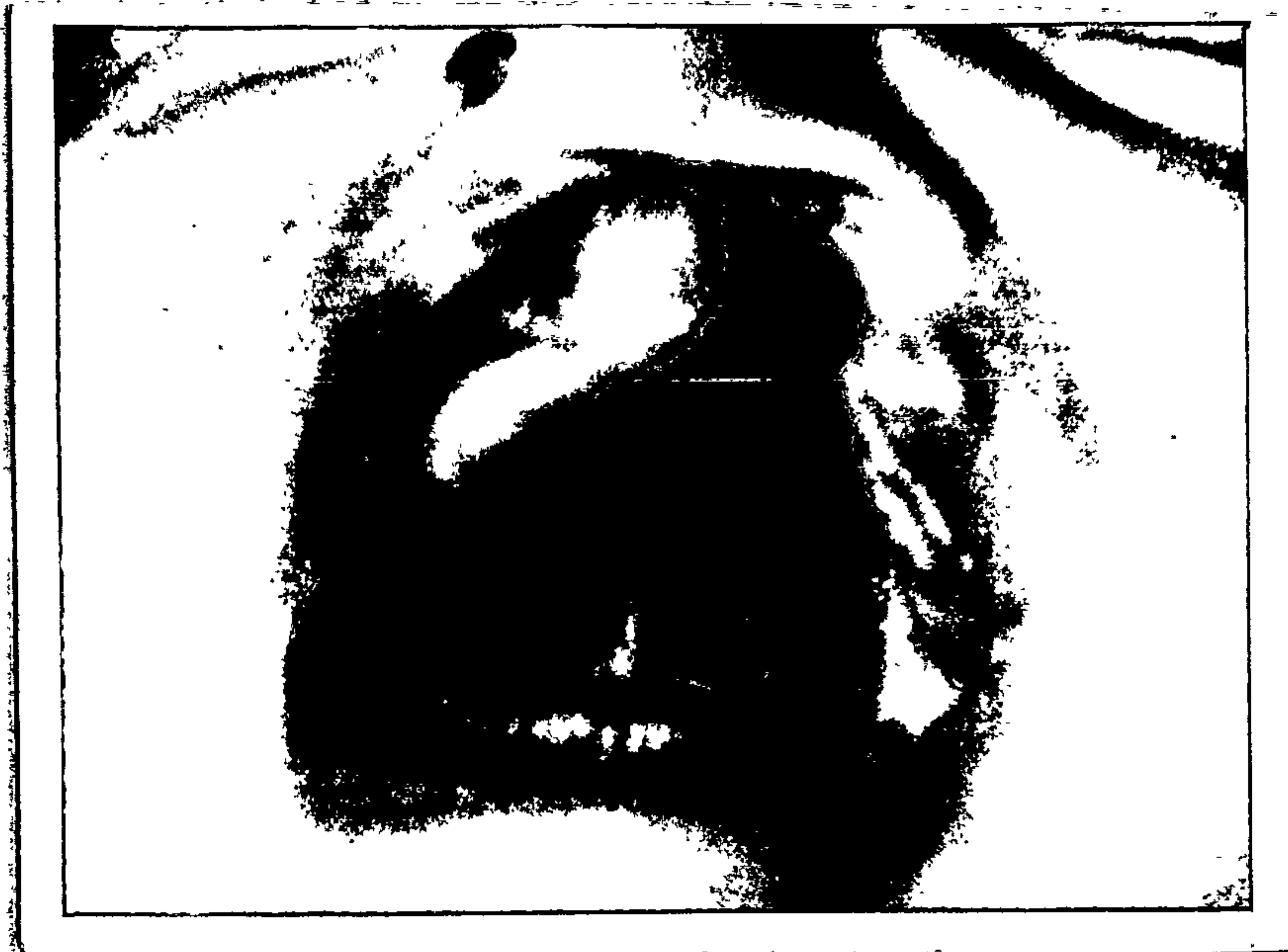


Fig. 14. Illustrating complete unilateral cleft of the maxillary lip, alveolus and palate with rotation of the premaxilla and flattening of the nostril prior to surgical repair. Note the disturbance of the vermilion line.

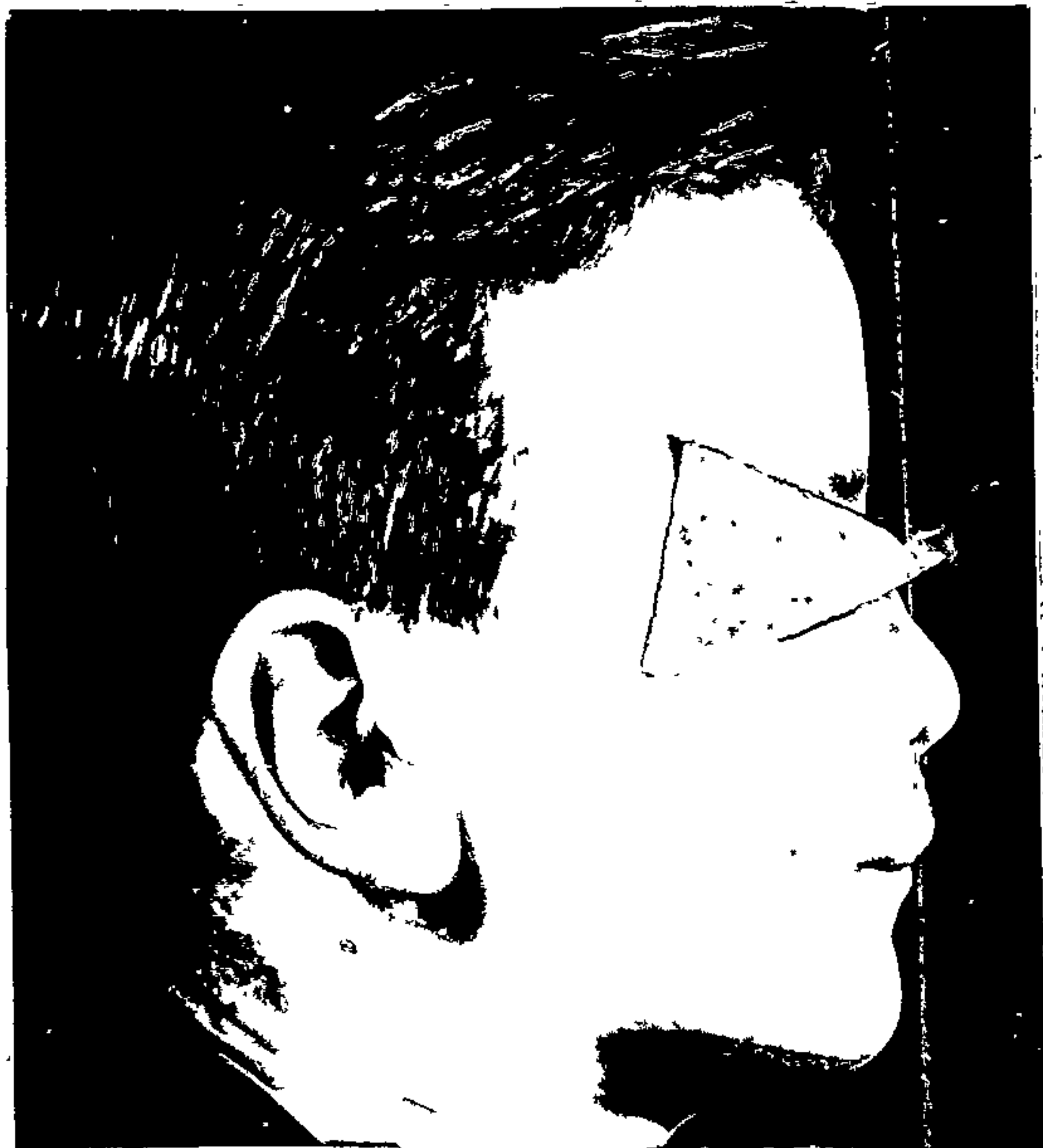

Fig. 15. Unilateral cleft of the lip some years following surgical repair. Note the restored continuity of the Vermilion Border.



### Nasal Clefts.

The embryology of the face according to the classical theory shows that the nasal region is developed primarily by the Frontal process, median nasal process, globular process and Lateral nasal process contact and fusion with the maxillary process.

A median line groove of the nose was recorded, the nasal cartilages being divided, and in one case absent nasal bones occurred, observed by Webster and Demming in 1950.<sup>115</sup>

The Surgical Procedure was a simple re-unity of the disturbed sections but where alar cartilage is disturbed, it may have to be split and raised or just raised and united.

### Oblique Facial Cleft:- Meloschisis.

Although uncommon, all degrees of facial oblique cleft may occur this being generally associated with other abnormalities in development e.g. Syndactylism and Dermoid cysts.

Oblique facial cleft occurrence is rare, and extends usually from the medial corner of the eye to the upper lip alone or in association with a lateral cleft lip.

Severe expression may result in a deformity that only grafting will restore. Both soft tissue and facial bone structure are affected, which may require tube pedicle grafts for restoration of facial contour.

### Macrostomia.

This expression of the cleft deformity may occur in all degrees from the corner of the mouth to the tragus of the ear, but in most cases examined, did not pass beyond the anterior border of the masseter muscles.

The tissue affected in most cases was the cheek mucosa and the buccinator horizontal muscle fibres. It is reported in the literature, that a few cases occurred where the zygoma bone was involved. Surgical repair may leave a slight scar only. In most cases the result is very satisfactory.

#### Lip Cleft Abnormalities.

"Lagocheilos" (like a hare's lip) as described by Thoma <sup>115</sup> is a correct expression of the feature. This cleft may occur in both the upper and lower lip. Mandibular cleft lip is rare and occurs usually in the median line. A median line maxillary cleft is rare, for the expression of the cleft in the maxilla is either usually unilateral or bilateral. Pruzansky has shown that the notching or cleft of the alveolus is directly proportional to the cleft of the lip.

The true hare lip normally occurring in rodents is possibly due to failure of the globular processes (thickened naso median process).

#### The Unilateral Cleft Lip

The cleft extends from the floor of the nostril on the affected side to the vermillion border in the complete cleft occurring more commonly on the left side and more often in males. The incomplete cleft may vary in size from a small cleft notch to that just described. Figure (19) of a bilateral cleft lip illustrates a complete cleft closed surgically and an incomplete, yet untouched. The alveolar process is affected accordingly. The cartilage and nostril are displaced and flared as in Figure (14) with the flaring of the premaxilla and rotation of the segment. The



vermillion border may extend up either side of the cleft to the nostril floor. Here is epithelial loss of tissue with cleft of the orbicularis oris, Oro nasal communication usually occurs with complete cleft of the alveolus.

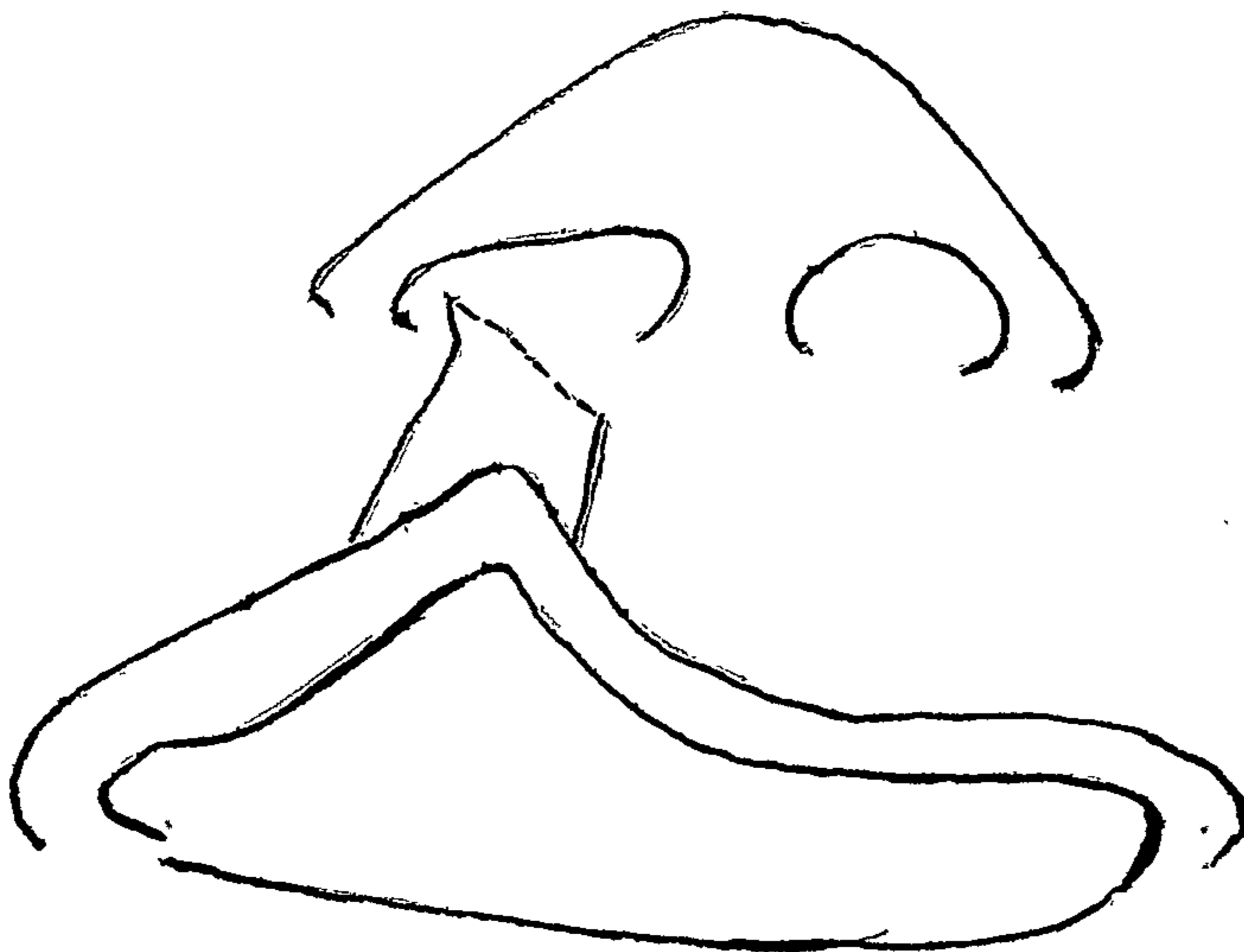
Unilateral Cleft Lip commonly is associated with cleft of the soft and hard palate. Where this occurs two segments are produced unattached, the premaxilla being joined to the non cleft side. Reference is made to the Figures Nos. (2, 3, 9)

The Aberrant Vector of muscle pull and the misplaced insertion of muscle fibres requires that the surgery be conducted as soon as practical, to prevent further distortion.

Surgical Technique - usually attempted in 3rd and 4th week

Simple cleft - incomplete. When not extending to the floor of the nostril, may be carried out by the Veau technique where the segments are of equal length and there is no alveolar cleft. The vermillion should be dissected away and the abutting tissue of the cleft rawed (but not irregularly) and joined as in the diagram No. (16). Mucosa area should be even with scarring minimum.

Figure 16.



Simple Unilateral Cleft of the lip - Complete.

This is usually associated with some degree of alveolar notching; however since the palate is complete, flaring of the nostril is not so marked, but may occur. The vermilion projects up either side of the cleft where the nostril is flattened or distorted. Mirault's and various other style operations may be used. Early operation has the advantage of moulding the alveolar process, where cleft, as soon as possible and presenting the mother with a relatively normal child, an important psychological feat for feeding, and mother and child relationship.

The vermilion border required exactness and delicacy in approximation as any vermilion left in the scar tissue will show as a red streak and spoil the cosmetic affect. The height, width and fullness of the vermilion border should be equal on both sides.

The nostril should be straightened without interference of the patency, small mucosal flaps being raised for closure of the alveolar cleft. The techniques vary. Veau closes the alveolar cleft at the same time as the lip.

The successful techniques proposed have been -

1. Mirault's operation
  2. Blair Brown
  3. Veau operation - suitable for incomplete clefts and utilizes a vomerine flap for the nasal floor.
  4. Hagedorn - Le Mesurier - A technique for complete cleft lip closure.
  5. Modified Rose Thompson, that is used for incomplete cleft repair. This produces a desirable vermilion border where there is fullness of tissue.
- } Produces a full lip.

Mirault and Blair-Brown proposed surgical techniques requiring exact measurements and executions using sterile dye for mapping out the incisions.



Points are determined on the skin and incisions made as in the Figure (17). Their methods are well explained in standard books and it is not intended to reproduce these articles.

The early incisions are made in the mucobuccal folds leaving a small flap of mucosa along the bone and undermining of the tissue of the lip, cheek and nose is accomplished. This undermining and freeing of tissues is important to provide mobility. Where distortion of the nasal cartilage occurs, the nasal tip is freed on that side. The thickness of the distorted alar cartilage is often a problem and in some cases it is necessary to reduce the subcutaneous tissue. The rotated Alar is sutured into place and care is seen that nasal obstruction by tissue does not occur. Blair-Brown utilized packing to prevent this.

Drooping of the Alar cartilage may be removed by excision of a crescent shaped ectodermal section, depending upon the approximation of the lip.

The incision is a Zig Zag or "Z" plasty, rather than a straight line and requires detail in execution. Care should be taken to control bleeding and the occurrence of haematomas.

The vermilion border is separated from the cleft of the lip and held by guy sutures rather than retractors to prevent damage and a flap is cut and used to form the floor of the nostril. Traction across the points X & Y produces the floor of the nostril.

The advocates of this technique claim that the Zig Zag suture line may eradicate the notching of the vermilion that frequently occurs, and reduces the red straight scar line.

The mucous membrane on the inner side of the lip is sutured using the usually vertical mattress sutures.

Barsky utilises steel wire on nasal retaining sutures, a procedure not used universally. Some surgeons have advocated wiring the alveolar segments on the cleft side. This has shown to restrict growth and development, and produce a malocclusion with the maxillary teeth descended lingually to the lowers.

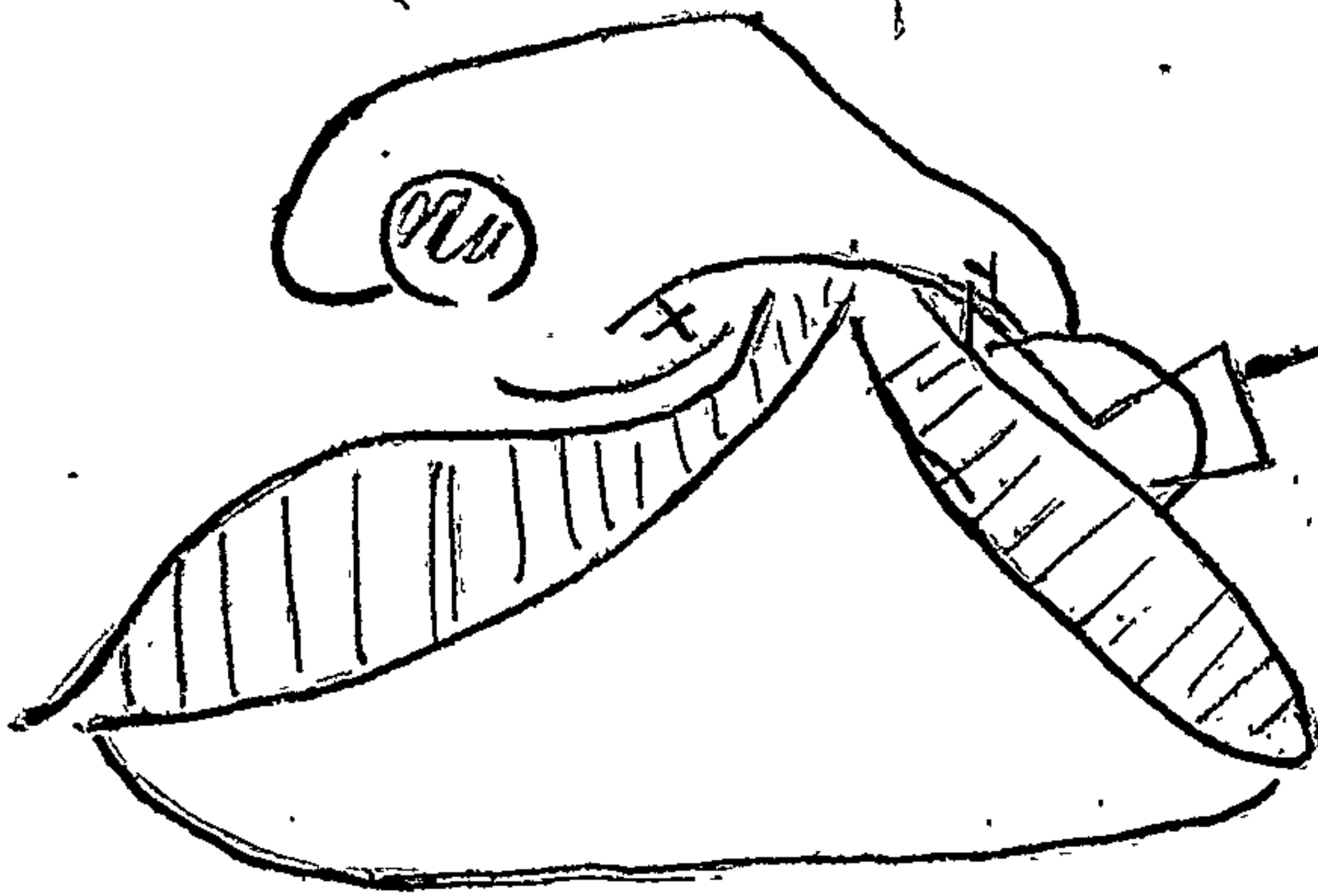
The vermilion border may be widened by horizontal incisions in the mucous membrane of the lip associated with relaxing incision vertically either side - Figure 17(e). As described by Barsky, Gilles and Eslander, a lip of equal length and width is required either side of the cleft, and the incision either side may have to be modified depending upon the individual case. Transfusions, the cleft lip Bow, "Logan Bow" and other post operative care should be strictly adhered to.

The sutures used are deep retention sutures and skin sutures. The latter are removed first at 5 to 7 days. Adjustments to the lip may be required at a later age depending upon growth and alignment of the corners of the mouth due to lip length. The results produced to-day are very satisfactory. The techniques vary and each operator may devise a different method at which he becomes very skilled.



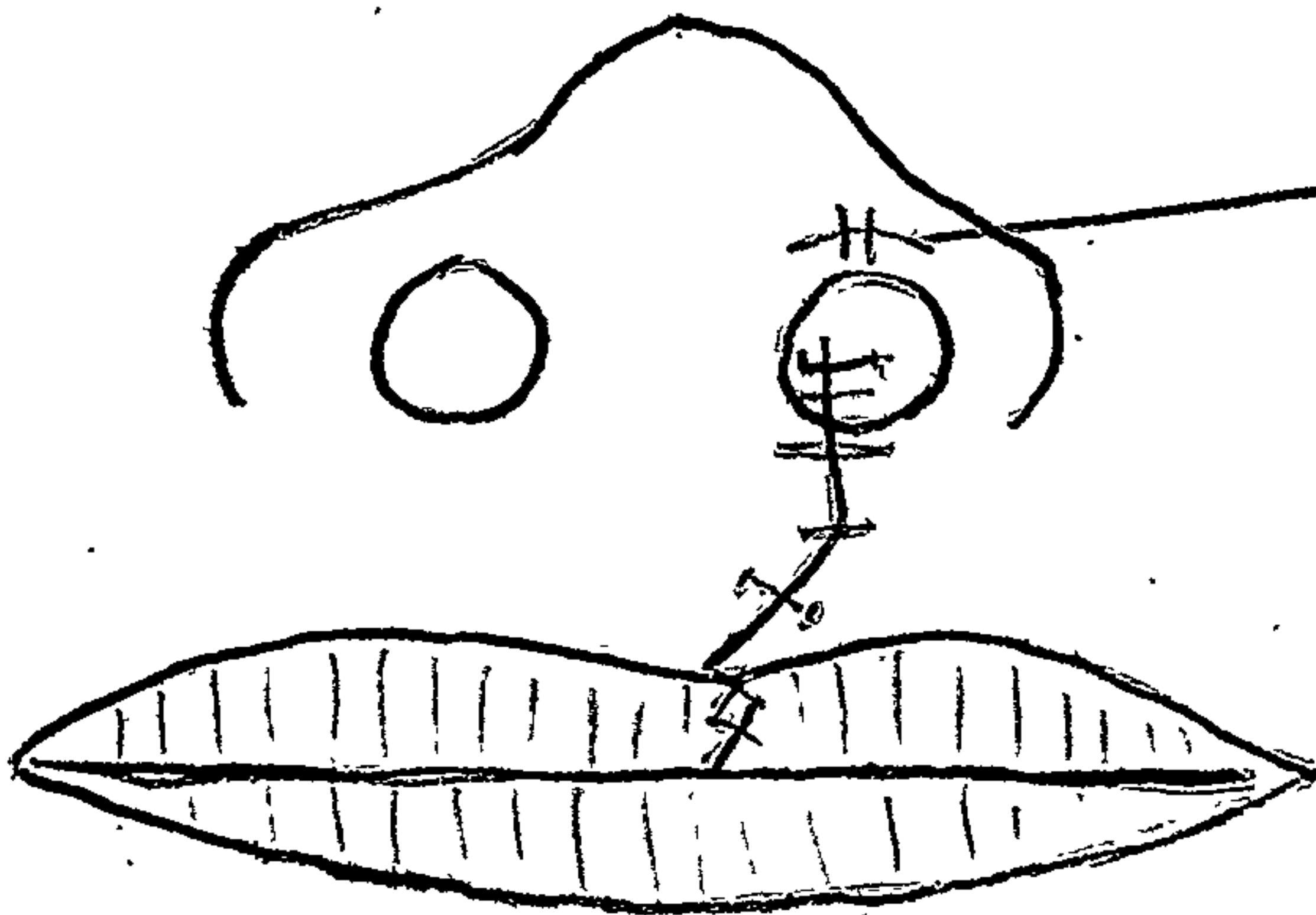
Figure 17.

Note that where the cleft occur on the left side the right maxillary lip is longer than the left, and vice versa. The incision line depends upon these factors and may be varied accordingly.



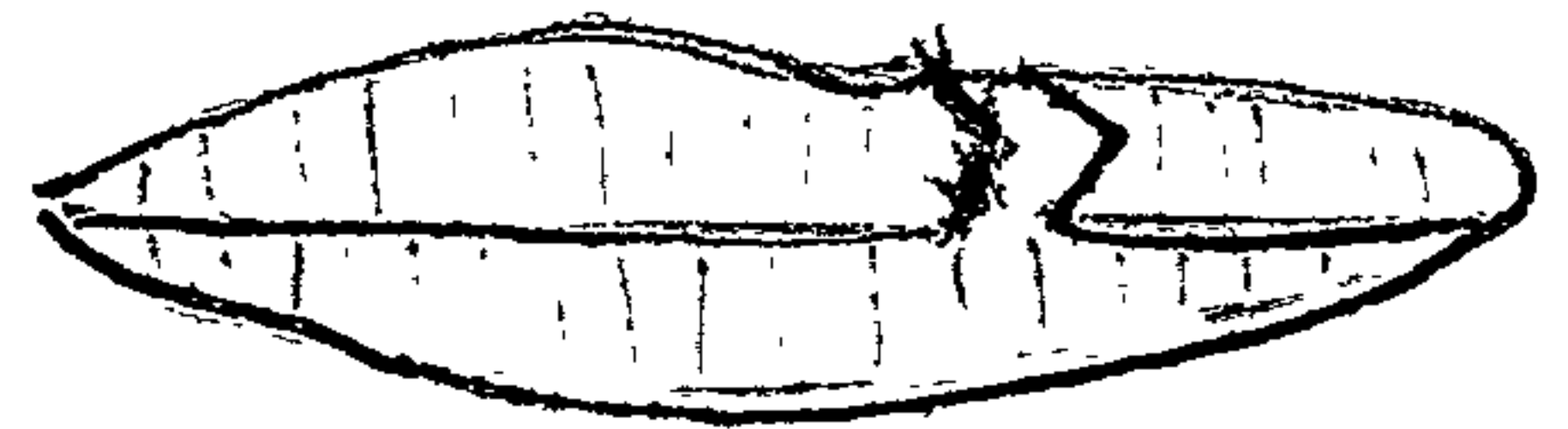
(a)

In this operation the vermillion border is dissected from the lip.

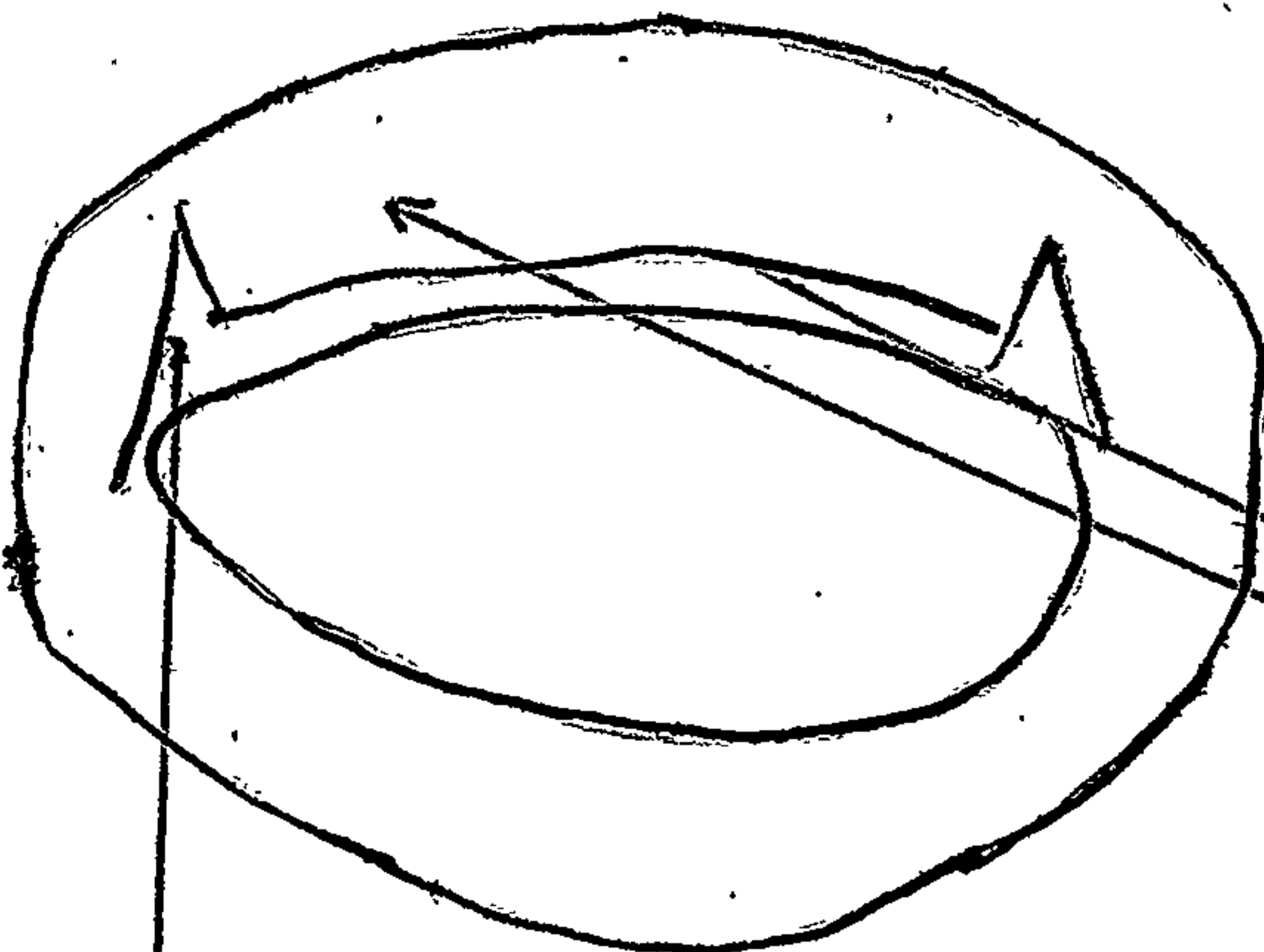


Incision and suturing of crescent shaped skin to correct the flatness of the nostril.

The Sections.



(b)



Incision

Upper lip

Palatal surface

(c)

Relaxing incision.

Veau technique utilizes vomerine flaps to close the floor of

the nostril and this procedure is used widely to-day. A Veau technique results in minimal shrinkage and suturing is carried out layer by layer.

In early surgery little attention was paid to the flattened nostril and suturing of the lip was by adjusting pins with figure eight sutures or wires with buttons. These methods utilised in the period 1885 produced cases with marked cicatrical tissue and not the even approximation of to-day. Notching of the vermilion occurred frequently and contraction of lip tissue.

33

Brophy in his surgical procedures closed the palate before the lip. This procedure is no longer used and its disadvantages will be discussed later.

The clumsy Hornsly compress was replaced by the Logan Bow, an instrument used post-operatively to prevent the sutures being pulled apart when the child cries. Techniques for adjustment of the Alar cartilage were devised by Brophy and many of the fundamental principals in these simple techniques are utilised by many to-day in adjustment to distorted nostrils. The fact that many of these secondary procedures were necessary only indicated the inadequacies of the techniques utilised for the cleft lip closure earlier. More satisfactory results are obtained to-day, resulting in less flattening of the nostril and less secondary operations.

4

Dr. Charles Mayo outlined the requirements of such a technique to produce.

1. Exact length of both maxillary lips.
2. Repositioning of the Alar and approximation.



3. Correct cosmetic appearance of the vermillion.
4. Release of tension of the soft structures from the hard bony tissues providing a mobile upper lip.

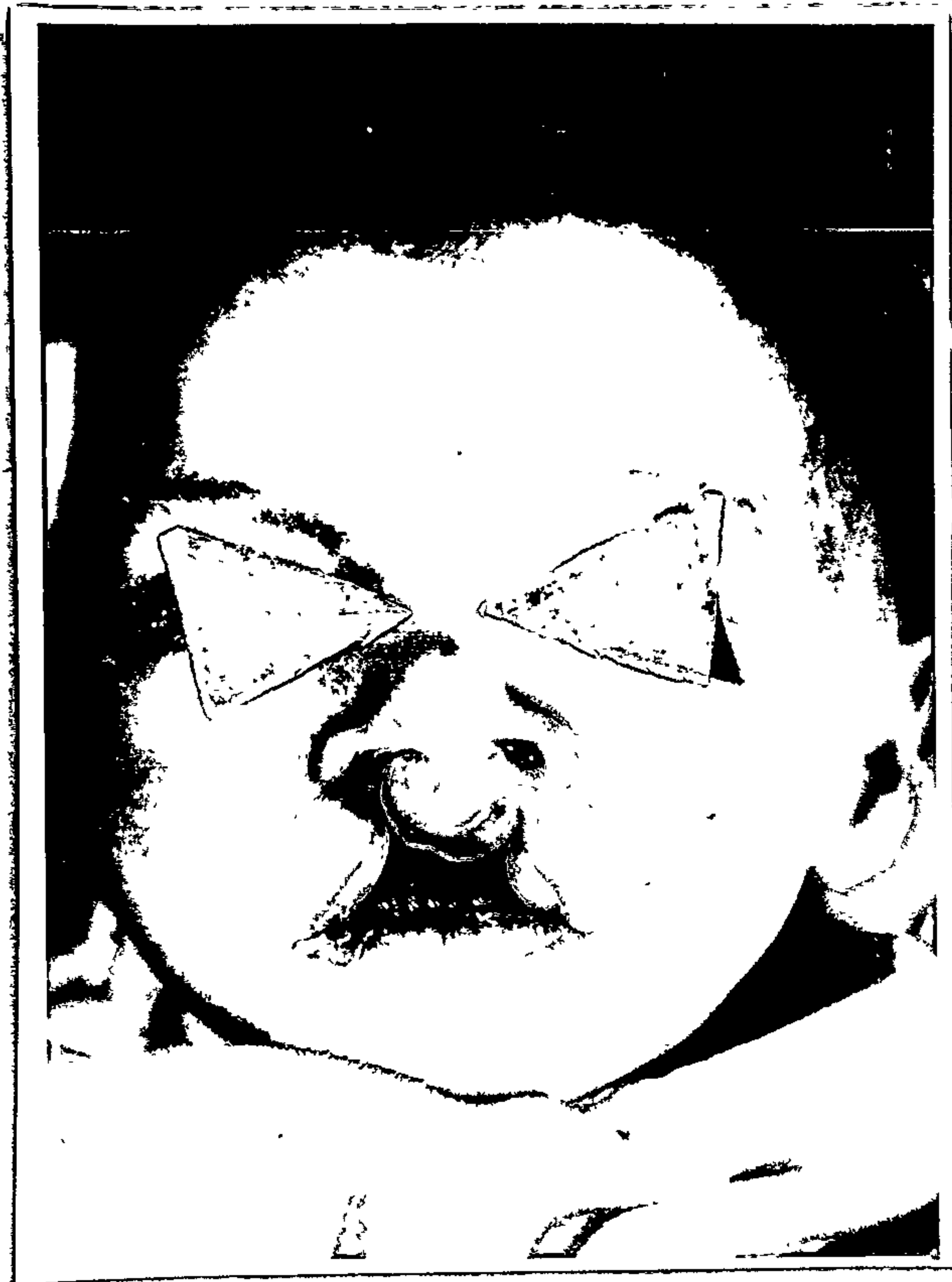

Figure 18. Illustrates bilateral cleft of the lip and alveolus prior to surgery. On the right side the cleft is complete, whilst on the left side incomplete. The right nostril is slightly more flared than the left; compare this with models in orthodontic section. Figs. (8b). This was associated with cleft palate.

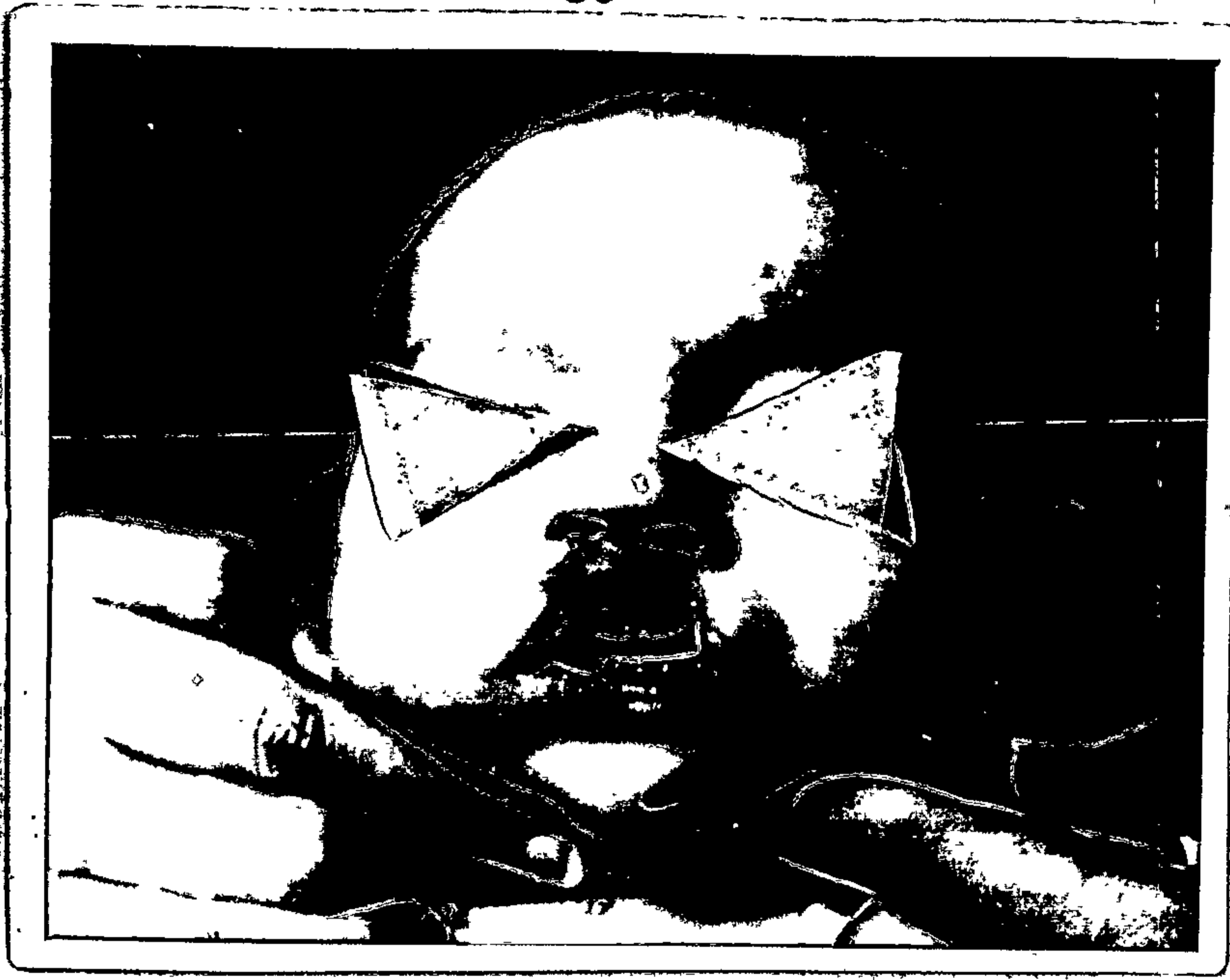

Figure 19. Illustrates surgical repair on one side of a bilateral cleft lip and alveolus, in the normal two stage repair. This was associated with cleft palate.



Figure 20. Illustrates the prominence of the premaxillary element in bilateral cleft lip and alveolus associated with cleft palate. Refer to Fig. (82).





Figure 21. Bilateral cleft lip and alveolus anterior view some years following surgery. Refer to figure (90).



Figure 22. Profile view of bilateral cleft lip and alveolus following surgery. Note, the deficiency in this case of the maxillary element. Compare with Figure (91.) where the typical prominence of most cases exists.

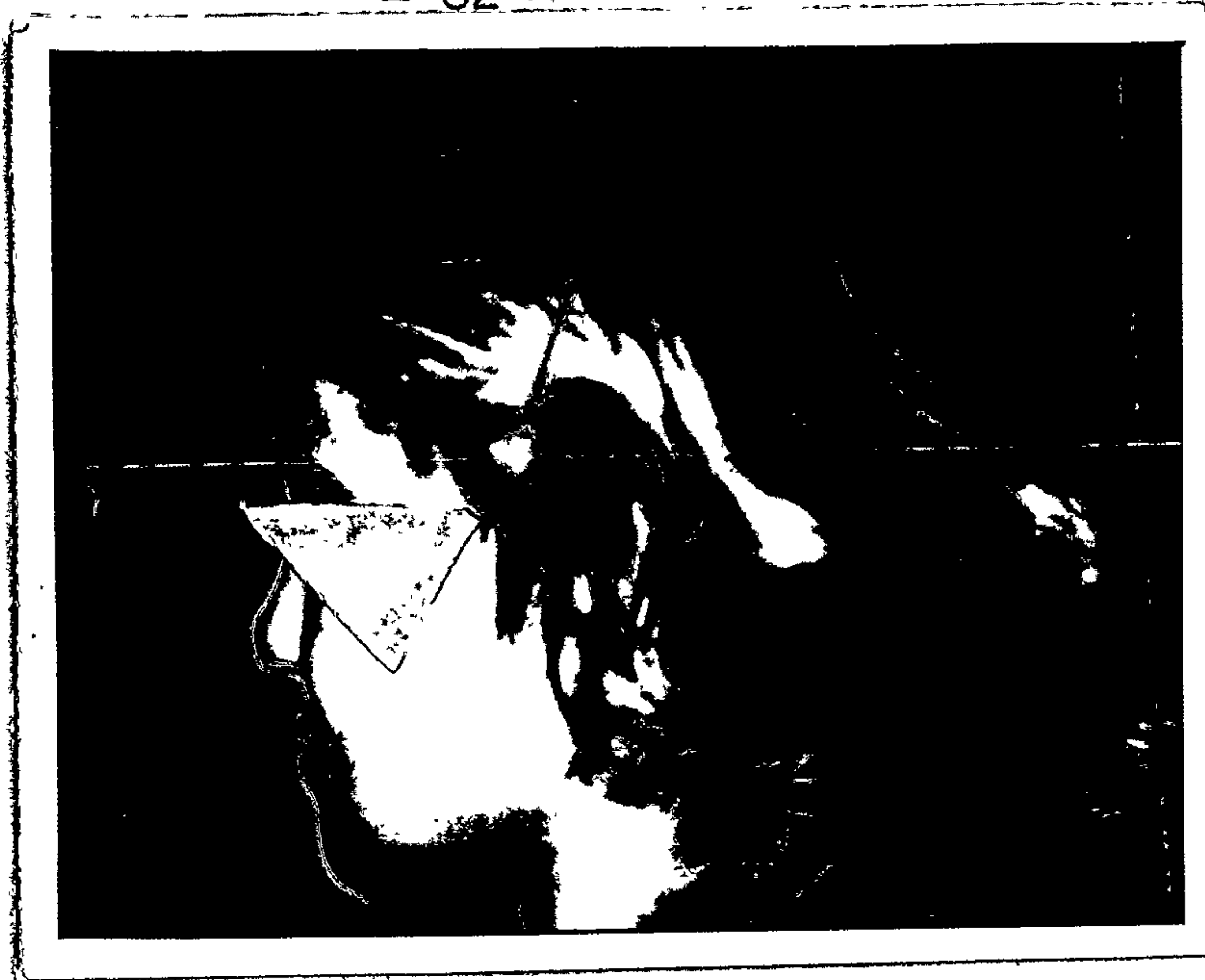

Figure 23. Illustrates the result of an unilateral cleft lip for comparison with Fig. 22. The profile in this case is reasonably normal, compare with Figure (91).

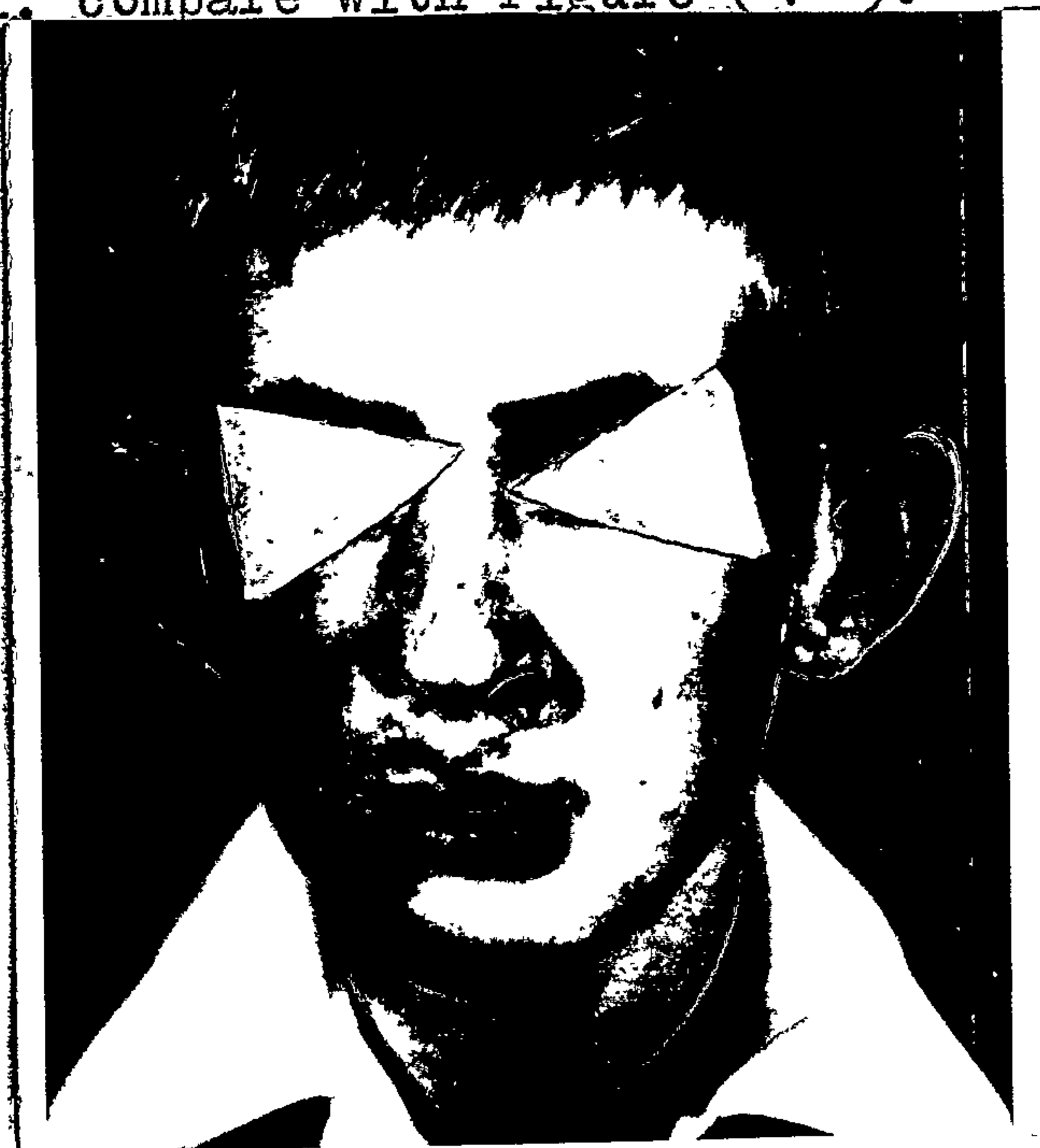


Figure 24. Illustrates the repair of a bilateral cleft lip and alveolus. The protruding mandibular lip is obvious and the tight maxillary lip. This surgical procedure does not provide the correct width to the lip. The premaxilla and prolabium in this case was elementary and undeveloped. Compare with Figure No. (90).



Bilateral Cleft lip surgical procedures.

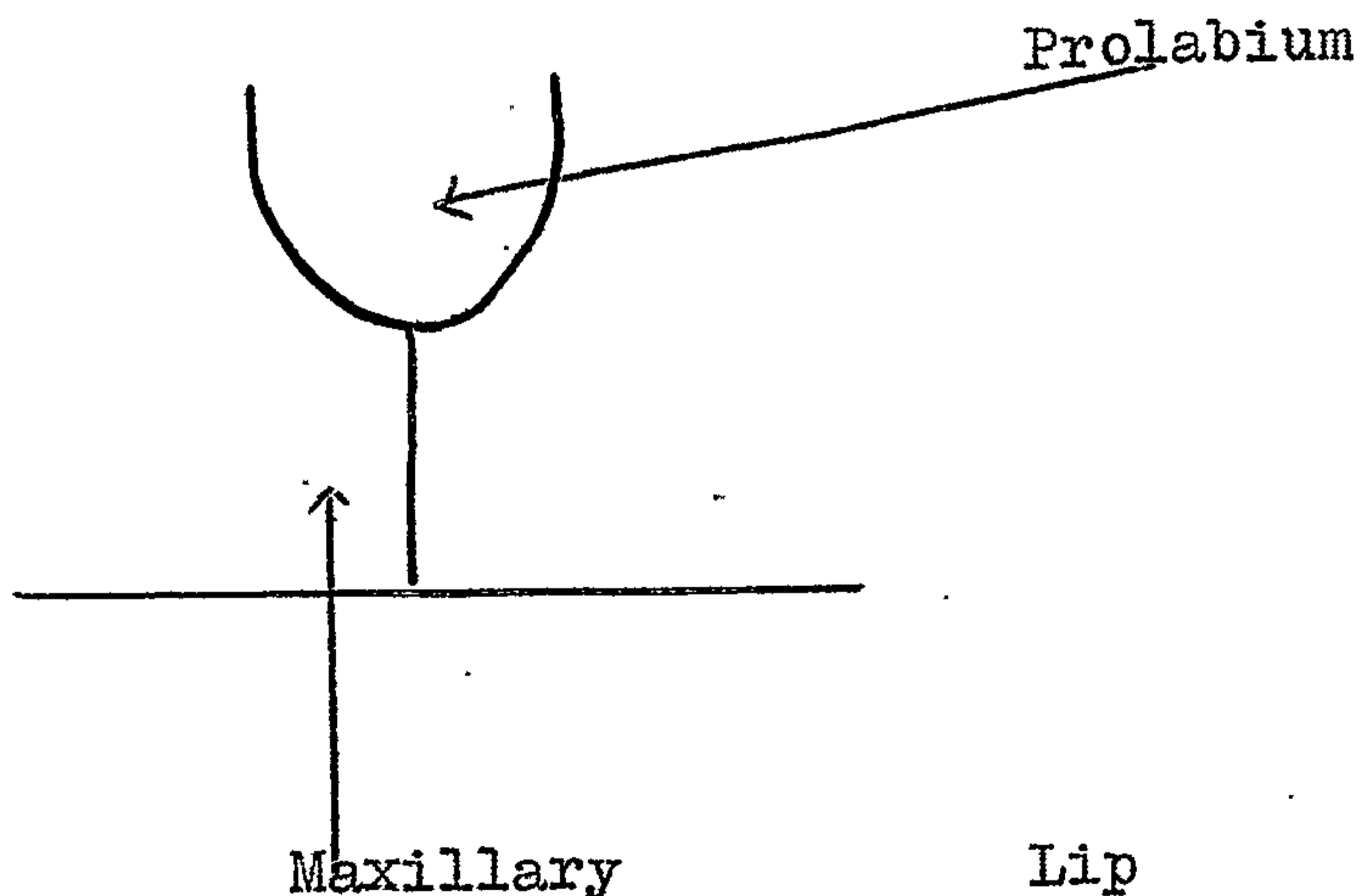
Introduction. Surgical procedures in this type have changed rapidly, and with new knowledge on growth, more changes will occur in techniques.

The problems existing in these cases are the protruding premaxilla and the bilateral collapse of the maxillary units.

The tightness of the maxillary lip has been solved in most cases where a degree of soft tissue prolabium exists, by a change in the surgical procedure. The problem of the protruding premaxilla is being attacked by both the surgeons and the orthodontists.

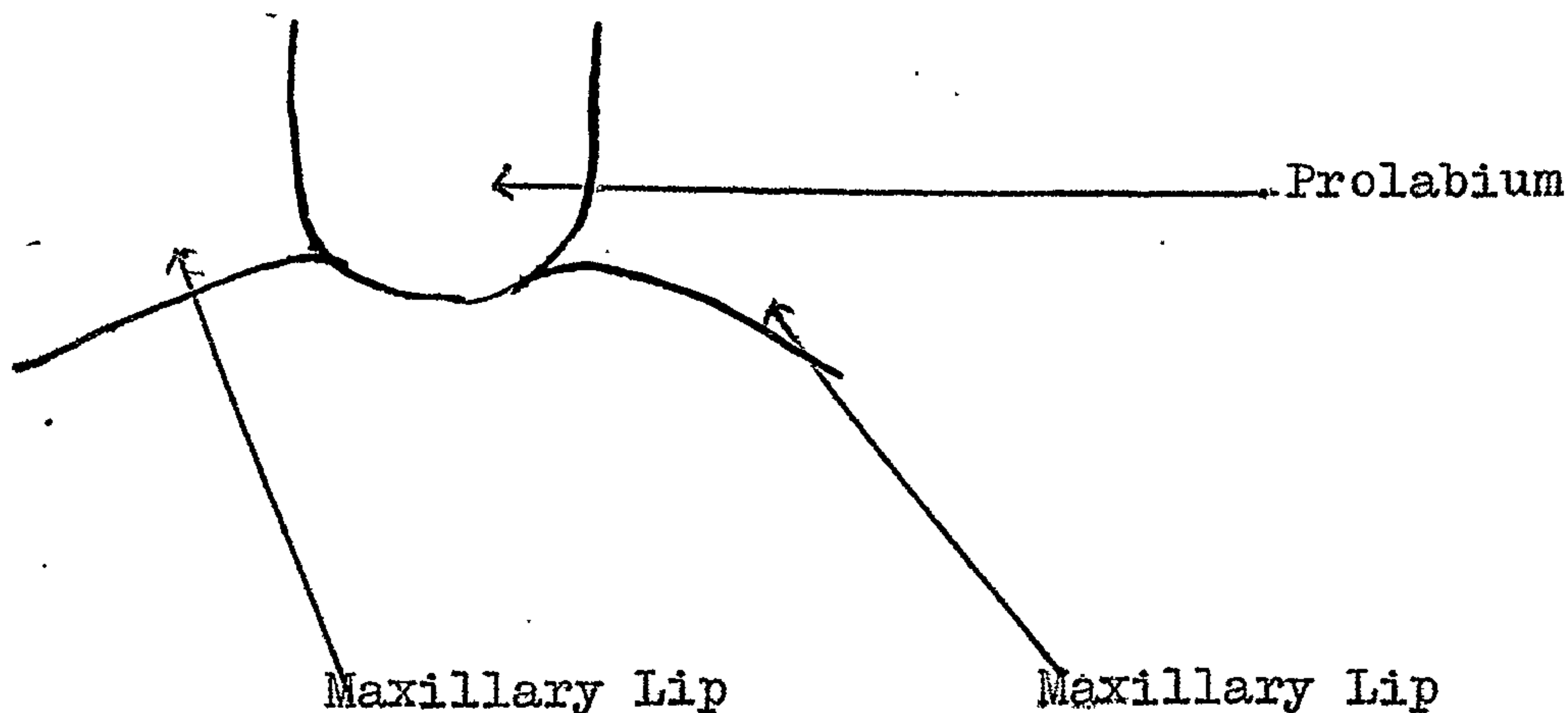
<sup>89</sup>Pruzansky has shown that the premaxilla, although prominent, is caught up with in growth by the maxilla and mandible by the age of 5 years. However, some cases clinically examined show the protruding premaxilla.

Figure 25. At 5 years.



The light maxillary lip of this design when examined clinically was found to exist associated with a very small premaxilla. Where soft tissue prolabium allowed, the technique was changed to the following design.

Figure 26.



This provided a loose, rather short maxillary lip associated with a prominent premaxilla. As yet no set plan of treatment for these cases has been presented.

126

E. Price closes the alveolar cleft by cancellous chip grafts from the Iliac crest associated with an acrylic splint to the maxillae.

Orthodontic treatment for the bilateral collapse so often occurring may be associated with surgical or orthodontic retraction of the premaxilla. But this retraction is merely a rotation of the premaxilla and incisors. The result upon the cartilaginous nasal septum and vomer is not yet known, but nasal obstruction due to deflection may be a sequel.

126

Surgical removal, a "V" wedge resection of the septum will provide distal placement of the premaxilla but requires a plaster head cap with a central connecting bar to the maxillary splint and universal clamps. Orthodontic expansion is still usually required for the maxillary elements to restore the bilateral collapse.

As yet the problem is far from solved. Where the premaxilla

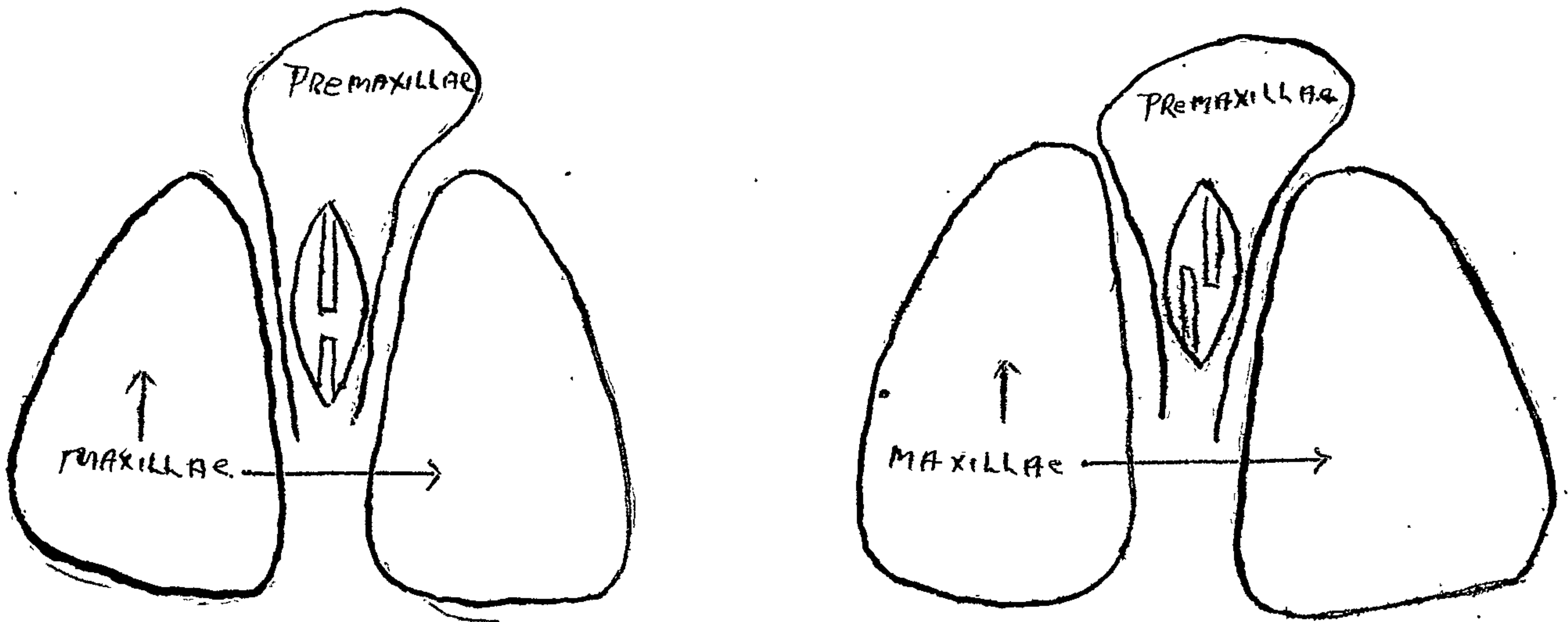


is small and the tight maxillary lip occurs orthodontia is at a disadvantage for expansion, although satisfactory results may be produced.

These patients are frequently candidates for the Abbé Eslander "V" switch operation that will provide more mobility, aiding and facilitating intra-oral treatment. These cases frequently require a prosthesis to replace lost dental structures.

Figure 27.

15.126  
Von Bardelbens Technique.



This technique may be used in the young infant where the vomer is a normal thickness. Where bulk exists in this inferior vomerine border, sliding bony segments cannot be produced, and a wedge resection may be necessary.

126.128

An alternative method is splitting the vomer and allowing the premaxilla to slide back between the two sectional elements.

33

Brophy's earlier treatment of wiring and pinning the maxilla together laterally at the time of closure of the lip, can only be condemned in these cases.

He stated - "It was predicted that as the result of my operation the upper arch and jaw would be contracted and be made narrower than the lower one and that it must always remain contracted - that teeth when they have erupted would be within the arch of the lower ones. My answer was that a skilled orthodontist would be able to spread the arch and correct the irregularity." This incorrect treatment resulted in some of the greatest distortions in cleft palate history and the principles are not upheld to-day.

The method of heavy wiring of the jaws into one unit was not only reflected in the oral cavity but also in the nasal floor.

As this treatment is not upheld, neither should the constant removal of the premaxilla and its replacement by a prothesis. The Premaxilla should not be removed even though it may amount to a small prominence on the end of the nose, claims Barsky,<sup>18</sup> but they may prove a problem if completely mobile. The degree of tissue loss by the clefts is a large influencing factor in palatal collapse and these features will be discussed in the respective chapter.

#### Surgical repair of Bilateral Cleft Lip.

Type A. The procedure utilised in previous cases and demonstrated in most text books are those of the Mirault Owen style. The cleft may be complete or incomplete or any variation of the two. In complete bilateral cleft the cleft extends into the floor of the nostril on each side. In incomplete it may extend from a notch of the vermillion border to just below the nostril floor. This variation will decide the degree of musculature cleft, an important assessment. The premaxilla may protrude quite markedly and its



position will vary depending upon the palatal cleft and its extent.

These cases are usually the severest expression of the deformity and are usually associated with a complete cleft of the soft and hard palate. The degree of cleft in the alveolus is usually directly proportional to the degree of the clefts of the lip.

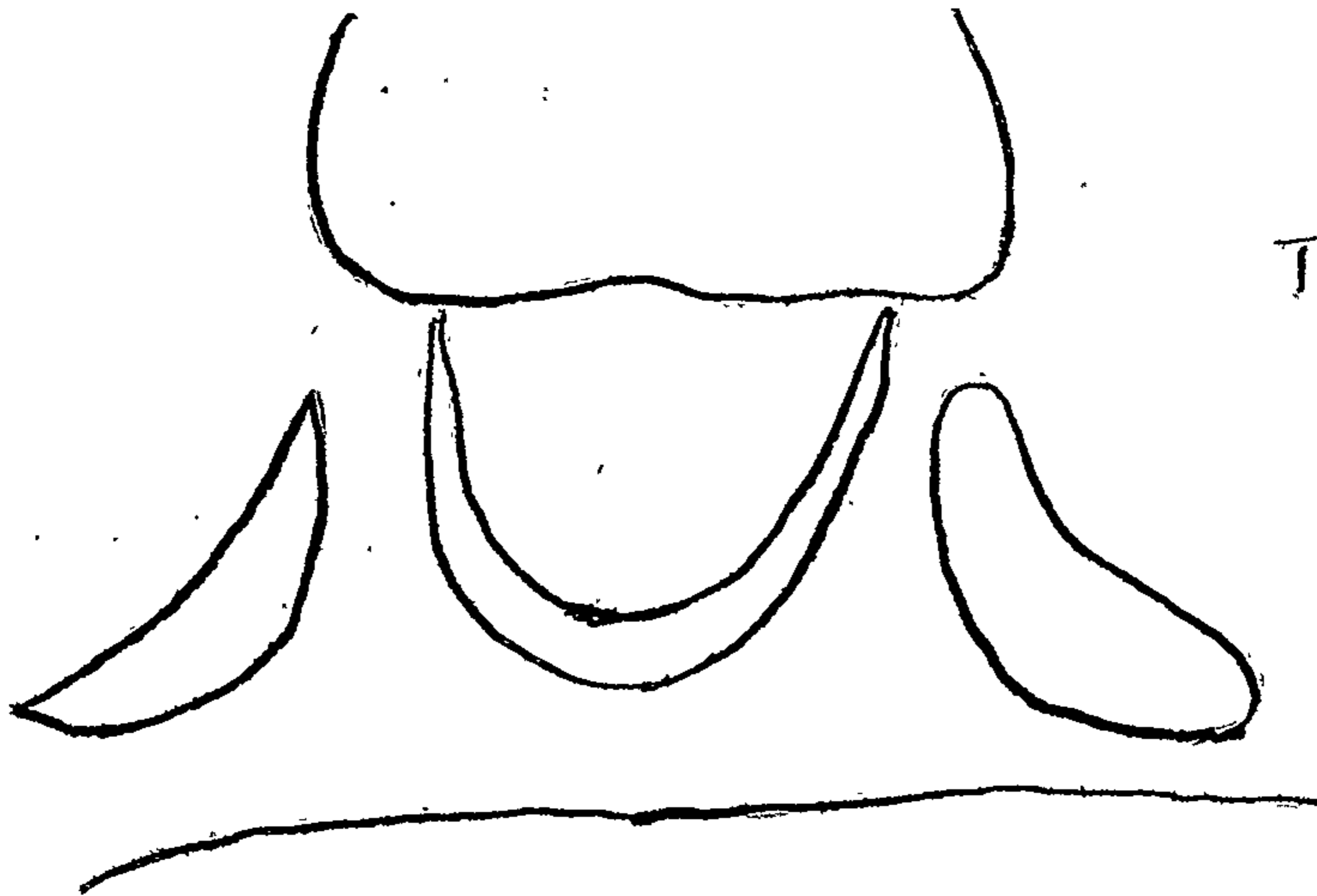
The protruding premaxilla will vary in size, width and replacement and on occasions will be atrophic. The tooth buds present too, will be found to vary with the size of the premaxilla. The consideration of repositioning the premaxilla viewed by Von Bardelebens<sup>18</sup>. The "V" section removal will only rotate the premaxilla as shown by Brophy<sup>33</sup>. Von Bardelebens<sup>18</sup> technique suggested repositioning by an oblique incision in the vomer. See figure (27) This technique slides the vomer sections, one upon the other and may provide small retractions in position. This is attempted in early infancy.

Figure (28)

AS RECORDED BY

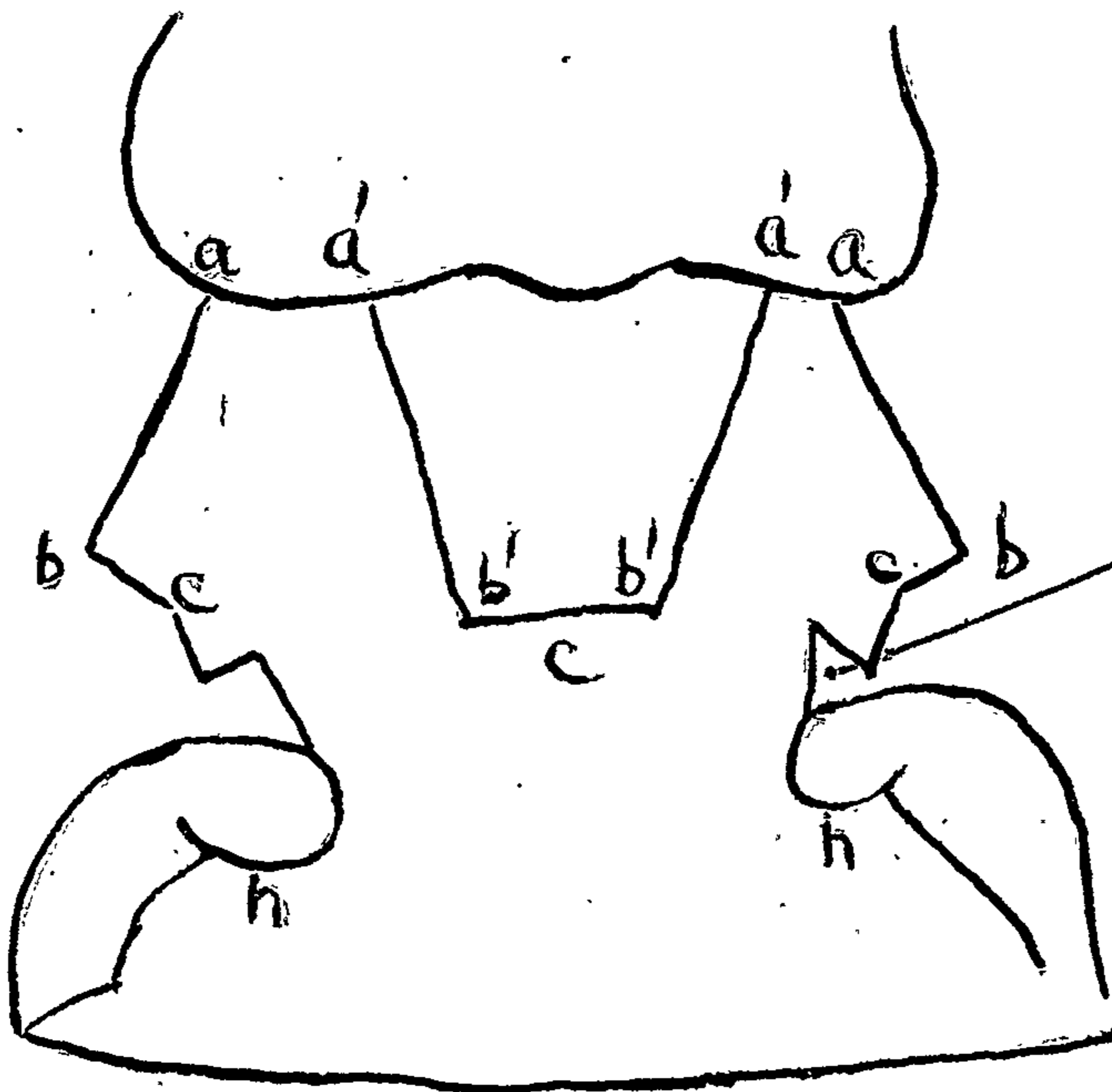
JOSEPH BARSKY

(a)



The Segments

(b)



The Z PLASTY  
FOR EXTENSION  
OF SOFT  
TISSUE:



(6)

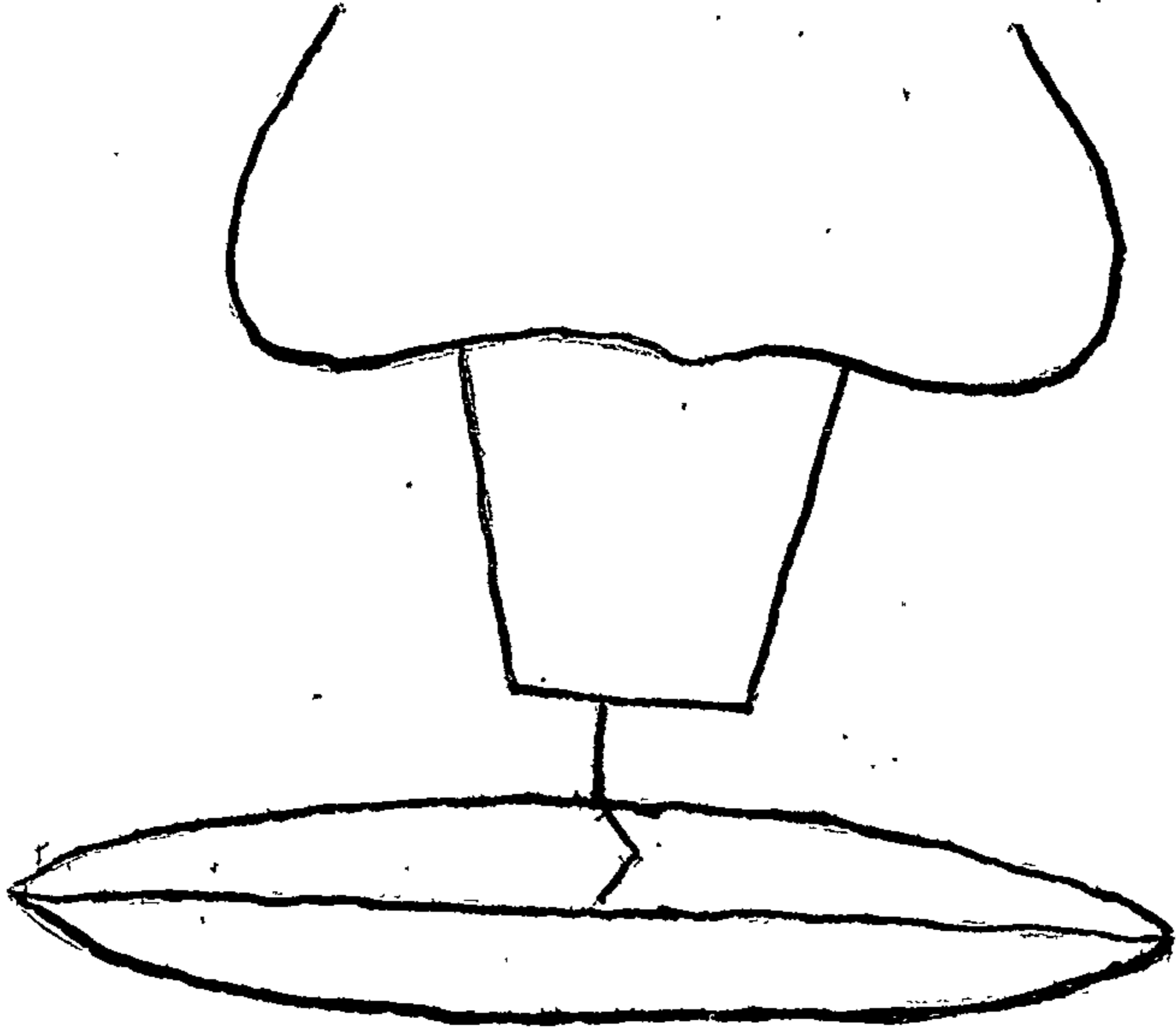
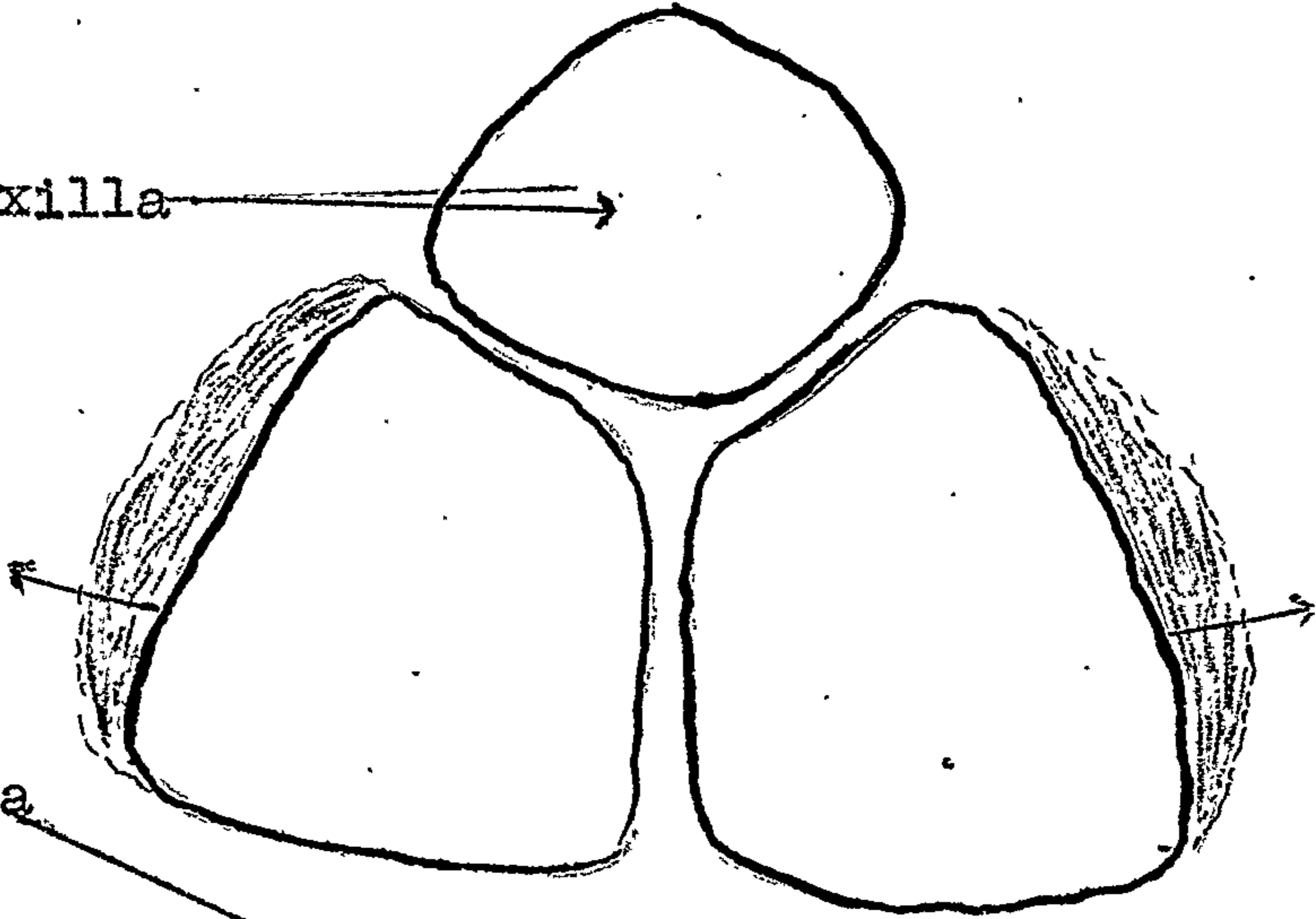


Figure (29)

Prominent premaxilla



Small premaxilla

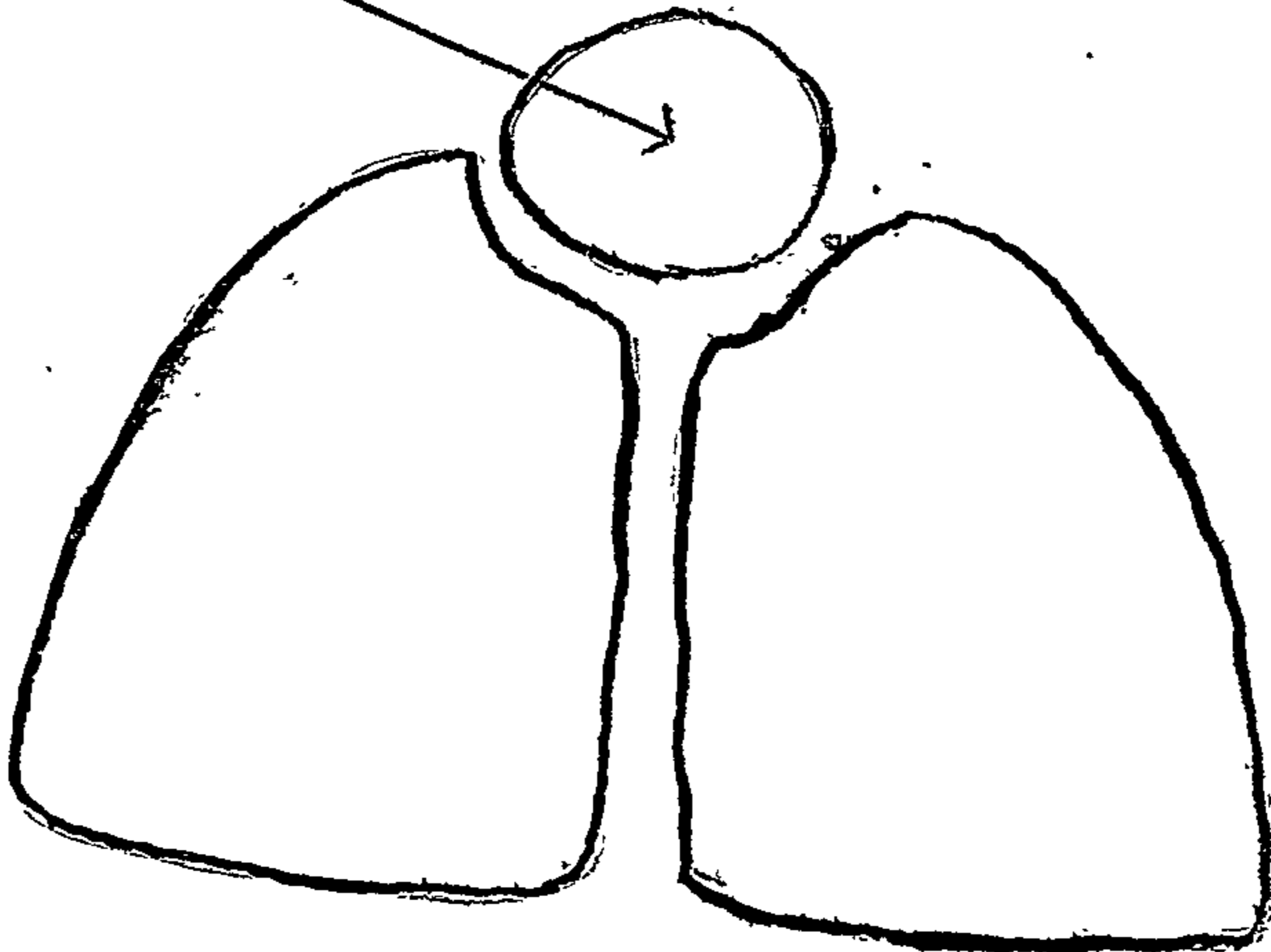



Figure (30)

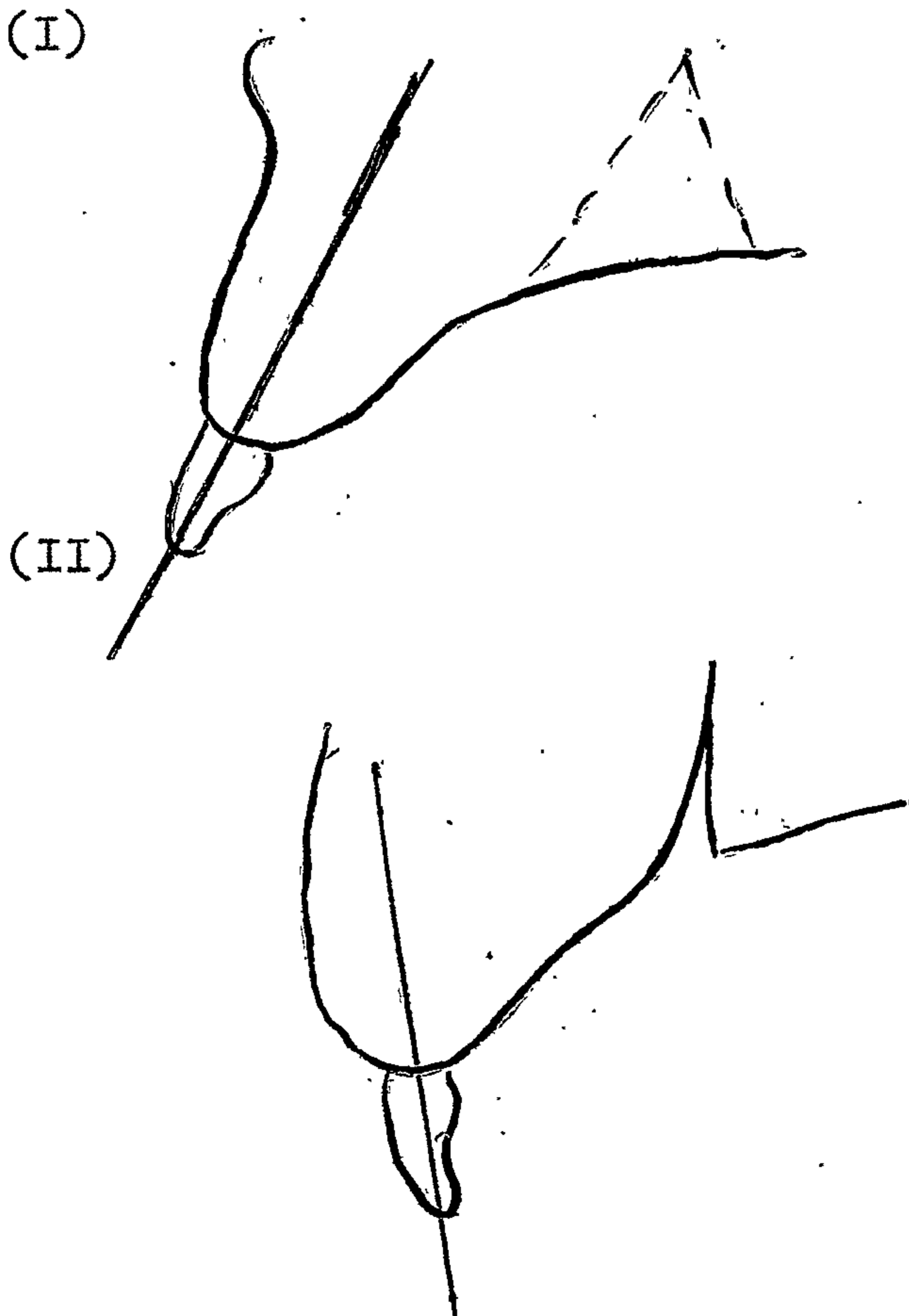
TWO STAGE SURGICAL PROCEDURE.



If the premaxilla be small, it is obvious that it will fail to fill the space, resulting in lack of support to the lateral maxillary elements.

FIG (31)

Vomer Section.



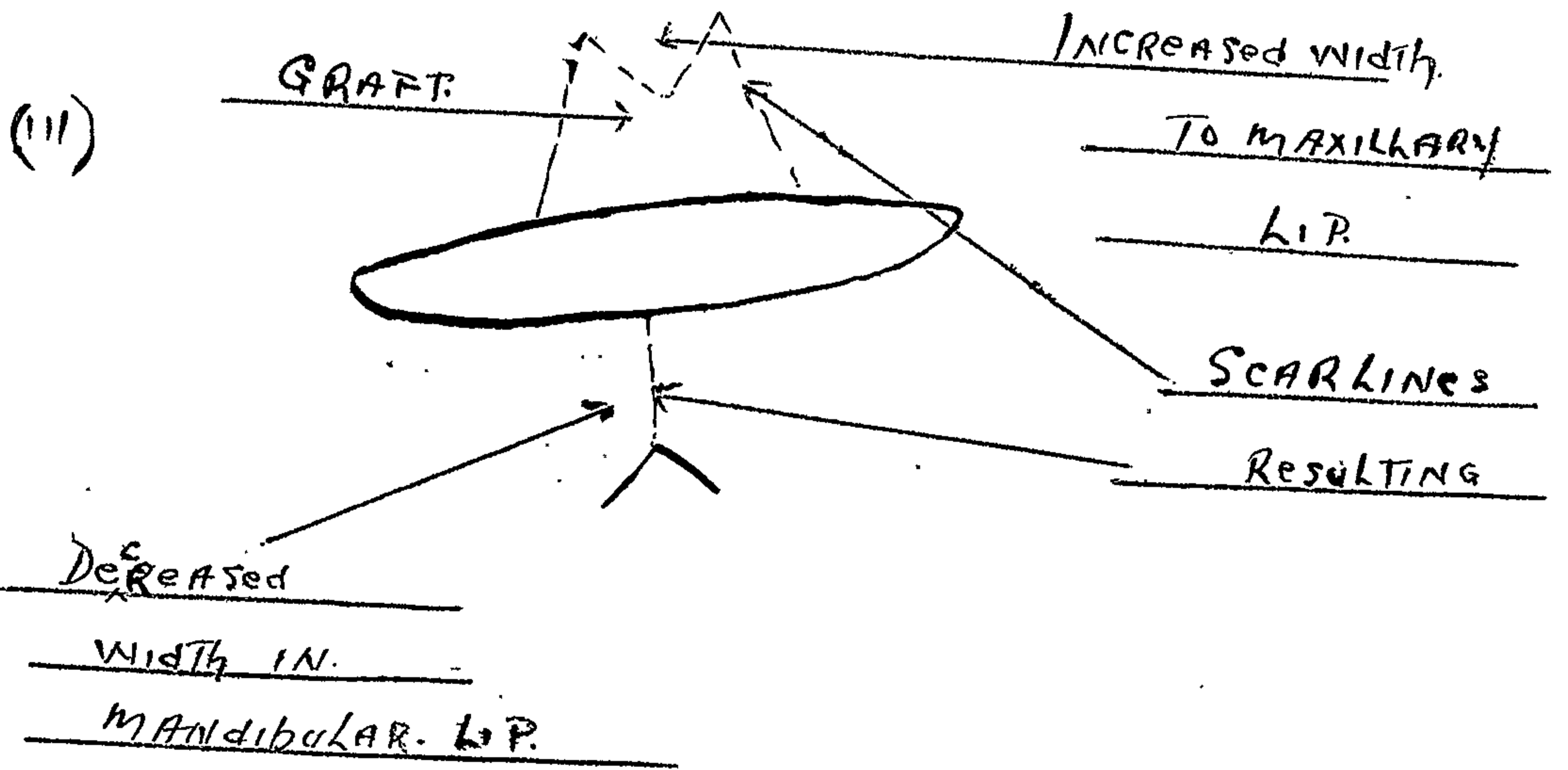

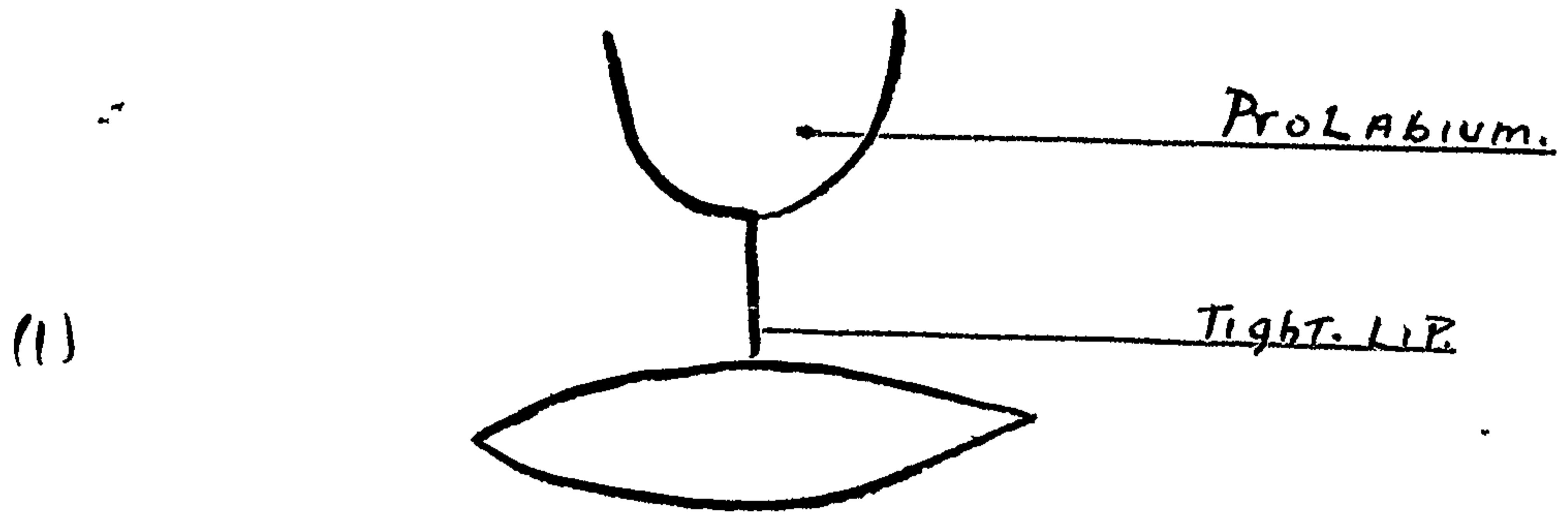
Vomer section will result in distal lipping of the upper incisor teeth.

Attempted distal movement without sectioning results possibly in a buckling of the septum and nasal obstruction.



Figure (32)

The Abbe' "V" Switch.



Brown, McDonnell and Byars all suggested and used a spare section from the vomer and the premaxilla was positioned and held by wiring or pinning. This method may have some advantages but may produce unaccounted for growth disturbance. Union does not occur, a fibrous opposition only. This is possibly due to the good blood supply to the middle 1/3rd of the face.

<sup>18</sup>  
The operation proposed by Barksy and based upon procedures of Brophy, Mirault and Owen provide the Y shaped upper lip. The surgical procedures are similar to those described in the unilateral procedure.

The incisions are made on either side of the muco-buccal fold and the tension released. The incision may be continued in the lining of the ala between the upper and lower cartilages and the lip and ala are mobilized. Exactness and delicacy are required, and the proper trimming of the flap and removal of the vermillion to the correct position. A "V" shaped joint of the vermillion is made to produce a Zig Zag suture line and the mucosa closed. Mucosa to mucosa and skin to skin is maintained.

Veau's double technique was used in many cases of bilateral incomplete cleft lip. The disadvantages of the above technique are illustrated in Figures (28-32).

1. Produced a long tight upper lip - non flaccid.
2. Bunching of the prolabium that made it difficult for columella assistance surgically.
3. This did not aid growth and development of the premaxilla.
4. Required frequently Abbé Eslander operation "V" switch at a later age.
5. The technique is difficult.
6. Cosmetics are poor and a notched vermillion may result.



7. Cicatricial tissue is frequently marked. Brophy utilised the Logan lip bow to reduce this cicatricial tissue without results.

Technique B. Ref. Figure (30).

It was found that if the lateral maxillary Labial processes are joined to the prolabium, the upper lip appears at first in some cases short, with loss of the bow shapes and notching. However, with growth and development the lip appears to lengthen. The prolabium appears to develop and the notching gradually resolves but not completely.

This surgical procedure has the following advantages -

1. Wide flaccid upper lip.
2. Easier Orthodontic expansion.
3. Correct moulding of the alveolar segments usually.
4. Normal facial growth and development possible in the facial complex.
5. Allows for increase in respiration. Nostrils do not appear to be pinched and the nasal floor is wider.
6. Advances and relaxation of the columella are easier.

The surgical Procedure.

The procedure will vary depending upon the degree of the clefts whether complete or incomplete. One side is treated at a time as illustrated in Figure (19). The procedure is similar to that of the unilateral technique with modifications from the Veau procedure and the Mirault depending upon the degree of the cleft. The incision is commenced in the mucobuccal fold and the tissue freed from tension. Care is taken to restore the nostril floor and to provide a lip free of vermillion.

Muscle sutures are applied before skin sutures, the skin sutures are inserted from above downwards.

Where the prolabium is markedly undeveloped, this technique may not be indicated. It is usually applicable to those cases where there is a prominent or normal premaxilla.

A summary of the complications of Bilateral Cases.

1. In most cases the premaxilla is placed forward of cranial structures and the maxilla collapsed bilaterally.
2. In a number of patients there was a short upper lip with <sup>50</sup> bunch cicatricial tissue in the labial sulcus.
3. In early years scar tissue is favourable; holding in a splint like fashion the premaxilla, even compelling it at times to position posteriorly during growth.
4. At 4 to 6 years the nose is frequently depressed at the lip. Fig. (91).
5. A short or long maxillary lip that may complicate orthodontic treatment.
6. A bulbous type premaxilla with increase over bite and overjet, similar to a class II malocclusion. The lower incisor may over-rupt and bite into the soft tissue, the lower arch assuming an abnormal "curve of spee".
7. In some cases an opened bite occurred anteriorly.
8. The prolabium may be bunched.
9. It may be necessary by graft to lengthen the labial sulcus but this occurs rarely.
10. Lack of completion of the nasal floor.
11. Irregularities of the mucocutaneous junction and vermillion border.
12. Scarring of the skin surface may be quite marked.
13. The vermillion may, at times, encroach upon the skin.
14. The levator labii superioris Alaeqae nasi may be disturbed or missing.
15. Nasal disfigurement.



No single operation can restore this abnormality and persistent attention during the first ten years at least is required to provide the completely normal result for a cleft case.

<sup>33</sup>  
Brophy claimed in 1923 that by approximating the bones, the nasal deformity was corrected. Unfortunately this did not occur and frequently it is necessary to do minor repairs later in life.

The surgical approaches in previously quoted cases require accurate detail in measurement of lip length. The "Z" plasty is a favourable means of increasing tissue length especially in scar tissue. To lengthen a lip, it may be required to do a buccal inlay with the aid of Gutta Percha and a prothesis to aid the repair by tissue placement.

In many cases secondary operations are required to tidy up small adjustments. The floor of the nostril is frequently a difficult feature to restore, and irregularities of the mucocutaneous junction may occur with fistula forming.

In many cases a flat lip may occur due to faulty framework and requires prosthesis for restoration of contour. Small notches may be repaired in the vermillion by the V to Y procedure, the incision being placed on the inner surface of the lip.

<sup>18</sup>  
The Gilles technique may be used for the restoration of the Cupid's Bow which will restore a pleasing curve to the mucocutaneous junction, a new arch being formed.

Nasal disfigurements frequently occur as a flattened ala <sup>18</sup> cartilage or the dropping of the cartilaginous rim. Barsky states - "flattening of the ala may be corrected in most cases by advancing the medial Crus of the lower ala cartilaginous tissue on the side of defect to meet its mate on the opposite side.

At the same time the floor of the nostril must be brought medially and somewhat forward. This is accomplished by a mid columella incision which may start at the base and extend towards the tip, where it curves towards the normal side".

This incision followed by undermining and advancing of the half incised columella provides a satisfactory result, using mattress sutures. The drooping alar may be raised by splitting the alar cartilage and swinging the cartilaginous pedicle to the mid-superior line and suturing.

Figures (84, 90), illustrates the short depressed nasal tip and short columella that may result in bilateral cleft cases. This requires advancing the tip of the nostril by lengthening the columella. This is achieved by taking flaps from the side of the columella and floor of the nostril at an appropriate age, not too young.

Deviations of the columella may be corrected by the typical Z incision depending upon whether this may occur at the tip or base of the columella. Figure (70) illustrates a deviation.

Where insufficiency of the maxillary lip occurs the Abbe Eslander type of operation provided the best clinical results. Figures (21, 22), illustrates the degree of discrepancy when compared to a normal lip. In early operations a "V" section was removed, but observation indicated that the section was more "W" shaped inverted and this section is removed from the lower lip and transferred to the maxillary lip as a pedicle graft; a two section technique is used. On the second operation the pedicle is severed from the mandibular lip. This does produce some



Figure (33) VARIOUS TYPES OF LIPS FOLLOWING SURGERY

(I)

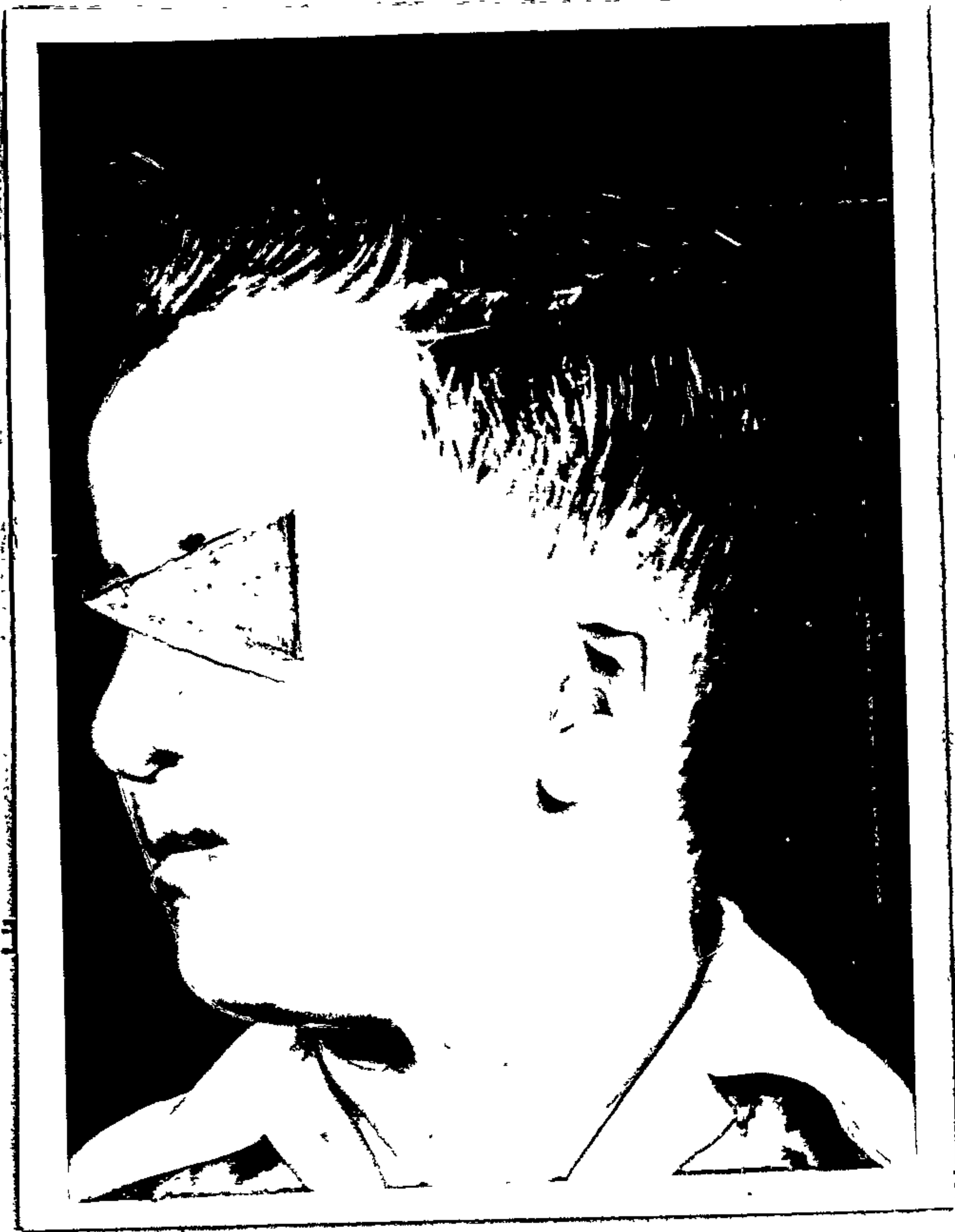MAXILLARY Lip tight.

TYPE. A.

TIGHT

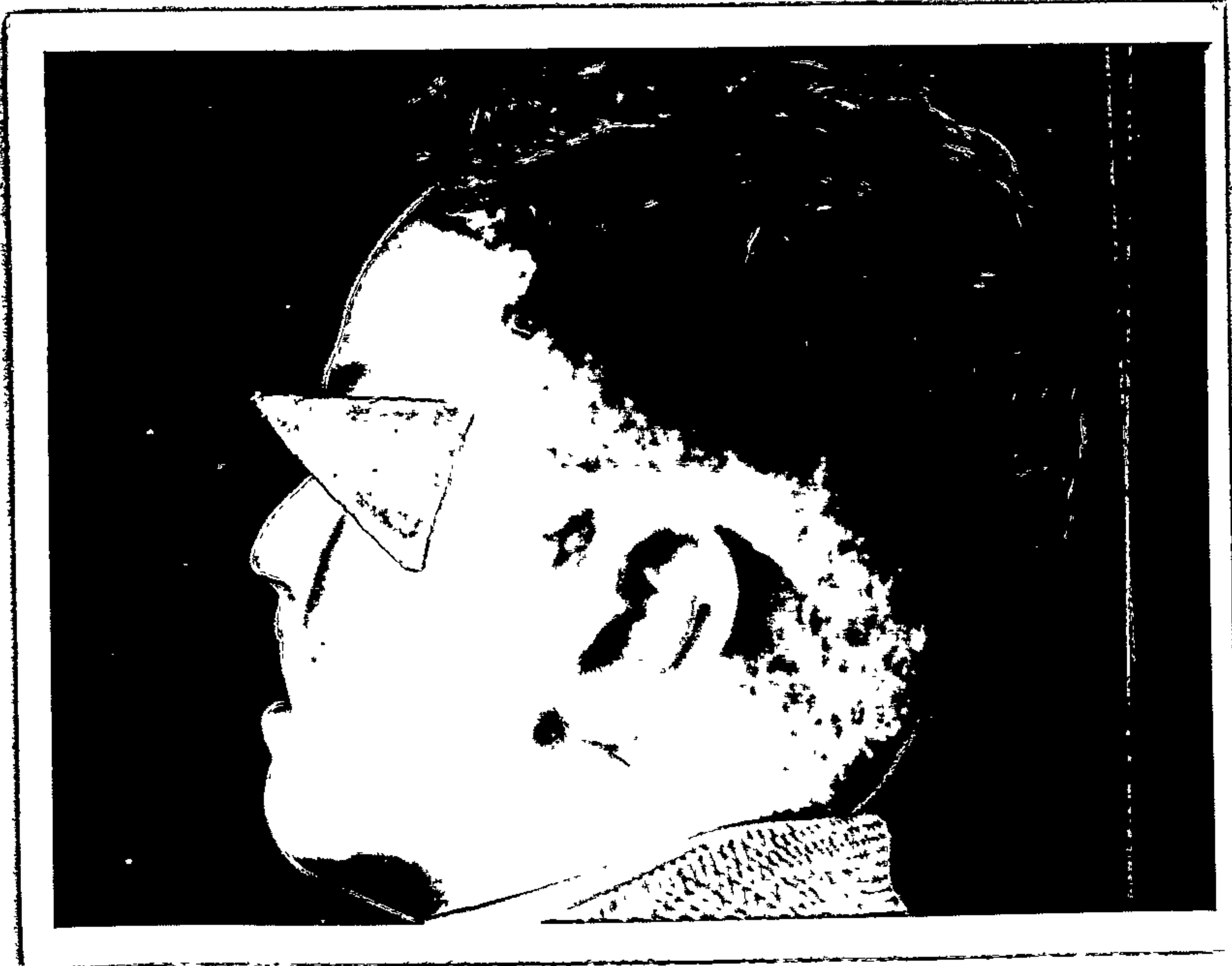MAXILLARY

LIPS



ANTERIOR VIEW

II



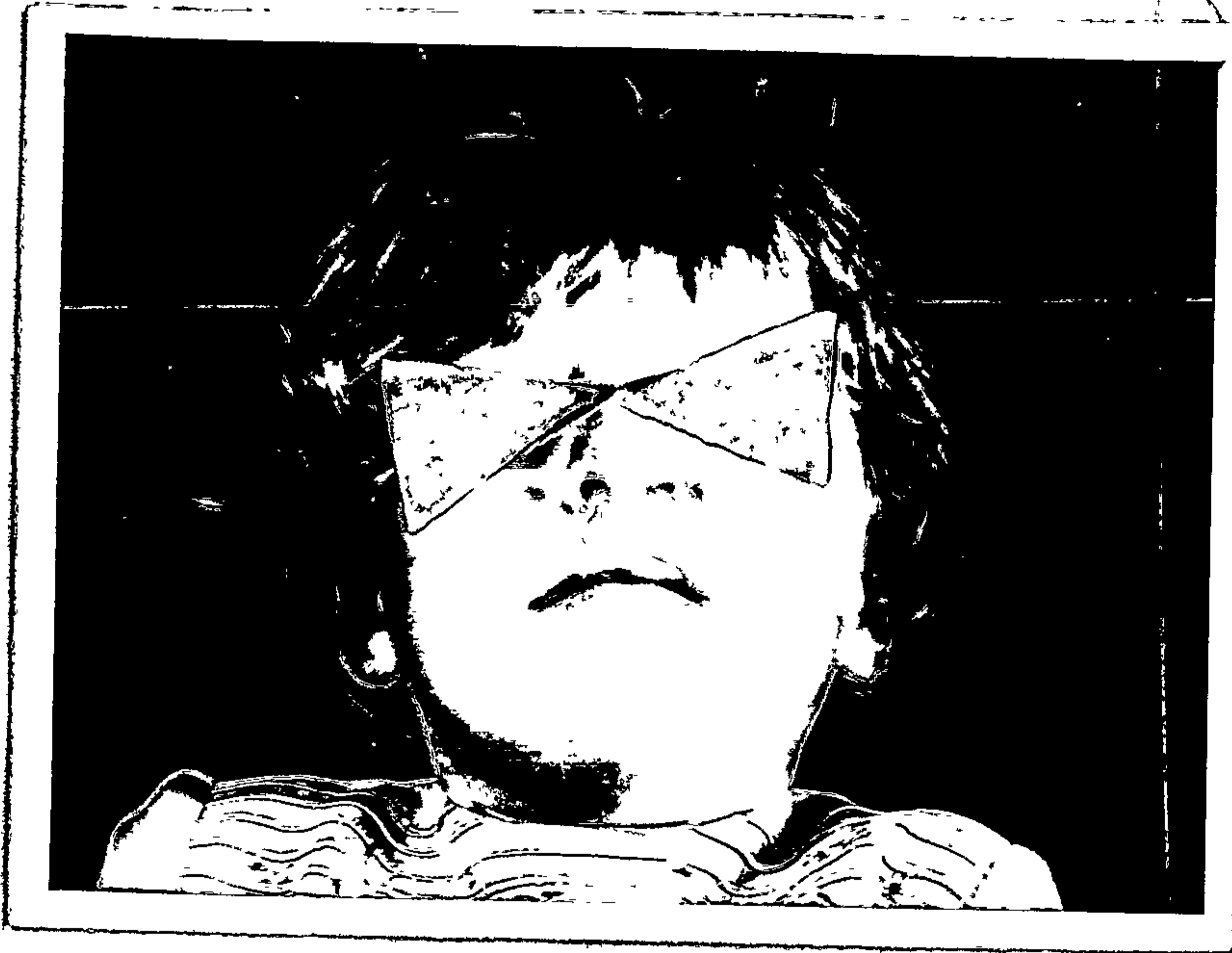LATERAL VIEW

II

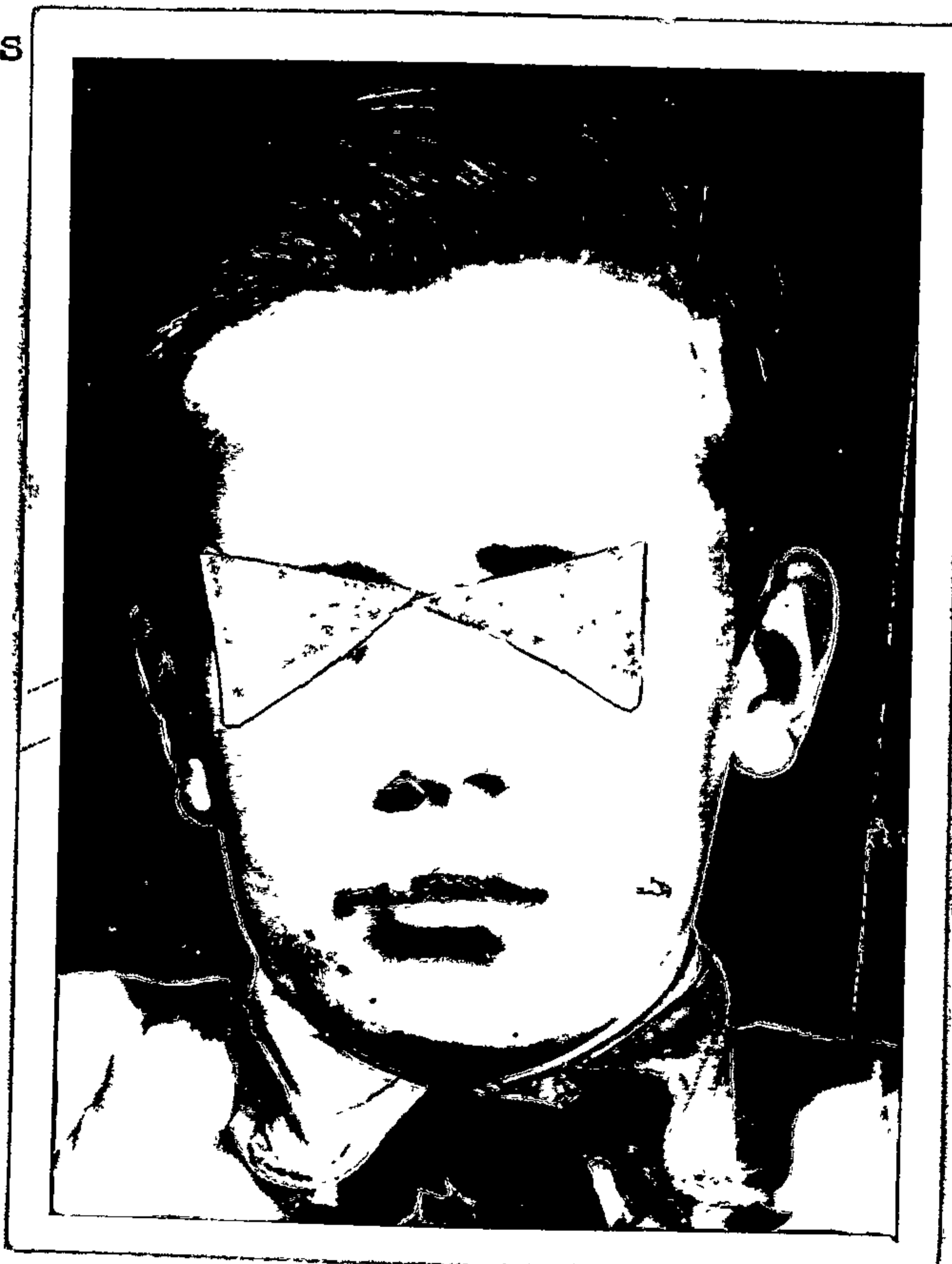(III)

FLACCID MAXILLARY LIPS.

TYPE B.



Scar Lines  
ARE STILL  
VISIBLE.





scarring at times, in the mandibular lip that has been known to require a "Z" plasty to reduce this result.

Treatment of a Protruding premaxilla in Bilateral Cleft Lips and Palate Cases.

The various methods of sectioning the vomer have been described and positioning of this premaxillary element is not a new feature. The techniques that have been employed in the past of pinning or wiring to the premaxilla and maxilla, are sometimes hazardous due to the developing tooth buds and the size and blood supply of this premaxillary element.

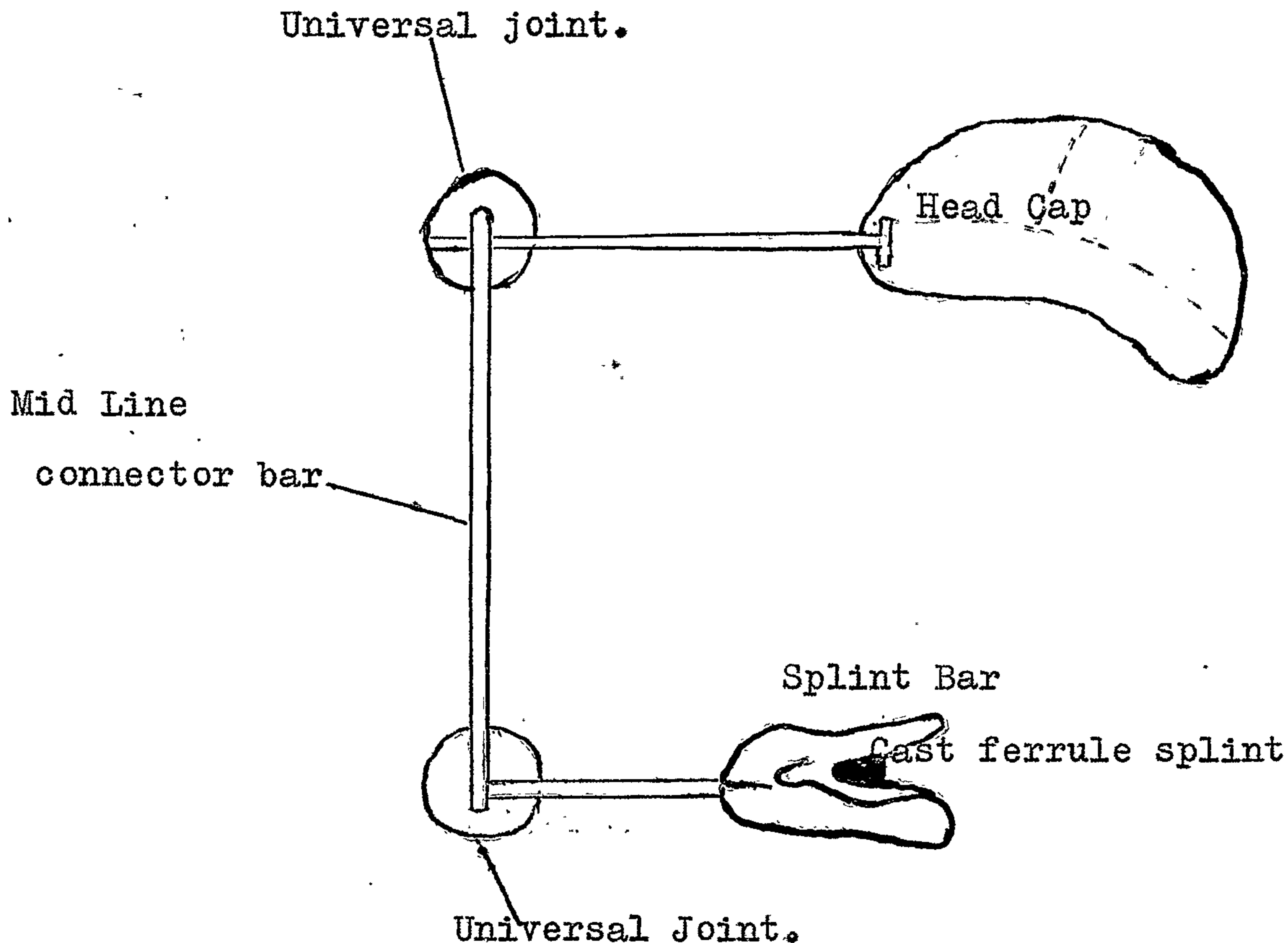
Cast ferrule splints have been applied following surgical retraction for stabilization but may fail through lack of retention, due to the bulbous formation of the deciduous teeth and the frequent loss of teeth. The cast ferrule splint is prepared by a model sectioning technique. The use of a plaster head cap, Professor Arnott style, with 3 central rods (one the connector) and two universal joints provides adequate fixation, stabilization and variation in positioning.

In children, this may not be completely stable should incorrect construction of the plaster head cap occur and hot weather may make the appliance uncomfortable.

Other appliances, complicated and costly have been designed<sup>4</sup> in aluminium, but in children may prove dangerous and an added factor of pinning may introduce avenues of infection more so than in adult cases.

Figure (34)

Head Cap Bar.



The advantage lies in the centre rod being placed in the middle of the mouth facilitating feeding. The mandible is not interfered with in function.

Attempts at an early age have been made at expansion of the maxilla at the same time as retraction of the premaxilla, but without success. Expansion has to be conducted later by orthodontic appliance for at this stage the dentition does not provide adequate retention for the appliance, to withstand the force of expansion.

Recent advances in Surgery.

The flatness of the lip has often worried surgeons. To improve this flatness Pickerell and Masters introduced the idea of Grafts of the tendon Flexor Digitorum sublimis, and the fascia,



the Tensor Fascia Lata of the thigh. The latter is in great supply and has the ability to glide when implanted.

The tendon graphs of the Palmaris Longus and the Flexor Digitorum Sublimus may be used without causing disfunction or disability, as may the Tendon of the Peroneus Brevis. This tissue is placed into the submucosa or subcutaneous tissue and should extend 1 cm. beyond the incision. The ends of the graft are anchored loosely to the Orbicular Oris and Buccinator muscles.

78b

Masters has substantiated the use of the interlocking "Z" incision both in the initial repair and for revision of secondary deformities. This incision is now used universally and produces most favourable results.

### The Cleft Palate.

#### Introduction.

Cleft palate in its multiple forms produces abnormal communication between the oral and nasal cavities and destruction of naso-pharyngeal sphincter. The result is abnormal nasal escape of air during speech, disadvantages in feeding respiratory disturbance and abnormal swallowing patterns.

The ultimate aim of cleft palate surgery to-day is to restore the oral cavity to normal and improve speech. Speech has become the guide of surgical success and to-day techniques swing more towards a pharyngoplasty associated with cleft palate closure than ever before.

During speech the passage of air from the larynx and the approximation of -

(a) The tongue to the palate and teeth.

- (b) Approximation of the posterior pharyngeal wall and the soft palate above Passavant's cushion. 38.
- (c) Movement of the soft palate tongue, cheek and lips in balance, result in the characteristic sounds of speech. Some sounds are explosive, others guttural or throaty and respective vowels and consonants are used as a means of checking function.

33

Cleft palate surgery has changed since the time of Brophy.

His technique of surgical closure of the palate at the same time as the lip is no longer used and his method of compression of the bony elements constricting both the palate and the nasal floor, has resulted in marked malocclusion and growth disturbances.

To-day techniques are bent upon producing normal width in the palate with a perfectly functioning soft palate or a substitute.

4.18

Classifications of the palatal defect have been many, but Veau's method of simple style has withstood the test of time.

Type I Cleft of the soft palate.

Type II Cleft of the soft and hard palate, extending to the incisive foramen.

Type III Complete unilateral cleft of the hard and soft palate and alveolar arch.

Type IV Complete bilateral cleft of the alveolus, soft and hard palates.

Figure 35.

Type I.

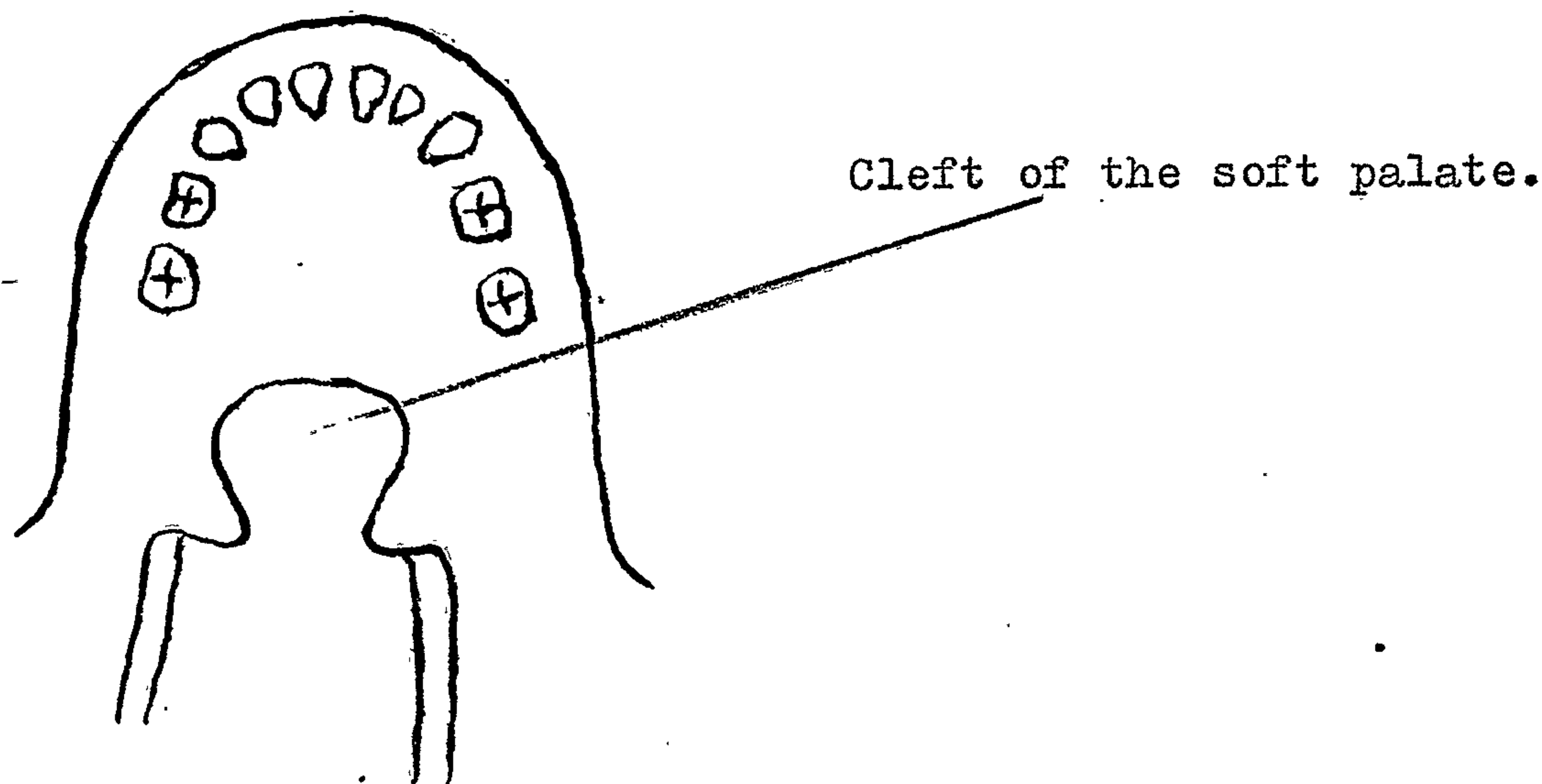
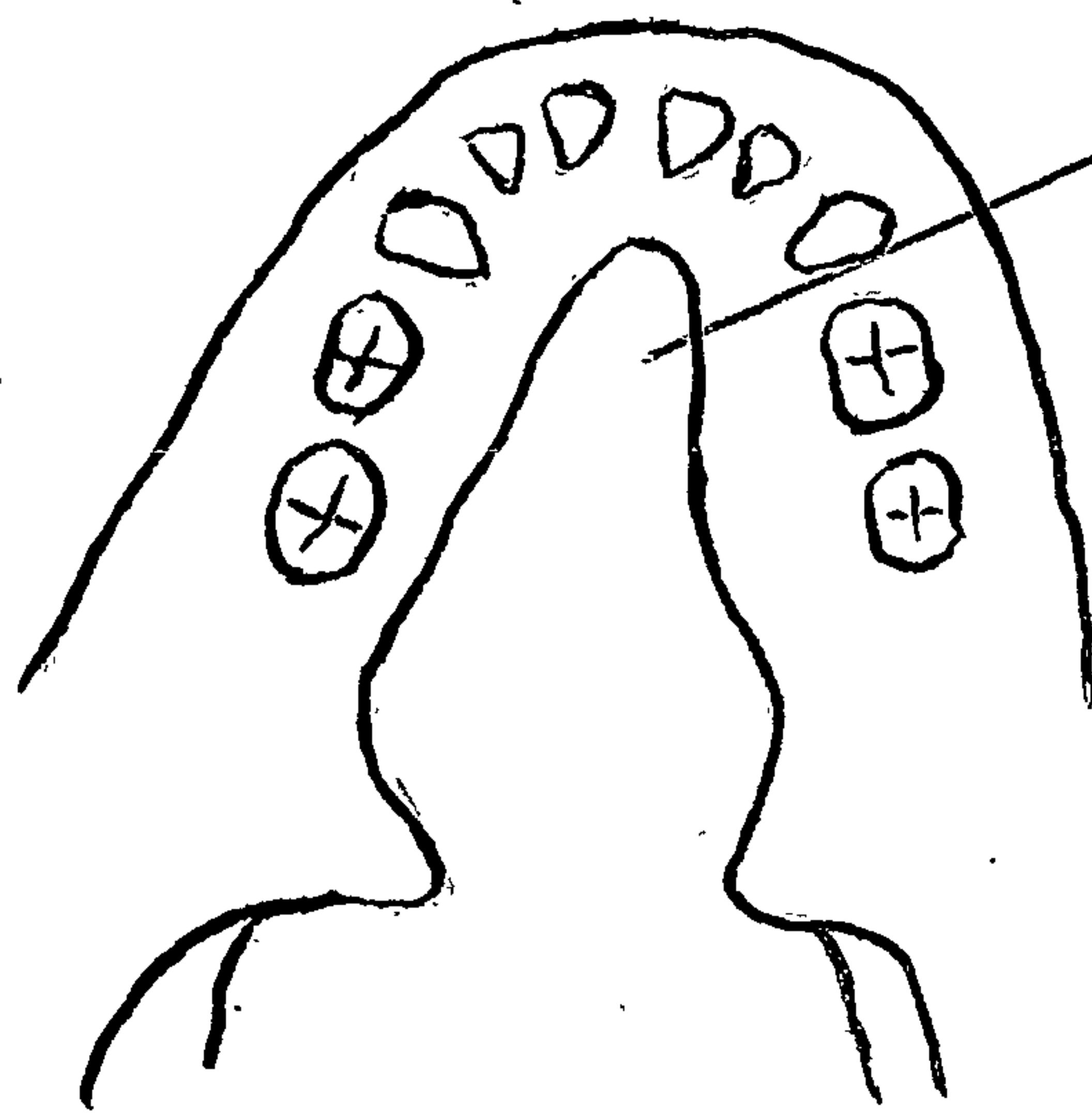


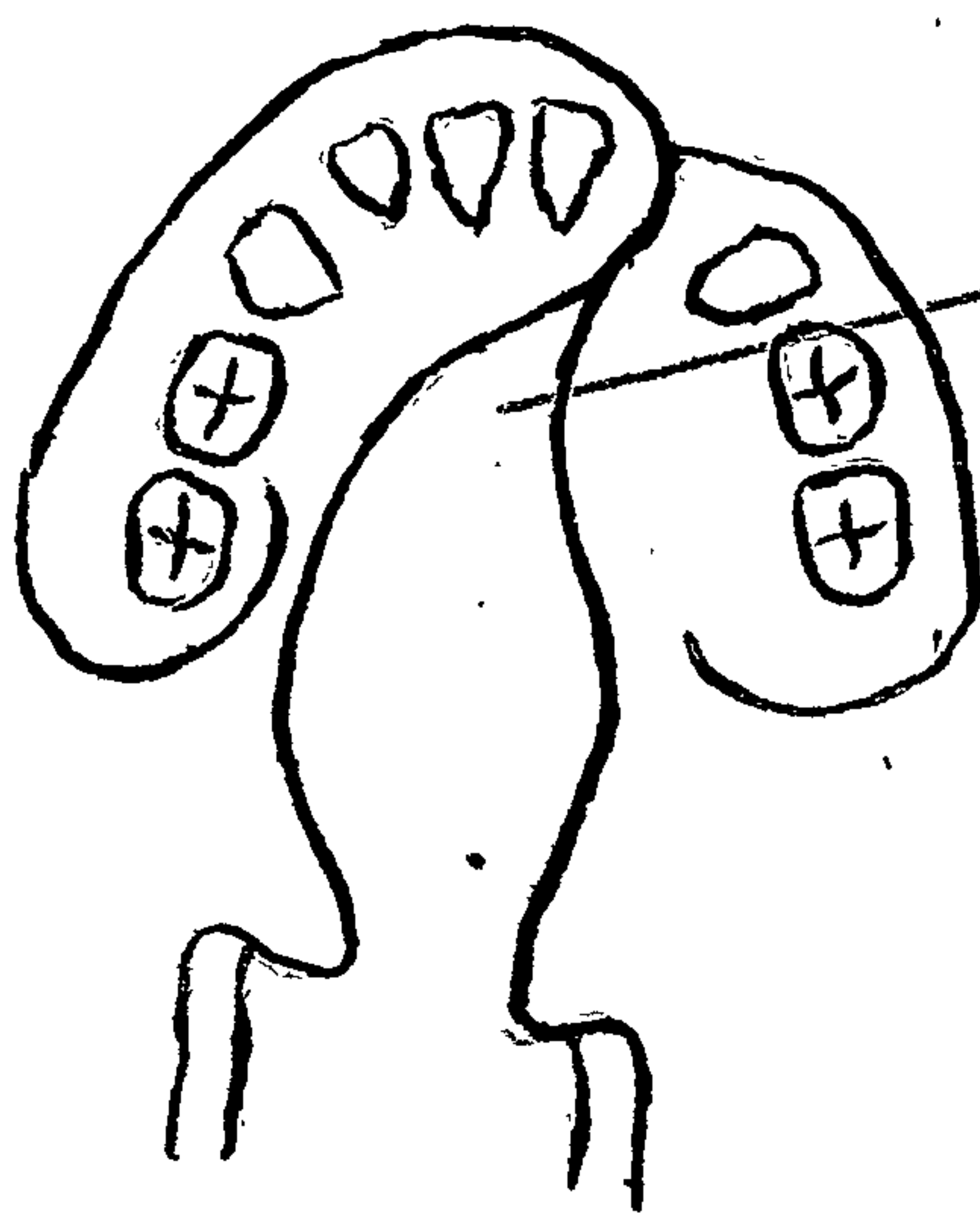


Fig 35  
Type II



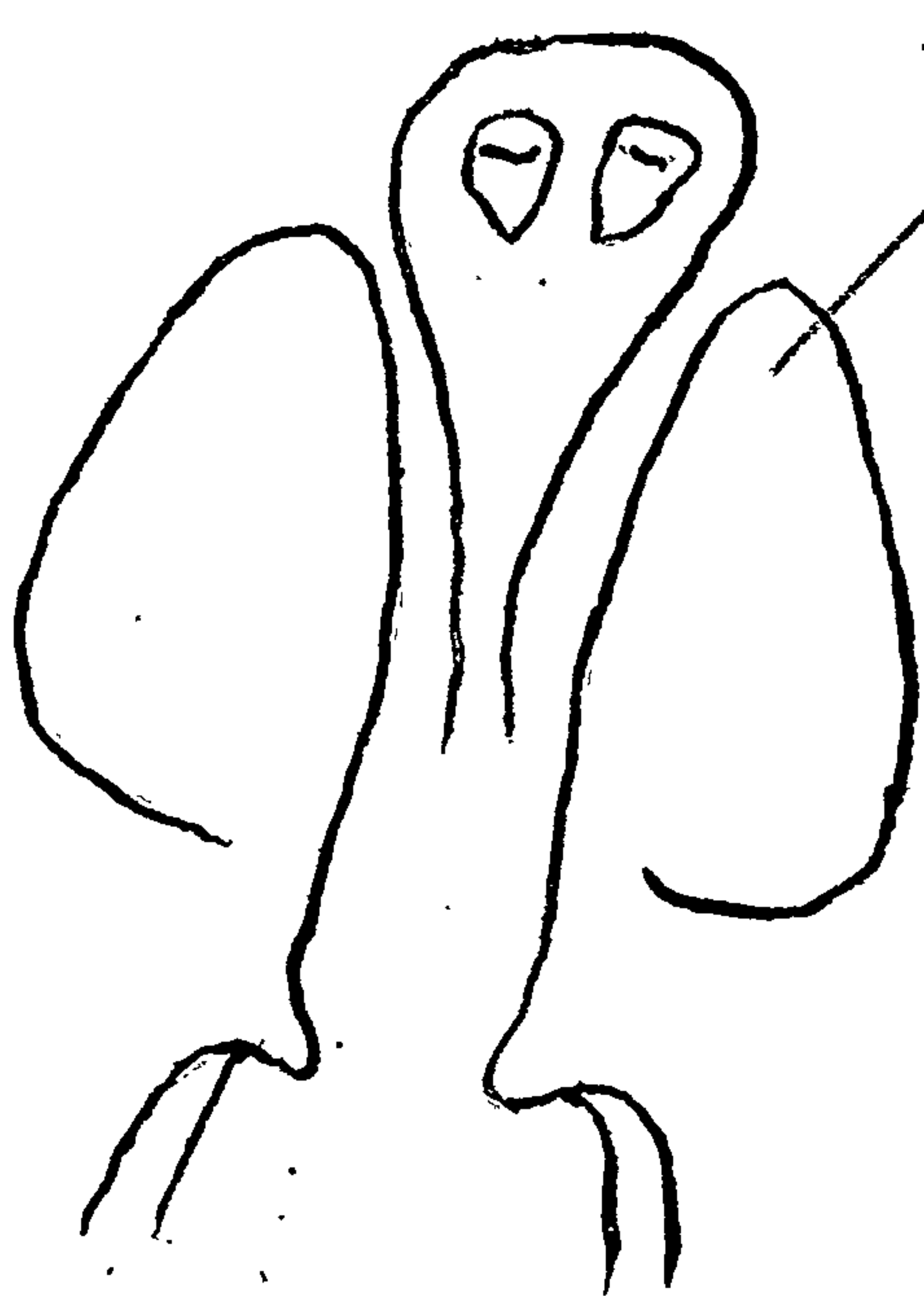Cleft of the soft and hard palate.

Type III



Unilateral cleft of the Alveolus and hard and soft palates associated usually with cleft of the lip.

Type IV



Gum pads no teeth.

Bilateral cleft of the alveolus and hard and soft palates associated usually with bilateral cleft of the lip.

The extent of soft and hard tissue loss depends upon the extent of the cleft. The tensor palati muscle in contraction elevates the velum to the level of the hamular process making the palate tense. The relation of the tensor palati tendon to the hamular process is an important surgical landmark. Passavant's<sup>38</sup> cushion is an important area in cleft palate surgery and speech. Earlier surgical techniques raised this area to provide approximation of the short soft palate to the pharyngeal wall, preventing nasal escape of air. The results were inconsistent, and a recent<sup>38</sup> paper by Calnan has indicated the fallacies of these surgical manoeuvres.

The time for cleft palate closure has become an important feature. Orthodontia desires that the cleft be closed as late as the 4th year, employing during the preceding period a palatal cover and obturator as a speech and feeding aid.

However, most surgeons feel that the speech and vegetative functions require closure rather at the 2nd year period and that Orthodontia can capably control and restore the later collapse.

<sup>18</sup>  
Barsky and many English surgeons close the palate at 18 months. It must be remembered that by 2 years the greatest progressive growth of the pharynx has occurred and in bilateral cases the medial pterygoid plates have widened by this time. Another indication for earlier closure is that neuro-muscular patterns, have more time to adapt and compensate during the formative periods.

<sup>33</sup>  
Veau found that a high mortality occurred in cases treated during the first year of life, but techniques have changed and



this rate has fallen. It is realised however, that the mortality rate decreases when the surgery is conducted in higher age groups.

### THE RESULTS OF CLOSURE FOLLOWING SURGERY

(Veau type classification of Clefts)

1. Type I. Veau palate usually produces a flaccid movable normal length palate with little disturbance in speech.
2. Type II & III. Veau palates may produce a slightly shortened palate varying with the size of the cleft and loss or displacement of tissue. In many cases the Type II results are very similar to that of the unilateral cleft lip alveolus combined with the soft and hard palate cleft and may result in a short incompetent palate. Scar tissue may slightly reduce the mobility and excess nasal escape of air may occur. There is usually a unilateral collapse of the maxilla, on the affected side.
- Type IV. Veau palate produces the maximum trouble. The maxillary elements are usually collapsed and sometimes the hard palate is scarred and incompletely closed. The degree of cicatricial tissue varies depending upon the tissue loss.

The soft palate is usually complete but short, fibrous and scarred with lack of mobility and complete function. These cases have produced poor speech and nasal tone with excess nasal escape.

The speech is frequently improved if the surgical closure of the palate is combined with a pharyngoplasty. <sup>75.77</sup>

### Surgical Techniques.

The hard and soft palates may be attached by several techniques depending upon the tissue loss and the desired result.

Some of the techniques utilised to-day are:-

1. Von Langenbech (Dieffenbah, Warren).  
4.65  
18.44.46.47
2. Dorrance Bush-back technique. (Pioneered by Hall and Ersk).  
50  
18
3. Warren B. Davis modification of the Ferguson  
18.95
4. Brown  
18
5. Gillies & Fry  
18.106.108
6. Wardrill
7. Veau 4.18.95

The aim of these techniques is to close the anatomical deformity and restore the deficient distorted velopharyngeal closure. This requires increase in tissue laterally (in some cases (Type II Veau)), in the hard palate and laterally and distally in some cases in the soft palate. Type I, III, and IV, Veau palates are usually "V" shaped and often approximation of misplaced tissue will restore the defect.

83.84  
Oldfield claimed that type II Veau palates which occur mostly in females are "U" shaped and have been treated in the past for deficiency of tissue. This surgical procedure is under revision at the moment by Oldfield as are Type I, III and IV Veau palates which occur more commonly in males.

#### The Surgical Technique.

33  
In 1923, Brophy introduced his compression technique, but the earlier Passavant flap method has held sway and is fundamental in modern surgery techniques.  
34.77

Earlier methods of Von Graefe in 1817 and Roux in 1819 failed  
18.38  
due to tension in the repair. Dieffenbach in 1828 separated the mucoperiosteum from the horizontal processes of the palatine bones to relieve tension. Mettauer in 1837 introduced many small incisions in the palate to relieve the tension and in 1862,



33.95

Von Langenbeck introduced his now famous technique.

The palate produced by the Langenbeck operation tended to be short and incapable of normal function. Scar tissue on the nasal aspect frequently produced contraction. Blair utilized flaps from the neck to reduce tension and Rosenthal in 1917 employed similar flaps from the upper arm.

77.78

The "Lane Operation" based upon the flap technique became popular, the larger flap being sutured after being well incised and freed, into the flap of the opposite side, however, fibromuscular scar tissue frequently resulted. This technique is more justified if the cleft is small and tissue plentiful.

The Von Langenbeck operation produces a short mobile soft palate that does not accomplish velopharyngeal closure. Many modifications of these basic techniques have since been introduced.

18.46.44.47

The Dorrance Push back operation was universally acclaimed to lengthening the short soft palate and this technique was incorporated in the early pharyngoplasty operations in the year 1863.

77

Ferguson noticed the improvement in tone following the Langenbeck method and improvement in speech gradually became the measure of surgical success. It is interesting to note that the Hyne's form of pharyngoplasty which decidedly fixes the soft palate and posterior pharyngeal wall reducing air escape via the naso pharynx, improves the tone of the voice quite markedly. Surgery seldom results in a normally functioning soft palate in bilateral cleft cases, a degree of incompetence of the musculature usually remaining.

33

In 1889 Billroth advocated division of the hamular process



during repair of the palate to less the tension of the tensor palati and possibly aid lengthening the soft palate. However, nasality in speech continued.<sup>77</sup> In association with these lengthening techniques of the soft palate - followers of Passavant increased and extended the size of Passavants ridge in the superior constrictor, then for many years the pharyngoplasty technique was laid aside.

34.69

Barry in 1905, by carrying out research and noting detailed accounts of the improvements following such techniques as Langenbeck, Dorrance and Passavant and armed with new knowledge in the physiology of the area concerned, soon realised that speech learning and indirectly, soft palate function, was largely dependant upon hearing.<sup>4</sup> Gillies and Fry introduced closure of the soft palate with modification, for they realised the importance of width in the hard palate, normal occlusion and the necessity for free movement of the tongue in speech. Gradually the requirements of normal speech were assessed, and sought after.<sup>77</sup> Grey Turner, in examining the Langenbeck Ferguson operation stated - "It is not sufficient, purely to have a complete roof and a moveable velum but the whole of the palate must be of normal length, mobile, sensitive and most suffice in function either by itself or together with the pharyngeal muscle".

Veau found that the best results came from operations before 5 years of age but the correct age for palatal surgery is still as yet undecided, not forgetting that each case is an individual and must be judged upon its merits.

77

Wardrill noticed and commented upon the inconsistency in speech results which were being obtained using standard methods



of operation. "Perfect anatomical results show gross defects in speech, whilst others with apparently poor anatomical results show great speech improvement." Wardrill's <sup>4.18</sup> four flap method combined the advantages of the Veau, Gillies, Fry and Dorrance operations and the importance of lack of tension.

The results, however, although an improvement were far from those desired.

#### The Von Langenbeck Technique.

Muco-periosteal flaps are freed from the hard palate through lateral incisions to the bone. The incision is distally in a line with the posterior teeth. Whilst raising the muco-periosteal flaps care is taken to preserve the palatine arteries. Freeing of the soft palate is accomplished in both the oral and nasal floor of the palatine bone allowing mobilisation of the flaps. The hamular process may be sectioned freeing the tensor palati muscle.

<sup>4</sup>  
Blair and Fry claim that the tendon of the tensor palati muscle may be sectioned. This technique allows approximation of the tissue in clefts of the soft palate and unilateral cleft of the hard and soft palates.

<sup>418</sup>  
Veau claimed that this technique resulted in healing by secondary intention with scar tissue on the nasal side which caused contraction with loss of mobility and length of the palate.

More tissue was found available in a high arch than in a low arch vault palate.

<sup>18</sup>  
Barsky's modification contained the following steps -

1. Placing relaxing incisions parallel to the posterior teeth on the side of the cleft.

2. Elevating the muco-periostum from the maxillary bone.
3. Dividing the palatal aponeurosis and nasal mucosa.
4. Fracturing the hamular process.
5. Freshening the margins of the cleft.
6. Suturing.

By freeing the palatine aponeurosis the soft palate is dropped from its normal level to a lower horizontal level. A complication in this stage is the accidental severing of the posterior palatine artery.

100

Subtleny has shown that the pharynx of the cleft palate subject is frequently wider than normal. Fracturing of the hamulus thus freeing the tensor palati muscle results in a narrowing of the naso pharynx, an important step, and allows the soft palate to drop in horizontal height and mobilisation to occur in a narrower part of the pharynx. Suturing is carried out carefully, layer by layer.

4.18

Veau's operation is basically the same but caters for -

1. Layer of nasal mucosa for the hard palatal flaps.
2. Three layers to the soft palate -
  - (a) Nasal mucosa.
  - (b) Muscle
  - (c) Oral mucosa.

This technique avoids the raw nasal surface in the reconstructed palate and avoidance of relaxing incisions in the posterior palate.

A Veau Operation utilizes.

- I. Minimal shrinkage  
18.128
- II. Vomerine flaps where possible.
- III. Veau muscle sutures, which provide fewer breakdowns of the palate using a Reverdin needle.  
18



IV. Uses long muco periostial flaps of the palate; a long flap that may tend to slough, due to failure in nutrition. Wardrill's technique may at times produce better results here.

and  
Ivy, Curtis use the Mirault-Blair operation on the lip followed by a Veau operation of the hard palate.

18  
Veau's Principles have been adapted to form the V to Y Procedure. This was advocated by Wardrill and its features are -

1. Closure of the cleft
2. Displacement of the velum posteriorly.

Figure 36.

Veau's operation for long anterior flap.

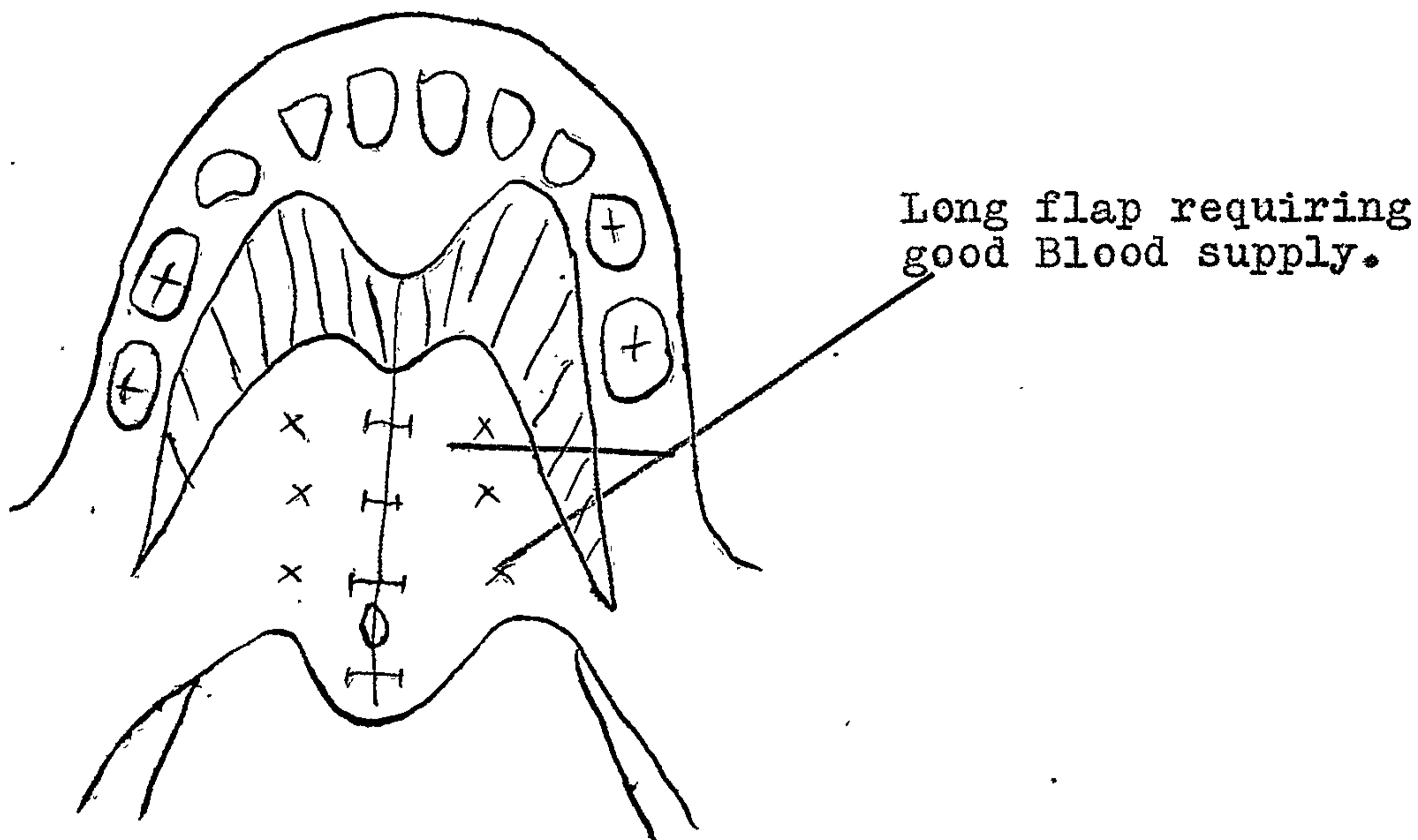
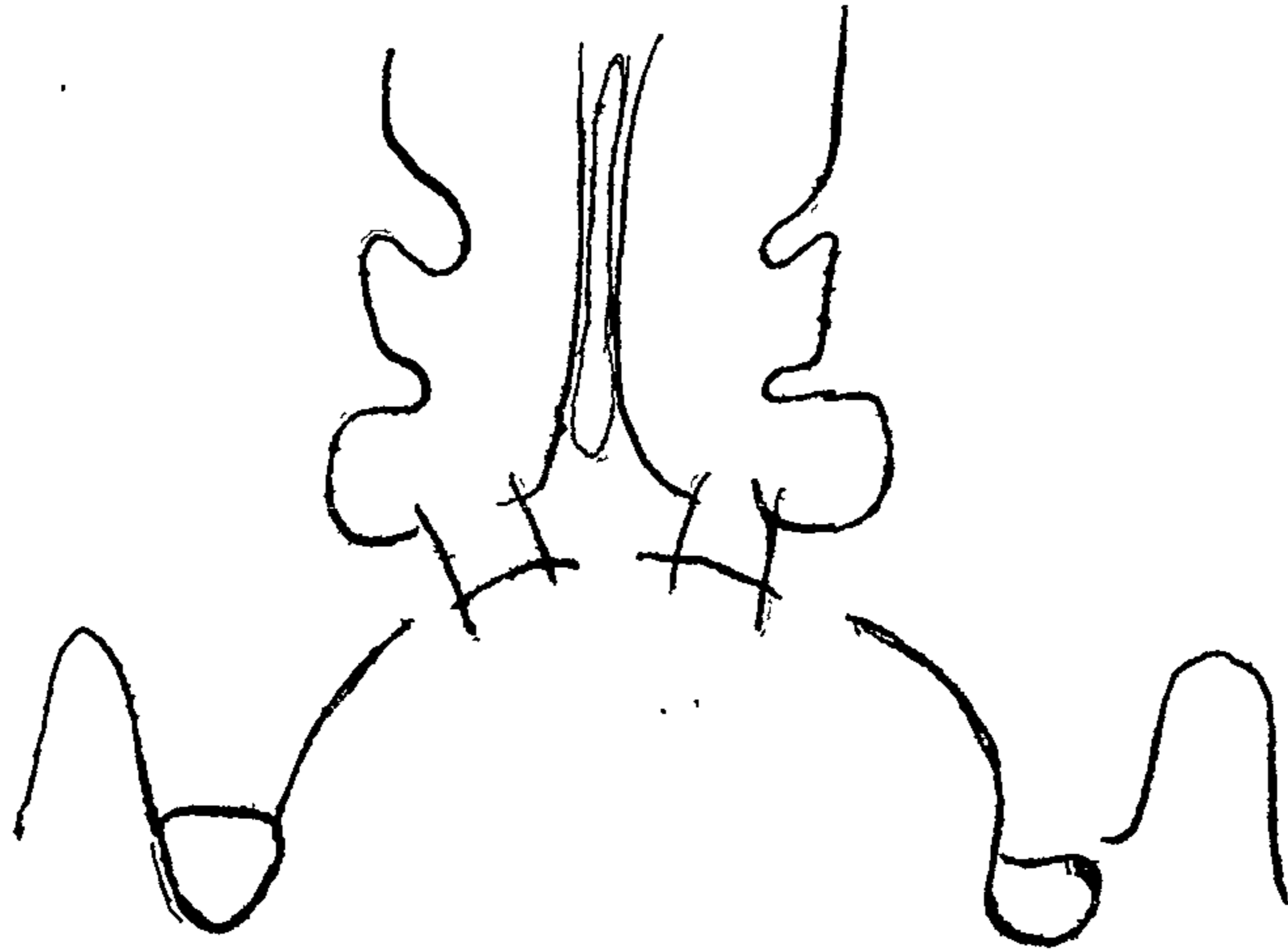


Figure 37.



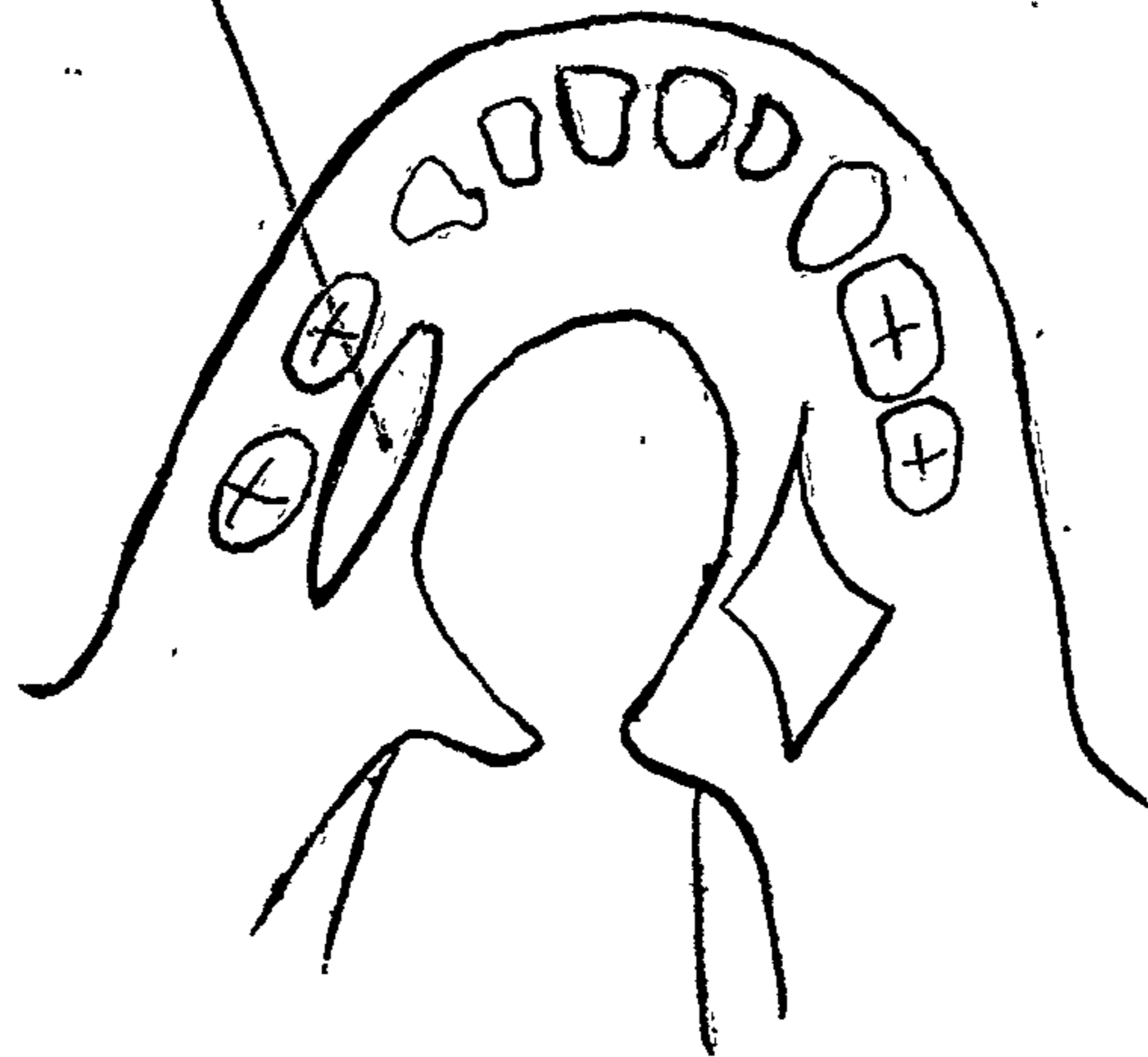
Veau's method of using vomerine flaps in the palate.

Figure 38.

Wardrill Closure Technique

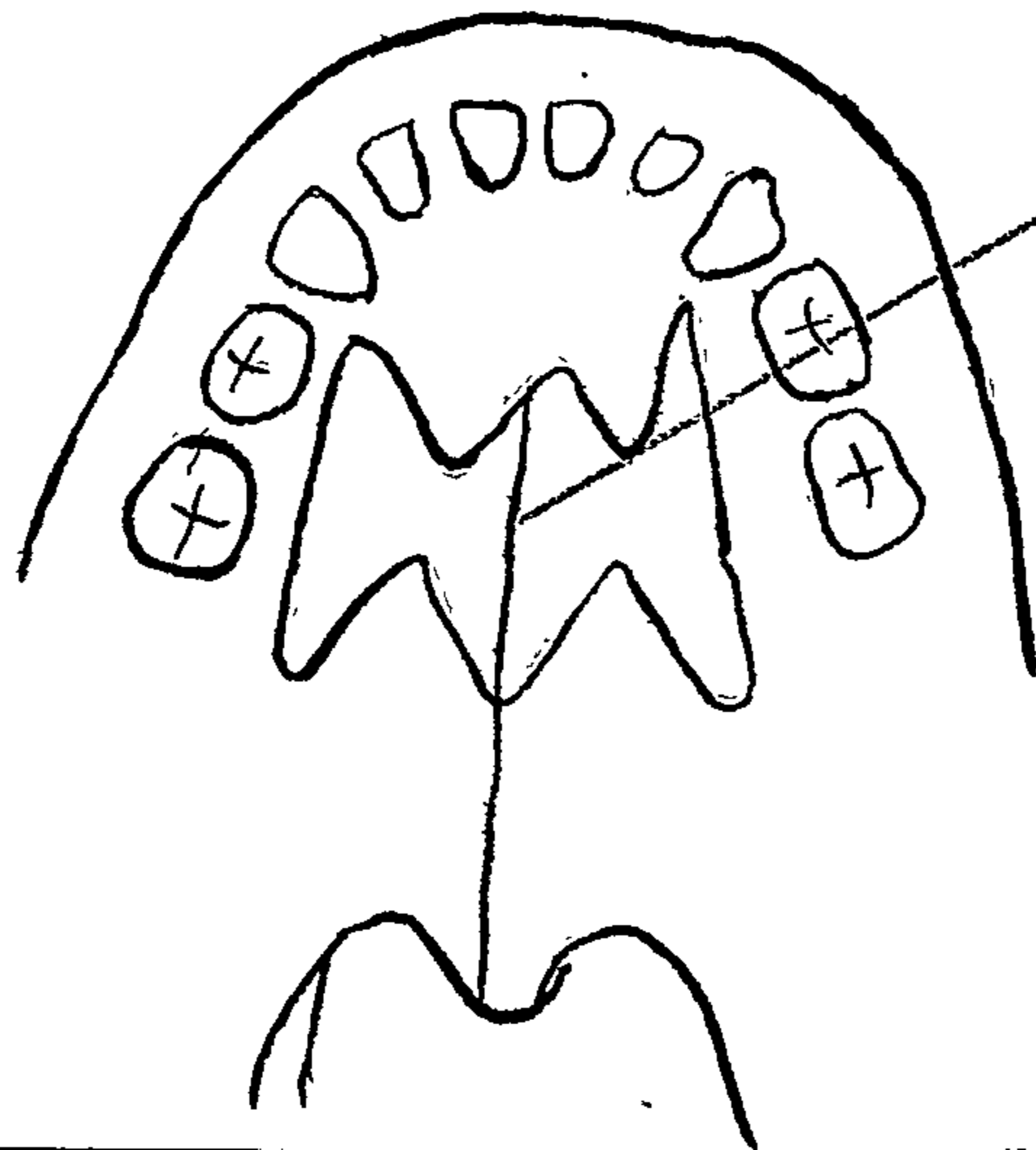(i)

Relaxing incision



(ii)

Nasal  
Mucosa closed





(iii)

Finish.

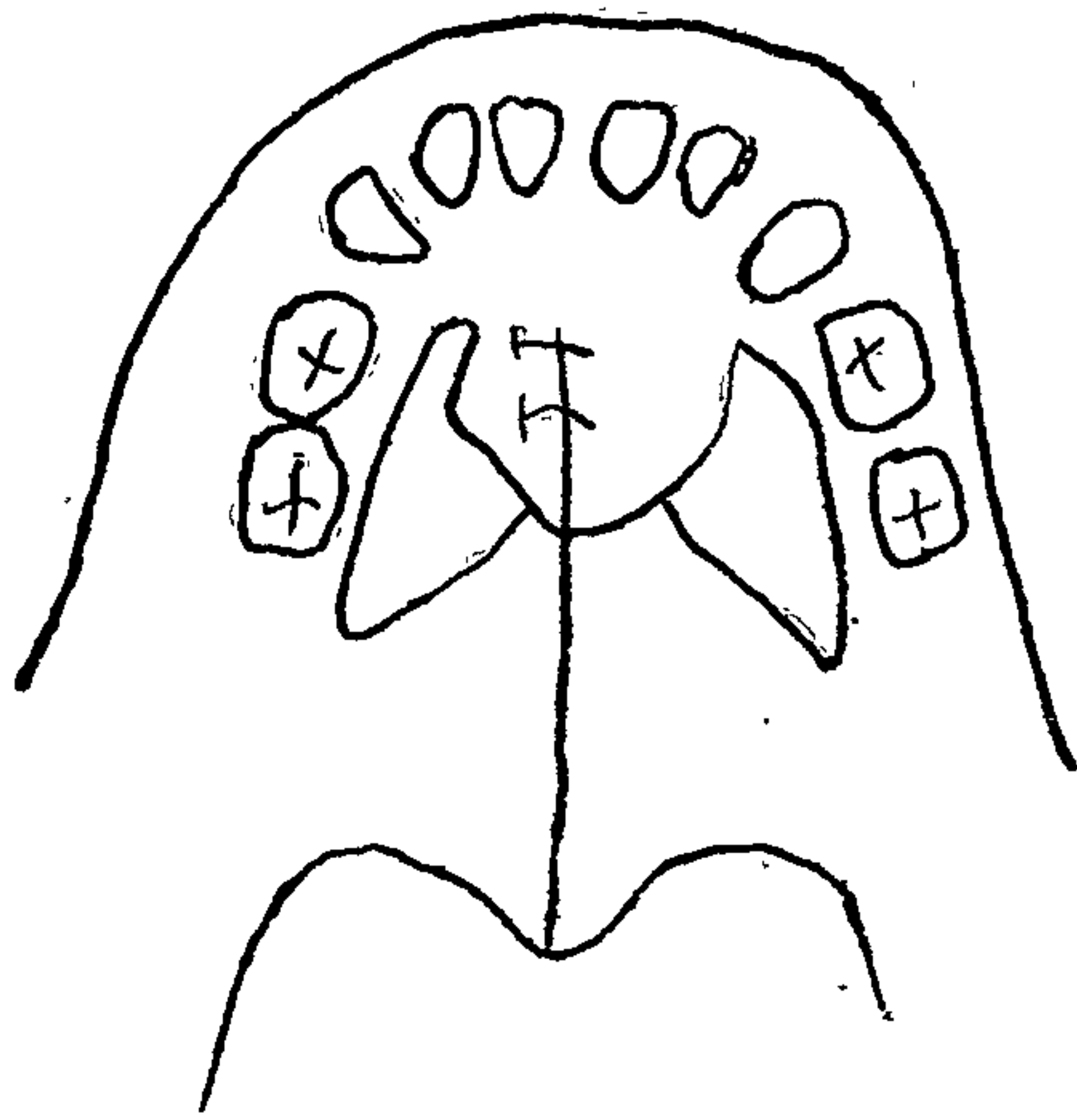
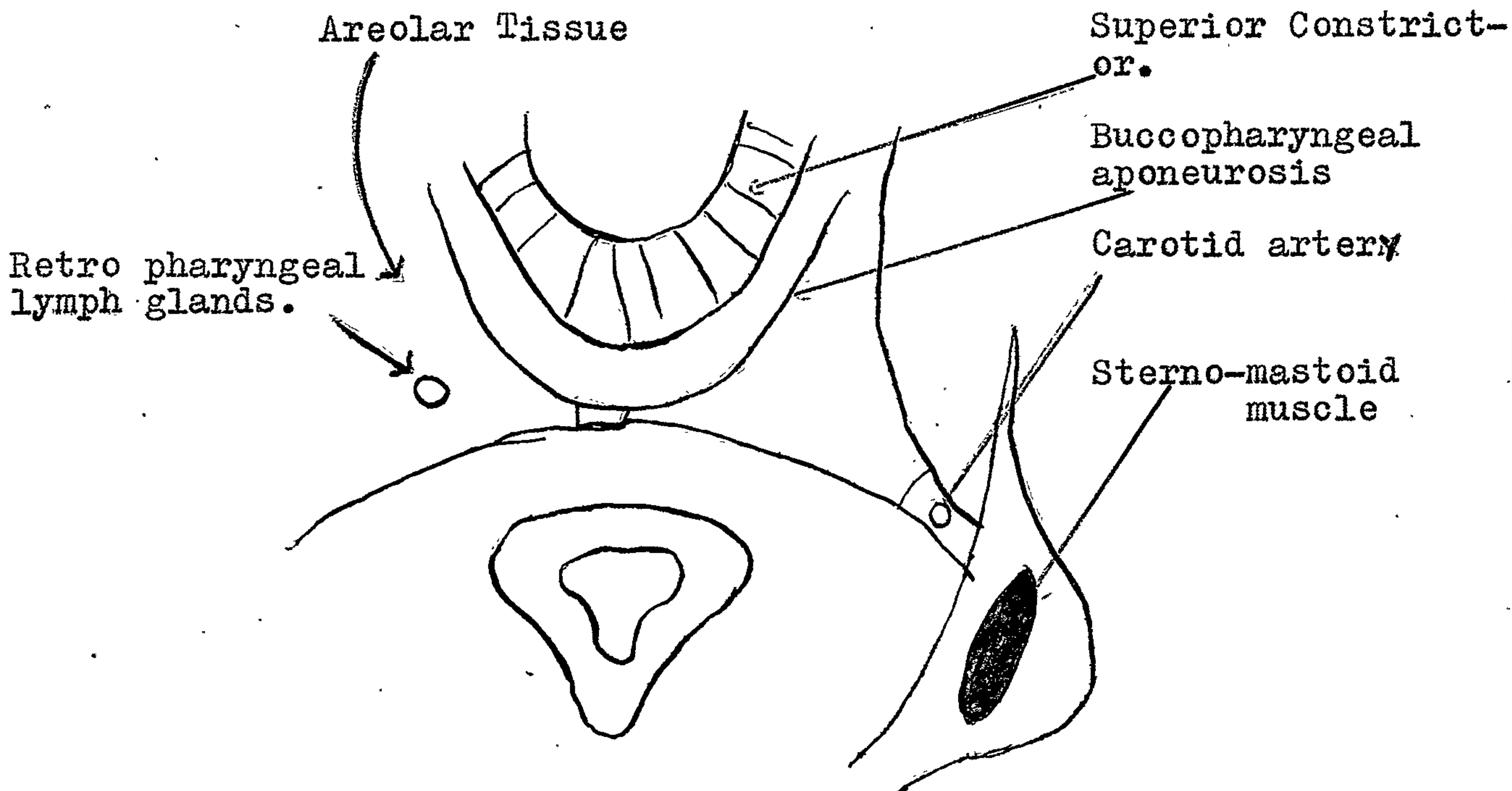


Figure 39.




The Wardrill technique utilises relaxation incisions and the "v" to "Y" technique incisions and may be associated with pharyngoplasty which is the approximation of the salpingo pharyngeus muscles conducted at the same time. The incision on the posterior pharyngeal wall is horizontal and is converted to vertical incision by the technique of suturing used. Fig. (40).

18.45.46.47

Dorrance in 1925 named incomplete velopharyngeal closure the "insufficiency of the palate" and introduced his Push Back operation.

This operation was completed in two stages. The first was the grafting of the muco-periostial flap before the actual push back operation. At times Dorrance in his palatal closure used the single or double vomerine flap, especially in bilateral cleft cases. This flap is tucked beneath the oral flap on the opposite side and is sutured into place, a procedure frequently hard to accomplish.

Figure (46)



PHARYNGO PLASTY (Velopharyngeal)

The first pharyngoplasty operations were conducted by Schonborn, Rosenthal and by Passavant in 1833.

This operation to-day involves the fixation of the soft palate to the posterior pharyngeal wall. Where the palate is insufficient it may require a push back operation with loosening of the nasal mucosa from the posterior border of the palatal process. Where tissue is missing a tube flap of the Gilles type may be contemplated.



33

In the Schonborn technique a posterior pharyngeal flap is cut with its base down and is united to the freshened oral surface of the palate. The raw area on the Pharyngeal wall is sutured but frequently opens.

Padgett reversed this flap with the base upwards and sutured to the nasal surface of the palate.

33

Posuinec and Schiechard introduced the technique of the pharyngeal flap base downwards and mobilised the posterior pillar of the fauces including part of the palato glossus muscle and the mucosa.

These two flaps form a horizontal curtain on the pharyngeal wall behind the soft palate. They are sutured together in the midline.

33

Passavant in 1862 fused the posterior pharyngeal wall to the soft palate. Dissatisfied with results, he turned to the procedure of forward displacement of the cushion. A flap was raised and folded and sutured into place giving a shelf like projection. This was not successful in improving speech. The incision passed through the superficial fibres of the superior constrictor to the level of the bucco-pharyngeal fascia and only this far. The incision should not involve the areolar tissue nor the prevertebral fascia. ( Fig. (39).

4

Wardrill in his cleft palate surgery conducted a pharyngoplasty and approximated the salpingo-pharyngei.

75

The salpingopharyngeus muscle on each side of the pharynx is dissected from its lower end and swung up towards the midline to unite in a ridge across the posterior pharyngeal wall as a tent

higher than Passavant's ridge. The nerve supply, accessory through the pharyngeal plexus is maintained through the superior attachment. The results to date are highly satisfactory. Adult cases treated show a decided improvement in the tone of the speech.

The complications of this procedure are -

1. Anaesthesia - the tube has to be passed through the oral cavity resulting in less space for operating.
2. Post operative bleeding.
3. Difficulty in breathing post operatively.
4. Ear symptom.
5. It may be necessary in this procedure to do a Push Back operation first to free the soft palate.
6. The size of the oro-nasal pharyngeal communication is the important factor in these surgical results.

#### Nasal Escape.

To date no, 100% efficient mechanism has been devised to measure nasal escape and its relationship to faulty nasal speech. It is known that where nasal escape exists, its reduction by pharyngoplasty results in improvement in speech tone.

37

The Phino-aerometer, a manometer to measure the nasal escape has been introduced quite recently, but it is felt that this apparatus does not reflect the true value. With this apparatus nasal airflow is recorded during the recital of a certain speech. The instrument indicated that a greater nasal escape occurred using an obturator than with surgical velo-pharyngeal closure. It is known that although a patient may provide certain values for nasal escape when reciting certain vowels and consonants, in every day speech where concentration falls the results differ and the escape is more marked.



Other methods used are the "U" tube water pressure device and audiometer. (Royal Alexandria Hospital for Children).

Variations in the Teeth.

105

Routine examination, both clinically and Roentgenographically, of cases has resulted in increased knowledge of the associated phenomena of cleft palate, and for cleft lip, and abnormal or defective tooth formation and eruption. The influence appears to be either hereditary or non hereditary.

1. Where it is hereditary, it is frequently associated with the genetical aetiology of the cleft alveolus and palate.
2. Cases of non-hereditary aetiology contain teeth either abnormally formed or abnormally placed and unerupted, or erupted in malocclusion due to ante-natal or post natal causes.

87

An example of the act of birth is the neo-natal ring. It represents a disturbance in the formation of dental tissues whilst passing through the adjustment of intrauterine to extrauterine existence (disturbance of nutrition of the ameloblasts.)

The disturbances usually found in clinical cases are -

1. Unerupted teeth.
2. Impacted incisors.
3. Supernumery teeth.
4. Mesoderms.
5. Distorted anatomical forms which may be subdivided into -
  - (a) Hypoplasia of the enamel.
  - (b) Crown distortion due to pressure.
  - (c) Twisted and bulbous roots.
  - (d) odontomas.
6. Partial anodontia.

Nutritionally teeth and bone are affected by similar diseases although each is dependent upon its own gene genetically, for size and growth potential respectively. The importance of environment

is never underestimated in these cases and has a great influence upon the caries rate.

115

Anodontia has been studied extensively and has been found associated with ectodermal dyscrasias, both appearing to be transmitted by sex limited recessive gene.

Cleft palate and cleft lip have been found associated with syndactylism, achondroplasia and other mesodermal disturbances.

Anodontia appears in the grandsons and is carried by some of the unaffected daughters and transmitted to some of their male off-

springs. <sup>34A</sup> Smith in 1929 reported that ectodermal dysplasia though sex linked and recessive occasionally may produce the defect in the female carrier, the condition now becoming a semi-dominant sex link character.

The dental lamina-dental ectoderm is suppressed and in its most severe form total aplasia occurs. <sup>24</sup> Brodie and Sautone proved by cephalometric appraisal of a boy with complete anodontia through the serial roentgens of the skull over a period of years that the absence of the teeth does not, significantly impair the development of the face and jaws, an important point where partial anodontia occurs in cleft, lip and palate, for the basal bone will develop independent of tooth presence.

Clinical examination of cleft conditions produced the following indications:-

1. Small dimples or groove clefts of the alveolus. These were found to fill in as the jaws grew. But the erupting deciduous lateral incisor may be notched, grooved to "T" shaped and erupting into a malocclusion.
2. Large clefts which may result in the forms already listed.



Surgery frequently resulted in trauma to or shifting in position of a tooth or teeth buds. Brophy frequently in his surgical manipulation of the jaws for contraction of the maxillary arch injured the teeth and had little regard for their importance or position in the developing complex. The introduction of wires through the alveolar process could not help but distort, injure or destroy the developing tooth buds.

Operative injury to-day is more common in the region of the alveolar cleft and is often associated with malformation and development of the canine and the second incisor tooth. Saptone, whilst completing experimental work on cats produced trauma at different stages of tooth development, and the result depended upon the different stages of differentiation of the tooth germ. His observations showed that where all differentiation had not progressed far, the enamel organ regenerated in the injured area being replaced by undifferentiated, mesenchymal cells.

However, during later development of the tooth in the phase of dentine deposition, he showed that the injured part was repaired by the production of osteoid substance. In cases where the tooth tissue was completely differentiated, the loss of dentine and enamel was replaced by young connective tissue from the dental follicle and osteoid tissue restored and continuity of the tooth. He claimed that ameloblast did not take part in the repair of the tissue but merely atrophied and degenerated in the injured area and mesenchymal tissue again formed collagenous ground substance which further formed osteoid dentine.

Saptone observed also that early injury to the enamel organ

on account of fragmentation of the tissue, would form isolated groups of cells and produce supernumery or accessory teeth and often was associated with displacement of the partially formed or deformed tooth. This then explains the phenomenon of germination where two teeth can occur (or in between variations) from one enamel organ, or fusion of two teeth from two enamel organs to give one tooth.

Separately formed tooth buds united later at the time of root development form in "concesence".

These, usually produced by an abnormal development of the cemen<sup>t</sup>um, are not common but have been shown to occur associated with cleft expressions.

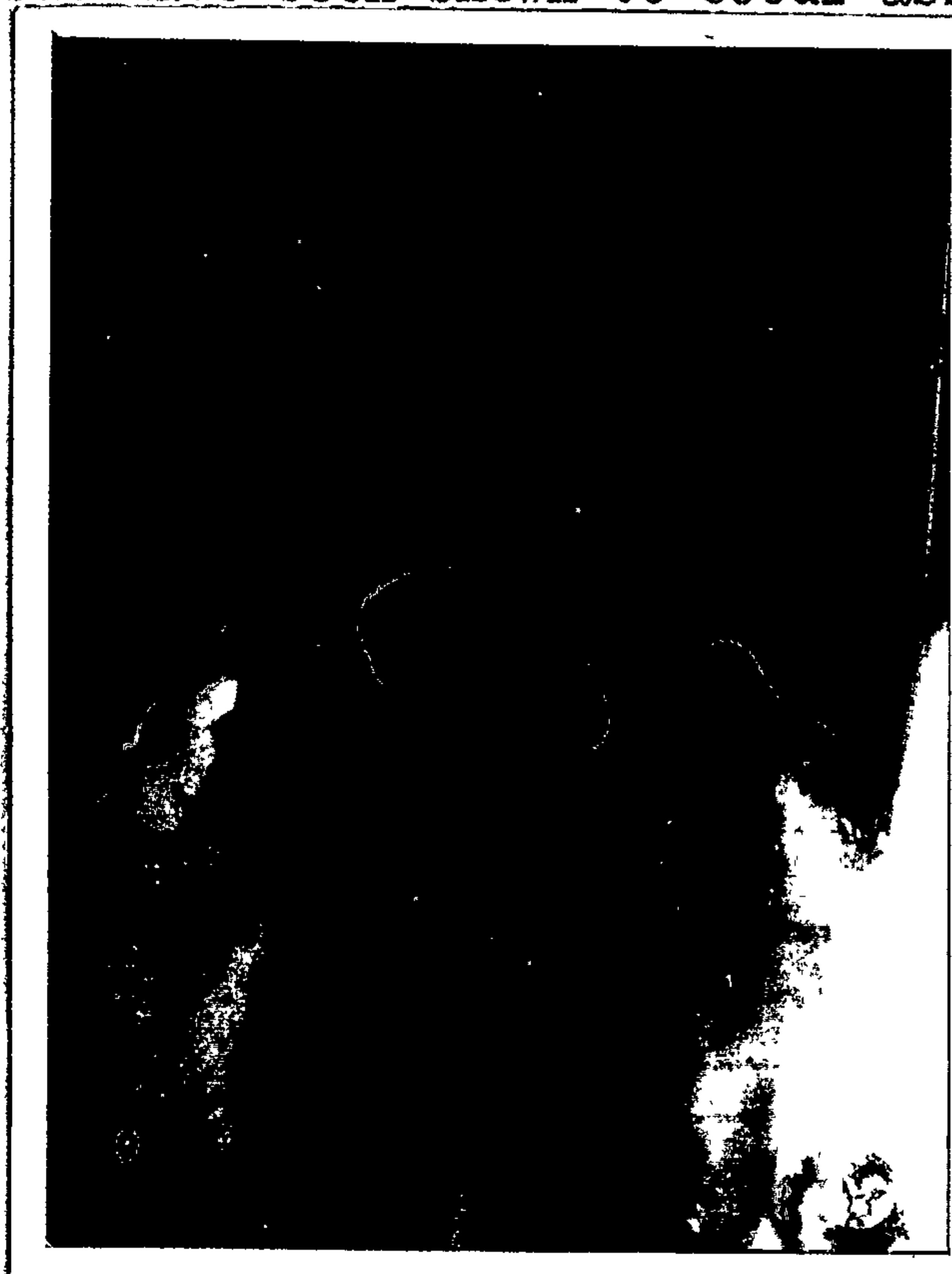


Figure (41 ).

An example of a bilateral cleft lip and palate with the vomerine premaxillary segment free and mobile. The maxillary central displays distortion in form, abnormal harmony in size, rotation and possible resulting malocclusion on complete eruption.

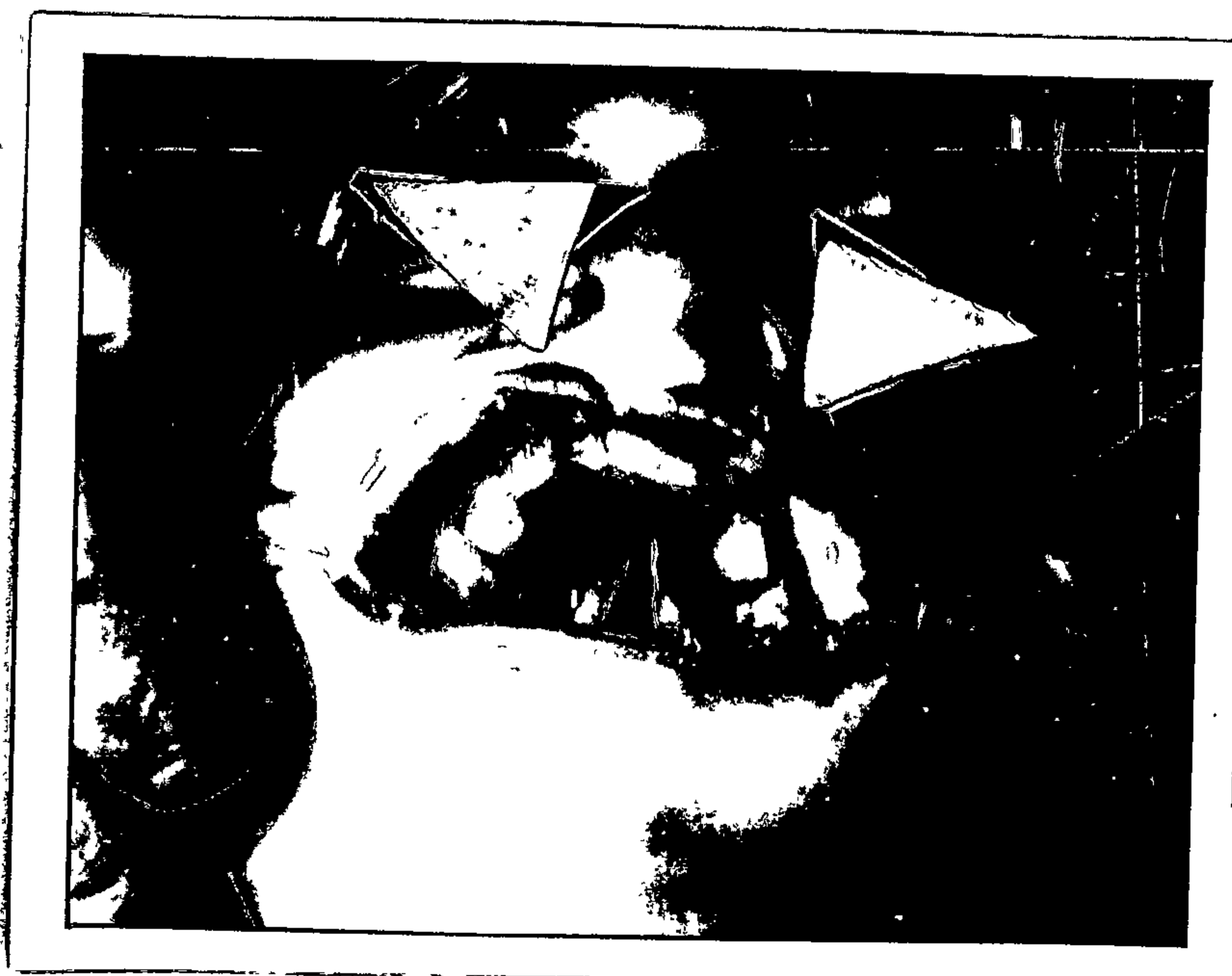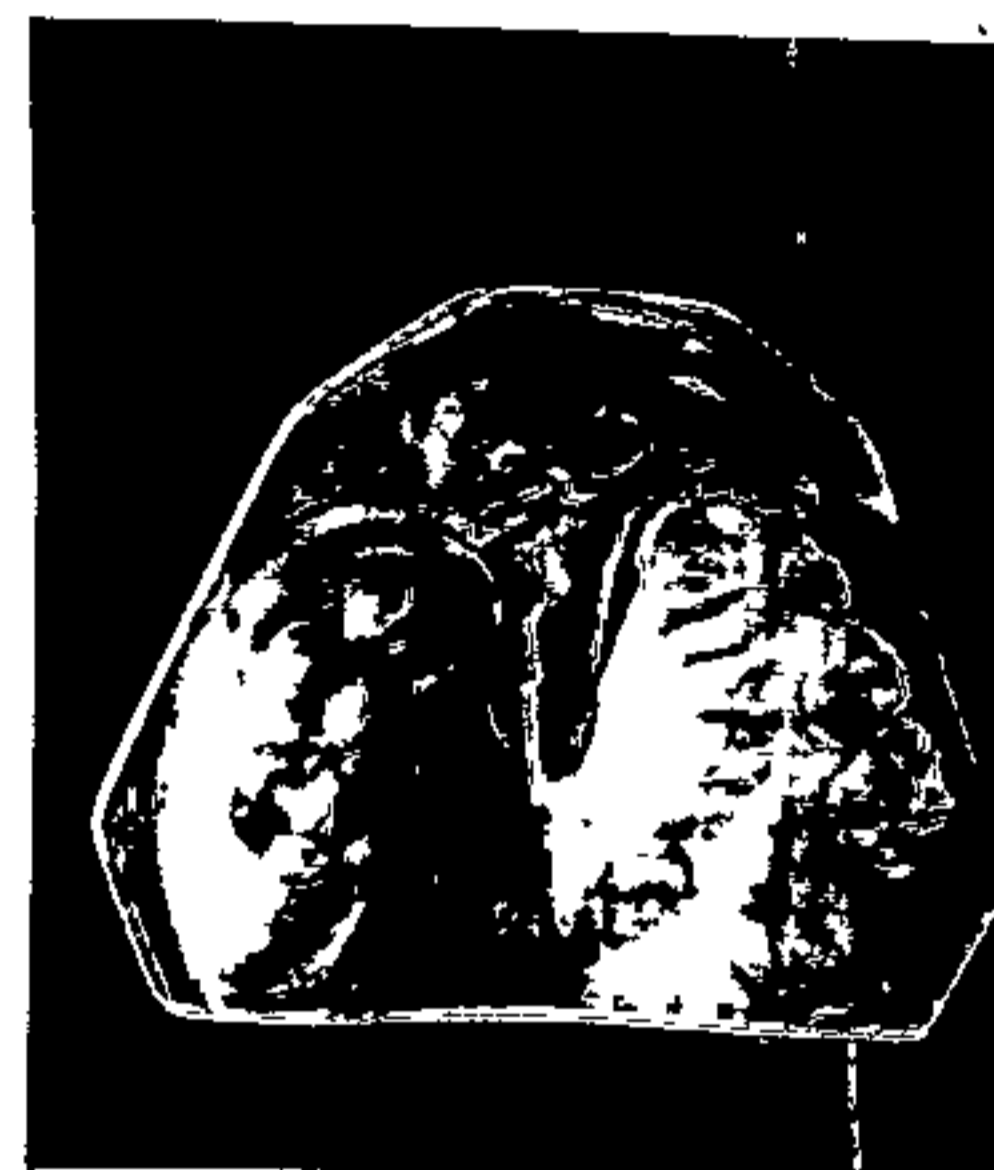
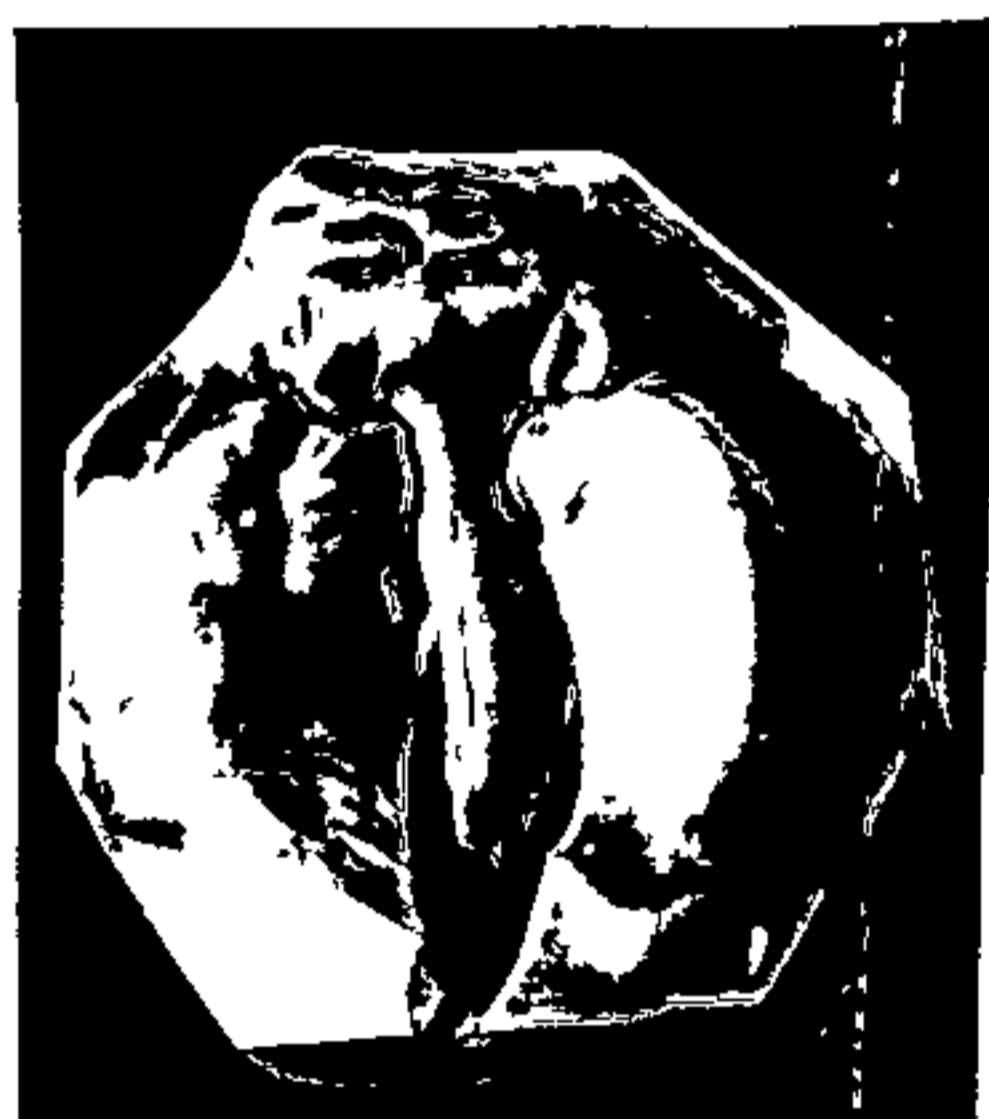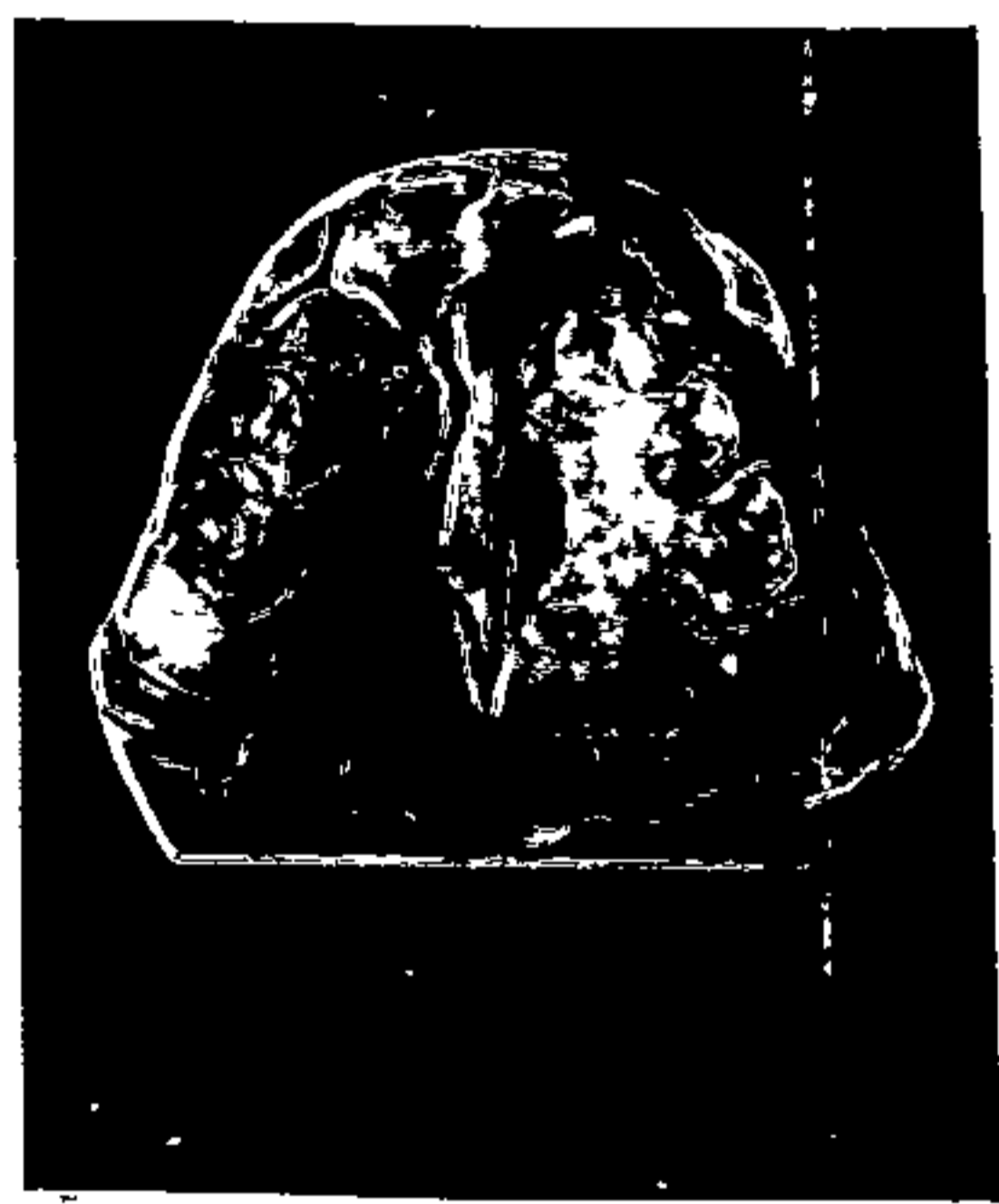


The maxillary laterals are missing, both in the deciduous and permanent dentition and the maxillary deciduous canine displayed hypoplasia. The upper right permanent maxillary canine is erupting in an abnormal position as is the upper left bicuspid.

Crowding in the buccal segments is quite obvious over all this stage. The degree of soft and hard tissue loss is quite easily assessed.

FIGURE 42

DISTURBED TOOTH FORMS



Cases of schizogenesis, resulting in Bifid crown with confluent root and root canals occurred seldom, one only was noticed in the literature available, but no doubt others have occurred. Germinated teeth have usually a common root but may be considered an odontome.

The dentine of the germinated tooth is contiguous but in the case of the concrescence the junction is at the cementum only, as explained.

115

Gerke in 1948 stated that 37.6% of cases presenting clefts were affected by dental anomalies or other hereditary disease and in 10% neurological disturbances occurred. A case of interest recently examined at the clinic Royal Alexandria Hospital for Children displayed -

1. Oro-pharyngeal closure :- imperfect.
2. Unilateral cleft lip and palate.
3. Missing lateral incisor in the deciduous dentition with rotation and notching of the central incisor and slight hypoplasia.
4. Deafness due to neurological disorder.
5. Cleipal Pheil syndrome.



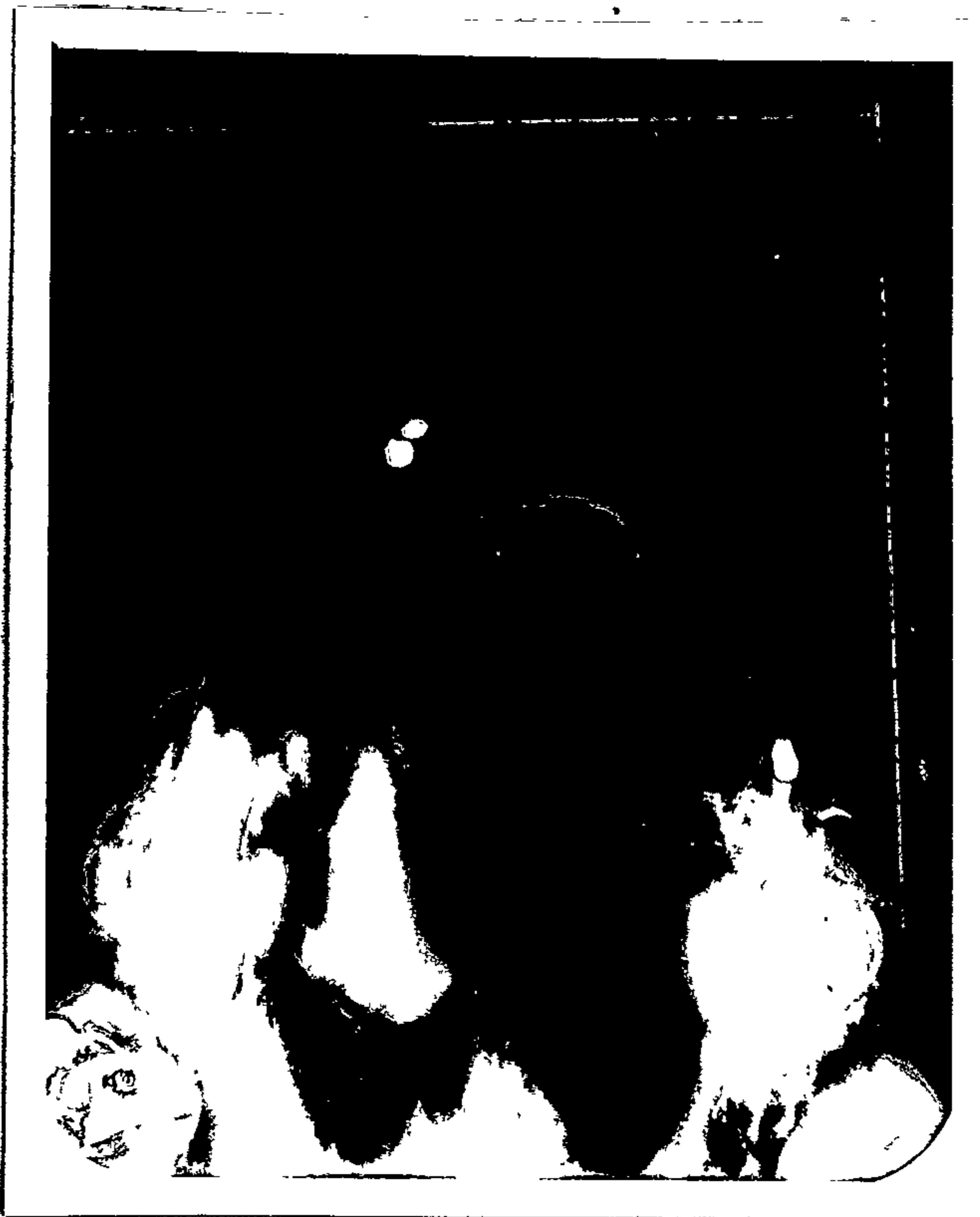

Figure (43)

This photograph of an occlusal film is that of a young girl 5 years of age. The case is a bilateral cleft lip and palate and the vomerine premaxillary segment is quite free and mobile. The distorted structure and position of the deciduous and permanent dentition in the premaxilla is quite apparent and in the right cleft lies an odontoma. The buccal segments already display crowding and the hard tissue loss is easily assessed. The intercanine width at this stage is reasonable and does not exhibit any marked collapse.




Figure (44)

This photograph is that of an occlusal film Roentgen of a bilateral cleft lip and palate and is included to illustrate the missing premaxillary segment and the incisor teeth with failure of formation of the upper left second bicuspid, and crowding in the left buccal segment. The intercanine width is reasonably normal.



FEEDING OF THE CLEFT PALATE CLEFT LIP CHILD

During normal feeding the child employs pressure squeezing the nipple with the lips between the tongue and alveolar process; at the same time maintaining suction between the tongue and alveolar process prior to the act of swallowing.

The cleft palate and a cleft lip child is handicapped for one or both of the sphincters, the orbicularis oris group and the palate-pharyngeal group of muscles may be disturbed resulting in failure of the sucking reflex due to incompetence of muscle and regurgitation of the milk through the nostrils.

Slight sucking may and usually does occur due to adaptability of the respective anatomical parts, but where lip alveolus and palate are cleft normal feeding is impossible as may be realised when the early photographs are re-examined. Under these circumstances artificial feeding is required or assistance by a special apparatus proposed by Dr. Wearn.

109.110

Methods of assistance are:-

1. Wearn type plate
2. Special teats - with holes larger than normal
3. Small spoon
4. Special food - (a) expressed breast milk (b) artificial food for infants.

Once the lip and alveolus are repaired, feeding may become normal, for the child may be capable of compensating for a palatal defect.

Feeding is important for the child must regain its birth weight and be healthy before surgery is undertaken to repair the defect.

109.110

Wearn stated that at birth there is no loss of tissue at all, merely a lack of union, a cleft. This is not agreed upon by all but it is agreed that the time of operation should be as soon as the child may stand the procedure (in case of lip conditions). He stated that the bottle would have different effects upon the bone structure than would the breast in feeding of a child. This has been disproved and most cleft children at some stage are artificially fed. Dr. W. Wearn constructed sucking plates which work with reasonable success, their only disadvantage being sterilization, which is still the problem of the common teat or dummy, a feat necessary to prevent the introduction of intestinal disease. In most hospitals where special appliances are not available, tube, pipette or spoon feeding is quite common. Dr. Kelsey Fry, Eastman's and Guys Hospitals, London, produced a feeding bottle<sup>4</sup>, with a small flap attached to the teat for closure of part of the cleft, the introduction of milk being completed by the nurse. A modification of this original idea was introduced with velop<sup>4</sup> flaps extending further to the posterior pharyngeal wall.

The advantages of these types of plates are that less air is introduced into the stomach during feeding and the sucking reflex functions well.

33

Brophy introduced a rubber type of appliance like a square flap with a handle. This appliance, although practical, is quite cumbersome. These types of teats allowed approximation of the tongue similar to the sucking of a cow. This method is claimed to institute the normal growth forces and produce the



broader palate by restoring negative pressure in the oral cavity during sucking. However, the follow up of several cases who have used such appliances has shown little if any difference from the other children with similar conditions, who did not use such appliances early. However, only good could result from this approach for the fundamental principle of all cleft palate therapy is to restore normal functional growth, habits and development.

The methods of feeding summarized are -

1. Pipette or dropper.
2. Teaspoon.
3. Catheter or tube feeding.
4. Velar sucking plate plus bottle.




Figure (45)

Photograph of an Roentgen of the naso-oro pharyngeal region illustrating patency of the naso pharynx during speech when closure should occur, possibly due to shortness of the soft palate with incorrect function. Excess escape of nasal air results.

ROENTGENOLOGY.

The Roentgenographic techniques employed in cleft palate, cleft lip examination are usually for -

1. Orthodontic evaluation which include -

- (a) Cephalometric appraisals.
- (b) Laminographic cephalometry.
- (c) Occlusal views.

2. Dental examination.

- (a) Periapical films.
- (b) Lateral X-rays.

3. Surgery for

- (a) growth interpretation
- (b) soft tissue outlines
- (c) skeletal morphology - lateral films.  
P.A. films.

4. Speech. To assess by means of lateral films and Barium or lipoidal tracer, the degree of function and patency of the palate-pharyngeal mechanism and adjustments of a prosthesis obturator.

Roentgenology has aided cleft analysis and diagnosis in all departments to a marked degree. It has led to a complete understanding of the degree and extent of the disturbance and has indicated the patterns followed during development. Cephalometry has produced many results, but justification of its value has not been accepted by all and a general reserve has been placed upon interpretation of the values as presented by Brodie and Downs.<sup>30.31</sup> Undecidedly it presents a comparison with the normal as well as an indication of the position and degree of abnormal development.

Cephalometric Laminography has introduced an examination and understanding of the influence of cleft palates upon such regions as the pterygoid plate inclination and has proved a successful



assistant to the surgeon. The orthodontist has been aided no end by a better understanding of the growth disturbances and has been provided with a means of comparison before and after treatment.

The prosthodontist has been substantially aided in evaluation of the degree of extension of the abberation, especially in cases where surgery has been unsuccessful or delayed.

38

Passavant's cushion which reflects on the posterior pharyngeal wall the contraction of the superior constrictor (or the position of the Atlas Vertebra) has been successfully examined during function and its approximation in a method of compensation to an inserted obturator witnessed.

#### Cephalometry and its variations.

Cephalometry has been utilized in many fields of orthodontia since its introduction by Brodie and Broadbent, and its evaluation by Downs and its modification by Boum. Diagnosis and classification of basal growth patterns as related to malocclusions have become accurate and indicative of Prognosis. Its use is invaluable as a means of assessing changes following orthodontic and/or surgical intervention in cleft lip and palate. The comparison of growth of the normal with growth of the cleft lip and palate have proved many suspected disturbances. Lately it was used to indicate and assess the changes of the premaxilla position during orthodontic retraction when associated with expansion of a bilateral cleft lip and palate case.

The measurement of overjet and overbite values in bilateral cases and the results of extirpation of the premaxilla has proved a substantial aid in treatment planning.

By means of the cephalometer it was possible to show if natural resolution of the dysplasia in the facial profile was occurring either rapidly or slowly.

Leonard T. Swanson in a study of one hundred children involving cephalometric analysis of cleft lip and cleft palate conditions including the relation of teeth to cranial base, of alveolar process position and relation of basal bone of maxilla and mandible to cranial structures recorded the values noted in the Cleft Palate Bulletin (34D R 8) <sup>34A</sup>

These values indicated that in cleft palate cleft lip patients mandibular overclosure and distal positioning of the mandible frequently occurred but that mandibular growth was normal.

Gilley suspected, on similar such observations and analysis that a decrease in Ramal height occurred. This is substantiated by <sup>the</sup> value of the mandibular plane angle. <sup>34d</sup>

The average 6° <sup>34</sup> lingual inclination of the lower incisor teeth was considered due to increased tension of the Orbicularis Oris muscle. Use is made of the cephalometer to record the vertical or anteroposterior movement in nasopharyngeal closure normally found in deglutition and in phonation.

<sup>62.69</sup> <sup>69</sup> Higley and Williams found that the closure was not complete for all sounds and the size of the opening between the oro pharynx and nasopharynx varied -

It was wide for "A"  
narrow for "B"  
completely closed in "I" and "U".

These are for the normal palate. In the cleft palate that <sup>69</sup> which has had surgical correction, Joseph Duban found some move-



ment of the palate in function but closure was not complete. He claimed that none had demonstrated closure of the soft palate and post pharyngeal wall, even after speech training, a fact sometimes verified in examination of our own clinical material. In most cases failure of closure was observed but occasional cases illustrated normal function or function to the critical point.

The degree of function of the soft palate varied with length and mobility which was influenced by the degree of scarring resulting from surgery. Mobility and function of the superior constrictor and salpingo pharyngeus could be examined Roentgenographically, illustrating it is often not just a movement of the soft palate to contact a stable posterior wall. Included is a photograph of an Roentgenograph indicating the method that may be utilised (of Barium salt or Lipoidal) as a tracer of soft tissue outline for observing the tissue position during certain functions.

Films were taken saying certain vowels and consonants, "A", "O", "K", "J", "G", "S", and a recording was taken during swallowing and at the physiological rest position. The increased degree of closure observed following surgery to restore a cleft palate was small and the majority of soft tissue outlines indicated that palato pharyngeal musculature was incompetent and patency resulted in nasal escape, indicating that in some cases a Hynes Pharyngoplasty would be of value.

Frontal laminography, a body sectioning radiographic technique, has shown that the maxillary arch is of greater width in the untreated cleft palate than in the normal individual for that age group.

It was proved that the inferior aspect of the vomer may be horizontally disposed and deflected towards its attachment to the palatal process of the maxilla on the non-cleft side.



THE GROUP SYSTEM TREATMENT AND ITS AID IN RESEARCH

An integrated and planned pattern of treatment has to be developed for the individual for complete rehabilitation within society.

To accomplish this a team of operators, each highly efficient in a phase of reconstruction, must be united and co-ordinated, each working towards this goal. Only in this way may the level of treatment be sustained at the required phase of perfection and delicacy. <sup>19</sup> Hamilton Baxter listed the specialists required for a complete rehabilitation as being -

1. Plastic surgeon.
2. Pediatrician.
3. Geneticist.
4. Dentist
5. Otolaryngologist.
6. Speech therapist.
7. Orthodontist.
8. Prosthodontist.
9. Psychologist.

Only within the confines of a large hospital could such a group exist with the required equipment, each as a separate unit in their own field, but working collectively upon the problems as a team. Research activities tend to break down the barriers between different specialists and restore the team spirit. To-day when a child is presented to the clinic, diagnosis is made and treatment planned. The importance of such a system is seen in follow up cases where surgery may be decided upon depending on an orthodontic expansion result. In such a case the appliance may be used as a retainer to stabilise the segments during surgery and prevent collapse rather than removal before surgery. Consultation together, of the orthodontist, otolaryngologist, surgeon

and speech therapist have frequently decided the fate of tonsils, adenoids and pharyngeal disturbance, in many cases resulting in a marked improvement in hearing, an important factor in speech.

Comparisons of results of one child with the previous, has often provided a modification in the technique used or a change in treatment planning or time of intervention in a field, particularly surgery. A complete history is attained and should, be the case referred, be available to the necessary people, in a form that is understood by all, simple, yet complete in all detail. Following diagnosis the child is referred to the respective specialists. The time to decide referral is at the clinic. The factors are the conditions influencing, features of the clefts and the age of the patient.

The disadvantages of group meetings are quite obvious, when the frequent repetitions of presentation of similar cases occurs. However, the gathering is stimulated by the interest of each operator and the presentation of cases illustrating the limitations of individual approach to the problem. Failures in treatment are few and success is measured by the resulting speech, aesthetics and function. Those case presenting failure are a challenge to all concerned in rehabilitation of the child. Failure may result from incorrect time of approach in progressive therapy. Each individual specialist learns to understand and appreciate the other's complications and handicaps and how they may be circumscribed or aided, e.g. orthodontia to aid the speech therapist in obtaining correct articulation during speech.

The examination of these children is invaluable in teaching



what variation to expect from the normal individual, the common standard. Variations in the age of treatment for the palate may depend upon the assessment of the collected specialists and the comparison with previously treated children together with new information provided by research. The age for surgical intervention in the palate has in many parts of America been postponed till the age of 3-4 years upon the advice of the orthodontist. The reason for such an approach has been to attempt to prevent the collapse either unilateral or bilateral that occurs in complete cleft conditions. This is often varied depending upon the intelligence of the child and the speech pattern.

The introduction of Hynes operation at an early age, together with soft palate repair means that orthodontia will follow at a later date usually 3-5 years of age. Most soft palates are repaired at 2 years of age with the intention of providing the best anatomical structures for speech, a mechanism much harder to perfect and repair than the collapsed palate.

The problems of anaesthesia should not be forgotten and its hazards within small oral and nasal cavities.

The mental hygiene of the patient and the parents is the responsibility of the pediatrician and/or physician claims Elaine Theodore and Elhrick<sup>49</sup>, just as the oral hygiene is the responsibility of the dentist.

Although the occurrence is only one in 750-900, complications such as thrush, respiratory infections, diarrhoea, problems in feeding, diet and general co-ordination between the mother and child, may provide some worrying moments for those concerned.

The mother's reaction to the abnormality is most important and in some cases psycho-therapy has had to be introduced. Enlarged adenoid and tonsils and respiratory infections are not infrequent and become the property of both the mentally incompetent and brilliant child.

61

Milton J. Hill wrote of the parents attitude to the cleft palate-lip child and found that a study of this position showed in many cases that there is still much to be desired in the relation of these two and the progress of rehabilitation.

Almost half the parents felt that the treatment was completed when the cleft was closed.

34c

Billy Jane McWilliams observed environmental factors in relation to speech development of children with cleft palate. Her observations indicated that there are many factors important to the child who is learning to talk, and that upset in emotions occurring in the home environment present a large hazard. Parent relationship is frequently reflected in the speech. Numerous investigations have indicated that the child who is not fully accepted by his parents suffers a serious slow down in learning to communicate verbally. We have long been aware that we cannot always explain the total speech disability on the basis of anatomical conditions.



PART II

ORTHODONTIA IN CLEFT ANOMALIES

<u>CHAPTER I</u>	Introduction and examination.
<u>CHAPTER II</u>	Classification.
<u>CHAPTER III</u>	Research.
<u>CHAPTER IV</u>	Normal growth, occlusion and its study. in relation to cleft palate lip complexities and abnormal growth patterns of cleft. Conclusions on growth.
<u>CHAPTER V</u>	Malocclusion and treatment. Cleft lip. Unilateral Cleft lip and palate. Bilateral Cleft lip and palate. Cleft of the hard and soft palate. Summary and conclusion.

---

PART II

ORTHODONTIA IN CLEFT ANOMALIES

Chapter I

Introduction:

By the introduction of cephalometry and its variation,  
100  
cephalometric laminography as developed by Brader, the deviations from normal in growth and development of the anatomical structures have been fully explored.

The aim of total rehabilitation of the child with these dento facial irregularities has led to closer co-operation with other specialists, and greater understanding of these problems in treatment.

Within the past few years there has been rapid growth in speech training, and greater concentration has been placed upon the dental irregularities affecting speech. Treatment is designed to prepare the child for living in society as normally as possible.

Many emotional and social adjustments are required, and during this period of development, speech which is the mechanism of transmission of one's concepts and opinions to others, frequently requires many helping hands to reach its' full natural potential.

Malocclusion has been found to be an influencing factor in abnormal speech production.

Initiation of orthodontic treatment at an early age has been found to be markedly beneficial - treatment is commenced in the deciduous dentition and is maintained at periods until the full dentition is in a correct occlusion. Such a procedure has



resulted in marked improvement in speech and articulation, masticatory efficiency, dental oral hygiene decrease, incidence of marginal gingivitis, and dental caries, facial bone contour, profile appearance and aesthetics.

An understanding of normal development as outlined by Brader and discussed under growth is essential for comparison of the arch and growth of the cleft child with the normal, and this is constantly made during treatment. The results produced in most clinics to-day are very satisfying. Orthodontia cannot restore lost segments of the arch, and in most complete cleft cases, either unilateral or Bilateral, a prosthetic appliance completes the therapy restoring lost segments and tissues.

Method of Examination of Cleft Lip and/or Cleft Palate Children.

The child of yesterday was presented to the orthodontist at a time when a malocclusion had been established in the second dentition. To-day from the time a child is received to the "Cleft Palate Unit", each and every specialist's interest is established and no longer does the malocclusion be discovered initially at the age of ten years. Early examination and diagnosis has led to earlier treatment.

Records are obtained usually after the surgeon has received the case, for he is the first "line of defence" in the attack upon the problem, and is the first called to the child. These records include:

1. Study models of both the maxilla and mandible, and may be taken before and after initial lip surgery, e.g. figure (46) and (48).

2. Roentgenographs, which include occlusal films and cephalometric analysis, if available.
3. Photographs - anterior and profile views prove very helpful before and after surgery and orthodontic treatment, to evaluate restored tissue position and facial contour.

From such records improvements in the overall treatment pattern may be arrived at and difficulties to be encountered, predetermined. The prognosis, structural, functional and psychological needs of the individual may be evaluated.

The results of older age groups will influence and plan of treatment in younger generations, and standard comparisons are obtained for use within the same age group.

By consideration of the anatomical and physiological controlling factors of arch formation in early examination, and by consultation with the surgeon, every effort is made to aid the dynamics of growth within the environment of the changing muscle forces. Surgical repair will not only establish anatomical unity of muscle, mucous membrane, and skin, but result in changes in the forces of the orbicularis oris, as witnessed in figures (64), (6) <sup>46E</sup> ~~(46)~~.

Asymmetrical tensions observed in examination prior to surgery, appears to pull the bony segments of the maxillae apart. However, surgery restores normal function, resulting in a moulding of these bony structures and illustrated in figures (46, 47, 48).

It suffices to say at this stage that examination must be complete and assessment of all abnormalities, such as Pierre Robins' Syndrome, which may contain a cleft palate, should be recorded. It is necessary as far as practical and where a reliable source exists, to trace the hereditary influence, care



being taken in interpretation of the available information.

The factors influencing malocclusion post-natally may be:

- (i) Intrinsic
- (ii) Environmental
- (iii) Systemic

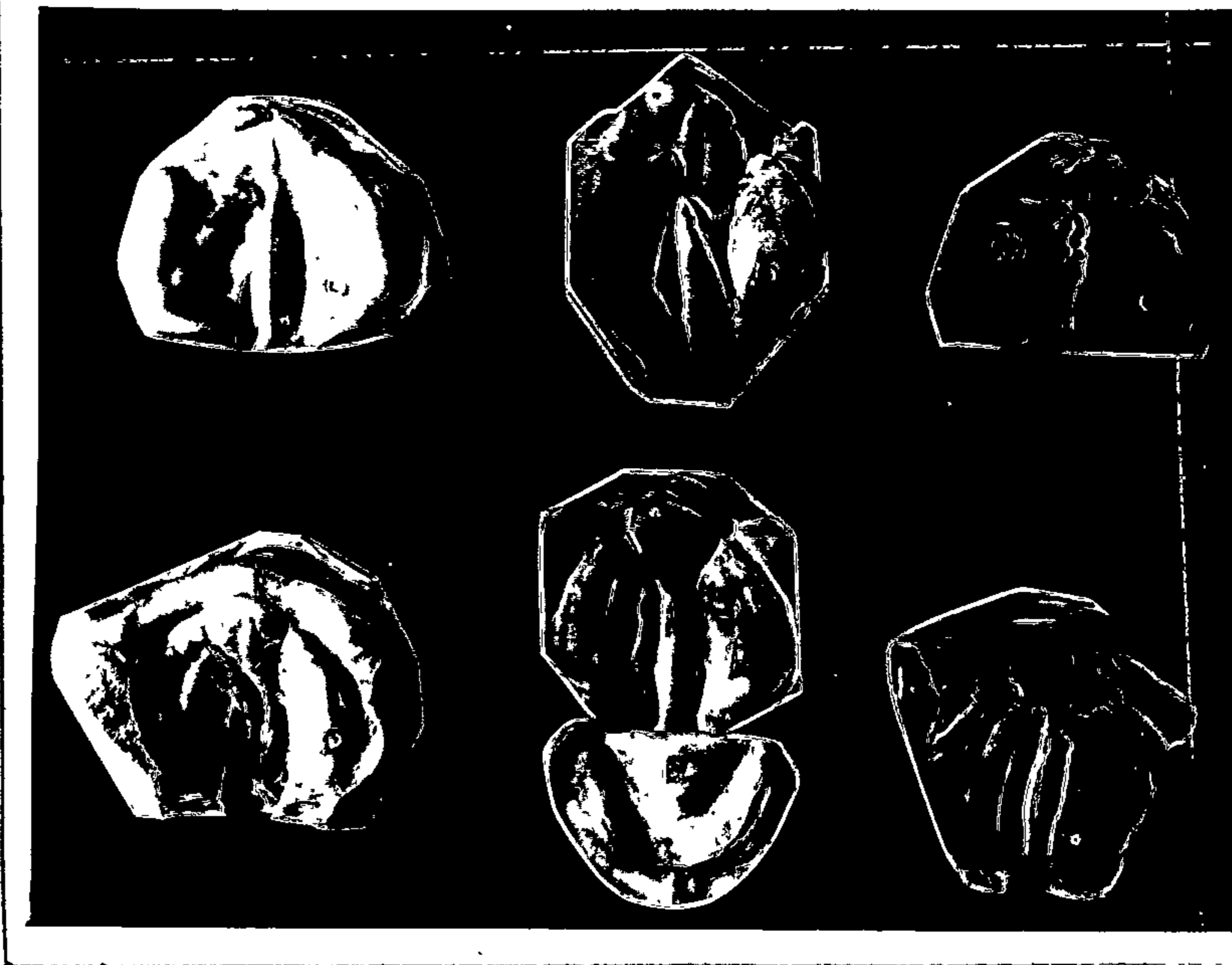


Figure (46)

Figure (46)(a)

This cast of the maxillary arch is taken some months after birth. Here is illustrated the presence of the maxillary incisors in the premaxilla, which has occupied a good position in this bilateral case between the two maxillary segments. The arch form is reasonable, and as yet the palate unclosed. There is little collapse of the two maxillae as yet.

Figure (46)(b)

This is a cast of the maxillary arch with part of the soft palate. The abnormality is a Bilateral Hare Lip and cleft palate. Here may be witnessed the rotated premaxillae and the inferior border of the nasal septum. The cleft is quite wide

and extending completely through the soft palate, with a marked oro-nasal communication, both laterally and palatally. Lip surgery has resulted in an even contoured though broken arch, whilst palatal surgery at this age can only result in marked contraction and distortion of the arch form.

Figure (46)(c)

This is a cast of a maxillary arch illustrating the growth and development at a later age in a bilateral cleft lip and palate anomaly. The premaxillae is slightly mobile and the alveolar cleft edges of the maxillae have collapsed towards the vomer. There is evidence of palatal surgery and cicatricial tissue in the palate.

Figures (46)(d), (e), & (f).

These illustrate similar bilateral hare lip and cleft palate presentations at birth following lip surgery. The variation and position of the palatal cleft is obvious, and clearly illustrated are the variations in the position of the inferior border of the nasal septum.

In Figure (46)(d) the septum is lying to the left with a distinct curve and during growth should collapse of the left maxillae occur, then restriction in size of the left nasal cavity must result. Orthodontic treatment has been towards preventing this disturbance, or in many cases where it has occurred, to restoring the size of the nasal passage by widening the maxillary arch orthopedically.

Figure (46)(e) shows the normal size mandible, but even at this stage comparison with the maxilla shows a premaxillary prominence.



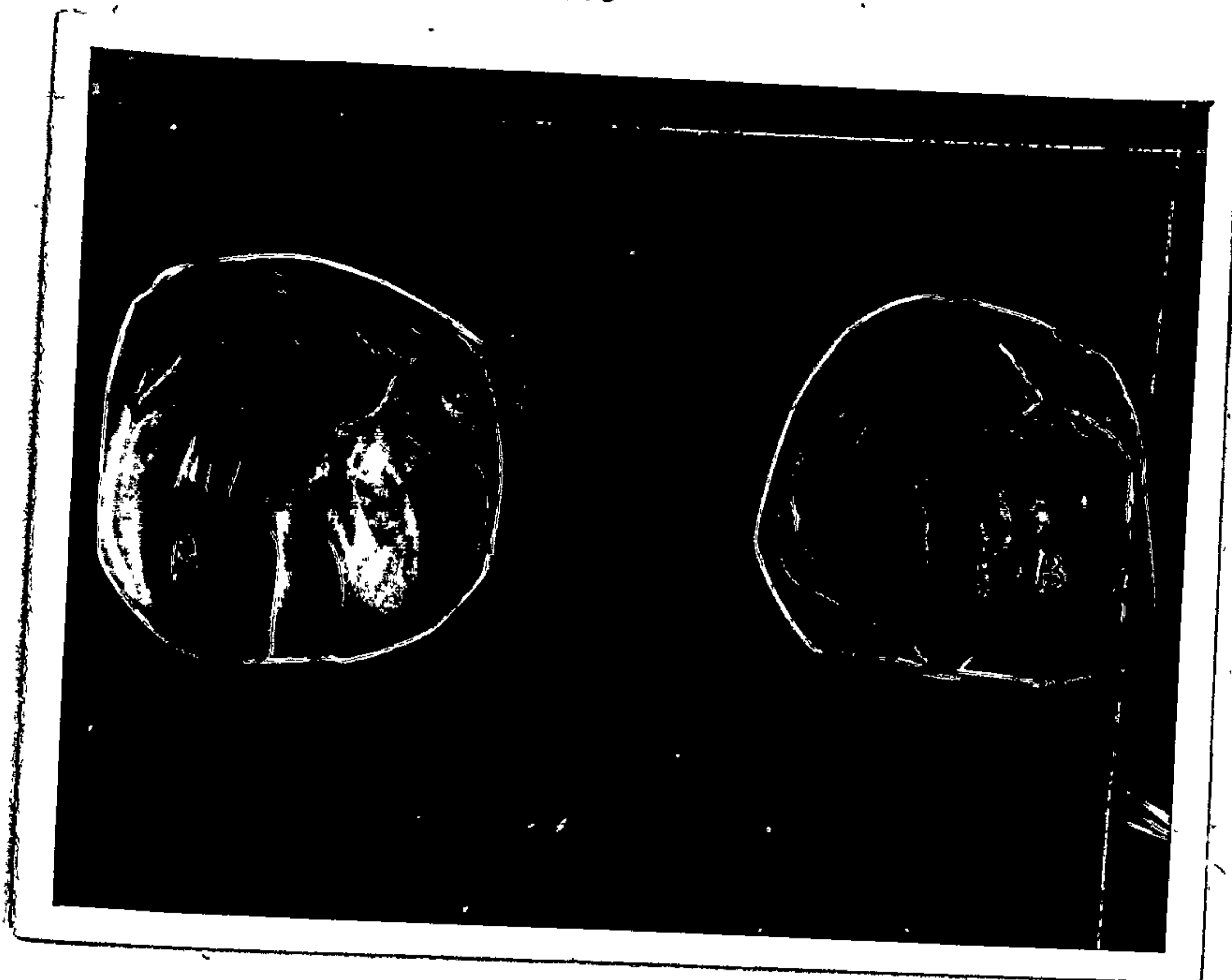


Figure (47)

Figure (47)(a)

This cast of a maxillary arch taken shortly after birth, illustrates the bilateral cleft lip and palate; the severer expression occurs in the left cast. The inferior border of the vomer is visible in the midline and is quite thick and rounded. An oro-nasal fistula lies in the labial sulcus. There is visible moulding of the alveolar segments following lip surgery, and this may result in an overlapping of the alveolar arch. Early palatal surgery will accentuate this collapse. The restoration of a functioning orbicularis oris is essential, whilst palatal surgery may be left until a later age. Approximation of the alveolar segments is far better than overlapping.

Figure (47)(b)

This cast of a maxilla illustrates a unilateral cleft condition of the lip and palatal cleft. The alveolar arch segments here are in apposition, and the maxillary arch form

satisfactory. There is substantial width and restoration of a normal functioning unit. The palate is as yet untouched and similar circumstances exist as in the preceding cast.




Figure (48)

Figure (48)(a) & (b) are casts of a maxillary arch. These illustrate clearly the resulting arch following lip surgery in a unilateral cleft lip and palate. Should palatal collapse occur it follows that it occurs unilaterally.

Figure (c) is a cast of the maxillary arch also a unilateral cleft lip and palate. The effect on the deciduous dentition is shown by the loss of the right lateral incisor. It may not have erupted and may lie within the cleft. The arch form is here quite reasonable and little collapse is evident.

Figure (d) is the cast of a maxilla affected by the Bilateral Cleft lip and palate. The palate displays cicatricial tissue and the premaxilla is lacking having either failed to develop or been lost during surgery. Here is clearly evident the collapse



of the maxillary arch with a marked fall in the intercanine width and stressed the need for early orthodontics in the deciduous dentition, to restore normal arch form and facial contour.

Figure (e) This cast of the maxilla was taken to illustrate the result of surgery on one side of the lip in a bilateral cleft lip and palate. Here may be witnessed the rotation of the premaxilla and the moulding of the alveolar segments abutting the cleft. The flaring of the alveolar segments visible in Figures (14, 64) has been reduced and when surgery is completed upon the other side, an arch similar to figure (46, 65) will result.

Intrinsic factors are those aiding the malocclusion that are part of or associated with the component elements of the dental arches.

Examination of the dental arches should be complete, stressing such factors as:

1. Caries incidence.
2. Premature loss of deciduous teeth - this may complicate classification of the malocclusion.
3. Restorations.
4. Abnormal position of permanent teeth.
5. Missing, supernumery, unerupted, and malformed teeth.
6. Abnormal cicatricial tissue or (frena)
7. Non-harmony in tooth size and bone structure.
8. Habits and perversions: e.g.
  - (i) Abnormal swallow
  - (ii) Speech abnormality dyslalia.

- (iii) Tongue thrust.
- (iv) Malocclusion
- (v) Thumb sucking, finger sucking, biting habits.
- (vi) Mouth breathing.
- (vii) Assessment of soft and hard tissue loss and scar tissue that may result from surgery. A soft tissue roentgenograph or a photograph will evaluate the facial profile, and provide a permanent record. Superimpositions showing changes in profile contours before and after surgery may be made from these records.

Environmental causes such as hypertrophy of pharyngeal lymphoid tissue and intranasal defects, such as deflected septum or bony spurs, may aggravate the malocclusion or abnormal speech by upsetting the balance of forces that normally play upon the oral structures, already a disturbed pattern. Examination of lymphoid tissue must be complete. This tissue is a line of defence, and generally is susceptible to chronic irritation and response by a cellular proliferation that greatly increases its size. The size of this tissue is most important, for its removal has often resulted in cleft palate cases passing into a regression of the speech, <sup>38</sup> The size of the naso-pharyngeal isthmus is increased by removal of this tissue.

When the pharyngeal tonsil is enlarged it may mechanically shut off the air passage from the pharynx to the nasal cavity. This in turn results in mouth breathing in a normal child. In a cleft palate condition it aids velo pharyngeal closure and wherever possible the pharyngeal tonsil should be retained in cleft palate cases.



CLASSIFICATION.

33

Brophy in 1915 distinguished fifteen types of cleft lip  
4.18.100  
palate complexes. Veau has reduced the classification to the  
following types:

1. Simple cleft of soft palate only.
2. Cleft of hard and soft palate only.
3. Unilateral cleft of maxillary lip and alveolar ridge.
4. Bilateral clefts of maxillary lip and alveolar ridge.
5. Clefts in the median line with intact soft palate.

102

Veau's classification was based upon the embryological growth  
disturbance that resulted congenitally in failure of union between  
embryonic processrs. 4.34.41  
Cooper's classification, based upon the  
assumption that midline clefts are rare, and unnecessarily class-  
ified, records:-

1. Soft tissue cleft of the palate.
2. Soft and bony tissue cleft of the palate.
3. Soft and bony tissue cleft of the palate associated with  
unilateral cleft of the lip and alveolus.
4. Soft and bony tissue palatal cleft with bilateral cleft of  
lip and alveolus.

Most classifications are based on surgical requirements.

121

Blair however, considers that it should be based upon anatomical  
deformity, as this is claimed to provide the easiest method of  
assessment.

29.32

88.90

However, by cephalometric appraisal, Brodie and Pruzansky  
have been able to show that disturbances in cranial growth have  
occurred and have references on treatment not obvious in classif-  
ication.

Pruzansky after a study with cephalometric laminography provides the following classifications:

- (i) Clefts involving the lip and palate.
- (ii) Clefts involving the palate alone.
- (iii) Clefts involving the lip alone.
- (iv) Congenital insufficiency of the palate.

This latter type is not a cleft but a condition often witnessed in these cases. The palate here refers to the hard palate and soft palate (Velum). No special mention is made of the alveolar process.

90

Pruzansky stated:

"By noting the degree of lip involvement it was possible to predict with considerable accuracy the extent of the defect in the alveolar process. The more complete the defect in the lip the greater was the cleft in the alveolar process and this was found to be a constant relationship."

However, observations have shown that submucous clefts of the alveolar process occur alone and in most cases are found to exist associated with multiple anomalies elsewhere in the body.

The relations of maxillary and mandibular arches to cranial structures have been studied intensely by Hillman, Broadbent, Brodie, Ballard, and Downs.

34

31

29.31

7

31

89

It has been assessed that although in most cleft cases the mandible may develop normally, this cleft complex may be associated with Class I, II, or III malocclusions, (Angle classifications) and further complicated classification and diagnosis.

By interpreting the relationship of basal bone development



of the maxilla and mandible to the cranial structures, and correct assessment of the incisor inclination, canine position and molar relationship where available, each of Cooper's classifications orthodontically could be further subdivided.

However, the disturbance may be so severe in some cases that subdivision may only confuse the issue and treatment.

Classification may in many cases indicate whether a correct incisor relationship will be established by treatment. Labial movement of the maxillary permanent incisors is frequently necessary and classification may indicate the prognosis.

Frequently in cleft palate lip complexes there is little change in the width of the palate at the region of the six year molars, but at the intercanine width there may be a marked reduction frequently associated with a reduced premaxillary element. (Fig. 48 D).

Rotation and mesial migration or mesial migration then rotation, of the six year molars occurs which may confuse classification orthodontically. The cephalometer has proved a handy weapon in evaluation of these factors of disturbed growth and development.

Classification anatomically does not indicate the pattern of occlusion and arch form that occurs in cleft lip and cleft palate association. Those conditions existing in these cases are:

- (1) Unilateral collapse - maxillary segment.
- (11) Bilateral collapse - maxilla.
- (111) Premaxillary prominence or lack.

Cross-bite relationships may follow this disturbance, and usually do.

Classification to-day must then consider the following conditions:

1. Classification according to anatomical deformity.
2. Classification according to angle Class I, II, or III.
3. Cross bite classification:
  - (i) Unilateral collapse.
  - (ii) Bilateral collapse.
  - (iii) Premaxillary prominence or lack.

All these factors must be assessed before a true classification orthodontically may be made.

The classification proposed incorporates most of these conditions and reflects upon arch form.

Type 1. Clefts of the lip, which may involve the alveolus only.

Type 2. Unilateral cleft of the lip and alveolus associated with complete cleft palate which may exhibit a unilateral collapsed maxilla.

Type 3. Bilateral cleft of the lip and alveolus associated with complete cleft of the palate which may exhibit

- (a) Bilateral or unilateral collapse of the maxillae
- (b) A prominence or lack of premaxillary element.

Type 4. Cleft of the hard and soft palate only.

Type 5. Cleft of the soft palate only.

Each type may have an associated angle malocclusion - Types I, II, and III.



R E S E A R C H.

The basis of research is observations and new interpretations of existing conditions. The last 25 years has made available remarkable mechanisms for examination. The orthodontist has been assisted by frontal cephalometric laminography, and the results of J. Daniel Subtelny (using the cephalometer) have shown and indicated that:

Five sixths of the total palatal breadth has been accomplished by the end of the fourth year, indicating that surgery of the palate would be better left until this age is reached in the patient.

Downward and forward growth of the palate occurs till 20 years of age. Surgical unoperated cleft palate patients have approximately normal growth of their jaws.

Surgical correction of the cleft palate limits the growth potential of the maxilla and surgery may render this structure deficient in anterior, posterior, lateral, and vertical growth. (Not necessarily agreed upon).

During this phase it was found that mandibular growth may remain almost normal. It was found also that the greater the number of operations, the greater the amount of cicatricial tissue and deviation from normal, for examination indicated that surgically repaired soft tissue grew more slowly than the surrounding tissue, due possibly to a lowering of its blood supply.

From the early fear that orthodontic treatment of expansion of the maxilla would break down the hard earned surgically closed palates, research and hard work has provided new concepts in treatment and expelled many of the worries. Samuel Pruzansky

stated and showed that the cleft palate child did not receive only orthodontic therapy, but rather orthopaedic treatment associated with orthodontic movement in therapy.

During expansion of the maxillae in collapsed cases, marked improvement of the facial contour resulted, and by careful seriological comparisons it was established that the maxillary segments in respective cases moved apart. Cooper earlier had claimed this result, but had not substantiated the claims with adequate material.

The forces of occlusion are in a constant dynamic state in the growing child and the growth potential is the initiating factor in arch form, occlusion, and articulation.

These facial bones, growing in an environment of functioning facial muscles of expression and pharyngeal muscles of deglutition<sup>11</sup> have been extensively examined by Ballard and Gwenne Evans, who have cleared some of the problems of neuromuscular patterns and behaviour.

The physical effects of these structures are reflected in the hard and soft tissues of the oral cavity, and abnormal development of bony segments does not provide normal functioning muscles. Surgical intervention did much to restore anatomical unity of the parts concerned, and remoulding of bony elements, but often supplied collapse either bilateral or unilateral.

By measurements and cephalometric laminography frontally, it has been established that there is little decrease in the Bi molar (6 year) width, but a marked fall in the intercanine width during growth.



Diagram I

Type I

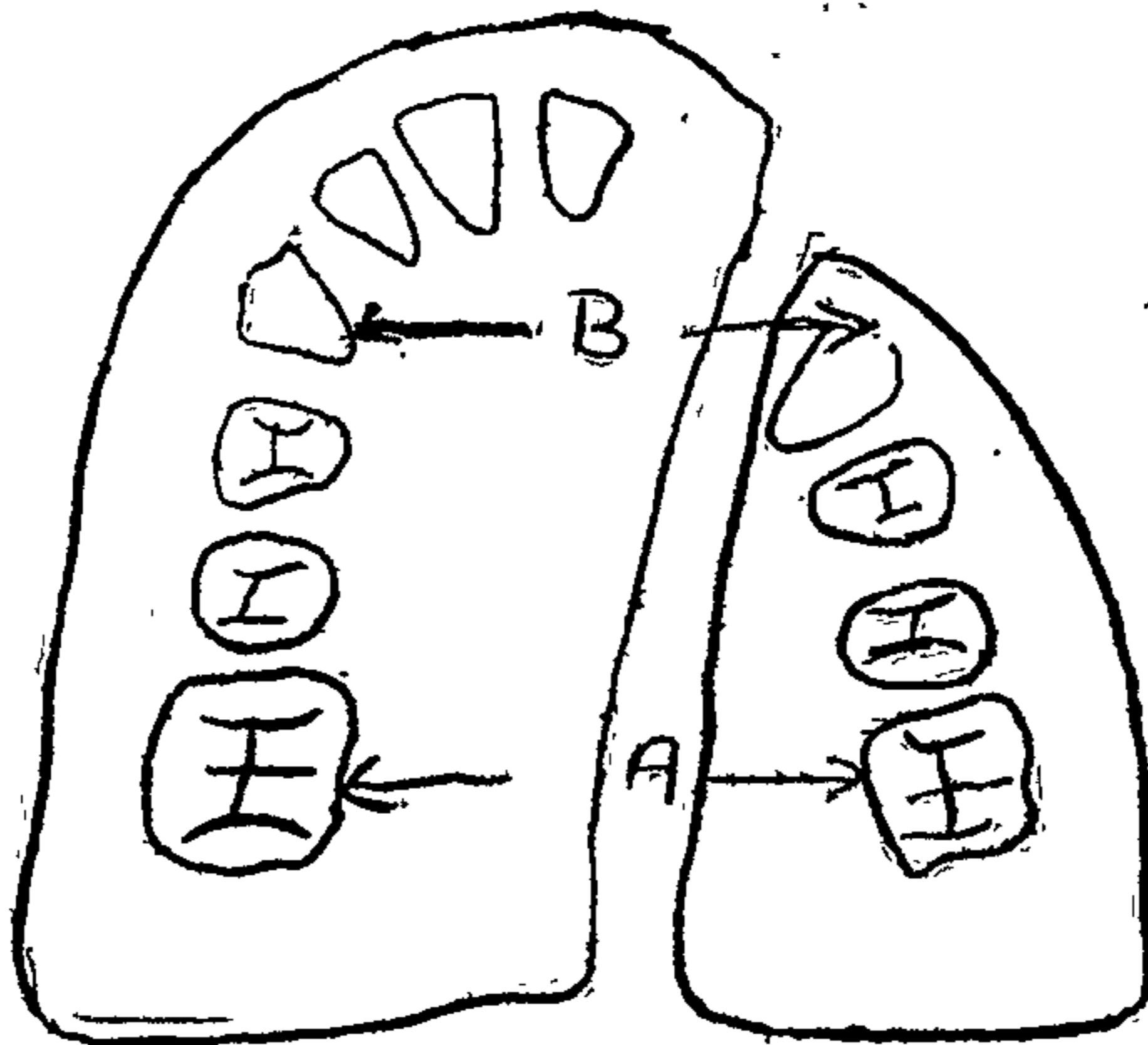
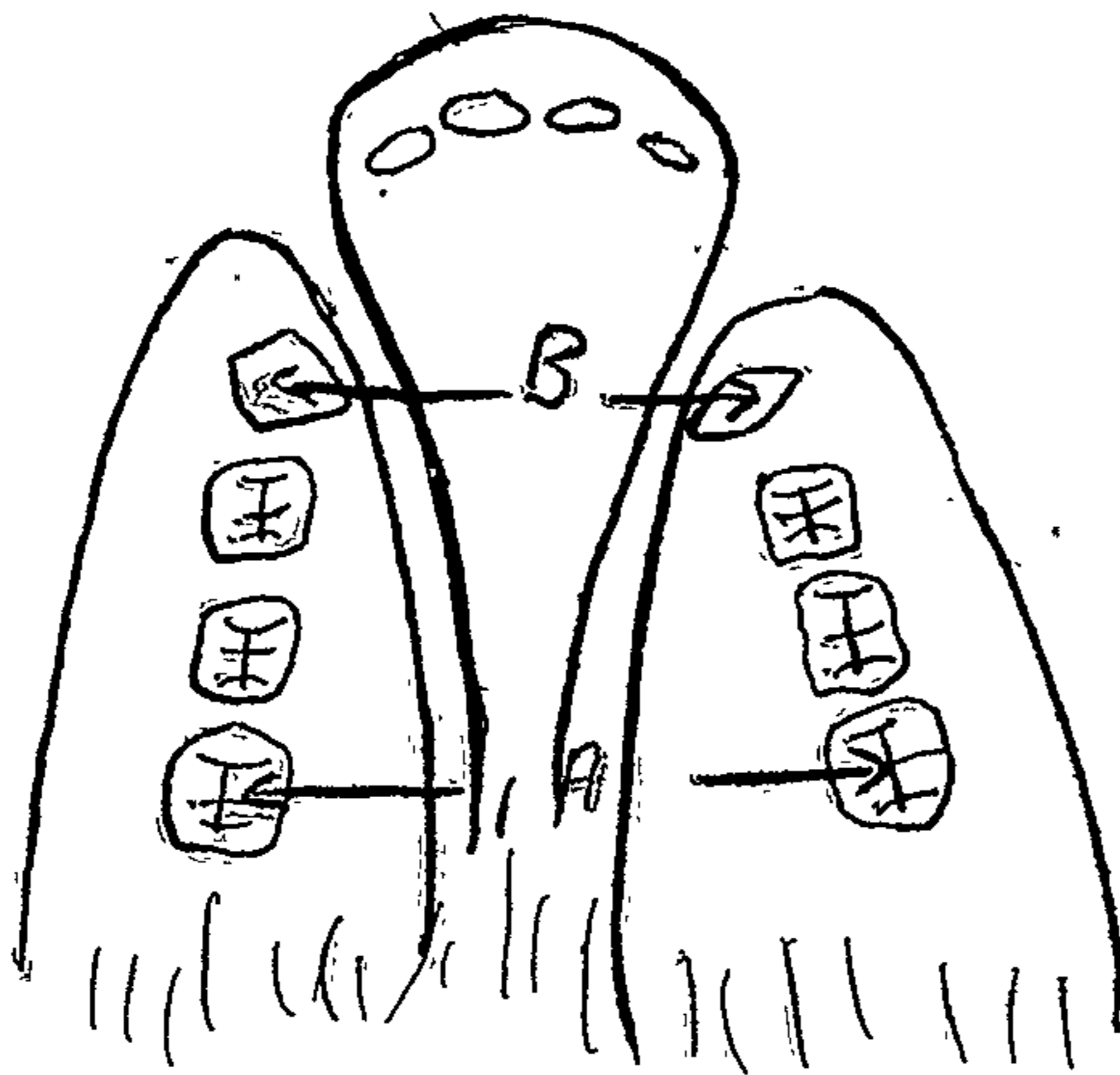


Diagram II

Type II

B = Reduced width

A = Normal width



Treatment is based upon restoration of this intercanine width and the question arose; would there be a change in the molar width? Observations have indicated that should expansion

be orthodontically provided to restore the normal arch form, true parallel expansion of the segments does not occur. The movement is more of a rotation occurring through a buttress in the post maxillary pterygoid plane, a position not yet determined. Frequently over-expansion is necessary as some degree of collapse follows expansion, and where a heavy force is used, expansion at the molar width occurs.

Two factors tended to influence this intercanine expansion during orthopaedic movement:

1. The type and degree of cicatrical tissue following surgery in the palatal repair.
2. The age of attempted treatment. (Expansion conducted early was found to progress rapidly.)

Bilateral expansion sometimes provides space for slight retraction of the premaxillary segment, but results are never dramatic.

The type of soft tissue resulting from surgery in the palate falls into three main types:

1. Gross fibrous cicatrical tissue, either completely or incompletely closing the palate.
2. Moderate occurrence of fibrous tissue completely closing the oro-nasal communicative.
3. Normal scar tissue following repair.

All grades between these have been observed and the rapidity of expansion is directly proportioned to the cicatrical tissues, little cicatricial tissue providing rapid expansion and vice versa.

Constantly applied force does not break down a tissue repair



so long as the force is firm and continuous, as does occur in orthodontic therapy. Where the related cleft is incompletely closed, expansion is rapid.

The repair in Bilateral Cleft lip and palate cases in the lip region is important. Where gross or marked cicatrization of tissue occurs, there is observed restricted forward growth movement of the premaxilla in early years, which is advantageous.

However, when orthodontic treatment is commenced, Pruzansky<sup>90b</sup> commented that marked fibrous tissue frequently is a source of annoyance to the orthodontist in establishing and maintaining arch form.

Distal movement of the premaxilla is encouraged in protrusive bilateral cases. Surgery to date does appear to best answer the problem, though not completely.

The removal of a "V" section from the vomer - nasal septum, leads often to rotation of the premaxillary element, as often does orthodontia.

Removal of a large rectangular section from the vomer results in posterior movement horizontally of the premaxilla, especially where edgewise arch is used post operatively orthodontically.

PROMINENT. PREMAXILLAE SURGICAL RESECTION AND POSITIONING.

Figure (50)

Diagram I

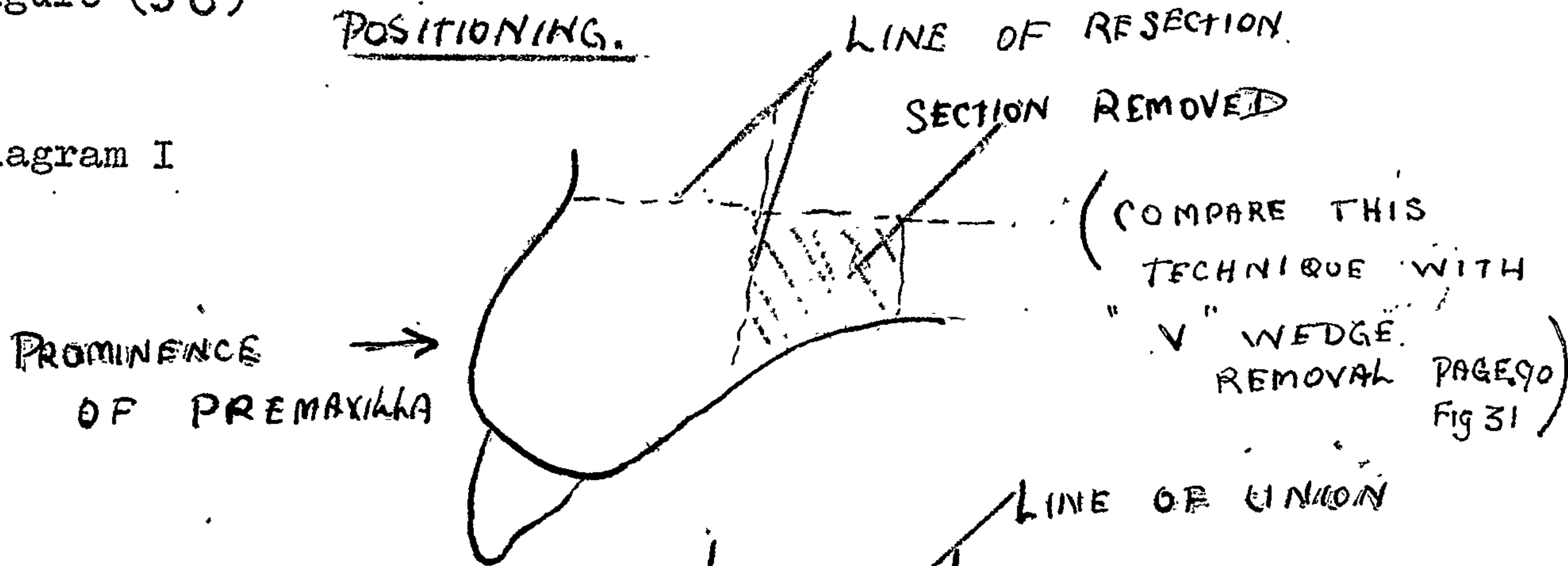
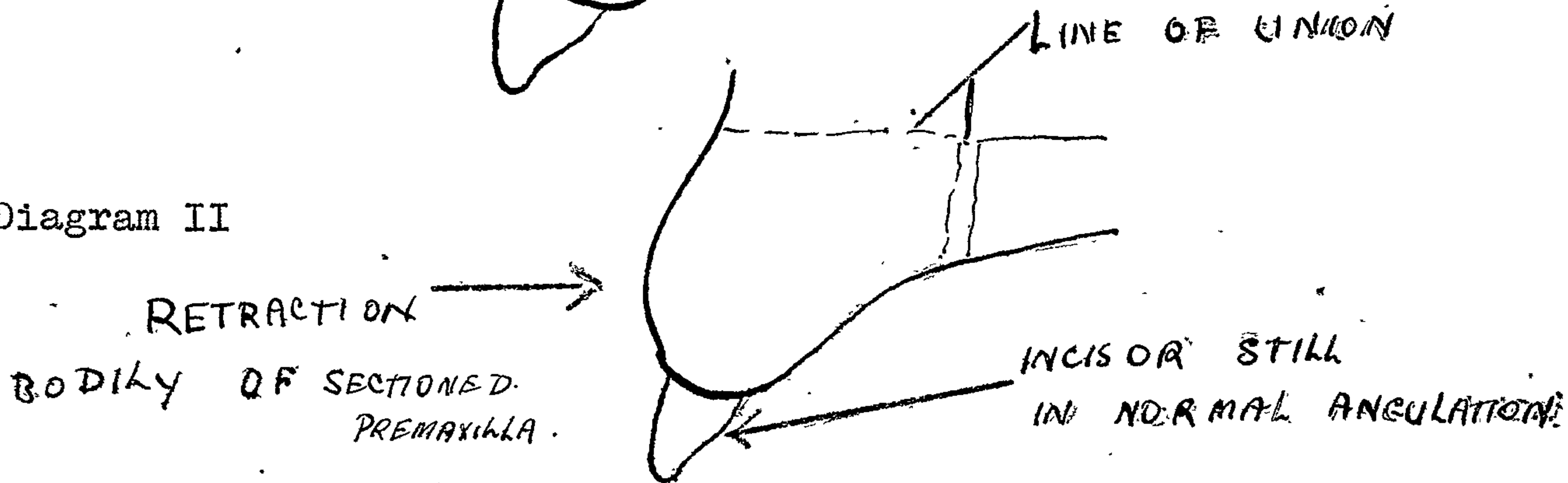


Diagram II



Normally the blood supply to the premaxilla is excellent, but occasional sequestration due to ischaemia has been recorded, and this complication should not be overlooked.

The response to splinting using case ferrule splints is encouraging but often complicated by the lack of undercuts and size of the deciduous teeth that are used for retention. A one piece splint appears far better than a sectioned splint for retention of the premaxilla and two maxillae following a "Wedge" section removal from the septum in bilateral hare lip cleft palate cases.

An assessment of whether surgical approach plus splinting or orthodontic therapy provides the best result is as yet not proved. It is known that the surgical technique does not provide for expansion of the collapsed segments and frequently has to be followed by orthodontic expansion. The orthodontic movement



distally of the premaxilla may be influenced by the degree of cicatricial tissue, and results most cases in just a tipping palatally of the incisors.

When the actual positions of bony changes and movement are known, then only may treatment be outlined with full confidence and results predicted.

Cephalometric laminography has provided vast information on the naso-pharyngeal growth and changes in cleft palate cases, and observations recorded by Daniel Subtelmy in the section <sup>100</sup> dealing with the nasopharynx.

Normal Growth occlusion, and it's study in relation to cleft palate lip complexities, and abnormal growth patterns of clefts.

Without a complete understanding of normal growth and its patterns both in soft and hard tissue of the maxilla-mandibular complexes, true comprehension of the abnormal patterns with their many variations is not possible.

As the sum of experience and knowledge in cleft palate increases, concepts of the pattern of abnormal growth and development form.

With a clear visualization of the normal as is known to-day, a standard is set for each age group for comparison to the abnormal. This may be clearly illustrated in cephalometric analysis as provided by Brodie, Downs, and subsequently Pruzansky, who examined both normal and cleft palate children cephalometrically.

It is not intended here to describe the normal growth pattern, but to include only a few photographs and diagrams to illustrate the method of approach of diagnosis of malocclusions. So much has been written about the forces of occlusion that it is impossible to present an original discussion, and this is not intended.

Angle early defined normal occlusion as that occlusion maintained in harmony in size and relation of the dental arches through the interdefence and mutual support of the occlusal inclined planes of the teeth and influenced by muscles labially, buccally, and lingually.

Newcomb, Strang and Downs have completely explored Angle's conceptions and have added further enumerations that govern arch



form and occlusion of the teeth.

11

8

Ballard, Gwenne Evans, Hays and Adams have all contributed to the understanding of neuro-muscular patterns, their abnormalities and perversions, and influences on bone growth and occlusion.

None of these factors is permanent being in a constant state of flux, changing with the years as expressed by Samuel Pruzansky<sup>89.90</sup> "a dynamic environment".

The forces ensuing from the contractions of the muscles of mastication and expression are operative from in utero - a period of prolific skeletal growth and differentiation.

The fact that the abnormality gains expression as early as the fifth week only indicates too clearly the upset that must occur in the normal forces.

The sphincter like actions of the Orbicularis Oris and the soft palate are disturbed and the forces operate in a direction opposite to normal. Bone growth consequently must be directly influenced, depending upon the degree of the abnormality.

Photographs of normal growth patterns cephalometrically examined by Brodie and co-workers from infancy to adulthood.

GROWTH OF THE FACE AS PRESENTED BY BRODIE & DOWNS.

AND REVIEWED BY DR. K. T. ADAMSON.

FIG. (51)

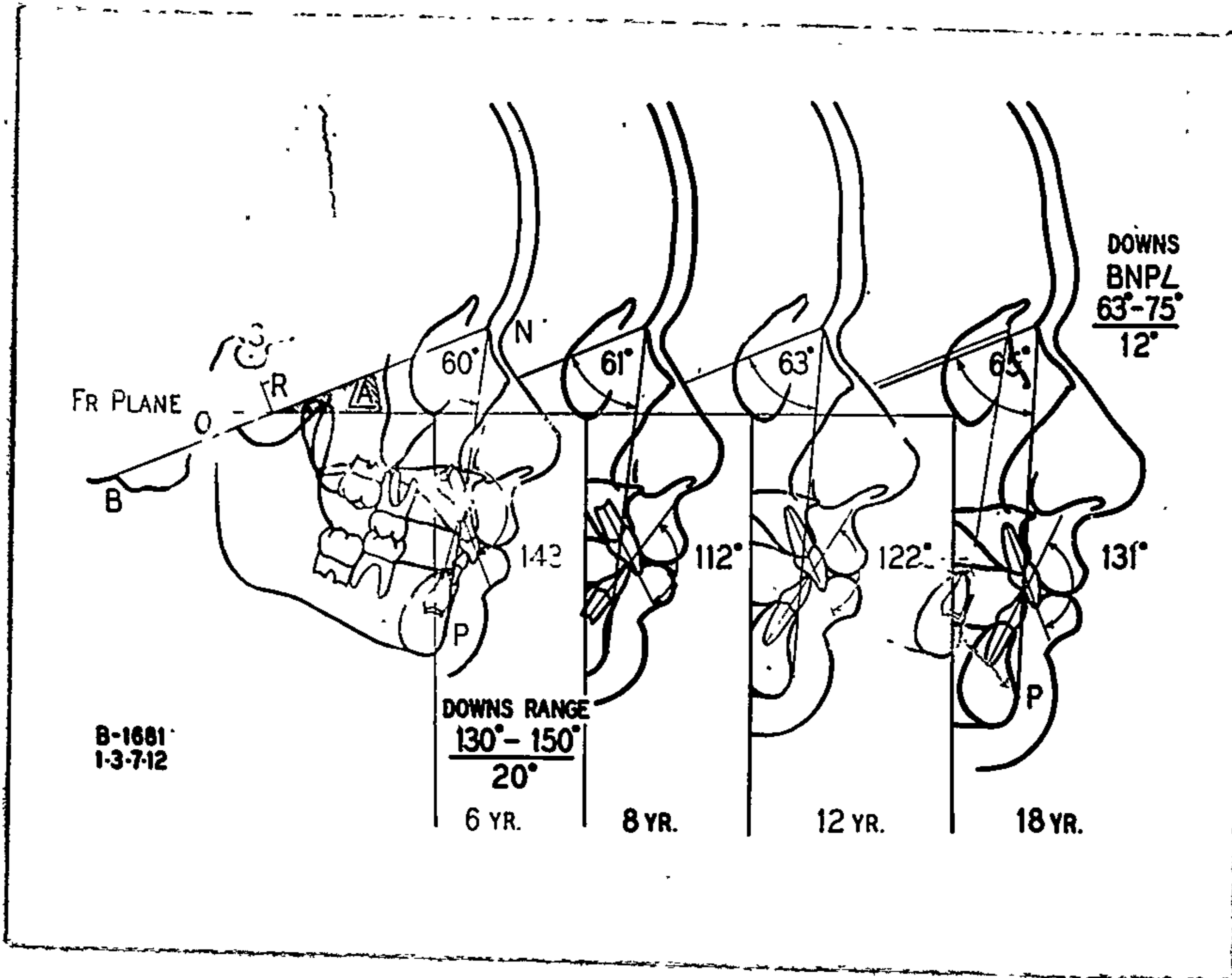
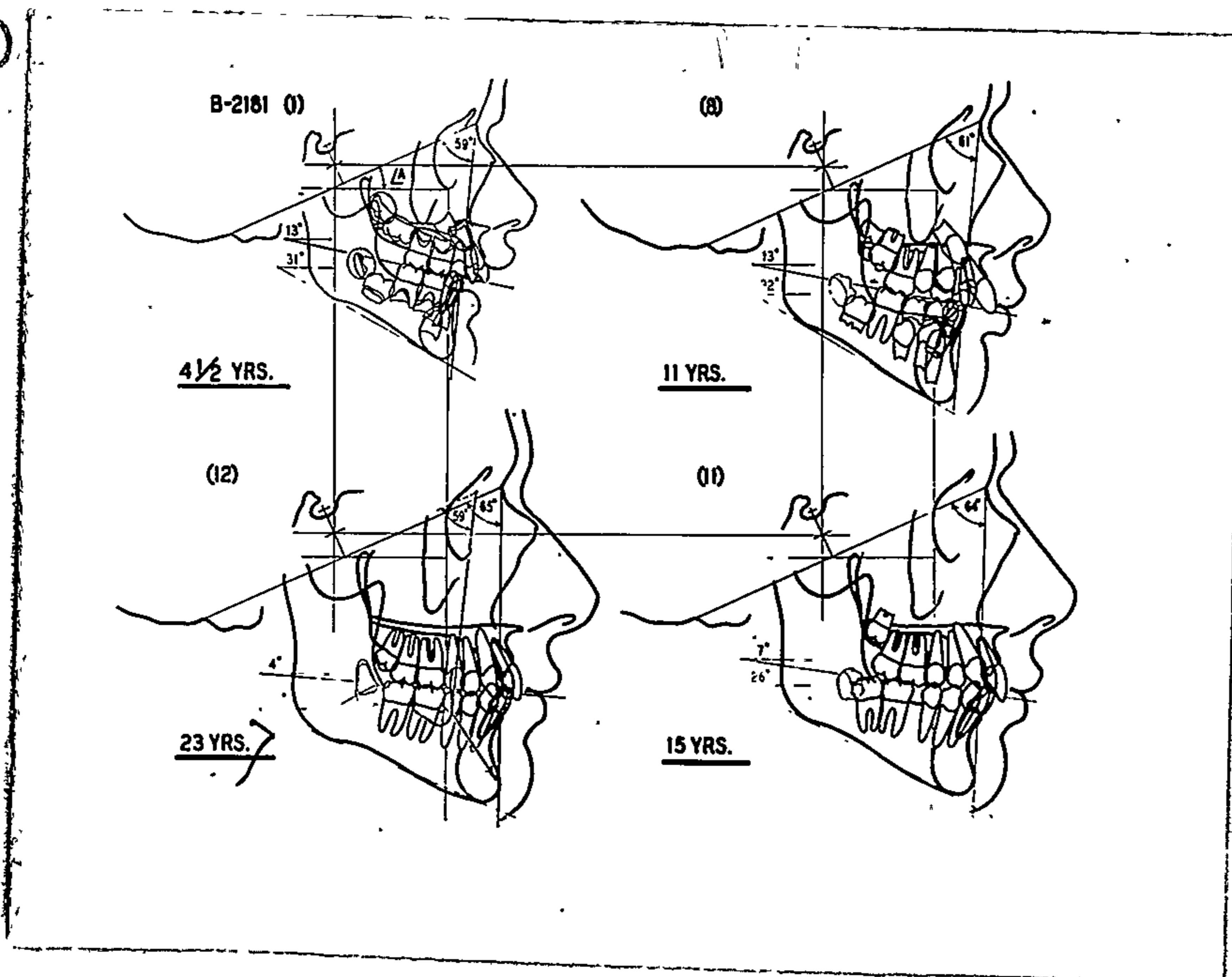


FIG (52)





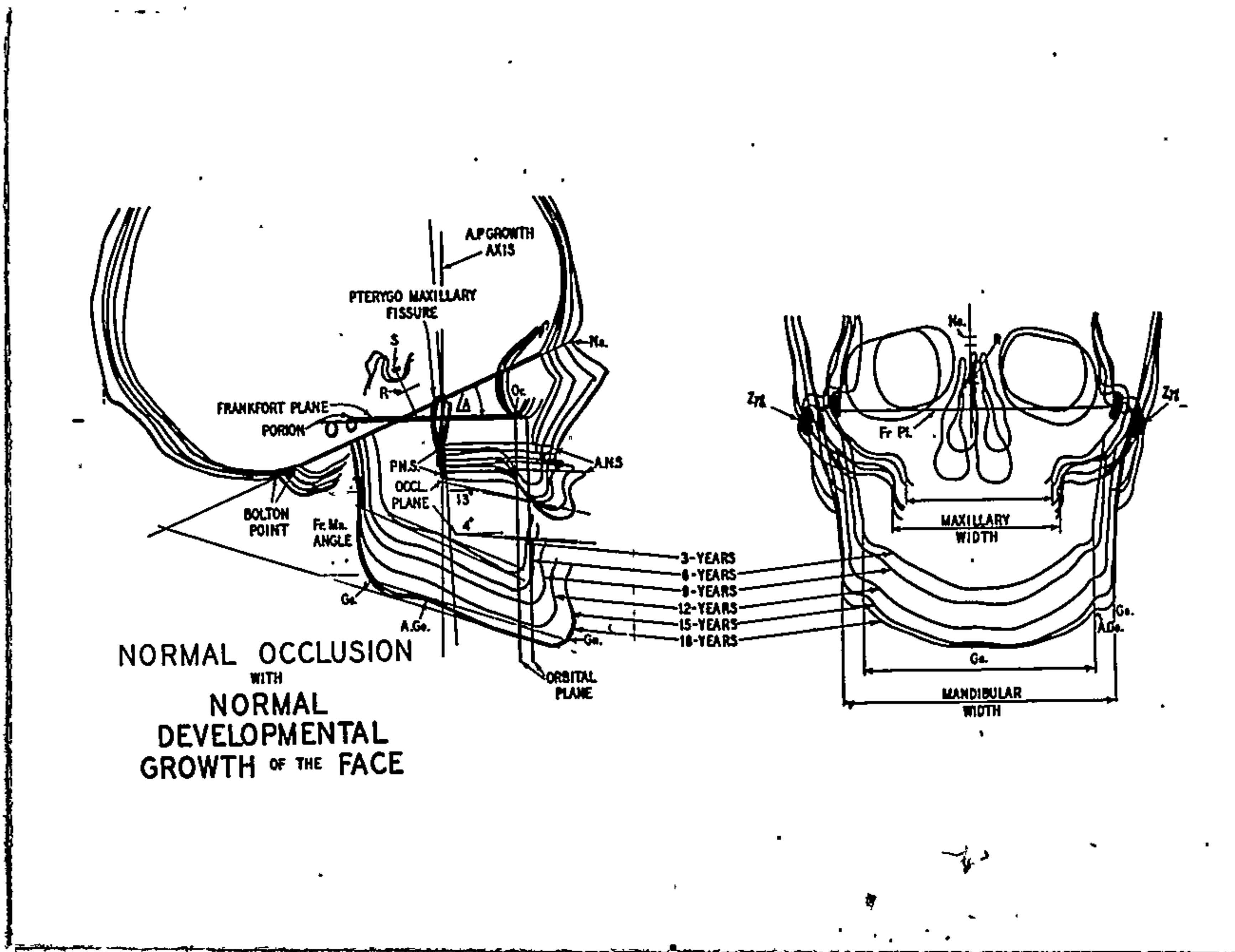


Figure (53)

Normal occlusion with normal developmental growth of the face.

GROWTH STUDY

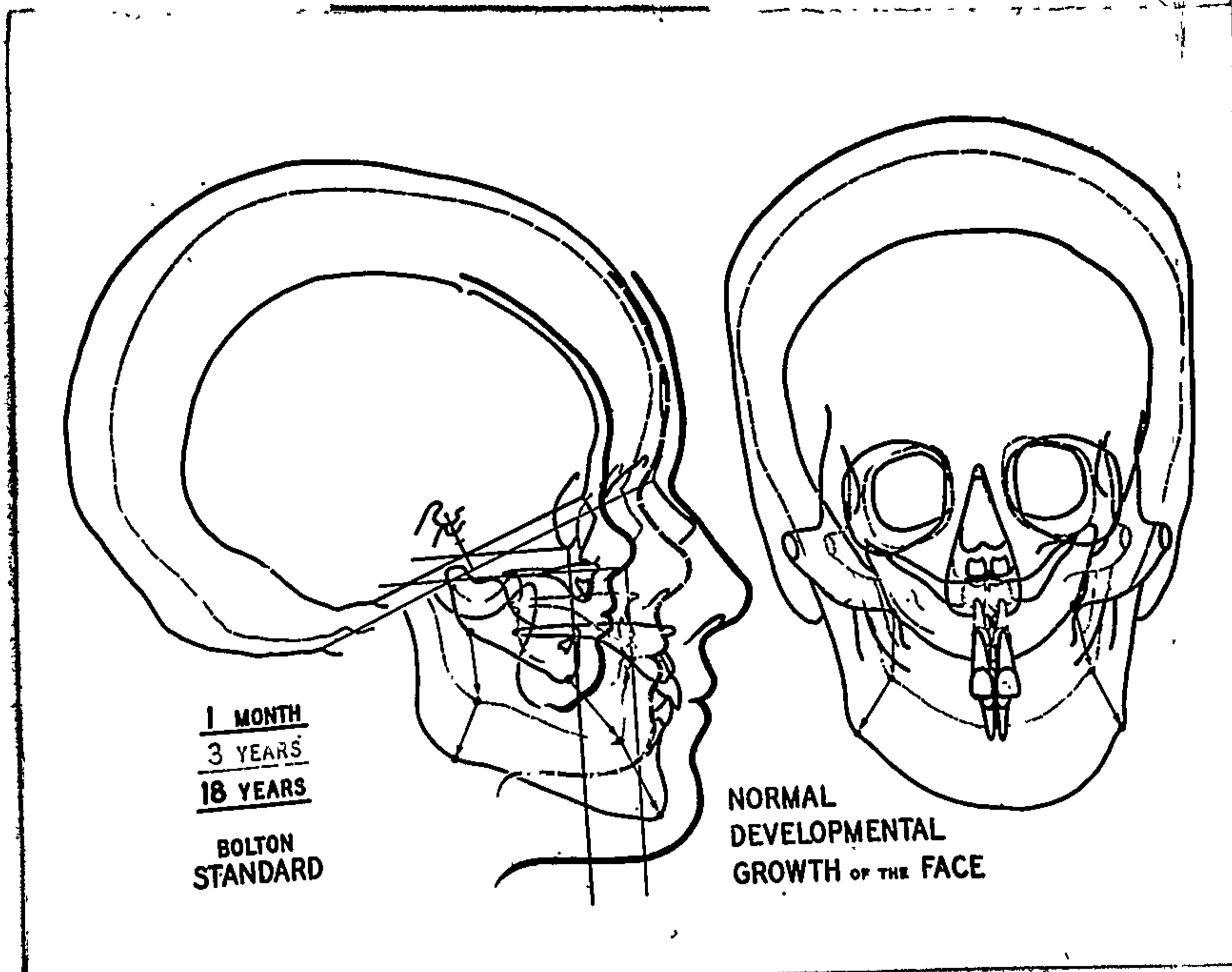
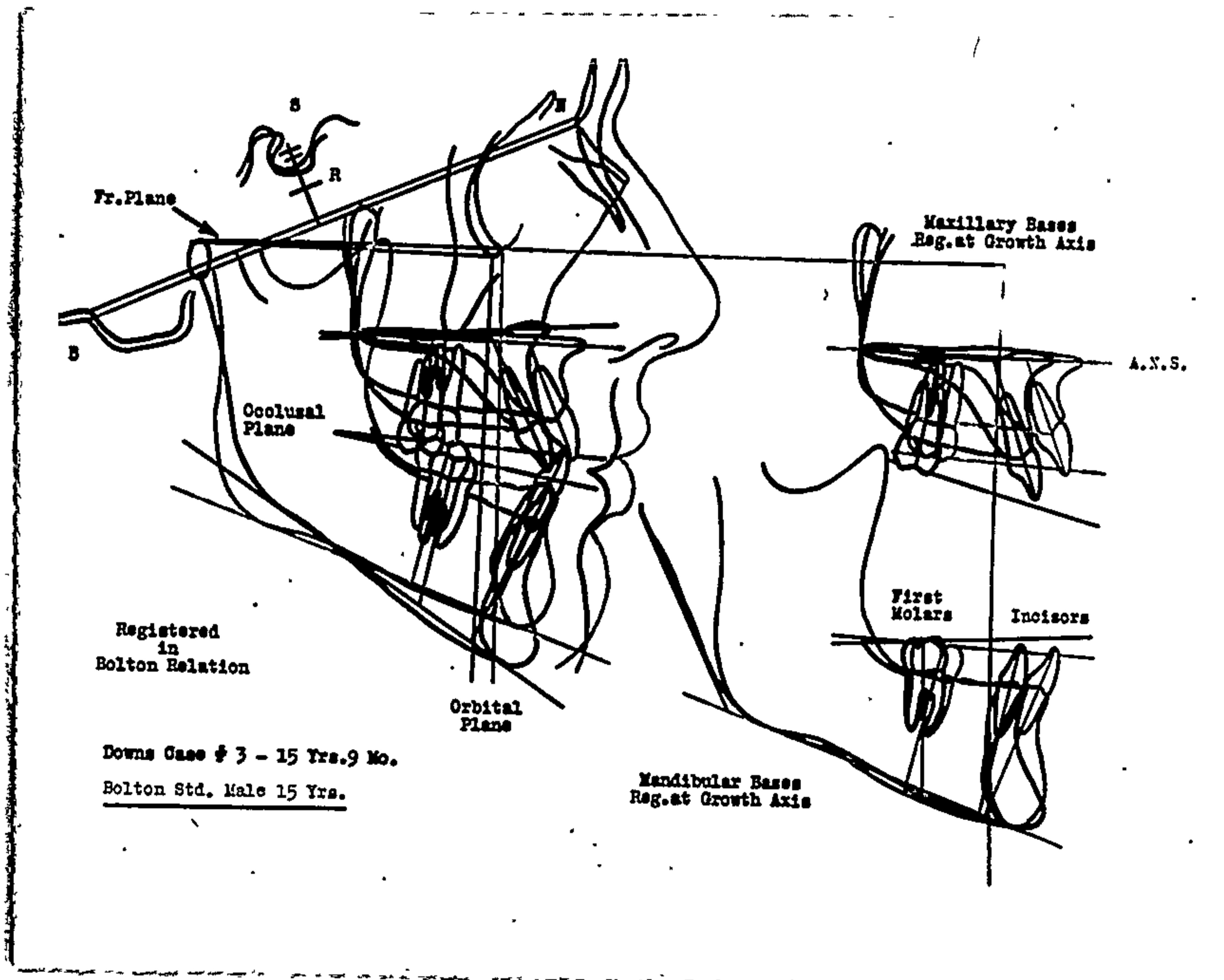


Figure (54)



Figure(55)



GROWTH STUDY

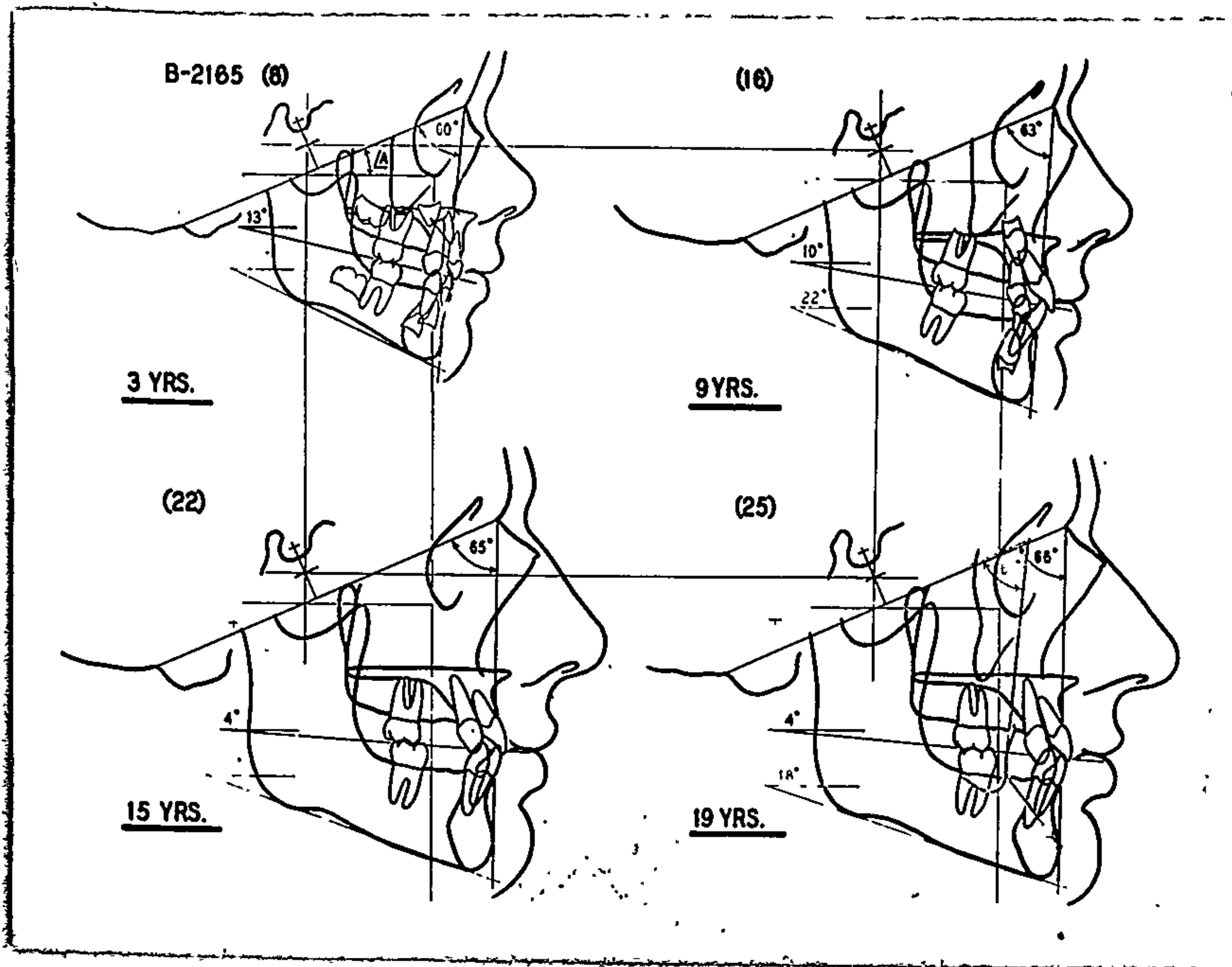


Figure (56)

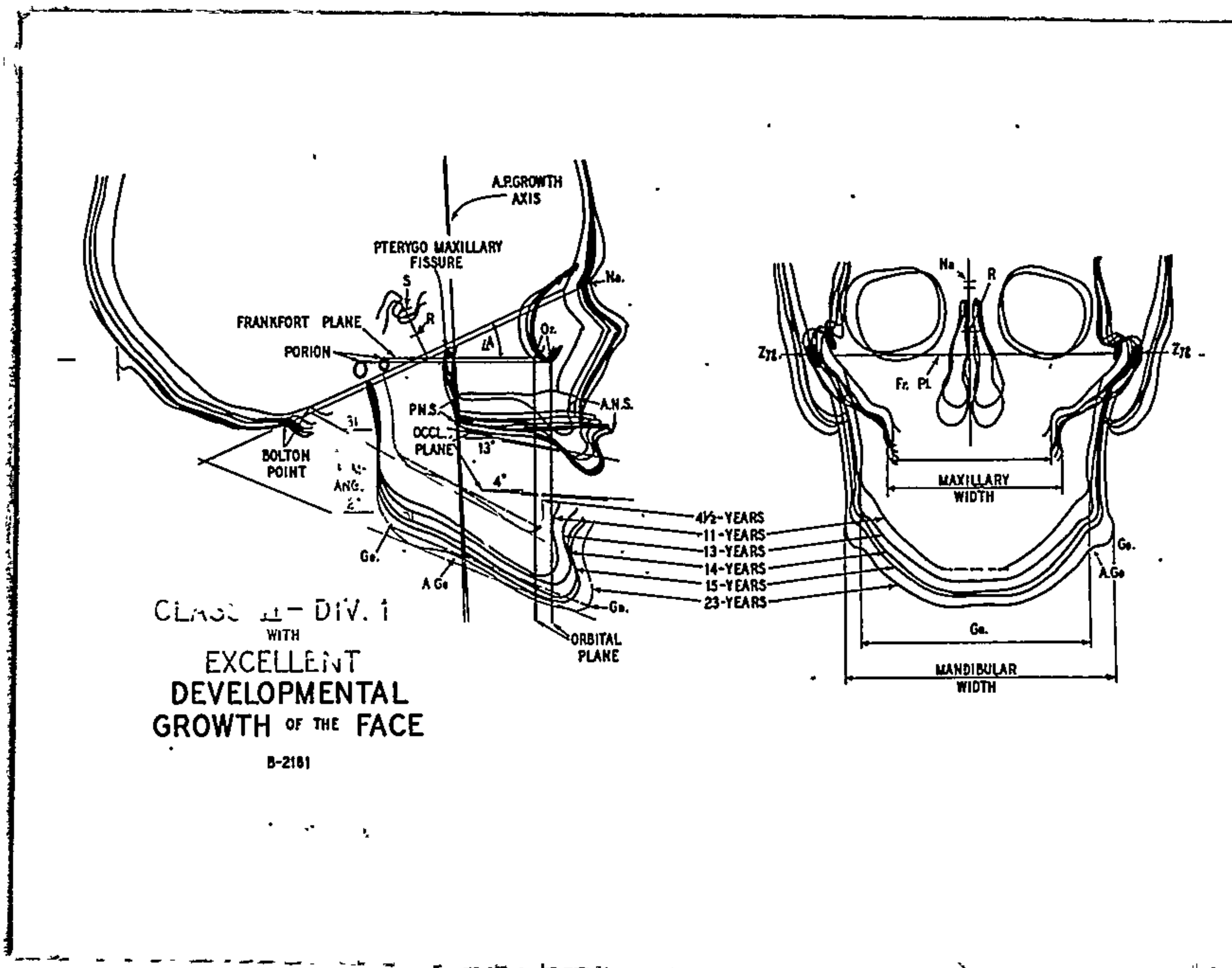


Figure (57)

FACIAL PROFILE DEVELOPMENT

10 days to 15 months.

Recorded from Cleft Palate Bulletin 1954.

FIGURE. (58.)

FACIAL PROFILE DEVELOPMENT.

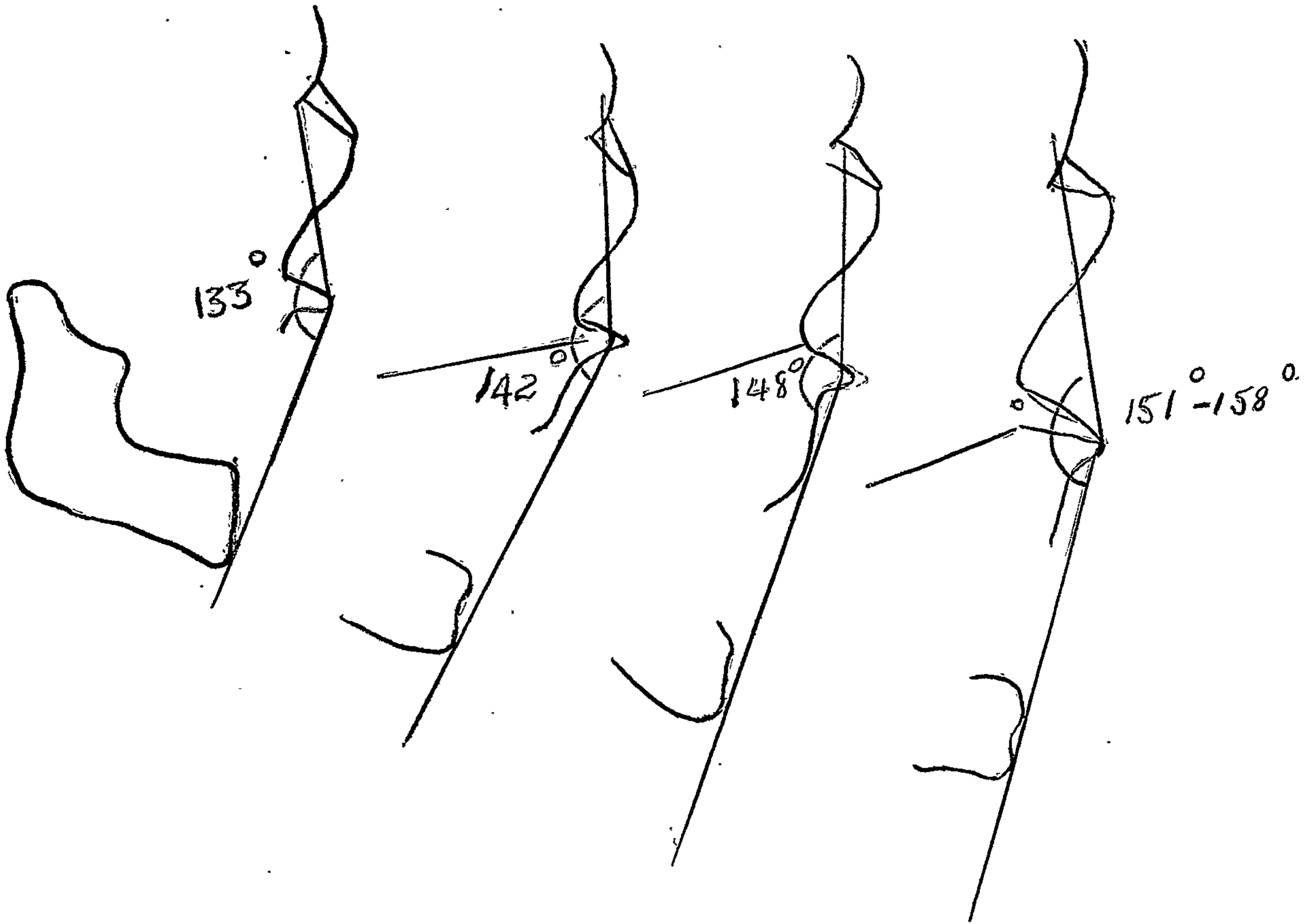
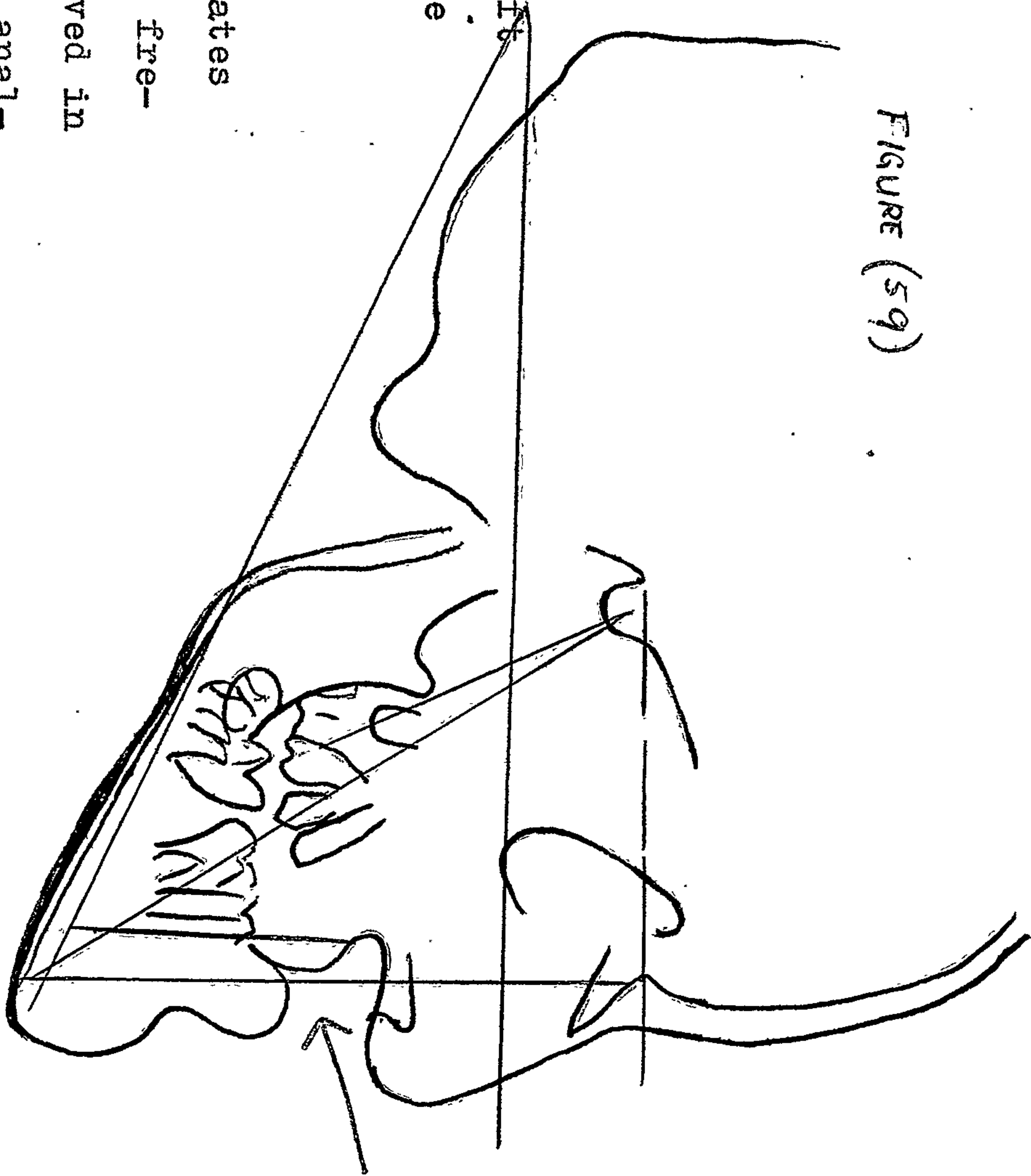




FIGURE (59)



CASE Bilateral Cleft Lip and Palate

Age 6 years.

This Skeleton profile indicates the concavity frequently observed in cephalometric analysis.

Harmony in function is absent after birth, and early treatments aim is to restore harmony so that a full expression of the inherent potentialities for normal growth and development may gain expression.

Abnormal Growth Patterns of Clefts:

34d

Following Broadbent and Brodie, Pruzansky and Richmond  
88  
reported on growth of the mandible in Pierre Robin Syndrome.

This syndrome often displays the cleft palate and is characterized by:

- (i) Hypoplasia of the mandible.
- (ii) Cleft palate.
- (iii) Glossoptosis.
- (iv) In severe cases inspiratory retraction of the sternum, cyanosis or bulging eyes.
- (v) Malnutrition.

The receding chin fails to support the tongue in a normal relationship and hence fosters the glossoptosis impinging the posterior wall of the pharynx.

88

Cephalometry has shown by analysis that the glossoptosis that occurs early may be fatal, but should the early period be survived, adequate mandibular growth occurs to reduce the retrognathic profile and the facial profile is aesthetically satisfactory by the sixth year.

Kennedy and Thompson reported one of the early cases of  
127  
Pierre Robin Syndrome associated with complete cleft palate, and the pathogenesis was explained by Keibe and Mall.

Where respiratory obstruction was not too severe, spontaneous



resolution of the clinical symptoms followed within a few weeks post-partum. Where respiratory obstruction was acute, frequently tracheotomy was employed.

<sup>88</sup>  
Beverley Douglas, to obtain a patent air way, introduced the technique of adhesion of the tongue to the lower lip, providing forward traction of the tongue and establishing an adequate air way.

With continued growth of the mandible, which was proved cephalometrically to occur in the horizontal ramus, resolution <sup>88</sup> of the respiratory obstruction occurred.

Complete cleft palate occurred in a few cases of this Syndrome. This added complication, claims P. Shammbaris, had little effect in one case upon respiration, but marked effect upon the feeding problem and the use of artificial palates did not aid matters due to the small mandible. Regurgitation nasally of milk provided added hazards to vegetative functions.

The growth disturbances observed in normal cleft palate - <sup>34a</sup> cleft lip complexes were:

1. Dental age and eruption occurred earlier in both boys and girls.
2. There appeared in many cases a lag in general growth and in a few cases, failure of growth in restricted skeletal regions.
3. Facial depth in most cases was found retarded, whilst the Porion nasion distance was least affected.

The figures recorded by the Cleft Palate Bulletin, 1956 indicated:

- (a) Head height - less than mean

(b) Head Length - retarded

(c) Head breadth - below mean but only slightly.

4. Pruzansky and others have shown that a positive angle of convexity frequently occurred, but other linear and angular dimensions in cephalometric analysis indicated deficiency in size of the maxilla despite this positive value.

The convexity of the profile was shown to change as indicated in Figure (58).

This merely shows and indicates the expression of the inherent and individual potentials for growth.

Therapy is a matter of freeing the individual from the impediments which block these growth patterns." Pruzansky.

Growth of the cephalo-facial region was studied extensively at the growth centres of North-Western and Philadelphia by means of ecto-oral measurements and endo-oral Roentgenographic cephalometry. This growth was also assessed in relation to skeletal growth and standardizations were made.

Suitable norms were produced from statistical data by <sup>66</sup> Krogman in 1950, using the standard deviation graphs produced by Hellman in 1939. The patients were all measured at specific stages of dental eruption.

These two clinics produced the best available literature for revealing the growth status with special reference to oro-facial cleft anomalies.

Examination of figure (3,4,5) from the Cleft Palate Bulletin 1954 on the Hellman standards, shows that the mean arithmetic averages for any given measurement is represented by a point on



the vertical line, directly opposite the dimension named. Thus a frame results which will demarcate the upper and lower limits of normal dimensionality.

This modified Hellman standard deviation graph indicated in cleft palate lip cases:

- (i) Dental eruption tended to be earlier.
- (ii) Total facial height was long than normal - a component opposite in direction to the findings of Goldstein and Stanton, and other research clinics.
- (iii) A class III malocclusion frequently resulted.
- (iv) Opened bites occurred in a few subjects.
- (v) Facial width was narrow at the Bicondylar and Bizygomatic regions.

The Bicondylar width narrowing suggests slight narrowing of the cranial base and was correlated with a narrowed Bizygomatic and Biparietal width. These observations were first described by Stanton and Goldstein<sup>34a</sup> in 1937.

The Bigonal widths showed a more normal distribution which these observers suggested is due to there being less influence upon these structures and the existance of the opposing pull of the masseter muscles.

They recorded that at birth there was a marked increase in the nasal breadth and palatal width in the cleft palate-cleft lip child compared to normal. These facts were first realised and recorded by Brophy in 1923 and Peyton in 1934, Brophy indeed, based his contraction surgery upon these features.

The standard deviation graphs of other clinics with cleft

lip-cleft palate cases indicated also failure in growth of facial depth, substantiating Pruzansky's observations. This, with the lesser disturbance in cranial base length as reflected by the Porion-nasion distance, indicated that the primary or early embryonic development of the brain and its cartilaginous base in the growth of the head approximated closer to normal than did retarded facial structures. The article states:

"Fundamentally this antecedent is but an example of the cephalocaudal gradient field of differentiation and growth within which a child's midline axial gradient is dominant."

Mandibular growth associated with cleft palate and/or cleft lip cases was observed by many workers, Brodie, Pruzansky, and others. Their observations, in association with our own at the Royal Alexandra Clinic for cleft palate and lip cases, indicated that the mandibular ramus is skewed towards deficiency of height and the condylar-gnathion depth is deficient accordingly. Measurements of the head in the mid Sagittal plane provide similar recording to those quoted previously for head length, height, and breadth.

It was observed that the cranial base which ossifies from cartilage and grows more slowly in response to functional growth stimuli, was the least affected in width.

Subnormal stature is possibly an expression of this adverse condition, and was found to exist with other hereditary anomalies such as Brachyphalangy, cleido-cranial dysostosis and Darier's disease, as recorded by Thoma.

Most clinical results confirm the impression that cleft lip



or cleft palate in children represents generalised growth failure. This undoubtedly depends upon the hereditary potential for growth and overall health of the individual child. This reduction in speed of the statural growth might be wholly or partly compensated for by prolongation of the growing period.<sup>34a</sup>

Standard cephalometry of selected material has to date indicated in cleft cases that:

1. Face height:

The nasal height component is slightly decreased. This was first observed by Brodie in 1941. This produces a tendency to nasal shortness and may have an important bearing to the surgeon and otolaryngologist.

2. The angle of convexity:

5.1 for boys.

9.4 for girls.

34a.55

These observations were opposite to those of Graber and the position is not as yet clarified, as although a positive value is recorded, deficiency in maxillary growth is recorded frequently in the literature and clinical examinations show this feature at times quite severely in Bilateral cases - most of the dysplasia as claimed by Wylie in 1948 occurring mesially to the first molar as illustrated in the profile views illustrated. Figure No. (59 )

3. There is indication in the ecto-oral distance (Porion to nasion) that the cranial base is less retarded in arterio-posterior growth than is the facial skeleton.

<sup>34</sup>  
Peyton in 1934 found by examination of fifty cleft palate infants and ninety-one normal children that the maxillary alveolar process was significantly short.

4. Evidence indicated mandibular under-development is reflected in ramal height deficiency rather than body length, and produces the large angle at the Frankfurth mandibular plane angle.

Analyses of the clinical cases and the literature indicated that the female mandible was more heavily handicapped. Sicher,<sup>34</sup> Weimman, Brodie, and Graber declare there is a tendency towards deficient ramal height which results essentially from disturbance in the growth of the metaphysical-epiphyseal cartilage bone structures.

5. Considerable distal tipping of the lower incisors was noticed,<sup>32.34</sup> being less severe in girls. Slaughter and Brodie claim that this was due to the taut band-like orbicularis oris. Figure No. (33) which aggravated under-developement of the jaws and distal tipping of the incisors.

The general retardation in cephalo-facial growth amongst cleft lip-palate complexes becomes more obvious as cephalometric analysis is compared to normal growth gradients.

In the present study clinically, middle facial height was found to be the component affected mostly in total facial height (Figure No. (59,69)).

Graber in 1949 claimed that the maxillary component of facial height in this condition is the retarded segment, and little has been written since to devaluate this statement (Fig. (59,69),(77,88a)

89

6. By comparison of models, Pruzansky showed that continual growth of the palate and development of the alveolar processes further increased the overlap and accentuated the containment



of the smaller segments within the larger in unilateral cases.

89

Pruzansky wrote:

"Constriction of the maxillary arch is the result of physiological consequences of muscle forces acting across an unbuttressed palatal arch."

Any derangement in the architecture of the palatal vault must be reflected also within the nasal cavity, at birth the medial and upward tilt of the palatal process can be seen on the side of the cleft palate, thus the floor of the nose is elevated and the height of the nasal chamber reduced. (Figure (65)).

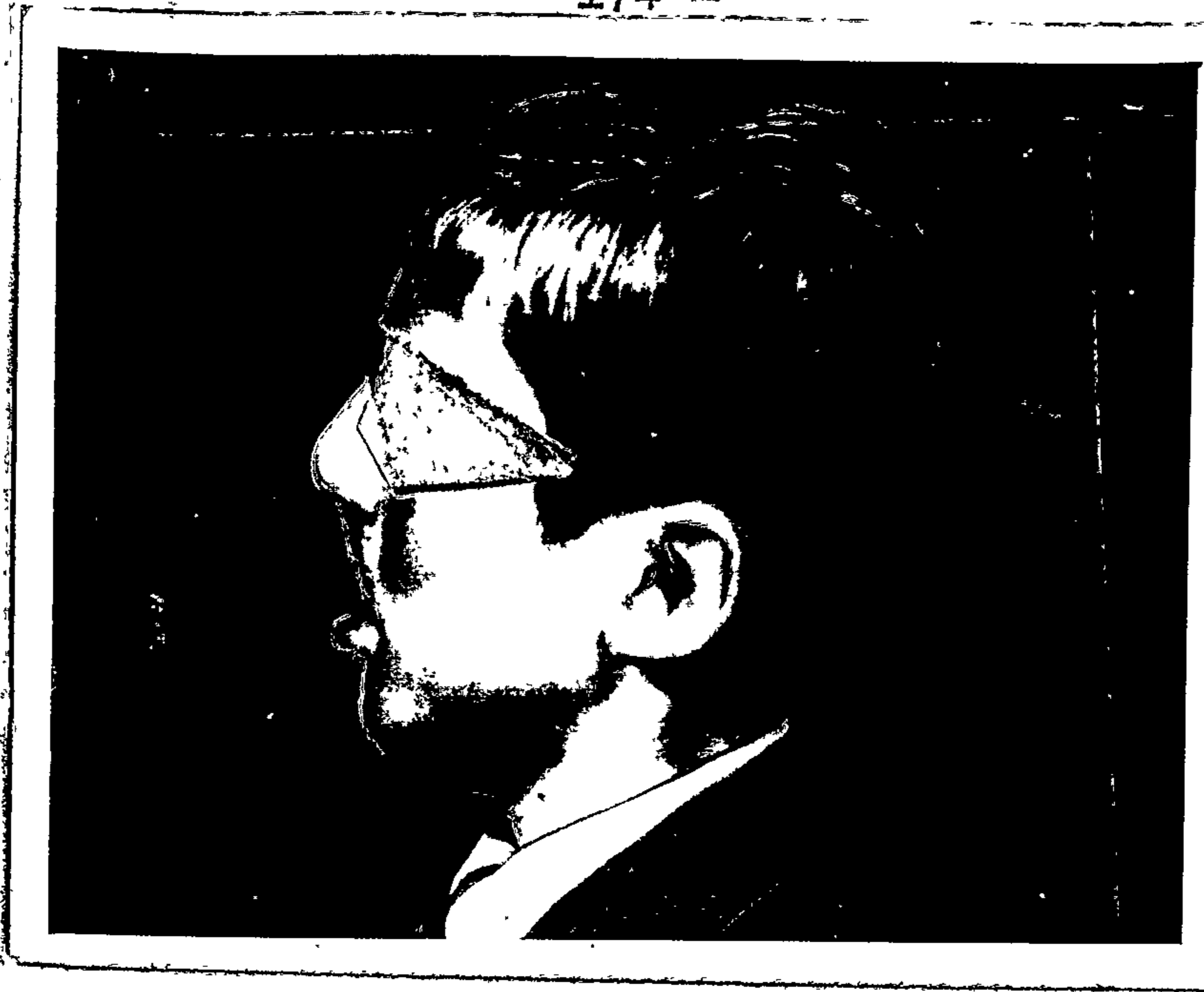

Figure (60)

Profile photograph of a Bilateral cleft lip and cleft palate illustrating the common existing lack of growth in the premaxillary and maxillary elements.

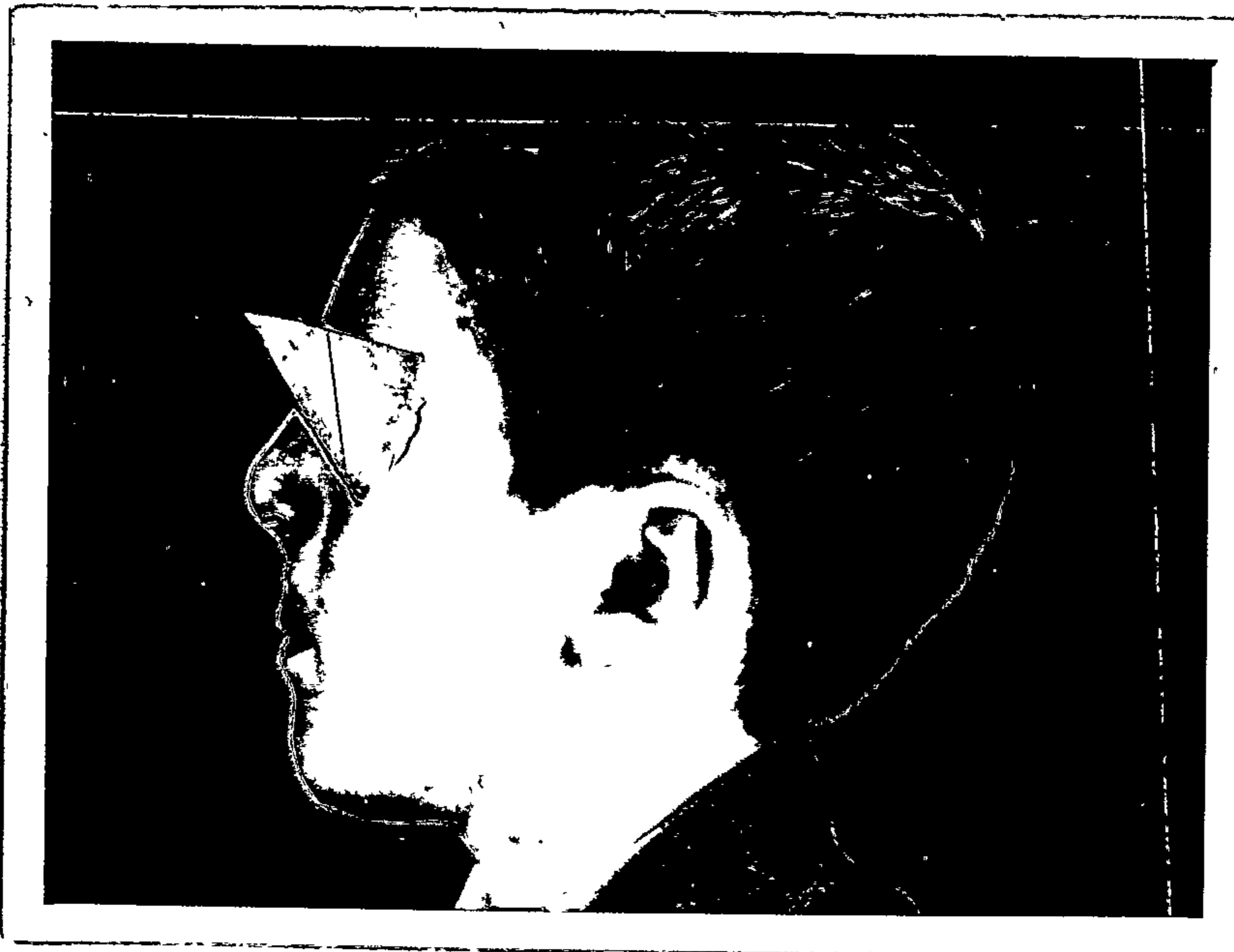

Fig (61)

Same case showing the restoration of the normal profile by aid of a prosthesis.





Figure (62)

Photograph of previous case (anterior view). This clearly illustrates the long upper lip that resulted from the single Y surgical procedure, and its protruding comparison lower lip. This upper lip may be widened by an Abbe-Eslander or "V" switch operation, and the following photograph illustrates the increase in cosmesis and lip form that follows such a procedure.



FIG (63)

TYPE OF  
This photograph illustrates the improved appearance, function,  
and width of the maxillary lip following Abbe-Eslander operation  
("V" switch.)



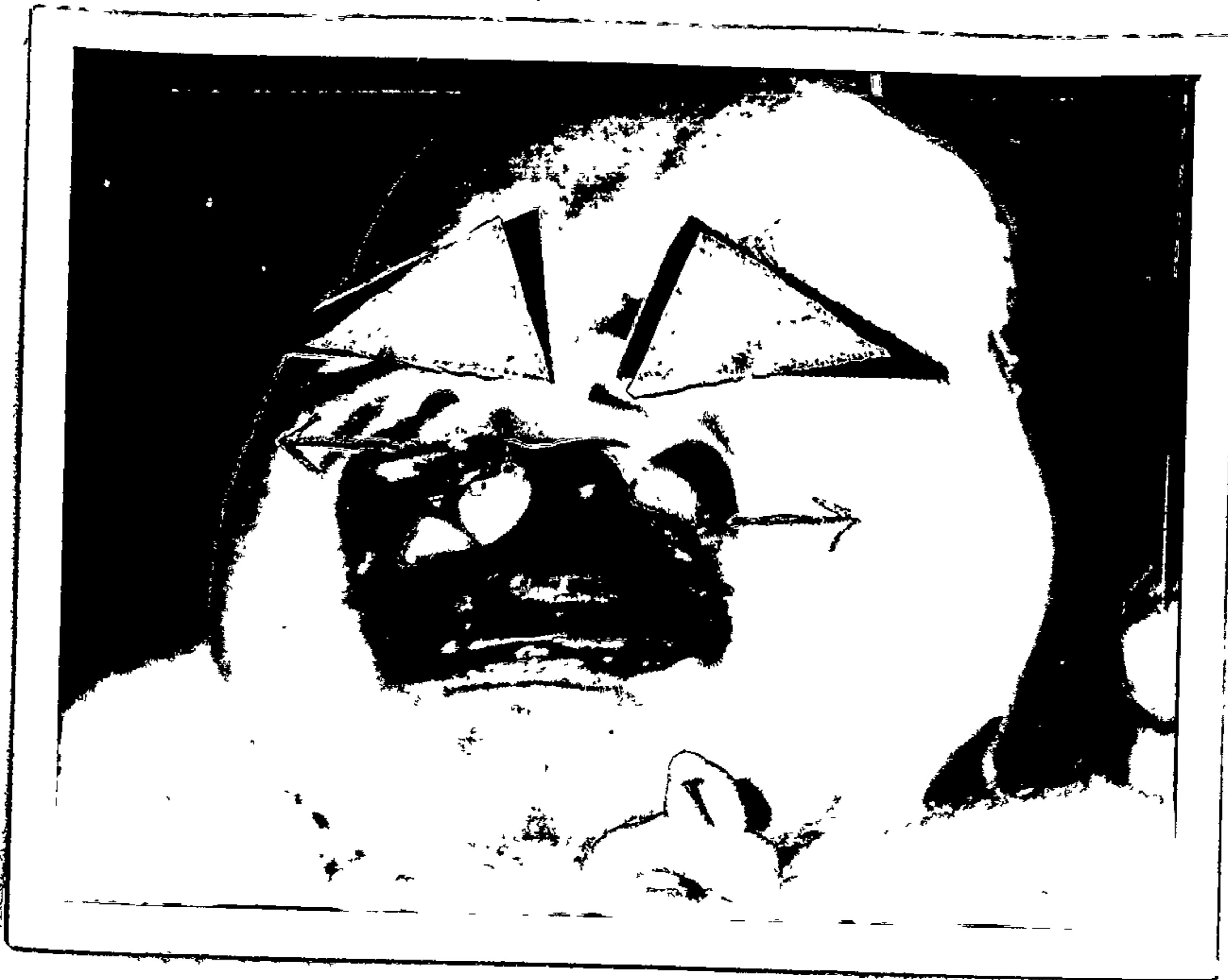

Figure (64)

Illustrating flaring of the premaxillae associated with rotation, due to the wide cleft formation.

The two segments of the orbicularis oris are pulling in opposite directions, accentuating this condition and flattening the ala of the nostril on the affected side.

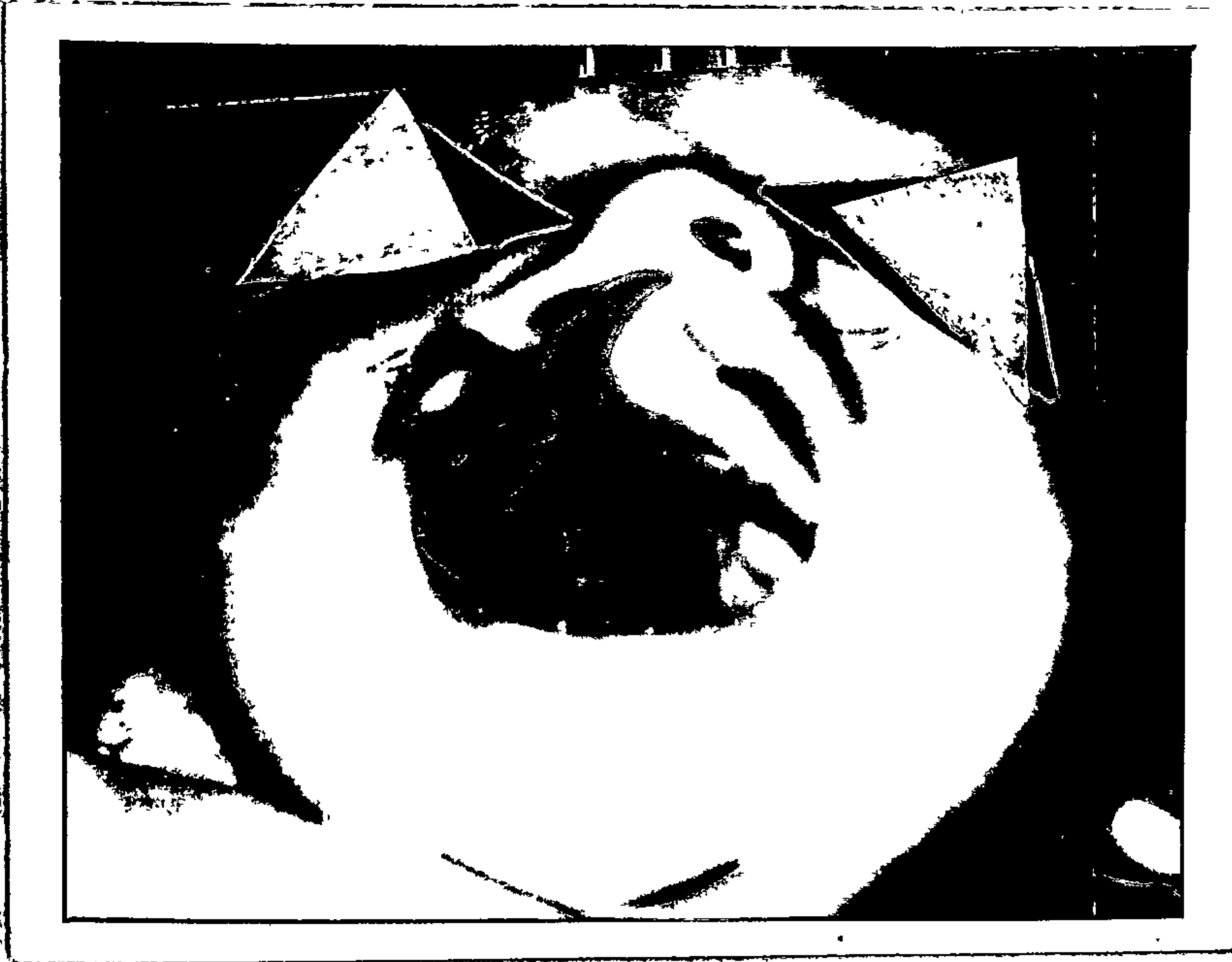

Figure (65)

Illustrating similar condition to Figure (64) preceding.

Typically showing the flaring premaxillary element and indicating the oro-nasal communication.



CONCLUSION ON GROWTH.

34a.42.59

89

Cloys, Harkins, and Pruzansky, with whom we are in full agreement state:

"Cleft palate individuals as a group show deficient patterns of maxillary growth laterally, antero posteriorly, and vertically."

Early traumatic surgery results in greatest deformity, there being a positive correlation between the number of operations, the amount of scar tissue, and the degree of insult to the tissues. To minimise interference with growth centres, it seems advisable to postpone surgical correction of the palate, at least until the end of the fourth year of life, when five sixths of the total maxillary width has been accomplished.

However, downward and forward growth, which depends primarily on the speno-occipital synchondrosis and sutural activity continues until 20 years.

It often appears that the surgically repaired palate grows more slowly than the surrounding tissue. This results in increasing functional difficulty and ultimate structural inadequacy. Patients whose cleft has not been manipulated surgically show a pattern of maxillary growth that is essentially normal.

90a

34a

These views were stated also by Grabner.

CHAPTER V.

CLINICAL APPEARANCE, ARCH FORM & MALOCCLUSIONS

RESULTING FROM CLEFT LIP AND/OR CLEFT PALATE, WITH TREATMENT.

Introduction:

Three years ago the first series of articles appeared from the research unit studies at the cleft palate centre at the University of Illinois. Their purpose was to establish a basis for discussion of this subject. Since that day many patterns have evolved on treatment of the resulting malocclusions.

The problem is frequently an oral orthopaedic orthodontic one, and orthodontic therapy has been based upon structural, functional, and psychological needs of the individual patient.

The fact that the malocclusion is often the result of collapse following surgery of the palate has already been quoted.

Before closure of the lip in a unilateral cleft lip and palate, the segment of the alveolar process mesial to the cleft of the premaxillary element projects labially, and is rotated towards the direction of muscle pull which arises from the non cleft portion of the upper lip. Figures (4, 64).

As stated previously in chapters (4<sup>+</sup>5 PART I) surgical repair either bilaterally or unilaterally, restores the Orbicularis Oris continuity and changes the vector of muscle pull, which prior to surgery pulled the bones apart. The palatal segments are then brought into close approximation and surgery upon the palate further accentuates this picture.

The clinical forms have orthodontically and surgically been divided into the following types:



Type 1.

Clefts of the lip which may involve the alveolus only

Clinical appearance and arch-form:

This state may occur in all degrees from simple notching to complete cleft either unilaterally or bilaterally. Bilateral cleft occurs usually associated with cleft of the soft and hard palates. Unilateral cleft of the lip may or may not be associated with a palatal condition. This section deals only with that reserved for the abnormal lip and alveolus.

The complete cleft extends to the floor of the nostril on the affected side and involves complete cleft of the alveolar process. This is possibly one of the simplest clefts that may occur in this sequence. The incomplete cleft may extend in varying degrees from the vermillion to the nostril floor. At birth Simonants bands, remnants of embryological development, may connect the ala of the nostril to the median line. However, the nostril is flared and flattened. Figure (19).

Surgical procedure may reduce the flaring, but quite frequently the cartilage remains slightly distorted, but in most cases the results are excellent. The degree of alveolar involvement is usually proportioned to the lip cleft, and all grades are presented clinically.

Where the disturbance occurs in the lip and alveolar process, no effect is reflected in the width of the palate. There may, however, be a disturbance in the teeth; the lateral incisor is the most frequently affected tooth, and may be missing, displaced, unerupted, distorted, impacted, notched, or may be situated in

soft tissue with little or no bony support in both the deciduous and permanent dentition. In most cases bony and soft tissue support exists.

The segments of the alveolar process are designated the names, premaxillary and maxillary, abutment segments, and are not usually in a complete continuous phase. The forces of the divided orbicularis oris are working in opposite directions up until the time of surgical repair:

Figure ( 19 ); since the palate is completely buttressed, the muscular effects are little shown. Surgical repair provides further moulding of these tissues, and at an early age little abnormality is visible outside a slight notching of the alveolus.

#### Malocclusion:

There is no change in arch form and the malocclusion is mainly confined to the teeth on the side of the cleft, the central and lateral incisors, and canine. Some cases may show no disturbance of the teeth, even and although notching has occurred in the alveolar process.

The central deciduous incisor may be rotated, as may be the canine, and the deciduous lateral may be rotated, misplaced, or missing.

In the permanent dentition, similar circumstances may exist and orthodontia is confined to restoring the maxillary arch to normal form.

It may be necessary in the permanent dentition of an adult to provide for replacement of the lateral incisor by a bridge or prosthesis. Several models for study should be taken to record



progress and roentgenology will establish the degree of bony supporting tissue for the lateral incisor. Where soft tissue support may exist only for the permanent incisor, it should be extracted and replaced by a prosthesis, but in most of these cases, normal occlusion with a full dental arch and normal arch form results. Simple cleft lip and alveolus have a favourable prognosis.

The occlusion may be associated with a malocclusion resulting from abnormal habits, or due to inherited or environmental factors, providing an associated Angle Class I, II, or III malocclusion.

It is the mode to-day to commence orthodontic treatment as early as practicable, usually  $3\frac{1}{2}$  to 4 years, just as soon as the child is capable of understanding and has some degree of co-operation.

Type 2.

Unilateral Cleft of the Lip and alveolus association

with complete cleft of the hard and soft palates

This anomaly and variations occur quite frequently, occurring mostly on the left side.

The appearance of the condition before and after surgery is indicated in Figures Nos. (2,3,4) AND (5,6)

With growth and development it is possible to maintain a normal width in the palate so long as surgery is delayed until the third or fourth year. Should palatal surgery be completed before three to four years, the changes in the palatal width, i.e. collapse, illustrated in Figures Nos. (490, 660b) occur. (71, 72, 73.)

The cleft extends from the lip through the alveolus, and soft and hard palates. In most cases it is complete, but all grades may occur to that of cleft lip and cleft hard and soft palates, with the alveolus intact, with little change in the maxillary arch. Surgery usually restores anatomical continuity but oro-nasal communications may result. The restoration of the Orbicularis Oris soon results in remodelling of the premaxillary and maxillary abutment segments.

At birth, examination of the palate indicates that the vomer and nasal septum is reflected to the non cleft side. At examination it is possible to view the anatomy of the nasal passage from the palate as exhibited in Figures Nos. (64, 65 ).

Following repair of the lip of forty cases examined, the majority exhibited approximation of the premaxillary and maxillary alveolar arches, whilst four exhibited some degree of overlapping of these segments.



Models, photographs, and Roentgenograms studied over the last few years indicate that in many cases an asymmetrical arch results and the small maxillary segment appears to be rotated medially and slightly elevated, as may be witnessed in a study of the included photographs.

<sup>89</sup>  
Samuel Pruzansky wrote of similar appearances in his group study.

Subsequent casts revealed (Figures <sup>71, 72</sup> 73, 77) that continued growth of the palate and development of the alveolar process further increased the overlapping and accentuated the containment of the smaller segments within the larger. This fact was observed in nearly every surgically treated case studied. However where surgery had been delayed or not attempted, as was well exhibited in one clinically examined child, little or no collapse occurred, and the inter-canine width was normal or nearly so.

The six year molars are frequently in a normal occlusion, but at the side of the cleft, rotation along the longitudinal axis occurs. This may be witnessed by examining the casts and photographs included.

As previously stated the lateral incisor is frequently misplaced, missing, or unerupted, and may even occupy the floor of the nostril horizontally (Figure ( 77. ).

This collapse and fall in inter-canine width will frequently place the deciduous lateral, canine, and first molar into a cross bite relation.

The second deciduous molar may also occupy a similar position.

Orthodontic therapy in the deciduous dentition of expansion and restoration of nearly normal occlusion will favour the eruption of the permanent teeth into a normal position. This expansion as early as possible is important, not just for teeth alone.

As the reduction in width is unilateral, the reduction of the nasal floor width occurs correspondingly. This reduced width and collapse may introduce blockage of the nostrils, which will limit respiration, and invite mouth breathing. This reduced respiration provides reduced function and stimulation of the nasal mucosa, a predisposing factor to congestion, oedema and chronic infection. Respiration and function is also a stimulus to growth in this region, as is clearly exhibited in the adenoidal facies <sup>10</sup> group where lack of respiration occurs.

This orthopaedic movement of expansion in these cases must be instituted as early as possible, as a widened palate means a widened nasal floor.

It is quite sensible to extract a malposed supernumery tooth rather than restore it to the arch, so long as it is done as early in treatment as possible.



Aim of Treatment: To restore a normal occlusion.

Treatment:

For an anterior cross bite relationship, an inclined plane will often restore the normal incisor overject-overbite relation, but fixed appliance therapy provides greater control, movement being quite rapid and retention frequently not required.

Samuel Pruzansky showed by cephalometry that such movement labially of the incisor is a downward and forward movement in relation to the anterior cranial base. Essentially what the bite plane accomplished is to produce labial torque upon the premaxilla, with repositioning of the teeth and bone, elevating its nasal surface and protruding its' labial aspect.

This is virtually restoring normal growth potential for Downs, Brodie, Ballard and others claimed that the floor of the nose forms in a forward and downward direction in relation to the anterior cranial base.

However, clinically in some cases examined, movement labially of the incisors was witnessed, independent of premaxillary bone movement.

The forward movement of the premaxillary bone was observed in clinical examinations. A degree of improvement in aesthetics was noticed in the region of the cleft and sub orbital region in facial pattern and outline.

Where the unilateral collapse occurs, fixed labial arch therapy may be instituted with expansion, often over-compensating the defect. As the molar width is little changed except for rotation on the cleft side of the molar, most of the expansion

occurs at the inter-canine width. Samuel Pruzansky, by frontal  
89.90  
laminography, showed this to be mostly orthopaedic movement. The  
movement is not as rapid as in bilateral cases, and clinical  
results indicate the cicatricial tissue when gross, may hinder  
this movement.

The palatal repair usually provides a palate that is  
reasonably mobile and functioning. This is little or not at  
all affected by orthodontic movement. The arch used is usually  
the round arch wire .018" or .022".

Edgewise arch was used in some clinics, but as the movements  
are often rotational, the round arch gives greater freedom and ease  
of manipulation.

For rotation of an individual tooth, double brackets may  
be required. Edgewise arch is very good for horizontal movement  
of teeth.

The results are quite good in unilateral cases. Usually  
the lateral incisor is missing on the side of the cleft and requires  
restoration by means of a "bridge" or a partial prosthesis in the  
permanent dentition. The arch form and occlusion may be practically  
restored to that of a balanced occlusion.

Treatment is commenced in the deciduous dentition and  
expansion obtained. This may take from six weeks to six months.

This occlusion is then maintained by a retainer. Frequently  
by over-expansion the slight degree of collapse that follows allows  
a normal occlusion to result.

During the mixed dentition, the permanent teeth may erupt in  
abnormal position.



Treatment (usually necessary) should be reapplied during this period and the arch reformed.

The eruption of the permanent premolar and canines and second molars completes the dentition. By this stage, usually the arch form is normal, but at times lingual eruption of teeth occurs, or crowding, and a third period of active treatment may have to be initiated.

Removable appliances do not function as well in these cases. A prosthesis may be utilized for a period where edentulous conditions occur in a child whilst awaiting eruption of teeth.

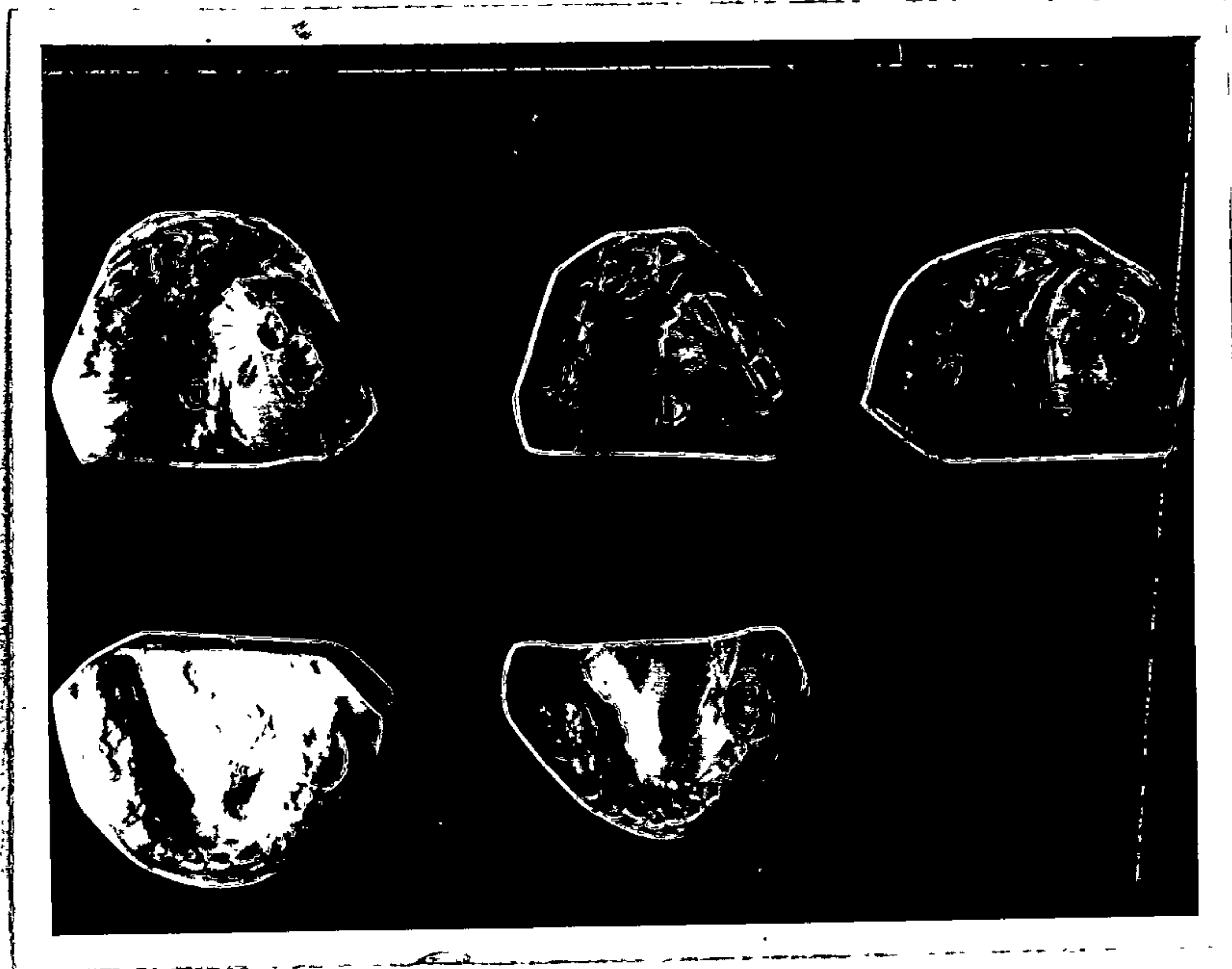


Figure (66)

This series of casts displays the disturbed arch form of the maxillae in unilateral cleft lip and palate. The lip and palatal repairs in all cases were conducted at a fairly early age.

Series a: is that of a maxillary and mandibular cast. The

mandible or model shows little change in arch form whilst the maxillary model displays the following features:

1. oro-nasal communication.
2. Cleft alveolus.
3. Slight cicatrical tissue.
4. Collapse of the left maxillary segment inside the larger right premaxillary element.
5. Rotation of the left central incisor and to a slight degree of the premaxilla.
6. The fall in inter-canine width.
7. The rotation of the upper left six year molar, but little change in the width of the palate between the molars.
8. Absence of the lateral incisor.

Figures (B) & (C) are similar casts recorded at an earlier age.

(b) illustrates less degree of collapse than (a) and the arch form in cast (c) is nearly normal in outline, except for the cleft area and missing deciduous lateral incisor. Even at this stage the rotation of the left deciduous central is present and the inter-canine width shows a slight decrease.

Reference is made here to Figure (48) a, b. & e., illustrating moulding of the arch <sup>AFTER</sup> ~~at~~ birth, before surgery of the palate has been instituted. This shows the normal width of the palate in most areas, even in the presence of a marked cleft, and comparison with the sequence of Figure (66) illustrates the change in arch form with growth and development.



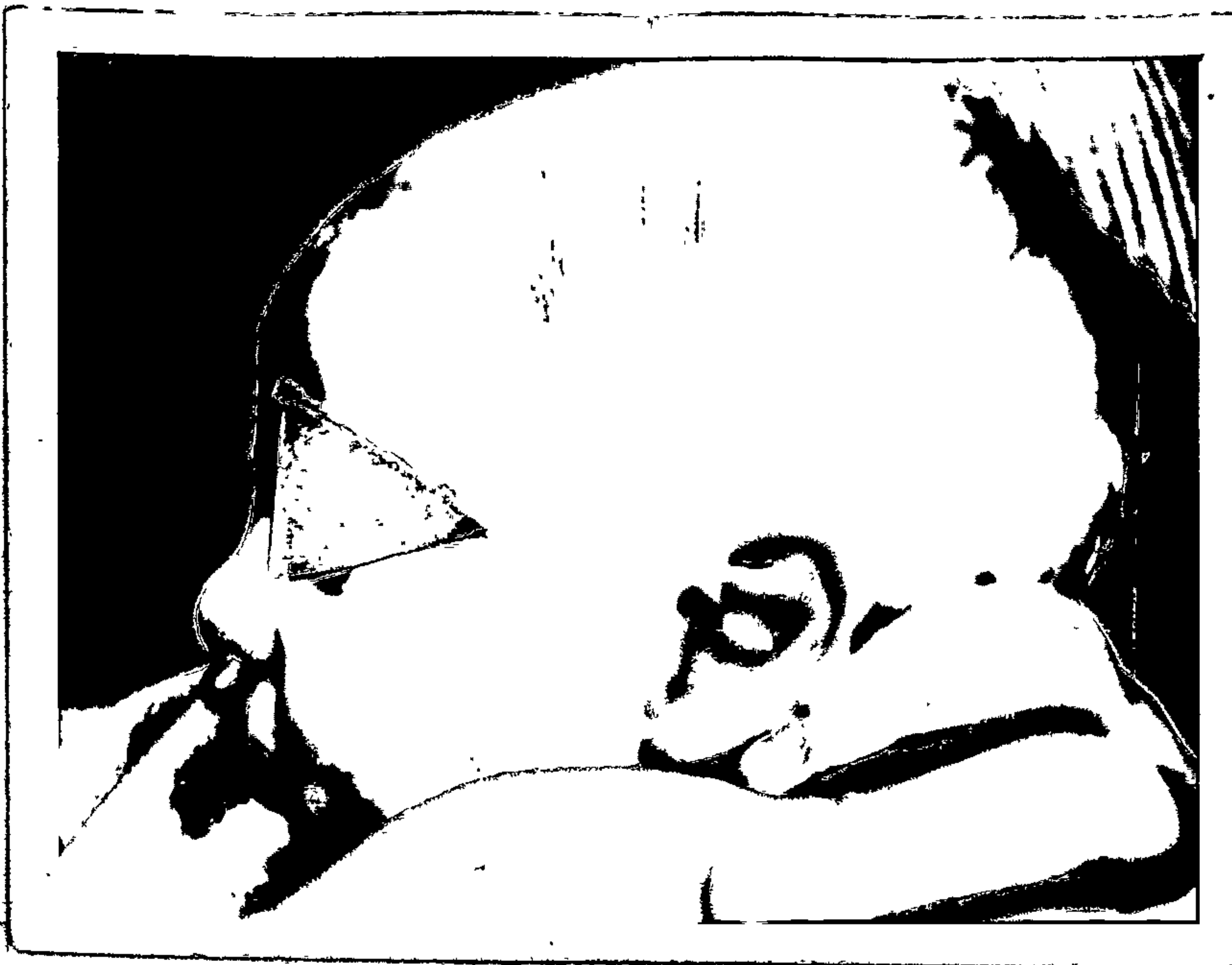

Figure (67)

Facial profile before surgery.

Refer to after surgery Figure (5 )

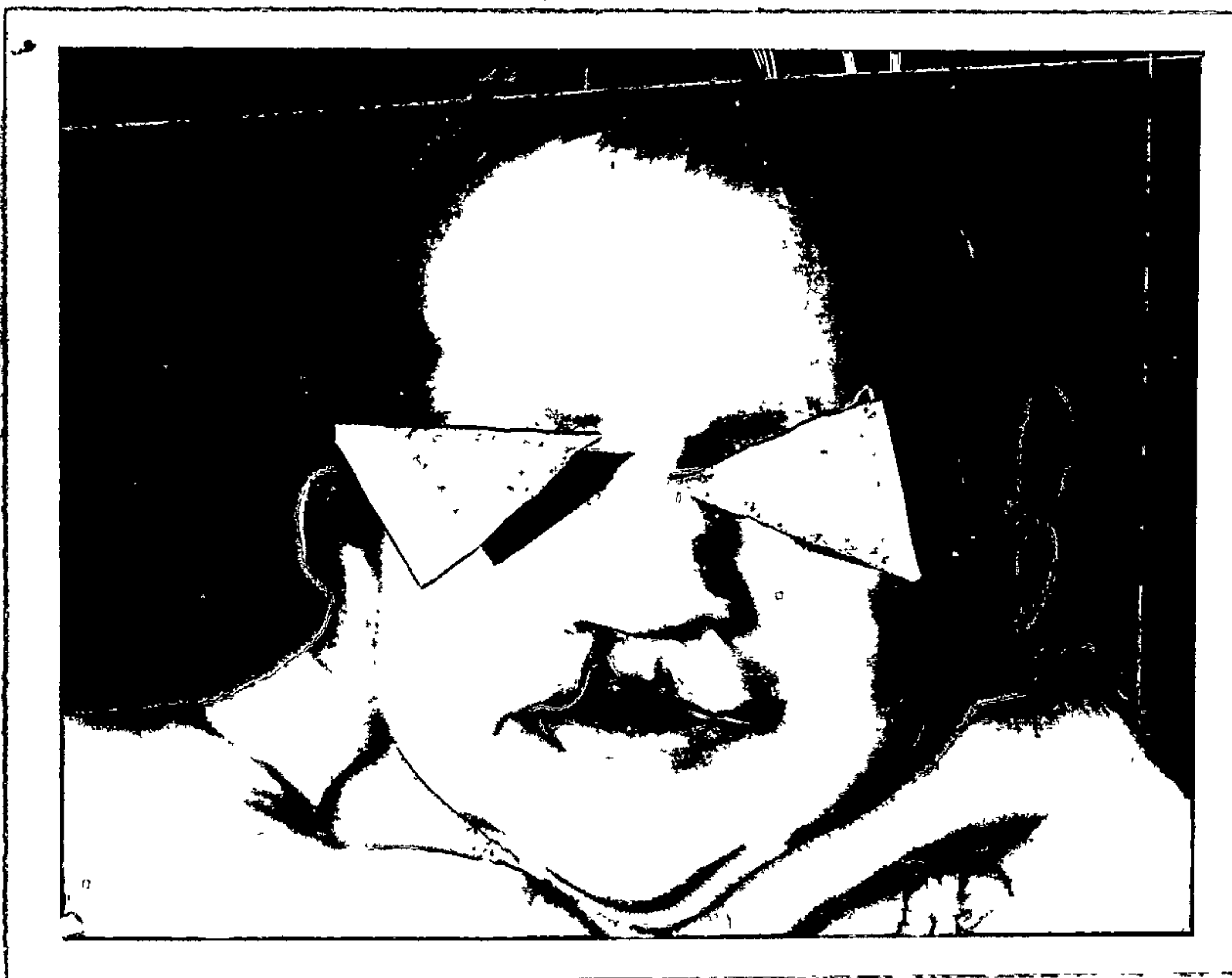

Figure (68)

Anterior view before surgery.

Refer to after surgery Figure (6 )



Figure (69)

Facial profile following surgery for a unilateral cleft lip and palate.



Figure (70)

Anterior view - following surgery. Here may be witnessed the disturbed nostril.



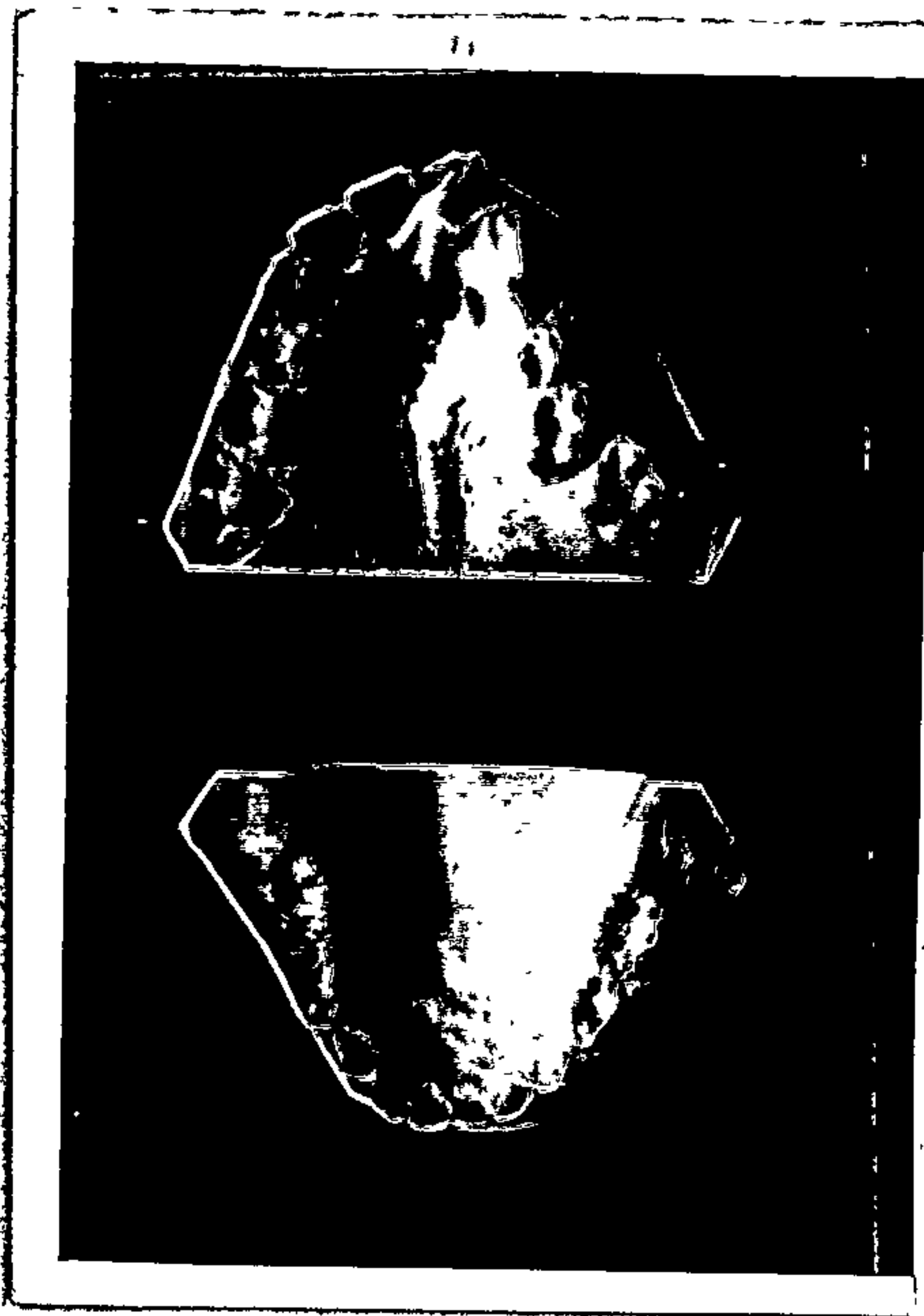

Figure (71)

Casts of the maxillary and mandibular dental arches.

Here may be witnessed the result of a unilateral cleft lip and palate, illustrating the disturbed lateral incisor, which has erupted palatally in the cleft and the unilateral collapse on the affected side.

There is the only slight rotation of the left six year molar, and rotation of the left central incisor.

The reduction in the inter-canine width is quite marked, whilst the change in the molar region is slight. Treatment here is logically expansion and restoration of individual tooth position and arch form.

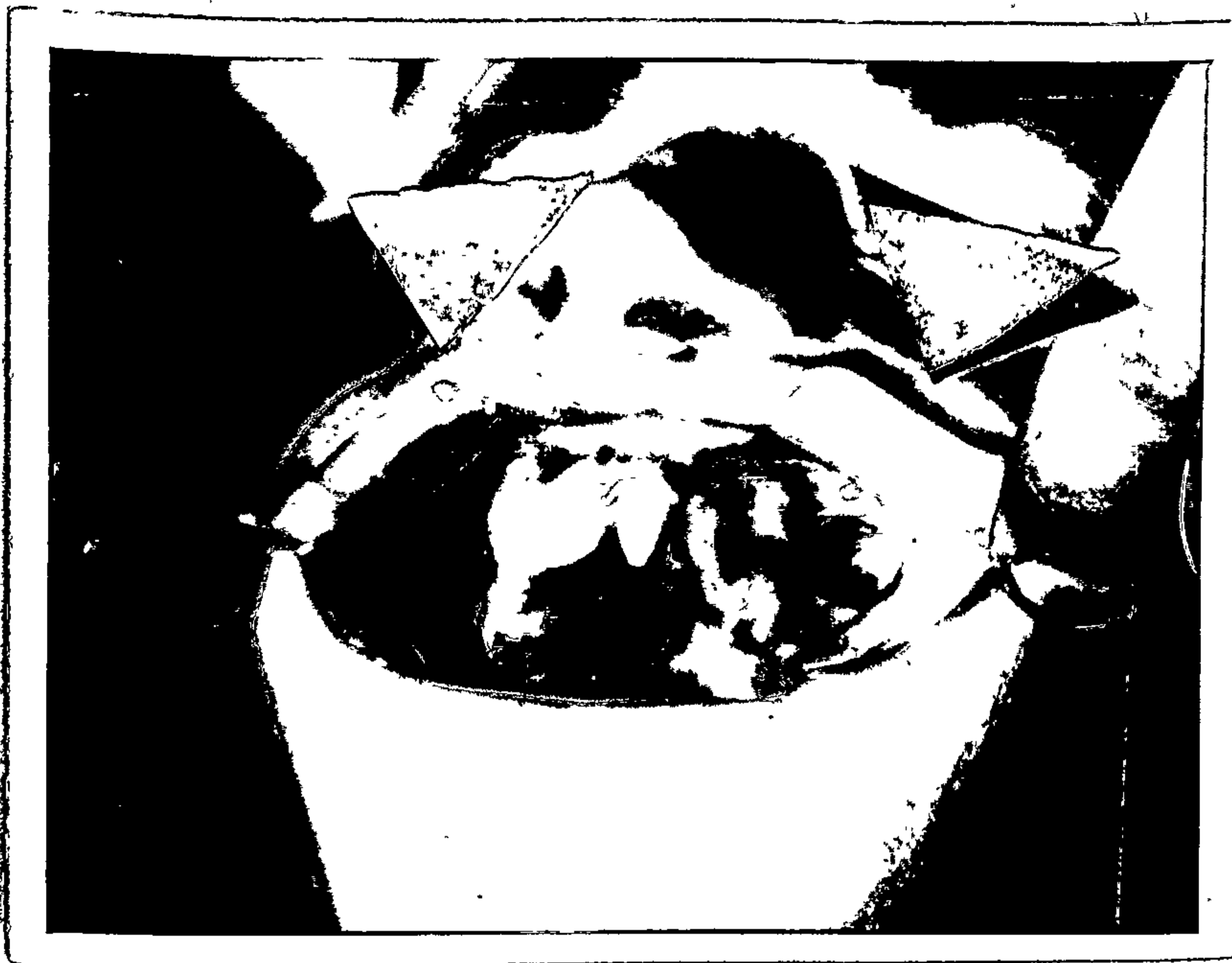

Figure (72)

This oral view of a unilateral cleft illustrates the oro-nasal communication that may exist following surgery and the collapse illustrated on the previous casts. The rotation of the central incisor and the palatal eruption of the lateral incisor is quite obvious in this view.



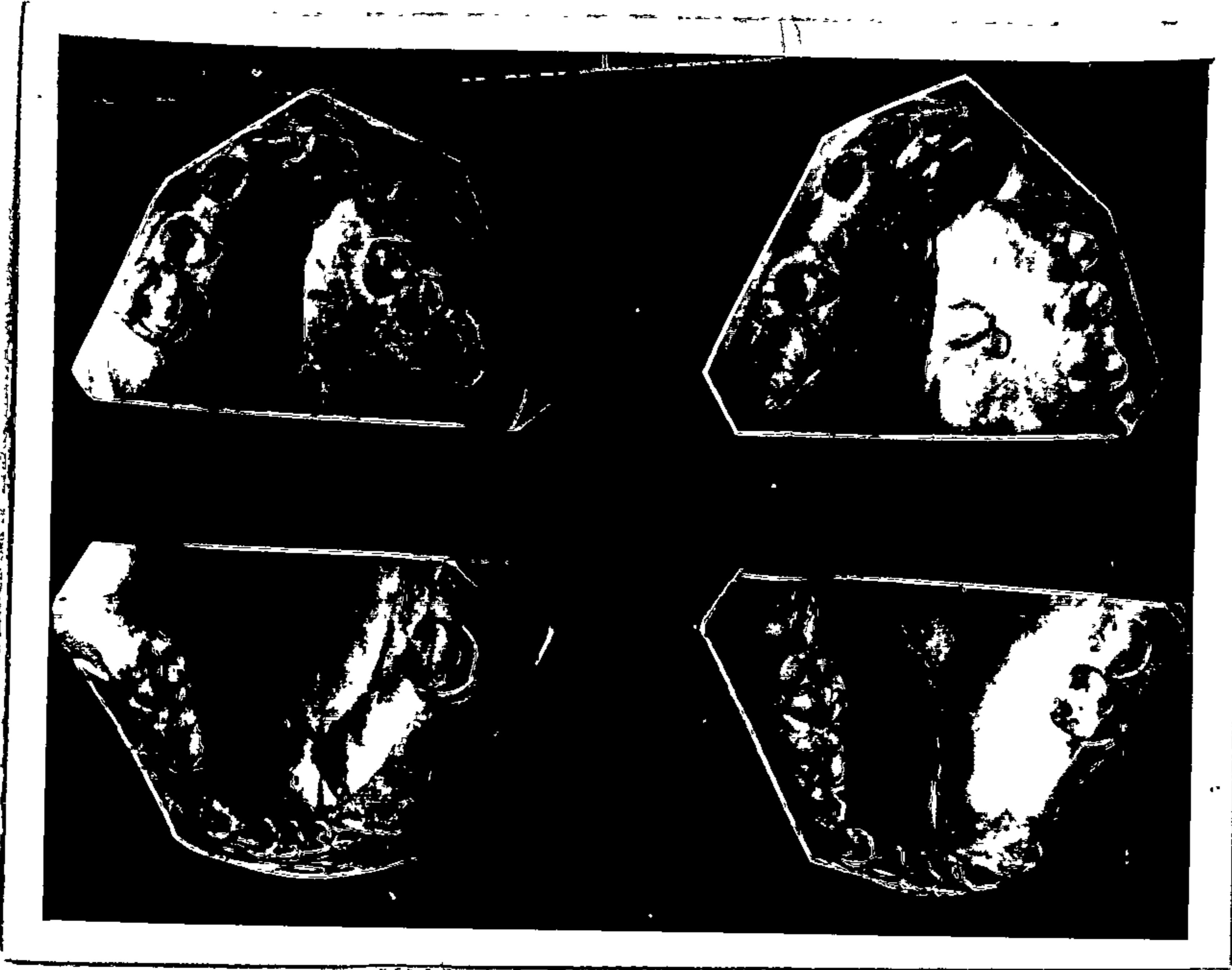


Figure (73) a. & b.

Models (a) and (b) both illustrate the appearance of a unilateral collapse of the left side of the maxilla.

Figure (a) illustrates a greater degree of collapse than does Figure (b) in which has occurred displacement of the permanent central incisor on the side of the cleft, in contrast to the normally placed central incisor in Figure (a).

In both cases the lateral incisors are missing and the canines unerrupted.

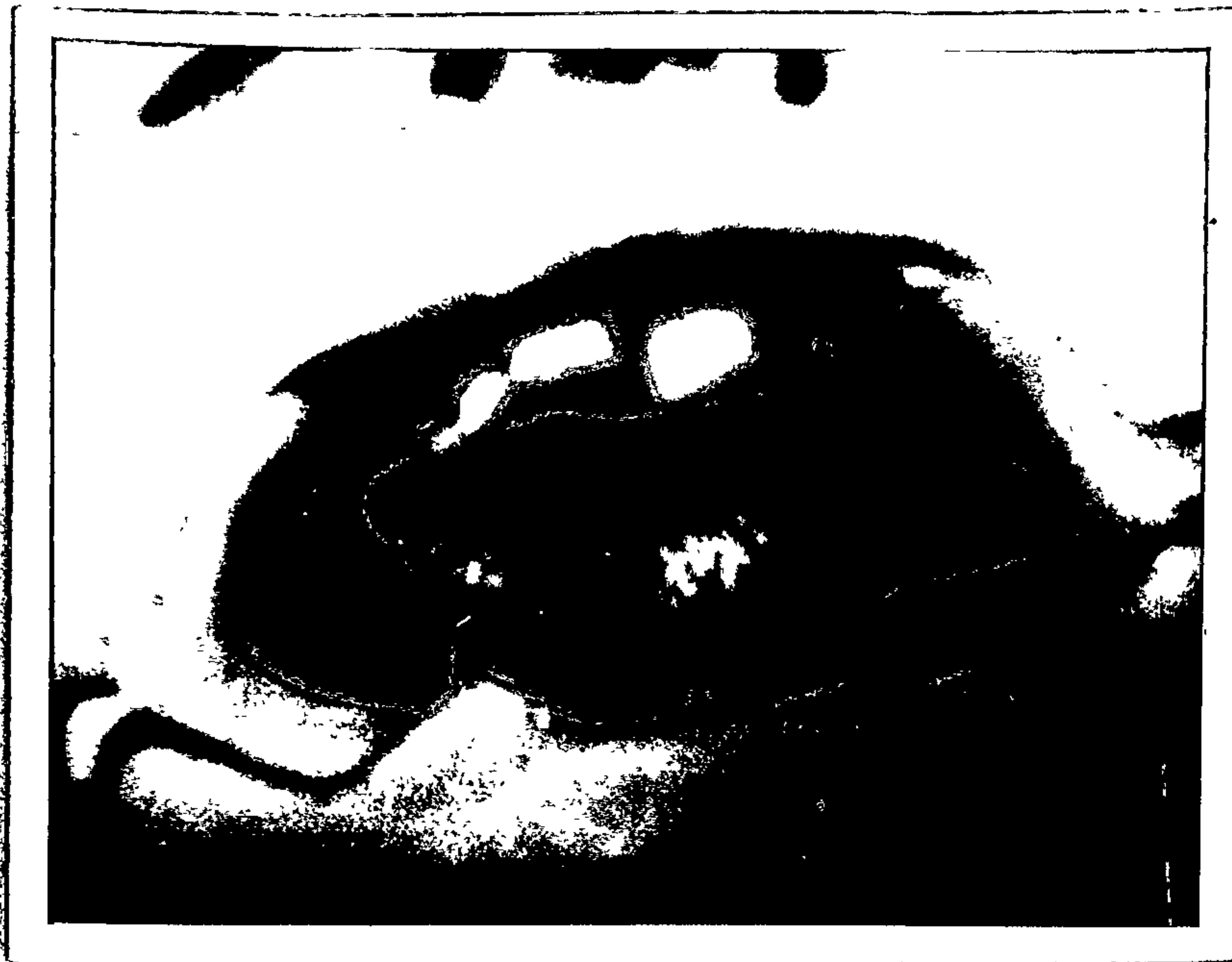

Figure (74)

This illustrates the rotated central incisor that occurs due to flaring of the premaxillary segment followed early by unilateral collapse of the maxilla. Here also may be seen the rarely occurring bifid tongue.






Figure (75)

This Roentgenogram of an occlusal view of a maxillary arch is taken mainly from the region anterior to the six year molars, and is included with its companion mandibular to illustrate reasonably normal development of bony structures, and as a means of comparison with the previous and following Roentgenograms.

The crowns of the teeth are well formed and the roots forming on the lateral and central incisors, the apical foramen of which are still well patent.

Photographs.

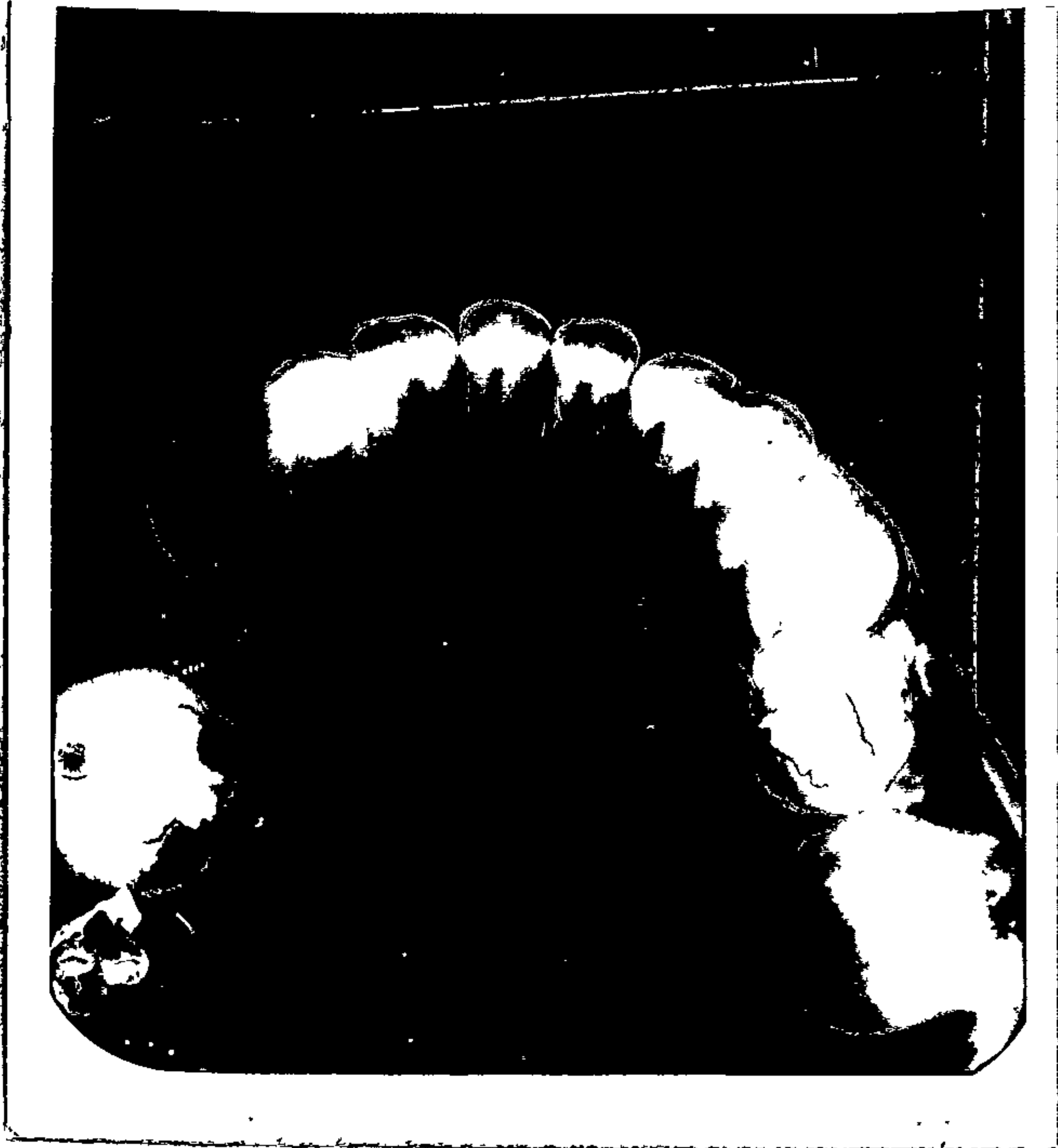

Figure (76)

Occlusal view of the mandible displays normal development of the arch contour.

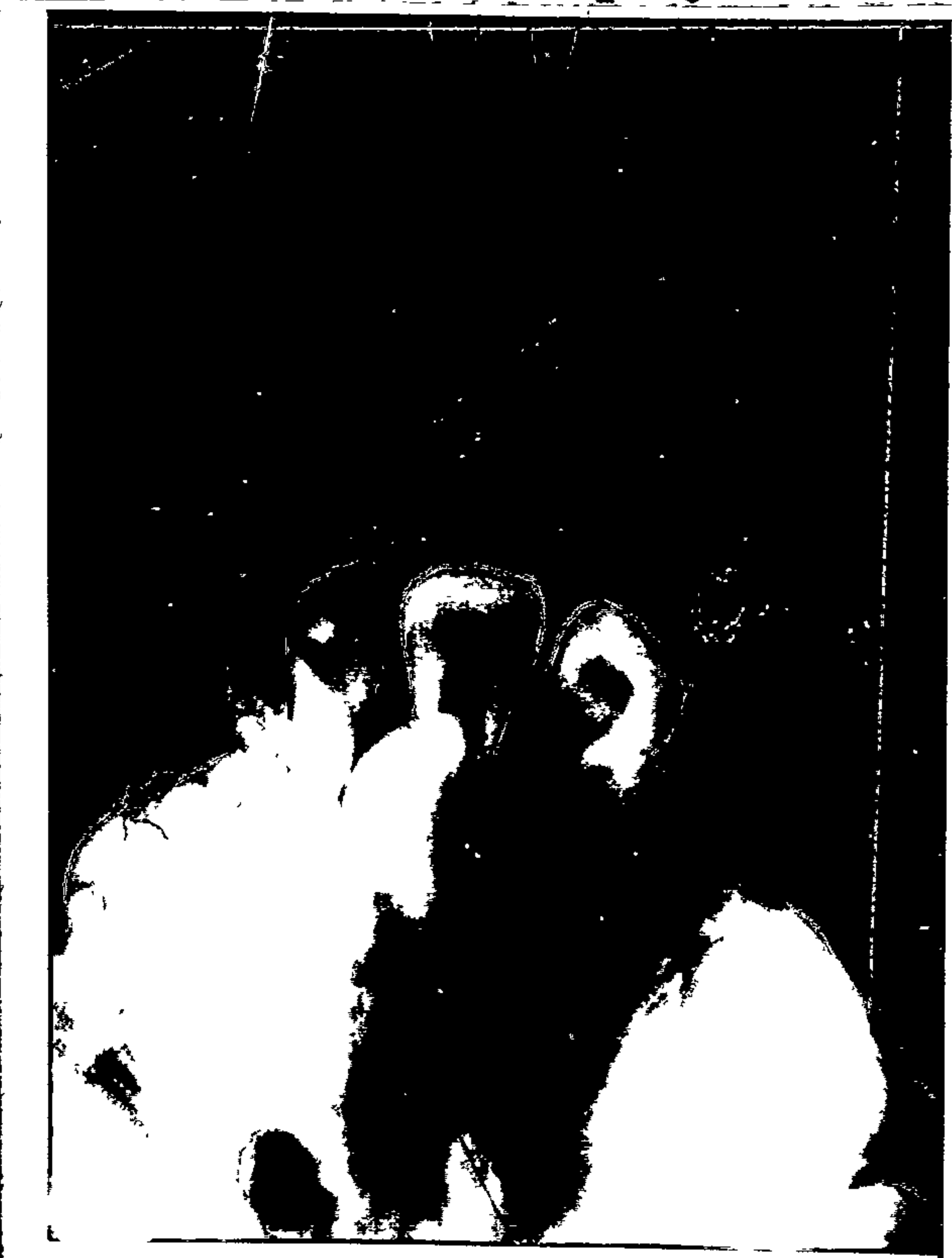


Figure (77)

Illustrates the crowding that may occur in the premaxillae in a unilateral cleft lip and palate and the bony tissue loss that results.



The disturbed eruption and malplaced teeth are quite obvious and it is easy to visualize a contracted arch that appears deficient in antero posterior depth. The inclusion of a lateral or canine in a cleft is quite frequent; the occurrence of an odontoma rare. The inclusion of a tooth within soft and hard tissue of the cleft region is illustrated here.

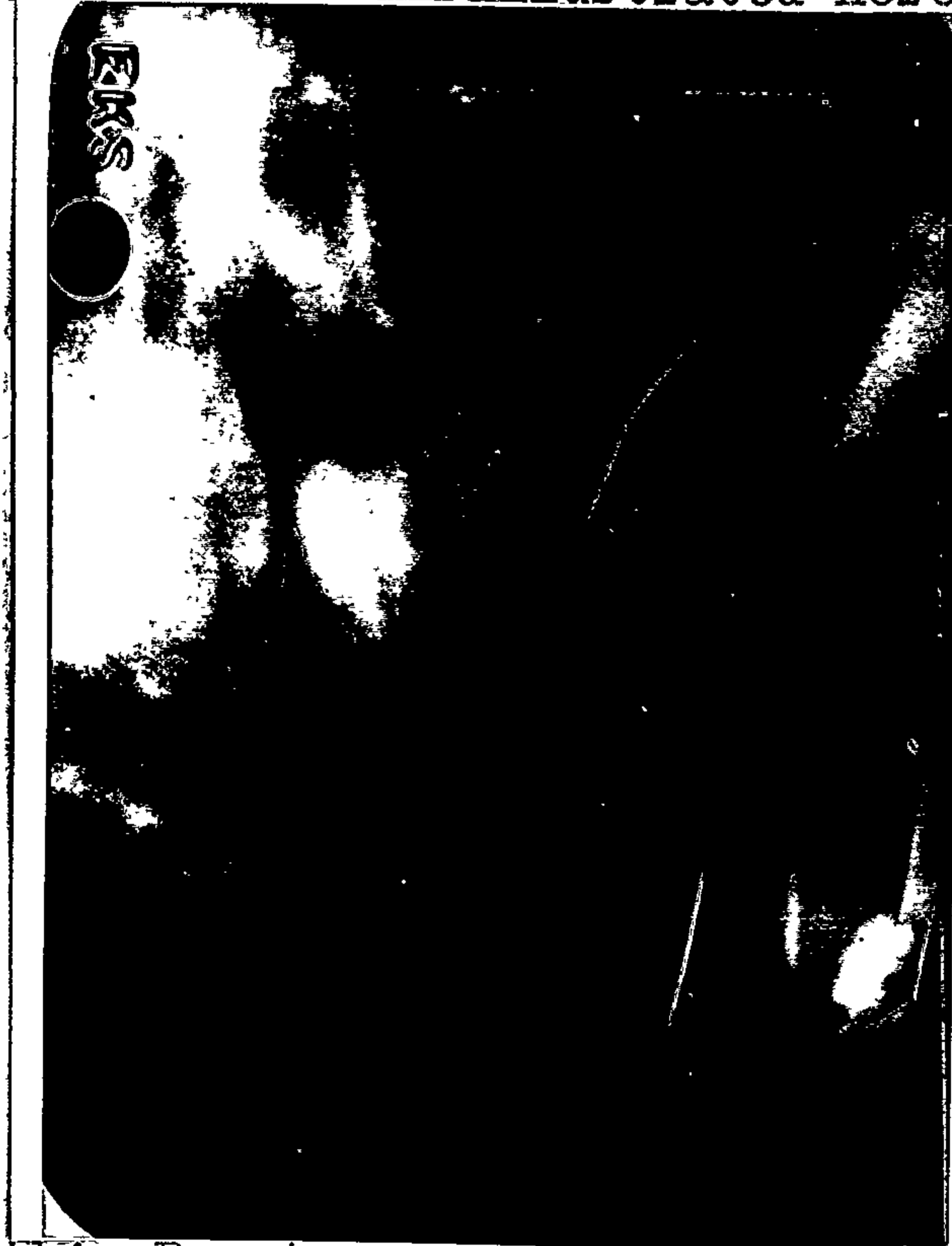


Figure (78)

Here in this Roentgenogram may be witnessed the bunching of the maxillary incisors on either side of the cleft during eruption. The degree of bone loss is illustrated by the radiolucent area between the erupting lateral incisor and canine. The abnormal angulation of the teeth is well illustrated.

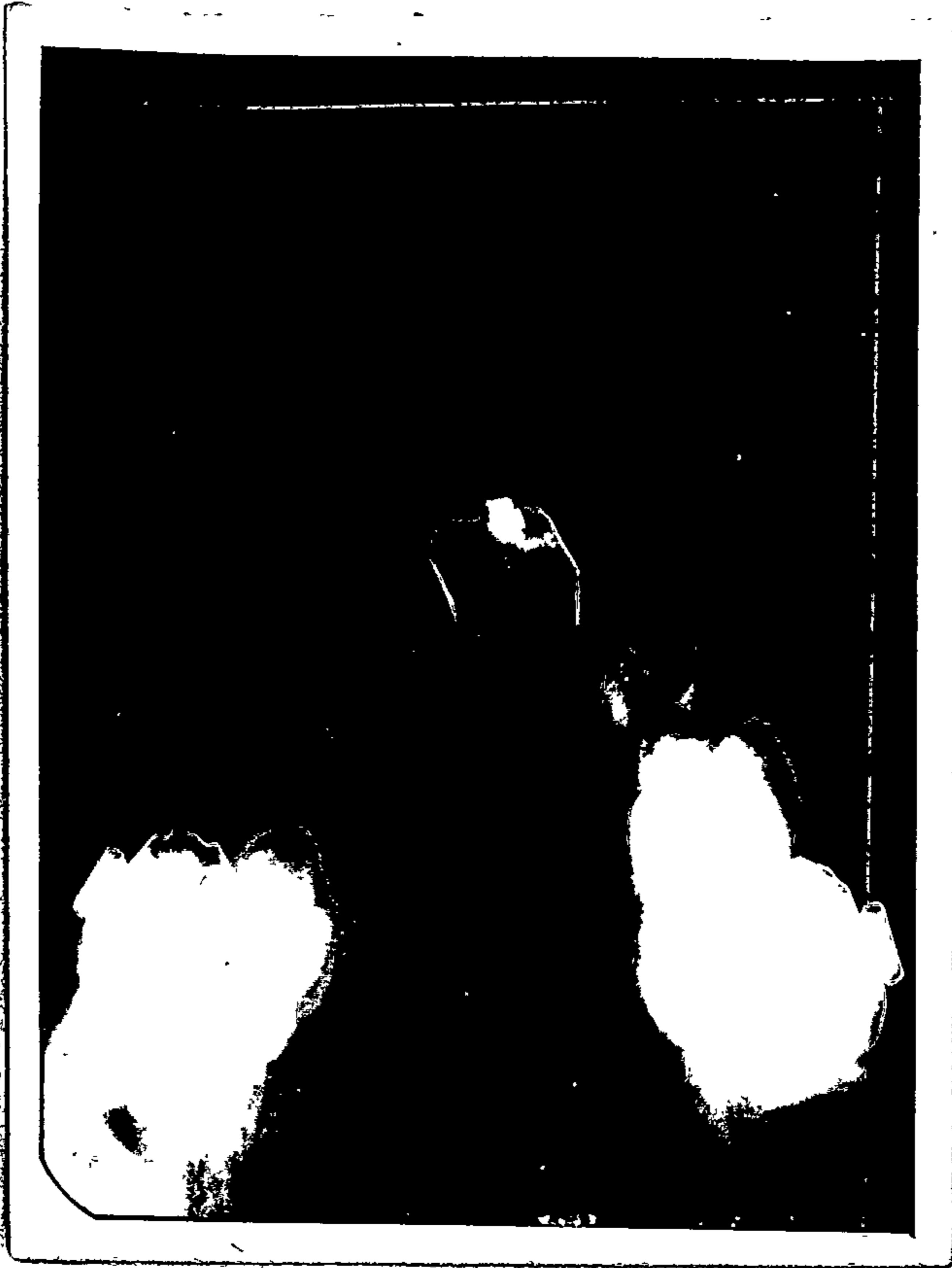


Figure (79)

Illustrates the malocclusion that exists before orthodontic therapy and the tissue loss in the cleft. Treatment will right malposed teeth and expand the segments of the arch laterally, but does not have deleterious effects upon the bony framework, nor destroy teeth that are close to the palatal-alveolar cleft.

The occurrence of root resorption has not yet been witnessed in the permanent dentition, but has been found to occur in the deciduous dentition during orthodontic therapy.



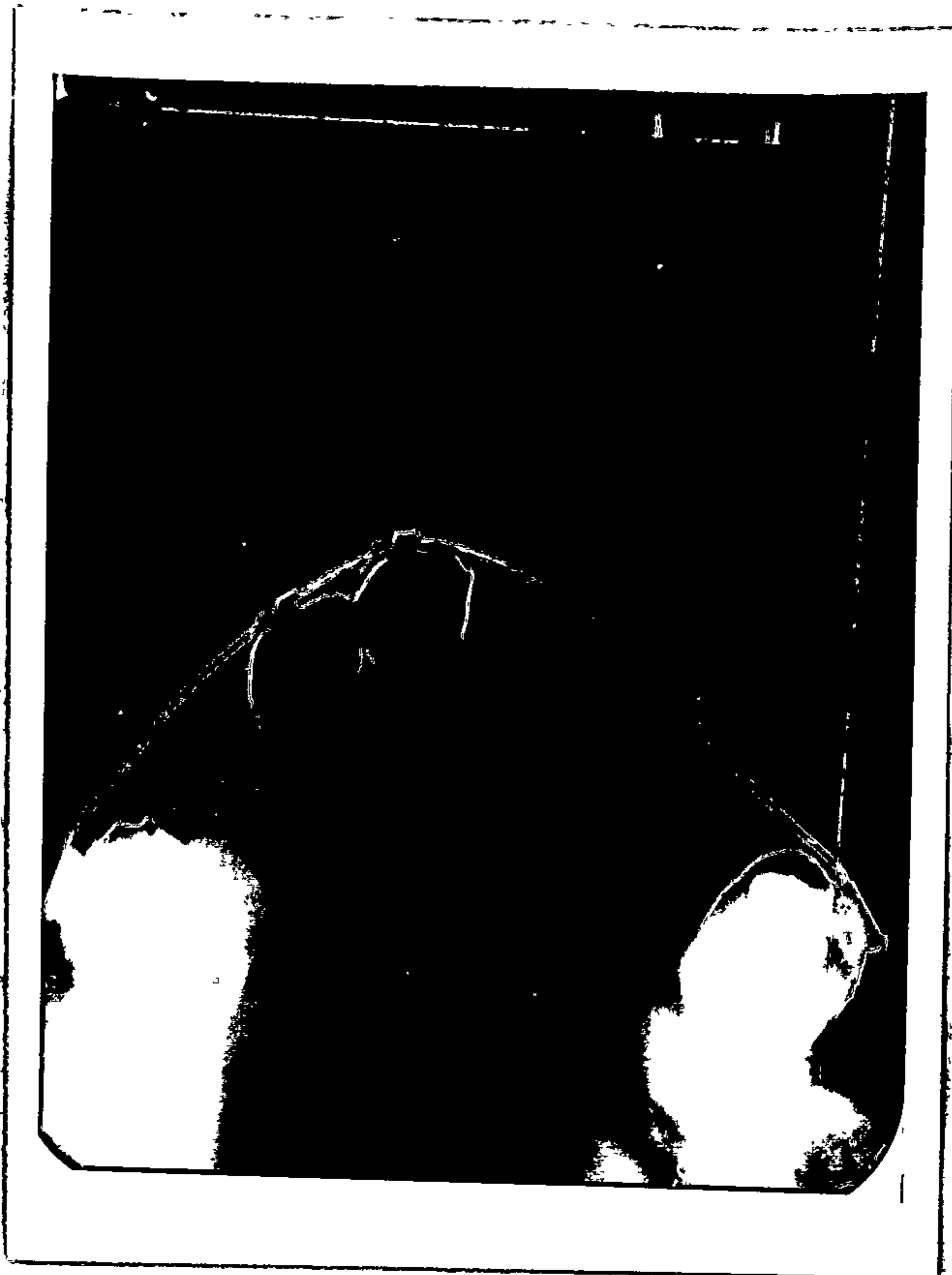


Figure (80)

Illustrates the response of teeth to orthodontic therapy. There is no change in the roots (resorption), and periodontal tissues are not destroyed. The teeth alongside the cleft do not tend to wander into the cleft area, and restoration of the normal arch allows a prosthesis to replace the lost units and tissue. Orthodontic therapy will frequently allow impacted teeth to erupt and assume a normal position within the arch.

The size of the bony tissue defect indicates whether an oro-nasal communication will be permanent or not.

Type 3.

Bilateral cleft of the lip and alveolus associated

With complete cleft of hard and soft palates.

This abnormality at birth may shock even the experienced surgeon in its severity. The dynamic effects of surgery are illustrated by the immediate improvement using a two stage repair of the lip. This surgery repairs the sphincter-like action of the orbicularis oris muscle and reverts the forces of muscle pull. See figure illustrating repair.

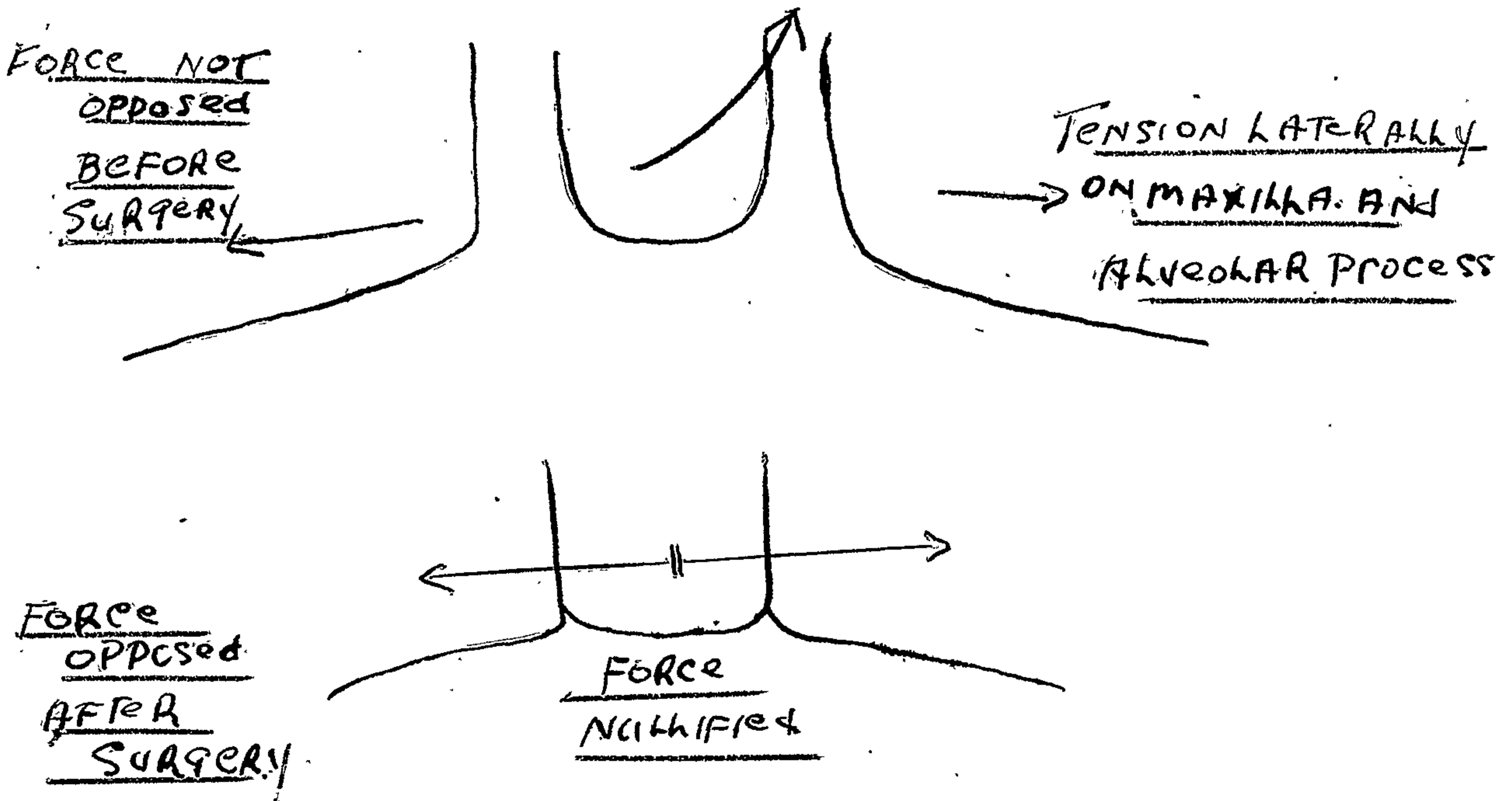


Figure (81)

The effect upon the alveolar process may be witnessed by observing Figure (46) and Figure (48)

Figure (48e) illustrates the effect of surgical repair upon one side of the segment, whilst Figures (82, 86) illustrates <sup>AS</sup> in Figure (46) b, c, d, e, f, the arch form following surgery bilaterally ON THE PALATE AND LIP RESPECTIVELY.



With the balance of forces restored, moulding of the bony segments occurs. The width of the palate in these cases before palatal surgery may be observed to be reasonably normal or enlarged, and little evidence of collapse occurs.

Observation of Figure (48E) indicates that at birth the three segments occur frequently, free and independent of each other. The nasal cavity and its full anatomy may be observed bilaterally orally.

As to the degree of tissue present, all grades have been observed from that of atrophy of the premaxilla with wide tissue loss, to practically normal existing tissue except for the narrow continuous cleft area. Division of the soft and hard palate make feeding a problem early in these cases, and the infant's weight may rapidly fall.

Surgical manoeuvres over the past fifty years have provided the collapsed arches that may be witnessed in most adult cases to-day.

The decrease in width is mainly at the inter-canine area and occurs bilaterally.

In the deciduous dentition the central incisors usually either protrude or retrude, and may be rotated. The lateral incisor and often the canines are either missing or displaced and may erupt in the cleft.

Figure (48C) illustrates the appearance at this phase before eruption of the six year molars. Rotation of the premaxilla may occur to one side or the other, depending upon the severity of the clefts. (Figure 89(D) (E) (F) AND 86(a) to (F).

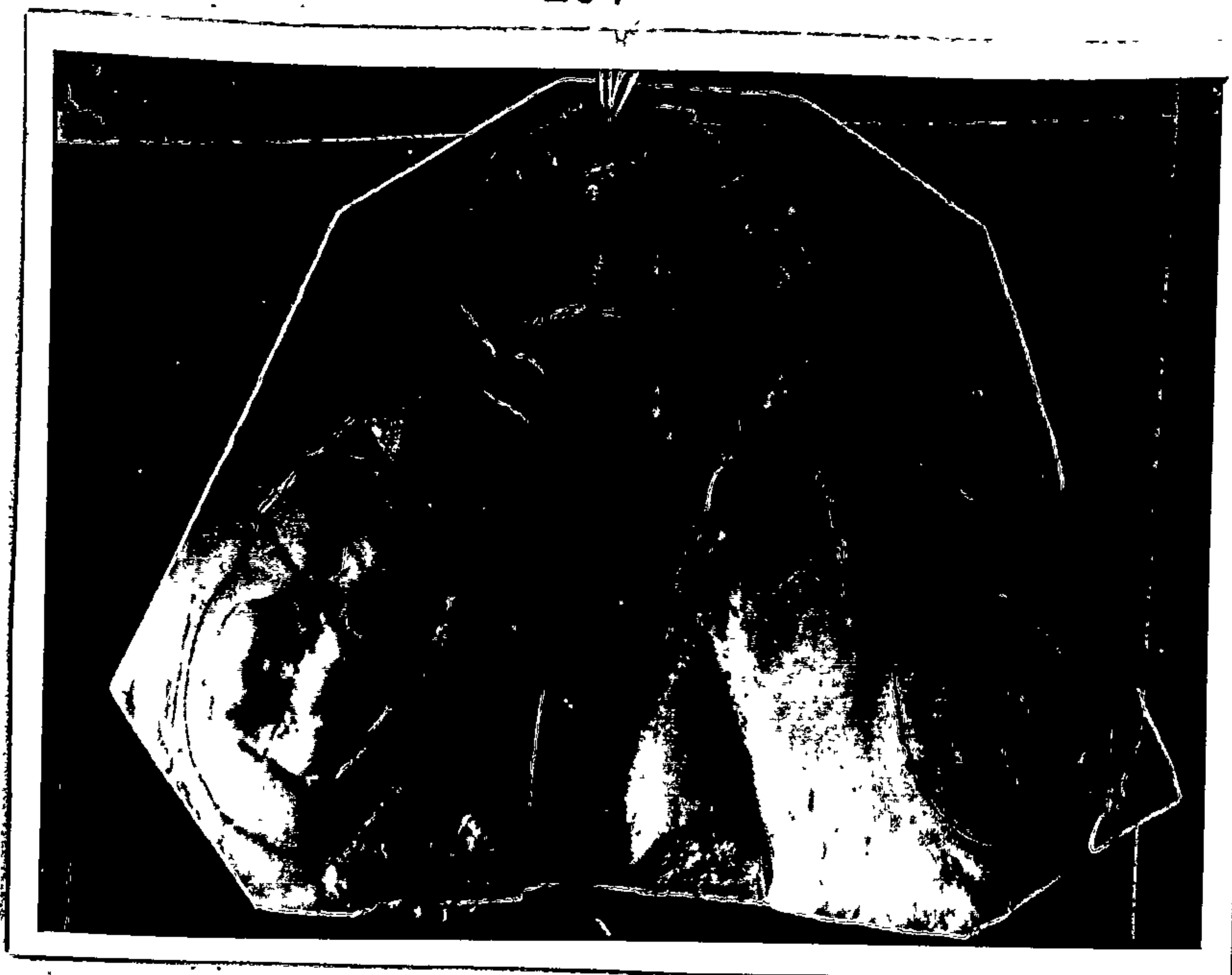

Figure (82)

This cast displays the characteristics observed in a bilateral cleft of the lip, alveolus, and cleft of hard and soft palates.

The rotation of both six year molars and maxillary segments, and the fall in inter-canine width accentuates the prominence of the premaxilla. Oro-nasal communications, one easily observed, are present.

The tissue is severely cleft, and the units, premaxilla, vomer, and maxillae, three in all, so typical of this type, are outlined. Part of the palate, as well as the cleft lip, displays the results of surgery which has provided cicatricial tissue, a feature hard to prevent when closure is attempted.

Quite apparently, following surgery there has been Bilateral collapse. Comparison of figures (46) (A)(B) (C) (D) (E) (F).

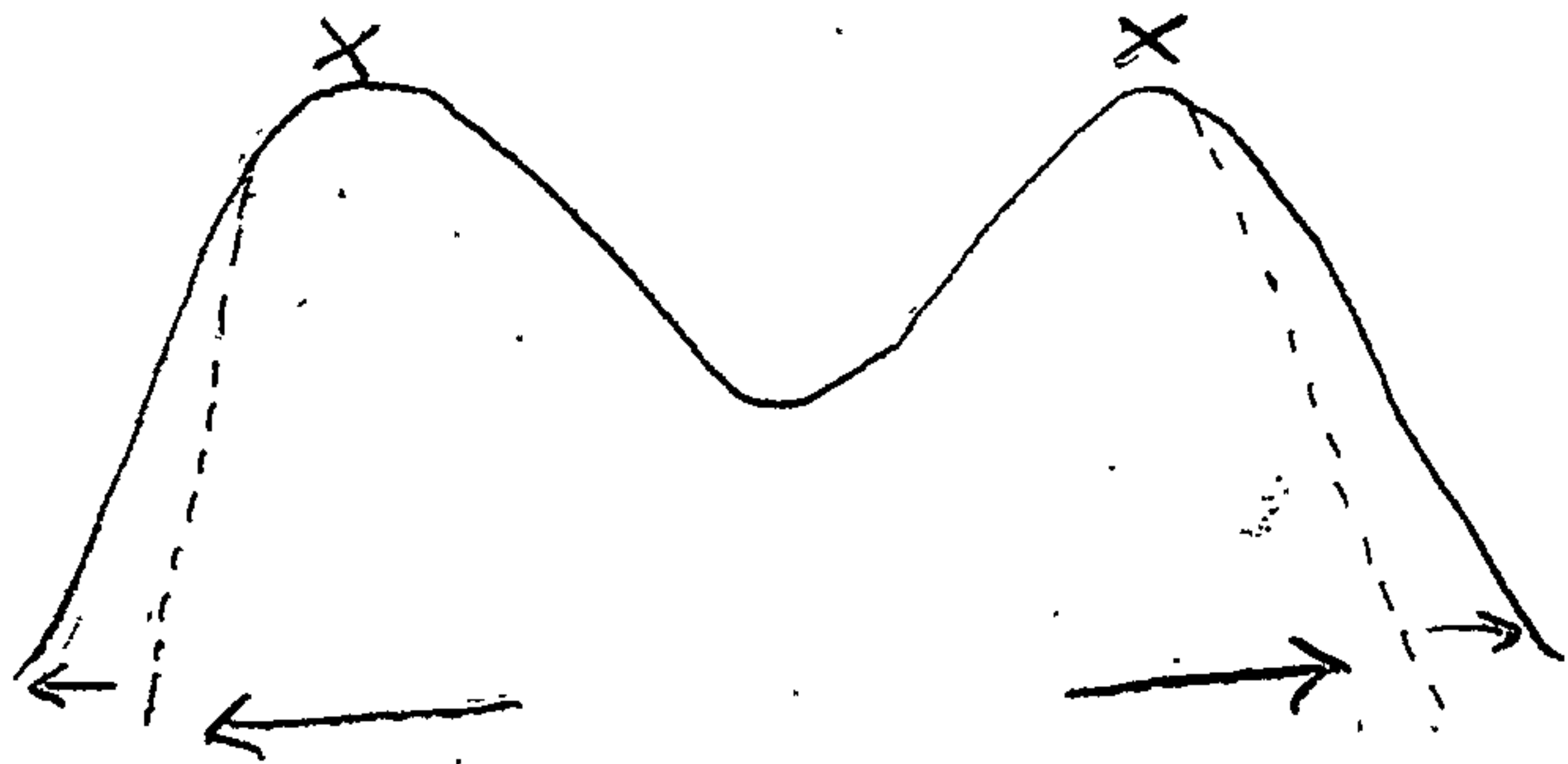
Also illustrated is how this collapse results in a pincer movement on the vomer by the anterior ends of the maxillae,



preventing any further displacements distally during growth of the premaxillary unit by cicatricial tissue of the lip which provides pressure. It is not until orthodontic therapy provides expansion that this rotational movement can occur.


Figure (83)

Method of CRIMPING wire in  
BUTTERFLY arch



crimping wire at X increases the  
width between molars.

(crimping = to flattening curve.)



crimping wire at Y increases  
intercanine width

Orthodontic treatment may be commenced in the deciduous dentition. Fixed arch therapy is usually employed with bilateral expansion by means of a round labial arch with butterfly formation which may be crimped at the three points. See Figure (83.)

Removable appliances utilizing Adams' clasps may be employed but do not prove as satisfactory as fixed arch appliances. Tension for distal movement, on the premaxillary unit, may be used by means of intramaxillary rubbers bilaterally.

In many of these cases associated with orthodontic therapy of expansion, a "V" section may be previously removed from the nasal septum to provide distal movement of the premaxilla.

During the mixed dentition a similar technique of arch expansion may be employed and therapy is usually continued into the permanent dentition, establishing this in a correct occlusion.

In some cases retarded growth of the premaxillary element occurs, and therapy is mainly then concerned in obtaining normal occlusion in the buccal segments. Arch form is very difficult to restore to normal, and the occurrence of a deep mandibular overbite complicates the picture.

The mandibular teeth may occlude against the soft tissue of the premaxilla and tend to prevent distal movement of the premaxillary incisor unit.

Over-eruption of the mandibular incisors may occur, further antagonizing this feature. Bilateral expansion appears to occur dramatically in many cases, whilst posterior movement of the premaxilla seldom occurs, the movement being mainly a rotation palatally of the incisor teeth, rather than a horizontal movement.



The permanent dentition is rarely complete, and a prosthesis usually has to supply the missing units.

Teeth that erupt within the cleft supported by soft tissue may be utilized in the deciduous dentition for expansion, but in the permanent dentition should be extracted.

With regard to growth during treatment, Samuel Pruzansky<sup>89</sup> states:

"The downward and forward growth of the body of the maxilla and mandible seems to catch up with the premaxilla, which is now encompassed by the repaired labial musculature, and held in rein by its tension throughout growth".

The premaxilla during retractive treatment should theoretically become enveloped within the complex of facial bones to assume its proper architectural position, but this does not always appear to occur, and surgical "V" section, may provide better results. He further states:

"For some children this natural resolution of the dysplasia in the facial profile occurs rapidly, and for others the process evolves more slowly".

Only time and research can supply correct treatment.



Figure (84)

This photograph illustrates the marked cicatricial tissue labially over the protruding premaxilla, giving a bird like appearance. The nostril is frequently flattened. These features are discussed at length.



Clinically it was assessed that from two to five years the resolution of the dysplasia in facial profile was slow, whilst from five to eight years the resolution was marked. From five to eight years orthodontic expansion and retraction of the premaxillary teeth is applied in therapy, and this assists normal growth forces.

This treatment in the deciduous and mixed dentitions is imperative to provide normal functioning forces and normal occlusion, both of which aid the growth potential.

This expansion as stated in previous cases, provided marked widening of the floor of the nostril. The inter-canine width is dramatically increased and the bilateral cross-bite reduced, providing a greater potential for respiratory power nasally.

In severe protruberance of the premaxilla, "V" section removal from the vomer with fixation by means of a cast ferrule splint supported by a plaster head cap, may be necessary (Figure 34) but frequently orthodontic treatment is again required for bilateral expansion. In most cases over-expansion is obtained for the degree of collapse frequently following cessation of orthodontic procedures, would destroy the normal occlusion if only the required width were established.

Expansion provides greater room for the tongue and its movements during speech and swallowing, increase in the nasal air way, improved appearance, and normal occlusion, no mean feat for a simple procedure. The cheeks appear to fill out and the flattened appearance is lost.

The soft palate in these cases is frequently short and

naso - oral fistula most common. Despite the loss of ecto-dermal tissue, supernumerary dental rudiments occur quite frequently in these cleft soft tissue areas.

Albright claims that these are not actually supernumerary teeth, but a reversion to <sup>the</sup> type of six incisors. His observations indicated family inheritance of supernumerary teeth in these cleft conditions.

The disturbance appeared in most cases, to affect the deciduous and permanent centrals, laterals, and canines. These teeth were found on occasion to be rotated, unerupted, impacted, missing, malformed, or displaced. Crowding of the erupting bicuspids in the mixed dentition frequently occurred, but orthodontic therapy restored these segments to a normal arch form and usually a normal occlusion.





Figure (85)

A Roentgenogram of the bilateral cleft lip, cleft palate, illustrating the degree of tissue lost and the division of the palate into a tripartite palate.

(a) Premaxilla and Vomer.

(b) Two maxillae.

The rotation of the erupting central incisor either side of the midline is apparent.

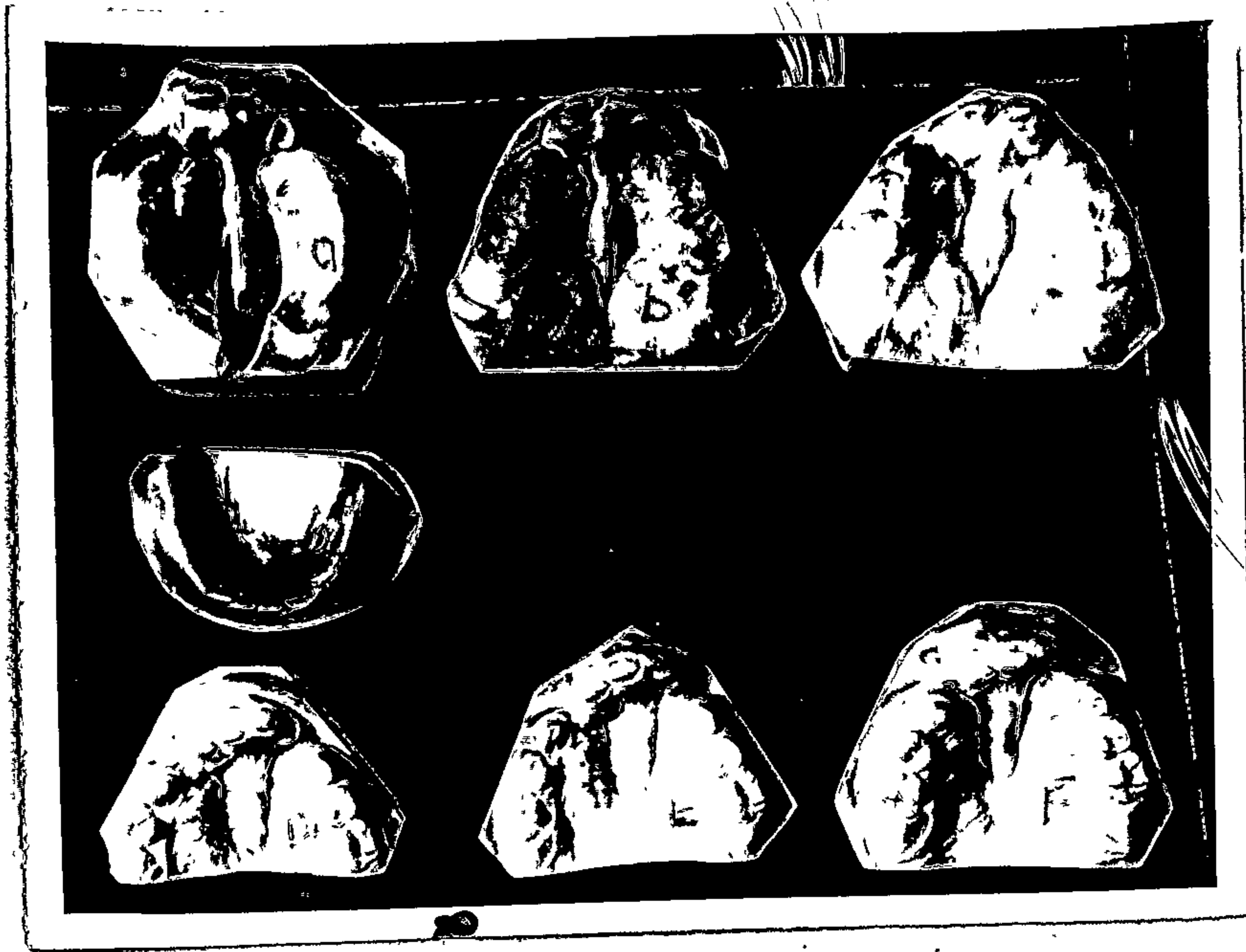

Figure (86a) illustrates a cast of a bilateral cleft lip and palate following surgery upon the lip but not as yet the palate. Compare with Figure (82). The mandible displays normal growth and eruption of incisors.

Figure (86b) is the cast of a similar disturbance in the deciduous dentition before the eruption of the six year molars.

Figure (86c) illustrates similar features to Figure (86b)

Figure (86d) is the cast of a bilateral cleft lip and palate, deciduous dentition, but with rotation of the premaxilla slightly to the right.

Figure (86e) shows the same anomaly as Figure (86d). Note here the actual union of the palate does not occur until the second deciduous molar.

Figure (86f) of this cast illustrates similar features as the preceding, but further rotation of the premaxilla has occurred and its' protrusion is not so great.





Figure (87)

This cast clearly indicates the bilateral collapse in the deciduous dentition. Comparison with the mandibular arch only too clearly emphasizes the protruberance of the premaxilla outside the maxillary units in the tripartite palate. These teeth also displayed hypoplasia and an increased rate of dental caries.

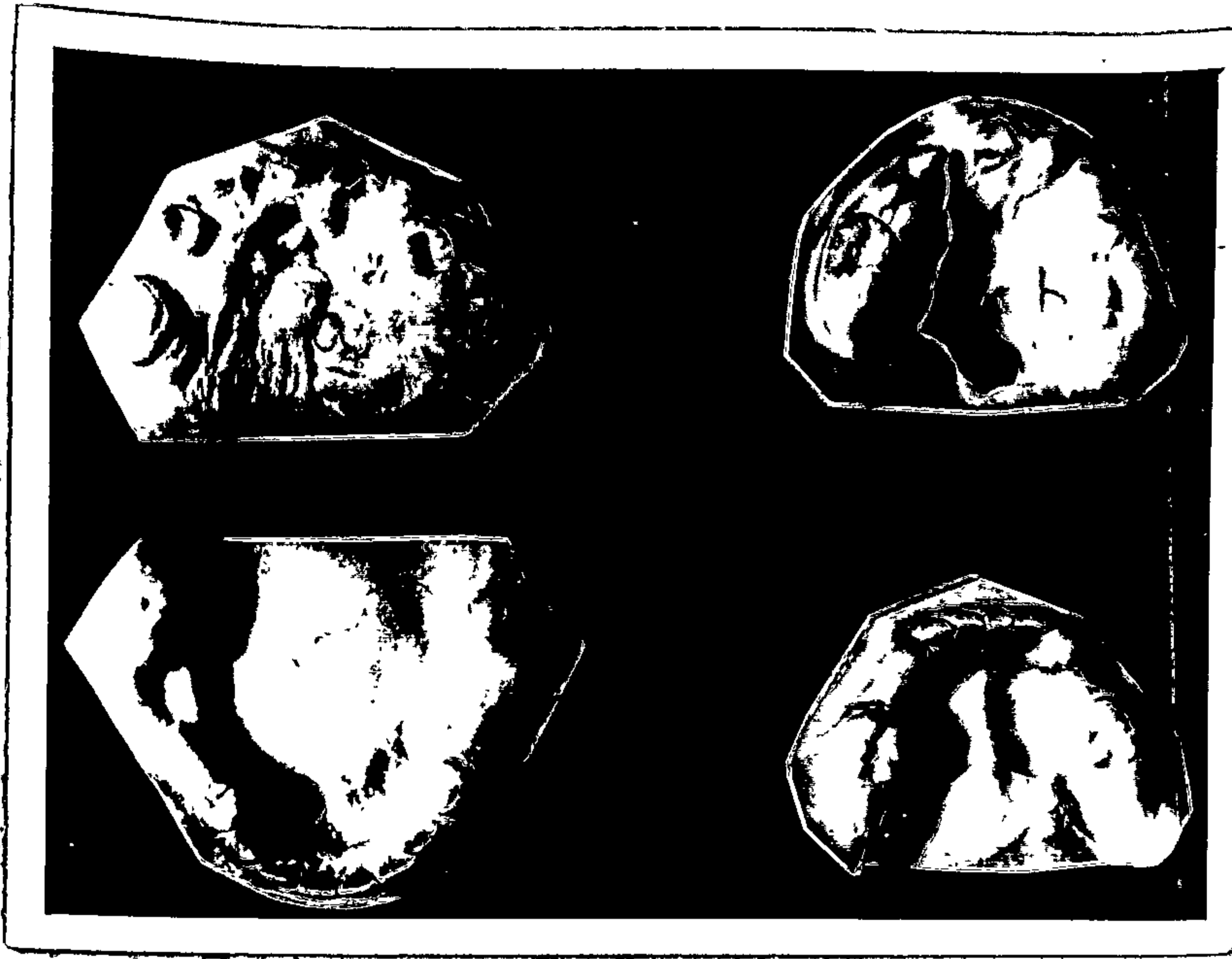

Figure (88)

Illustrates the cicatricial tissue that may occur resulting from closure of a palate. By comparison of upper and lower models, it can easily be observed that the maxillae are lacking in antero posterior length, and that the maxillary incisors will occlude lingually to the mandibular incisors. Crowding in the anterior segments of the maxilla frequently occurs with rotated central and lateral incisors.

Also illustrated is the degree of tissue loss that may occur in this type of palate. Surgery is frequently incapable of coping with such a loss. The size of the premaxilla is reduced here also, and the incisors malpositioned in the arch.



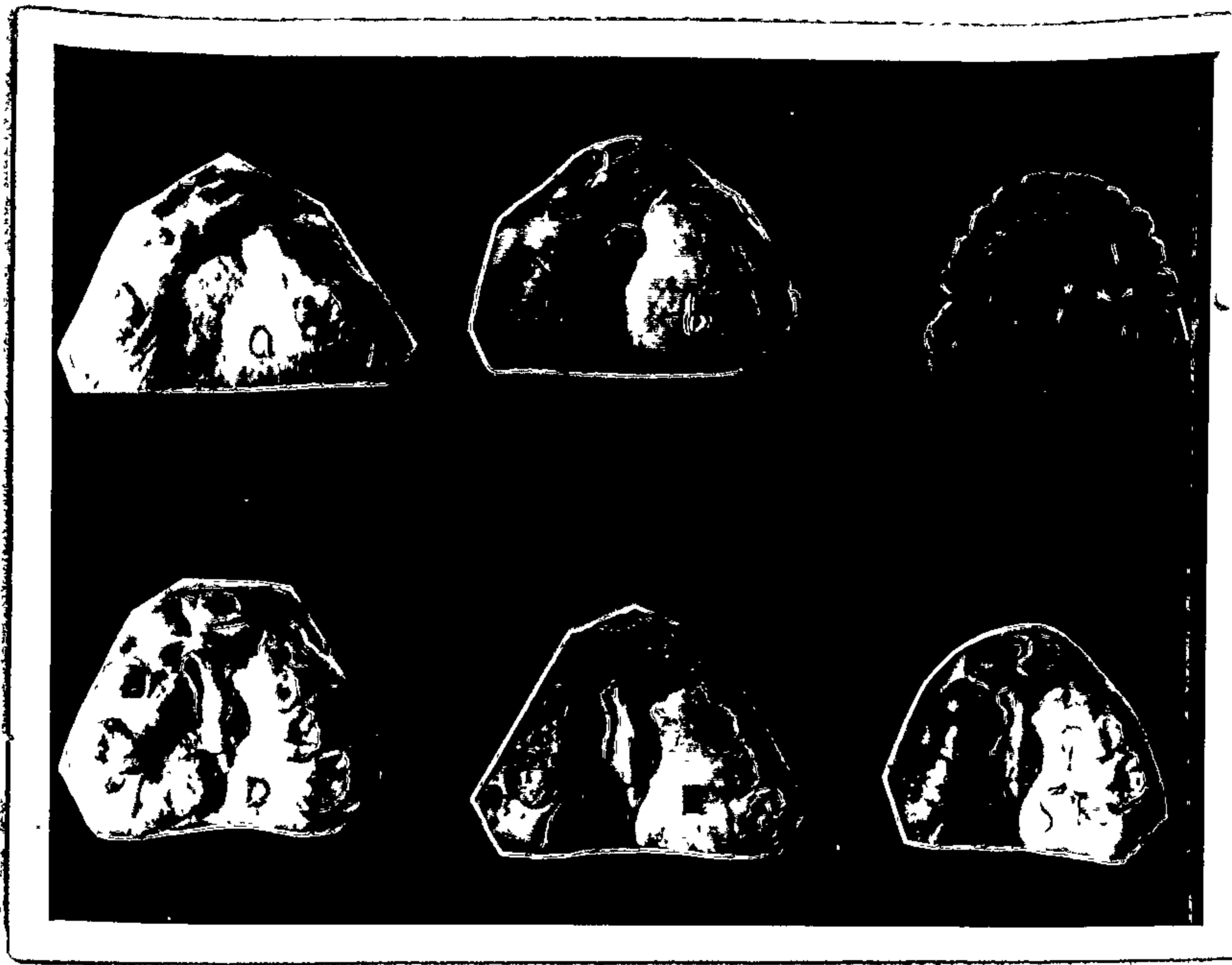


Figure (89)

This group of casts is included to illustrate the appearance in the unilateral collapse and bilateral collapse of the palate. Rotation is more often severer in the unilateral premaxillae and incisors rather than in the bilateral case. Frequently the bilateral condition contains maxillary incisors that are deformed.

The degree of cicatricial tissue in each case may vary and no true comparison may be made due to too many influencing factors.

Figure (89c) illustrates the type of prosthesis that may be utilized for a while whilst awaiting eruption of teeth in cases where the appearance of the child may have some psychological effect and aid treatment, as it did in this case.

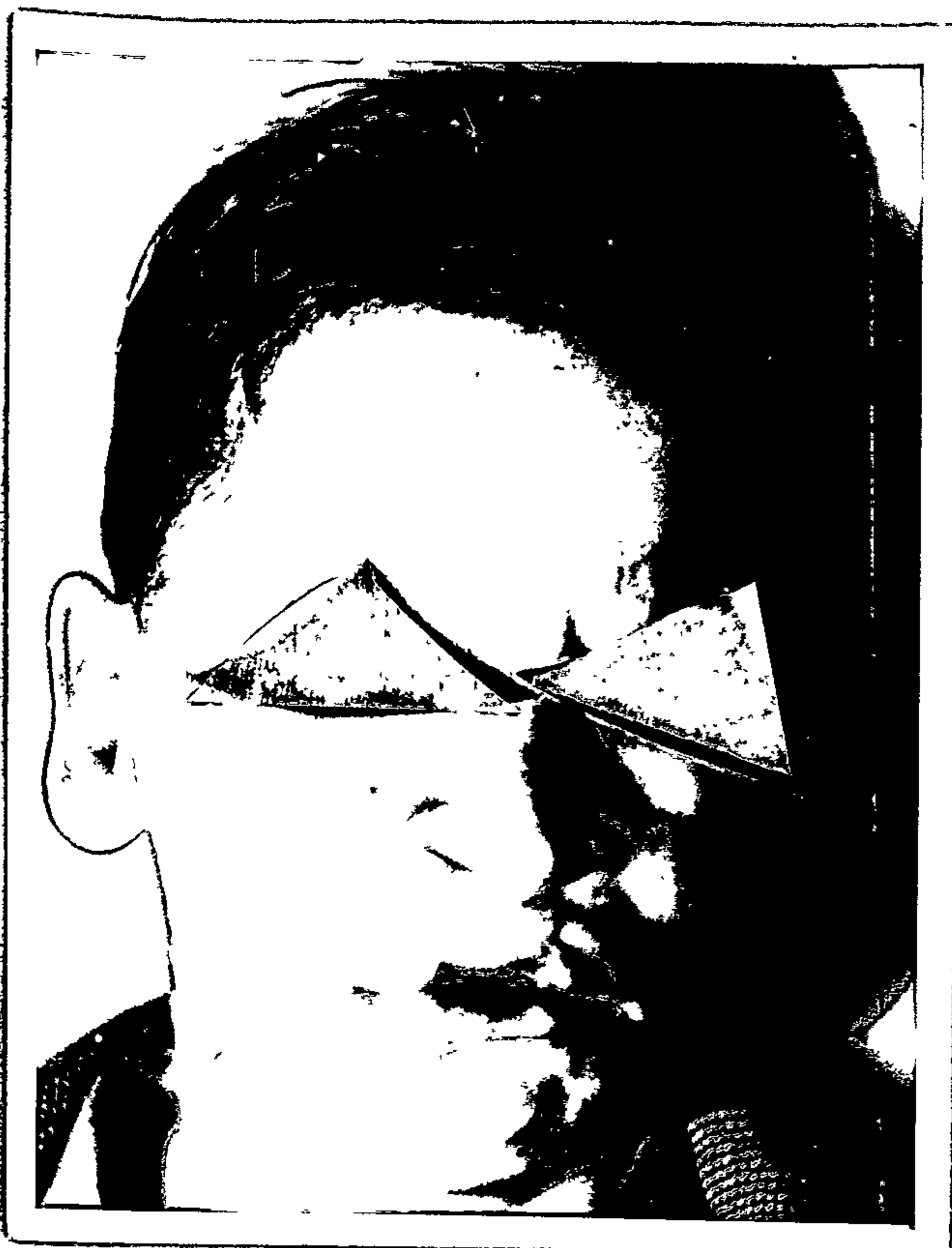

Figure (90)

Anterior view of two stage bilateral hare lip repair that has resulted in a slightly notched vermilion. In this technique the maxillary elements are united to the prolabium and do not meet each other. This provides a wider lip, but shorter. Growth and lengthening of the lip appears to occur and a better result occurs with this loose, wide, shorter lip.

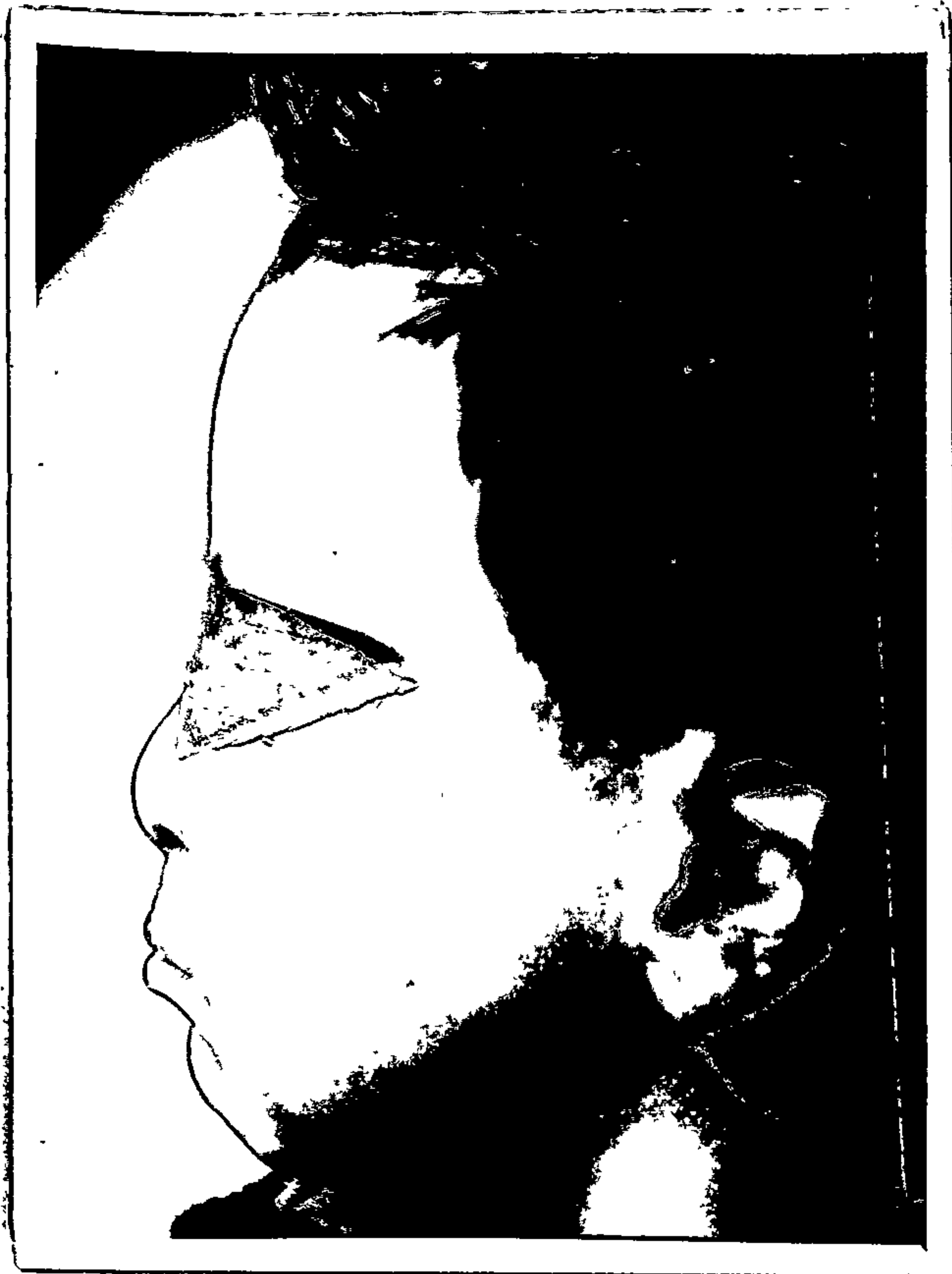

Figure (91.)

This is the profile of the previous patient. Here may be witnessed a satisfactory lip position, although slight bunching below the nostril did occur. Comparison of this with Figures <sup>93,</sup> (22) indicates that this technique provides better aesthetics and normal lip tone. The abnormal tense lip that tends to counteract orthodontic movement does not occur.

This technique erradicates the use in many cases of an Abbe type operation later.



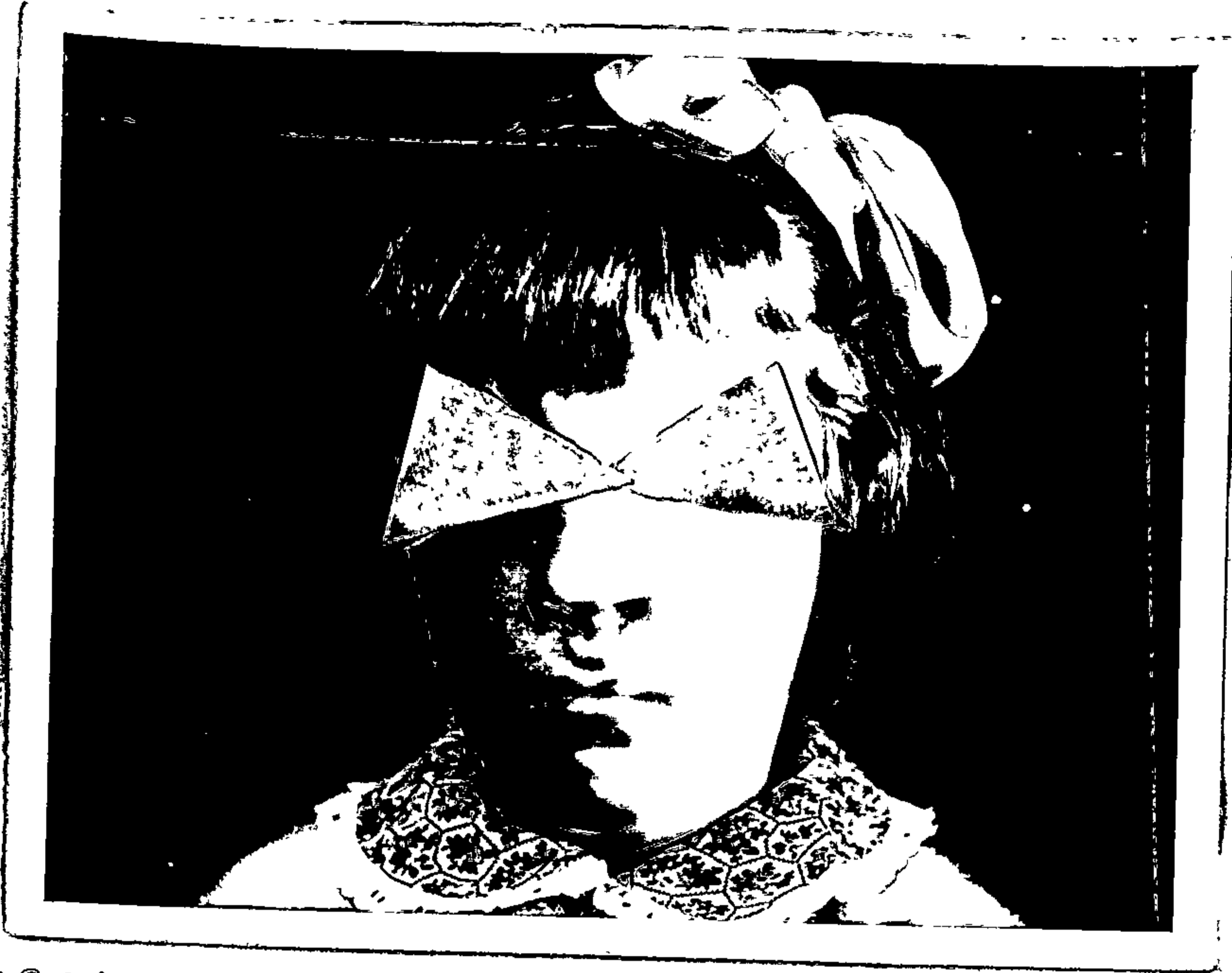

Figure (92)

Anterior view of the surgical technique that provides a tight upper lip. This fact is important, for orthodontic treatment and growth potential may be influenced by such a structure.

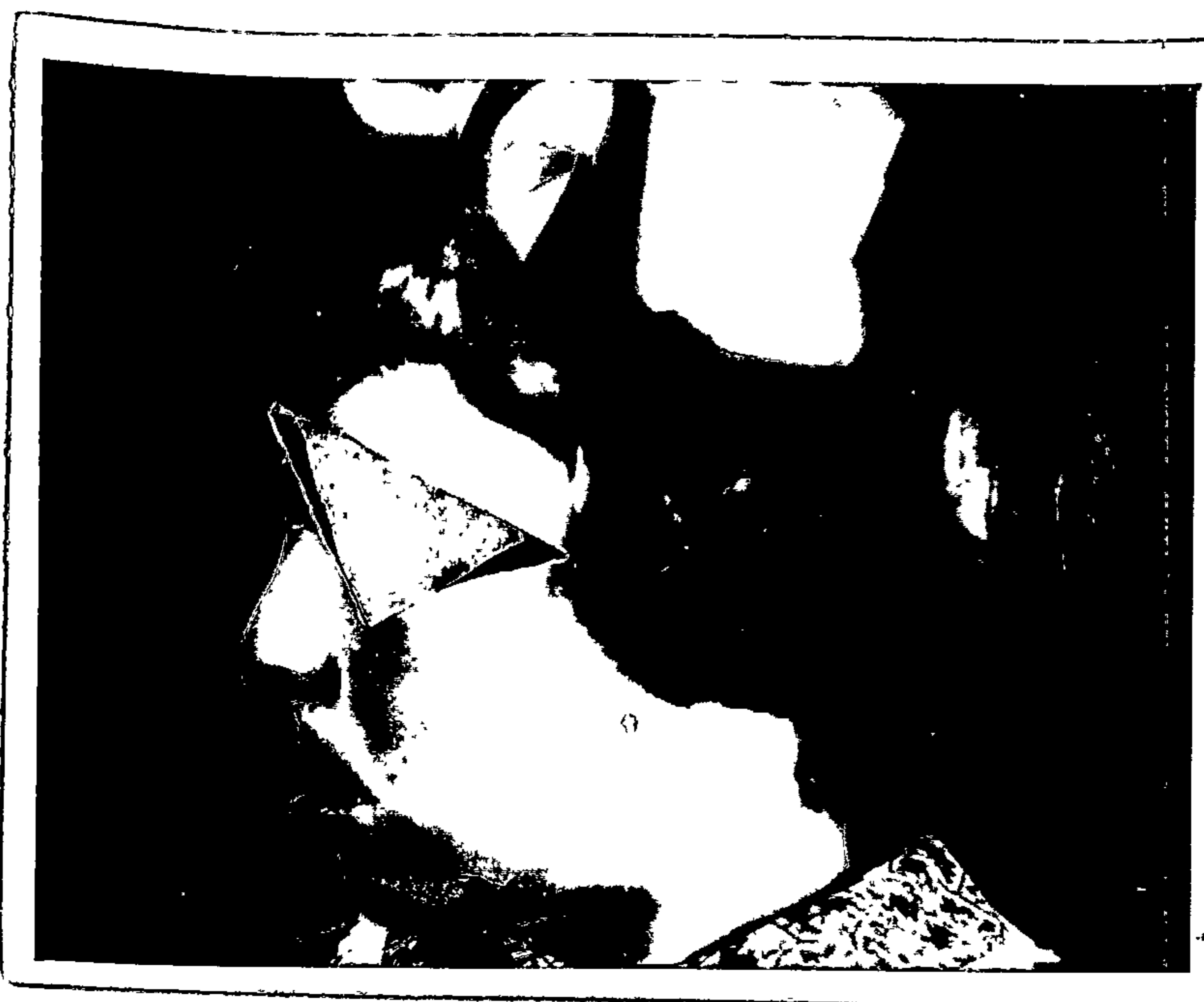

Figure (93.) This lateral view illustrates the tight upper lip that may result from this single surgical closure technique of uniting the maxillary lip units beneath the probalium.

The lip is tight and long and provides a marked contrast to the mandibular lip which appears constantly pouting.

As previously stated, this type of lip may influence bone growth, premaxilla and orthodontic therapy for collapsed arches.

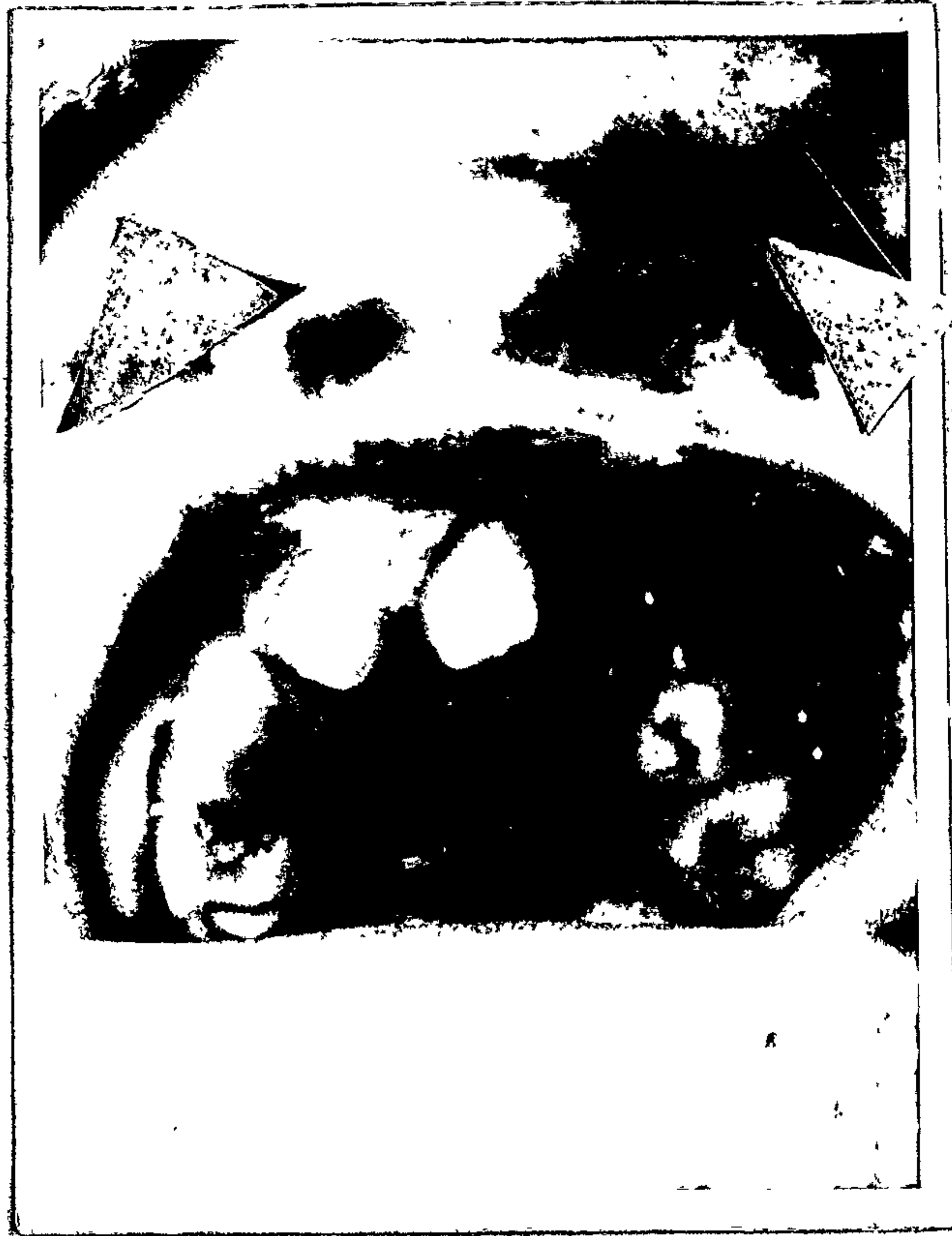

Figure (94)

This oral view of a bilateral cleft lip and palate illustrates the contracted arch and the rotated central incisors. The caries incidence was noticed here to be raised also.



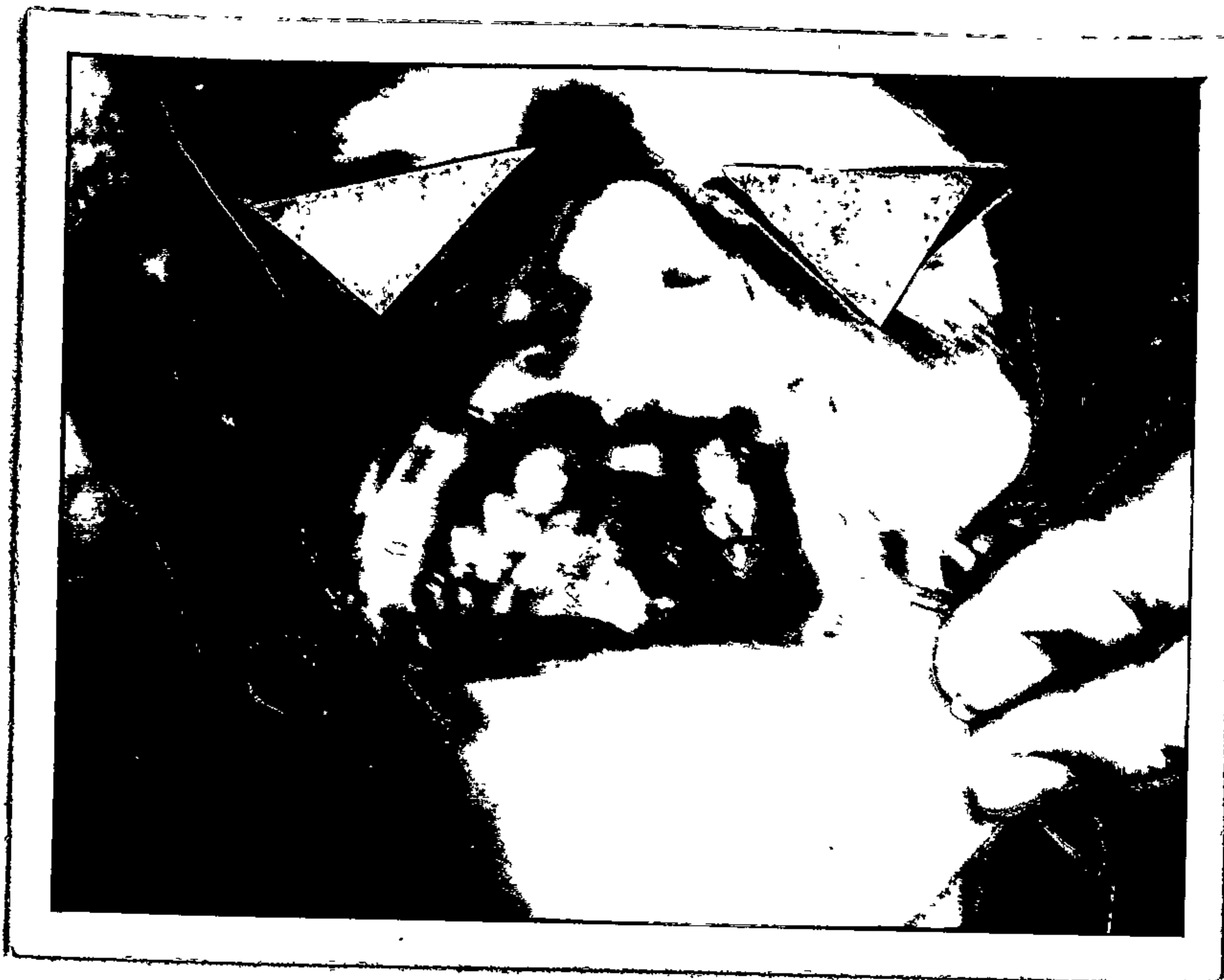

Figure (95)

This oral view of a bilateral cleft lip and palate illustrates the palatal cleft and the collapsed maxillary arch. The right nostril was slightly flattened and distorted.

The degree of cicatricial tissue labial to the premaxilla is an important factor for growth and orthodontic movement.

In the early deciduous years the premaxilla often protrudes, and during this phase of growth it acts as a stop, restricting downward and forward growth, fixing this unit between the two gradually collapsing buccal segments. Figure (90).

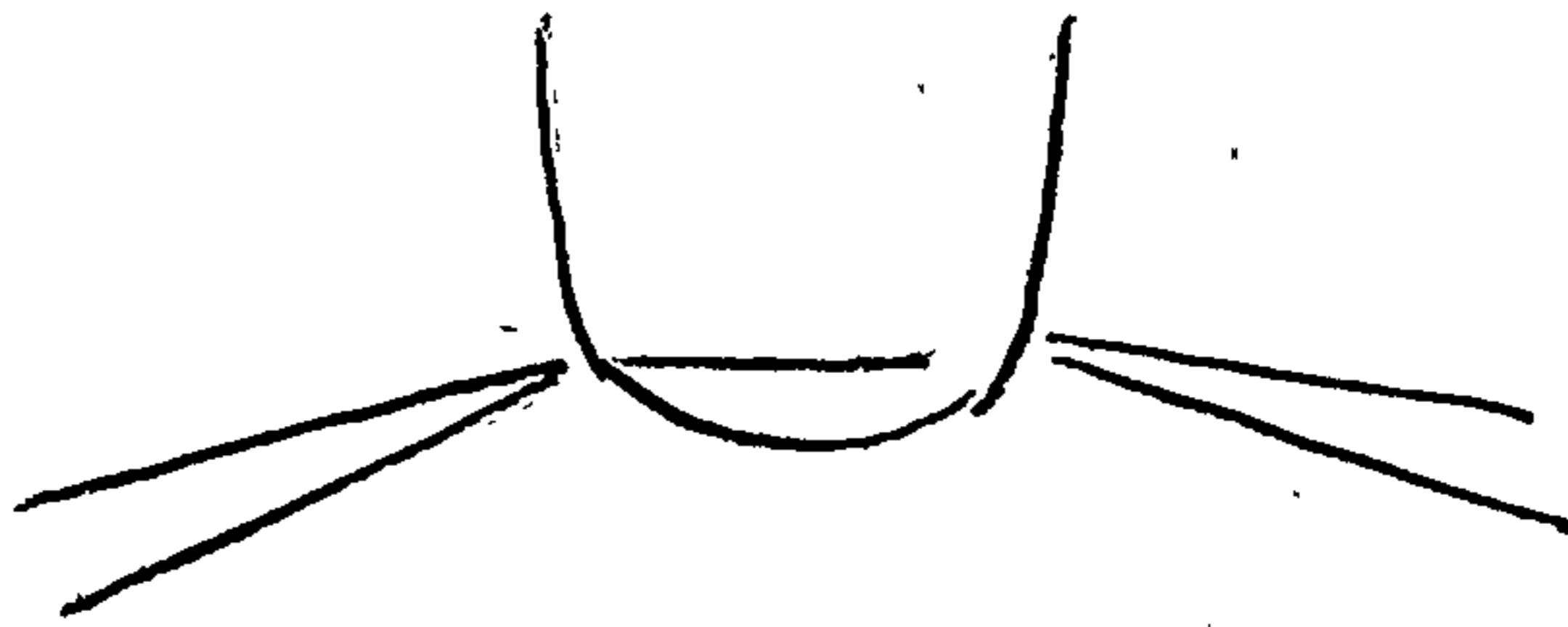
The type of upper lip that results will vary depending upon the surgical approach, (described in the surgical section). Brief reference to Figures 90 AND 92 will illustrate the two types of resulting lip.

In type (a) a free wide maxillary lip with slight cicatricial tissue as stated above may occur in the labial sulcus. This aids therapy by presenting a possible resistance to forward growth of the premaxilla, but when orthodontic treatment is instituted, hinders distal movement of this segment and incisors.

The tight upper lip may tend to restrict the maxilla in development and growth and provide an arch similar to that illustrated in Figure 88(a). In some cases where this type of surgery was used, the premaxilla was found to be lacking.

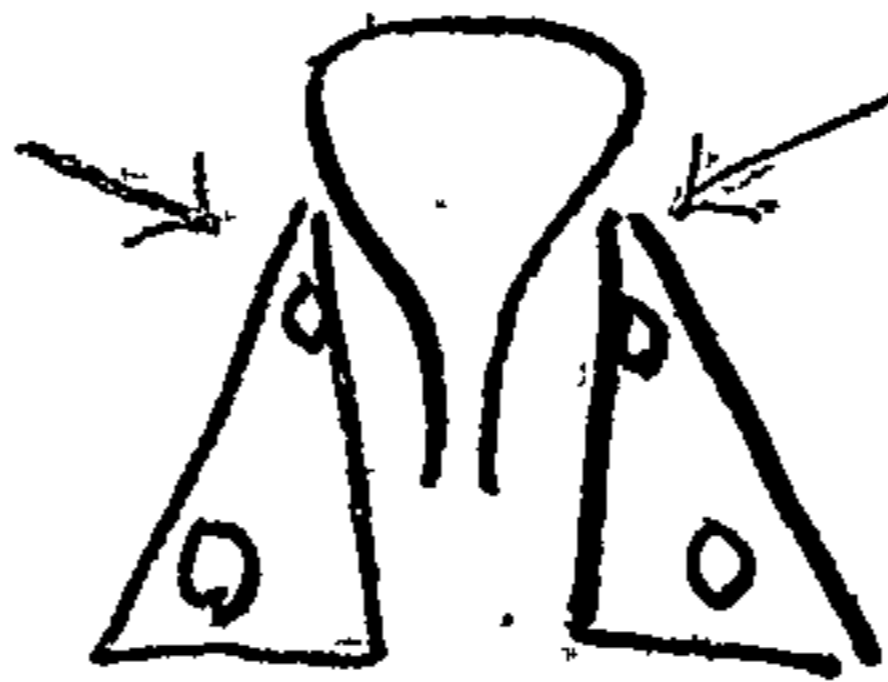
Figure (9b)

A.




A wide flaccid  
free lip.

B.



C.



A long narrow  
tight lip.

Where a thin tight upper lip occurred, collapse of the buccal segments was more marked than with other surgical procedures, and proved a hazard in expansion technique. This surgical procedure also was noted as the main supply of candidates at a later age for the Abbe type "V" switch. The wider upper lip technique provides a maxillary lip a little short and frequently notched. This may necessitate secondary surgical operations.

Of a few cases observed, the lip appears to lengthen and the notch disappear, the lip becoming more uniform, and the flaccid lip then presents ideal condition for the expansion bilaterally of the palate and retraction of the premaxilla by either surgical or orthodontic procedures.

Frequently the palatal repair is deficient and the cicatricial tissue resulting an important factor. Grafts are not always desirable as odours have resulted from sweat glands



included in the tissue.

The deficiency in a palatal repair tends to aid orthodontic expansion. During manipulation of materials and instruments, care should be taken of the premaxilla as this segment is frequently mobile.

Slight Fissural Fistula that may occur due to the forceful separation by the expansion technique, may be closed simply surgically or restored by a prosthesis later. Separation of tissue will occur only where the soft and hard tissue is cleft. Normal mucosa will not rupture during expansion.

The widening of the palate then provides more room for function of the tongue in movement. Correct articulation during speech therapy and positioning of the tongue to the hard palate and teeth is easier to perform.

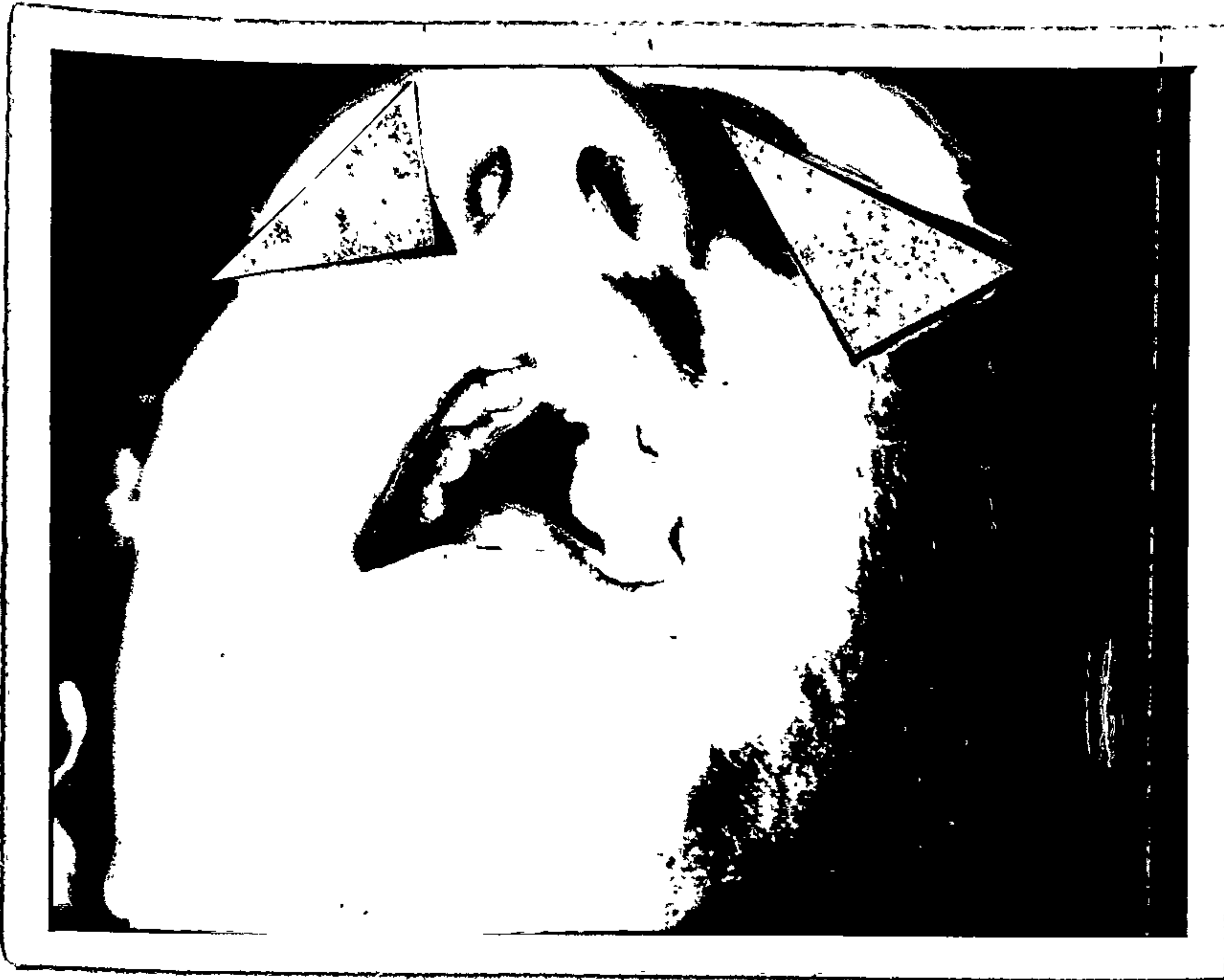

Figure (97)

Cleft of the hard and soft palates.

Surgical repair has restored the soft palate continuity, whilst the perforation of the hard palate still exists.

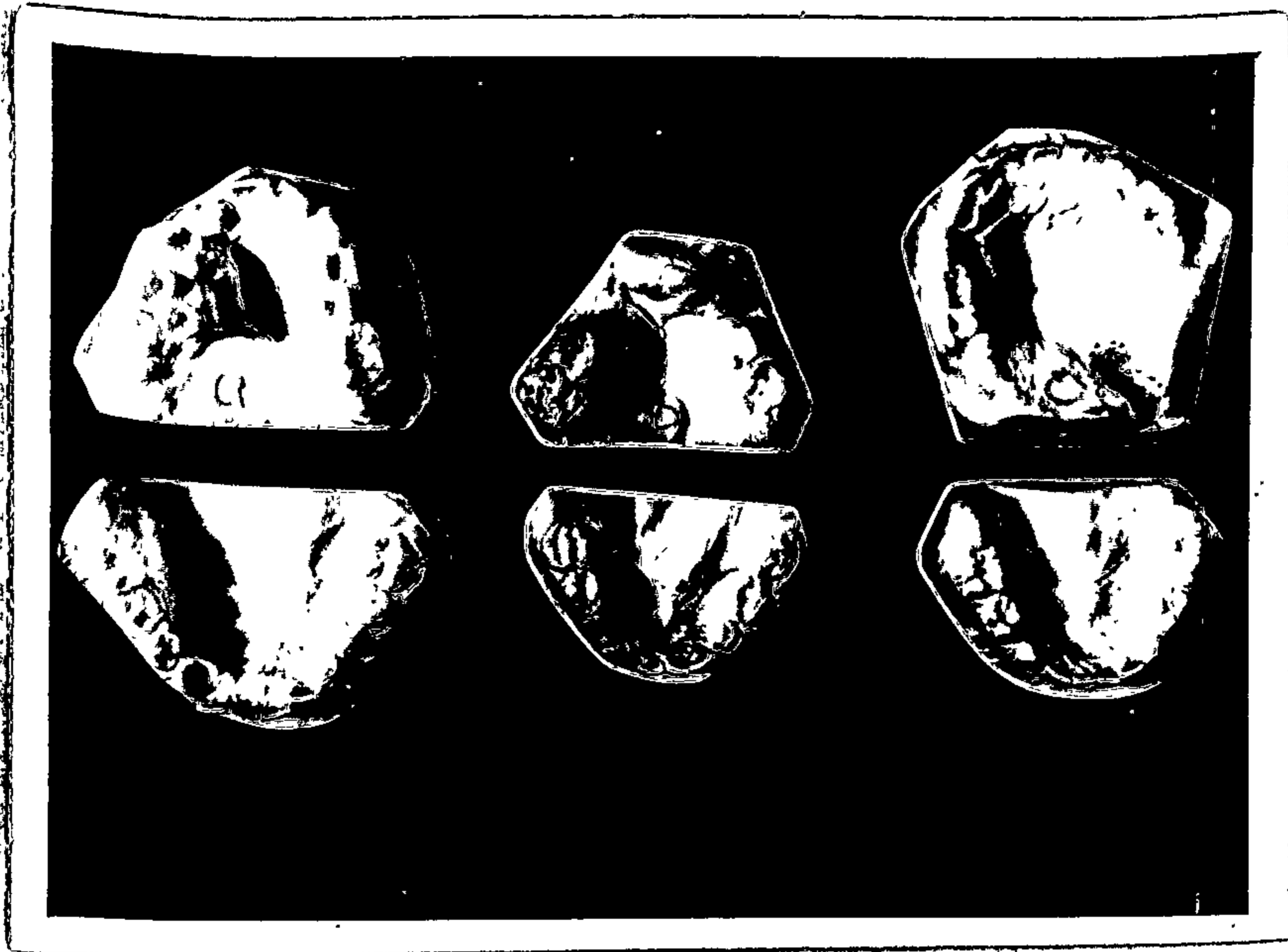


Figure (98)                      Comparison of various arch forms.

Cast (a) illustrates a unilateral cleft lip and palate with unilateral collapse of the maxilla. The width at the palate at the six year molar appears slightly constricted. There still persists a fistula to the nasal cavity from the oral cavity that requires a prosthesis to obtain closure. This type of case is typically seen, although the perforated palate is slightly uncommon to this marked degree. Compare with (b) and (c).

Figure (b) illustrates a bilateral cleft lip and palate and indicates the collapse and degree of cicatrization that results. Compare the inter-canine width with (a) and (c).

Figure (c) illustrates a cleft soft palate only. The maxillary arch is of good contour and the occlusion was normal. The cleft of the soft palate is as yet unrepaired. This shows the lack of effect that a soft tissue cleft may have upon arch form and occlusion.





Figure (99)      Illustrating the degree of the severity of  
clefts that occur at birth.

Type 4.

Cleft of the hard and soft palates

As previously explained, this group may or may not be influenced genetically. Pruzansky found that these clefts exhibited a higher incidence of mandibular micrognathia and malocclusion (e.g. Class II Div. I) than do other categories.

Observation clinically has indicated that the maxillae often shows increased width at birth and during the early deciduous dentition are usually associated with a normal mandible.

Radiographically the tongue may be seen positioned within the cleft at birth and during the deciduous dentition. Thus the introduction of a foreign body, the tongue, between the palatal segments may produce the increased width.

Following surgery to the palate and the change from deciduous to permanent dentition, there is frequently over a period of time, a marked decrease in the width of the maxilla to normal occlusion. A slight bilateral collapse was noticed in one case, but in most cases observed the occlusion was quite normal except where an associated Angle malocclusion occurred.

Four cases of Class II Division I were diagnosed and two of Class III malocclusion associated with existing clefts of the soft and hard palates.

89

Pruzansky recorded a cleft palate with width enough posteriorly to overlap the buccal segments of the lower arch and hence advocated in these rare cases contraction of the maxillary arch before surgical intervention.

No doubt the tongue is the main causative factor in expansion of this upper arch during the formative periods. It's removal from this posture will allow the facial musculature to mould the buccal segments to normal occlusion.

The object as with all malocclusion, is to establish normal inclined plane relationship of the teeth, arch form, harmony in size and width of the arches, arch relationship. This will occur when normal occlusion and symmetry of balance in oro-facial muscular tension are restored.

11

Ballard, Gwenne Evans, and many co-workers claim that other factors being normal teeth assume a position of equilibrium between the muscular forces, internally the tongue, externally the facial musculature of the lips and cheeks.

With cleft palate, the tongue once it has receded from the abnormal position between the cleft (if this occurs early enough) will allow these forces to act.

#### Treatment.

Surgical intervention repairs the anatomical defect. The occlusion is usually unaffected. Should collapse occur bilaterally, expansion will restore the occlusion. Where there is over-expansion, orthodontic therapy before surgical intervention is claimed to produce best results - Pruzansky.  
89.90

Contraction of the arch is hard to achieve by orthodontic therapy in the secondary dentition, and treatment should be undertaken in the deciduous and mixed dentitions. Abnormal tongue positions will produce abnormal neuro-muscular patterns in speech quite hard to eliminate once formed. Correction is



easier during the early formative period than in adult life. Thus the timing of orthodontic therapy is becoming an ever increasing essential for elimination of disturbed postural and Kinetic muscle patterns which underly the abnormal patterns of speech.

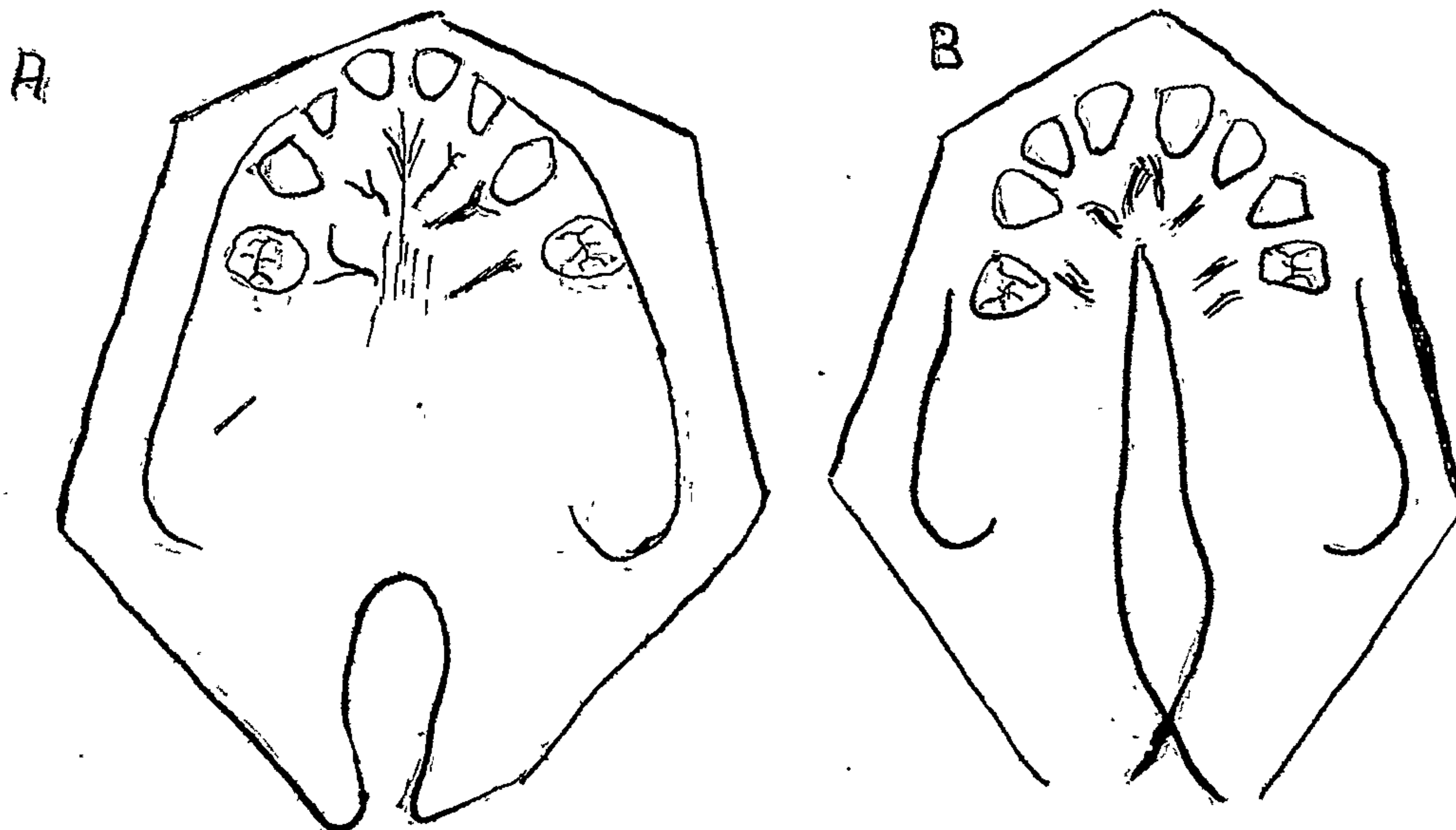


Figure (100)

Type A illustrates the cleft of the soft palate.

Type B is a cast of cleft of the hard and soft palate.

Type 5.

Cleft of the soft palate only.

This type of cleft was found to occur fairly frequently, but in most cases the occlusion was quite normal, as illustrated in Figure (98c)

The arch form and relationship are usually undisturbed, and axial inclination of the teeth normal. Close scrutinization of Figure (98c) indicates that the arch does tend to appear oval in character, rather than typical.

Cases presented by other clinics illustrated the same factors, especially where the cleft involved the hard palate as well. Surgical repair of soft and hard palatal clefts caused frequently a constriction in the arch over a period of time. However, where soft palatal surgery only occurred, then little change resulted.

This did tend to indicate that surgery was not a great influencing factor on growth where normal tissue existed.



Summary and Conclusion:

Practical results indicate that orthodontic therapy should be introduced at a pre-school age, as early orthodontic therapy will expand bilateral collapses and prevent early eruption of the lower incisors, reduce cross bites, expand unilateral collapse, and constrict widened palate in cleft of the soft and hard palate.

Late orthodontic therapy does not usually establish a normal occlusion.

Concerning the protrusiveness of the premaxilla in bilateral collapse cases, Pruzansky showed by cephalometric analysis:

"The downward and forward growth of the body of the maxilla and mandible seem to catch up with the premaxilla, which is now encompassed by the repaired labial musculature and held in rein by its' tensions."

No further literature to date has disproved this fact on growth. Frequently the deformity is so marked however, that surgical repositioning of the premaxilla is required.

The appliances most used were bite planes, and fixed labial arch wires, round or edgewise.

Pruzansky and colleagues used edgewise arch for rotation and distal movement of the premaxilla, and incisor teeth. Dr. Tout and myself use round arch wire.

Oral orthopaedic-orthodontic techniques establish a symmetry of balance in growth forces, and result in:

- (i) re-establishing contour of the face in the infra-orbital region in expansion of the maxilla.

- (ii) normal occlusion.
- (iii) facilitation of speech therapy where dental deformities are corrected.
- (iv) Providing tongue room
- (v) increasing masticatory power and normal ability to swallow.
- (vi) increased aesthetics.
- (vii) reduced prominence of the premaxilla in bilateral cleft cases.
- (viii) reduction of periodontal disease due to normal occlusion and arch form and reduced caries rate.
- (ix) increased width of palate, and therefore increased breadth of nasal floor.
- (x) a greater capacity for nasal respiration.
- (xi) decreasing mouth breathing, therefore reduces nasal, oral and pharyngeal infections.
- (xii) providing the potential for normal growth and development of the facial complex.

Disadvantages: Increased fistula size may provide increased regurgitation of food and liquid into the nasal cavity.

---

Observations have indicated that surgical palatal intervention alone does not necessarily provide collapse of the buccal segments or over-riding of their cleft borders. This collapse was found to occur usually in cases where cleft lip surgery had previously moulded the alveolar edges. The establishment of normal tension in facial musculature provides normal force against an unbuttressed palate and collapse occurs gradually.



This is quite frequently observed in cases that have been treated orthodontically and not retained.

The problem of retention is acute. In unilateral cases where over-expansion has been established, relapse will occur to varying degrees. Where retention is provided for some six to twelve months, usually a normal occlusion results. Should no retention occur, then orthopaedic collapse of the teeth and bone segments occurs, and frequently the individual teeth also move.

Rotated incisors are usually more prone to assume these previous positions and should be retained for six months.

Where bilateral orthopaedic and orthodontic expansion has occurred, retention is imperative. Should collapse occur following failure in retention, it is twice as marked as in the unilateral case due to the duplicate pre-existing collapse.

Retention should be maintained by means of an appliance or prosthesis for six to twelve months and even longer, following completion of orthodontia. At no stage during treatment should the appliance be left out, as collapse will result. During periods of rest in some unilateral cases, the occlusion will retain the expansion, but in most cases of bilateral expansion, collapse is rapid and ruins the occlusion.

Where surgical repair of a lip or palate is contemplated during or following treatment, the appliance should be returned as soon as possible to the oral cavity, especially where teeth are missing and incomplete proximal contact occurs. Collapse in these cases is rapid.



Whilst all these factors are considered in the child, it is not known what will be the result when the dental structures are destroyed with age and extracted, and the edentulous condition results.

Adult cases examined following old surgical procedures exhibit collapsed arches and deficient structures. As to whether the loss of the teeth later in life will provide collapse maxillae in unilateral and bilateral cleft lip and palate cases with to-day's techniques, cannot be answered as yet.

---



## CHAPTER 1.

Introduction. A prosthesis is a mechanical appliance used to restore loss of tissue or loss of tissue function. The aim of a cleft prosthesis is to restore normal mastication, deglutition and speech activity, and may be used as a substitute for an adjunct to surgery or orthodontia where destruction of part of the oral tissues has occurred.

In many cases of cleft lip and palate the maxillary lip may appear collapsed where anterior teeth are deficient, and normal functions mastication, deglutition and speech activity are disturbed. The speech has lost its resonance and has a degree of nasality due to excess nasal escape of air. This feature is being treated surgically today by the Hynes operation, but there still remains many patients who will not have surgery completed or cannot receive surgical treatment or have not received correct surgical approaches in their younger days.

These patients with deficient structures when clinically examined usually have respiratory infections and inflammation caused by the regurgitation of food and liquid from the oral the nasal passages. This regurgitation is typically displayed in the feeding child, who has a divided palate. The personality of the patient may be vastly affected and psychologically disturbed. Environmental standards may require that these physiological functions be practically normal; for speech is the main mode of expression and conveys the thoughts of the individual.

The degree of palatal deficiency varies greatly, Veau's classification of the palate divided the types into four, and the occurrence was found to be as follows:-



- |      |                                                                                     |       |
|------|-------------------------------------------------------------------------------------|-------|
| 1.   | Cleft soft palate only.                                                             | 20.8% |
| 11.  | Cleft of the soft and hard palate.                                                  | 30.8% |
| 111. | Cleft of the soft and hard palate associated with unilateral cleft lip and alveolus | 38.8% |
| 1V.  | Cleft of the soft and hard palate associated bilateral cleft lip and alveolus.      | 9.6%  |

Cloyd S. Harkins<sup>59</sup> has further sub-divided the cleft palates into six clinical types.

- i. Bifid Uvula.
- ii. Cleft soft palate only.
- iii. Soft and hard palate clefts.
- iv. Soft and hard palate clefts to the incisive suture.
- v. Cleft of the soft palate, hard palate, alveola ridges and one side of the lip. (unilateral)
- vi. Cleft of the soft and hard palates, alveola ridges and both sides of the lip. (bilateral).

It is interesting to note that acquired cleft palates do not appear to affect the speech tone to the same degree as does the congenital cleft. This may be due to the fact that patterns of speech and voice production have already been learnt and accommodations are easier. Protheses in these cases have shown clinically to quickly restore the voice production to normal tone.

The congenital type of cleft palate requires a rehabilitation programme that is intense. Voice production has to be built up with growth and development. Mounds, casts and radiographs provide records for comparison during growth. The child today receives an intense orthodontic programme, so that intermediate appliances are used to a greater extent. Malocclusions are reduced and articulation restored to a reasonably satisfactory standard. A prosthesis is

fundamental in establishing the entirety of the arch in most cases, for teeth are missing and during childhood and youth the caries incidence is fairly high.

The child of yesterday is the adult of today and when an adult presents for a prosthesis, in many cases, may display collapsed arches and maloccluded teeth with crowding. Edentulous cases are common due to the lack of early conservative treatment, thus making a prosthesis a difficult restoration to control during function with lack of retention, the tongue being sometimes called upon to perform this function. The least help in these cases will provide a well satisfied patient. Restoration of the occlusion is frequently difficult and in many cases, although improvement in speech tone results by the use of an obturator, it is not a marked improvement.

Classification of prostheses into types is difficult, for a prosthesis may be introduced at various stages in the total rehabilitation and be influenced by the desired result. Classification may be made using function as the division, subdivisions may be further made within these groups.

As with surgery, the success of a cleft palate prosthesis is largely measured by the speech result. Ivy states: <sup>64</sup> "The chief reason for closure of a cleft palate is to render as good a speech as possible."

The fundamental requirement of most appliances is speech improvement. The other acquisitions are secondary to a degree and easier to produce. The production of a restoration in this field requires a sound fundamental knowledge of normal denture construction,



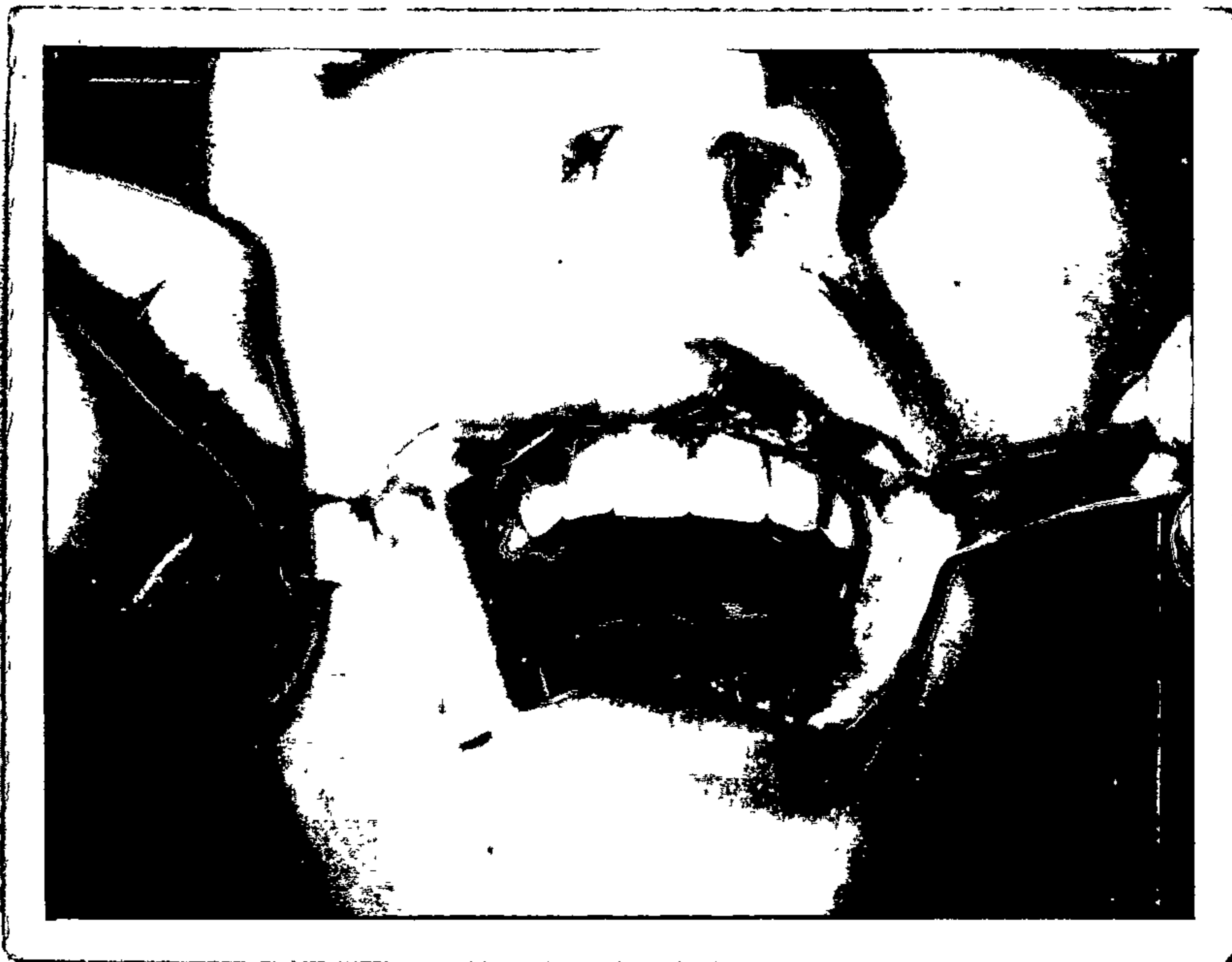the anatomy and physiology of the disability and the physiology of speech production, with an understanding of the influence of malocclusion.

74.34

According to McDonald, speech results from respiration, phonation, resonance, articulation and integration of physiological activities. When these are co-ordinated by the central nervous system they result in normal speech.

ORAL PROSTHETIC RESTORATIONS.

FIGURE.  
NO 101.





The Prosthesis. Improved speech is the main function of most prostheses, the other acquisitions are:-

1. Hard palatal cover.
2. Soft palate restoration.
3. Obturators controlling oro-nasal communication.
4. Restoration of lost dental structures.
5. Restoration of facial contours and aesthetics (correction of retrusion of upper lip).
6. Increased masticatory efficiency.

The need for a prosthesis is indicated in the following clinical circumstances:-

- i. In cases where dental structures have been lost and the lip is flaccid, retruded and collapsed.
- ii. Where the soft palate is complete and re-union by surgery a success but the hard palate contains an oro-nasal communication, bounded by hard cicatricial tissue. In these cases the palatal cover will restore the deformity where surgery has failed.
- iii. Failure to close the soft and hard palate by surgery, is rare today, but cases do exist. In these it is necessary to use a prosthetic restoration and speech aid combined - the prosthesis.
- iv. The patient that refuses further surgery may be treated with these restorations.
- v. During phases of rest in orthodontia, it may be necessary to use a retainer to prevent collapse incorporating at the same time teeth and tissue restoration.
- vi. To aid speech where the soft palate is deficient and surgery no longer intended.

Recent observations have indicated that the best speech results from an early surgical treatment (at two years) of the soft palate.

An appliance may be necessary for the above reasons and consequently may be divided into different types.

## Appliances.

Type "A". To aid feeding in the first three years.

Type "B". Speech aids after two and half years of age, including intermediate or final prosthetic restorations combined with obturators where the hard and/or soft palates are deficient. The latter of these may be termed a permanent prosthesis. An intermediate prosthesis may be used during phases of surgery.

Type "C". Prosthetic restorations where the soft palate is complete and functioning or where a Hynes operation has been performed but a hard palatal defect exists.

Type "D". Splints for surgical procedures, either protective or fixative.

Type "E". Retainers used during orthodontic treatment.

Type "A". These have been described in the appropriate section of feeding and nursing. Reference will be made here to some of the types proposed.

- i. The Wearn artificial palate.
- ii. The Brophy nipple.
- iii. The Davot cleft palate nipple.
- iv. Kelsey Fry's teat holder.

The construction of these appliances may require the impression of the maxillary unit. This may be quite difficult in young children and a general anaesthetic may be necessary. These aids are usually required only in the first three years of life and do not interfere with normal speech development.

The nipples have a function that tends to resist the collapse of the maxillary arches in the bilateral cases.

Type "B". Speech aids may be constructed after the first two and half years of life. Rapid progressive pharyngeal growth has subsided at the age of two years and in bilateral cleft cases the pterygoid plates may be spread providing a wider pharynx. In cases where it is decided to leave palatal surgery till four or five years of age speech aids may be constructed.



84.

Oldfield M. C. has stated that the best speech results exist in early treated palates and Harkins<sup>59</sup> states that faulty speech habits should be prevented as soon as possible and advocates the use of a simple speech aid before the eruption of the deciduous teeth is completed.  
Intermediate group. 4 - 6 years.

Their use is further indicated in the child where palatal surgery has been unsuccessful and velo-pharyngeal closure does not occur. Where a short mobile palate exists is often better treated by a Hynes' type pharyngoplasty surgically. However, at this age, in certain cases where a cleft of hard and soft palate exists a speech aid may be necessary due to reduce rhinolalia.

The 4 - 6 year intermediate group may exhibit a wide pattern of variations. The function of the speech aid at this age is to regulate the air column to the oral cavity preventing nasal escape during speech and deglutition.

Fundamentally it may restore more than just deficient soft tissue and osseous structures, as is frequently seen in the third group of permanent speech aids.



Permanent speech aids.

These may be necessary where there exists permanent oro-nasal communication through failure of surgery to restore anatomical continuity of the soft and hard palates. Collapse of the maxillary lip exists where the premaxilla is deficient or missing and loss of teeth may result in disturbed speech. The soft palate may be cleft and scarred. These features associated with dentulous or edentulous alveolar arches, rarely containing all teeth, are the characteristics of the post-surgical prosthetic group.

The divisions of a speech aid are:-

- A. Palatal cover for the hard palate.
- B. Velar section or connector.
- C. Obturator.

Part A. The palatal cover: may be of acrylic or chromium cobalt or gold, depending upon whether there are teeth present, oral hygiene and caries rate. Where an anterior palatal perforation exists, an anterior obturator may be constructed. Frequently teeth are lost and the structures resemble a partial denture. At all times the denture base must respect the fundamentals of denture construction. The design should be influenced by the saddles present and may be -

- i. tooth borne.
- ii. tooth and tissue borne.
- iii. tissue borne.

Edentulous cases present complicated problems of retention and the palatal anterior obturator may be the only means of retention by obtaining a lateral spread into the nasal cavity floor. One adult case treated contained little palate at all, the cleft being one and half inches wide and retention was very hard to obtain.

In partial edentulous conditions the teeth present must take the

force of contraction of the remaining substance of the repaired soft palatal muscle and the approximation of the superior constrictor to the obturator posteriorly and the denture must defeat the force of gravity. The retention must be good and little hope is usually possible of complete stress breaking although fundamental principles may be incorporated. It may be necessary in selected cases to prepare crowns for bicuspid and molars, this may facilitate retention.

The palatal section must be light, durable and aesthetic. Where teeth are carried in a speech aid prosthesis, it is possible to restore the lip contour to normal and often where anterior teeth are replaced, the normal overjet and overbite relation may be established. Such a denture may close too, a labial communication to the nasal cavity, and restore the tissue lost by the cleft.

Complete rehabilitation of the oral cavity is required and where a tooth erupts out of alignment, it need not necessarily be extracted but may be used for retention, being incorporated in the palate of the denture. Modifications to the tooth may be necessary.

Such dentures may be used in children as retainers during rest periods when orthodontic therapy has provided a suitable arch.

It was once considered favourable to excise a floating pre-maxilla and restore by a prosthesis. This manoeuvre is not used today, in most cases it is retained and the prosthesis constructed around the developing anatomical parts wherever possible. The pre-maxilla is only removed in cases of very exceptional severe mobility.

Part "B". The connector.

Connectors have been experimented with for many years. This section occupies the defect of the soft palate and connects the hard



palate cover with the obturator. The materials used for these appliances have been:-

- i. Methyl methacrylate (acrylic) hard and soft variety.
- ii. Cast gold.
- iii. Vitallium.
- iv. Wrought wire.

Types have been:-  
a. fixed.  
b. moveable.

Fixed connectors may be constructed from the above materials and depend upon the compensation of the anatomical structures to function around this non-movable body. The structure will depend upon the size of the cleft.

The muscles concerned in closure of the soft palate and posterior pharynx are as follows:-

Soft Palate. Musculus uvula, palatopharyngeus, palatoglossus, levator palati and tensor palati.

Pharynx. Salpingopharyngeus, stylopharyngeus, superior constrictor.

These muscles will in turn either directly or indirectly exert forces upon the connector and tend to disturb its position if not accurately placed. It should be placed so that it is in line with or slightly above Passavant's cushion<sup>38</sup>, often just slightly above the normal position of the soft palate. The connector should be well constructed muscle trimmed and function easily in speech and deglutition, replacing the continuity of the soft palate.

They are used in the pre-surgical or post-surgical periods and in the latter, little abnormal change will result through their continual use, in the positions or growth of the soft tissue, including the muscle fibres.



The best results have been obtained with the Suersen fixed type, the patient compensating fairly accurately in most cases.

The moveable type has been experimented with in many ways to present a soft palate that physiologically would replace the function of the velum. The results, in most cases, were disappointing. The types used were the Pinlock Hinge, Kingsley, and soft acrylic. Soft acrylic deteriorated rapidly and did not produce satisfactory results.

The Hinge type did not move physiologically and its advantages were lost. Besides being complicated and hard to make its cost far outweighed its advantages, and necessary repair rate.

The fixed type is the main type used today, this replaces the soft palate tissue loss and compensates theoretically for soft palate function during speech and deglutition. The two types that have proved successful are the Fitz-Gibbon all-metal prosthesis, and Wright's all-acrylic style, especially useful as an intermediate temporary style appliance.

Part "C". The bulb or obturator.

Anterior - attached to the hard palate cover - used for a deficiency in the hard palate

Posterior - (attached to posterior end of) the connector for palato-pharyngeal closure.

The size of the posterior obturator varies with age and development of the pharynx and the degree of movement of the lateral and posterior pharyngeal muscles. Both the anterior and posterior obturators may be wide or narrow, depending upon the loss of tissue and the closure desired.

The function of the obturator is to establish closure, forming complete separate oral and nasal cavities during physiological closure. This is normally accomplished by velo-pharyngeal function. The soft palate contacts the posterior pharyngeal wall at Passavant's cushion region and the lateral walls of the pharynx contact the soft palate, completely closing off the communication in deglutition and in special phonations such as "K".

The pharyngeal section is placed reasonably high, usually in the same plane as the connector. If placed too high or too low, it does not function. Function and position is measured by the degree of nasal escape of air, the resonance produced, and the improvement in speech. Frequently, to provide an anatomical correct connector and obturator it may be necessary to surgically re-divide a badly united mobile palate. Unless this is done the connector and obturator may be continually moving and fail in function.

The position the obturator should occupy is just anterior to Passavant's pad where it is functionally stable at rest.

For positioning and adjustments, the posterior of the bulb may be covered with tinfoil or a lipoidal type substance and lateral cephalometric rays taken during function. During deglutition it should just contact the posterior pharyngeal wall at Passavant's ridge region.

Precise progressive muscle trimming will establish a well functioning obtuator at the point of maximum constriction of the pharynx. The bulb is usually constructed of acrylic and reinforced, and is either hollow or solid. Clear acrylic is well tolerated by the tiss-



ues and does not irritate the superior constrictor (which may be observed functioning), unless over-extended. By using low fusing wax in construction and moulding a well functioning appliance results.

<sup>69.34</sup>  
McDonald has shown that complete nas-pharyngeal closure is not necessary to prevent nasal speech but that a critical point must be reached.

Type "C". Where the soft palate is complete or functioning, or a Hynes type pharyngoplasty has been utilized, a prosthesis may be required to restore the continuity of the arch and the loss of palatal tissue by the cleft.

The patient is usually partially edentulous and in most cases the arch is uniform in contour in the adult, if restored by orthodontia. The construction obeys the rules for partial denture construction. Retention and stress breaking will depend upon the size of the palatal cleft defect and the saddles present. The material used may influence the design, "Chromium Cobalt" dentures usually providing a very satisfactory result.

Type "D". Splints either protective or fixative.

Surgery frequently requires that a splint be constructed to post-operatively maintain a dressing or preserve non-interference to palatal sutures during post-operative periods of convalescence, especially in children. This may frequently be provided by a wire frame appliance arranged across the palate.

The splints used mostly in cleft palate surgery are for repositioning the premaxilla. In bilateral cleft palate and lip cases the premaxilla is frequently protruding and mobile. This type produces hazards in the adult and frequently the premaxilla was excised to



provide a normally functioning denture. Today it is preferred to remove a section from the vomer and reposition the premaxilla distally in an approximately normal position. Orthodontic treatment in these cases does little but tip the upper incisors distally and does not provide distal movement for the bulbous premaxilla. This was shown recently by Dr. S. Tout at the Royal Alexandra Hospital for Children, Sydney.

The types of materials used for these cases where surgical reduction is indicated are:-

- i. acrylic splints.
- ii. silver cast ferrule splints.

Where only a few teeth exist support is better obtained by an acrylic base with either wire or cast ferrule retainers as illustrated by Cloyd S. Harkins<sup>59</sup> and McDonald<sup>74</sup>. Retention may be complicated in these cases. One case attempted personally had four deciduous molars with no teeth in the premaxillary element. Retention of the splint was very difficult. These cases are better attempted early so that orthodontic treatment may later expand and restore the occlusion.

Cast ferrule splints, where teeth are standing, provide good results but the deciduous teeth are bulbous and points of retention few.

Stabilization of the splint may be obtained through a head cap. Professor Arnott, Kelsey Fry, Archer and other texts illustrate the means by using a plaster head cap, universal points and metal rods. One single midline support connector is advised, for this provides less interruptions and disturbances to the functioning orbicularis oris and mandible, facilitating feeding and oral hygiene.

A prosthesis may act as, or be constructed for, epithelial inlays which as Thiersch grafts are placed in the labial or buccal sulcus. These appliances are constructed with gutta percha to mould the lip and hold the graft in place whilst healing and taking of the graft occurs, the gutta percha being later replaced by an acrylic mould. Type "E". During periods of orthodontic rest it is necessary to retain the established occlusion. Dr. <sup>130</sup>Tout has shown that this is especially necessary in cases where there is further surgery undertaken during these periods. The retainer should not be left out longer than twelve hours for the collapse is rapid and dramatic.

The movement is not just orthodontic, orthopaedic separation of the bony segments has occurred and this has been achieved against the forces of the muscles. The dynamic force of the appliance has to overcome this resistance and then exert enough force to move the teeth and the bony segments. Removal of a retainer leaves these unbuttressed segments unsupported against the forces of the lips and collapse occurs.

These retainers may be simple in design or complicated, depending upon whether dental units and soft tissue are restored. In these cases the prosthetic restoration also acts as the retainer.

Speech requirements of a prosthesis.

Speech is controlled by the physiological function of respiration, phonation, resonance articulation, intergrated by the central nervous system. Respiration controls the expiratory rate of air which is set in vibration by the laryngeal cords.

The tongue alters its position in the oral cavity and varies the stream of air escaping. The difference between a vowel and a consonant is a graduation from "S" to "A" in the size of the oral cavity. A small opening produces a consonant and a large opening a vowel. The tongue is a very important mechanism and is approximated to the palatal roof. The heights and different positions of approximation of the tongue and the palate produce the different sounds.

<sup>74.34a</sup> McDonald and <sup>69.</sup> Baker contend that complete closure of the nasopharynx was not the entire important factor. The crucial point they claim is a balance between naso-pharyngeal closure and the position of the tongue and mandible, which determines oro-pharyngeal closure. In a cleft palate both these disturbances occur and a nasal speech results.

The construction of the palatal cover becomes then a very important feature. The correct vertical dimensions and incisor relation will influence speech production. McDonald claims that the palatal cover should restore normal anatomy and teeth that erupt palatally should be covered if satisfactory, but if appearing above the contour of the palate be extracted or reduced and crowned. This is to prevent reduction in the volume of the oral cavity. The appliance should be constructed to allow correct movement of the tongue and positioning to the palate.



CHAPTER 11. Speech and Speech Therapy.

Introduction. The anatomy of cleft palate speech is such an extremely complicated process involving the delicate integration of so many anatomical parts which may be used for other functions, that its definite control and function is not completely known. Speech results obtained in cleft lip and palate patients are still far from satisfactory. <sup>77</sup> Morley defines normal speech as "speech which is intelligible, natural and free to the trained ear from defects typical of cleft palates and equal to that of the patients environment."

It is not known as yet whether normal speech may be obtained in all cleft palate cases. It is a mechanism that has been phylogenetically placed on the vegetative pathways of respiration and deglutition. Speech requires fine adjustments of control by neuromuscular balance. The myodynamics and physiology of the voice mechanism have been completely explored and its character is dependent upon many associated factors which include resonance and the auditory mechanism. Hearing has an important foundation in speech and many cleft palate children have auditory deficiencies.

Resonance and voice production are dependent upon the passages of the pharynx, nasal and oral cavity and the character of the basic osseous. Cranial structures such as the maxillary and frontal bones and their associated sinuses. Whilst the fundamental control is neurological and dependent upon the cyto-architectural formation of the cortex and its development in relation to primary and associated areas, the control of speech is complex.

The neurological cortical areas of speech were first examined in

82.122.123.

1861 by Paul Broca, a French surgeon, who correlated aphasia (loss of the expression of speech) to a small lesion at the posterior end of the third frontal convolution of the dominant hemisphere.

The theory of limited areas being appropriated to different functions in the cerebral cortex as suggested by Broca and Hughling Jackson is being replaced today by the theory of cyto-architectonic formation, the cortex containing six distinct layers, and the areas are not sharply delineated as previously conceived. Different areas of the brain were donated specific numbers.

Area 24S when electrically stimulated yielded alteration in blood pressure, heart rate and respiration and also movements of the lips and vocalization. Thus area 24S must be related to emotional expression. In monkeys where the hippocampi are destroyed, emotional reactions and facial expression are lost.

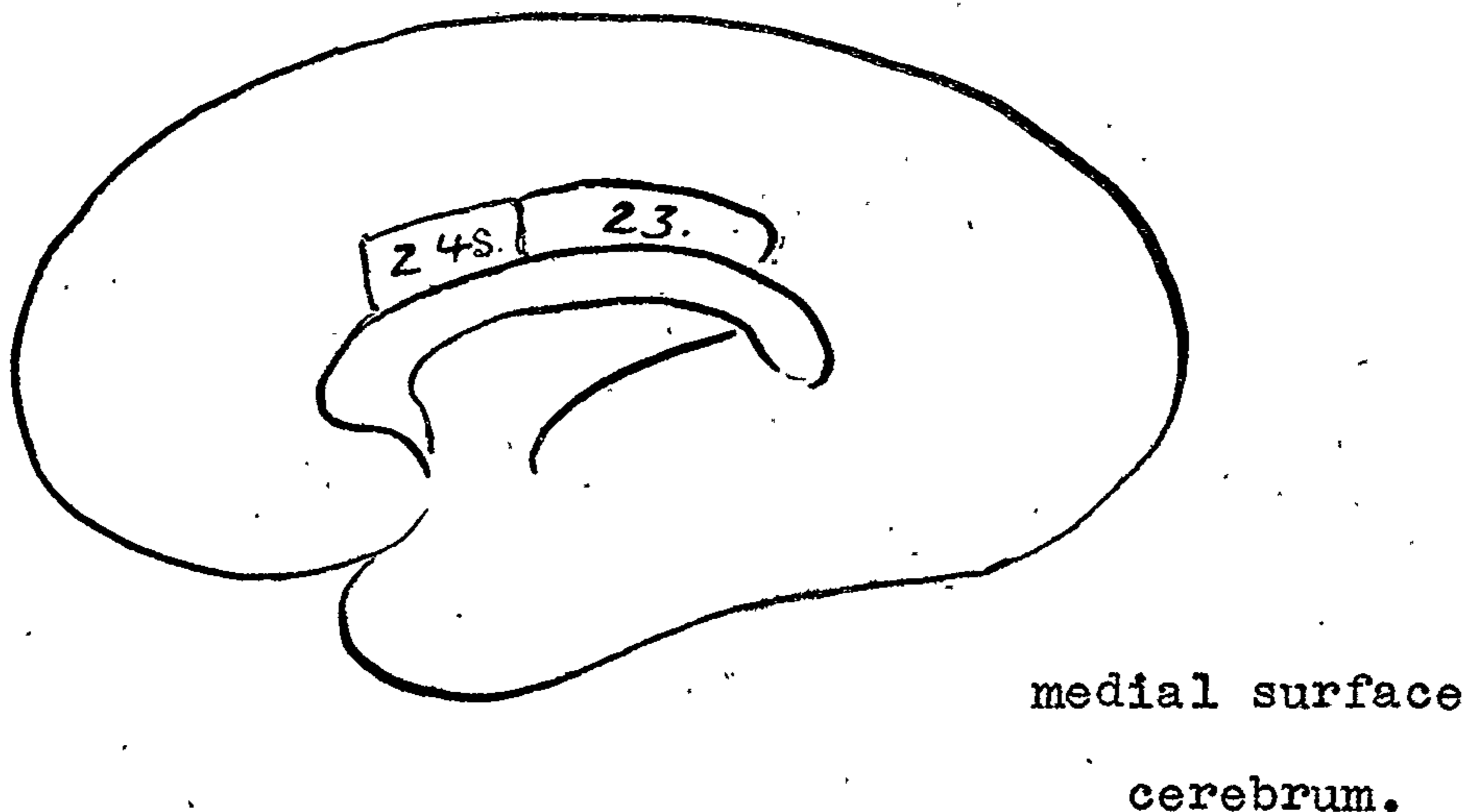


Figure. 102

The sensory motor cortex occupies the lateral parietal lobe and is divided into primary and association areas.

The frontal association areas 9, 10, 11, 12, 13, 14, in the



orbito-frontal pole receive afferent fibres from the dorso-medial

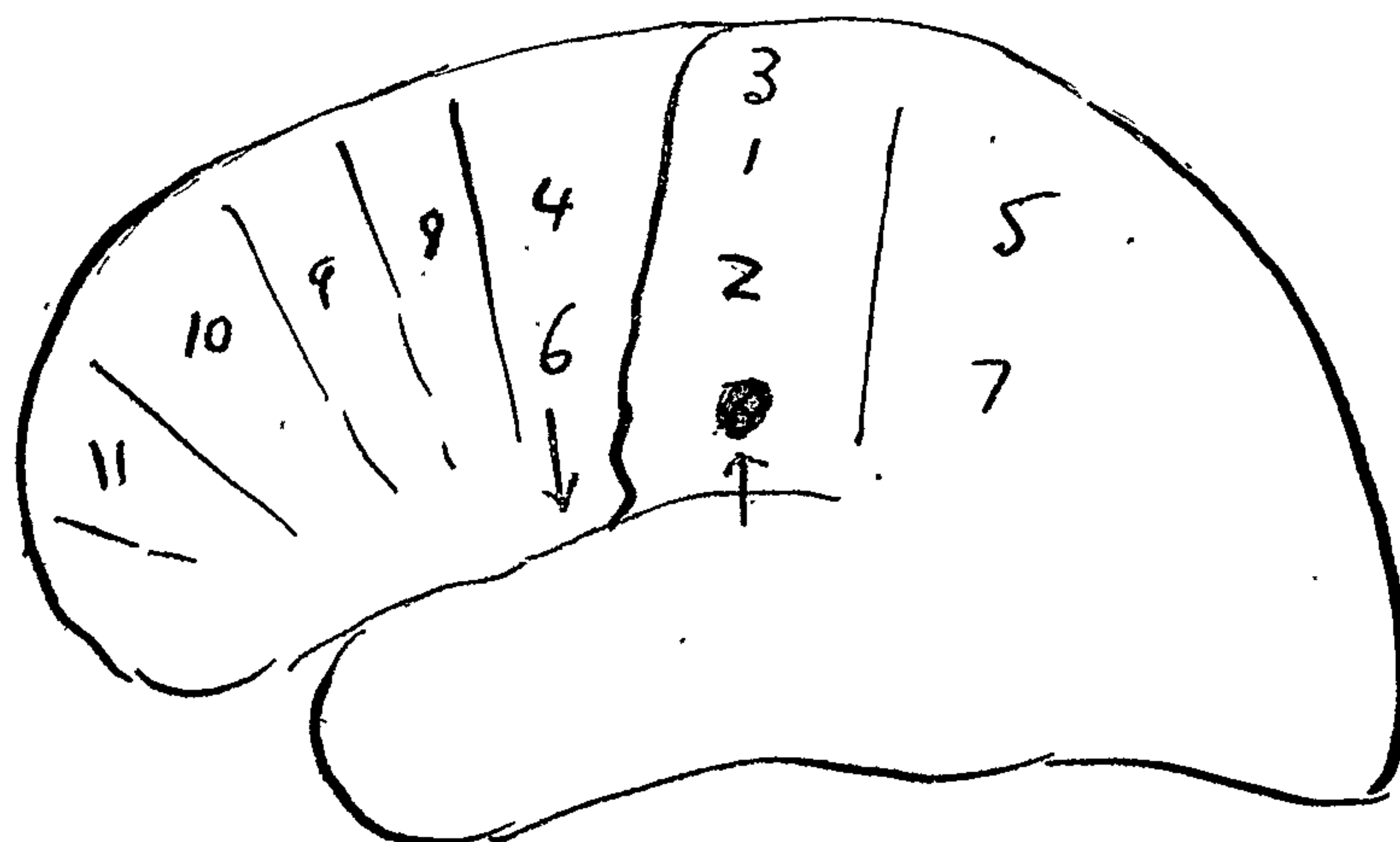


FIGURE 103

nucleus of the thalamus which conveys impulses from the hypothalamus and are concerned with the visceral sensory process which may include and influence speech.

The sensory motor cortex in turn sends efferent stimuli to the same thalamic nuclei which project the afferent fibres to the cortex and it appears that the pulvinor and thalamic nuclei serve as association centres for sensory impulses reaching the thalami. The cortical representation of the lips and tongue is proportionally much larger in the sensory cortex than arm or leg and this may be due to their high functional importance in speech and other functions.

The face, mouth and larynx appear to have a bilateral representation in this cortical topographical organization.

The sensory exteroceptive sensations are represented in areas 3, 1, 2, 5 and 7. whilst proprioceptive sensations in areas 4 and 6.

It was found that extensive destruction by lesions of the posterior part of the dominant parietal lobe caused a sensory aphasia. In this condition the patient is completely unable to grasp the content or meaning of the word or sentence and the patient loses the function of correct verbal expression in speech and articulation.



Area 4 is the final common pathway and motor projection from the cortex for speech control. The extra-pyramidal system, areas 6 and 4, 5 and 7, are concerned with complex involuntary reflex movements - swallowing - deglutition and may be concerned in speech control and pauses in speech.

Area 44, at the foot of precentral gyrus, is concerned with chewing, grunting swallowing and licking and lesions or disturbances have shown to cause abnormal movements of the jaw, tongue, palate and

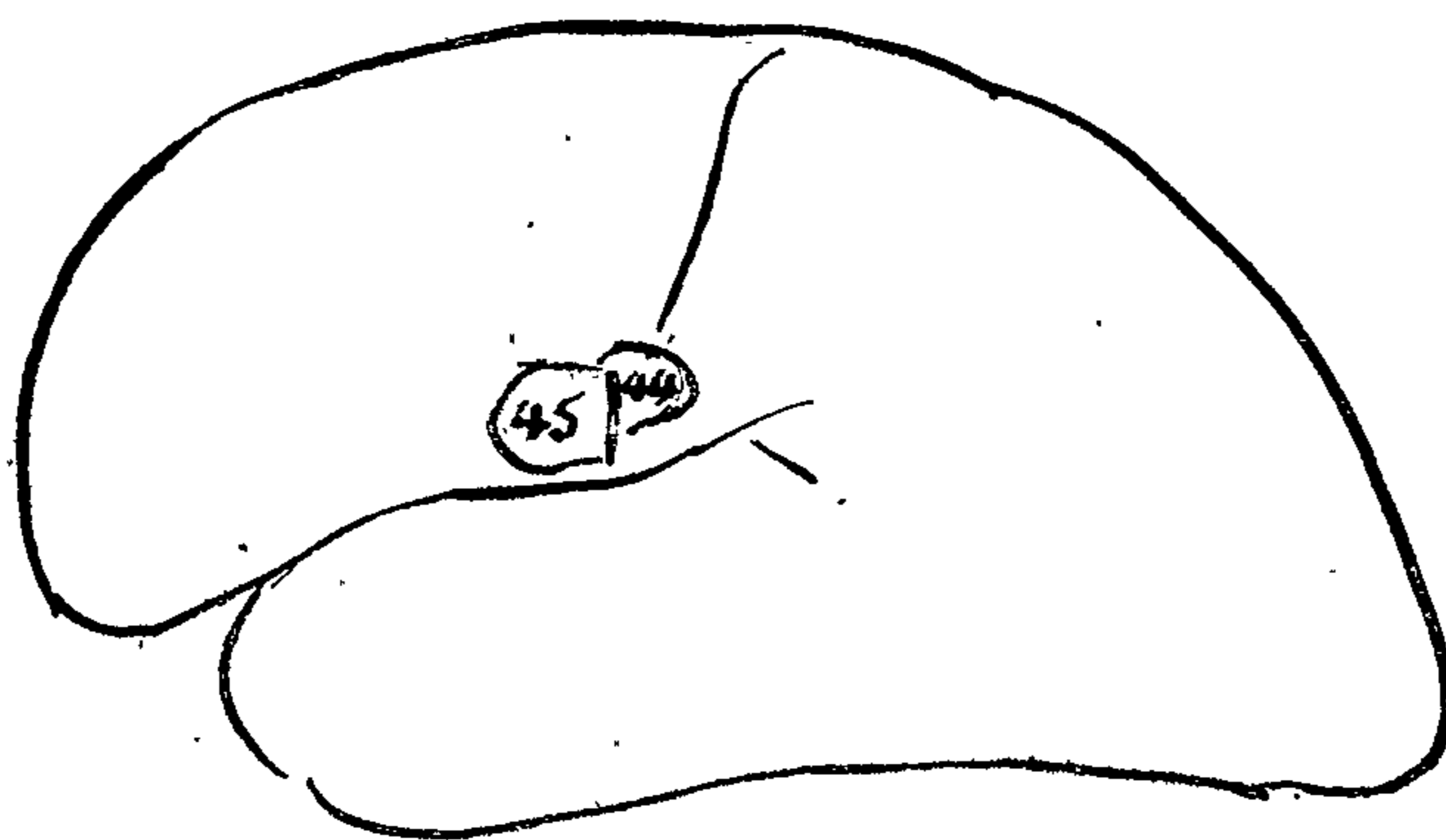


FIGURE 104.

a dysarthria (disturbance of articulation); all most important parts involved in speech.

The main speech area is Broca's area 45, at the posterior end of the third frontal convolution. A loss of the capacity for articulated speech "A motor aphasia", can occur should a lesion or disturbance occur in this region.

Frontal association areas 9, 10, 11 and 12 of the frontal pole receive the hypothalamic projections via the dorso-medial nucleus of the thalamus, and are important for learning, comprehension and speech

expressions

The neurological control of speech and expression is then complicated and not just a single area will control this important function.

The fact that speech is superimposed upon the vegetative areas infers that the neurological control will be by both somatic and visceral motor efferents. The sensory afferent fibres will be both somatic (skeletal musculature) and visceral, e.g., vagus and glosso-pharyngeal.

The afferent nerve supply is the means of registration of stimuli interpretation occurs in the higher centres and the efferent motor supply will control the muscles of the larynx and the muscles of facial expression, mastication and the tongue. Articulation is most important in speech for correct pronunciation and disturbances such as malocclusion may result in disturbed speech. The neuro-muscular patterns are disturbed in clefts and surgical repair, though producing anatomical continuity may not be capable of restoring the neurological muscular balance disturbance.

A brief summary of the nerves and their control will be mentioned to indicate their function in speech.



The 12th Cranial Nerve. The hypoglossal arises in the medulla oblongata from the nucleus in the floor of the fourth ventricle. The fibres are efferent and arise from distinctive cell groups of the nucleus. Each cell group is considered to refer to a muscle or part of. The anatomical pathway is well known and the efferent fibre, supply the homolateral extrinsic muscles of the tongue (except the palato-glossus) the styloglossus, hyoglossus, genioglossus and geniohyoid. Neurological disturbances in the fourth ventricle may influence motor control, the efferent impulse transmission pathway.

The hypoglossal is also influenced by cortico-bulbar afferents from the motor cortex, mostly crossed to the most medial cell group of the nucleus.

In recent reviews the hypothesis was advanced that at least in some of the cleft palate cases nasality resulted from the persistent habit of elevating the mandible and dorsum of the tongue during speech.

The abnormalities in the position and movements of the tongue are supported by the observations of speech therapists in the clinic associated with the study group, and also stated by McDonald.

During embryological development, the tongue assumes an elevated position between the cleft palate into the nasal cavity. The fact exists that surgery, although providing a united palate, does not change the habit of abnormal positioning of the tongue and the thrusting habit developed intra-uterine. These facts may have indirectly an important bearing upon voice production and movements of the tongue during speech.



The Vagus and Glossopharyngeal. The vagus is a complex nerve and will only be described in relation to speech.

The proprioceptive sensory fibres, general visceral afferent, important for the knowledge of the position of the tongue, pass from the posterior part of the tongue, pharynx and larynx and trachea via the vagus to the tractus solitarius, the caudal part of its nucleus.

The sensory afferent fibres from the posterior one third of the tongue and pharynx pass via the glossopharyngeal nerve to the caudal part of its nucleus and tractus solitarius.

The secondary afferent pathway from the nucleus solitarius via the medial lemniscus pass to the thalamic nuclei and hypothalamus with reflex connections to the visceral efferent nuclei in the reticular formation - a reflex circuit.

There may be similarly a disturbance in this neurological-muscular balance and positioning of the tongue due to the abnormal embryological development of the palate. The tongue, following cleft palate surgery is situated on a different position, a fact that the brain may take time to correlate and maintain. The vagus supplies through the superior laryngeal, the crico-thyroid, whilst the internal ramus receives sensory fibres from the larynx.

The recurrent laryngeal supplies the rest of the larynx with motor fibres, whilst the glossopharyngeal has efferent motor fibres to the stylo-pharyngeus and afferent taste fibres from the posterior one third of the tongue.

It was previously noticed that difficulty in swallowing and a nasal quality in speech or complete aphonia occurred from bilateral

supra-nuclear or nuclear lesions of the vagus as well as regurgitation of fluids through the nose.

These manifestations have been seen in cleft palates. It is not inferred that central neurological factors are the cause of these disturbances, but peripheral disturbance through disturbed embryological growth followed by new positions of muscular balance by surgery may be additive factors influencing speech.

There does seem some truth in this statement for cases where complete anatomical restoration surgically has been accomplished, still display "cleft palate speech". One case recently quoted in the literature, after years of speech therapy and complete rehabilitation, upon marriage, (an added emotional factor), reverted to her old bad nasal speech.

In similar circumstances the accessory nerve supplies the soft palate and pharynx through the pharyngeal plexus, muscles that are also disturbed in cleft palate cases, the soft palate is divided and the pharynx often widened.

Some of these muscles are derived from the second branchial arch, the musculature most affected by this disturbance. The cleft in some way distrubs the efferent impulses to these muscles, both before and possibly after surgery.

The trigeminal supplies the first branchial arch and the tensor palati. Cleft lip usually disturbs this arch mainly affecting the orbicularis oris, but little neurological disturbance seems to occur control and sensation are quite good and speech defects are only the explosive conconsants such as "P" and "B".

Whether or not a neurological disturbance occurs cannot yet be assessed. Should it occur, the higher centres may in some way not respond or receive the afferent stimuli for normal speech and articulation.

FLOOR. 4<sup>th</sup> VENTRICLE

MEDULLA OBLONGATA.  
AFFERENT. SYSTEM.

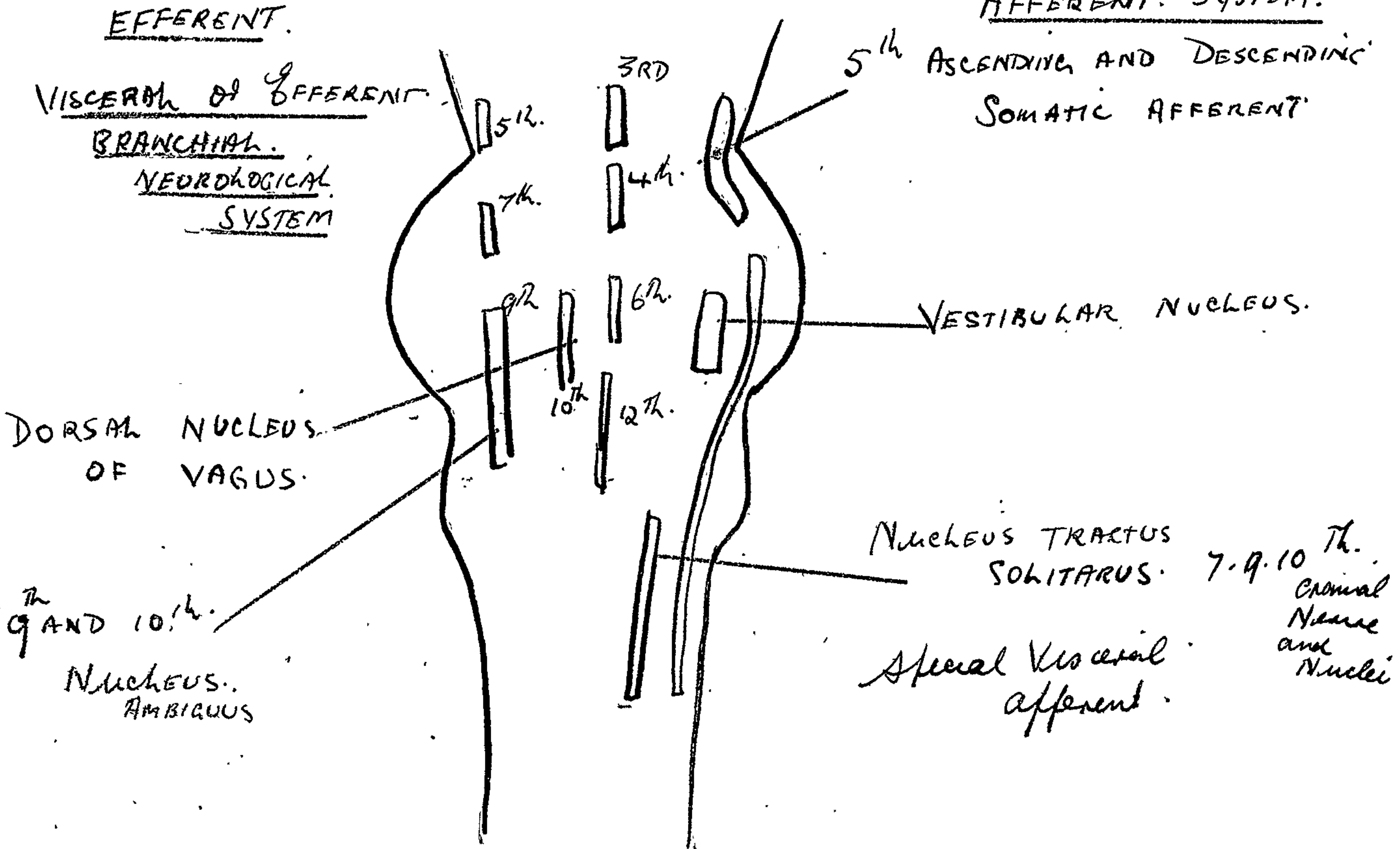


Figure 105.



## Development of Speech.

We learn to speak the language of the environment we inhabit. Before a child can express his thoughts in language he must pass through the many stages during which he gradually acquires the ability to co-ordinate the movements of the various muscle groups, eventually developing articulation and speech by two to three years, sometimes later.

The growth of speech and expression is dependent upon neurological development and control. The sensory receptors receive the stimuli and the response of the child to the environment, patterns the speech. The nervous system is this growing medium for receiving the responses to perceptible stimuli. The stimuli are recorded by the special sense organs.

- i. Optic - sight.
- ii. Auditory - hearing.
- iii. Tactile - touch; fingers & lips.
- iv. Olfactory - smell.

Tactile responses of importance during speech are the contact of the lips and this may be disturbed in cleft lip.

These stimuli pass to the cerebral cortex and higher centres and are recorded. The growing co-ordination of the muscles concerned in speech results in an expression to the stimuli received, as these muscles move in co-ordination, a pattern of movement forms. These patterns are expressed by Ballard<sup>10</sup> as speech habits and any alteration, in such a habit would require in a child or adult, a breakdown of this original neuromuscular pattern by the introduction of conscious effort in speech.

This is seen typically in children who have not attended the

speech clinic for a while after a series of lessons. They have frequently reverted to their previous speech and in some cases even worse. The building up of new patterns of speech requires much concentrated effort.

Abnormal auditory perception may complicate the issue. The child that is partially deaf has frequently to produce sounds he or she has never heard. This will then influence markedly the pronunciation. When a cleft palate may occur the speech may be unintelligible. These children require consistent therapy.

During speech development vowels appear first. These are followed some ten weeks later by the lip and tongue patterns and formation of consonants. The child of twelve months enjoy laryngeal play as the higher centres gradually control the varying muscles and co-ordinated function occurs. This laryngeal play has been seen to occur even in deaf children and is apparently the growth and development of expression.

"P" and "B" are formed first and the "K" and "G". "S", "Z", "U", "F", and "V" are not produced till later, even after the primary dentition has erupted.

Since the lip is repaired early "P" and "B" can be formed without trouble except that they are explosive consonants and require velo-pharyngeal closure, "K", "G" and "NG" also require function of the soft palate. The speech in the cleft child is disturbed from the onset and the child may utilize the one word sentence and gestures beyond the early childhood range. This one word sentence is a normal development and the beginning of the vocabulary. The ges-

tures gradually decrease and the sentence lengthens, until fluent speech is attained. Morley claims that the greatest increase in the vocabulary is between  $2\frac{1}{2}$  to 3 years of age.

By 4 to 6 years of age the child has learnt to articulate each consonant correctly. Normal speech follows and by the time the child is reading and writing, visual as well as auditory, images influence the sound he uses in speech.



The action of the muscles in normal and abnormal speech.

The superior constrictor in the cleft palate child contracts and remains in a state of contraction as long as speech continues, thus maintaining Passavant's ridge raised<sup>38.77</sup>, and causing a narrowing of the naso-pharynx from side to side. When the muscles are acting normally the nasal chamber acts mostly as a resonating chamber to the constantly dimensional changing oral cavity except during "M", "N", "NG"<sup>69</sup>.

The uvula and soft palate are drawn up and stretched by the tensor palati. It was once believed that the soft palate vibrated. This belief is no longer held and research has shown that it is just suspended immobile. The levator palati pulls the soft palate upwards and backwards to near contact of the posterior pharyngeal wall. Complete velo-pharyngeal approximation may not always occur. The palato-glossus and palato-pharyngeus are the opposing muscles during this function. The velo-pharyngeal closure is in the region of Passavant's ridge<sup>38</sup>.

The palato-pharyngeal arches may contract and approximate, restricting the oro-pharyngeal opening, and the tongue varies its position to the palatal arch. The soft palate will vary in height depending upon the desired sound. During rest it is relaxed.

In a cleft palate the soft palate is unbuttressed and the two elements pull apart in phonation. The soft palate cannot approximate to Passavant's ridge and palato-pharyngeal approximation is lacking for the muscles segments are working in opposite directions.

The tongue anterior, middle and posterior, normally positions itself to various parts of the palate controlling the volume of air

escaping. The lips and incisors will further deflect and vary this escaping air, resulting in various consonants. A consonant requires lip control as well. . Frequently, an opened bite or malocclusion will result in disturbed speech a fact not accepted by all. The vowels are mouthed, "A" requires the greatest control and widest oro-pharyngeal opening, the tongue is depressed and the lips wide apart. Variations of this to near closure of the lips results in the range of vowels and consonants to "S". "M", "N", "NG" require a slight nasality and a degree of nasal escape.

Cleft palate and cleft lip will disturb the musculature and position of the tongue. The function of the soft palate is now under intense study, for even when surgery has restored unity and length, there does not appear to be approximation to the posterior pharyngeal wall in many cases. This, as previously indicated, may be a neuromuscular disturbance, plus abnormal placing of the tongue.

These changes in the cleft palate and cleft lip result in failure of formation of the closed nasal cavity and incorrect positioning of the tongue during articulation. It is not possible to obtain the explosive forces required for some consonants and expressions in speech.

The use of prostheses as obturators to prevent nasal escape are relatively successful, but in divided palates the muscles rarely compensate and contraction does not occur in most cases around the connector. The bulb compensates by contacting the posterior pharyngeal wall, but it is usually not perfect. The best results have resulted from pharyngoplasty as previously stated.

Speech therapists do not appear as yet to have analysed the fundamental physiological requirements for good speech, as there are so

many influencing factors. To complicate the issue, as previously stated, good anatomy following surgery has been associated with bad speech and good speech with bad anatomy. Treatment procedures in the past have been related directly to anatomical deficiencies.



Speech Patterns of a child with cleft palate.

The development proceeds at first as for the normal child. The "P" sound is produced by holding air under pressure between the buccinator muscles of the cheek whilst the palato-pharyngeal muscles contract.

When the cleft occurs, nasal escape follows, resulting in nasality in the speech or the child may use tricks such as producing the sound in the larynx- the glottal stop. The child with the cleft may be completely unconscious of any difference in speech between himself and the normal individual.

Speech therapy requires that the palato-pharyngeal closure be established as soon as possible by either surgery or a prosthesis for the majority of consonant sounds occurring are used before two years of age.

By this period abnormal patterns have formed but are eradicated by a normally working palate, for the child is quick to learn new patterns. The longer the operation is delayed, the longer will it be before normal speech can be produced, other factors equal.

At 4 to 5 years of age, correction of faulty habits require blowing games and breath direction. Should the age 6 to 12 be reached before correction is instituted malocclusion and psychological factors may influence speech improvement.

The child of four with a cleft palate has developed abnormal patterns of speech to compensate for the disability. Various consonants such as "S" and "P" may not be sounded. Speech Therapy teaches the child conscious effort in speech and trains the mind to

control the muscles, whilst the orthodontist and surgeon restore the anatomy to near normal.

The types of abnormal speech were divided by Morley and Wardrill into the following classifications:-

Group I. Normal relations of the tongue, lips and teeth for the production of all sounds but nasal escape of air resulting in weak consonants and vowels and nasalized.

Group II. Articulatory substitutes.

- i. glottal stop.
- ii. pharyngeal S
- iii. replacement of one sound for another. Those commonly substituted for are "F", "K" & "T".

Group III. Vowel sounds and nasal resonants only. No attempt to produce other consonants. Sounds are unintelligible.

The anatomical and physiological results following surgery vary, various types of palates result and in many cases closure of the palato-phyngeal, sphincter cannot occur due to a short contracted immobile palate.

Surgery will frequently improve tone but fails to erradicate bad speech habits. Therapy must be instituted to improve speech in these cases.

The speech therapist.

The aim of the speech therapist is to restore normal functional speech. Speech therapy divides the 43 speech sounds into 25 consonants and 18 vowels.

Voice is produced by the column of exhaled air that is set in vibration by the vocal cords. It is varied by resonance in the various chambers and articulation of the oral cavity.

The therapist concentrates on teaching the patient the difference between normal and abnormal speech and attempts to eliminate compensatory manoeuvres such as glottal stop and nasal grimace. Correct articulation requires much time and tuition to be established in these cases, frequently complicated by the malocclusion that occurs.

The group system treatment does much to aid the child psychologically and aids learning by the observation of the errors of others. The child is given the feeling of security and is managed easier.

Individual tuition must be used during certain phases to correct abnormal articulation and phonations.



Speech Therapy Diagnosis requires the assessing of abnormal or normal function of the musculature during speech.

The factors considered are;

1. Normal occlusion of the teeth.
11. Function of the palate.
111. Positioning of the tongue.

Therapy exercises to restore normal functions are used for certain muscles.

1. The occlusion of the teeth is most important.

The position of the incisors and the contour of the arch should be examined. The relation of the first molars observed and if a malocclusion suspected referred to the orthodontists for diagnostic opinion. Dysphasia frequently accompanies malocclusion. Opened bites, abnormal overjet and overbite, crossbites and collapsed arches may, in selected cases, disturb articulation resulting in faulty speech.

Dental malocclusions such as bilateral collapsed maxillary arch and defects in palatal length may result in difficulty in "t" and "d" which require placement of the tongue in relation to the palate. The tongue tends to protrude and destroy the result, especially in chronic defects. "A", "K" and "G" may be disturbed by crowding in the mandible, for the tongue tends to seat itself whilst these are produced in the middle of the tongue.

2. Function of the soft palate and pharynx. The anatomical restoration of the soft palate is the work of the surgeon; where this fails the prosthodontist constructs an obturator. The aim is to produce the best speech mechanism for the patient and to have reasonable speech available by the time it is required. The recent Hyne's

velopharyngoplasty has modified the palate and pharynx for speech, where it has been impossible to produce a competent palatopharyngeal sphincter.

McDonald states that a complete closure of the nasopharynx is not required, but a critical point must be reached. Correct functions of the tongue is an important associated pattern in preventing nasal escape.

The appearance of the nasal grimace clinically is contraction of alar cartilages.

The alar nasi attempts to close the nostrils anteriorly to prevent air escape.

The Nasal Snort may accompany consonant sounds and frequently occur with "S".

Nasal Tone occurs normally in speech using "M", "N" and "NG". The nasal cavity is one of the resonating chambers and nasal tone may occur in anatomical defects of the palate especially in vowel sounds whose tone depends upon resonance. Should the soft palate be rigid or the nasopharyngeal isthmus large, then the vowel sound will be disturbed.

The degree of competence of the palatopharyngeal sphincter is hard to assess and a yardstick of some type is definitely required.

Concerning the glottal stop, Negres states:

"The ingress of air into the glottis is prevented by approximation of the true vocal cords but they have little power to prevent egress. The false cords do not normally function as a valve, but where the edges are approximated they act as a valve and offer great



resistance to the egress of air and are a chief factor in coughing."

It seems in man they may cause the air stream to be severed. Consequently the sphincter like muscle may be then used in phonation by vibrating and interrupting air current.

The cleft palate patient can use this sound as a substitute for explosive sounds "P", "B", "D" and "K" and "G".

The sound "S" is a fricative sound and may be produced by the pharynx in the cleft palate rather than using the tongue, palate and lip.

The therapist attempts to train the child so that during function the main volume of breath passes through the oral cavity and not the nasal cavity. Speech therapy may fail in some cases and these are then brought to the clinic for group observation to assess if further surgery may be of aid. Mentality is sometimes a limiting factor and the speech results obtained will vary accordingly.

Speech therapy is usually conducted following surgery but where surgery is delayed exercises may be practiced.

Enlarged turbinates and deflected septum in the nasal chamber may result in speech disturbances. One child at Royal Alexandria Hospital for Children showed remarkable improvement in speech when a nostril was widened and an enlarged turbinate removed.

Some children have shown relaxation of the palatopharyngeal sphincter before relaxing the lips in explosive sounds resulting in loss of air through the nose leaving insufficient pressure for explosive consonants.

However some feel that the importance of the palatopharyngeal sphincter has been exaggerated and long overplayed.



### TESTS & EXERCISES.

The Blowing test assesses the patients ability to use the sphincters and may be used as a means of measuring nasal escape.

Whilst blowing (especially where much pressure is required as during inflation of a balloon) the palate should rise to its maximum height, and a tight closure of the sphincter should occur.

This palatopharyngeal function will influence fricative sounds such as "S" and explosive consonants "P" and "B". This test may measure incompetance of this mechanism.

### The Exercises.

Those for articulation of the vowels and consonants.

- A. Lip exercises.
- B. Tongue exercises.
- C. Articulatory nursery rhymes with the concentration

on individual sound perfection in the young.

Books in graduated form for age may be used.

Reading aloud is suggested for this stimulates all the sensory areas of speech, hearing and sight.

Pitch and inflection should be practiced.

### Those for tone and nasality:

1. Breath direction - the child is taught to direct the air column through the oral cavity and not the nose.
2. Exercise to obviate nasal tone "hums" "snorts" - exercises.

### Games.

1. Blowing games for developing muscles of the cheek explosive type.
2. Suction games.
3. Whistling.
4. Conscious attempt at movement of the soft palate whilst observed in a mirror.

Some claims have been made that nasality is due to tension in the

hyoid area and culde sac resonance and there blowing exercises utilized merely increase the nasality<sup>69.</sup>

There is room for further research in this field for many views are antagonistic and knowledge incomplete, nothing substantial has been proved. It does appear that for a normal speech to occur velopharyngeal closure is necessary to a critical point or a Hynes type pharyngoplasty as a substitute.

### 3. Positions of the tongue in cleft palate speech.

"S" was found to be most misused, non used and abused sounds produced. It is normally produced by a stream of air passing through a small passage between the tongue and hard palate, teeth and lips. This may be substituted in the cleft by a hiss produced by the posterior positions of the tongue.

This is an example of the abnormal positioning of the tongue that frequently occurs when the palatal deformity occurs.

"T" and "D" are produced by the tongue contacting the posterior surface or edge of the upper incisor teeth. The loss or disturbance of these structures may produce a sound interdentially.

"N" requires the tongue to contact the foot of the palate and may be substituted for by "NG" or "N" may be used instead of "T" or "D".

Observations clinically have indicated that the misarticulation occurs in three ways as -

1. Substitution, distortion or omission with distortion the greatest abnormality. A constant articulation error has been found to occur in cases which cannot be attributed to the failure to effect a velopharyngeal closure.



34b.

Herbert Klinger states "that the malformation of sounds due to improper tongue movement positioning and lack of control with abnormal movement of the lips will produce this constant error in articulation". This may be due to the embryological cleft disturbance producing abnormal neurological musculature balance during growth; i.e. the positioning of the tongue in the cleft.

Many lazy tongues may be witnessed, resulting in failure of opposition to the palatal vault during articulation.

McDonald and Baker<sup>34b</sup> feel that the nasality, nasal emission and articulatory disorders result from the habit that cleft palate patients have of elevating the mandible and the dorsum of the tongue and not allowing freedom of use of the tip of the tongue in the articulation of speech vowels. The tongue position may have developed during infancy to keep the food from entering the nasal cavity.

It was observed in a few cases clinically that patients with wide unrepaired clefts of the hard and soft palate had less nasality than patients with repaired clefts.

<sup>17-69</sup> Berry believes that the sounds were defective because the tongue did not make the proper articulatory adjustments and that it lacked the mobility and co-ordination for normal voice production.

<sup>69.</sup> Matthew and Byrne did not support this hypothesis.

<sup>62.69.</sup> Higley has shown that in a study of velopharyngeal closure in vowel sound.

The width of the opening between the oral and nasal pharynx varied accordingly.



Vowels:

- "A" wide opening.
- "O" narrow opening.
- "I.E.U." complete closure.

<sup>69</sup>Williams found the sphincter open for "E".

<sup>69 AND 34 b & c</sup>Luban<sub>^</sub>E. McDowell found the sphincter was patent in many cleft cases during the phonation of "C" where closure should have occurred.

SUMMARY.

Research by Jane McWilliams<sup>34b</sup> on specially selected cleft patients examined by using a phonetically balanced test (i.e. each list contained twenty three consonants sounds in the same relative proportion that they appear in normal conversation) and conducted by three related auditors, indicated :-

1. The articulation consonants error was proportional to the speech intelligibility of the cleft palate adult.
2. Articulation error and nasality are closely related.
3. "S" and "Z" were by far the most frequently misarticulated sounds.

These facts were in accordance with our own clinical observations. Jane McWilliam found that when a patient erred, they did not err on the given sound each time it appeared in the sample. The problem of the physical defect appears to be complicated by individual ability to communicate and both are reflected in the intelligibility of the speech.

The speech may show (either or both) nasality or misarticulation and there was no tendency that indicated a relationship between nasality and velar length.

Huttum<sup>63</sup> found the occurrence in cleft cases to be:-

- |                                      |     |     |
|--------------------------------------|-----|-----|
| 1. Normal non nasal speech           | 71% |     |
| 2. Non nasal with articulate defects | 12% |     |
| 3. Slight nasality                   |     | 11% |
| 4. Moderate nasality                 | 4%  |     |
| 5. Hyponasality.                     | 2%  |     |

Many children with non nasal speech have shown marked lateral pharyngeal movement of the posterior Faucial pillars or marked movement

Passavant's cushion.

Clinical observations have indicated where the palate is long and muscle reasonably active pharyngeal wall exists then nasality seldom occurs. Nasality will occur where there is a short palate with little lateral activity of the pharyngeal wall and/or little activity of posterior pharyngeal wall in cleft palate cases.

We have observed within our own clinic the importance of the parents help and attitude and their aid in helping speech correction and administration of exercises and constant practice.

Psychological problems may occur where the child is not correctly treated.

Bewilderment and withdrawal from social contacts with an effort to avoid speech.

An aggressive attitude or sensitivity may develop with a sense of inferiority and a subconscious fear of speech that may take years of therapy to eradicate if ever.

A very good summary was written by Elizabeth McDonald who stated that, "Everything else equal normal speech is more likely to be obtained by mechanism with the following characteristics:-

1. A fairly low wide palatal arch - not too flat.
2. A tongue that approximates in width and length the general contour of the palatal arch.
3. A tongue blade that can move freely and is not impeded by the lingual frenum.
4. Teeth that can be closed with a relatively complete obstruction of air and free from open spaces between the dentures.
5. A uvula, flexible and large enough to close off the nasopharynx.
6. Fairly wide opening at the fauces.
7. Fairly wide oropharynx and nasopharynx unobstructed by growths such as adenoids.
8. Comparatively large apertures at the turbinates.
9. Large nasal fossa.



10. Thyro - arytenoid folds which are long, moderately rounded freely moveable areas provided with free margins.
11. Free agile muscle operating the soft palate, tongue and thyro arytenoid folds and wall of the pharynx.

Very few cleft palate cases exhibit these factors, in fact many normal people do not.

By comparison of speech before and after operation it is possible to assess how much was due to anatomical insufficiency.

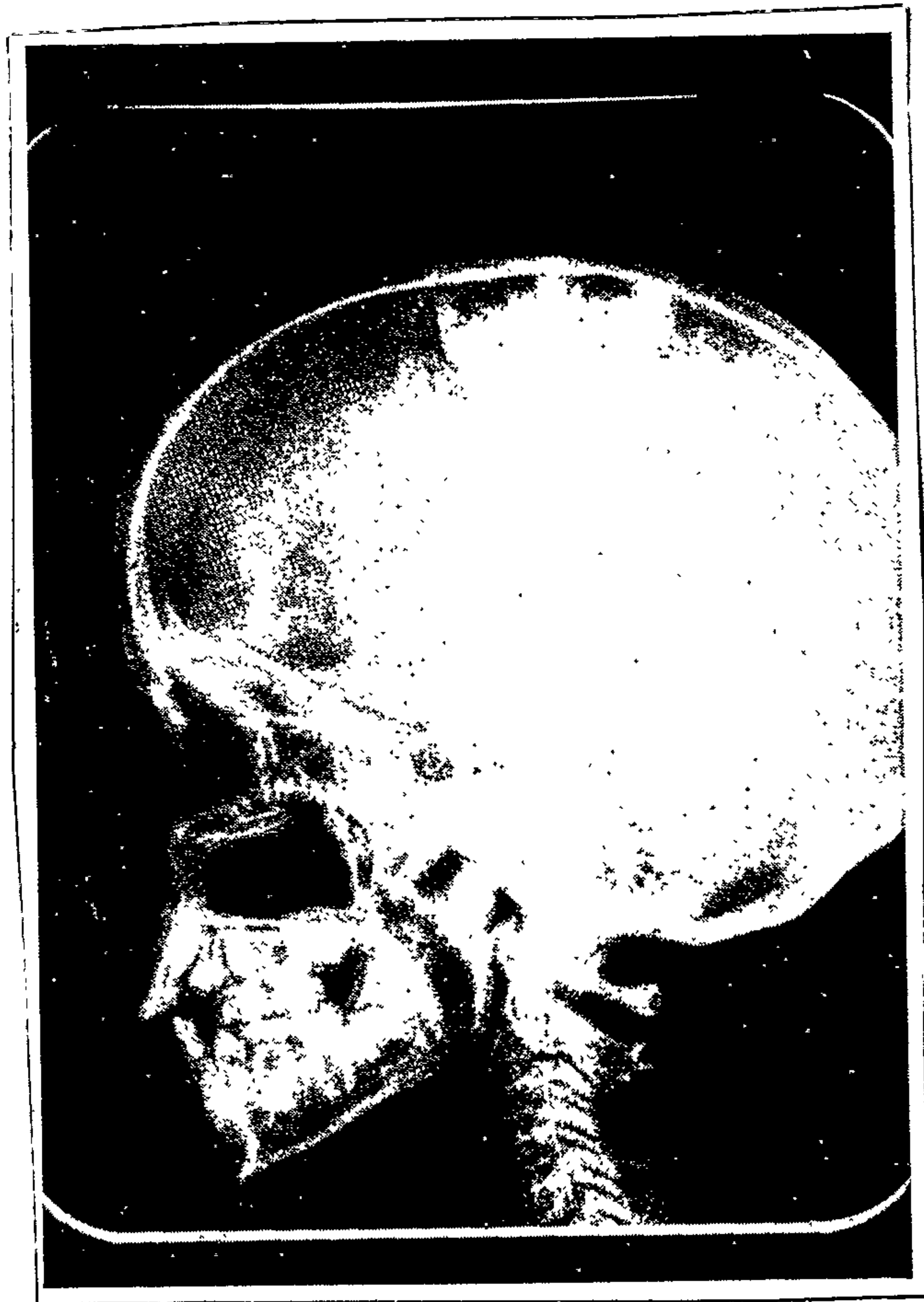


Figure 106 ILLUSTRATES A PATENT ORO - NASO - PHARYNX.

Hearing and the effect of its disability on speech.

Normal auditory perception is to through stimulation of the hair cells of the Organ of Corti which transmits impulses to the spiral ganglion via the cochlear nerve the impulses travel in the order of the Dorsal and ventral cochlear nuclei, Stria acoustica dorsalis to the lateral lemniscus of the opposite side the medial genicular body, the auditory radiation of the sublenticular part of the internal capsule and finally the auditory cortical centre and association areas.

Hearing may be transmitted by vibration by tympanic membrane and ossicles which in turn influence the organ of corti or by vibration through the normal bone structure.

Disturbance in any one of the mechanisms, Tympanic membrane ossicles, or infection in mastoid region, otitis media; or neurological disturbances either unilaterally or bilaterally will result in some degree of deafness.

Many displayed a heavy loss of thirty to forty decibells.

The middle ear may suffer (otitis media) especially in children by infection from the pharynx passing by way of the eustachian tube. So nasal and pharyngeal infection may reflect upon the auditory ability in the cleft palate child. This child is frequently prone to such catarrhal conditions.

63

Of one group selected by Huttum 22% of the children with cleft palates displayed hearing loss averaging twenty decibells or more in the speech.

In many cleft cases high frequency disturbances occurred.

The importance of this factor is obvious in the cleft palate child when it is realised that the child learns to speak from sound of the

parents and tends to imitate.

this defect is a big handicap and requires concentration and frequent lip reading to adjust to the disability.

Teaching is complicated and the child is slow to learn. Difficulty in expression occurs where deafness is superimposed upon a mechanism of voice production that is already abnormal.

A good auditory memory span for individual sounds is frequently a great help in speech training and deafness removes this added aid that may be present in some cleft children. The ability to hear and discriminate certain sounds aids understanding and expression, and its loss cannot be underestimated. The patient should be referred to the otolaryngologist should this disturbance or any other of this region present. Most patients are examined by the otolaryngologist early in the treatment planning.

Frequently the E.N.T. Surgeon in the past unknowingly removed the adenoids and tonsils because of recurrent history of infections of the middle ear and upper respiratory tract.

The speech pathologist frequently required adenoids to fill the pharynx and frequently their removal converts many months of improvement (in speech production) to failure. Today the group system has made available a greater understanding of the overall problem and treatment and rehabilitation is advancing to the common benefit of patients, parents and those interested in this cause.

THE END.



BIBLIOGRAPHY.

1. ANTHONY: American Text Book of Prosthodontics 1948  
(Partial Denture Construction)
2. ADAM C. P.: The Modified Arrowhead Clasp  
A demonstration before the British  
Society Orthodontists. Dental Record May, 1949
3. AREY: Developmental Anatomy. Philadelphia 1946  
(W. B. Saunders)
4. ARCHER: Text Book of Oral Surgery Saunders 1952
5. BADEN E.: Fundamental Principles of Oral Facial  
Prosthesis Therapy in Congenital Cleft  
Palates. Parts I & II.  
Journal Prosthetic Dentist 1954 X
6. BAKES F.P.: "Speech Training of Patients who wear  
speech corrective appliances"  
American Journal Orthodontia and  
Oral Surgery 1946
7. BALLARD C.F.: Private Correspondence.
8. BALLARD C.F.: An Orthodontic View to occlusion in  
relation to Periodontal Problems  
Dental Practitioner. June 1953
9. BALLARD C.F.: The facial musculature and anomalies  
of the dento-alveolar structures.  
Part I and Part II (Private Correspondence)
10. BALLARD C.F.: Adenoidal facies and mouth breathing  
Reprinted from The Medical Press  
October 8th, 1952. Volume CCXXVIII No. 5918.
11. BALLARD C.F.: The upper respiratory musculature  
AND GWENNE- and Orthodontics. Dental Record 68  
EVANS. Vol. I 1947  
Transactions of the British Society  
of Orthodontists.
12. BALLARD C.F.: Some cases to Illustrate the Relationship  
between Etiology, Prognosis and Treatment  
Planning in Orthodontia. The Dental Record  
October 1953
13. BALLARD C.F.: The Clinical Aspects and Physiological  
Mechanism of Abnormal paths of closure.  
1954 Transactions of the European  
Orthodontic Society.

14. BALLARD C.F.: The Significance of soft tissue Morphology in Diagnosis; Prognosis and Treatment Planning. Reprinted from 1953 Dental Record. Transactions of the European Orthodontic Society.
15. BALLARD C.F.: A consideration of the physiological background of mandibular Posture and Movement. The Dental Practitioner 1955.
16. BALLARD C.F.: "Soft Tissue Pattris". Private Correspondence.
17. BARNETT F.: A Rationale for closer Co-operation between the orthodontist and speech and hearing therapist. American Journal of Orthodonta August, 1955, page 572.
18. BARSKY ARTH.JOS. Principles and Practice of Plastic Surgery, Baltimore. Williams and Wilkins 1950.
19. BAXTER HAMILTON: Complete Cleft Palate Rehabilitation Programme for cleft palate and cleft lip cases. Journal Canadian Dental Assoc. 1954
20. BEDER O.E.: The Oro Facial Cripple. American Journal Orthodontia and Oral Surgery. 1946
21. BERNSTEIN M.: The relation of speech defects and Malocclusion. American Journal of Orthodontia, parts I & II Feb. 1954, P. 149.
22. BEST AND TAYLOR Text Book of Physiology.
23. BJORH A.: The Face in Profile. Berlingska Boktryckeriet 1947
24. BJORK ARNE: Professor Copenhagen Denmark. Cranial base Development American Journal of Orth., March, 1955.
25. BJORK: Variabilities and age changes in Overjet and Overbite. American Journal Orth. 1953.
26. BOYD: Text Book of Pathology
27. BRASH Etiology, Irregularity and Malocclusion at Birth. 1929 Dental Board Lectures.
28. BRODIE ALLEN G: Consideration of Musclature in diagnosis treatment and utention. American Journal Orth. November 1952



29. BRODIE ALLEN G.: Behaviour of normal and abnormal Facial Growth Patterns Am. J. Orth. & Oral Surgery
30. BRODIE ALLEN G.: The application of Principals of Cephalometric Laminography to the Study of Frontal Planes of the Head A.J.O. 1953
31. BRODIE ALLEN G.: Growth & Pattern of the Human Head from Third Month to Eighth year of Life. Am. Journal Orth. 1941
32. BRODIE A.G. & SLAUGHTER W.G.: Facial Clefts and their Management. Plastic Reconstruct Surgery 1949
33. BROPHY: Cleft Lip and Palate Philadelphia 1923
34. CLEFT PALATE.  
BULLETIN Cleft Palate Bulletin. American Association for Cleft Palate Rehabilitation. Graduate School Medicine, University of Pennsylvania.  
(A) May 1954 Parts I & II  
Tables Page 2 and Nos. 1 - 11  
(B) April 1956  
(C) Jan. 1956 1 P. 7  
2 P. 8  
(D) October, 1955.
35. CALDWELL J.B.: A Method of Surgical Closure of a perforation of the hard palate.
36. CANICK M. L. Cleft Lip and Cleft Palate. Plastic and Reconstruct Surg. July, 1954, page 31.
37. CALMAN: British Journal Plastic Surgery Jan. 1956
38. CALNAN: The error of Gustav Passavant. British Journal Plast. & Recon. Surgery, April, 1954.
39. CLARR & RAINSON Text. The Anatomy of the Nervous System
40. CONVERSE: Bone Grafting & Contour restorations of the face. Plastic & Reconstruct Surgery 1954
41. COOPER H.K.: Cleft Palate Dentistry Opportunities Hournal Am. Dent. Assoc. 1951 .
42. Cloyd.S, HARKINS, KOEPP BAKER: Twenty five years of cleft palate Prosthesis. Am. Journal Orthodonture. X



43. DOVIN: Role Cephalometry in Orthodontic case Analysis Anceric Journal Orthodontia 1952
44. DORRANCE G.M.: Congenital Insufficiency of the Palate Archer. Text Book Oral Surgery
45. DORRANCE G.M.: "The Push Back Operation". Plastic & Recon. Surg. September, 1946
46. DORRANCE G.M. AND BRANSFIELD J.W.: The Push Back Operation for repair of cleft palate. Plastic and Reconst. Surgery, 1946
47. DORRANCE G.M.: The Operative Story of Cleft Palate Saunders, Philadelphia 1933
48. DOIG R.R. AND COLTMAN : Cleft palate following Cortisone Therapy in early Pregnancy. The Faucet October 6th, 1956.
49. ELHRICH T.O.: The Role of Pediatrics in cleft palate Cleft Palate Bulletin, October, 1955.
50. FEER, HAGERTY, HOFFMEISSER: An evaluation of the Warren Davis Osleoplastic technique in cleft palate. Plastic & Recons. Surg. July, 1954.
51. FRAZER: Text Book of Osteology.
52. FITZ-GIBBON: "Cleft Palate" Dental Items of Interest, October, 1931.
53. GENETICS. The Dept. of Anatomy. Medical School, University of Sydney.
54. GELBKE An Unusual application of the Eslander Abbe Plastic Operation of the lip. Plastic and Reconstruct. Surg. July, 1954.
55. GRABER: Clinical Cephalometry. Am. Journal Orth., August, 1952, January, 1956.
56. GROSS P.O.: A method of keeping the palatal mucoperiosteum against the bony structures following cleft surgery.
57. HAMILTON, BOYD, AND MOSMAN: A Ent. Book Human Embryology. Williams & Wilkins 1957 Edit.
58. HARRIS H. & HALDANE: Biochemistry of Genetics.

59. HARKINS C.  
CLOYD S. Oral Prosthesis in Rehabilitation of  
Cleft Palate patients.  
Archer - Text book oral surgery.
60. HEMLEY: Fundamentals of occlusion.
61. HILL H. M.: Cleft Palate Bulletin, January, 1956
62. HIGLEY L. B.: Facial reconstruction and Speech.  
Journal Am. Dent. 1943.
63. HUTTUM (Rochister, New York)  
Misarticulation adds to the subjective  
judgement of nasality. Cleft palate  
Bulletin, 1956.
64. IVY R. H.: Recent Trends in Cleft palate treatment.  
Plastic & Reconst. Surg. 1950.
65. JAYS H.D.: Cleft Palate Am. Journ. Orth. April, 1952
66. KROGMAN: I The problems of Turning facial growth  
with special reference to the period of  
changing dentition. Am. Journal Orth. 1952  
II The problem of the cleft palate defect.  
Plastic & Reconstruct. Surg. Journ. Oct. 1954
67. KRANTZ & CARR: "Cortisone Therapy". P. 1023.  
Pharmacological Principals of medical Practice.  
Williams & Wilkins. 3rd Edition.
68. LANE: Extracts from "Cleft Palate & Cleft Lip".  
Barsky, London, Medical Publishers.
69. LUBAN JOSEPH: Speech in Cleft Palate. Am. Journ. Orth.  
Feb. 1955.
70. Le MESURIER: A method of cutting and suturing the lip in  
treatment of complete unilateral clefts.  
Plastic & Reconstruct. Surg. 1949.
71. LUNDSTORM A.: The significance of Genetic and non genetic  
Factors in the profile of the Facial Skeleton  
Am. Journ. Orth. December, 1955.
72. MCGREGOR A.LEE: Synopsis of Surgical Anatomy, 6th Edition  
P. 324 & 332.
73. McWilliam: "Environmental Factors in Speech Defect."  
Cleft Palate Bulletin, Jan. 1956, April, 1956.
74. McDONALD E.T.: Speech consideration in cleft palate pros-  
thesis Am. Journal Pros. Dent. 1951. The  
Pharyngeal flap operation as a speech aid.  
Plastic Reconst. Surg. 1951.
75. MORAN R.F.:



76. MILLHON AND STAFNE: The incidence of supernumery & Congenitally raising lateral incisors etc. Am. Journ. Orth. & Oral Surgery Novermer 1941.
77. MORLEY MURIAL E: Cleft Palate and Speech. Baltimore. Williams & Wilkins 1945 and 1951.
78. MASTERS PICKERELL:  
a. Georgiate Horton: Restoration lip contour using fascia Tendon and Denmal grafts. Plastic & Reconst. Surgery, July, 1954.  
MASTER NICKOLAS:  
b. GEORGIAD: The repair of the incomplete cleft of the lip and secondary lip deformities. Plastic & Reconst. Surg. 1954.
79. MALHEN & BYRNE: Speech & Cleft palate patient. Joseph Luban, Am. Journal Orth. February, 1955.
80. MALSON: Complete Denture for the congenital cleft palate patient. Am. Journ. Prosth. Dent. July, 1955.
81. NANDA: The rates of growth of several facial components measured from serial cephalometric Roentgenograms. Am. Journ. Orth. Sept., 1955.
82. NEURO-ANATOMY: Dept. "Issued Notes". Medical School., Sydney University. Dept. Anatomy, 1956.
83. OLDFIELD M.C.: Cleft palate following cortisone therapy in early Pregnancy. The Lancet, July 14th, 1956.
84. OLDFIELD M.C.: Cleft Palate and the mechanism.  
a. of speech. Brit. Journ. Surg. Oct., 1941.  
B. Modern trends in Hare Lip and cleft palate. Surg. Brit. Journal Surg. 1937 and 1949.
85. OLINGER N.A.: Oral defects and their relation to defective speech. Am. Journ. Orth. & Oral Surg., 1946.
86. OLINGER N.A.: Eugenic aspects cleft palate and other facial deformities. Journal A.D.A., 1944.
87. ORBAN: Oral Histology & Embryology Ind. Edit. P.27.
88. PRUZANSKY AND BEERS D.: The growth of the head of an infant with mandibular microsyralhia, glossoptosis and cleft palate following the Beverly Douglas operation. Plast. & Recon. Surg. Sept., 1955.
89. PRUZANSKY S: Factors determining Arch form in clefts of the lip and palate. Am. Journ. Orth. St. Louis. Vol. 41 No II Nov. 1955. pages 827 - 851.



90. PRUZANSKY: a. Description and Analysis of unoperated clefts of the lip and Palate. Am. Journ. Orth, 1953.
- b. The role of the orthodontist in a cleft palate team. Plastic & Reconstruct. Surgery, July, 1954.
- PRUZANSKY c. The rationale for velar closure as a primary  
& SLAUGHTER W.: procedure of cleft palate defects. Plastic & Reconst. Surg. May, 1951.
91. Rangell: "Development of Plastic surgery in Sweden."  
(Stockholm) British Journ. Plast. Surg. July, 1955.
92. RICKETTS R.M. The cranial base and soft structures in cleft palate speech and breathing.
93. RICKETTS R.M.: Facial and denture changes during orthodontic Treatment as analysed from the temporo - mandil joint. Am. Journ. Ortho. March, 1955.
94. RITCHIE: Cleft Palate correction of anatomy & function Archer Oral Surg. 1952 Ed.
95. ROSE AND CHARLESS Manual of Surgery. Saunders 1954 Edition.
96. Schour NOYES: Oral Histology & Embryology. Page 35 - 45. Reference P. 37.38.41.43.
97. SHELDON FRIEL: The development of Ideal occlusion of the gum pads and teeth. Am. Journ. Orth. March, 1954.
98. STRANG: A text book of Orthodontia.
99. STRAITH VOLINDE TEASLEY A new method of columnar advancement. Plastic & Reconst. Surg. 1954.
100. SUBTELNY J.DAN: "Width of the Naso Pharynic and related anatomic structures in normal & unoperated cleft palate children. Am. Journ. Orth. December, 1955, P. 889.
101. STEYLER R.: Acrylic and other Synthetic resins as used in dentistry.
102. STARK R.B.: The Pathogenesis of Hare Lip and Cleft Palate. Plas. & Recon. Surg. Jan. 1954, P 20-38.
103. SWANSON L.T. Radiography in cleft palate, cleft lip, cleft palate Bulletin, October, 1956.
- 104 Terry H.K. Cases indicating early treatment. Am. Journal Ortho. April, 1955.

105. WALDRON: Management of Unilateral clefts of the palate  
Plast. & Recons. Surg. 1950.
106. WARDRILL: The technique of operations for cleft palate.  
Brit. Journ. Surg. 1937.
107. WARDRILL: British Journ. Surgery, 1933.
108. WARDRILL: Extracts from Brit. Journal Surg. 1928 (July)  
and Principles plastic surgery by Joseph  
Barsky.
109. WEARN W.J.: The immediate Dental treatment for cleft  
palate babies. Read before the Australian  
Dental Congress 1930.
110. WEARN W.J.: Feeding of cleft palate babies.  
Australian Nurses Journal January, 1931.
111. WEINMANN J.B.  
& H. SICKER: Bone & Bones.
112. WRIGHT SAMPSON: Applied Physiology.
113. WRIGHT PAYLING: An introduction to pathology. Honeyman, 2nd  
Edition, 1954.
114. WRIGHT WALTER: How to make a cleft palate obturator of  
acrylic resin. Year Book Dentistry, 1940.
115. THOMAS K.H.: Text Book of Oral Pathology. Saunders Mosby,  
4th Edit. P. 528 - 540.
116. THOMAS K. H.: Text Book Oral Diagnosis.
117. THOMA K. H.: Text Book of oral surgery Parts I & II  
Second edition.
118. TRAUNER: A new procedure in Velo pharyngeal Surgery  
for secondary operations on too short a soft  
palate. Plast. Surg. Vol. 8, Page 291, Jan. 1956.
119. TURNER A. LOGAN: Disease of the Nose, Ear and Throat, Edit. 1940.



SUBSIDIARY BIBLIOGRAPHY PRIVATE.

120. DR. ADAMSON: Melbourne - Private correspondence.
121. BLAIR AND IVY: The essentials of oral Surgery, Mosby. Edition 1946.
122. CUNNINGHAM C.: Text Book of Anatomy 12th Edition. Edit. by A. Robinson, Oxf. Pub.
123. FULTON: A. Text book of Physiology. (Neuro-physiology section).
124. GRANT: Method of Anatomy. 3rd edition. Williams & Wilkins.
125. GRAYS ANATOMY: Descriptive and Applied, 28th Edit. Longmans P. 96 - 120.
126. Dr. NELSON: Private Correspondence.
127. MR. P. SCHAMBARIS: Private Correspondence.
128. DR. J. STEIGRAD: Private correspondence.
129. PATTERN B.M.: Human Embryology. Phil.
130. DR. S. TOUT: Private Correspondence.
131. DR. D. DEY: Private Correspondence.
132. RANDELL C. Treatment of Cleft palate associated with micrognathia. British Journal Surg. Vol. 8 p. 283 - 290. January, 1956.
133. DR. DAVEY: Private Correspondence.
-





**UNIVERSITY OF SYDNEY**  
Dental Library