

IV. Discussion.

The temporomandibular joint formed from two blastemata (SYMONS, 1952; BAUME, 1962 a,b; FURSTMAN, 1963; YUODELIS, 1966; BAUME and HOLZ, 1970) between the sixth and the fourteenth weeks of intra-uterine life. The weight of evidence suggests that the meniscus of the joint was derived from the mesenchyme that lay between these two blastemata.

The critical time for the formation of the bony elements of the joint was between the sixth and tenth weeks, whereas the critical time for the formation of the articular disc was between the tenth and the fourteenth weeks.

After the fourteenth week the joint was basically completely formed and continued to increase only in size after that time.

Meckel's cartilage played no part in the development of the joint but it was of importance in acting as a guide for the developing mandible. The ramus arose from membranous bone and grew by surface apposition while endochondral bone formation only occurred in the condyle.

Chapter 4. The Histology of the Temporomandibular
Joint in a 4 month old Bonnet Monkey
(Macaca radiata).

Contents

	<u>Page.</u>
I Introduction	91.
II Results	91.
1. Anterior Capsule	91.
2. Posterior Capsule	93.
3. Meniscus	97.
A. Pes menisci	97.
B. Pars gracilis menisci	97.
C. Pars posterior menisci	101.
D. Bilaminar zone	101.
4. Articular Surface of the Temporal Bone	108.
5. Articular Surface of the Condyle	112.
A. Perichondrium	112.
B. Zone of young and resting chondrocytes	112.
C. Zone of flattened chondrocytes	112.
D. Zone of hypertrophic and degenerate chondrocytes	116.

E. Zone of irruption and bone formation	116.
6. Synovial membrane	118.
A. Antero-superior stratum	118.
B. Antero-inferior stratum	118.
C. Postero-superior stratum	120.
D. Postero-inferior stratum	120.
E. Pes menisci	120.
F. Pars gracilis menisci	124.
G. Pars posterior menisci	124.
III. Discussion	125.

Chapter 4.

The Histology of the Temporomandibular Joint in a 4 month Old Bonnet Monkey (*Macaca radiata*).

I. Introduction.

The Bonnet monkey used in this study was approximately 4 months old and could thus be considered to simulate a temporomandibular joint complex similar to that found in a young human, with respect to histological features. In view of the close evolutionary relationship between the human and the monkey, it could be expected that the human and the monkey would be similar, but slight variations would not be unexpected.

II. Results.

1. Anterior Capsule.

The anterior capsule consisted of the antero-superior and the antero-inferior strata of the meniscus and thus attached the meniscus to the temporal bone and the condyle, respectively (Fig. 4-1).

The antero-superior stratum attached the meniscus to the anterior surface of the articular eminence.

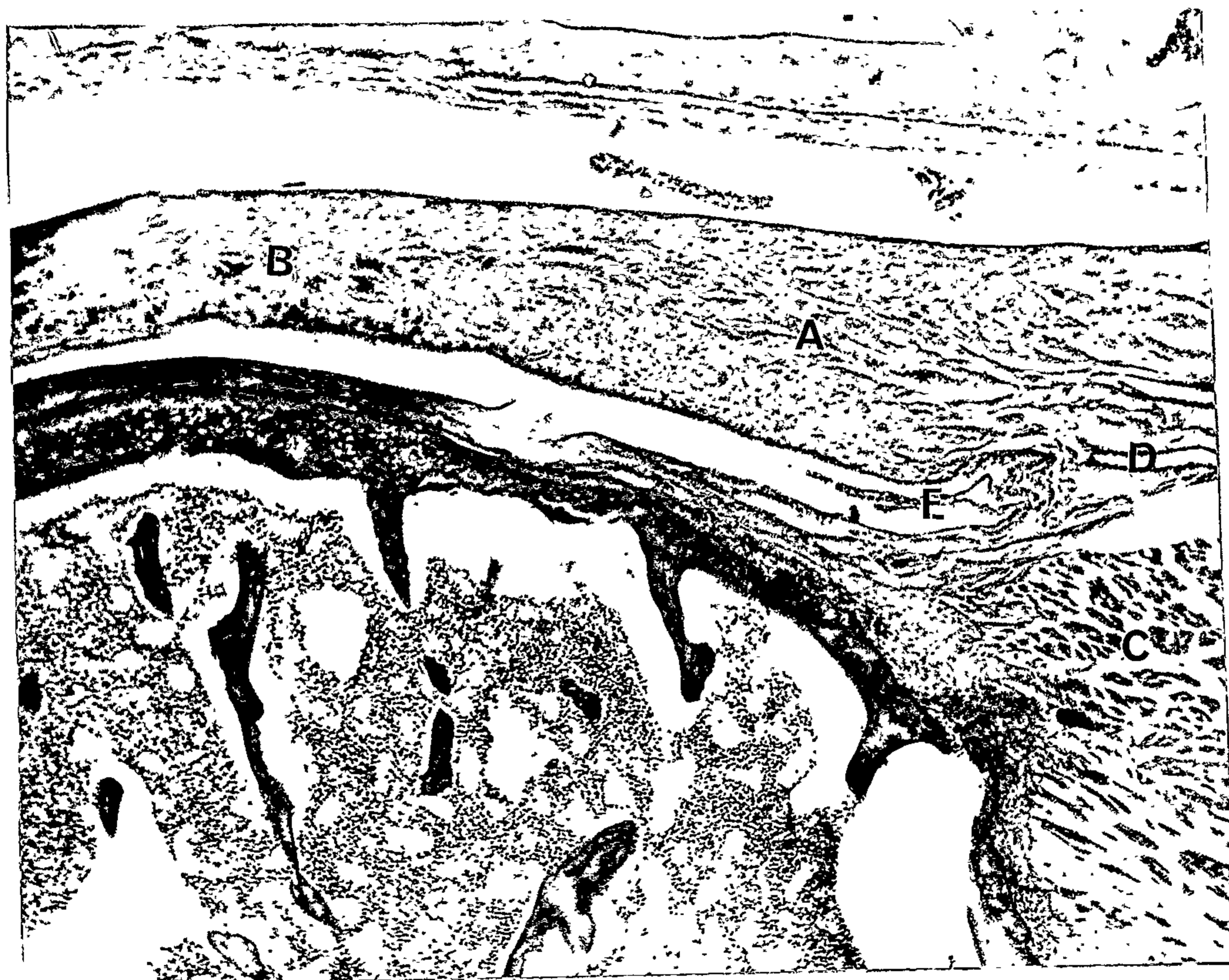

Figure 4-1. Anterior part of the temporomandibular joint x 40 (H and E).

- A - Pes Menisci
- B - Pars gracilis menisci
- C - Lateral pterygoid muscle
- D - Blood vessel
- E - Synovial villus

It was lined by a fibrous type of synovial membrane several cells thick (Fig. 4-2). The stratum itself consisted of fairly well orientated collagenous fibres.

The antero-inferior stratum consisted of collagenous fibres which passed from the helix of the pes menisci to the condyle, just above the insertion of the lateral pterygoid muscle (Figs. 4-1 and 4-3).

A single layer of synovioblast cells lined the surface of the antero-inferior stratum to provide the synovial membrane at the antero-inferior reflection of the inferior joint compartment (Fig. 4-3). Several small blood vessels and nerve bundles were also present in the inferior stratum (Figs. 4-1 and 4-3).

2. Posterior Capsule.

The posterior capsule was comprised of the postero-superior and the postero-inferior stratum of the meniscus. The postero-superior stratum was reflected onto the articular surface of the temporal bone (Fig. 4-4). The postero-inferior stratum attached the posterior part of the meniscus to the posterior extremity of the posterior slope of the condyle.

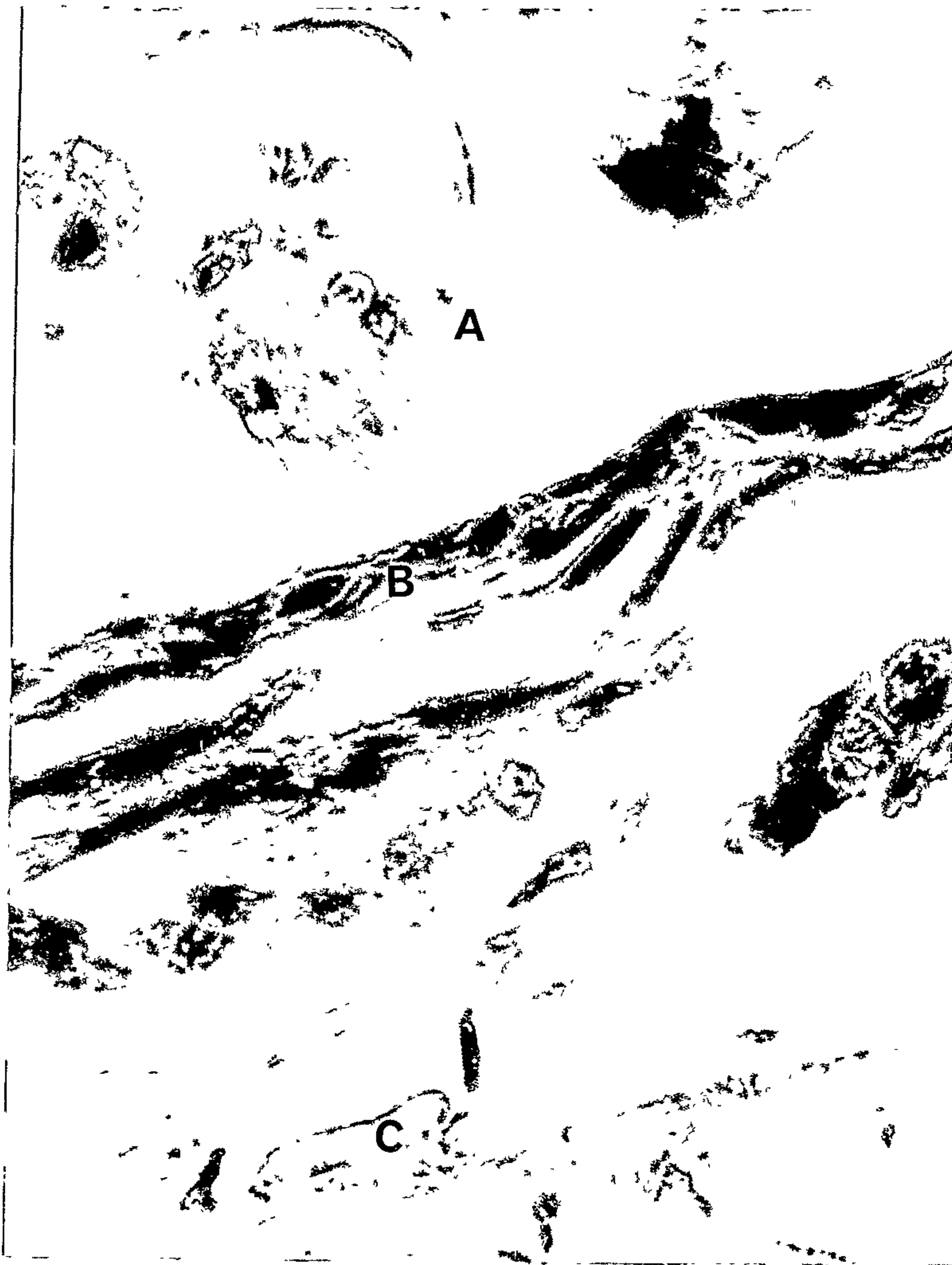

Figure 4-2. Superior surface of the antero-superior stratum x 600 (H and E).

- A - Superior joint compartment
- B - Synovioblasts
- C - Collagen fibre




Figure 4-3. Reflection of antero-inferior stratum
x 150 (H and E).

- A - Lateral pterygoid muscle
- B - Antero-inferior stratum
- C - Pes menisci
- D - Blood vessel
- E - Synovial membrane

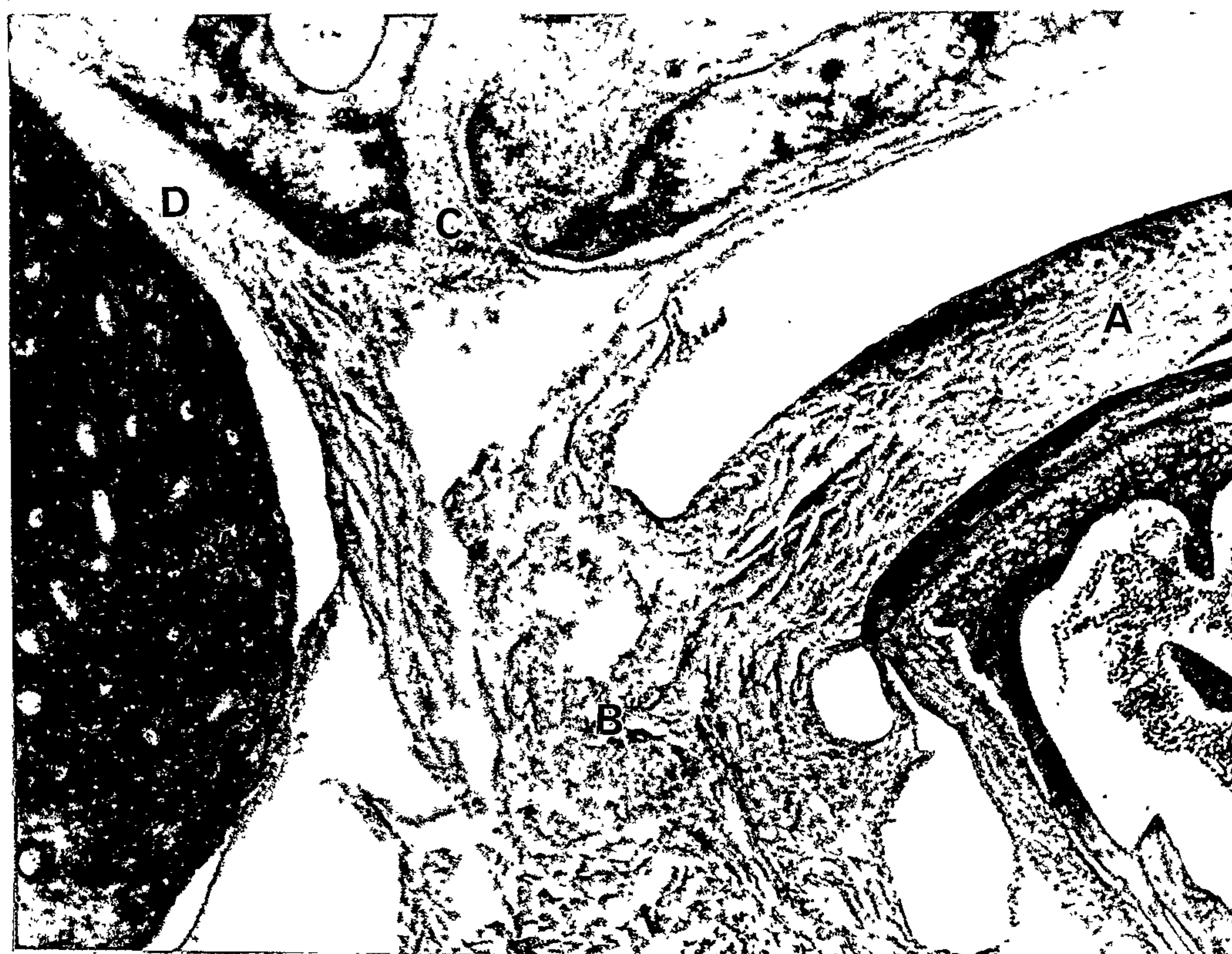

Figure 4-4. Posterior of the temporomandibular joint x 40 (H and E).

- A - Pars posterior menisci
- B - Bilaminar zone
- C - Squamo-tympanic fissure
- D - Petro-tympanic fissure

3. Meniscus.

The meniscus separated the head of the condyle from the temporal element of the temporomandibular joint. Macroscopically the meniscus in the monkey was similar to that in the human.

A. Pes Menisci.

The pes menisci consisted of fibrous tissue, that exhibited some vascularity, predominantly orientated in an antero-posterior direction (Fig. 4-5). Interspersed between the collagenous fibres were many elongated fibroblasts.

The superior and inferior surfaces of the pes were lined by a cellular type of synovial membrane (Figs. 4-6 and 4-7). On the superior surface the synovioblasts were of the squamous type, while the cuboidal type cells were predominant on the inferior surface. Synovial villi were apparent at the reflection of the pes onto the perichondrium of the condyle. These villi consisted of a fibrous tissue tongue that was covered by synovioblasts (Fig. 4-3).

B. Pars Gracilis Menisci.

The pars gracilis was interposed between the anterior slope of the mandibular fossa and the anterior articular surface of the condyle (Fig. 4-1).




Figure 4-5. Pes menisci x 150 (H and E).

- A - Fibroblast
- B - Blood vessel
- C - Synovial membrane

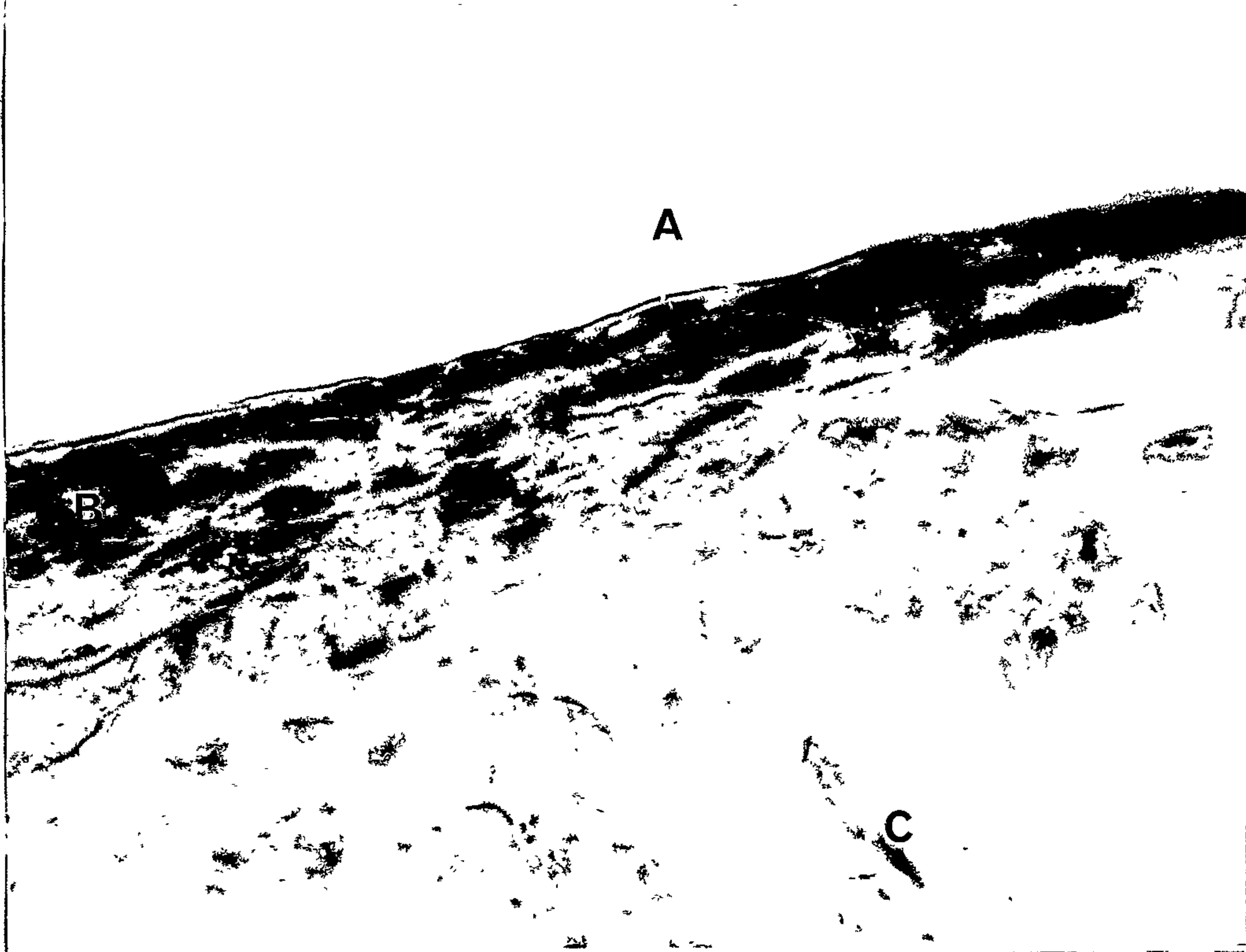


Figure 4-6. Superior surface of the pes menisci.
x 600 (H and E).

- A - Superior joint compartment
- B - Synovial membrane
- C - Fibroblast




Figure 4-7. Inferior surface of the pes menisci.
x 600 (H and E).

- A - Inferior joint compartment
- B - Synovial membrane
- C - Fibroblast

It consisted of fairly well orientated collagenous fibres and fibroblastic cells (Fig. 4-8). Its superior surface was lined by a fibrous type of synovial membrane (Fig 4-9). However the inferior surface was lined by an areolar type of synovial membrane (Fig. 4-10). The cells of both synovial membranes were fibroblastic in nature. No neural or vascular elements were identified.

C. Pars Posterior Menisci.

The pars posterior menisci consisted of unorientated collagenous fibres. Most of the cells appeared to be fibroblastic, while others appeared to be chondroid in nature (Fig. 4-11). Its superior and inferior surfaces were lined by a fibrous type of synovial membrane (Fig. 4-12 and 4-13). The cells of the synovial membrane of the superior surface were squamous type cells, but the cells of the inferior surface were more cuboidal.

D. Bilaminar Zone.

The bilaminar zone was found posterior to the pars posterior, in the area formed between the postero-superior and postero-inferior strata of the meniscus.




Figure 4-8. Pars gracilis menisci x 300
(H and E).

- A - Superior joint compartment
- B - Inferior joint compartment
- C - Fibroblast
- D - Synovial membrane

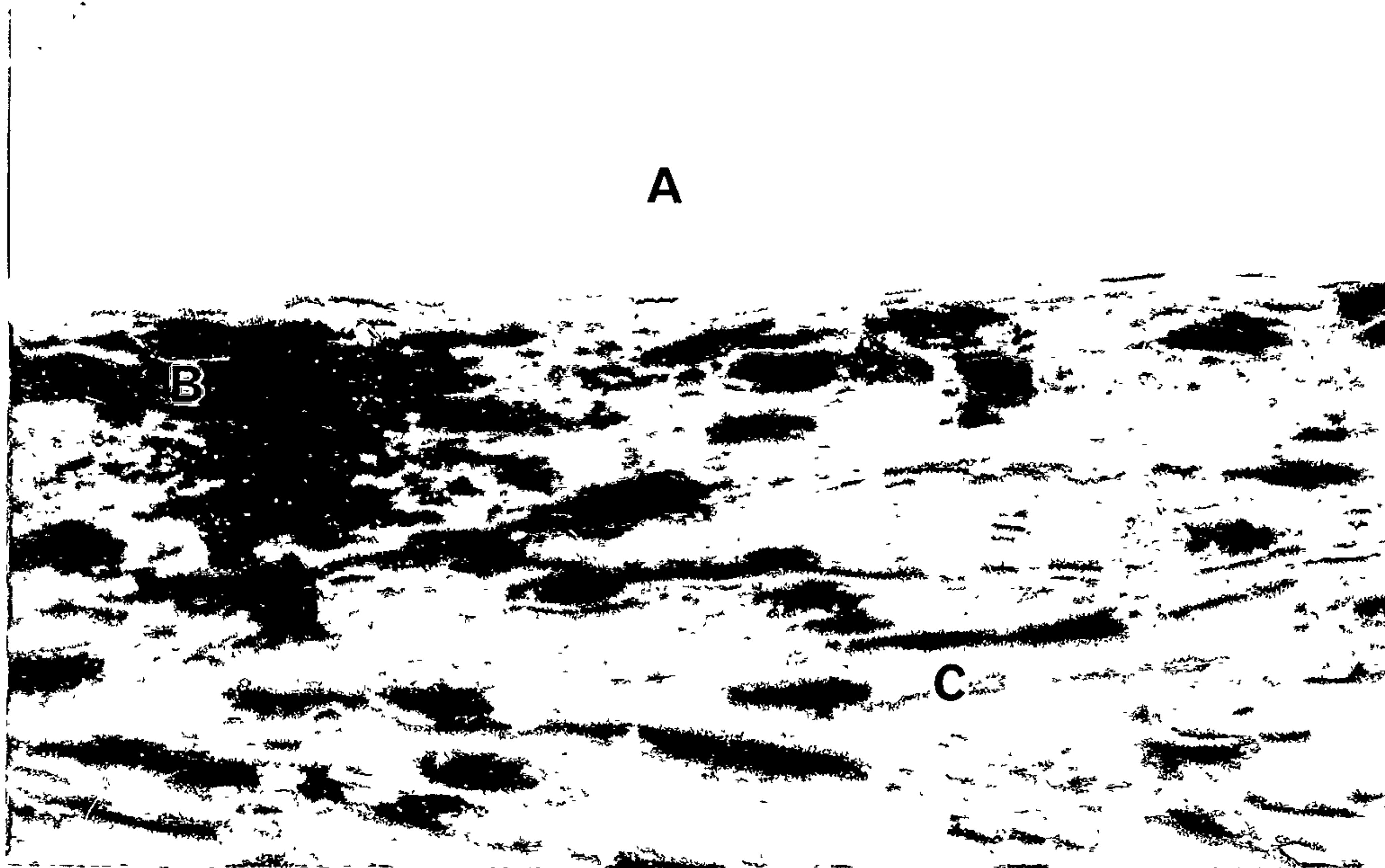


Figure 4-9. Superior surface of pars gracilis menisci
x 600 (H and E).

- A - Superior joint compartment
- B - Synovioblast
- C - Fibroblast.




Figure 4-10. Inferior surface of pars gracilis menisci x 600 (H and E).

- A - Inferior joint compartment
- B - Synovioblast
- C - Collagenous fibre

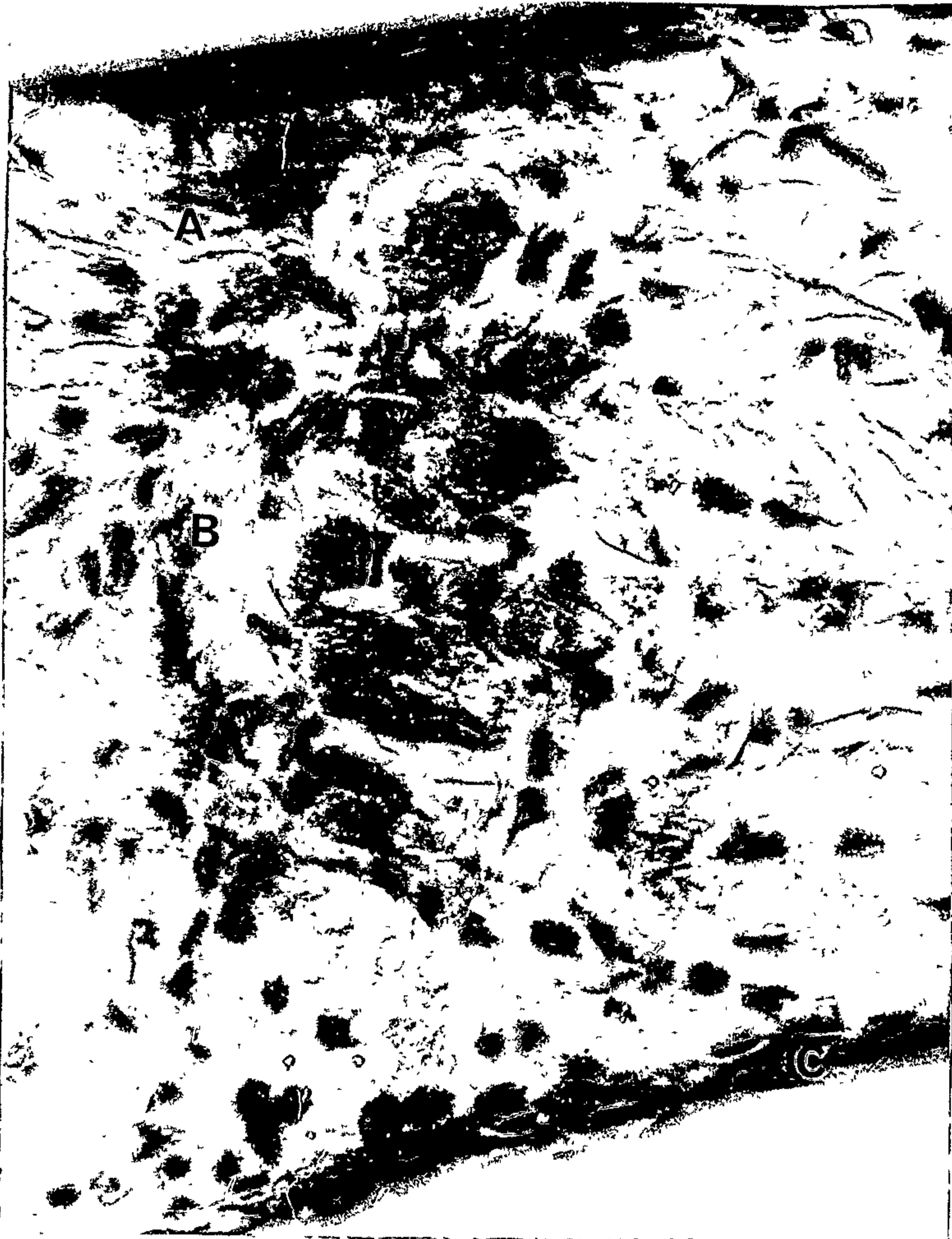

Figure 4-11. Pars posterior menisci x 400.

(H and E).

- A - Fibroblast
- B - Chondroid cell
- C - Synovial membrane

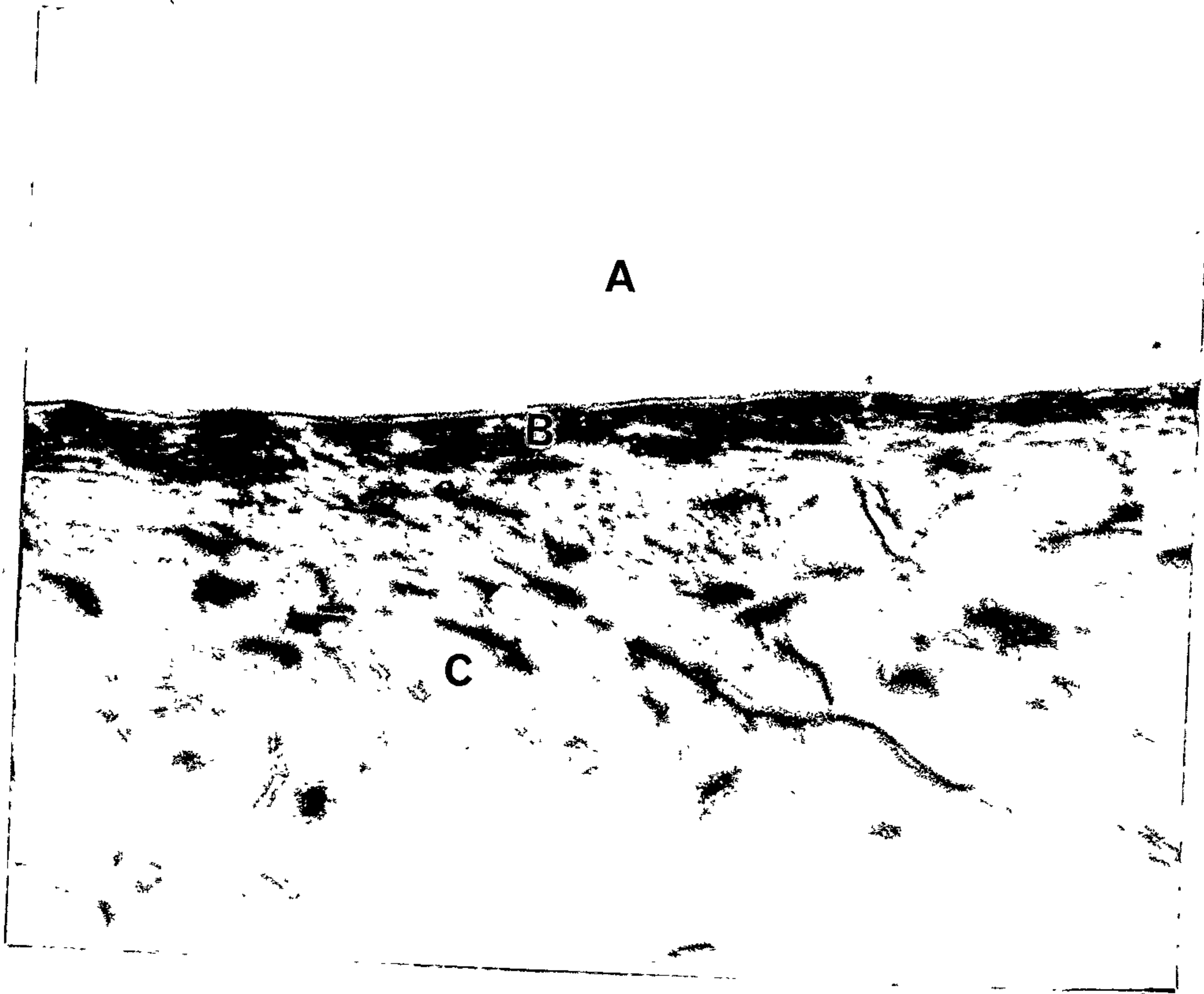

Figure 4-12. Superior surface of pars posterior menisci. x 600 (H and E).

- A - Superior joint compartment
- B - Synovioblast
- C - Fibroblast

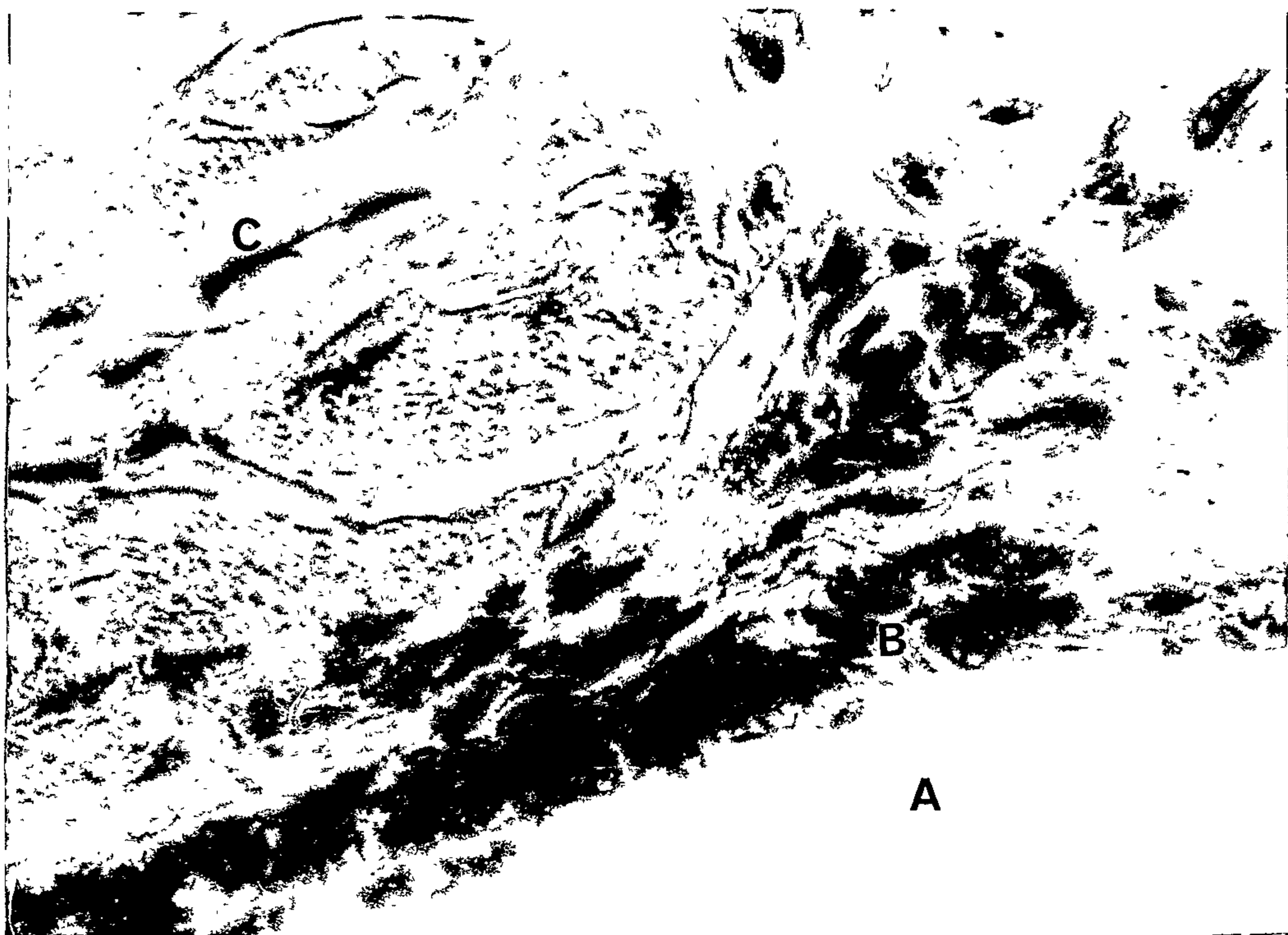


Figure 4-13. Inferior surface of pars posterior menisci x 600 (H and E).

- A - Inferior joint compartment
- B - Synovioblast
- C - Fibroblast

The structure and contents of the bilaminar zone differed greatly from the outer regions of the meniscus, as would be anticipated from the role the different parts play in function.

The bilaminar zone was composed of loosely packed wavy collagen and elastin fibres, between which were distributed numerous fibroblasts (Fig. 4-14).

The fibres had no definite orientation but inclined to follow the stratum of the meniscus to their attachments to the temporal bone and the neck of the condyle.

4. Articular Surface of the Temporal Bone.

The articular surface of the articular eminence and mandibular fossa was covered by perichondrium (Figs. 4-15 and 4-16).

The outer layer of the perichondrium consisted of orientated collagenous fibres and fibroblasts. The inner layer consisted of cells which were presumed to be young and resting chondrocytes. Beneath this layer was a discrete layer of hyaline cartilage which rested upon a layer of hypertrophic and degenerate chondrocytes. The cartilage matrix was seen to be calcified around a number of these chondrocytes. Beneath this was the cortical compacta of the temporal bone (Fig. 4-15).



Figure 4-14. Bilaminar zone x 150 (H and E).

- A - Superior joint compartment
- B - Inferior joint compartment
- C - Synovial villus
- D - Blood vessel

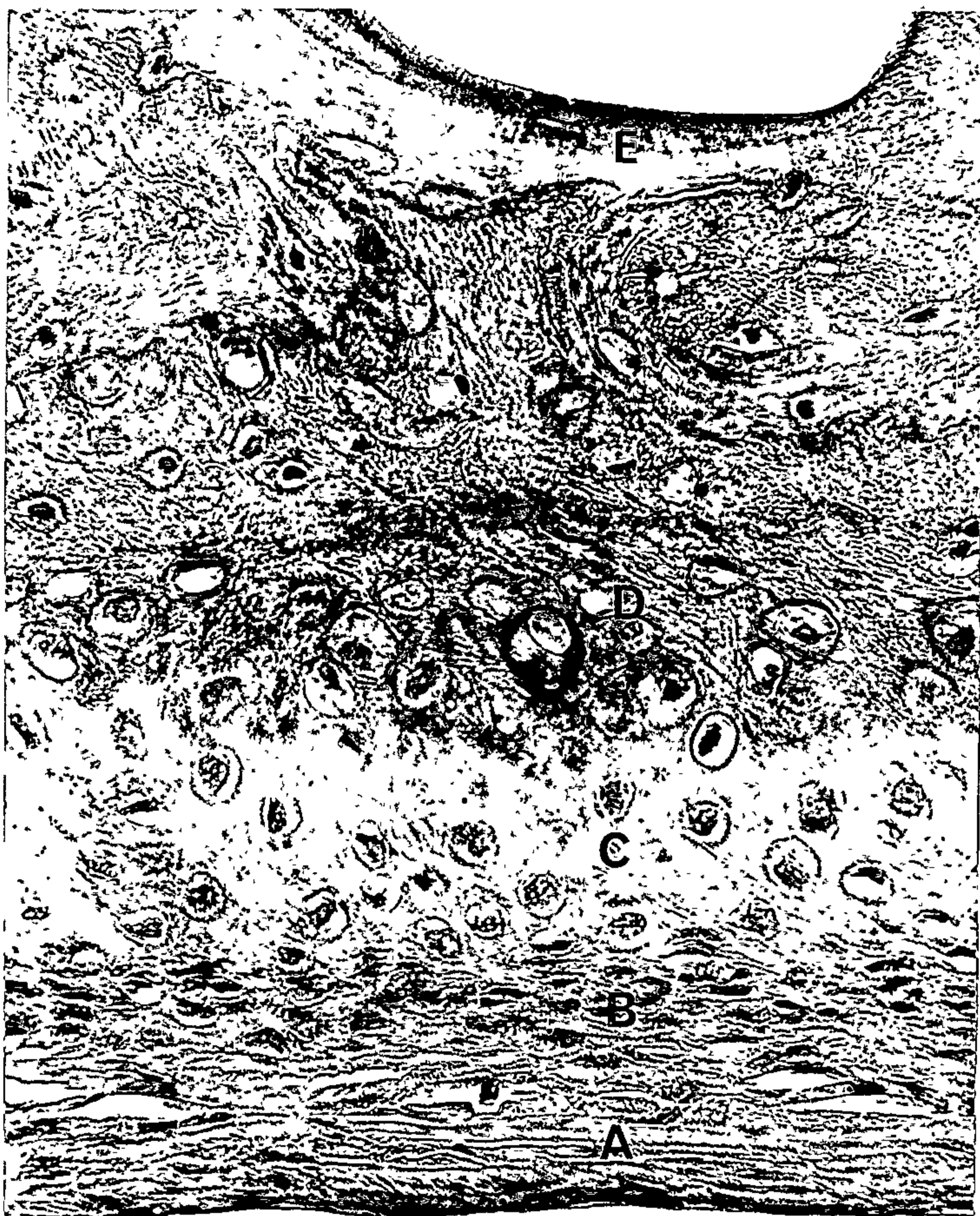

Figure 4-15. Periosteum of the mandibular fossa
x 300 (H and E).

- A - Fibrous layer
- B - Young and resting chondrocytes
- C - Hyaline cartilage
- D - Hypertrophic chondrocyte
- E - Cortical compacta

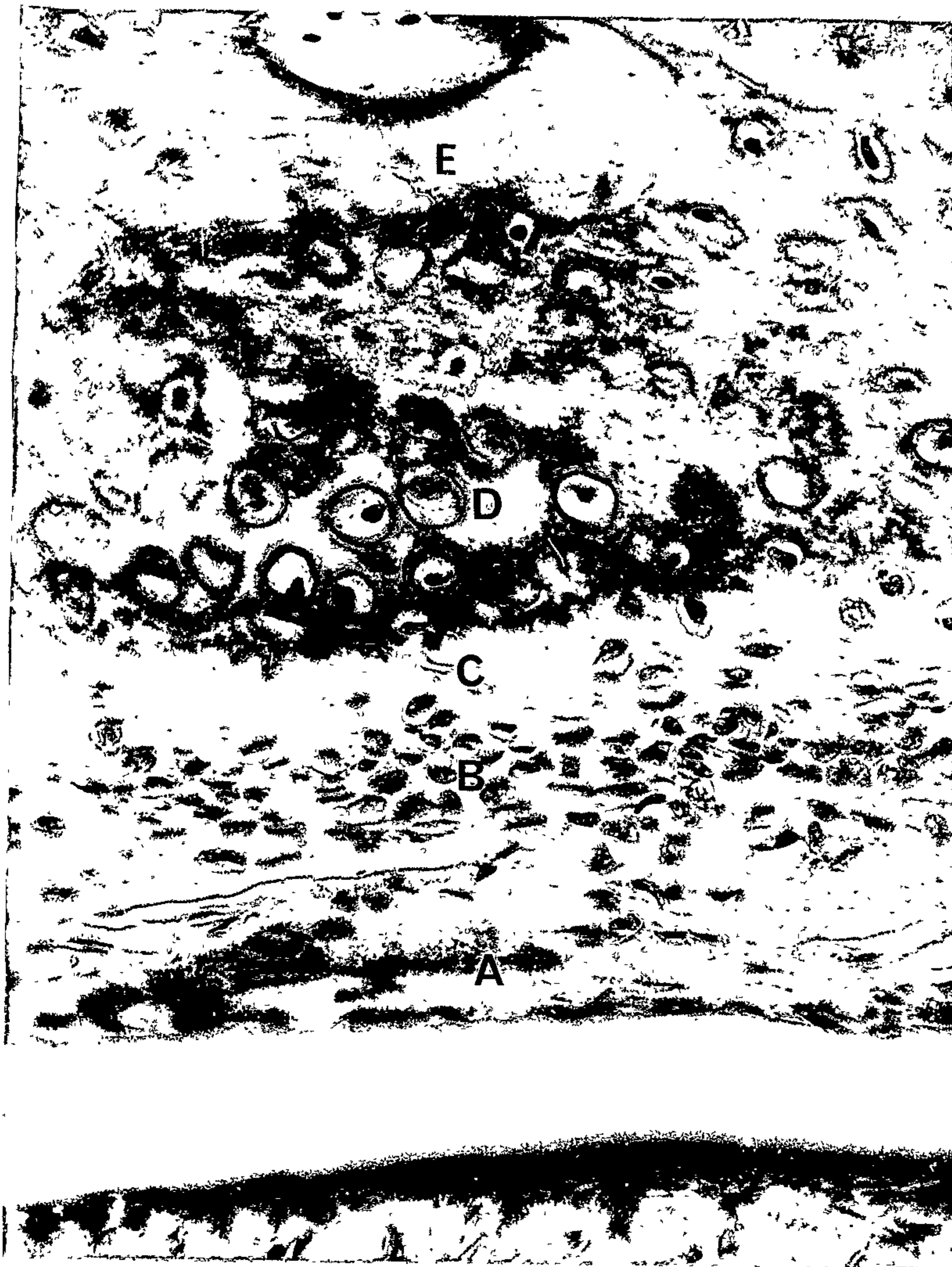

Figure 4-16. Periosteum of the articular eminence
x 300 (H and E).

- A - Fibrous layer
- B - Young and resting chondrocytes
- C - Hyaline cartilage
- D - Hypertrophic chondrocyte
- E - Cortical compacta

The mandibular fossa and articular eminence were similar in structure and components, except that the layer of hyaline cartilage was more extensive in the mandibular fossa.

5. Articular Surface of the Condyle.

A. Perichondrium.

The perichondrium that lined the articular surface of the condyle consisted of dense, tightly packed fibrous tissue with a moderate number of flattened fibroblasts. All the elements of the perichondrium were strictly orientated in an antero-posterior direction, over the curvature of the articular surface (Figs. 4-17 and 4-18).

B. Zone of Young and Resting Chondrocytes.

The perichondrium was in intimate contact, on its inferior surface, with a zone of young and resting chondrocytes. This layer was approximately five cells thick. The cells in this zone were ovoid in shape, in some areas, while in other areas they were more of the squamous type (Figs. 4-17 and 4-18).

C. Zone of Flattened Chondrocytes.

A zone of flattened chondrocytes, which was very thin and indefinite, lay immediately below the young and resting chondrocytes (Figs. 4-17, 4-18 and 4-19).

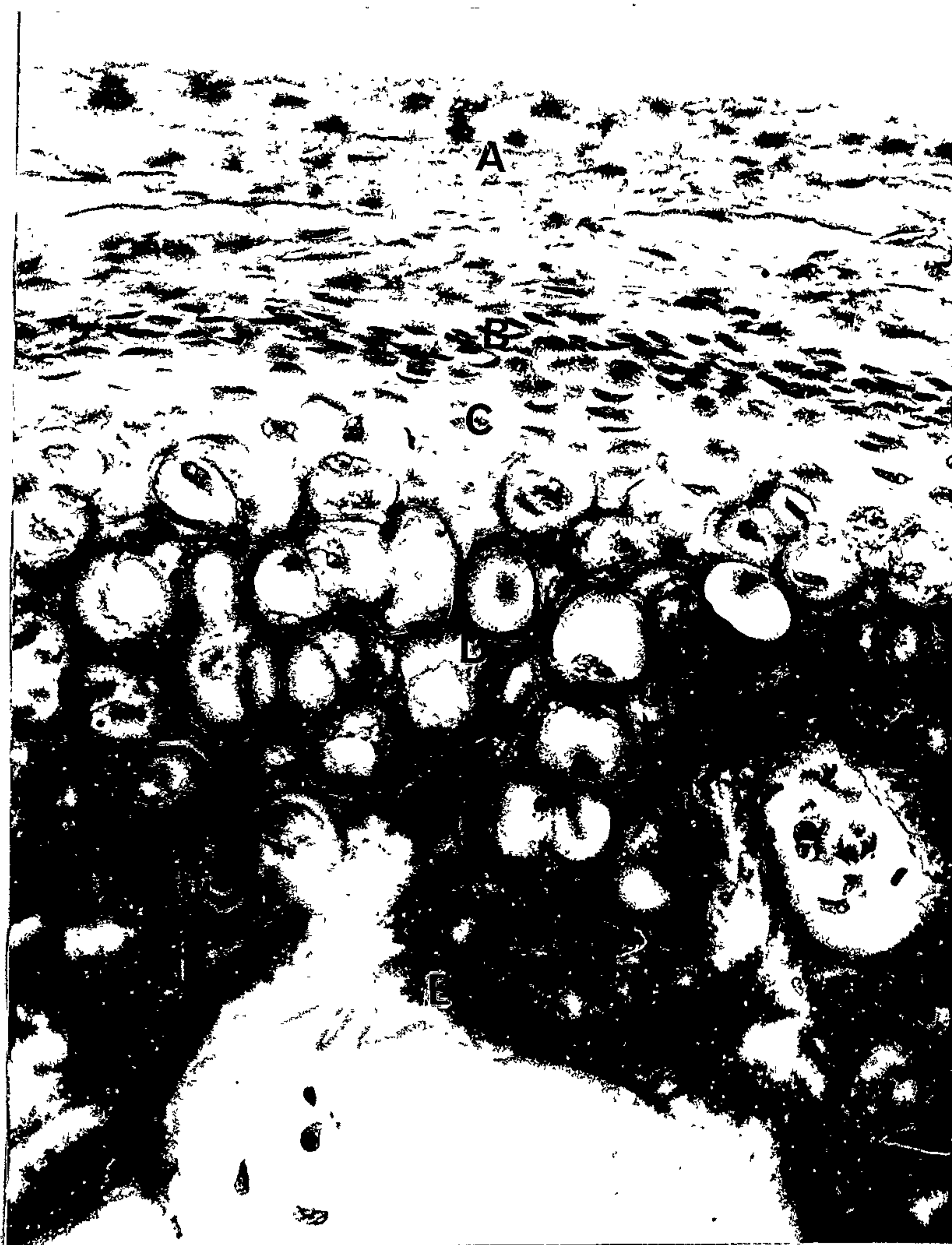


Figure 4-17. Crest of the condyle x 300
(H and E).

- A - Perichondrium
- B - Young and resting chondrocytes
- C - Flattened chondrocytes
- D - Hypertrophic and degenerate chondrocytes
- E - Calcified endochondral bone

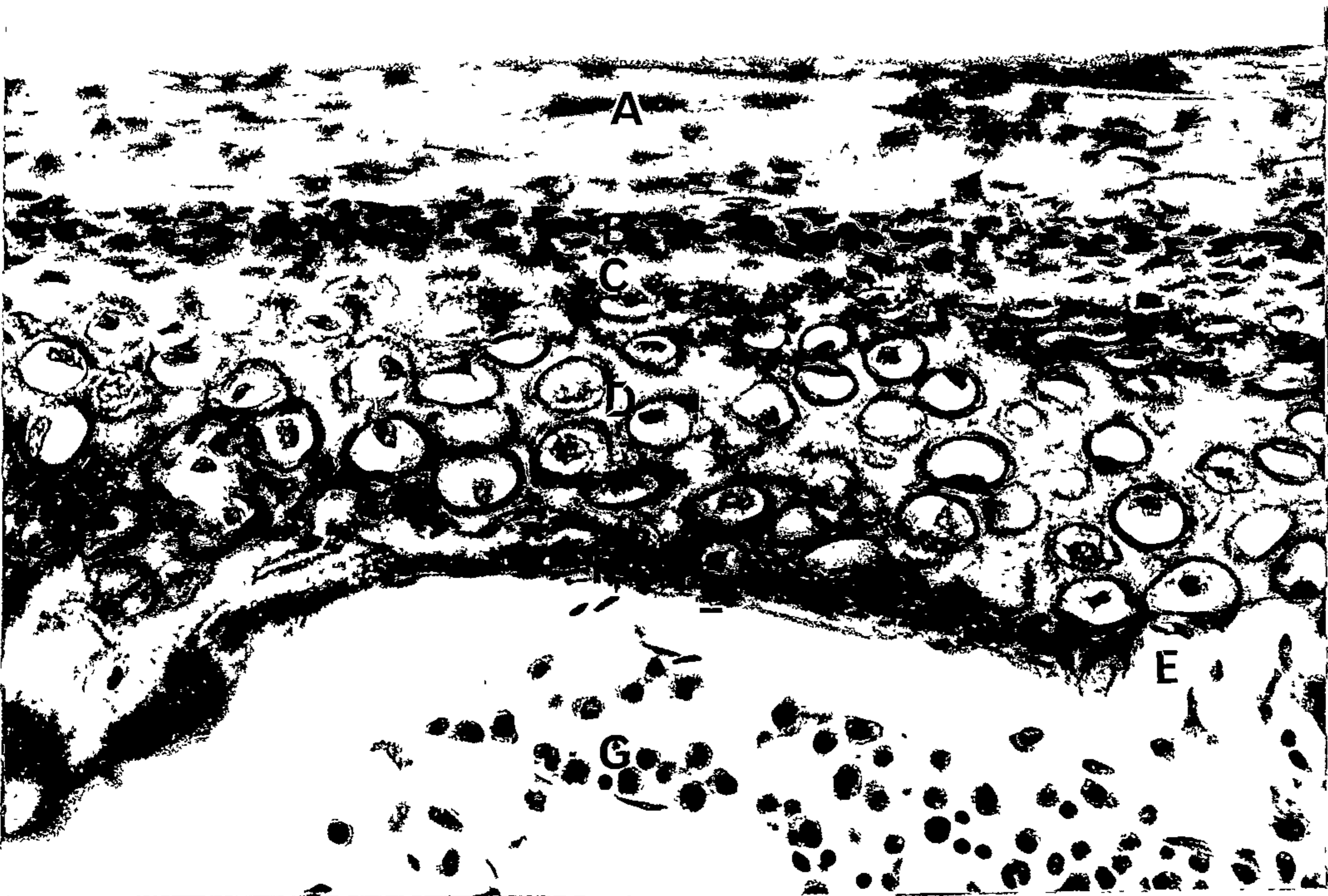


Figure 4-18. Anterior articular surface of the condyle x 300 (H and E).

- A - Perichondrium
- B - Young and resting chondrocytes
- C - Flattened chondrocytes
- D - Hypertrophic and degenerate chondrocytes
- E - Irruption
- F - Calcified endochondral bone
- G - Medullary space



Figure 4-19. Crest of the condyle x 350
(Silver and van Gieson).

- A - Perichondrium
- B - Young and resting chondrocytes
- C - Flattened chondrocytes
- D - Granules
- E - Hypertrophic and degenerate chondrocytes

In the sections that were treated with silver stain the inferior border of this zone was defined by a layer of darkly stained granules. Below the line of granules was a zone of hypertrophic and degenerate chondrocytes (Fig. 4-19).

D. Zone of Hypertrophic and Degenerate Chondrocytes.

The zone of hypertrophic and degenerate chondrocytes was rather thick. Differentiated, hypertrophic and degenerate chondrocytes were present, roughly in that order, from the more superficial layers down (Figs. 4-17 and 4-18). In the more superficial layers a cartilage matrix was present, but this was followed by mineralisation in the deeper tissue.

E. Zone of Irruption and Bone Formation.

The zone of irruption formed the inferior extremity of the calcified cartilage of the zone of hypertrophic and degenerate chondrocytes (Fig 4-20). The zone of irruption consisted of dissolution of the calcified cartilage and its replacement with calcified endochondral bone, but some remnants of the calcified cartilage persisted within the bone. The endochondral bone formed into trabeculae that were orientated at right angles to the articular surface of the condyle (Fig. 4-20).

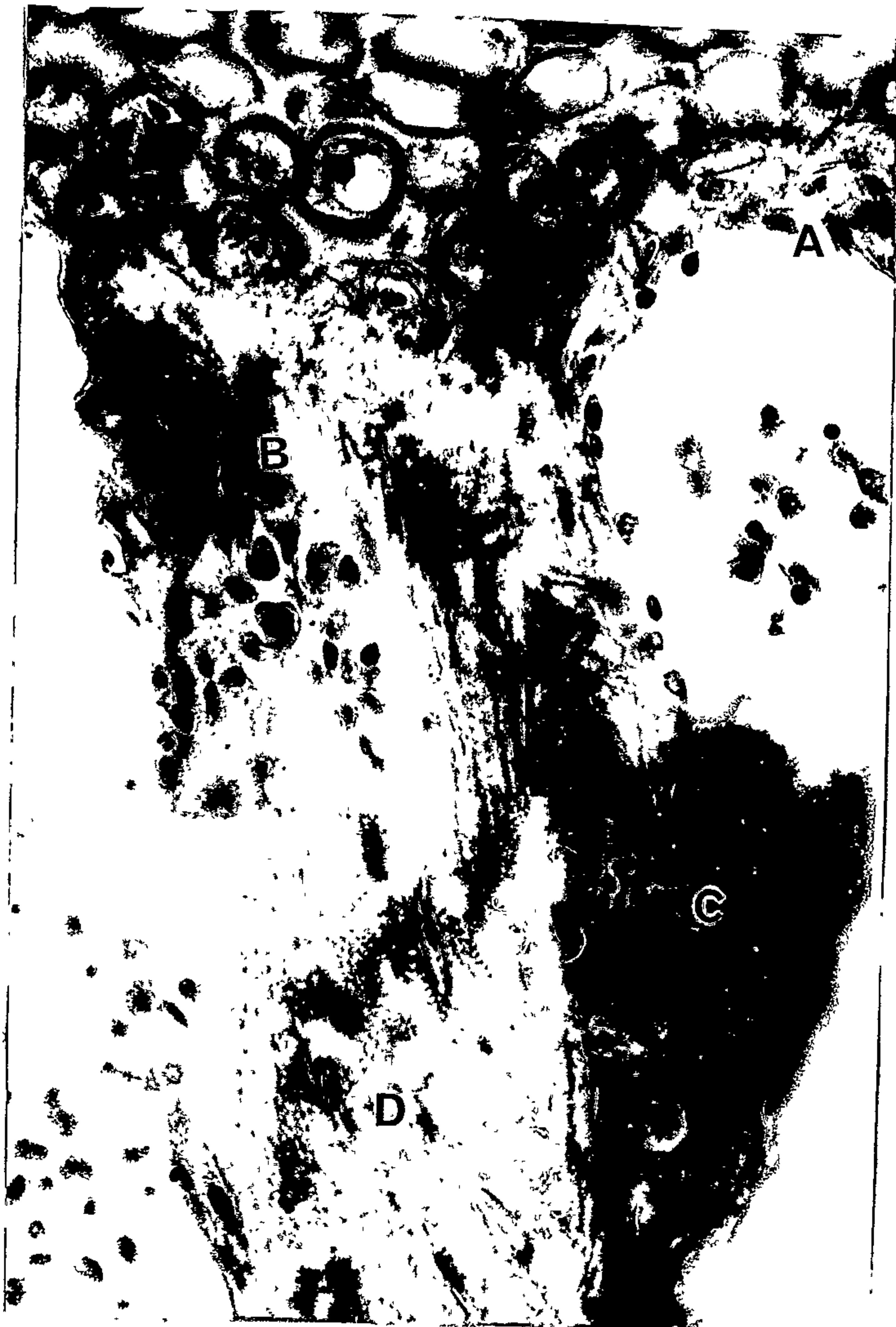

Figure 4-20. Irruption with endochondral trabecula at right angles to the curvature of the condyle x 360 (H and E).

- A - Irruption
- B - Bone deposition
- C - Calcified cartilage
- D - Endochondral bone

6. Synovial Membrane.

Synovial membrane was present lining all surfaces of the joint compartments, with the exception of the articular surfaces of the temporal bone and condyle.

A. Antero-superior Stratum.

The anterior extremity of the superior joint compartment was formed by the reflection of the antero-superior stratum of the meniscus onto the temporal bone. This reflection was lined by a cell-rich type of synovial membrane which gave the appearance of having small villi. The cells that formed the synovial membrane were roughly cuboidal and were supported by connective tissue and collagen fibres (Fig. 4-21).

The antero-superior stratum was lined by a synovial membrane of squamous type synovioblasts (Fig. 4-2).

B. Antero-inferior Stratum.

At the reflection of the antero-inferior stratum onto the neck of the condyle were several villi that projected into the antero-inferior joint compartment. These villi were very long, but, thin being approximately three cells in thickness.




Figure 4-21. Synovial membrane of the antero-superior joint compartment x 450 (Silver and van Gieson).

- A - Superior joint compartment
- B. - Synovial membrane
- C - Collagen fibres

The villi were composed almost exclusively of synovial cells but a thin core of fibrous tissue supported these cells (Figs. 4-3 and 4-23).

Along the inferior surface of the antero-inferior joint compartment was a one cell thick synovial membrane (Fig. 4-23).

C. Postero-Superior Stratum.

At the reflection of the postero-superior stratum a very rich synovial membrane was evident. A large villous was present between the menisci and the temporal bone projecting into the joint compartment space. This villous had a thin fibrous tissue core that was covered completely by a cell rich synovial membrane of several cells thickness. The synovial cells were cuboidal in shape (Fig. 4-22).

D. Postero-inferior Stratum.

At the reflection of the postero-inferior stratum of the meniscus, onto the neck of the condyle, was a short but thick villous that bulged into the inferior joint compartment space (Fig. 4-24). This villous was covered by a cell rich synovial membrane, of several cells thickness (Fig. 4-24).

E. Pes Menisci.

The superior surface of the pes menisci was lined by a thin synovial membrane. The cells were of the squamous type and were in intimate contact with the superior joint compartment (Fig. 4-6).




Figure 4-22. Synovial villus of the postero-superior joint compartment reflection x 500 (H and E).

- A - Postero-superior joint compartment
- B - Synovial villus
- C - Synovial membrane




Figure 4-23. Synovial membrane of the inferior surface of the pes menisci x 450 (H and E).

- A - Pes menisci
- B - Synovial membrane
- C - Synovial villi
- D - Antero-inferior stratum

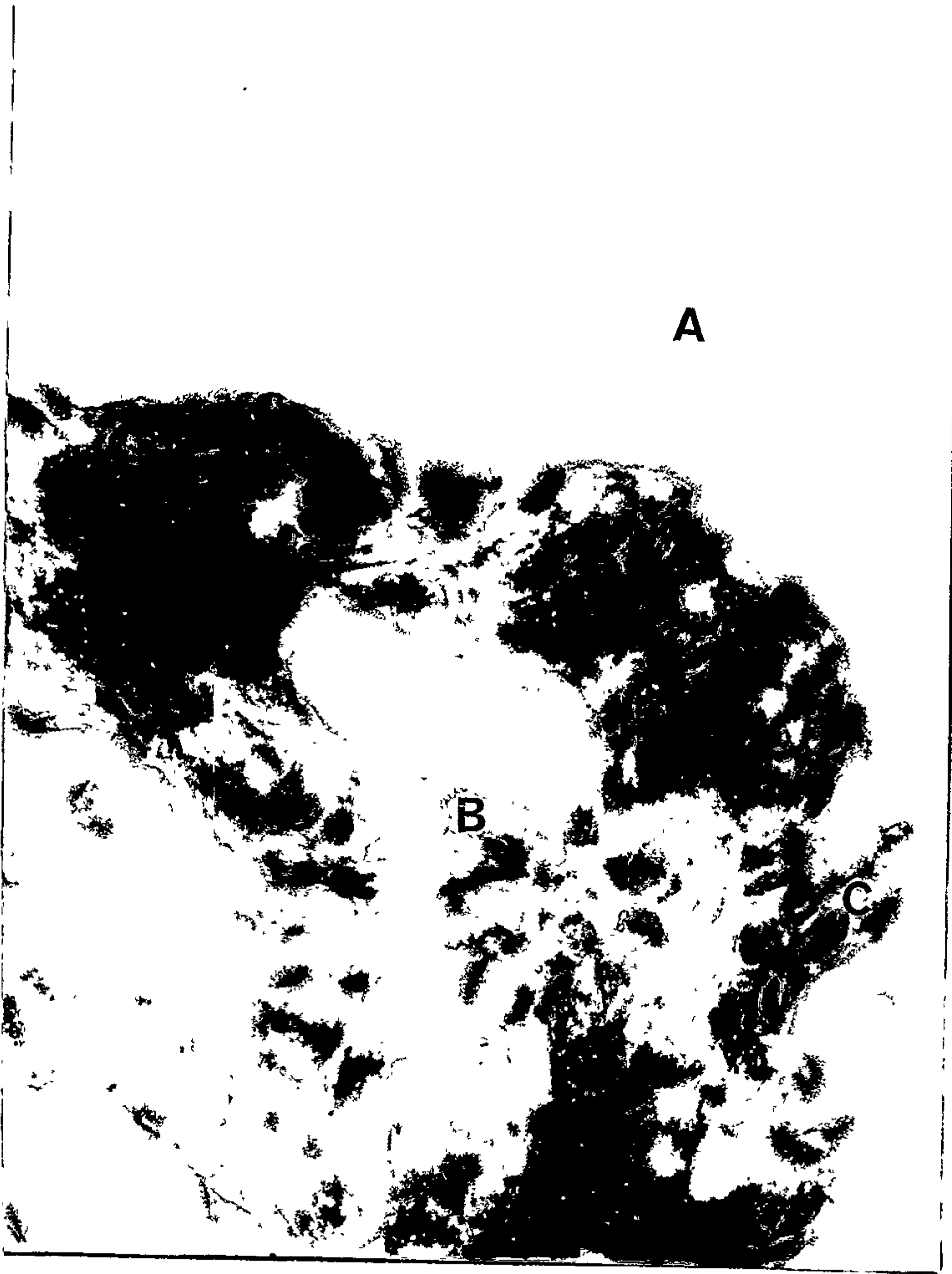

Figure 4-24. Synovial villus of the postero-inferior stratum x 500 (H and E).

- A - Postero-inferior joint compartment
- B - Synovial villus
- C - Synovioblast

The synovial membrane on the inferior surface was in direct communication with the inferior joint compartment and was composed of cuboidal type cells (Fig. 4-7).

F. Pars Gracilis Menisci.

The structural difference between the pes and the gracilis was not conspicuous, however the synovial membrane lining these areas was fairly obviously different. Whereas the synovial cells of the pes were in intimate contact with the surface, those of the gracilis were covered by a thin layer of fibrous tissue (Figs. 4-9 and 4-10).

G. Pars Posterior Menisci.

As in the pars gracilis a fibrous type of synovial membrane lined the superior and inferior surfaces of the pars posterior (Figs. 4-12 and 4-13). The synovial membrane on both surfaces was again covered by a thin layer of fibrous tissue.

Discussion.

Several studies (BREITNER, 1931; BAUM and DERWICHSWELLER, 1961) have been reported in which changes were induced in the condylar articular tissues of monkey. However, these studies did not relate this condylar response to any region of the condylar articular tissues. In particular little interest has been shown in the description of the histology of the condylar tissues in these monkeys.

The condylar articular tissue of a 4 month old Bonnet Monkey (*Macaca radiata*) examined in this study was found to have histological features similar to that of a 19 month human, as illustrated by SHARPE et al (1965). The cellular maturity of the monkey appeared to be not quite as advanced as in the 19 month human but the cellular organisation was quite similar.

In the young monkey an articular zone of fibrous tissue, a proliferative zone of young and resting chondrocytes and hypertrophic zone of hypertrophic chondrocytes were clearly demonstrated. The chondrocytes were surrounded by large lacunae, as would be expected from their very young age.

In the four month Bonnet monkey the articular chondrocytes of the hypertrophic zone presented an appearance similar to that seen in the epiphyseal plate of a young human (OGSTON, 1875, 1878).

A synovial membrane was found to line all surfaces of the joint compartment, with the exception of the articular surfaces of the temporal bone and the condyle. An areolar type of synovial membrane was evident lining the various strata and the pes meniscus, while a fibrous type was present lining the pars gracilis menisci and the pars posterior menisci.

Chapter 5. The Histology of the Aged Human

Temporomandibular Joint Complex.

<u>Contents</u>	<u>Page.</u>
I Introduction	129.
II Results	129.
1. Anterior Capsule	129.
2. Posterior Capsule	131.
3. Menisci	131.
A. Pes menisci	134.
B. Pars gracilis menisci	134.
C. Pars posterior menisci	134.
D. Bilaminar zone	145.
4. Articular Surface of the Temporal bone	145.
5. Articular Surface of the Condyle	157.
6. Synovial Membrane	161.
A. Antero-superior Reflection	161.
B. Antero-inferior Reflection	163.
C. Postero-superior Reflection	163.
D. Postero-inferior Reflection	168.

E. Pes menisci	168.
F. Pars gracilis menisci	171.
G. Pars posterior menisci	171.
III Discussion	172.

Chapter 5.

The Histology of the Aged Human Temporomandibular Joint Complex.

I. Introduction.

The temporomandibular joints described here were from aged cadavers. All the cadavers were edentulous, two being male and the third being female. The following description was a composite from the three joints.

II. Results.

1. Anterior Capsule.

The anterior capsule was formed by the antero-superior and the antero-inferior stratum of the meniscus and thus attached the anterior part of the meniscus to the temporal bone and condyle, respectively. The strata formed a reflection at their attachments to the temporal bone and condyle, which formed the anterior extremities of the superior and inferior joint compartments.

The lateral pterygoid muscle was attached to the anterior part of the capsule, in the region of the helix of the pes, as well as to the neck of the condyle (Fig 5-1).

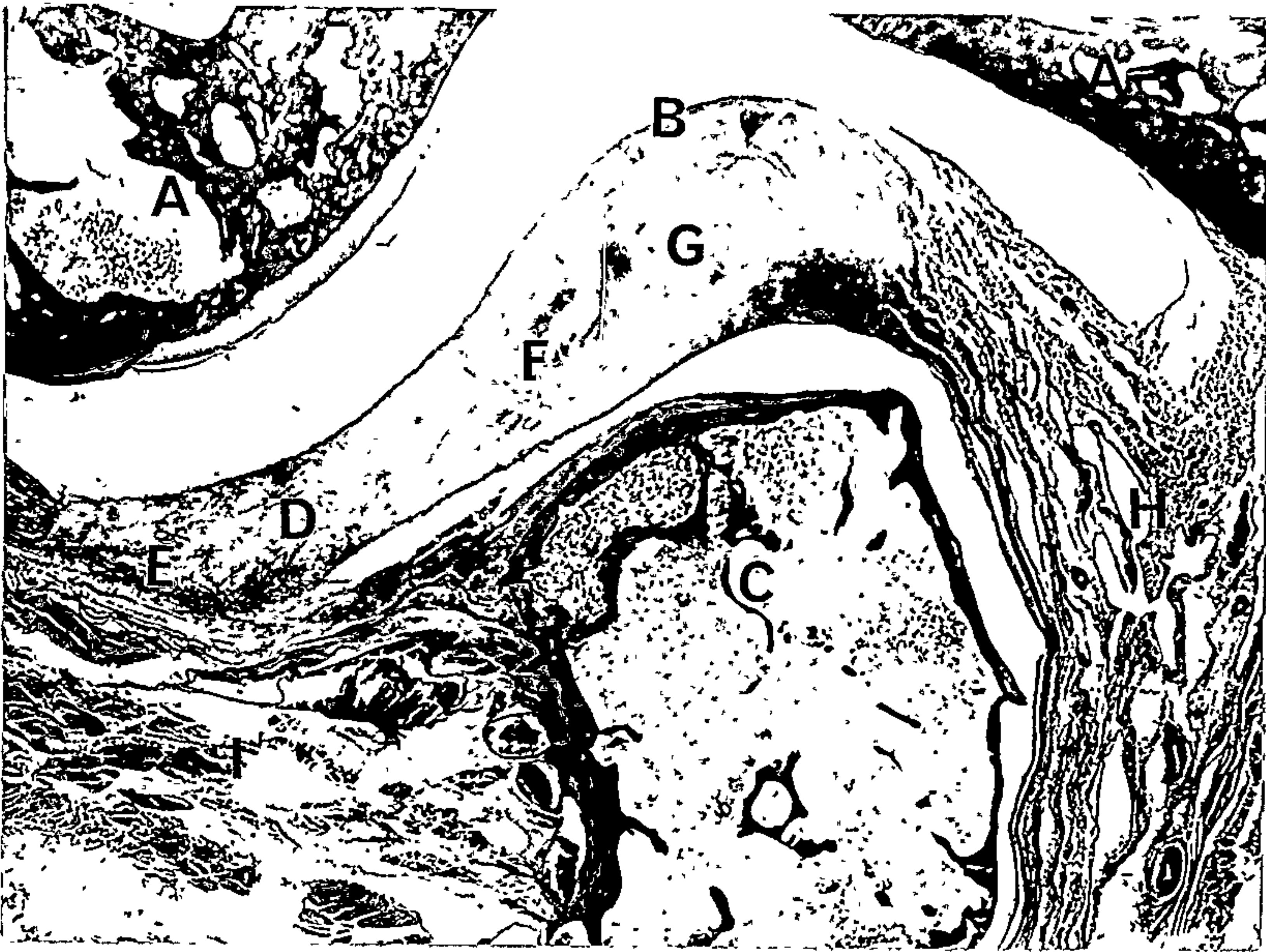

Figure 5-1. Low power photomicrograph of an aged human temporomandibular joint, sagittal section x 4 (H and E).

- A - Temporal bone
- B - Meniscus
- C - Condyle
- D - Pes menisci
- E - Head of the pes menisci
- F - Pars gracilis menisci
- G - Pars posterior menisci
- H - Bilaminar zone
- I - Lateral pterygoid muscle

2. Posterior Capsule.

The posterior capsule was formed by the postero-superior and the postero-inferior strata of the meniscus, which attached the posterior part of the meniscus to the temporal bone and the condyle, respectively.

These two strata were the posterior extensions of the meniscus, but their structure was vastly different to that of the meniscus (Fig. 5-1). The postero-superior stratum consisted of collagen fibres and thick elastic fibres (Figs. 5-1 and 5-2), whereas the postero-inferior stratum was a ligamentous structure with fine elastic fibres (Figs. 5-1 and 5-3).

The postero-superior stratum was orientated in an antero-posterior direction at its contact with the pars posterior menisci, and then passed in a postero-superior direction (Fig. 5-1). In contrast, the postero-inferior stratum was orientated in a postero-inferior direction for its entire extent (Fig. 5-1).

3. Meniscus.

The meniscus could be divided into several different regions on histological and macroscopic grounds.

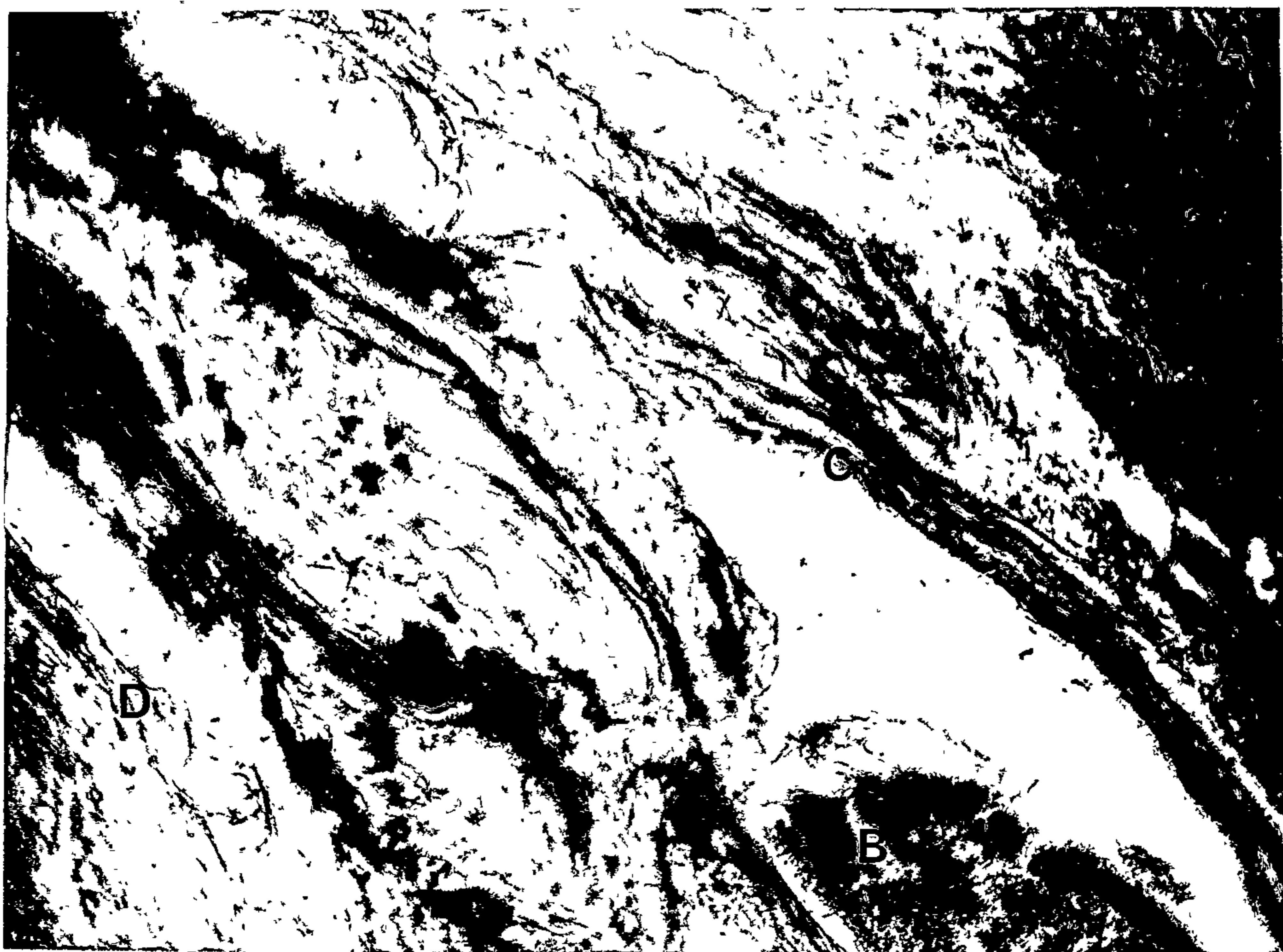


Figure 5-2. Attachment of the postero-superior stratum of the meniscus to the temporal bone x 60 (Aldehyde Fuchsin).

- A - Temporal bone
- B - Blood vessel
- C - Thick elastic fibre
- D - Thin elastic fibre




Figure 5-3. Postero-inferior stratum x 60.
(Aldehyde fuchsin).

- A - Fine elastic fibre
- B - Collagen fibres

A. Pes Menisci.

The pes menisci was the anterior part of the meniscus from which arose the two anterior strata that formed the anterior capsule (Fig. 5-1).

The pes menisci consisted of wavy collagen fibres together with fine elastic fibres (Figs. 5-4 and 5-5), all of which were orientated in an antero-posterior direction until they joined the strata at the helix, where the fibres lost their orientation (Fig. 5-6). Fibroblasts were found but were not numerous (Figs 5-4 and 5-5). Between the fibres of the pes were a number of blood vessels (Fig. 5-6).

The superior surface of the pes was covered by an areolar type of synovial membrane (Fig. 5-4), whereas the inferior surface was covered by a fibrous type of synovial membrane (Fig. 5-5).

B. Pars Gracilis Menisci.

The pars gracilis menisci was immediately posterior to the pes, with which it was continuous (Fig. 5-1). The gracilis comprised approximately one third of the length of the meniscus and it was interposed between the anterior articular slope of the condyle and the corresponding part of the glenoid fossa (Fig. 5-1).

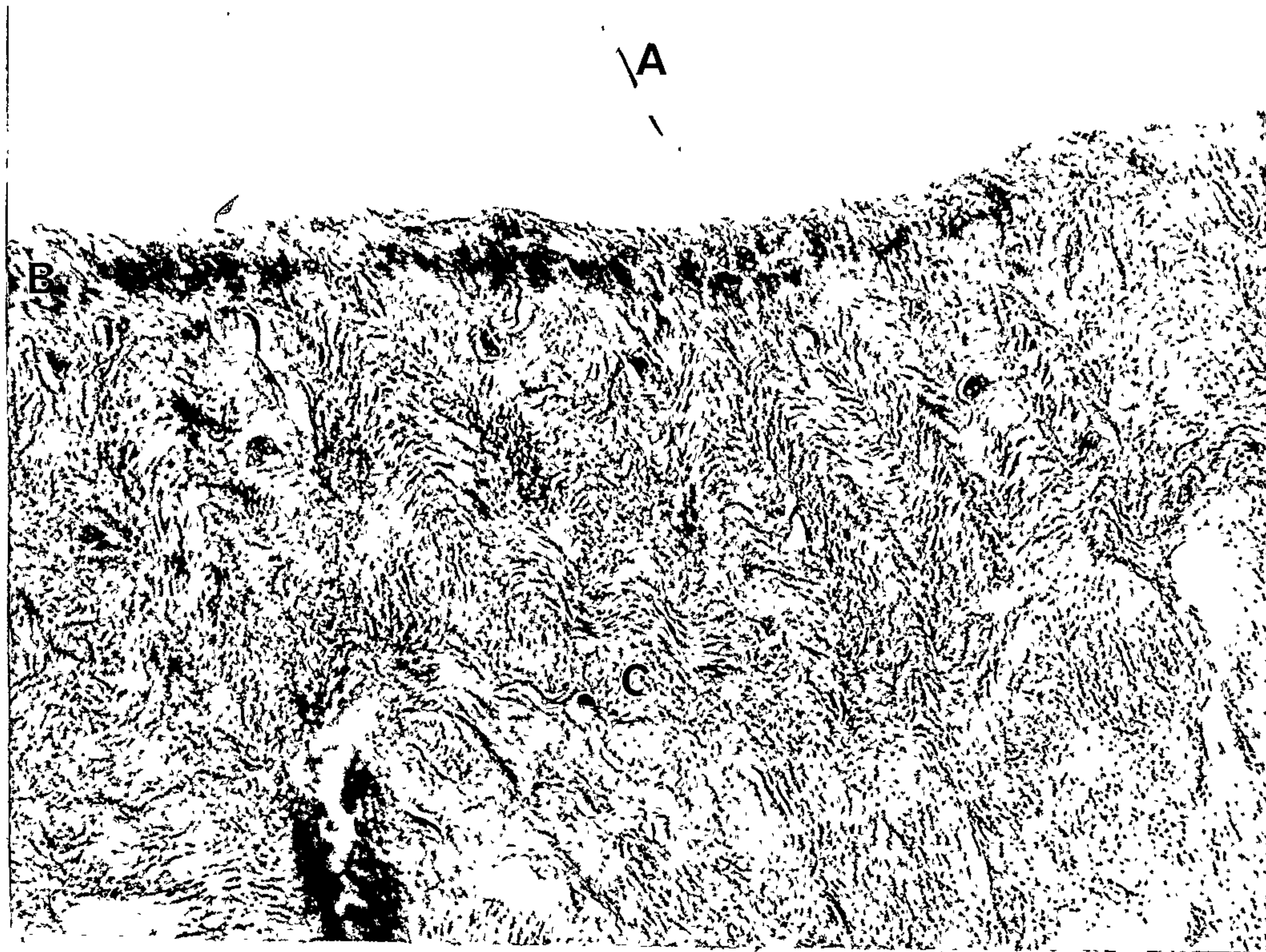


Figure 5-4. Superior surface of the pes menisci x 300 (H and E).

- A - Superior joint compartment
- B - Synovial membrane
- C - Pes menisci.

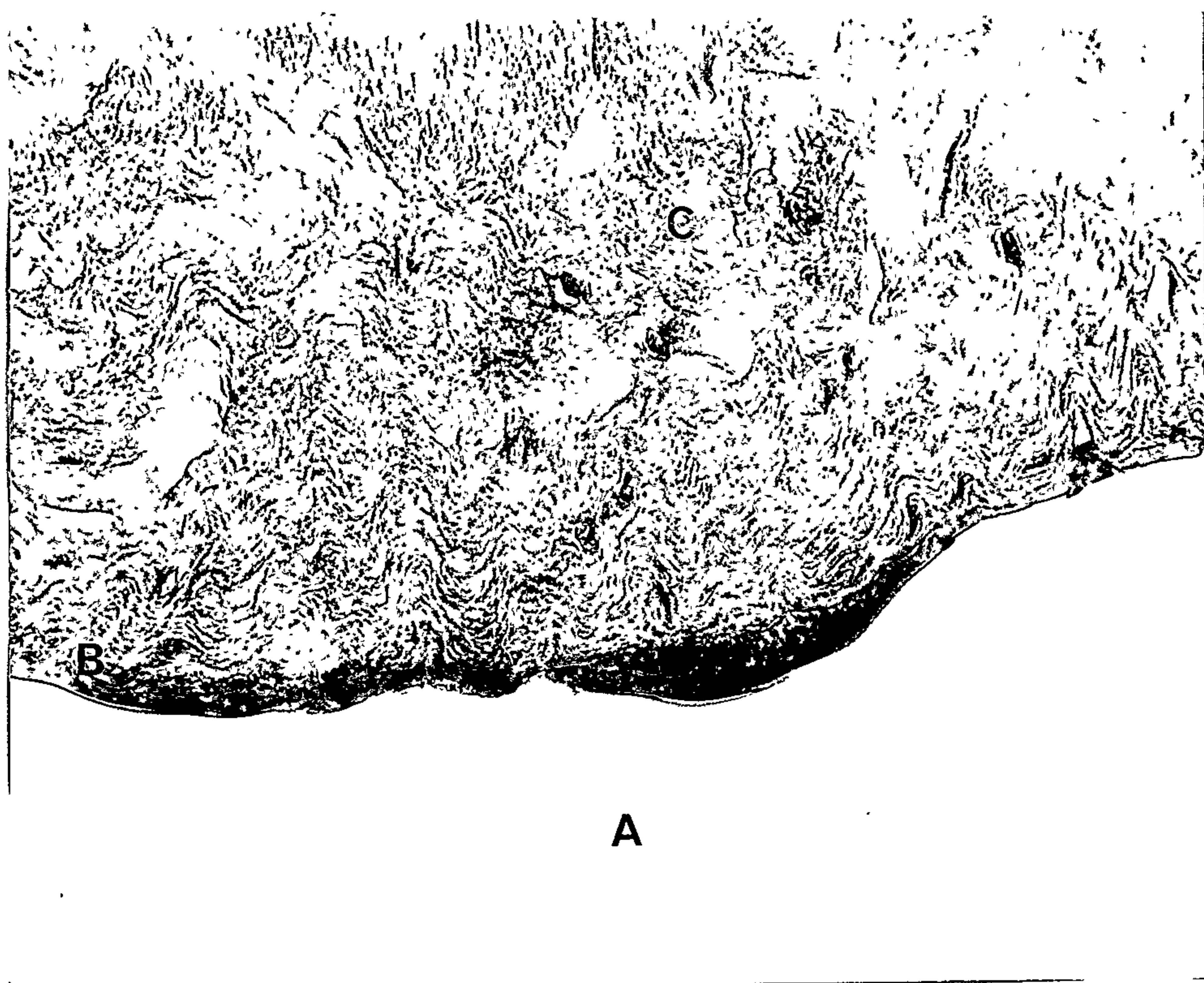


Figure 5-5. Inferior surface of the pes menisci.
x 300 (H and E).

- A - Inferior joint compartment
- B - Synovial membrane
- C - Pes menisci



Figure 5-6. Hela of the pes menisci x 120.
(H and E).

- | | | |
|---|---|------------------------------|
| A | - | Unorientated collagen fibres |
| B | - | Fibroblast |
| C | - | Blood vessel |

The gracilis consisted of collagen fibres that were principally orientated in an antero-posterior direction, but in the more central regions a whorled appearance was evident (Fig. 5-7). A chondroid type of cell was present between the collagen fibres. These cells were ovoid in shape and were surrounded by a capsule of lighter stained matrix (Fig. 5-8). Throughout the gracilis were areas of tissue whose staining characteristics gave the appearance of cartilaginous matrix (Fig. 5-9).

The junction between the pars gracilis and the pes could be identified by a change in cellular morphology. The cells in the pes were fibroblastic in nature, whereas the cells in the gracilis were chondroid (Fig. 5-10), especially in the inferior regions (Fig. 5-12). No neural or vascular elements were observed.

The superior and inferior surfaces of the gracilis were lined by a fibrous type of synovial membrane (Figs. 5-11 and 5-12). In both cases the synovial cells were not in contact with the joint compartments, but were covered by fibrous tissue.

C. Pars Posterior Menisci.

The pars posterior menisci was the posterior extension of the pars gracilis, but there was no clear histological demarcation between the two areas, as there had been between the pes and the gracilis.

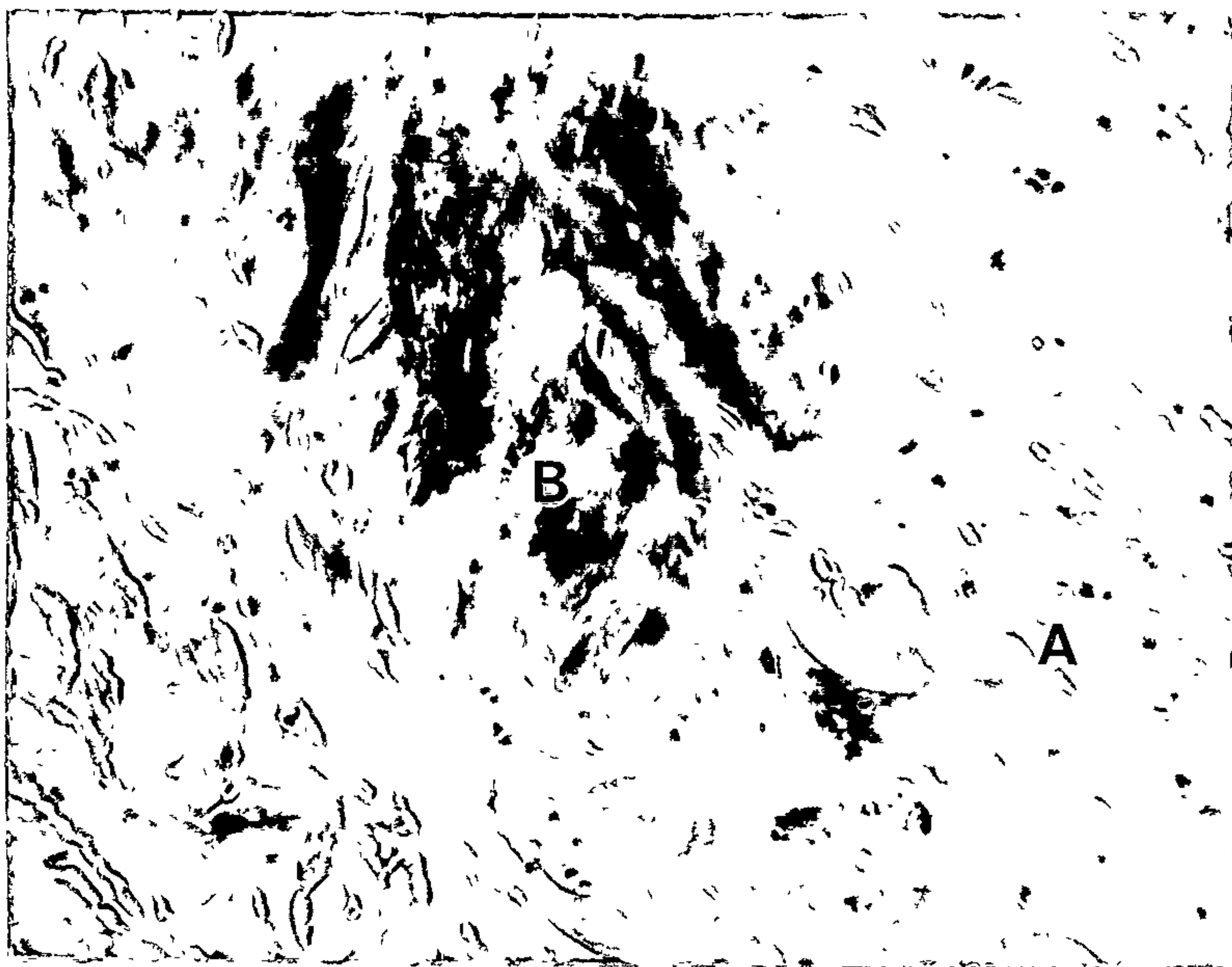


Figure 5-7. Middle of the pars gracilis menisci.
x 150 (H and E).

- A - Chondrocyte
- B - Disorientated collagen fibres



UNIVERSITY OF SYDNEY
MEDICAL LIBRARY

Figure 5-8. Middle of the pars gracilis menisci
x 600 (H and E).

A - Chondrocyte with lacuna

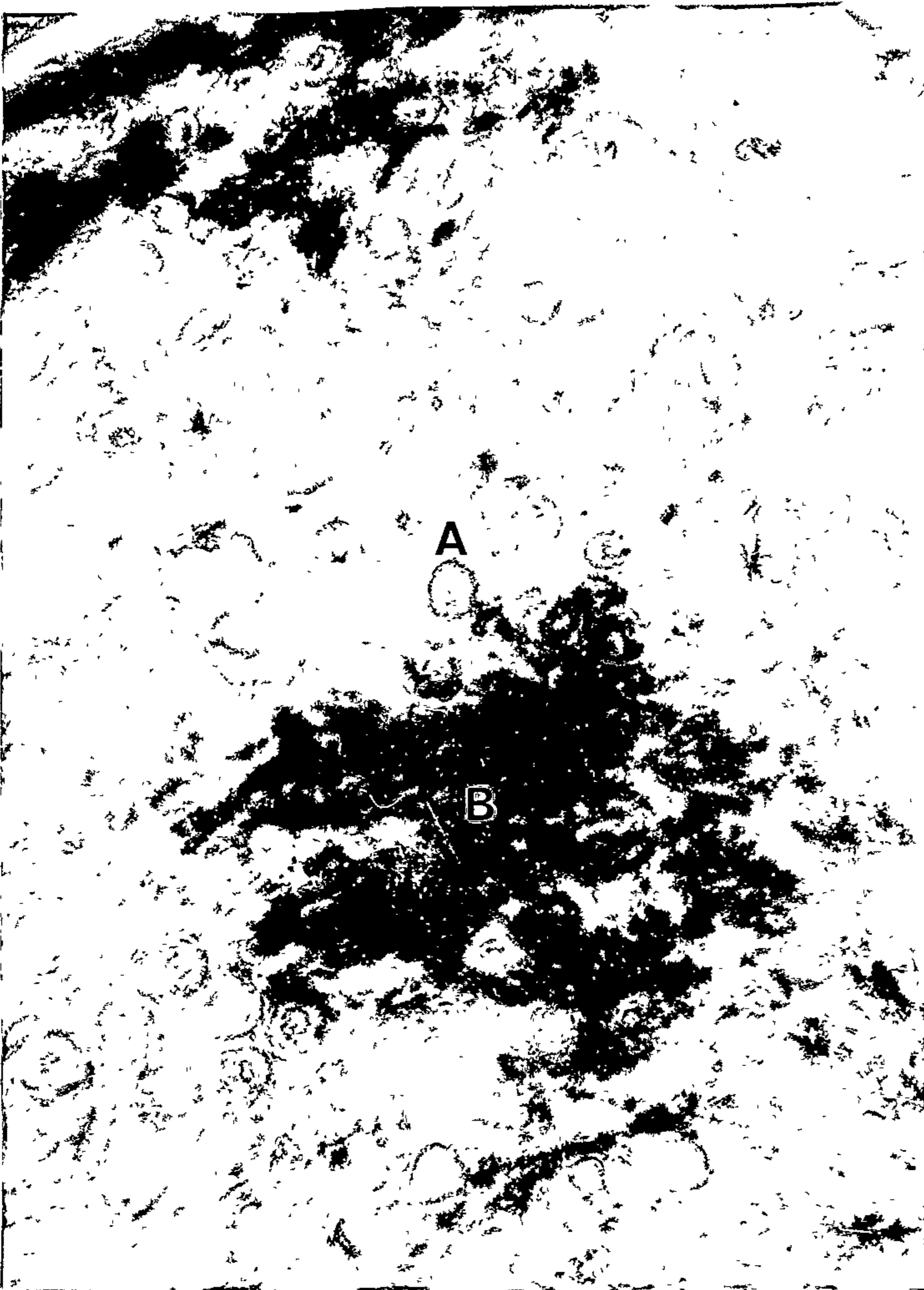


Figure 5-9. Pars gracilis menisci x 200.
(Aldehyde fuchsin).

- A - Chondrocyte
B - Cartilaginous matrix



Figure 5-10. Junction of the pes menisci and the pars gracilis menisci x 300 (H and E).

- | | | |
|---|---|----------------------------|
| A | - | Pes menisci |
| B | - | Pars gracilis menisci |
| C | - | Wavy collagen fibres |
| D | - | Collagen fibres |
| E | - | Inferior joint compartment |
| F | - | Chondrocyte |

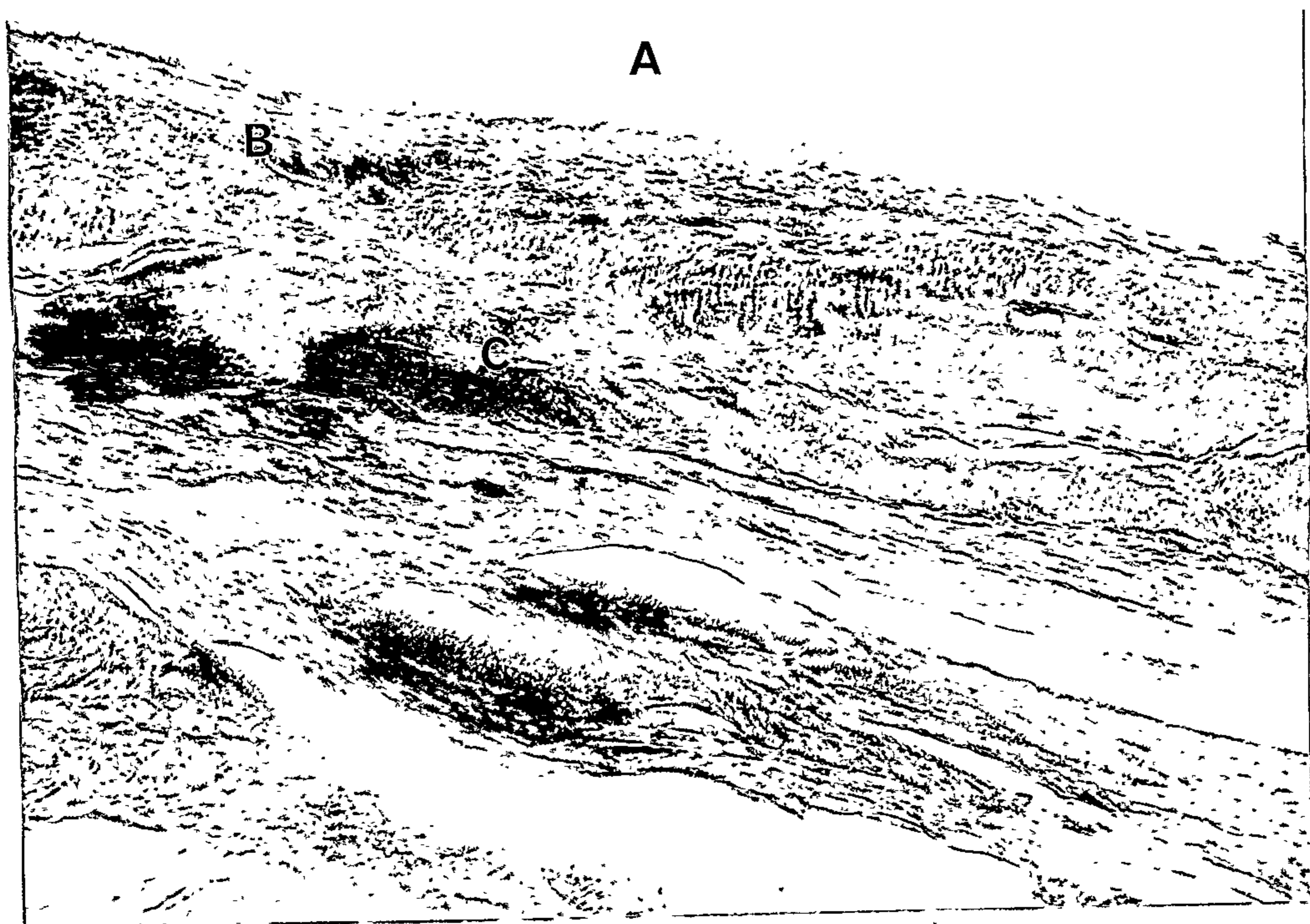


Figure 5-11. Superior surface of the pars gracilis menisci x 300 (H and E).

- A - Superior joint compartment
- B - Synovial membrane
- C - Fibroblast

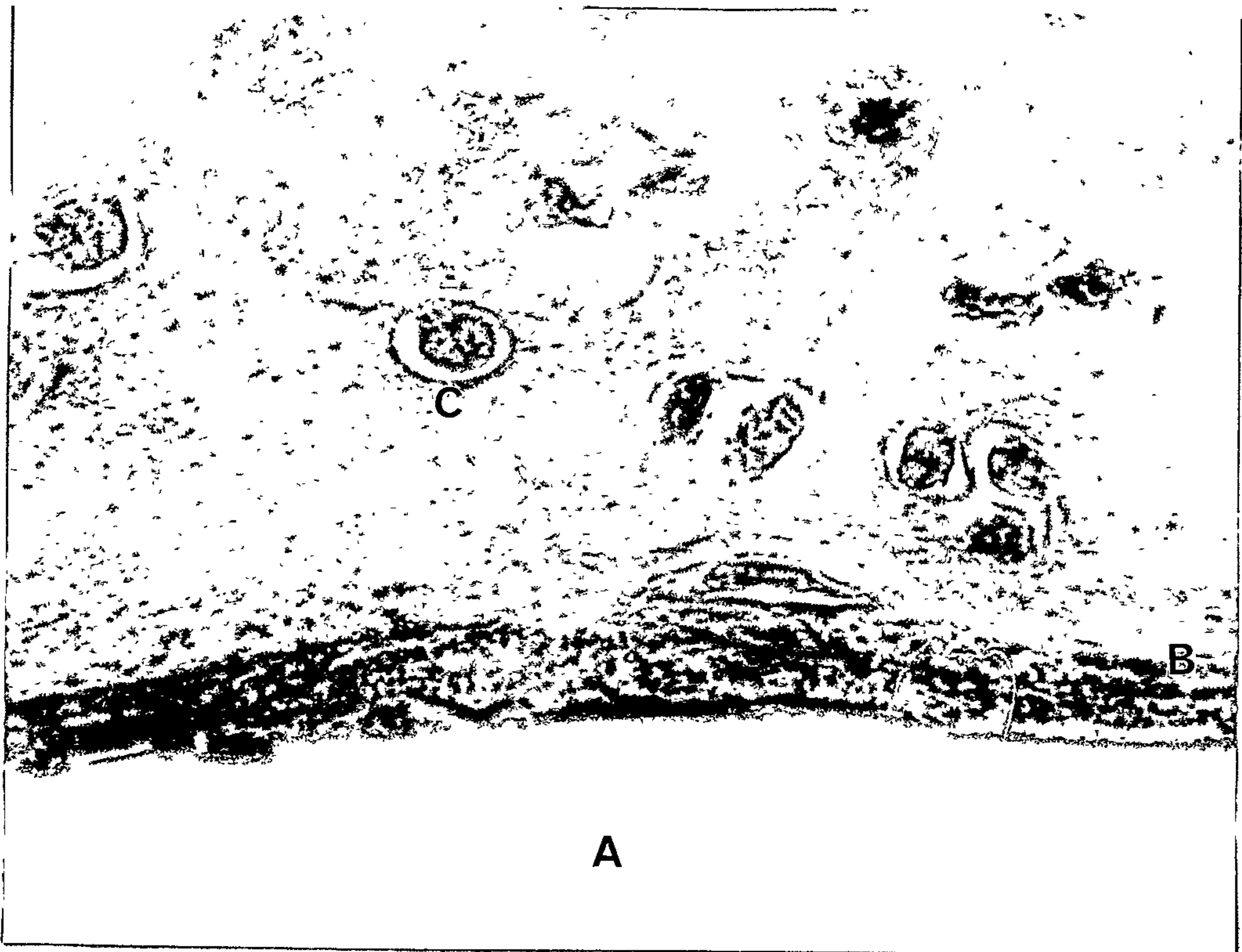


Figure 5-12. Inferior surface of the pars gracilis menisci x 500 (H and E).

- A - Inferior joint compartment
- B - Synovial membrane
- C - Chondrocyte

The pars posterior consisted of collagen fibres and fine elastic fibres, which were orientated in an antero-posterior direction in the more superficial layers (Figs. 5-13 and 5-14). The fibres in the other areas did not appear to have any orientation (Fig. 5-13). As in the gracilis chondroid type cells were present, but neural and vascular elements were absent.

The superior and inferior surfaces of the pars posterior were lined by a fibrous type of synovial membrane that was covered by fibrous tissue (Figs. 5-14 and 5-15).

D. Bilaminar Zone.

The bilaminar zone of the temporomandibular joint complex was the tissue that was bounded by the postero-superior and postero-inferior strata of the meniscus (Figs. 5-1 and 5-16).

The bilaminar zone consisted primarily of loose connective tissue within which many structures were present. Within this tissue lay a venous plexus, together with arteries, capillaries and nerve bundles from the auriculo-temporal nerve (Figs. 5-17 and 5-18).

4. Articular Surface of the Temporal Bone.

The articular surface of the temporal bone formed the roof of the mandibular fossa, and was only separated from the middle cranial fossa by a thin plate of bone.




Figure 5-13. Superior surface of the pars posterior menisci x 150 (H and E).

- A - Superior joint compartment
 B - Fibroblast




Figure 5-14. Superior surface of the pars posterior menisci x 300 (H and E).

- | | | |
|---|---|----------------|
| A | - | Fibrous tissue |
| B | - | Synovioblast |
| C | - | Fibroblast |

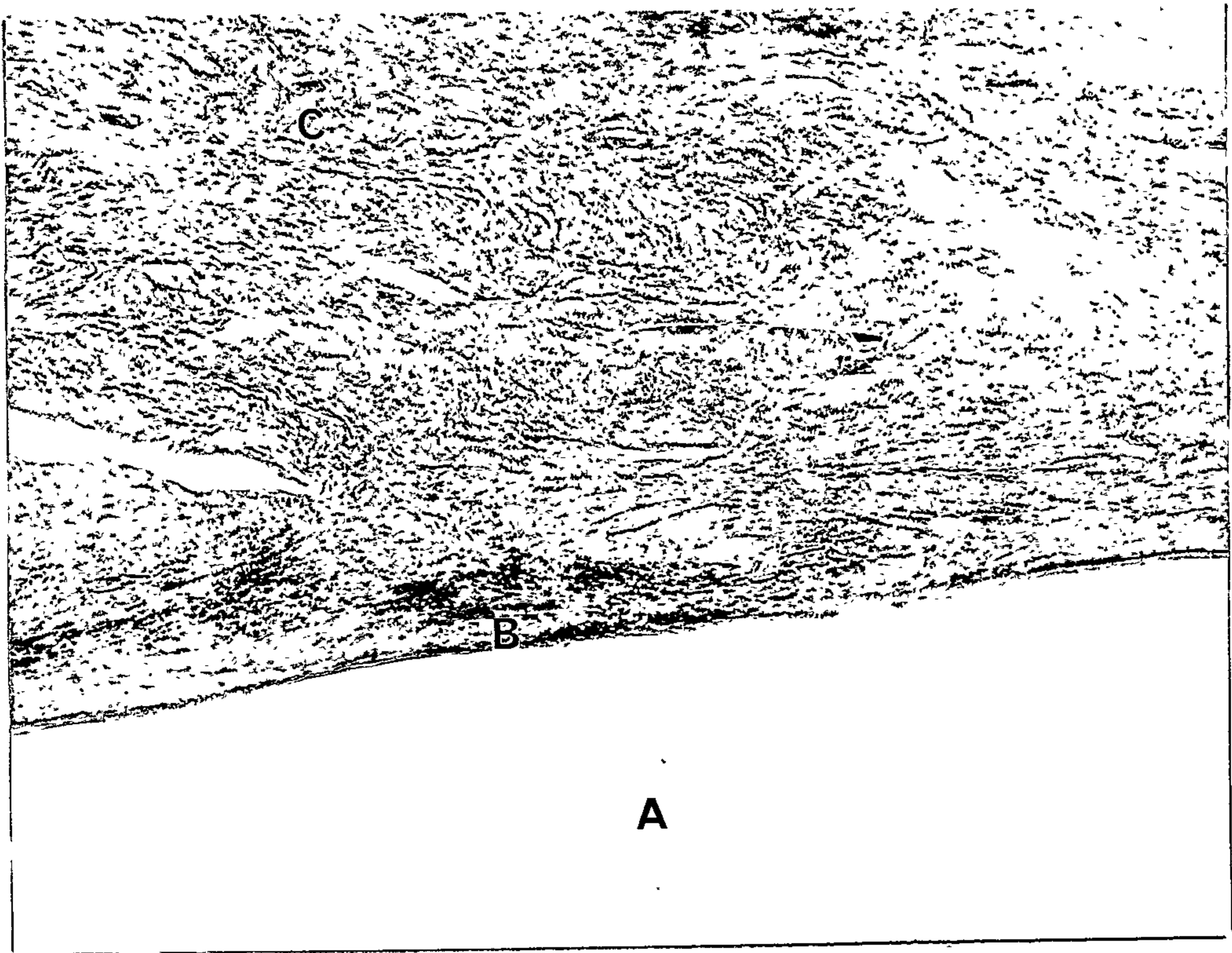


Figure 5-15. Inferior surface of the pars posterior menisci x 300 (H and E).

- | | | |
|---|---|----------------------------|
| A | - | Inferior joint compartment |
| B | - | Synovioblast |
| C | - | Fibroblast |

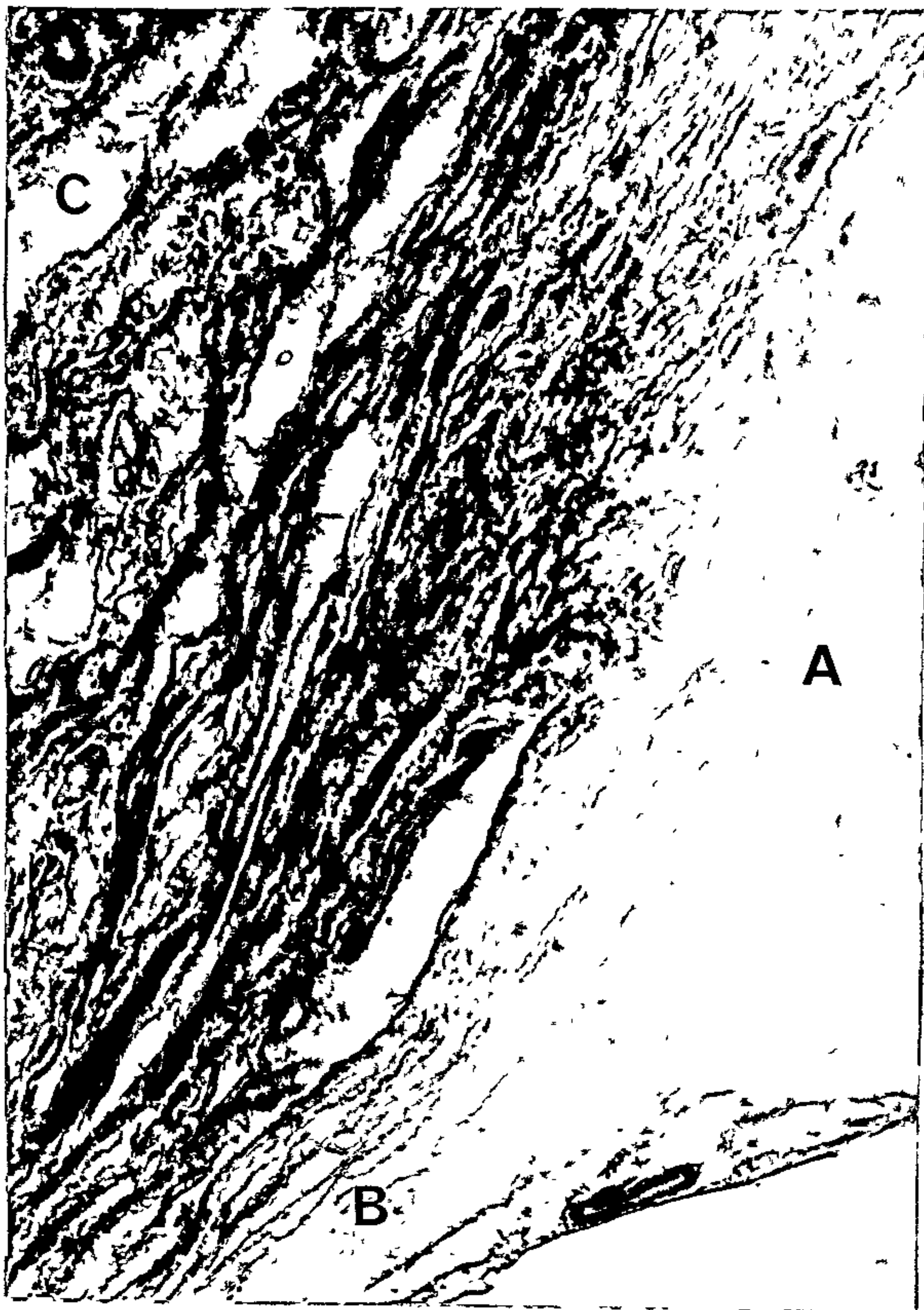

Figure 5-16. Posterior extremity of the pars posterior menisci x 100 (Aldehyde fuchsin).

- | | | |
|---|---|--------------------------|
| A | - | Pars posterior menisci |
| B | - | Postero-inferior stratum |
| C | - | Bilaminar zone |



Figure 5-17. Bilaminar zone x 100 (Aldehyde fuchsin).

- | | | |
|---|---|-------------------------|
| A | - | Venous plexus |
| B | - | Elastic fibre |
| C | - | Loose connective tissue |

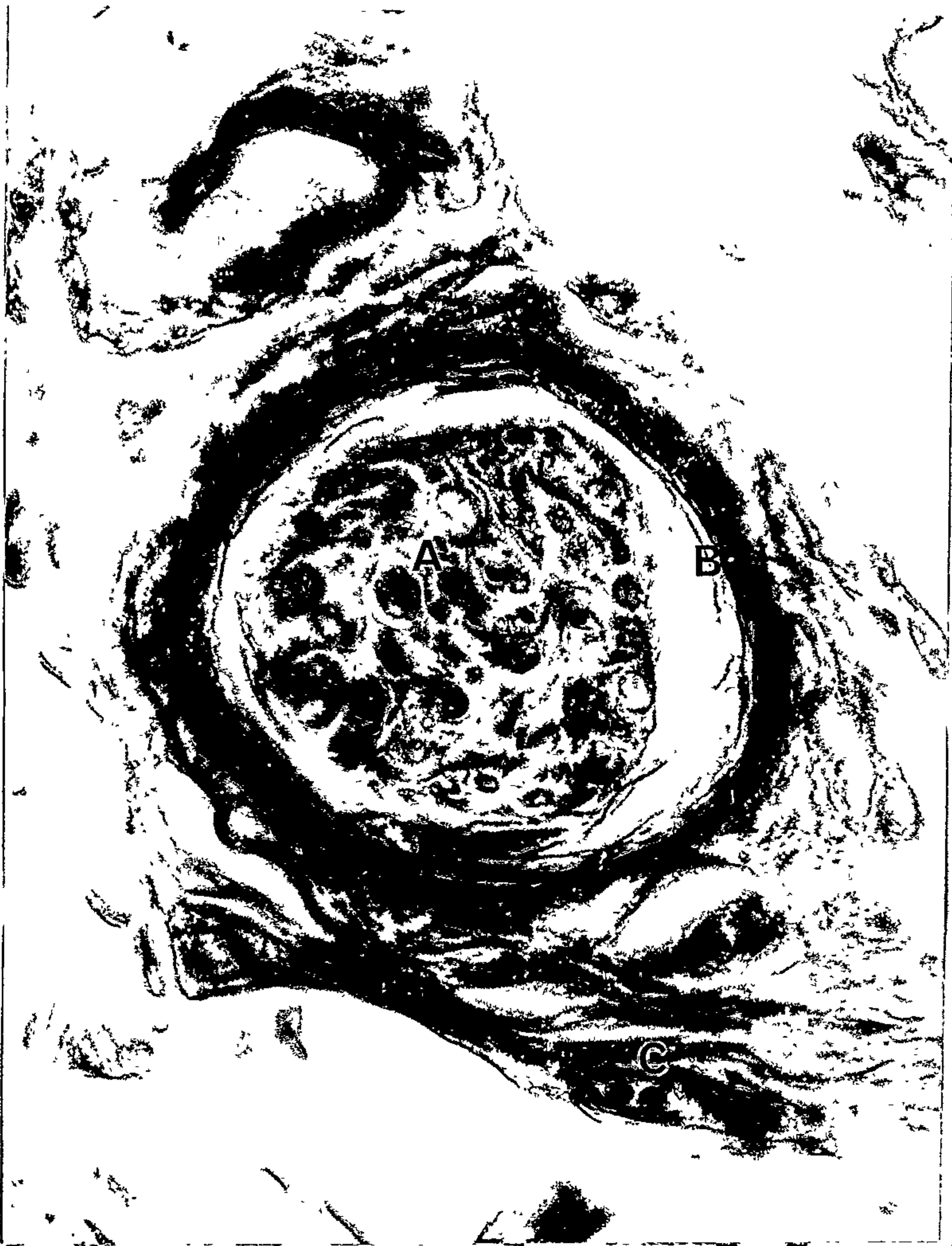


Figure 5-18. Auriculo-temporal nerve in the bilaminar zone x 450 (H and E).

- | | | |
|---|---|--------------------------------|
| A | - | <u>Auriculo-temporal</u> nerve |
| B | - | <u>Perineurium</u> |
| C | - | Blood vessel |

A layer of fibrous periosteum covered the articular surface of the temporal bone, but the thickness of that tissue varied greatly. The fibrous periosteum was of a fairly uniform thickness, lining the posterior and middle parts of the glenoid fossa, but on the articular eminence and the anterior articular slope, the lining was thickened (Fig. 5-1). The fibrous tissue was thickest over the anterior articular slope of the mandibular fossa and the articular eminence.

The connective tissue that lined the roof and posterior wall of the mandibular fossa were quite thin (Fig. 5-19), relative to the thickness in the anterior areas of the mandibular fossa. This tissue consisted of fibrous tissue with a moderate number of fibroblasts. The appearance of the tissue resembled periosteum.

The connective tissue that covered the anterior articular slope of the mandibular fossa was composed of four fairly discreet layers (Figs. 5-20, 5-21 and 5-22). Superficially was a layer that resembled either hyaline cartilage or fibrous tissue, internal to which was a layer of fibrocartilage. This fibrocartilage was superficial to a cellular layer. Deep to the cellular layer was an acellular layer in which was obliquely orientated fibrous tissue. The fibrous tissue was in contact with the subchondral bone of the glenoid fossa.



Figure 5-19. Roof of the mandibular fossa.
x 300 (H and E).

- A - Superior joint compartment
- B - Periosteum
- C - Cortical compacta of the temporal bone.



Figure 5-20. Anterior articular surface of the mandibular fossa. x 150 (H and E).

- A - Assumed hyaline cartilage
- B - Fibrocartilage
- C - Cellular layer
- D - Acellular fibrocartilage with obliquely orientated fibres.



Figure 5-21. Superficial layer of anterior articular slope of the mandibular fossa x 300 (H and E).

- A - Hyaline cartilage
- B - Fibrocartilage
- C - Cellular layer
- D - Oblique fibres of fibrocartilage

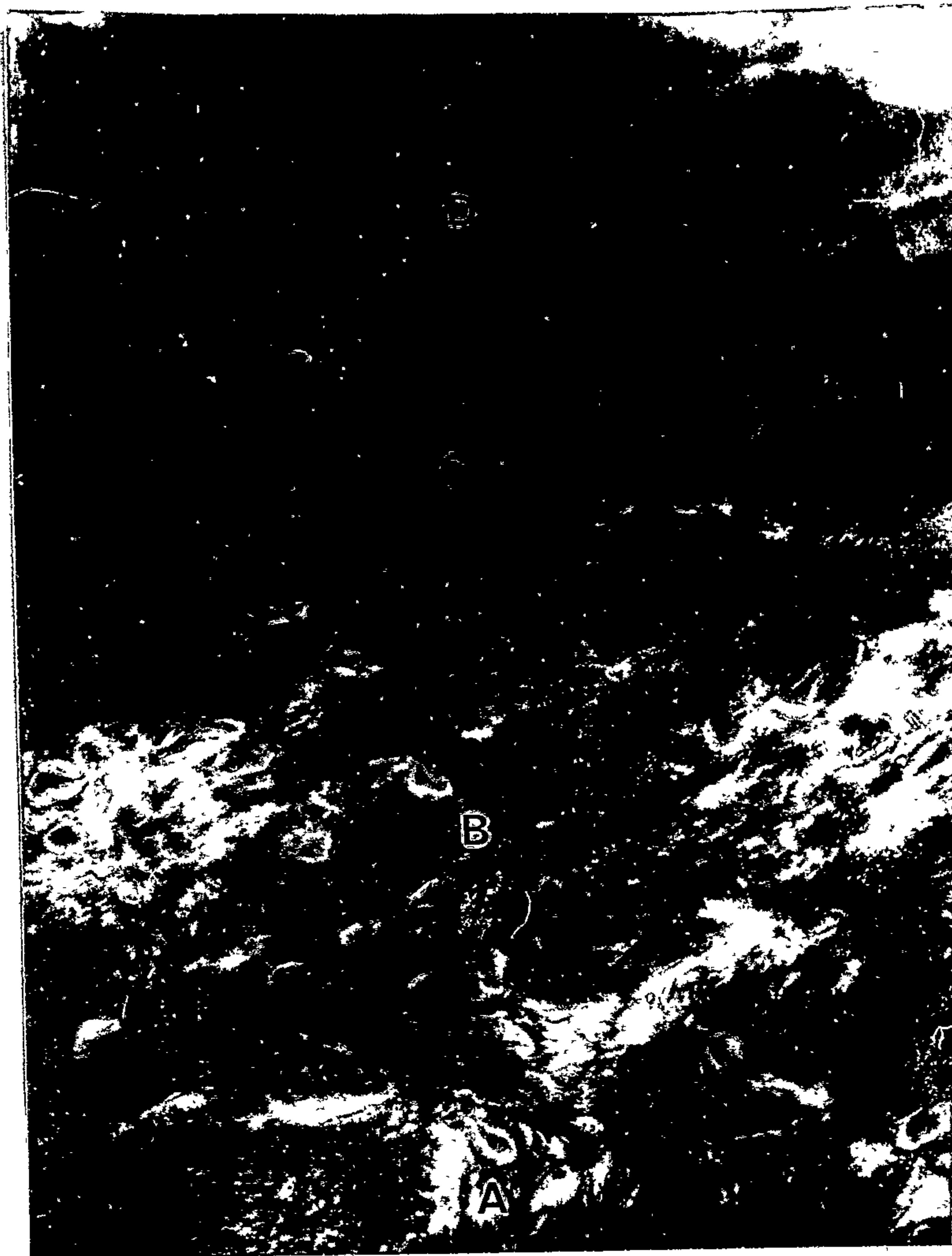

Figure 5-22. Deep layer of the articular tissue of the anterior articular slope of the mandibular fossa. x 300 (H and E).

- A - Fibrocartilage
- B - Cellular layer of chondrocytes
- C - Calcified cartilage
- D - Cortical compacta

The surface layer of hyaline cartilage when present, had many flattened chondrocytes. The fibrocartilage beneath had fewer chondrocytes. The cellular layer consisted of numerous chondrocytes, some of which appeared to be hypertrophic. The acellular layer of fibrous tissue appeared to attach the perichondrium to a thin layer of calcified cartilage.

The connective tissue of the articular eminence was approximately twice the thickness of that of the anterior articular slope of the mandibular fossa (Figs. 5-20 and 5-23). The structure and composition of the articular eminence tissue varied from that of the mandibular fossa.

The surface of the articular eminence was lined by a layer of fibrous cartilage, within which were flattened chondrocytes (Figs. 5-23 and 5-24). Superior was a very thick layer of fibrocartilage that was populated by a small number of chondrocytes (Figs. 5-23 and 5-25). This layer was comparable to the fibrocartilage layer that was seen in the mandibular fossa, but on the articular eminence it was greatly increased in thickness. A zone of obliquely orientated fibres attached the fibrocartilage to the subchondral bone (Figs. 5-23 and 5-25).

5. Articular Surface of the Condyle.

The articular surface of the condyle was more complex than that of the temporal bone.

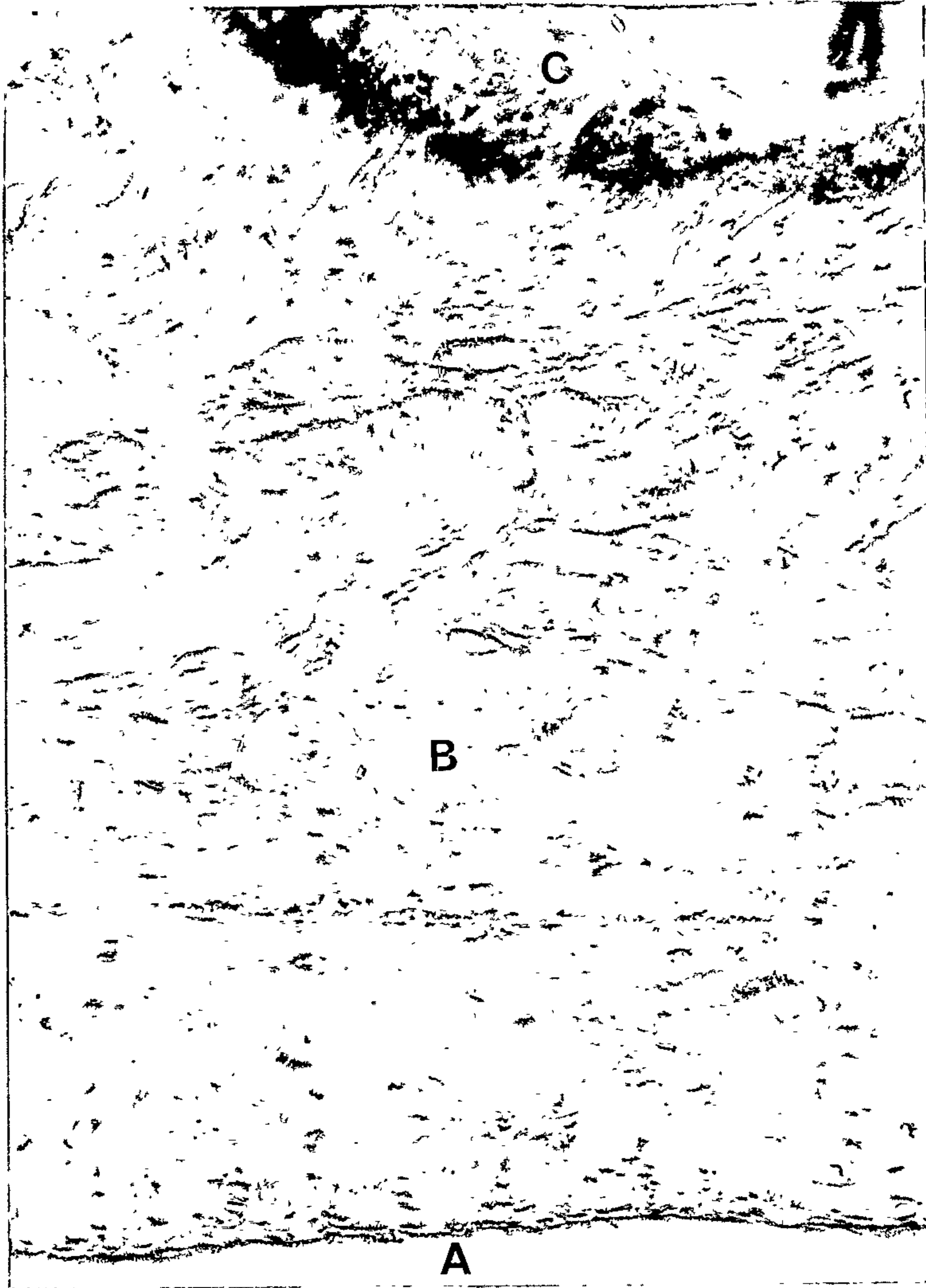


Figure 5-23. Articular eminence x 150 (H and E).

- A - Superior joint compartment
- B - Fibrocartilage
- C - Cortical compacta of the temporal bone.



Figure 5-24. Outer layer of the articular tissue of the articular eminence x 300 (H and E).

- | | | |
|---|---|----------------------------|
| A | - | Superior joint compartment |
| B | - | Fibrocartilage |
| C | - | Chondrocyte |



Figure 5-25. Deep layer of the articular tissue of the anterior articular slope of the articular eminence x 300 (H and E).

- A - Fibrocartilage, horizontal fibres
 B - Fibrocartilage, oblique fibres

Remodelling occurred over most of the condylar articular surface, thus the articular surface of the condyle will be discussed in Chapter 6.

6. Synovial Membrane.

Synovial membrane lined all surfaces of the superior and inferior joint compartments, with the exception of the articular surface of the condyle and temporal bone.

There are several types of synovial membrane; their classification being determined by the type of supporting tissue (KEYS, 1932).

A. Antero-superior Reflection.

The antero-superior joint reflection was formed by the antero-superior stratum of the meniscus (Fig. 5-1). This stratum was lined by a layer of synovial cells, several cells in thickness (Fig. 5-26). The nuclei of these synovioblast cells were dense and ovoid in shape, and were in intimate contact with the surface of the synovial cavity. In the tissue below the synovial membrane were numerous small arteriolar type blood vessels (Fig. 5-26). This synovial membrane resembled the areolar type of KEYS (1932).




Figure 5-26. Synovial membrane of the antero-superior joint compartment. x 300 (H and E).

- A - Superior joint compartment
- B - Synovial membrane
- C - Blood vessel

B. Antero-inferior Reflection.

The antero-inferior stratum of the meniscus formed the anterior extremity of the inferior joint compartment, where it attached the meniscus to the neck of the condyle, just inferiorly to the articular surface of the condyle (Fig. 5-1).

The surface of the stratum was lined by a thin membrane of the fibrous type (Fig. 5-27) or of the areolar type (Figs. 5-28 and 5-29), from which arose numerous villi (Figs. 5-27, and 5-29). This membrane was supported by loosely packed fibrous tissue that was well supplied by vascular and neural elements (Figs. 5-27, 5-28 and 5-29). The vascular elements appeared to constitute an arterio-venous anastomotic system (Fig. 5-29).

C. Postero-superior Reflection.

The postero-superior stratum was lined by an elaborate synovial membrane that was supported by a rich vascular complex (Fig. 5-30). The surface of the stratum was formed by numerous convolutions, just prior to the attachment of the stratum to the temporal bone. These convolutions had a central core of fibrous tissue that was covered by a thick lining of cuboidal type synovioblast cells. These cells formed a synovial membrane of approximately two or three cells

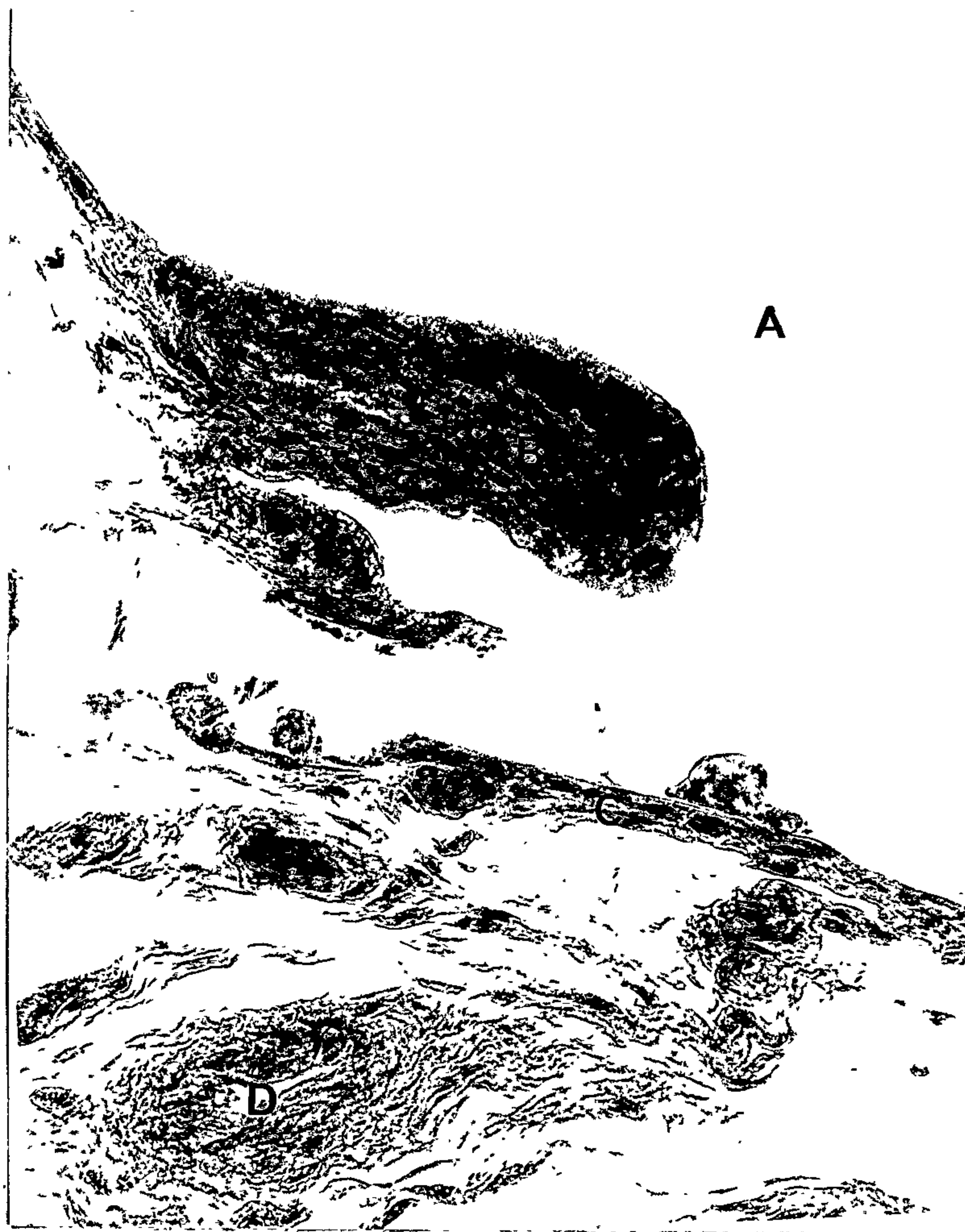


Figure 5-27. Synovial villus in the antero-inferior joint reflection x 300 (H and E).

- A - Inferior joint compartment
- B - Synovial villus
- C - Synovial membrane
- D - Blood vessel

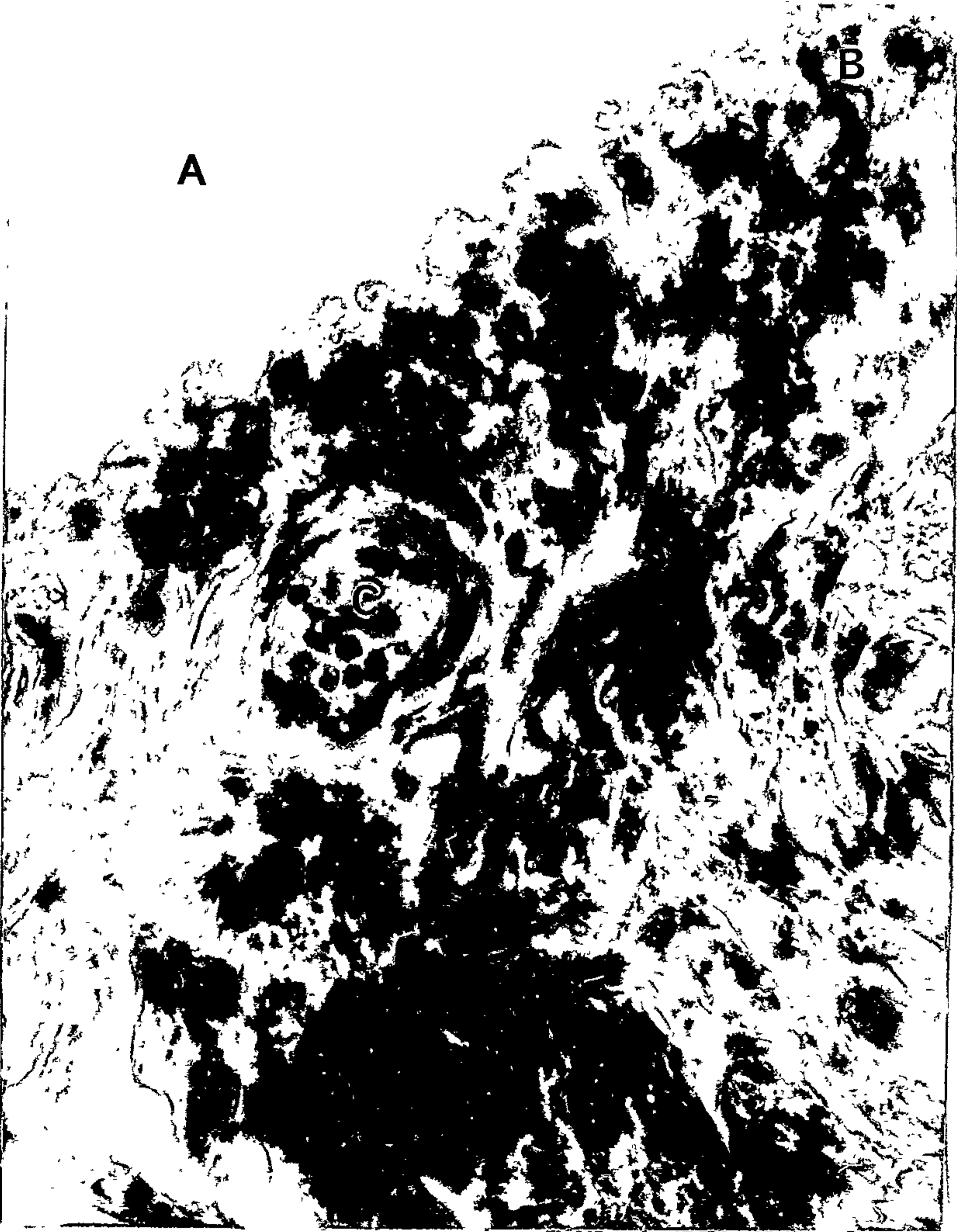

Figure 5-28. Synovial membrane of the antero-inferior joint compartment x 400 (H and E).

- A - Inferior joint compartment
- B - Synovial membrane
- C - Blood vessel

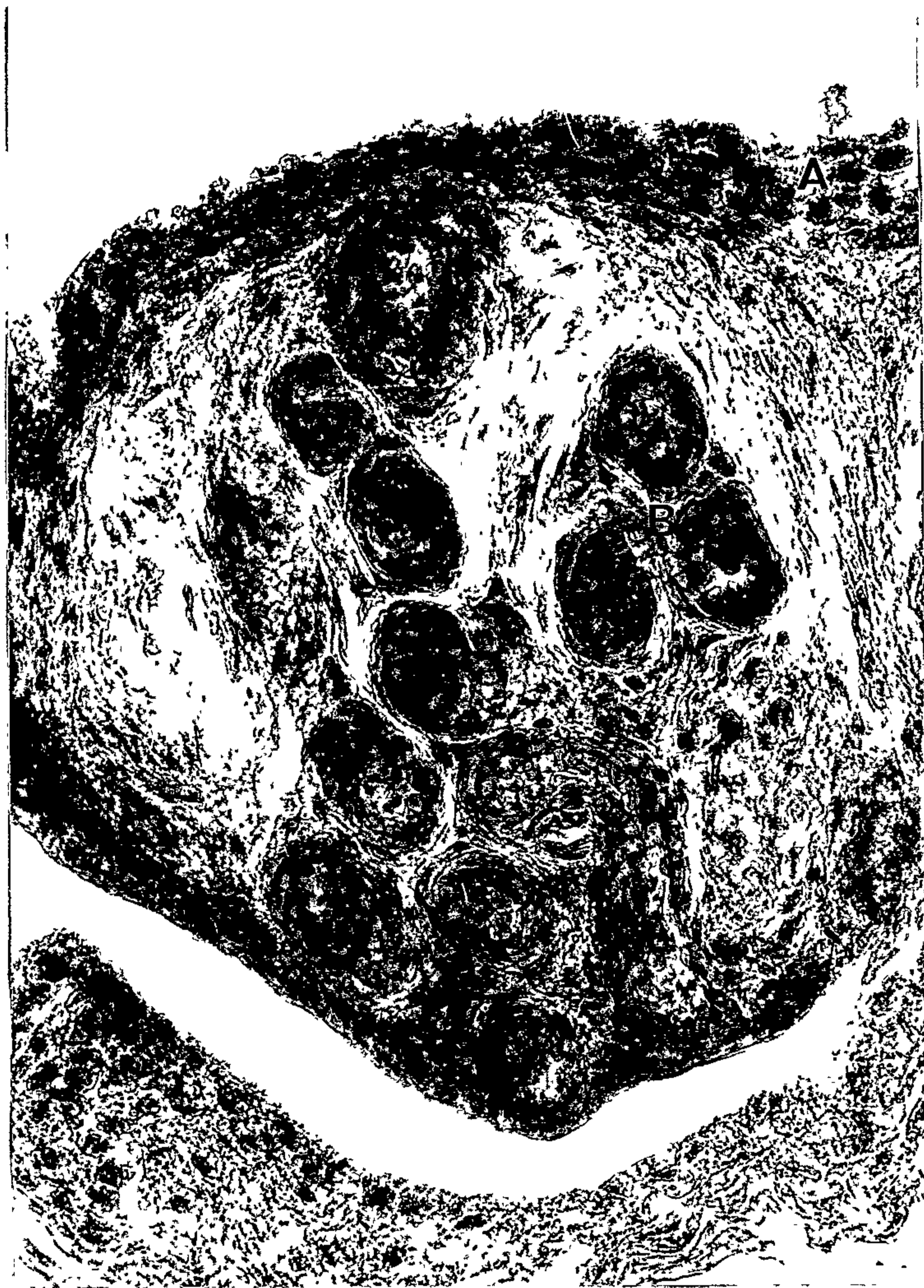

Figure 5-29. Villus at the antero-inferior reflection
x 300 (H and E).

- A - Synovial membrane
- B - Arterio-venous anastomotic system

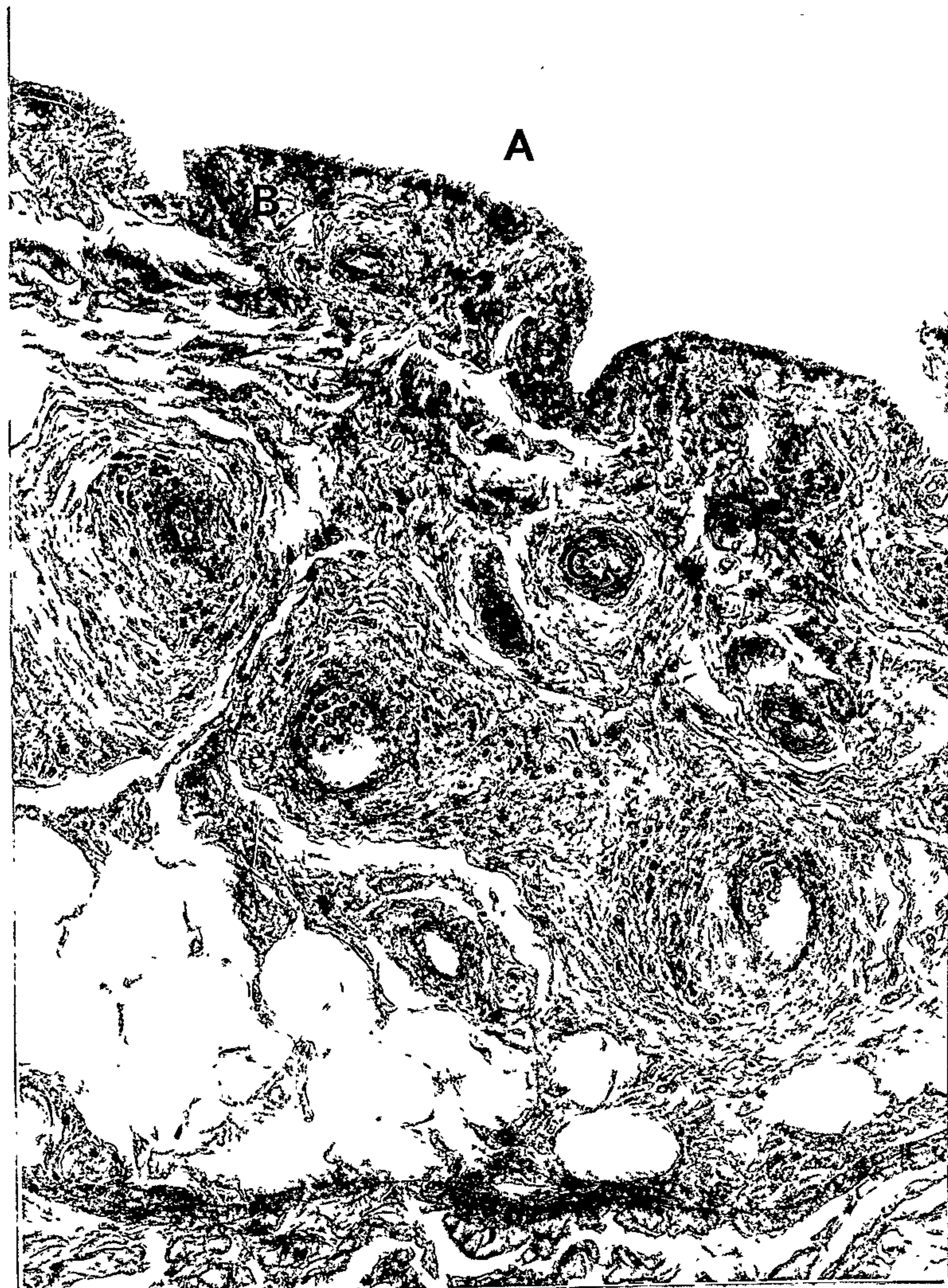


Figure 5-30. Synovial membrane of the postero-superior reflection x 150 (H and E).

- A " Superior joint compartment
- B " Synovial membrane
- C " Blood vessel

thickness which was in intimate contact with the superior joint compartment space. This synovial membrane was of the areolar type (Fig. 5-30).

D. Postero-inferior Reflection.

The reflection of the postero-inferior stratum onto the neck of the condyle formed the posterior extremity of the inferior joint compartment.

The few synovioblast cells that lined the postero-inferior stratum were in intimate contact with the inferior joint compartment space (Fig. 5-31). The membrane was supported by fibrous tissue throughout which were numerous blood vessels and nerve bundles. These blood vessels in the stratum appeared to be of the arteriolar type (Fig. 5-32). The synovial membrane of the postero-inferior stratum was of the areolar type.

E. Pes Menisci.

The superior surface of the pes was the continuation of the surface of the antero-superior stratum, and the synovial membrane of the pes was similar to that which lined the stratum. However, blood vessels were not present in the submembrane tissue (Fig. 5-4).

The inferior surface of the pes was lined by a fibrous type of synovial membrane (Fig. 5-5).

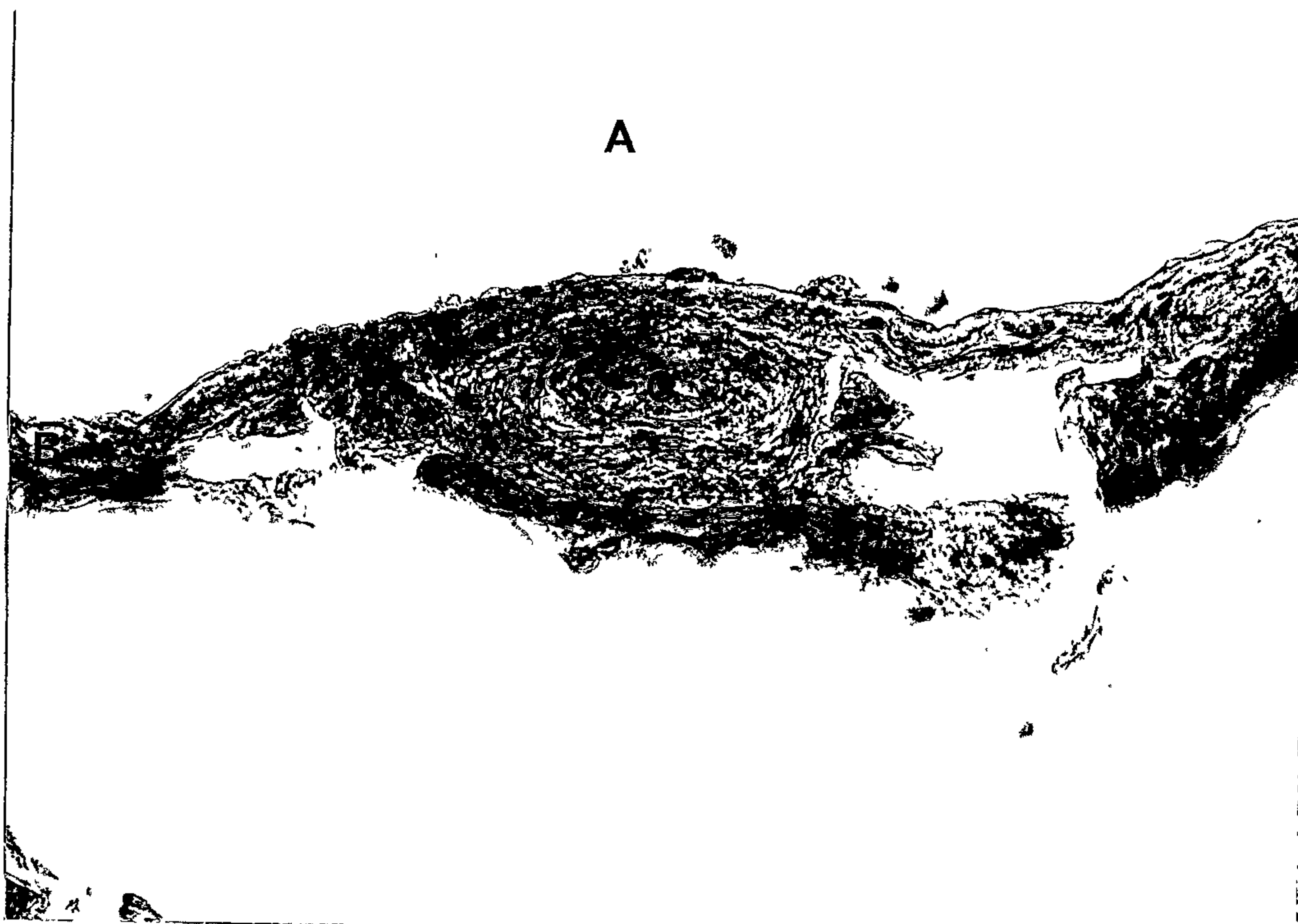


Figure 5-31. Synovial membrane of the postero-inferior reflection x 400 (H and E).

- A - Inferior joint compartment
- B - Synovial membrane
- C - Blood vessel

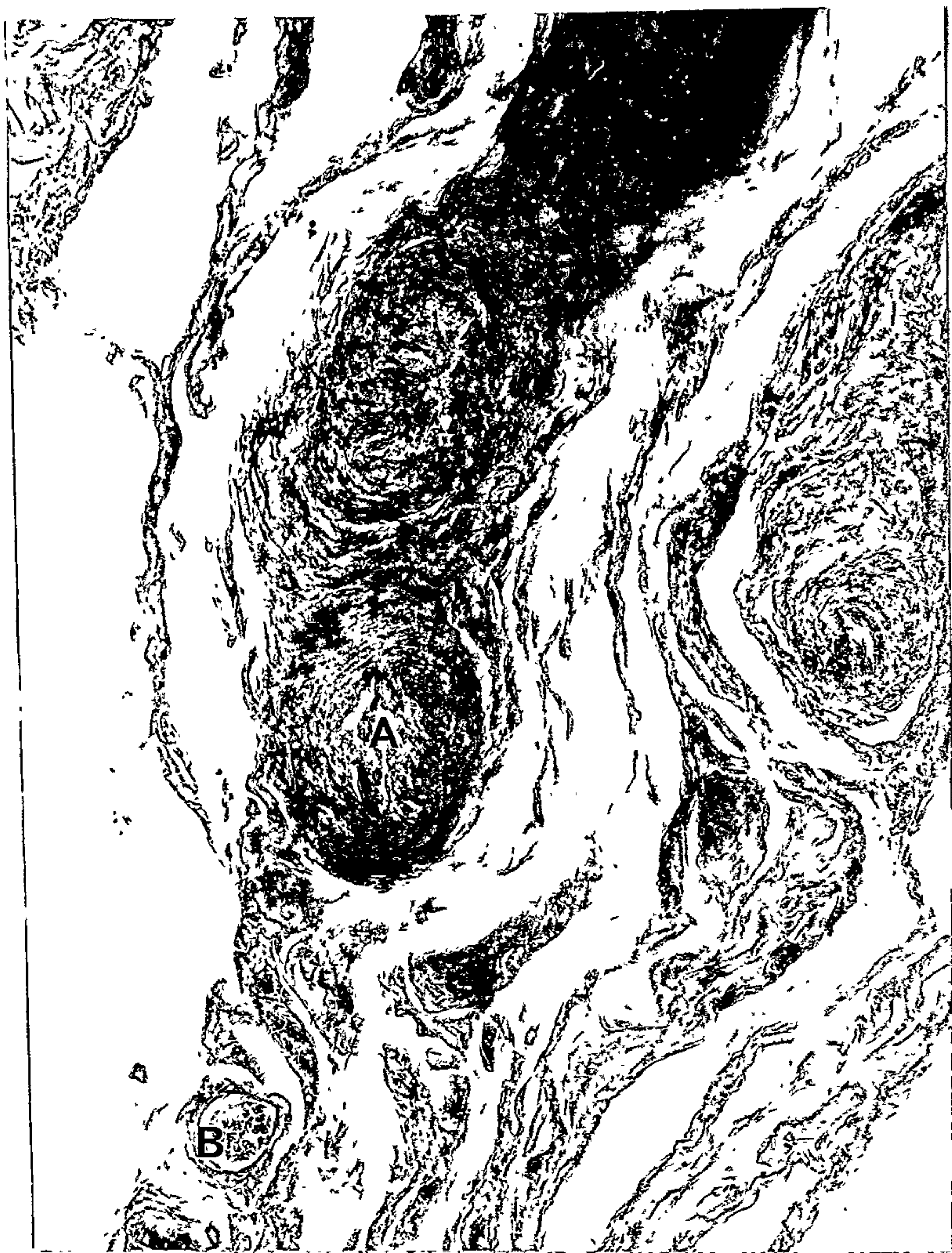

Figure 5-32. Neuro-vascular complex in the postero-inferior stratum x 150 (H and E).

- A - Blood vessel
 B - Nerve fibre

F. Pars gracilis Menisci.

At the junction of the pes with the gracilis a difference in the synovial membrane was evident. Whereas the synovioblasts of the pes were found on the surface of the meniscus, in the gracilis the synovioblasts were sparse and were covered by a thin layer of fibrous tissue, such that the synovioblasts were submerged (Fig. 5-11). The synovioblasts were flattened and resembled fibroblasts. Thus the synovial membrane could be classified as the fibrous type.

The inferior surface of the gracilis was lined by a fibrous type of synovial membrane (Fig. 5-12).

G. Pars Posterior Menisci.

A fibrous type of synovial membrane covered the superior surface of the pars posterior (Fig. 5-14).

The inferior surface was also lined by a fibrous type synovial membrane (Fig. 5-15).

Discussion.

In the aged human temporomandibular joint it is apparent that there are significant changes in the tissues of this joint. These changes are very evident in the meniscus and synovial membrane of the joint.

The meniscus exhibited degenerative change with regard to the number of cells and type of cells that were present between the fibrous tissue that provided the bulk of the meniscus.

Chondrocytes and cartilage formation were present in the meniscus, in particular in the pars gracilis menisci. These cells indicated a metaplastic change in the fibroblasts resulting from wear and pressure on the meniscus, in function.

Wear within the meniscus was also demonstrated by a decrease in the vascularity in the pes menisci, but more dramatically in the alteration of the synovial membrane that lined the joint compartments.

The synovial membrane was thinned in all regions and in the region of the pars gracilis and pars posterior the synovioblasts were separated from the joint compartment space by a reasonably thick layer of fibrous tissue.

The observations made in this study were similar to those made by GRIFFIN and SHARPE (1960), ORBAN (1972) and GRIFFIN et al (1975).