


SOME OBSERVATIONS ON THE HISTOLOGY  
OF THE TEMPOROMANDIBULAR JOINT.

A thesis submitted for the  
degree of Master of Dental  
Surgery.

SYDNEY UNIVERSITY

1 9 7 5



WILLIAM G. MARSHALL.

## TABLE OF CONTENTS.

	<u>Page.</u>
Introduction	1.
Acknowledgements	2.
Chapter 1 - Materials and Methods	3.
Chapter 2 - The Histology of the Temporomandibular Joint Complex in the Sixteen week (132 mm C.R) Foetus.	24.
Chapter 3 - The Embryology of the Human Temporomandibular Joint.	78.
Chapter 4 - The Histology of the Temporomandibular Joint Complex in a 4 month Old Bonnet Monkey ( <i>Macaca radiata</i> ).	89.
Chapter 5 - The Histology of the Aged Human Temporomandibular Joint Complex.	127.
Chapter 6 - Remodelling in the Articular Surfaces of the Temporomandibular Joints in Man.	174.
Chapter 7 - Conclusions	241.
Appendices	246.
References	253.

## Introduction.

The following study was undertaken to examine the histology of the temporomandibular joint of a foetus, 16 weeks of age, a Bonnet Monkey, (*Macaca radiata*), 4 months of age, and several aged human joints. The emphasis of this work was towards the age changes that affect the temporomandibular joint. The age changes that were of special interest related to the changes in the synovial membrane of the joint compartments and the changes that occurred in the articular surfaces of the condyle and temporal elements of the temporomandibular joint. The present study was concerned with the normal age changes in the temporomandibular joint, rather than pathological changes.

The classification of the various parts of the temporomandibular meniscus was according to GRIFFIN and SHARPE (1960) and GRIFFIN et al (1975), although the alternative terminology of REES (1954) was recognised. The synovial membrane was described in accordance with KEYS (1932).

The terminology of the remodelling of the articular surfaces was based on the initial work of JOHNSON (1959, 1962), as applied to the temporomandibular joint by BLACKWOOD (1959, 1966 a and 1969) and MOFFETT et al (1964).

Acknowledgements.

It is a pleasure to acknowledge the assistance of the Department of Anatomy, Adelaide University, who made available the material presented in this study.

The Department of Oral Pathology and Oral Surgery, Adelaide University, made available the facilities whereby the material was embedded, sectioned and stained.

Similarly, I am grateful to the Department of Histology and Embryology, Sydney University, who supplied the photographic material and facilities for this study, and also assisted in several staining techniques.

I am also indebted to Associate Professor C.J. Griffin for his assistance and encouragement in this work.

I would also like to acknowledge the assistance provided by my wife in proof reading and typing this thesis.

Chapter 1                      Material and Methods

<u>Contents</u>	<u>Page.</u>
I            Introduction	4.
II           Human Foetus	4.
III          Bonnet Monkey ( <i>Macaca radiata</i> )	5.
IV          Human cadavers	5.
V           Preparation of Specimens for Histological Examination.	7.
VI          Celloidin Embedding	14.
VII         Staining	18.
1.    Introduction	18.
2.    Haematoxylin and Eosin (Lillie/Mayer)	19.
3.    van Gieson	22.
4.    Gomori's Aldehyde fuchsin	23.

## Chapter 1. Material and Methods.

### I. Introduction.

The original work presented in this thesis was undertaken to study several different aspects of aging in the temporomandibular joint. One foetus, sixteen weeks old, was examined as the elements of the temporomandibular joint are considered to have been established by that age (SYMONS, 1952; BAUME, 1962; FURSTMAN, 1963 YUODELIS, 1966). One Bonnet monkey, four months old, was examined to illustrate the histological features in a young simian temporomandibular joint. Finally three aged human cadaver preparations were examined histologically.

### II. Human foetus.

One sixteen week (132mm C.R.) (PATTEN, 1948) foetus, that had been fixed in formalin, was obtained from the Department of Anatomy, Adelaide University. The crown-rump (C.R.) measurement was obtained after the foetus had been fixed for several days.

The temporomandibular joint was removed, en bloc, with a dental drill. A block was removed from each side of the foetus, after which the blocks were prepared for histological examination.

The blocks were sectioned on a Spencer A.O. Rotary microtome with a wedge knife. One block was sectioned in the sagittal plane and the other in the coronal plane. The sections were 7um thick and were stained with haematoxylin and eosin, according to appendix 1, and mounted on glass slides.

### III. Bonnet monkey (Macaca radiata).

One Bonnet monkey, four months old, was obtained from the Department of Anatomy, Adelaide University. The head was fixed in formalin for ten days before being handled.

A block of temporal bone, which included the temporomandibular joint, was removed from both sides using a dental drill. The two blocks were then prepared for histological examination.

The blocks were sectioned in the sagittal plane using a Spencer A.O. Rotary microtome with a wedge knife, the sections being 7um thick.

The sections from one block were mounted on glass slides and stained with haematoxylin and eosin, or aldehyde fuchsin, according to appendices 1 and 3. The other block was treated by de Casto's silver stain and counter stained with haematoxylin and eosin or van Gieson.

#### IV. Human cadavers.

Three aged cadavers, two male and one female, were made available by the Department of Anatomy, Adelaide University.

The temporomandibular joint was removed from one side of each of the cadavers with a dental drill and surgical chisel. The blocks were then prepared for histological examination.

The blocks were double embedded in paraffin wax before being mounted on a wooden block ( $1\frac{1}{2}$  by 1 inch). This block was set on a M.S.E. Base Sledge microtome, with an angled wedge knife. All the blocks were sectioned in the sagittal plane, the sections being 10 to 15  $\mu$ m in thickness, depending upon the difficulties experienced in cutting the sections. The sections were stained with haematoxylin and eosin, van Gieson or aldehyde fuchsin, in accordance with appendices 1,2 and 3.

V. Preparation of specimens for histological examination.

The human blocks were placed in 5% aqueous nitric acid, whereas the foetus and monkey blocks were placed in standard formic formate decalcifying solution, until decalcified (Table 1).

TABLE 1.                      Period for decalcification.

Material	Nitric acid	Formic acid	Days
Human	+		13
Human	+		13
Human	+		12
Monkey		+	9
Foetus		+	5

The decalcification was surveyed radiographically to determine the point of complete decalcification (Figs. 1,2 and 3). Care was taken to change the decalcifying agent daily so, as to allow the decalcification to be completed in the shortest time possible. The specimens were placed in approximately eight times their volume of decalcifying agent to ensure that plenty of acid, of sufficient strength was continually available.




Figure 1. X-ray of human block after  
3 days in 5% aqueous nitric acid.




Figure 2. X-ray of human block after  
10 days in 5% aqueous nitric acid.

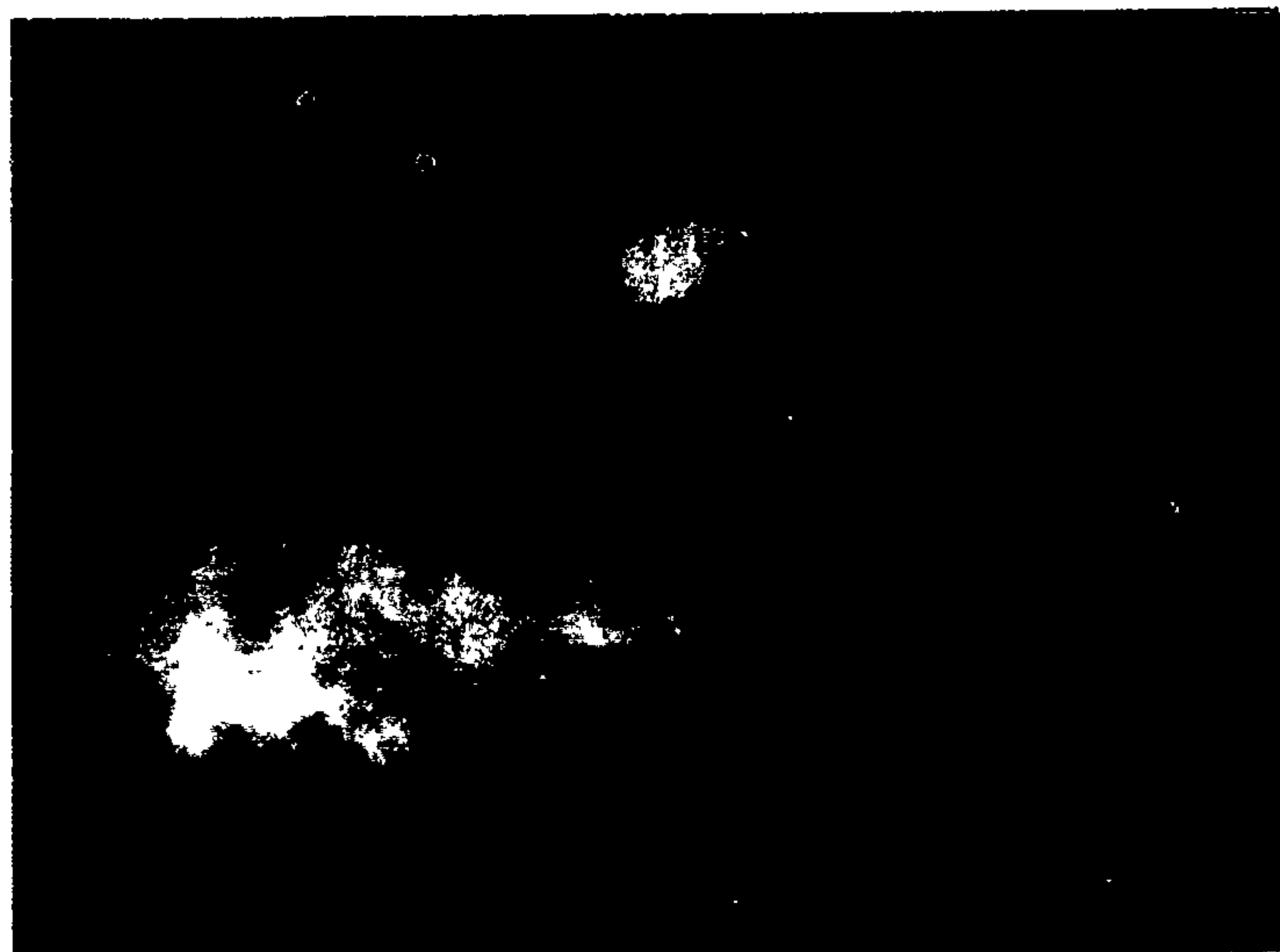


Figure 3. X-Ray of complete decalcification of human block after 12 days in nitric acid.

Nitric acid was used as the decalcifying agent, in spite of the disadvantages associated with its use, for the human specimens because of the large size of these specimens. In large specimens, nitric acid causes swelling of the tissues, especially at the peripheries, and tends to destroy the basophilia of the nuclear material (CLAYDEN, 1962). In contrast formic formate decalcifying solution does not affect the basophilia and causes little swelling, even after prolonged periods of immersion (CLAYDEN, 1962). However, formic formate decalcifying agent is a slow decalcifying agent and would have led to prolonged immersion of the human specimens because of their large size.

After decalcification of the blocks it was essential to neutralise the acid, that remained in the tissue, to prevent over decalcification, and also to make the tissue amenable to staining with haematoxylin. Haematoxylin is unstable in an acid medium, such that if the tissues are not neutralised, the residual acid will negate haematoxylin staining (LILLIE, 1965). The blocks that were decalcified with nitric acid were neutralised in 70% alcohol, that was changed daily for three days. The alcohol causes slight shrinkage of the tissues and thus it may compensate for swelling caused by nitric acid.

The blocks that were decalcified in formic formate solution were neutralised in 5% sodium sulphate for one day.

It is essential to remove all water from the tissues prior to paraffin embedding. The dehydration was carried out by treating the blocks in 95% alcohol, absolute alcohol I, absolute alcohol II, and absolute alcohol III, each for one hour. The change of solutions ensured that all the water was removed from the tissues.

Alcohol does not mix with paraffin wax, so it is necessary to use an intermediate agent that will clear the alcohol from the tissues, replacing the alcohol with a liquid that is miscible with alcohol and wax. LILLIE (1954) noted that methyl salicylate was a suitable clearing agent, and this was the agent used in the present work. The specimens were placed in a 50% absolute alcohol, 50% methyl salicylate for another hour. The specimens were then placed in methyl salicylate, to which 1% celloidin had been added, until the blocks became transparent. The foetal material required 2 days for clearing, whereas the monkey required 4 days, and the cadaver blocks up to 10 days. The clearing was performed at 37 degrees centigrade, in an incubator.

The embedding required the methyl salicylate to be replaced with paraffin wax, which in this study was Paraplast +. This is a commercial paraffin wax that incorporates a plasticiser, which makes it exceptionally good for hard tissue preparations. The replacement of the methyl salicylate was done by placing the blocks in a solution of two parts methyl salicylate to one part paraffin wax for one hour, at 60 degrees centigrade, then a one in one solution of methyl salicylate and paraffin wax, for one hour. This was followed by one hour in a one part methyl salicylate, to two parts paraffin wax. There were then three changes into pure Paraplast + paraffin wax, each being for one hour, the last being under a vacuum of 25 inches of mercury.

Complete infiltration of wax was attempted in the minimum possible time, which varied with the size of the specimen, so that excessive contraction, that occurs during this phase of the preparation, could be reduced as far as possible. BRAIN (1949) noted that there was measurable shrinkage of tissues after clearing and embedding. Although shrinkage has been attributed to prolonged treatment in absolute alcohol, and the action of the clearing agents (ROMEIS, 1928; TARKAN, 1931), the time and temperature required to infiltrate the tissues with molten wax also leads to a degree of shrinkage (BRAIN, 1966).

When it was considered that the blocks were adequately infiltrated, they were removed to a vacuum embedder, where they were placed in wax under vacuum for 1 to 3 hours. The blocks were then embedded in paraffin wax, cooled under refrigeration and stored at room temperature. The blocks were cooled quickly to reduce the crystal size of the wax, in order to improve the consistency of the blocks (BRAIN, 1966).

The foetal and monkey material was blocked using standard embedding moulds, but the cadaver blocks were too large for this method. Two pieces of angle iron were formed on a ceramic tile to make a mould large enough to accept the blocks, with approximately 15 mm between the sides of the mould and the tissue.

In all the cadaver blocks it was found that the methyl salicylate had not been completely replaced by the infiltrated wax. In each case it was necessary to re-infiltrate these blocks, under vacuum, after a number of sections had been cut. In one block this was necessary four times before adequate infiltration of the deep tissues was achieved.

## VI. Celloidin embedding.

Celloidin has been used, as an embedding medium for hard tissues, in which there was delicate soft tissue, because the celloidin provided considerable support for these tissues during sectioning and was thus considered desirable for the handling of this type of material.

Celloidin, or LVN, has several advantages and disadvantages concerning its use as an embedding medium. There is less shrinkage and disturbance of tissue with celloidin, due largely to the lack of heat associated with its use, especially as compared with paraffin wax techniques. The plasticity and reduced hardness of the medium are claimed (DRURY and WALLINGTON, 1967) to improve the cutting qualities of large blocks of dense bone, compared with similar preparations embedded in paraffin. It was also claimed that there was superior cohesion of tissue layers of different consistencies with celloidin, which reduced the artefacts due to tearing and separation of the tissues.

The disadvantages relate primarily to the difficulty in technique that are inherent in celloidin techniques. Impregnation of the tissues by celloidin is exceedingly slow because of the viscosity of the material.

It is very difficult to achieve sections thinner than 10um in thickness and it is difficult to obtain serial sections because the celloidin does not provide a ribboning effect when sectioned. Celloidin is also inconvenient because it is necessary to keep the block wet, with alcohol, during storage and section cutting.

In contrast to the celloidin embedding, the double embedded paraffin wax technique provided a compromise between the properties of the paraffin wax and celloidin. The double embedding technique utilises the advantages of the celloidin, vis the plasticity and support, together with the advantages of paraffin wax, vis ease of handling, ribboning qualities and saving of time. BRAIN (1974) has developed a modified paraffin wax which he claims is suitable for use with decalcified material to provide sections in which soft and decalcified hard tissues are not disturbed.

In view of the past use of celloidin, the first block, which was a 12 week foetus, was prepared for celloidin embedding using a technique similar to that described by HAWTHORN (1971).

The block of temporomandibular joint, was placed in 70% alcohol, which was changed daily, for one week. This was followed by 1/2 days in 95% alcohol,

that was changed twice daily, and then two days in absolute alcohol, changed twice daily, for two days. The final step in the dehydration consisted of the immersion of the block in a 50/50 absolute alcohol/anaesthetic ether solution, changed twice daily, for one day.

LVN celloidin was used to increase the quantity of celloidin that was dissolved in solution compared with normal celloidin. The block was placed in a 5% LVN solution for 10 days, 10% LVN for 8 days and 15% LVN for 7 days, to achieve impregnation. The block was impregnated for such a long period to ensure adequate impregnation.

The impregnated tissue was blocked in 15% LVN in a dessicator using a cardboard boat, placed on several glass rods over a small quantity of anaesthetic ether for 2 hours. At the end of that time the ether was replaced with chloroform for 24 hours and was completely immersed in chloroform for a further 24 hours. The block was then stored in 70% alcohol until ready for use.

The block was mounted on a wooden block prior to sectioning on a sledge microtome. Before mounting it was necessary to soak both the wooden block and the tissue block in absolute alcohol/ether for one minute to soften the celloidin. 10% LVN was then placed over the surface of the wooden block and the tissue block pressed into it.

The combination block was then hardened in chloroform and stored in 70% alcohol. It was essential to store the LVN block in 70% alcohol and to keep it wet, with the same solution, during all manipulations and section cutting. The block was kept wet during sectioning by a drip apparatus, which was set up over the microtome, to enable the alcohol solution to drip onto the block during the entire procedure.

Considerable difficulties were encountered with the celloidin embedded tissue. The drip that was set up over the microtome, to keep the block wet, was found to be most inconvenient and difficult to control.

Cutting the celloidin sections proved an exceedingly difficult task. Numerous angulations of the microtome blade were tried and the blade was sharpened frequently. After several attempts of cutting sections it was decided to reinfiltate the tissue with celloidin. The tissue was thus subjected to another 10 days in 5% LVN, 8 days in 10% LVN and 7 days in 15% LVN. The tissue was then blocked as previously. Again the cutting of sections proved very difficult, with the result that very few reasonable sections were obtained. The sections were 20um in thickness but were of uneven thickness.

This occurred because as the blade passed over the block, the block twisted on its mounting, due to the plasticity of the celloidin block. This block was subsequently discarded.

As a result of the difficulties encountered using the celloidin technique it was considered of advantage to try a double embedded paraffin technique. This was done for all blocks used in this study with a considerable degree of success.

## VII. Staining.

### I. Introduction.

The treatment of tissues, during preparation, affect the staining characteristics of the tissues. This alteration in the staining characteristics of the tissues is brought about by the various fixative agents, and also by the nature and type of the decalcification agents. Thus fixation assists the interaction between the tissues and the dyes (DRURY and WALLINGTON, 1967). Chromatin is split into DNA and protein when the tissues are fixed by formaldehyde and ethyl alcohol, which enables the DNA to be stained with basic dyes, such as haematoxylin. However the affect of nitric acid on the

tissues is deleterious to their staining properties as it destroys, or reduces, the basophilia of the DNA, with subsequent poor staining of this complex, by the basic dyes (DRURY and WALLINGTON, 1967).

The pH of the tissue to be stained affects its staining properties, in as much as it affects the basophilia or acidophilia of the various components of the tissue. Thus it was essential to remove all acid from the tissues after decalcification.

Several stains were used in the present study to highlight different features of the various structures. The stains used were haematoxylin and eosin, van Gieson, and Gomori's aldehyde fuchsin.

## 2. Haematoxylin and Eosin (Lillie/Mayer).

The haematoxylin and eosin (H and E) staining combination was used as the standard stain because of its versatility in displaying both acidic and basic characteristics in tissues.

Haematoxylin is a widely used stain for the demonstration of cells nuclei, muscle striation and collagen fibres (CLAYDEN, 1962), preceding the staining of the cytoplasm and connective tissue with eosin.

The haematoxylin used in this study was Lillie/Mayer and the eosin was that found in appendix 4.

The slides, on which the sections had been dried in an oven, were placed in pure Xylol for approximately two minutes until the wax had been dissolved from the slides and the sections appeared transparent. As Xylol is not miscible with aqueous solutions it is essential to replace the Xylol in the sections with an aqueous alcohol solution. To these ends the sections were transferred from the Xylol, to 50% Xylol/absolute alcohol for two minutes then to 70% aqueous alcohol for another few minutes. At this stage the sections are receptive to staining and could be thus treated.

The sections were stained in Lillie/Mayer haematoxylin for 10 minutes and then the superficial excess stain was washed off in running water for 5 minutes. As this technique stained the haematoxylin by regression, it was essential to remove the excess haematoxylin stain from the tissue by treating the sections in a 1% hydrochloric acid in 70% alcohol solution for a few seconds, that is, by differentiation. The acid changed the colour of the slides from blue to red.

The slides were then 'blued' in an alkaline solution, which in this case was tap water, for 10 minutes.

The alkaline solution brought out the desired blue colour by the precipitation of the mordant, which carried the haematin that is associated with the haematoxylin, with it. The sections were, at this stage, stained by the haematoxylin with the result that the nuclear material and basophilic cytoplasm were stained blue, bone was stained purplish blue and cartilage was

To achieve well balanced sections, with relation to colour contrast, it was desirable to counter-stain the haematoxylin stained sections with a counter stain of eosin. After the 'blueing' was completed the sections were placed in eosin for 4 minutes. The excess eosin was then washed off in water and the sections examined to verify that the staining was adequate. The cytoplasm and muscle fibres appeared deep pink and collagen a lighter pink.

Since the sections had been subjected to aqueous solutions it was essential to remove the water before the sections could be mounted using the current mounting agents, which are miscible with Xylol but not water. This required the sections to be dehydrated by passing through 70% aqueous alcohol and then into absolute alcohol. This was followed by immersion in 50% Xylol absolute alcohol, and then in pure Xylol for 2 minutes, after which the sections were ready to be mounted in a suitable synthetic resin medium, which in this case was 'Xam' .

### 3. van Gieson.

The van Gieson mixture of picric acid and acid fuchsin provides a simple technique for the differential staining of collagen. It stains nuclei, blackish; collagen deep red; muscle, cytoplasm and fibrin brown to yellow; bone orange and elastin black.

The sections were taken to water in the same way that they were with the H and E technique. The sections were placed on a rack over the sink and the Weigert's haematoxylin was poured over the slides, there to remain for 10 minutes, while it stained the nuclei. The haematoxylin was washed off with tap water, which was itself washed off with distilled water. As this was a progressive staining technique it was not necessary to differentiate, or 'blue', the sections after treatment with haematoxylin.

The van Gieson stain was then used. It was poured over the sections for 4 minutes. The van Gieson stain used was a mixture of saturated aqueous picric acid and acid fuchsin (DRURY and WALLINGTON, 1967).

After 4 minutes, the excess van Gieson stain was washed off with distilled water. The sections were then placed in 95% alcohol, dehydrated, cleared and mounted.

#### 4. Gomori's (1950) Aldehyde Fuchsin.

This stain was designed to illustrate the presence of elastin fibres, which together with some mucopolysaccharides and mast cell granules, appear deep purple-violet. Other structures were stained according to the counter-stain, which in this study was 0.5% light green stain.

The sections were deparaffinized and brought to water, as with the H and E technique. Up to 2 hours was required for the sections to be stained by aldehyde fuchsin stain, the formulation for which appeared in LILLIE (1965). The excess stain was washed off with 70% alcohol with several changes and the sections were then counterstained with 0.5% light green stain for a few seconds, the excess being removed by washing with 70% alcohol. This was followed by dehydration, clearing and mounting.

Chapter 2. The Histology of the Temporomandibular  
Joint Complex in the Sixteen week  
(132 mm C.R.) Foetus.

<u>Contents.</u>		<u>Page.</u>
I	Introduction	26.
II	Results - Sagittal	27.
	1. Anterior Capsule	27.
	2. Posterior Capsule	30.
	3. Meniscus	30.
	A. Pes menisci	32.
	B. Pars gracilis menisci	32.
	C. Pars posterior menisci	34.
	D. Bilaminar zone	34.
	4. Articular Surface of the Temporal Bone	37.
	5. Articular surface of the Condyle.	39.
	A. Perichondrium	39.
	B. Zone of young and resting chondrocytes	42.
	C. Zone of flattened chondrocytes	42.
	D. Zone of hypertrophic and degenerate chondrocytes	42.

	25.
E. Zone of irruption	44.
F. Zone of bone deposition	44.
6. Periosteum of the Condylar Neck	48.
7. Auriculo-temporal Nerve Complex	52.
8. Petro-tympanic Fissure	52.
9. Middle Ear	55.
III. Results - Coronal	57.
1. Anatomy	57.
2. Capsular Complex	59.
A. Lateral capsule	59.
B. Medial capsule	59.
3. Meniscus	62.
4. Articular Surface of the Temporal Bone	62.
5. Articular Surface of the Condyle	67.
A. Perichondrium	67.
B. Zone of young and resting chondrocytes	70.
C. Zone of flattened chondrocytes	70.
D. Zone of hypertrophic and degenerate chondrocytes	70.
E. Zone of irruption and bone deposition	74.
6. Remodelling of the Condylar Neck	74.
IV. Discussion	76.

## Chapter 2.

### The Histology of the Temporomandibular Joint Complex in the Sixteenth Week (132 mm C.R.) Foetus.

#### I. Introduction.

The temporomandibular joint complex was completely established by the 14th week (SYMONS, 1952; BAUME, 1962a,b; FURSTMAN, 1963; YUODELIS, 1966) such that after that time development of the temporomandibular joint results in its increase in size, change in morphology, and alteration in its orientation, relative to the surrounding structures. Consequently, in the 16 week foetus a complete but immature joint complex could be anticipated.

At the sixteen week stage the development in the middle ear is said to be far from complete as pneumatization had not occurred by that time (TUCHMANN-DUPLESSIS, 1968). The ossicles were formed in cartilage (RICHANY et al, 1954) but the formation of the anterior ligament of the malleus did not commence until after the 18th week (HANSON et al, 1962).

The initial part of the present study was concerned with the histology of the temporomandibular joint complex at about the sixteenth week of intrauterine life.

The crown-rump length of the foetus was 132 mm, which according to PATTEN (1948) this corresponded to the 16th week of foetal life.

## II. Results - Sagittal.

The temporomandibular joint and middle ear complex were examined in sagittal section (Fig. 2-1).

The condylar neck was inclined posteriorly at an angle of approximately 45 degrees with the horizontal, and had a shape reminiscent of that found in the mature joint. The superior and inferior joint compartments were well defined, such that the meniscus was clearly discernible.

### 1. Anterior Capsule.

The anterior strata of the meniscus comprised the anterior capsule and thus formed the anterior borders of the joint (Fig. 2-2).

The antero-superior stratum was seen to attach the meniscus to the temporal bone, whilst the antero-inferior stratum attached the meniscus to the condyle, below the articular surface of the condylar head. More anteriorly the lateral pterygoid muscle was evident, having been sectioned in cross-section because of its medial orientation (Fig. 2-2).

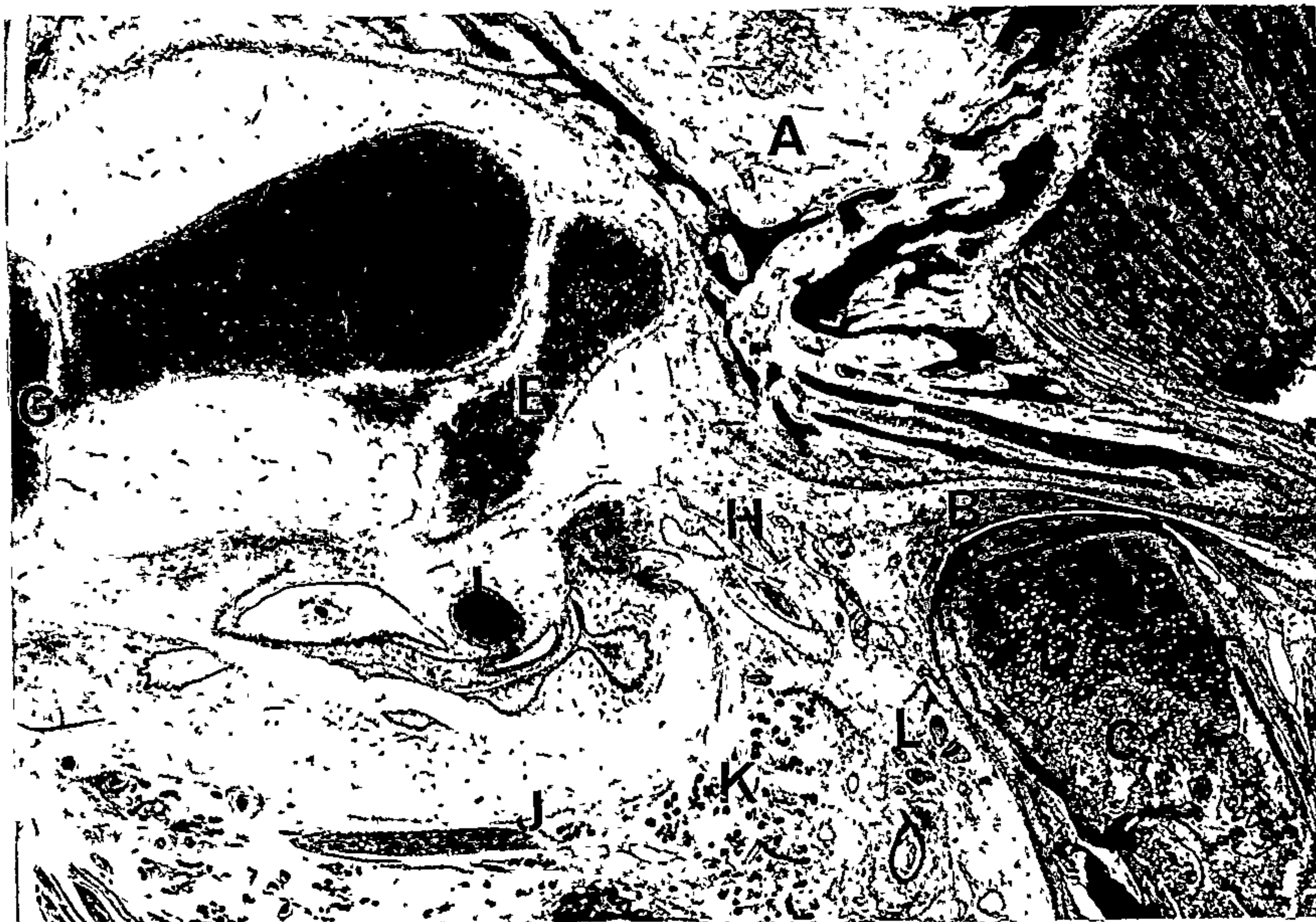

Figure 2-1. Photomicrograph of sagittal section of a sixteen week foetus. x 4 (H and E).

- A - Temporal Bone
- B - Meniscus
- C - Condyle
- D - Condylar cartilage
- E - Malleus
- F - Incus
- G - Stapes
- H - Petro-tympanic fissure
- I - Meckel's cartilage
- J - Facial nerve
- K - Parotid gland
- L - Auriculo-temporal nerve

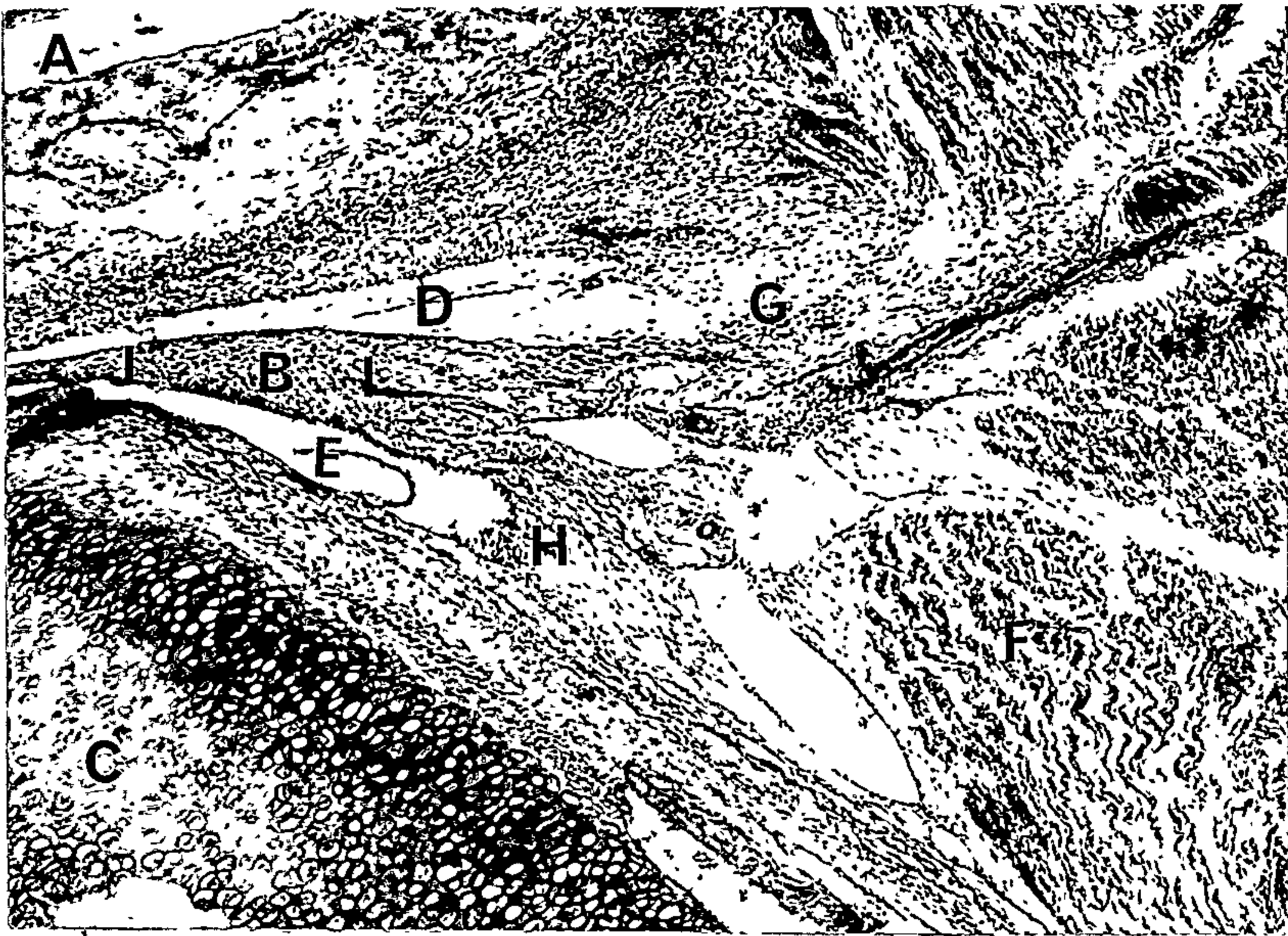


Figure 2-2. Anterior part of the temporomandibular joint. x 15 (H and E).

- A - Temporal bone
- B - Meniscus
- C - Condyle
- D - Superior joint compartment
- E - Inferior joint compartment
- F - Lateral pterygoid muscle
- G - Antero-superior stratum
- H - Antero-inferior stratum
- I - Pes menisci
- J - Pars gracilis menisci

## 2. Posterior Capsule.

The posterior capsule was made up by the posterior strata of the meniscus. They defined the posterior extent of the joint compartments but did not indicate the posterior border of the temporomandibular joint complex, which is usually considered to include the bilaminar zone (REES, 1954)(Fig. 2-3).

The postero-superior stratum attached the meniscus to the temporal bone, while the postero-inferior stratum attached the meniscus to the neck of the condyle, below the posterior articular slope (Fig. 2-3).

## 3. Meniscus.

The meniscus divided the joint cavity into a superior and an inferior joint compartment, the superior being more extensive than the inferior (Fig 2-1). The shape of the meniscus was similar, but not identical to the mature meniscus, so that the various regions of the meniscus could be identified. The pes menisci (Fig. 2-2) formed the anterior part of the meniscus and was continuous posteriorly with the pars gracilis menisci. The pars posterior was continuous with the posterior strata (Fig. 2-3). Although morphologically these different areas of the meniscus could be discerned, it was not possible to make such a distinction when examined histologically (Figs. 2-4 to 2-9).

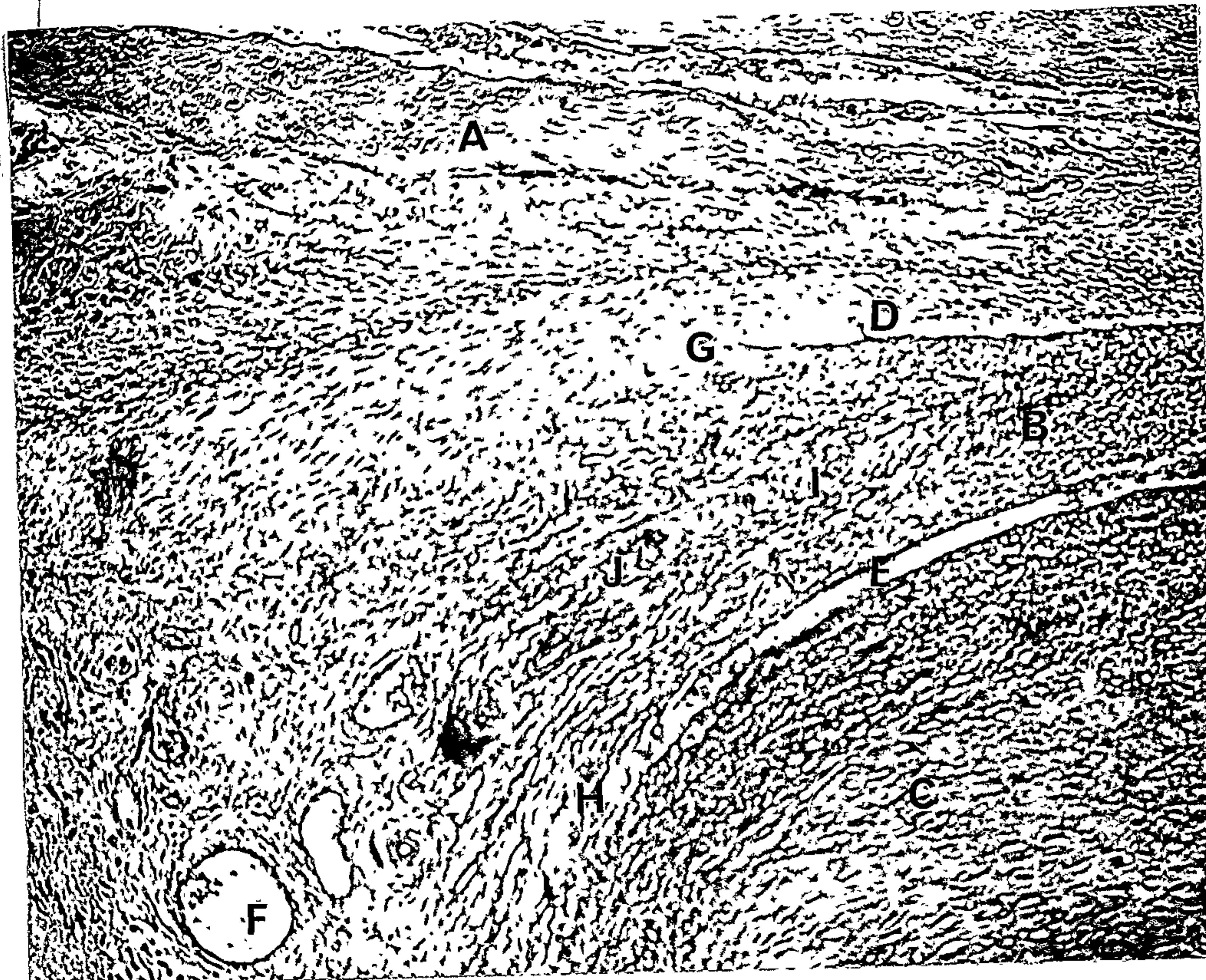


Figure 2-3. Posterior part of the temporomandibular joint x 96. (H and E).

- A - Temporal bone
- B - Meniscus
- C - Condyle
- D - Superior joint compartment
- E - Inferior joint compartment
- F - Blood vessel
- G - Postero-superior stratum
- H - Postero-inferior stratum
- I - Pars posterior menisci
- J - Bilaminar zone

#### A. Pes Menisci.

Structurally the meniscus consisted of highly cellular fibrous tissue (Fig 2-4). The collagen fibres, which formed the fibrous content of the pes, were seen to be roughly orientated in an antero-posterior direction. Vascular elements could also be discerned (Fig 2-4).

Superior to a band of orientated fibroblasts, on the superior surface of the pes, was a layer of squamous type synovioblasts, several cells thick (Fig. 2-4). On the inferior surface of the pes was a cellular type of synovial membrane (Fig. 2-4), but in this region the cells were both of the cuboidal and squamous type.

The superior and inferior strata of the pes menisci formed the anterior extremities of the superior and inferior joint compartments. The synovial membrane that lined the surfaces of the pes continued along these strata to their reflections onto the temporal bone and condyle respectively (Fig. 2-2).

#### B. Pars Gracilis Menisci.

The pars gracilis menisci (Fig. 2-5) was more cellular than the pes. The cells had large roundish nuclei which were not obviously orientated. Fine collagenous fibres were also seen.

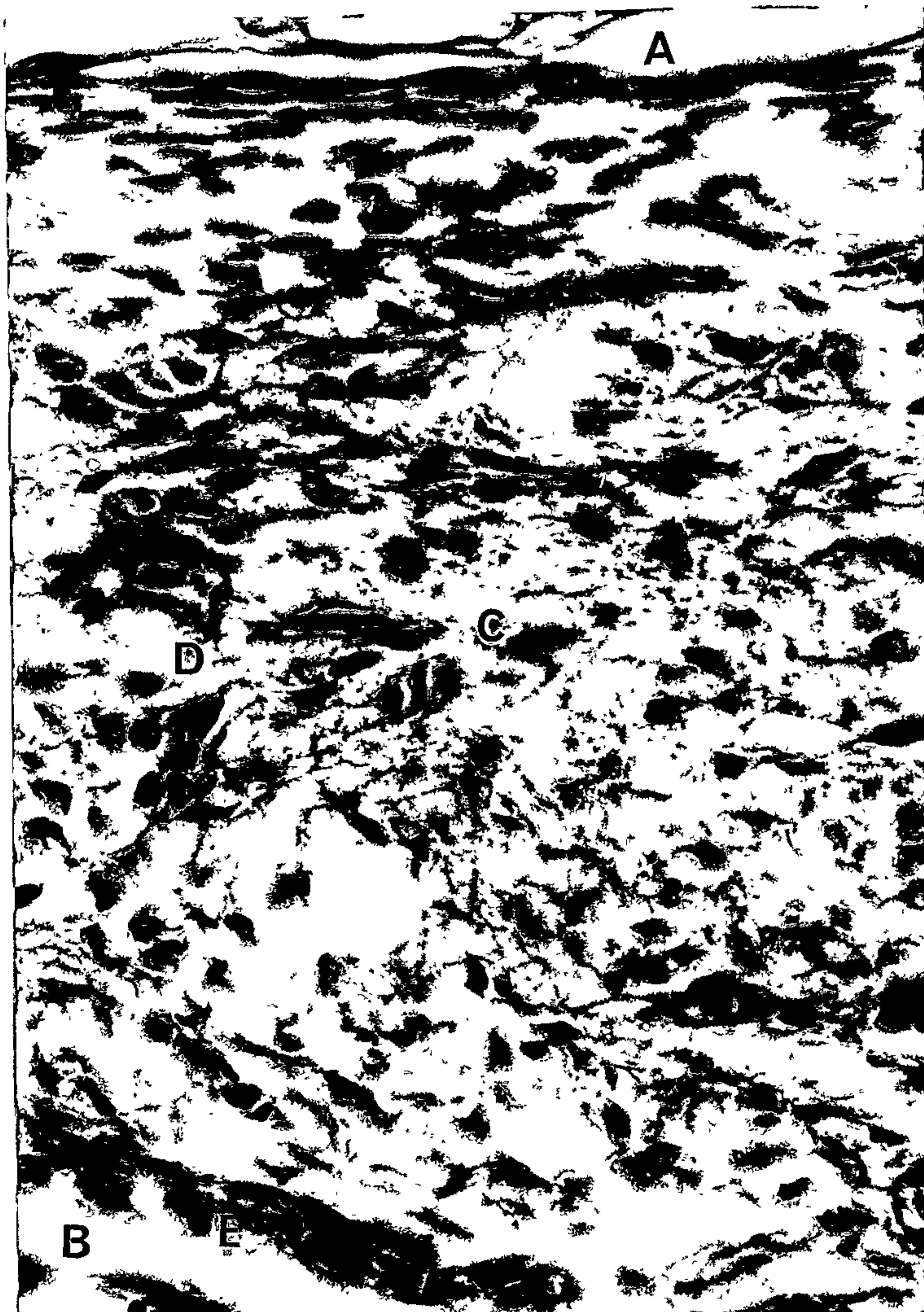

Figure 2-4. Photomicrograph of Pes menisci  
x 960 (H and E).

- A - Superior joint compartment
- B - Inferior joint compartment
- C - Fibroblast
- D - Blood vessel
- E - Synovial membrane



Figure 2-5. Photomicrograph of the Pars gracilis menisci x 960 (H and E).

- |   |   |                            |
|---|---|----------------------------|
| A | - | Superior joint compartment |
| B | - | Inferior joint compartment |
| C | - | Fine collagen fibre        |
| D | - | Temporal periosteum        |
| E | - | Synovial membrane          |

A small number of round cells, with a large cytoplasm, resembling chondrocytes, were present near the inferior surface of the pars gracilis.

As in the pes, there was a layer of flattened cells constituting a squamous type of synovial membrane on the superior surface (Fig. 2-5). The inferior surface of the gracilis was lined by cuboidal cells that constituted a synovial membrane in that area.

#### C. Pars Posterior Menisci.

The pars posterior was immediately posterior to the pars gracilis, and histologically it appeared to be more cellular (Fig. 2-6).

A synovial membrane similar to that found in the other areas of the meniscus was observed. On the superior surface was a cellular type of membrane approximately two cells thick. These cells were of the squamous type, unlike the inferior surface which had a synovial membrane of cuboidal type cells, approximately two cells thick (Fig. 2-6).

#### D. Bilaminar Zone.

The bilaminar zone was posterior to the pars posterior menisci and was outlined by the indefinite postero-superior and postero-inferior strata of the meniscus (Fig. 2-3). These strata attached the meniscus to the temporal bone and neck of condyle, respectively.

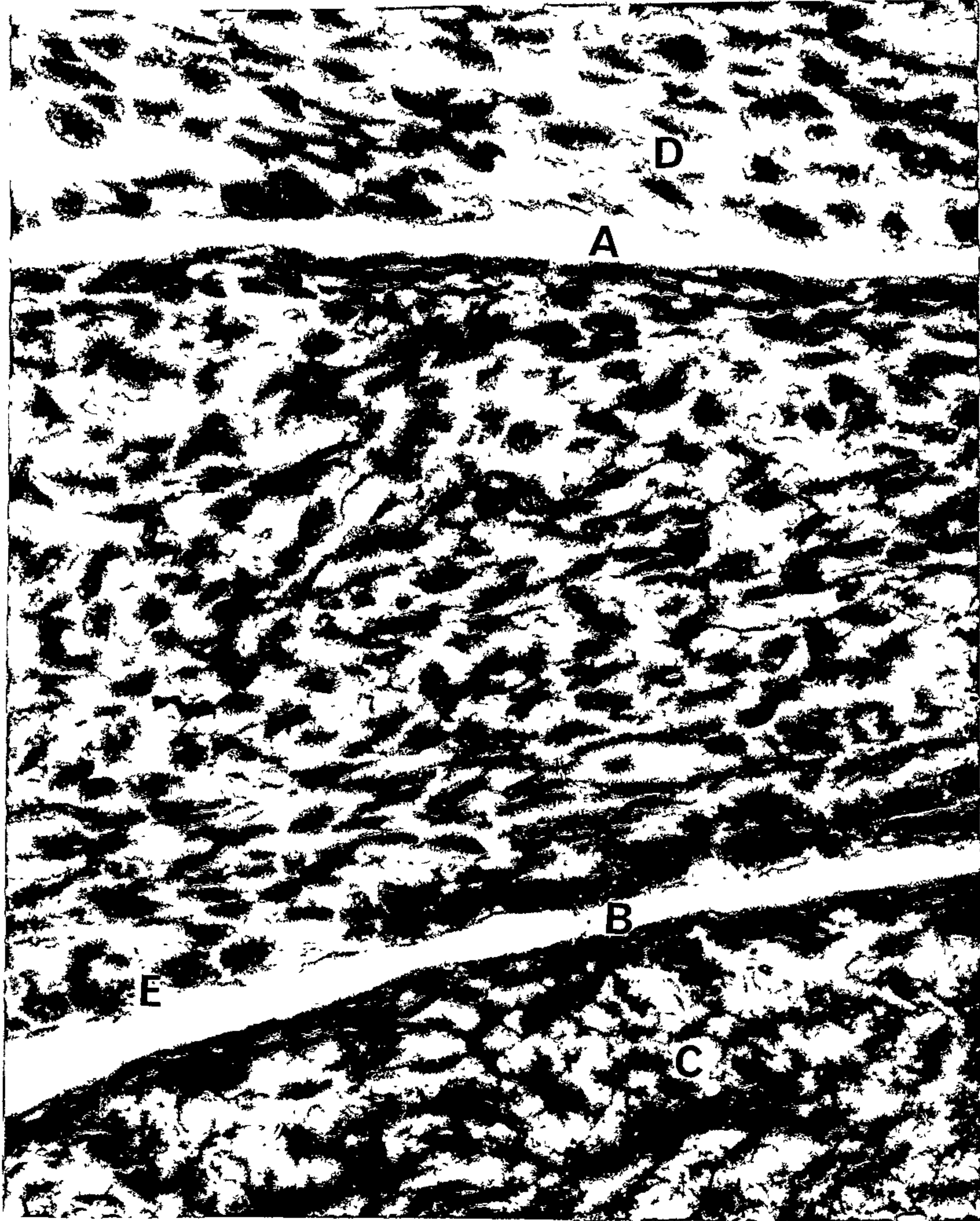

Figure 2-6. Photomicrograph of the Pars posterior menisci x 960 (H and E).

- A - Superior joint compartment
- B - Inferior joint compartment
- C - Condyle
- D - Temporal periosteum
- E - Synovial membrane

The bilaminar zone was comprised of fibroblasts and undifferentiated mesenchymal cells with fine collagen fibres that appeared to be randomly orientated. The undifferentiated cells had large rather pale staining nuclei whereas the nuclei of the fibroblasts stained more densely and were elongated when viewed in profile (Fig. 2-7). Numerous blood vessels and nerve bundles were present throughout the bilaminar zone (Figs. 2-1, 2-3 and 2-7).

#### 4. Articular Surface of the Temporal Bone.

The temporal element of the temporomandibular joint, in the 16 week foetus, did not exhibit the concavity that was present in the mature joint. In contrast to the concavity of the mature joint, the articular surface of the temporal bone was flat, such that a glenoid fossa was not evident at that age (Fig. 2-1).

The articular surface of the temporal bone was covered by a thick layer of periosteum, which was easily divisible into an outer and an inner layer. The outer layer consisted of densely packed fibroblasts type cells orientated in an antero-posterior direction. Internal to the outer layer was an inner cellular layer. The inner layer contained numerous cells, but the cells were much more loosely packed than those in the outer layer.

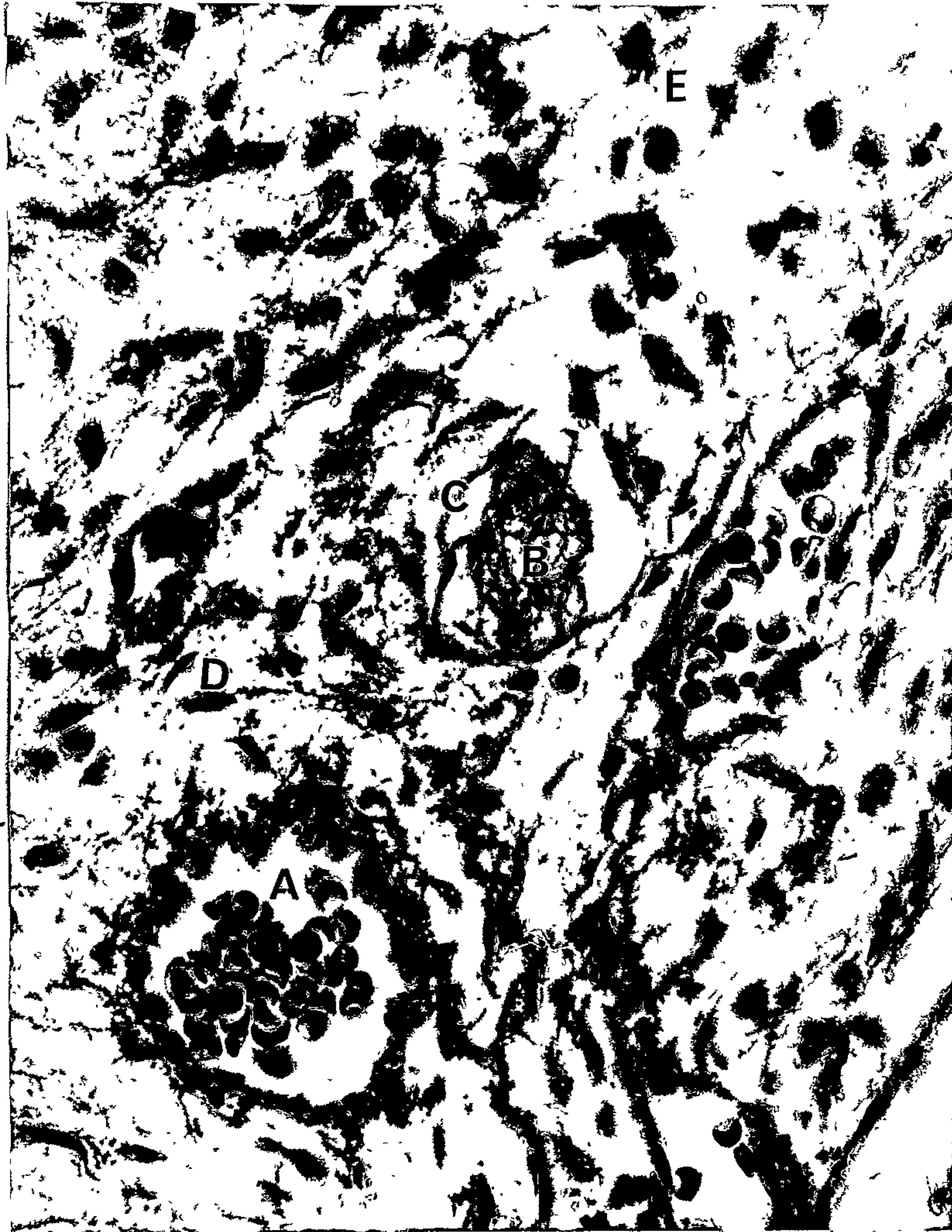


Figure 2-7. Bilaminar zone of the temporomandibular joint x 960 (H and E).

- A - Blood vessel
- B - Nerve fibre
- C - Epineurium
- D - Fibroblast
- E - Undifferentiated mesenchymal cell

Osteoblasts could be identified adjacent to the developing temporal bone. These cells appeared to be polarised with a juxta-nuclear clear area (Fig. 2-8).

Blood vessels of the capillary type were present throughout the inner and outer layers of the periosteum, but no synovial membrane covering the periosteum was observed.

### 5. Articular Surface of the Condyle.

The articular surface of the condyle was vastly different to that of the temporal bone, because of their different embryological development. The temporal bone was formed as membraneous bone (Fig. 2-8), whereas the condylar head was formed from secondary cartilage (Fig. 2-1) (MOFFETT et al, 1964).

#### A. Perichondrium.

The articular surface of the condyle was covered by a thin layer of perichondrium of only two or three cells thickness (Fig. 2-9). The perichondrium was comprised of densely packed collagen fibres and was therefore identified as the fibrous superficial layer of the condyle. Below this fibrous layer was a layer of presumptive hyaline cartilage. The cells within the presumptive hyaline cartilage lay within definite lacunae (Fig. 2-9) and thus resembled chondrocytes.




Figure 2-8. Photomicrograph of the mandibular fossa x 960 (H and E).

- A - Temporal bone
- B - Osteocyte
- C - Cellular Layer
- D - Blood vessel
- E - Outer Fibrous Layer of Periosteum
- F - Fibrous layer of periosteum



Figure 2-9. Surface of condyle.

x 960 (H and E).

- A - Fibrous layer
- B - Presumptive hyaline cartilage
- C - Young and resting chondrocytes
- D - Flattened chondrocytes
- E - Chondroid type cell

### B. Zone of Young and Resting Chondrocytes.

Beneath the fibrous layer and presumptive hyaline cartilage was an indefinite zone of young and resting chondrocytes (Fig. 2-9 and 2-10). This zone was seen, on occasion to form projections into the secondary cartilage below (Figs. 2-1 and 2-28) and encircle islands of secondary cartilage. The zone of young and resting chondrocytes was approximately one and a half times as thick as the perichondrium and presumptive hyaline cartilage (Fig. 2-9) but the boundaries between the different layers was not distinct. In fact the boundaries suggested could only be construed to approximate the different layers. These layers merged with each other without forming distinct boundaries. The whole picture of the secondary condylar cartilage was one of continued cytomorphosis as the cells became more removed from the surface.

### C. Zone of Flattened Chondrocytes.

Below the zone of young and resting chondrocytes was an extensive layer of flattened chondrocytes (Figs. 2-9 and 2-10).

### D. Zone of Hypertrophic and Degenerate Chondrocytes.

A zone of hypertrophic and degenerate chondrocytes was seen immediately below the zone of flattened chondrocytes.




Figure 2-10. Subsurface layer of condyle  
x 960 (H and E).

- A - Young and resting chondrocytes
- B - Flattened chondrocytes
- C - Hypertrophic chondrocytes

The zone of hypertrophic chondrocytes could be identified by a marked increase of their cytoplasm (Fig. 2-10) while the zone of degenerate chondrocytes could be identified by calcification of the intercellular matrix and disintegration of the nuclei of the chondrocytes (Fig. 2-11).

#### E. Zone of Irruption.

Inferior to the hypertrophic and degenerate chondrocytes was the zone of irruption (Fig. 2-12). Osteogenic mesenchyme was seen to invade the calcified cartilage which it appeared to destroy. However, remnants of calcified cartilage were seen in the irruptive zone (Fig. 2-12).

#### F. Zone of Bone Deposition.

A zone of bone deposition was apparent below the irruptive zone. This consisted of trabeculae of bone containing remnants of calcified cartilage (Fig. 2-13).

The orientation of the zones described above were not always in a supero-inferior direction. This was due to the extensions of the zones of young and resting chondrocytes into the underlying tissue (Fig. 2-28).

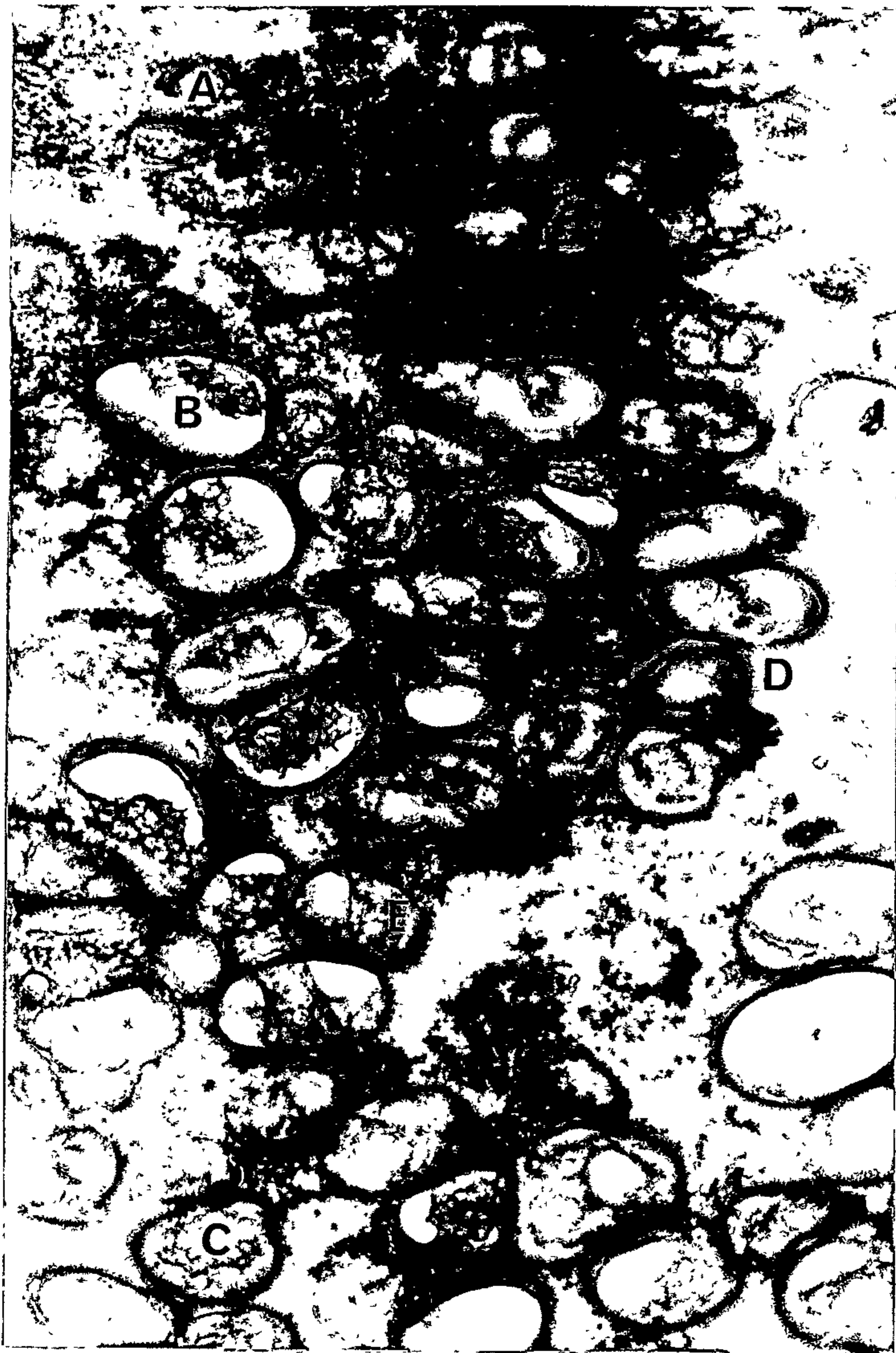

Figure 2-11. Zone of hypertrophic and degenerate chondrocytes. x 960 (H and E).

- A - Chondrocyte
- B - Degenerate chondrocyte
- C - Hypertrophied chondrocyte
- D - Pericellular calcification
- E - Nuclear degeneration

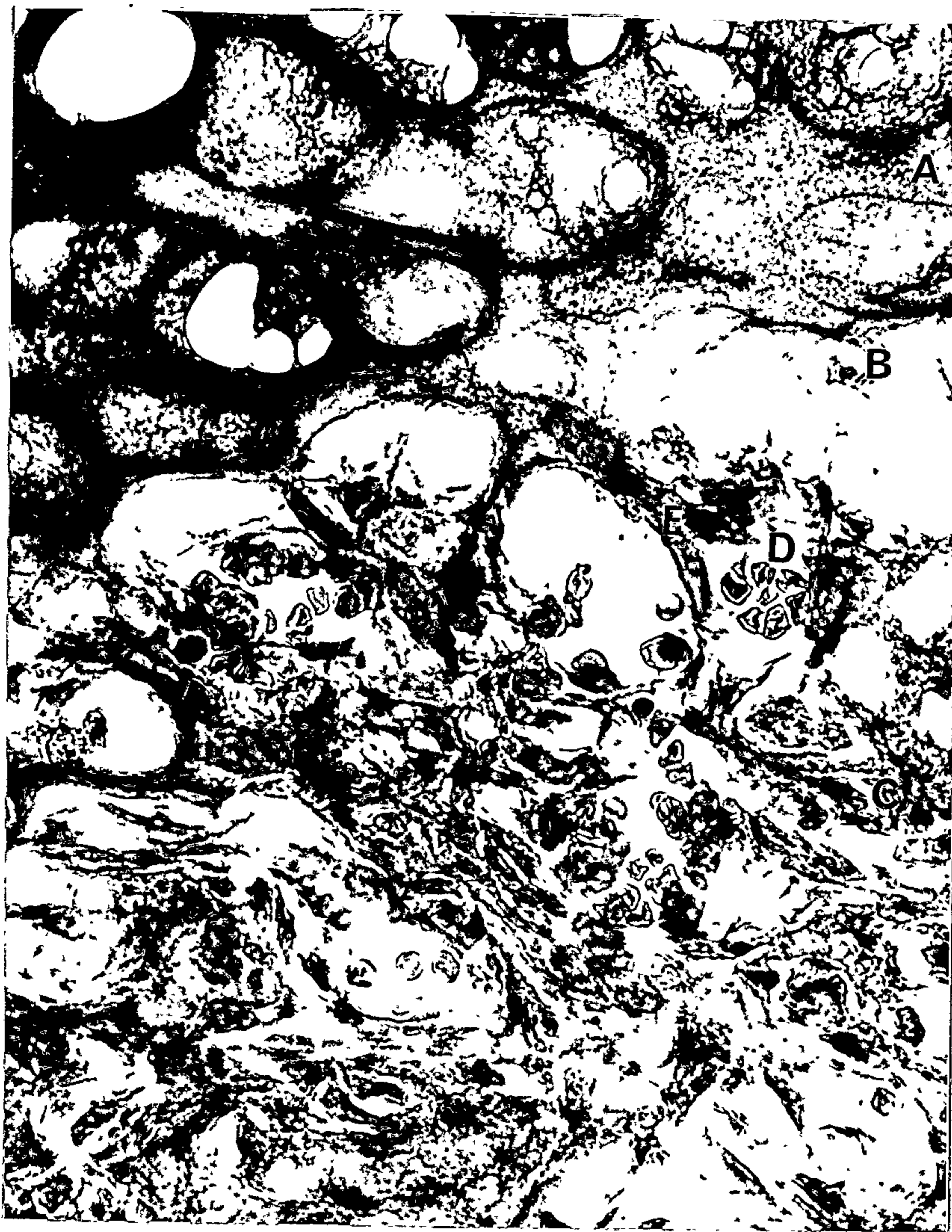


Figure 2-12. Zone of irruption x 960  
(H and E).

- A - Zone of hypertrophic and degenerate chondrocytes
- B - Zone of irruption
- C - Zone of bone deposition
- D - Osteogenic mesenchymal cell
- E - Calcified cartilage

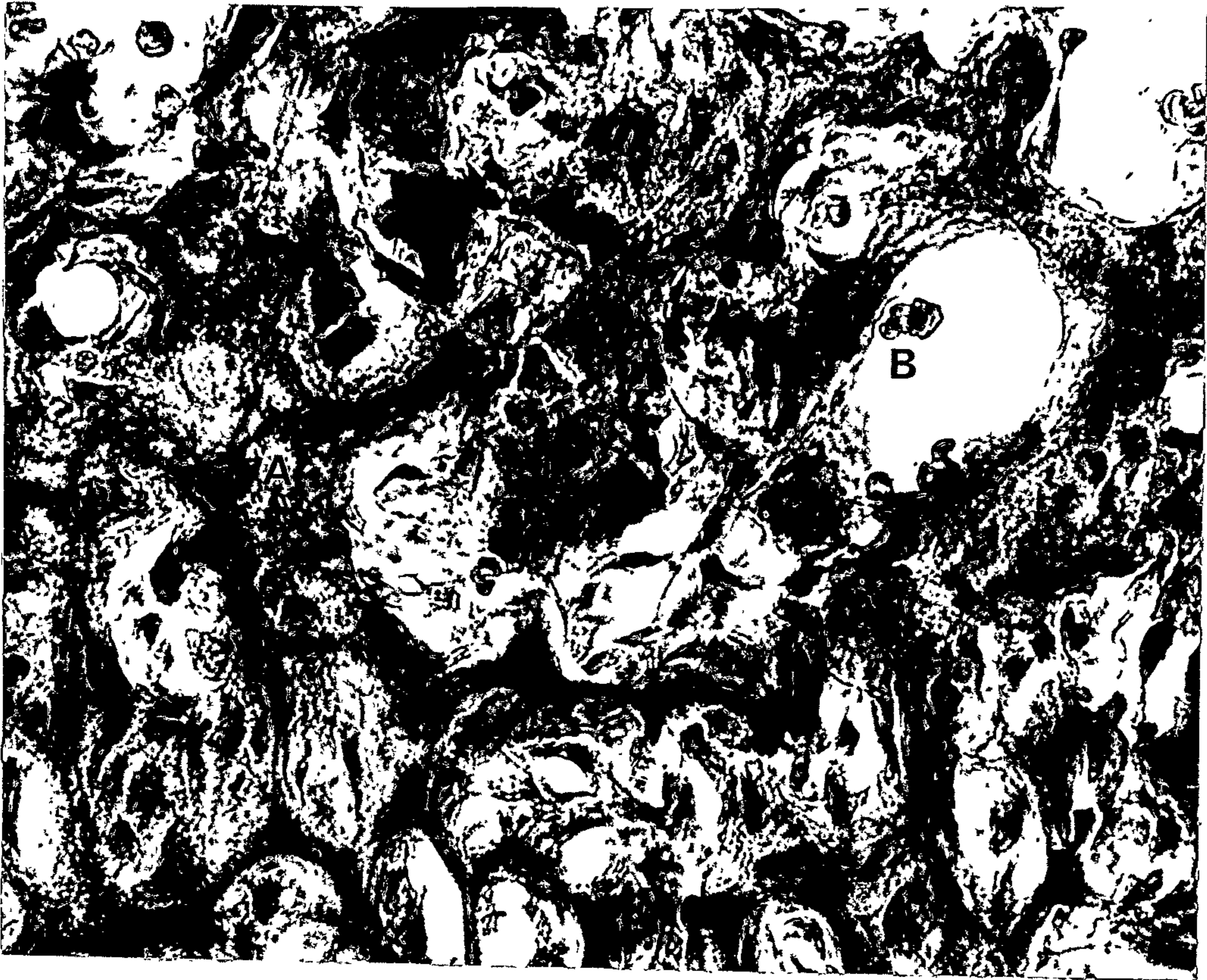

Figure 2-13. Zone of bone deposition

x 960 (H and E).

A - Primary endochondral trabecula

B - Osteogenic mesenchymal cell

## 6. Periosteum of the Condylar Neck.

The perichondrium covered only the articular surface of the condyle (Fig. 2-14), whereas on the anterior and posterior surface of the condylar neck was a thick layer of presumptive periosteum.

The periosteum consisted of an outer fibrous layer and an inner cellular layer (Figs. 2-15 and 2-16). The outer fibrous layer was several cells thick and contained numerous fibroblast type cells, together with collagen fibres, orientated along the direction of the surface of the condylar neck. The outer layer was in contact with the pericondylar tissue, on its outer surface, and the inner layer of the periosteum, on its inner surface. The inner layer was approximately fifteen cells thick and attached the outer layer of the periosteum to the underlying cartilage of the condylar neck. The cells of the inner layer were considered to be chondroblastic in nature (Fig. 2-16). As the tissue underlying the periosteum was cartilage, this tissue should strictly be regarded as perichondrium or presumptive periosteum.

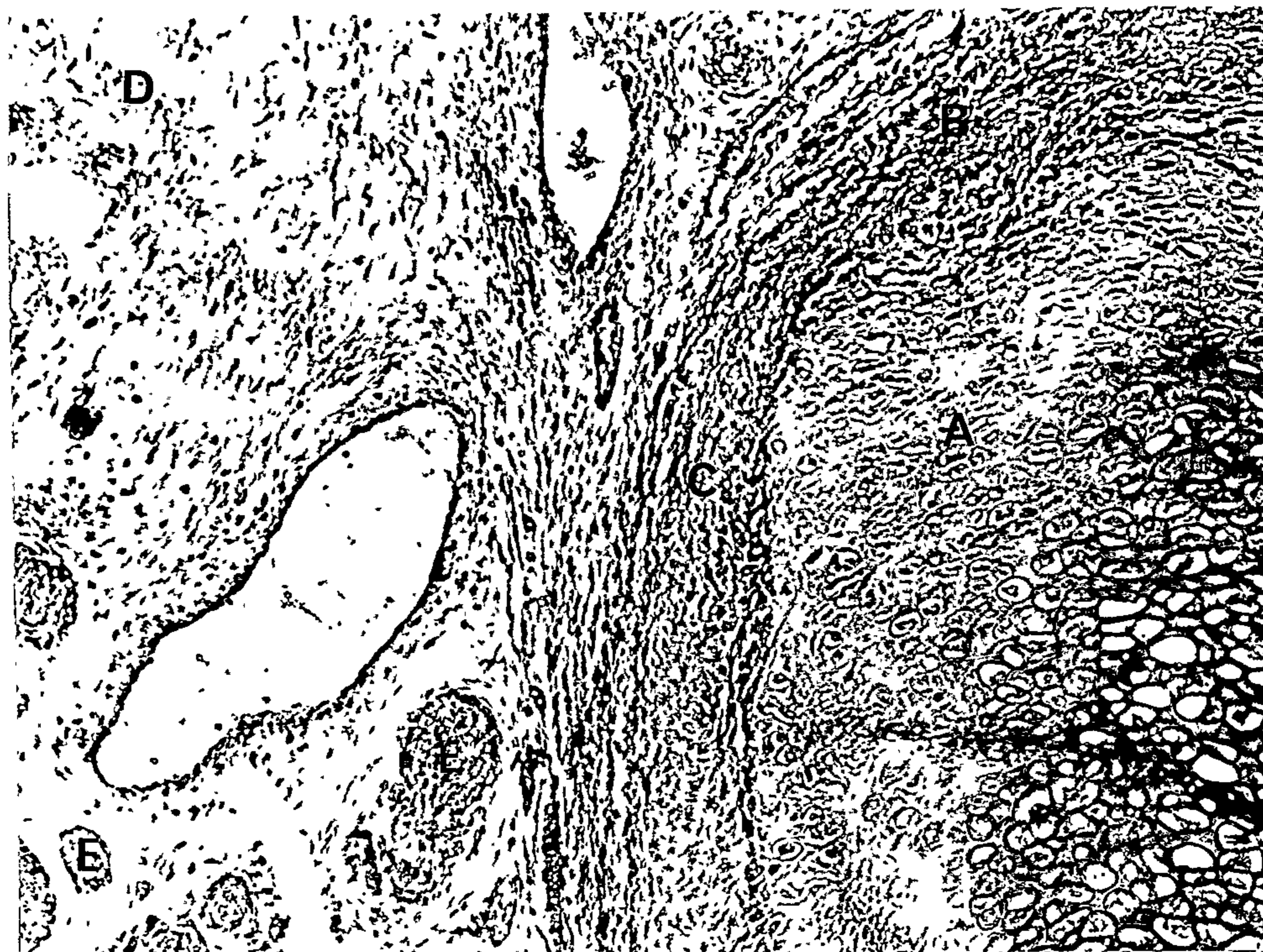

Figure 2-14. Posterior part of the Temporomandibular joint x 960 (H and E).

- A - Condyle
- B - Perichondrium
- C - Periosteum
- D - Bilaminar zone
- E - Auriculo-temporal nerve complex

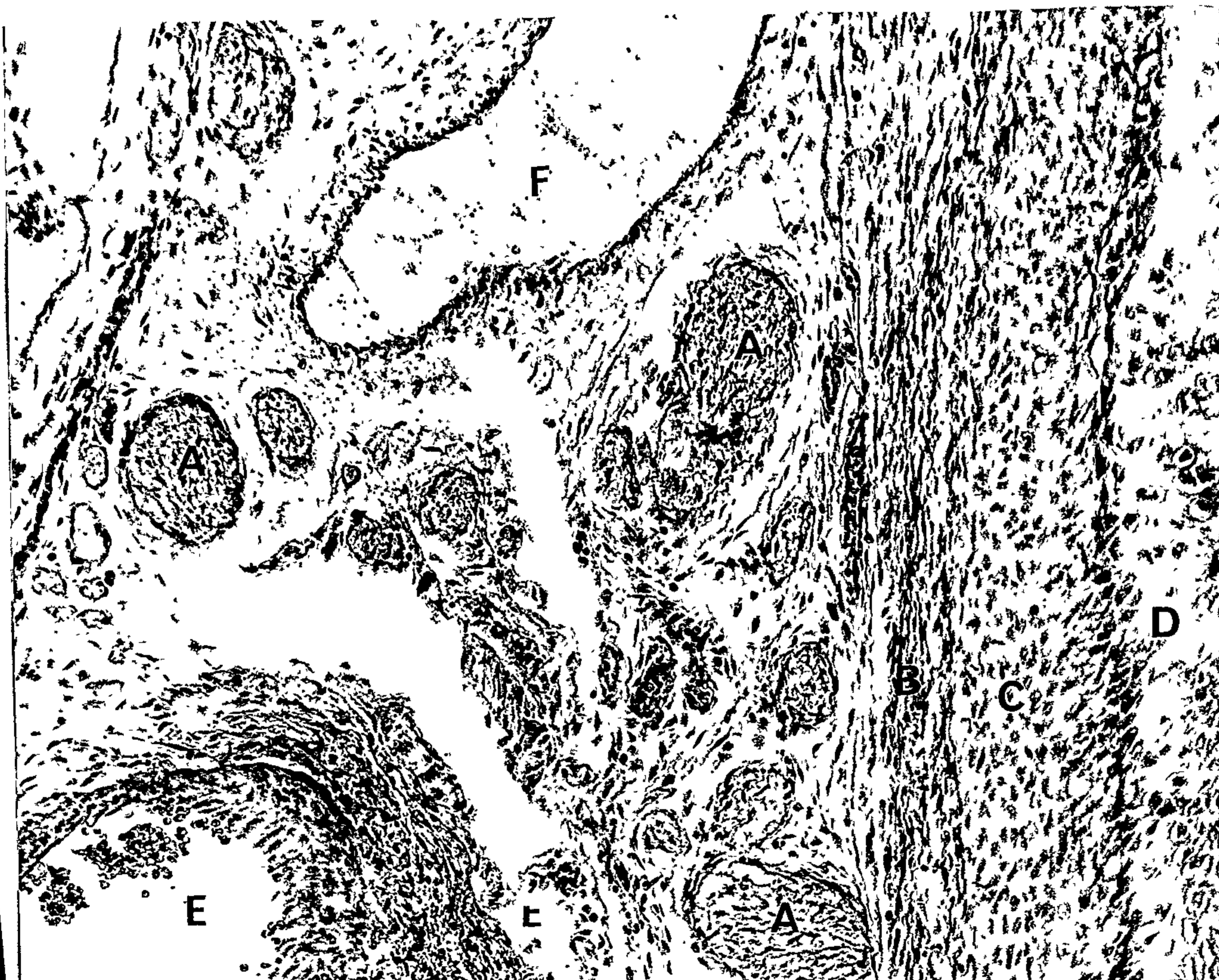

Figure 2-15. Detail of figure 2-14.

x 240 (H and E).

- A - Auriculo-temporal nerve
- B - Fibrous periosteum
- C - Cellular periosteum
- D - Condylar cartilage with chondrocytes
- E - Artery
- F - Vein




Figure 2-16. Periosteum of the condylar neck x. 960. (H and E).

- |   |   |                     |
|---|---|---------------------|
| A | - | Fibrous periosteum  |
| B | - | Cellular periosteum |
| C | - | Chondrocyte         |
| D | - | Cartilage           |

## 7. Auriculo-Temporal Nerve Complex.

The auriculo-temporal nerve complex was found posterior to the condyle, below the posterior articular slope of the condyle, and between the condyle and the parotid gland (Figs. 2-1 and 2-3).

There were approximately a dozen sections of the nerve complex in the sections examined (Figs. 2-1 and 2-15). In close proximity to the nerve complex were several large blood vessels, two of which were present in Figure 2-15. In addition to the large vessels, several small vessels were also apparent.

## 8. Petro-Tympanic Fissure.

The petro-tympanic fissure was a wide patent communication between the posterior aspect of the temporomandibular joint and the middle ear complex (Figs. 2-1 and 2-17).

The temporal bone formed the superior boundary of the fissure. The inferior boundary was less well defined, and could be considered to have been represented by a condensation of mesenchyme, that appeared to have formed the boundary of the middle ear cavity (Fig. 2-17).

The periosteum of the temporal bone, in the region of the fissure, was approximately twice the thickness of that found in the region of the joint (Fig. 2-17 and 2-18).

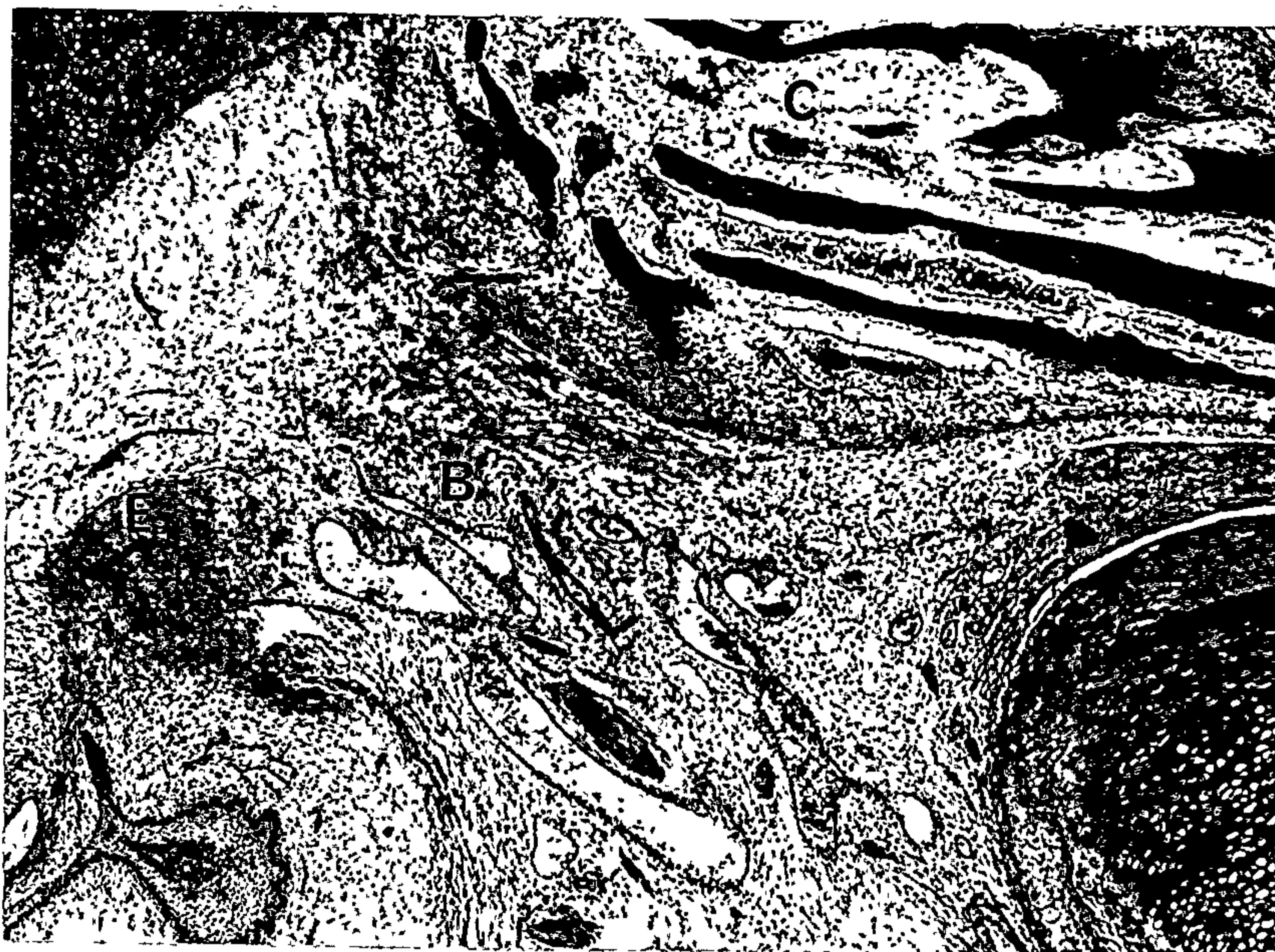

Figure 2-17. Petro-tympanic fissure  
x 20 (H and E).

- A - Malleus
- B - Petro-tympanic fissure
- C - Temporal bone
- D - Condyle
- E - Mesenchymal condensation



Figure 2-18. Contents of the petro-tympanic fissure x 120 (H and E).

- A - Temporal bone
- B - Cellular periosteum
- C - Fibrous periosteum
- D - Fibrous tissue in the petro-tympanic fissure
- E - Blood vessel

The periosteum was considerably more cellular than the contents of the fissure which provided an uninterrupted communication between both structures (Fig. 2-17). Within the fissure were numerous blood vessels of all types.

### 9. Middle Ear.

The middle ear cavity was filled with loose mesenchyme that surrounded the structures that occupied the cavity (Fig. 2-19).

The ossicles of the middle ear were well formed in cartilage, and the joints between them were evident. Cavitation in these joints was well advanced and their primordial joint capsules present (Fig. 2-19).

Meckel's cartilage was seen directly inferior to the manubrium of the malleus. The tympanic cavity, in which cavitation had occurred, lay inferior to the Meckel's cartilage.

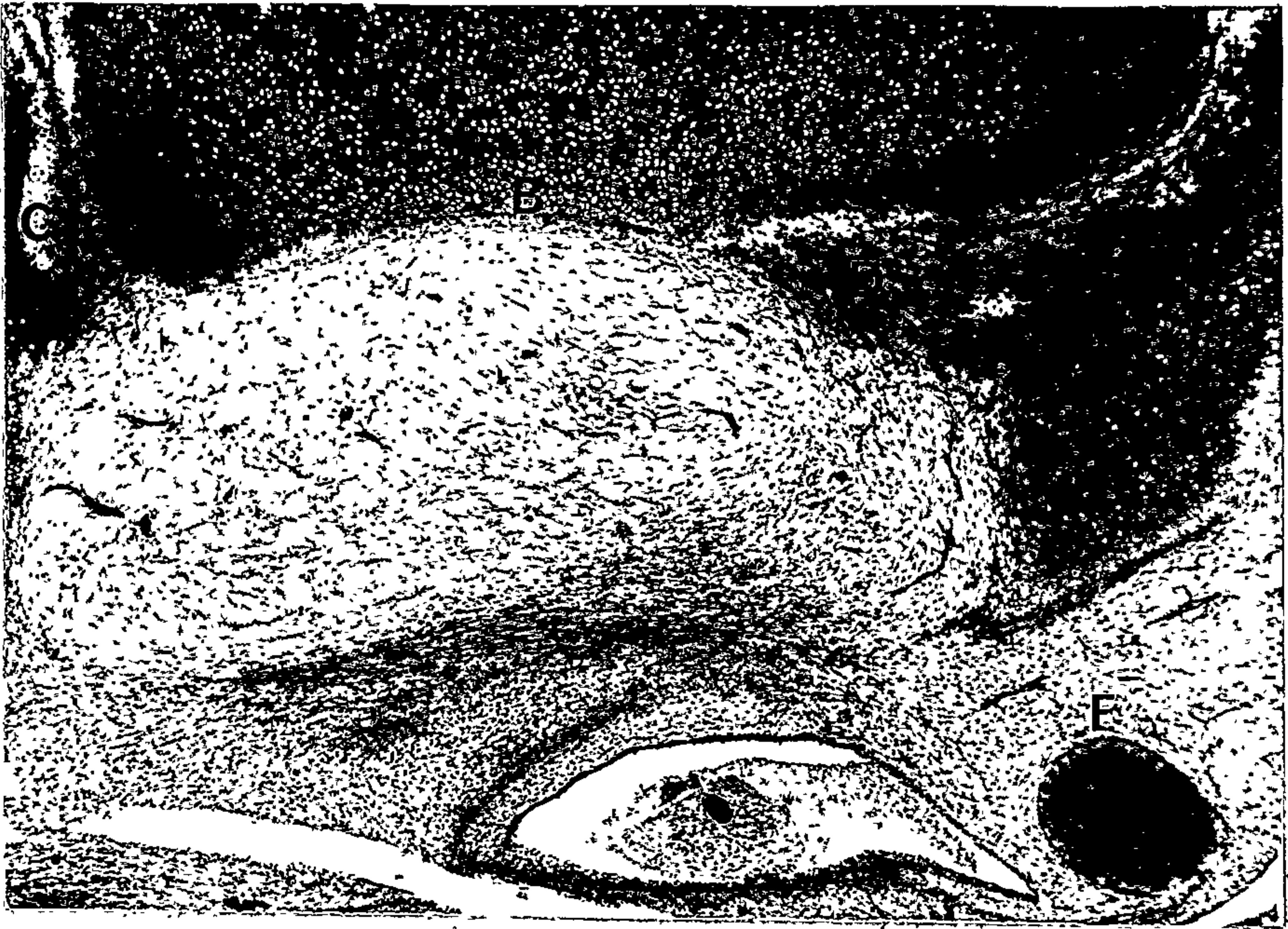

Figure 2-19. Middle ear compartment  
x 20 (H and E).

- A - Malleus
- B - Incus
- C - Stapes
- D - Joint capsule
- E - Meckel's cartilage

### III. Results - Coronal.

#### 1. Anatomy.

In coronal section it was seen that the temporomandibular joint, in the 16 week foetus, was placed more superiorly, than in the adult, relative to the floor of the middle cranial fossa (Figs. 2-20 and 2-21).

The condyle was separated from the temporal element of the joint by the meniscus of the temporomandibular joint. The lateral capsule of the joint was well formed and represented the lateral extension of the joint complex.

Medially, the meniscus was continuous with the lateral pterygoid muscle, which also gained an insertion into the medial border of the neck of the condyle. The fibres of the lateral pterygoid muscle were orientated in a medial and inferior direction, because of the superior position of the joint, at this stage. As the joint descended, with respect to the floor of the cranial fossa, the fibres of the lateral pterygoid muscle would attain the more horizontal orientation that was present in the mature joint complex. The medial pterygoid muscle was present in the region of the angle of the mandible and was orientated in an antero-superior direction (Figs. 2-20 and 2-21).

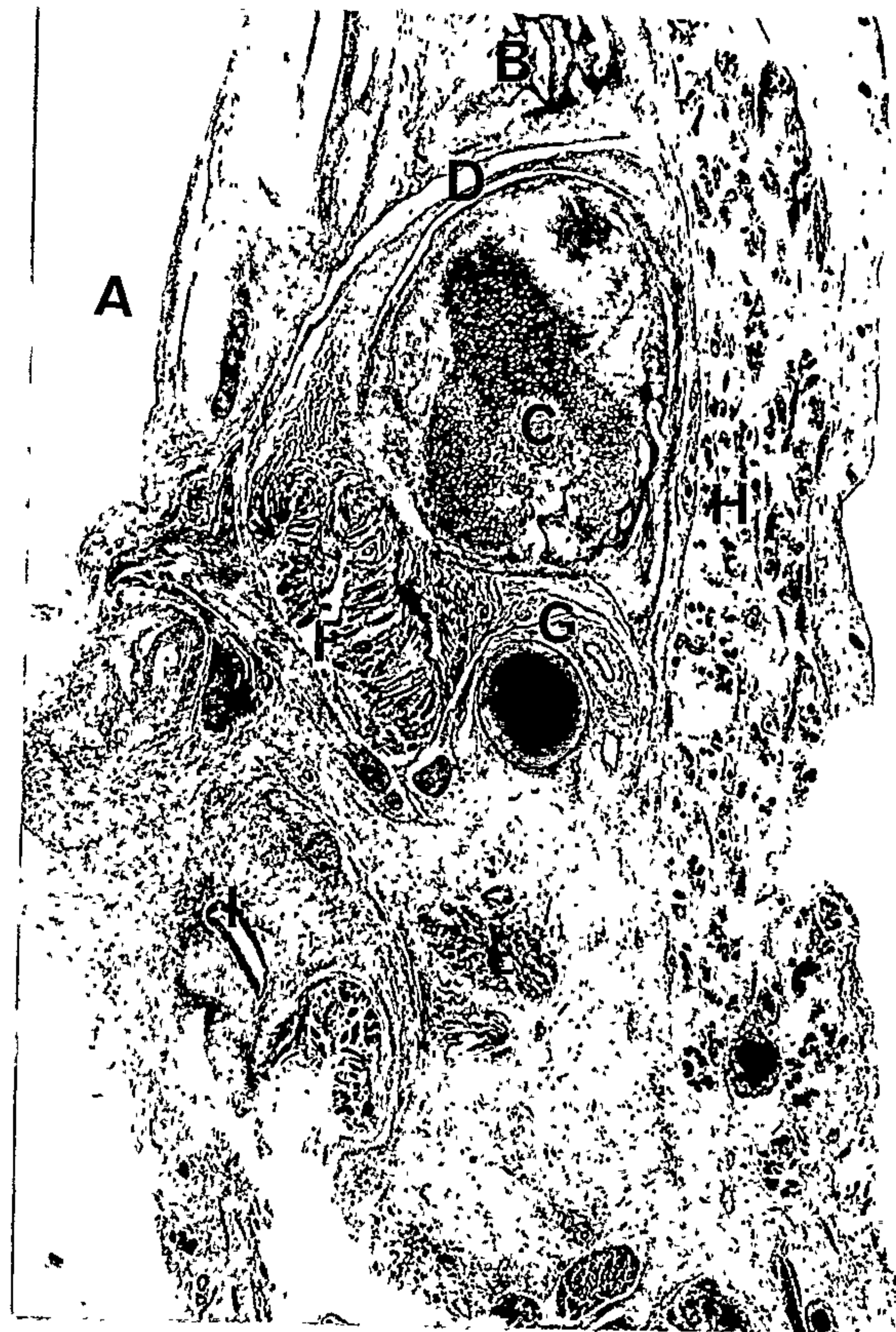
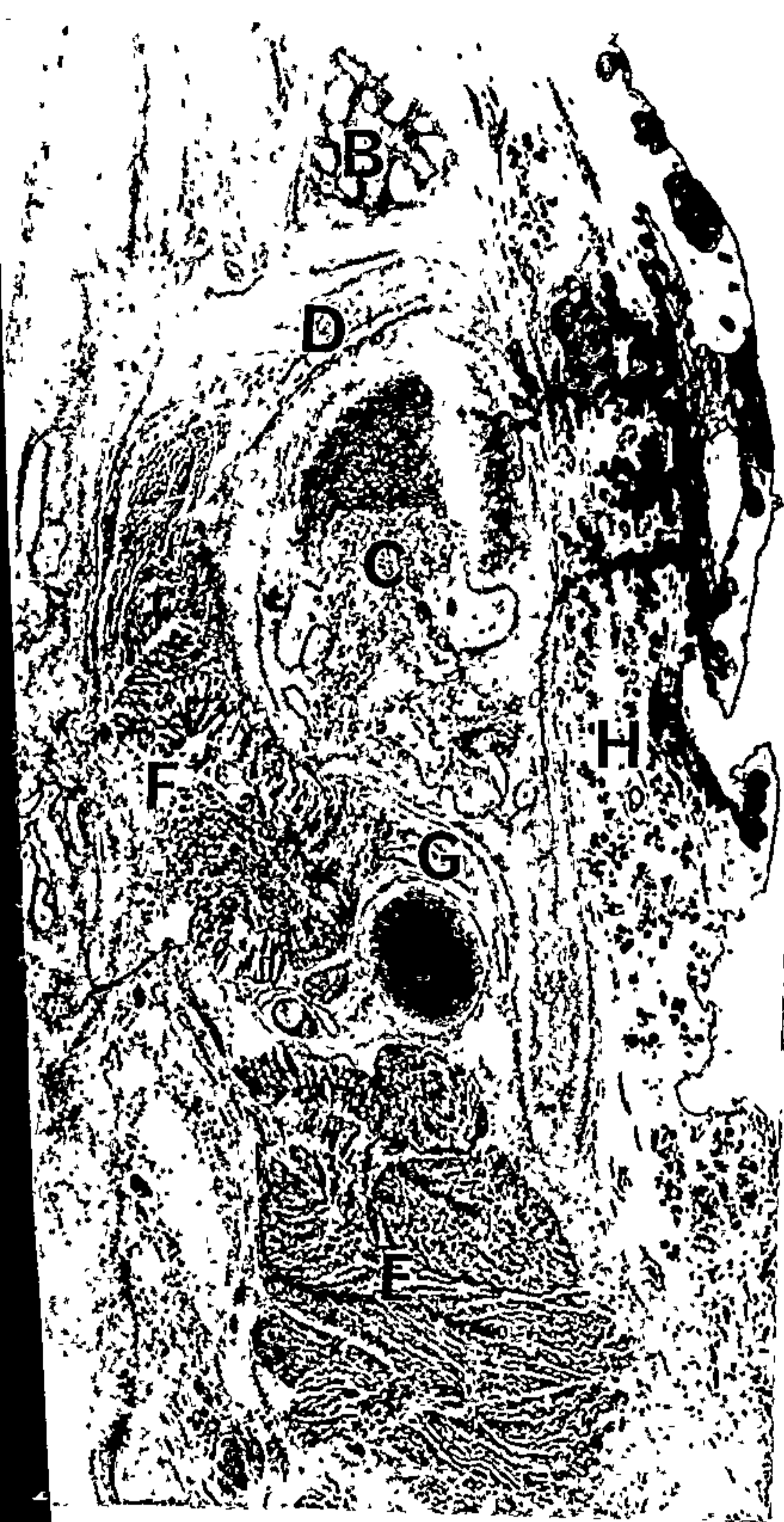

Figure 2-20

Figure 2-21

Coronal section of temporomandibular joint.

x 4 (H and E).

- A - Middle cranial fossa
- B - Temporal bone
- C - Condyle
- D - Meniscus
- E - Medial pterygoid muscle
- F - Lateral pterygoid muscle
- G - Meckel's cartilage
- H - Parotid gland
- I - Eustachian tube

The lateral aspect of the ascending ramus was covered by the parotid gland and externally was skin. Meckel's cartilage was directly inferior to the head of the condyle and was slightly ovoid in shape. In close proximity to the cartilage was the inferior alveolar nerve and vessels (Figs. 2-20 and 2-21).

## 2. Capsular Complex.

### A. Lateral Capsule.

The lateral capsule was seen to pass from the lateral surface of the immature mandibular fossa to the neck of the developing condyle (Fig. 2-22). In parts, it seemed not to be distinctly separated from the lateral surface of the meniscus. The lateral capsule consisted of fibrous tissue orientated in a supero-inferior direction. The lateral aspect of the capsule was associated with several blood vessels and small nerve bundles (Fig. 2-22).

### B. Medial Capsule.

In the 16th week the medial capsule had not yet differentiated, instead fibres of the lateral pterygoid muscle appeared to converge into the medial aspect of the meniscus (Fig. 2-23). The attachment of the meniscus to the condyle was much firmer than that to the temporal bone.



Figure 2-22. Lateral capsule x 240

( H and E ).

- A - Lateral capsule
- B - Meniscus
- C - Temporal articular surface
- D - Condylar articular surface
- E - Blood vessel
- F - Nerve fibre



Figure 2-23. Medial capsule x 240

(H and E).

- A - Meniscus
- B - Lateral pterygoid muscle
- C - Superior joint compartment
- D - Inferior joint compartment

### 3. Meniscus.

The meniscus lay between the lateral and medial capsule, and thus joined the two. The meniscus consisted of highly cellular fibrous tissue. The fibroblasts were orientated antero-posteriorly, such that in coronal section the cells appeared ovoid in shape (Fig. 2-24), in contrast to the elongated shape that was evident in the sagittal sections. Between the cells and fibres were numerous voids that were reminiscent of capillary type blood vessels.

Along the superior surface of the meniscus was a fibrous type of synovial membrane. On the inferior surface was a one cell layer of cuboidal type synovial cells that represented the synovial membrane in that area (Fig. 2-24).

### 4. Articular Surface of the Temporal Bone.

The articular surface of the temporal bone was formed by a meshwork of trabeculae (Fig. 2-25). Osteocytes were seen in their lacunae within the bone, and osteoblasts were in contact with the bone (Figs. 2-25 and 2-26).

The periosteum that covered the surface of the bone was thick and was comprised of two distinct layers. The inner layer had few cells (Fig. 2-26), whereas the outer layer was highly cellular (Fig. 2-27).

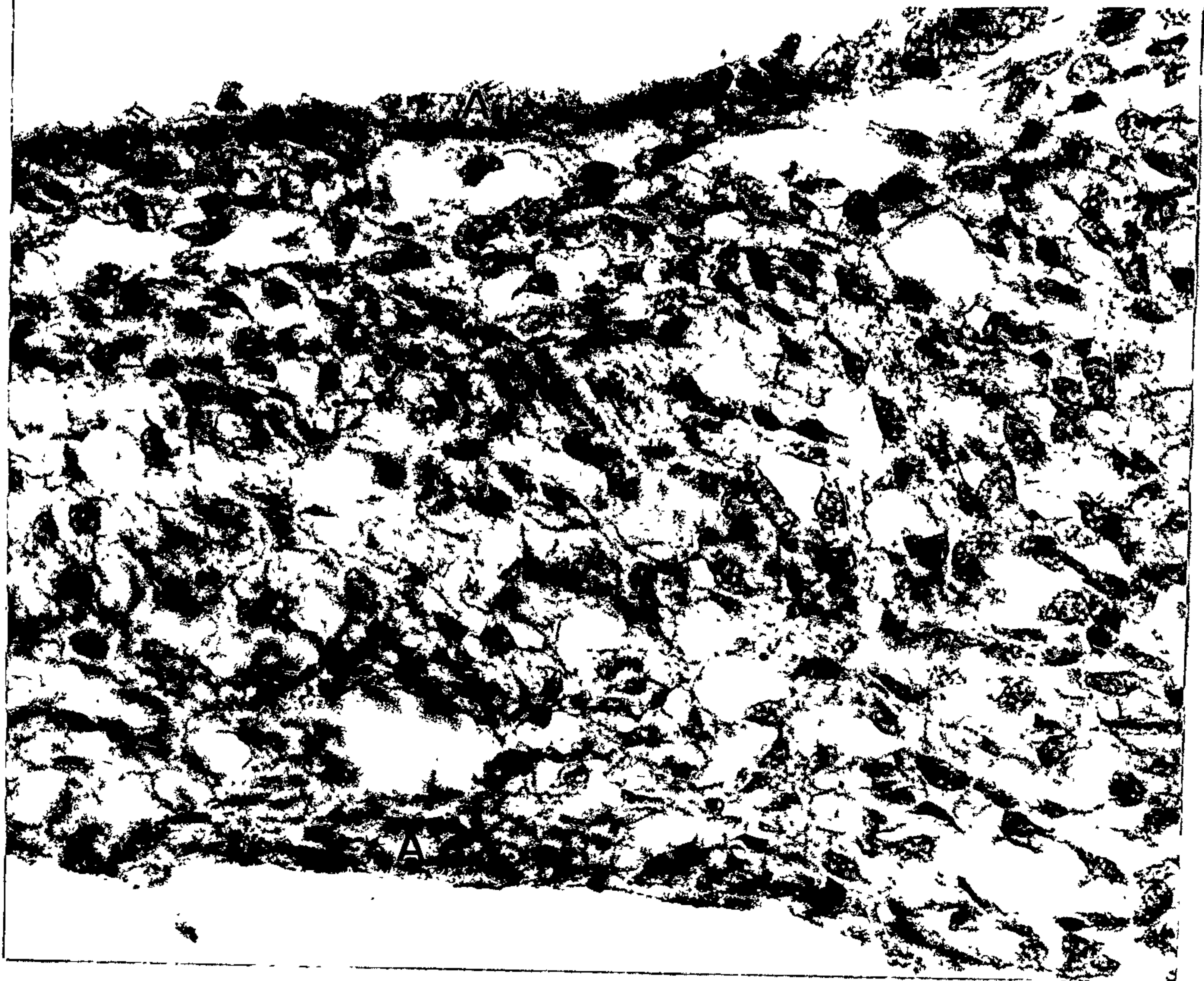

Figure 2-24. Central region of the Pars posterior menisci x 960 (H and E).

A - Synovial membrane

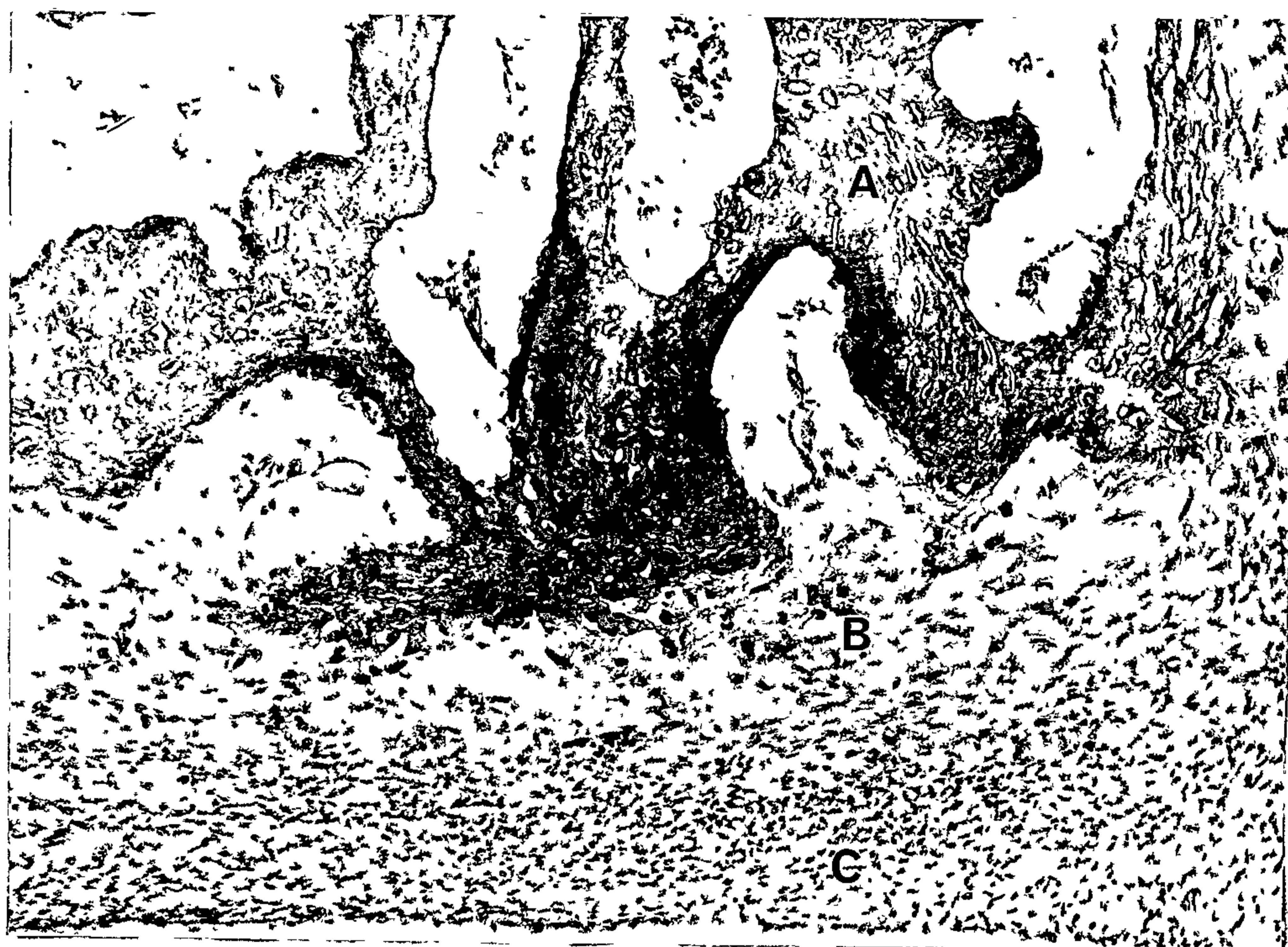

Figure 2-25. Periosteum of the temporal bone.  
x 240 (H and E).

- A - Calcified temporal bone
- B - Cellular periosteum
- C - Fibrous periosteum




Figure 2-26. Fibrous layer of periosteum attached to the temporal bone x 960 (H and E).

- A - Calcified bone with osteocytes
- B - Osteoblast
- C - Capillary

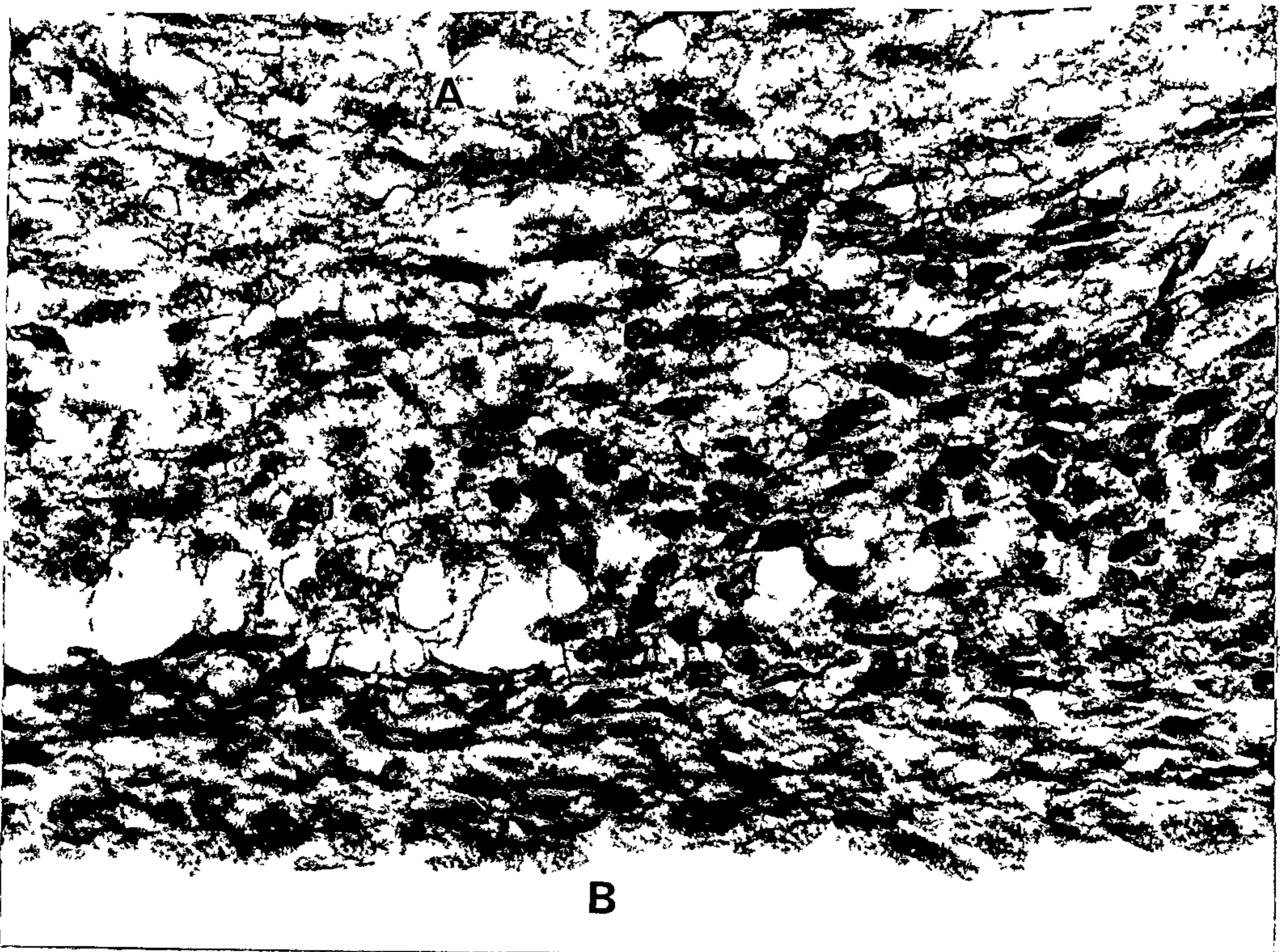


Figure 2-27. Cellular layer of periosteum of the articular surface of the temporal bone x 960 (H and E).

- A - Capillary
- B - Superior joint compartment

The fibres of the inner layer appeared to be randomly orientated except in the area that was in close proximity to the bone surface. The tissue that formed the attachment to the bone was highly fibrous and was attached to the temporal bone by Sharpey's fibres. The outer layer of the periosteum possessed many randomly orientated fibroblasts except in the surface layers where the fibroblasts had an antero-posterior orientation. Capillary type vessels, were more numerous in the outer layer than the inner layer of the periosteum.

#### 5. Articular Surface of the Condyle.

The articular surface of the condyle in coronal section, was similar to that seen in the sagittal section, except for the different shapes of the cells, resulting from the different plane of section.

#### A. Perichondrium.

The surface of the condyle was covered by a thin layer of highly cellular tissue that was orientated in the antero-posterior direction (Figs. 2-28 and 2-29). Beneath the perichondrium were many vascular canals. These vascular canals were found exclusively in this region, and indicated the upper layers of the presumptive hyaline cartilage (Figs. 2-28 and 2-29).




Figure 2-28. Perichondrium x 240 (H and E).

- A - Meniscus
- B - Perichondrium
- C - Presumptive hyaline cartilage
- D - Zone of young and resting chondrocytes
- E - Zone of flattened chondrocytes
- F - Zone of hypertrophic and degenerate chondrocytes
- G - Tongue-like intrusion of young and resting chondrocytes
- H - Vascular canal




Figure 2-29. Perichondrium x 480

(H and E).

- A - Perichondrium
- B - Presumptive hyaline cartilage
- C - Zone of young and resting chondrocytes
- D - Zone of flattened chondrocytes
- E - Vascular canal

### B. Zone of Young and Resting Chondrocytes.

A zone of young and resting chondrocytes lay immediately inferior to the presumptive hyaline cartilage. In some areas this zone was narrow and indistinct (Fig. 2-29), whereas in other areas this zone contributed to tongue-like projections into the substance of the condylar head (Fig. 2-28).

### C. Zone of Flattened Chondrocytes.

A zone of flattened chondrocytes was evident below the young and resting chondrocytes. The thickness of this layer varied greatly. In some regions it was only two or three cells thick (Fig. 2-30), whereas in other regions it was of considerable thickness where the tongue-like projections were present. The inferior limit of the zone was identified by a zone of hypertrophic and degenerate chondrocytes (Fig. 2-29 and 2-30).

### D. Zone of Hypertrophic and Degenerate Chondrocytes.

A zone of hypertrophic and degenerate chondrocytes was easily identified by the characteristic calcification around the cells (Figs. 2-30, 2-31 and 2-32). This layer did not form a uniform strip across the condylar head because of the tongue-like projections from above, and also because of the erosion of its lower surface by the tissue below (Fig. 2-32).

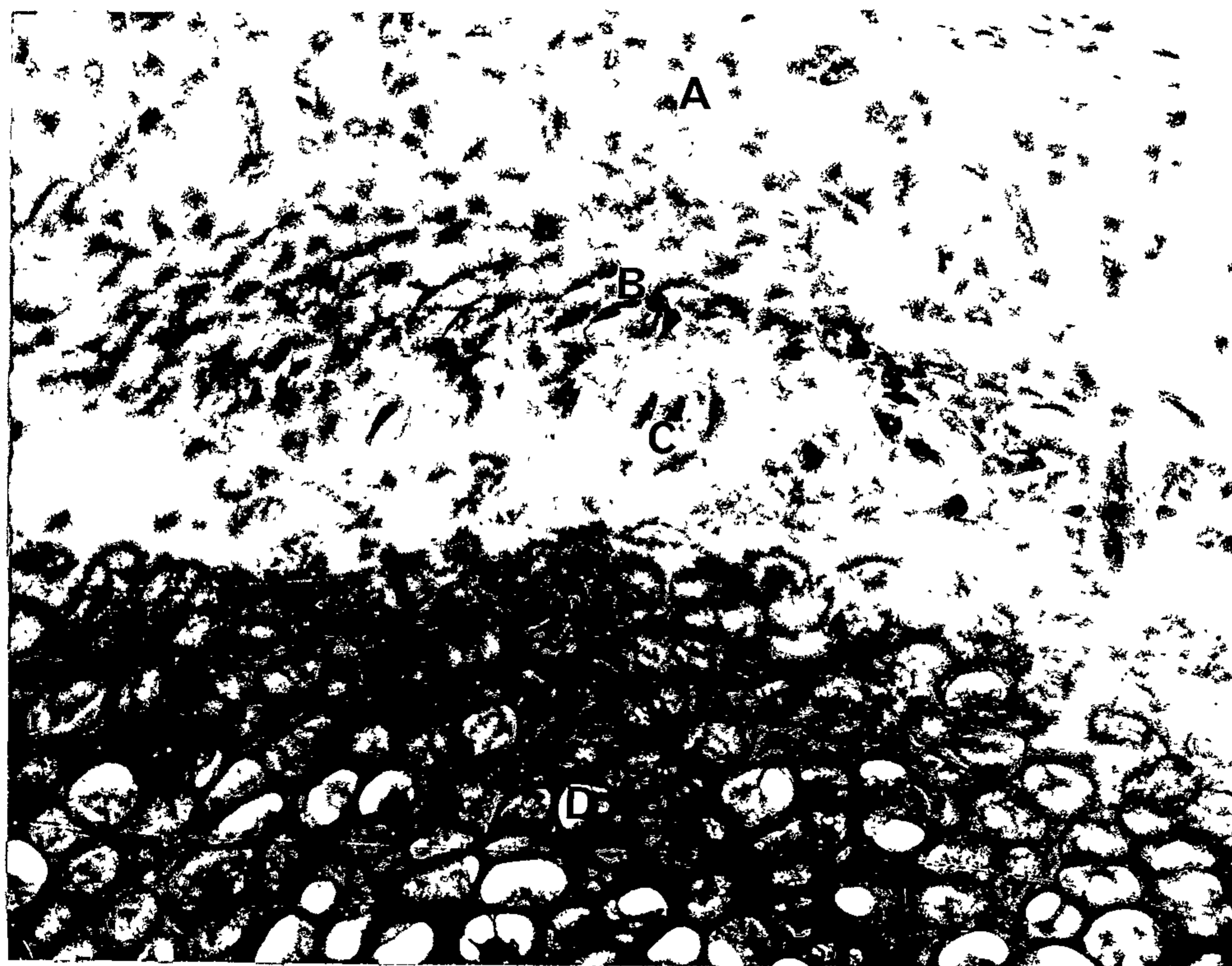


Figure 2-30. Secondary cartilage x 240  
(H and E).

- A - Presumptive hyaline cartilage
- B - Zone of young and resting chondrocytes
- C - Zone of flattened chondrocytes
- D - Zone of hypertrophic and degenerative chondrocytes

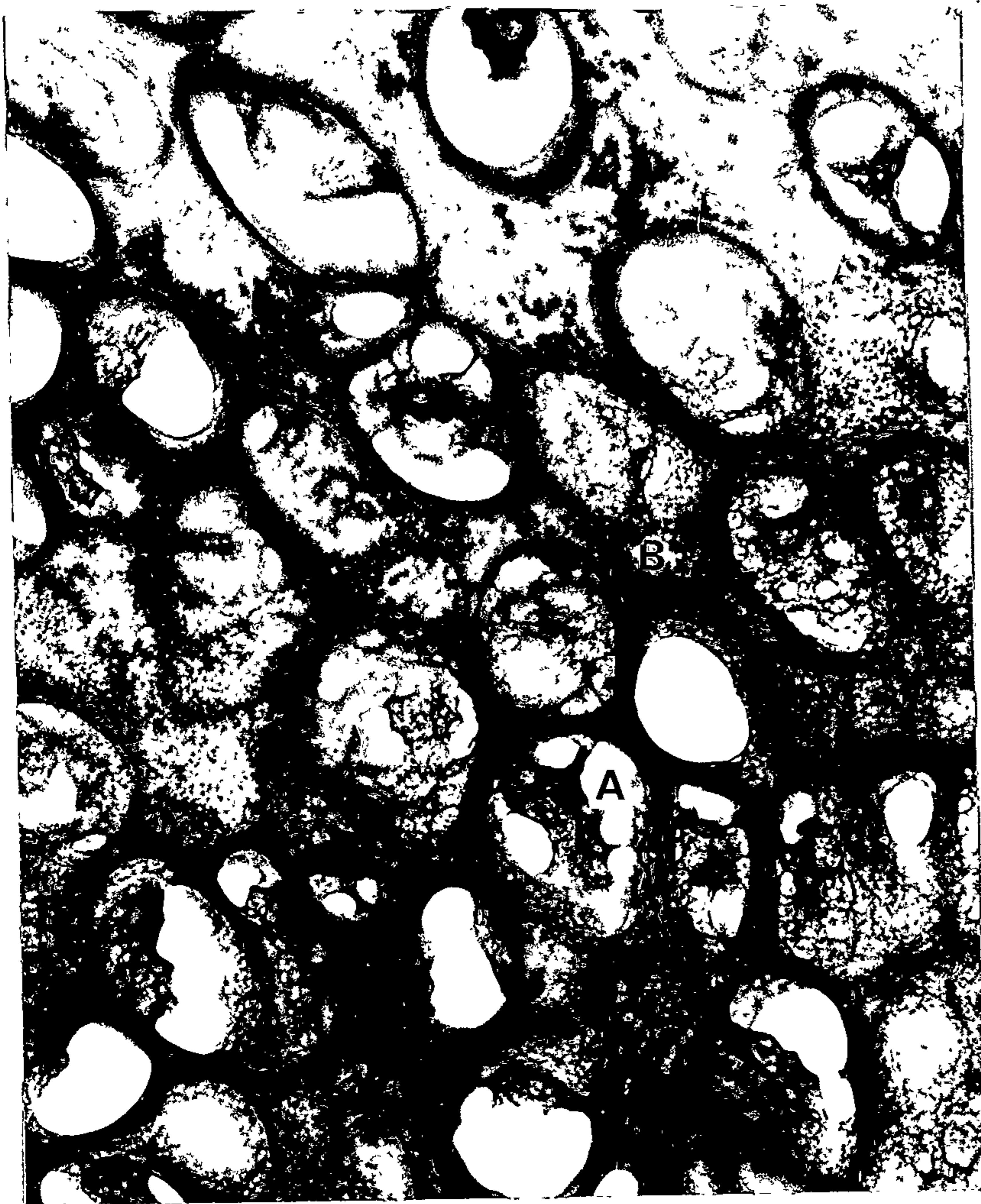


Figure 2-31. Degenerate chondrocytes  
x 960 (H and E).

- A - Degenerate chondrocyte
- B - Calcification

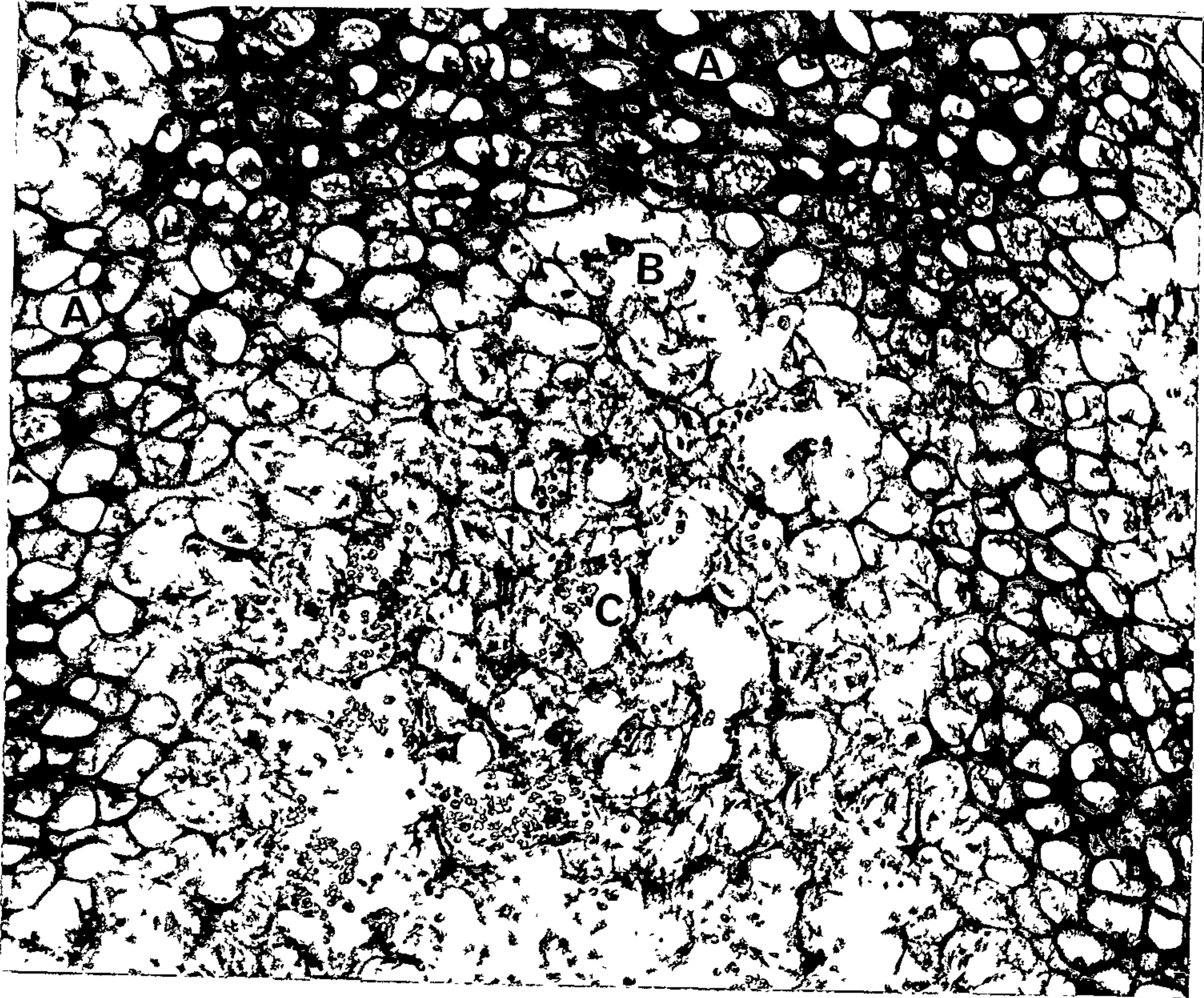


Figure 2-32. Irruption of secondary cartilage and bone deposition x 240 (H and E).

- A - Zone of hypertrophic and degenerate chondrocytes
- B - Zone of bone deposition
- C - Osteogenic mesenchymal cells

### E. Zone of Irruption and Bone Deposition.

A zone of irruption and bone deposition formed protrusions up into the hypertrophic and degenerate chondrocytes (Fig. 2-32). Inferior to the zone of irruption the primary endochondral trabeculae, which provided the framework for the formation of the endochondral trabeculae, were formed.

### 6. Remodelling of Condylar Neck.

Even at the early age of 16 weeks remodelling of the condylar neck was evident (Fig. 2-33). The endochondral bone of the condylar neck contained many osteocytes, while several large osteoclasts were observed on the external margin of the lateral condylar neck. These osteoclasts were seen to lie in Howships lacunae and represented the cellular layer that had been noted in the sagittal sections (Fig. 2-16). External to this layer was the fibrous layer of the periosteum which was in contact with the pericondylar tissue.

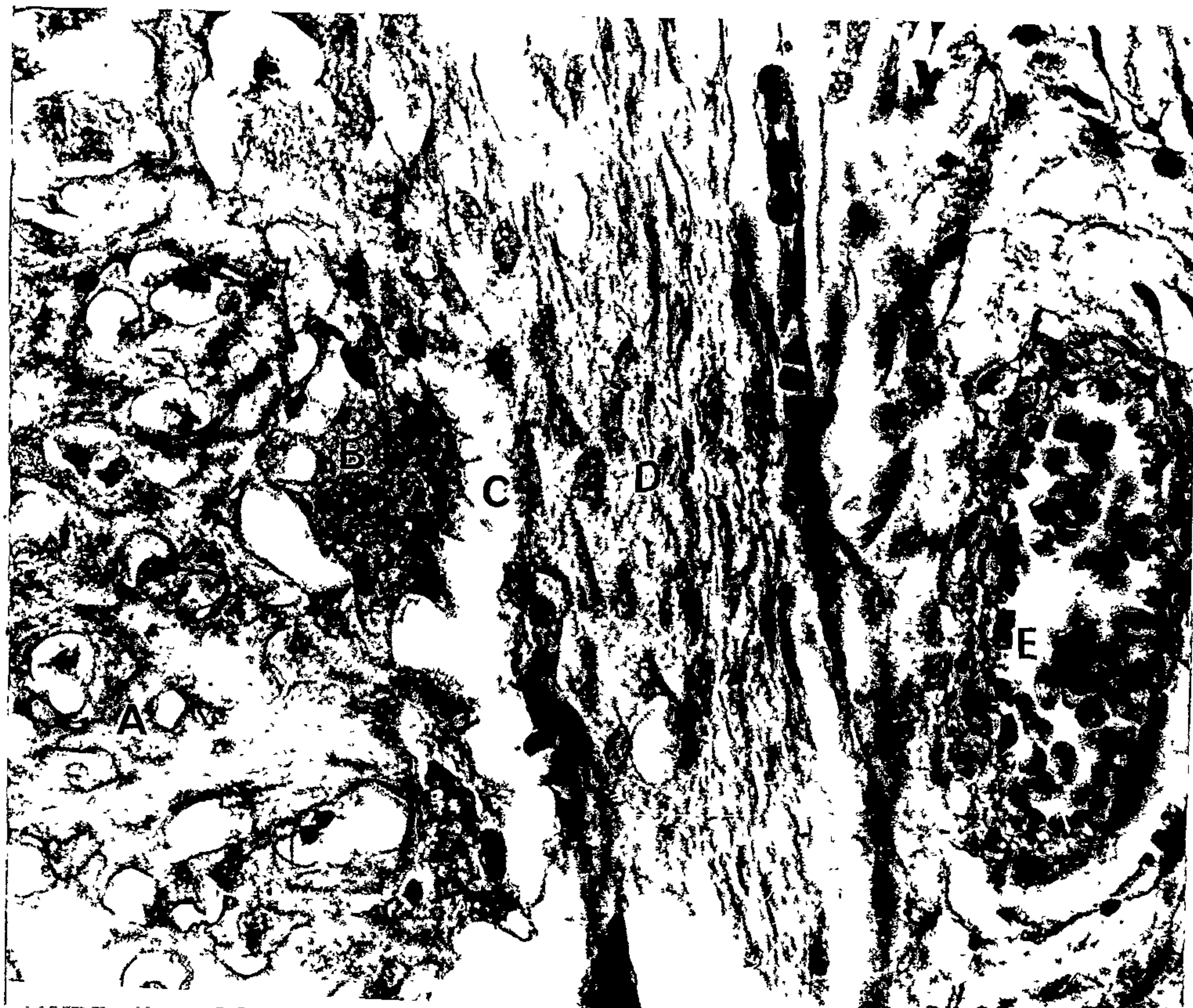


Figure 2-33. Remodelling of lateral condylar neck  
x 960 (H and E).

- A - Neck of condyle with osteocytes
- B - Osteoclast
- C - Cellular layer of periosteum
- D - Fibrous layer of periosteum
- E - Blood vessel

#### IV. Discussion,

At the 16th week of foetal life, all the elements of the temporomandibular joint complex were present. The meniscus was formed and the superior and inferior joint compartments were established. The lateral capsule was almost defined whereas the medial capsule had not differentiated, with the result that the lateral pterygoid muscle was in intimate contact with the medial aspect of the meniscus.

All the surfaces of the meniscus were lined by an areolar cell rich type of synovial membrane. Of particular interest was the cell density of all parts of the meniscus.

Condylar growth, by secondary cartilage, was quite apparent and all the zones seen in growing long bones were present, with the exception that a definite or presumptive epiphysis was not apparent.


The cytomorphosis of the cells of the secondary cartilage was similar to that found in the metaphysis of the long bones. The irregularities in the various layers of chondrocytes appeared to be due to the tongue-like protrusions of the young and resting chondrocytes into the deeper layers of the condyle. However, condylar secondary cartilage was similar to the growth centres found in the long bones,

presumptive epiphysis was not present.

The petro-tympanic fissure was very wide in the 16th week foetus. A band of fibrous tissue was seen to travel from the posterior part of the meniscus of the temporomandibular joint, through the fissure, to mingle with the tissue that filled the middle ear cavity. The contents of the fissure were in intimate contact with the periosteum, of the temporal bone, but it was not possible to observe adhesion between these two structures.

Chapter 3The Embryology of the HumanTemporomandibular Joint.ContentsPage.

I	Introduction	79.
II	Embryology	80.
III	Articular Disc (Meniscus)	86.
IV	Discussion	88.



## Chapter 3.

### The Embryology of the Human Temporomandibular Joint.

#### I. Introduction.

The embryonic development of the human temporomandibular joint differs considerably from other joints in the body, thus reflecting its more complicated evolutionary history. GAUPP (1911) indicated that the temporomandibular joint developed late in the evolutionary process and was a distinguishing feature of mammals.

Most synovial joints in the body had completed their initial cavitation by the 7th week of intra-uterine life, whereas the temporomandibular joint had scarcely begun to develop at that stage (SPERBER, 1973). Whereas limb joints develop directly into their adult form by cavity formation, within the single blastema from which both adjoining endochondral bones develop, the temporomandibular joint developed from initially widely separated bony elements that grew towards each other (SPERBER, 1973). Further contrast with the other synovial joints related to the presence of fibrocartilage, rather than hyaline cartilage, on the articular surface of the temporal glenoid fossa and mandibular condyle (LAST, 1966).

On the condyle this fibrocartilage acted as a growth for the mandible (ORBAN, 1972 ).

When studies related to embryology are compared there are always minor variations in the descriptions related to the times of appearance, or development, of different structures (Appendix 8). In the first instance some variations may result from two embryos, or fetuses, of the same crown-rump length, not having reached the same degree of development. Other discrepancies can be attributed to the inadequacies of methods used for age determination of embryos and fetuses. Also slight variation in age may occur if the crown-rump length of the embryo and fetus is determined before or after fixation (HAMILTON, et al 1959). In order to standardise the findings expressed by the different authors all C-R lengths have been related to PATTEN (1948) (Appendix 8).

## II. Embryology.

SYMONS (1952), BAUME (1962a,b), FURSTMAN (1963) and YUODELIS (1966) indicate that the temporomandibular joint developed from two separate regions the condylar and temporal blastemata.

The condylar blastemata gave rise to the condyle while the temporal blastemata formed the glenoid fossa of the joint, and the intervening tissue provided the primordium of the articular disc of the joint.

The condylar and temporal blastemata developed in different planes, the temporal blastemata always being more superior, posterior and lateral to the condylar element (YUODELIS, 1966; BAUME and HOLZ, 1970). However, as the areas differentiated, the two blastemata moved into a position, where they could constitute the joint.

The condylar and temporal (glenoid) blastemata regions were composed of condensed areas of undifferentiated mesenchyme cells, surrounded by unorientated cells (BAUME, 1962 a,b; FURSTMAN, 1963; YUODELIS, 1966).

The joint began to develop during the 6th week of intrauterine life (SYMONS, 1952; BAUME, 1962 a,b; FURSTMAN, 1963; YUODELIS, 1966; BAUME and HOLZ, 1970). The first evidence of the formation of the mandible occurred in the 14 mm C-R embryo (6½ week) (FURSTMAN, 1963; YUODELIS, 1966). At that time small areas of membranous bone formation were present lateral to Meckel's cartilage, in the anterior 1/3 rd of the mandible (FURSTMAN, 1963; YUODELIS, 1966), and there was

slight condensation of mesenchyme in the temporal region (YUODELIS, 1966).

The condylar process could be recognised in the seventh week, by the insertion of the external pterygoid muscle into the terminal part of the mesodermal condensation. This mesodermal condensation was situated some distance from the region of bone formation that was evident in the mandible. (SYMONS, 1952; YUODELIS, 1966). This primordial condyle lay dorsosuperiorly to the primordial ramus (YUODELIS, 1966).

By the eighth week of prenatal life the membranous bone of the mandible had increased markedly in size, both in the antero-posterior and supero-inferior direction and had penetrated the condylar process.

This bone formation was lateral to Meckel's cartilage and corresponded with the future bone core of the mandible. Ossification of the temporal region of the joint was also present at that time (SYMONS, 1952; FURSTMAN, 1963; YUODELIS, 1966), and a band of fibrous cells had begun to form a cap over the primordial condyle (SYMONS, 1952; YUODELIS, 1966).

SYMONS (1952), FURSTMAN (1963) and YUODELIS (1966) noted a marked condensation of mesenchyme at the superior aspect of the bone core of the membranous bone, by the tenth week. This condensation of mesenchyme had formed into a spherical shape, to be the precursor of the condyle.

Embryonic cartilage was also found in this region (SYMONS, 1952; FURSTMAN, 1963). YUODELIS (1966) indicated that a highly condensed area of fibrous tissue also covered the articular surface of the condyle. Probably the most significant development during the 10 week stage was the first indication of the inferior joint cavity (SYMONS, 1952; YUODELIS, 1966), whereas FURSTMAN (1963) did not observe this until the twelfth week. During the tenth week the attachment of the lateral pterygoid muscle was more evident and the muscle fibres were orientated in a superior direction, because the condyle had not reached its mature superior position at that stage.

In contrast to all the other authors MACALISTER (1955) did not observe any development of the temporomandibular joint until the 10th week. Although the temporal blastemata was evident in the sixth week, the condylar blastemata was not evident until the seventh week (YUODELIS, 1966). Once the condylar blastemata had developed it differentiated at a greater rate than the temporal structure, such that the two areas reach their respective positions about the 12th week (BAUME, 1962 a,b; FURSTMAN 1963; YUODELIS, 1966). Between the tenth and twelfth weeks ossification of the mandible began from several secondary cartilaginous growth centres (YUODELIS, 1966).

One of these centres was on the condyle. It grew rapidly during that period to dramatically reduce the primordial articular space. This cartilaginous growth centre in the condyle played an important part in the growth of the condylar process by appositional growth.

As with the inferior joint cavity, the superior joint cavity formed from a series of clefts in the mesenchyme between the developing condyle and glenoid fossa. SYMONS (1952) and YUODELIS (1966) found that the superior joint cavity was evident by the twelfth week, whereas FURSTMAN (1963) claimed that the inferior joint cavity made its appearance at that time and that the superior joint cavity was not evident until the fourteenth week.

The greatest changes in the joint region occurred between the 10th and the 12th weeks, during which time the condylar and temporal units came into their correct relationship. After the compartment parts of the joint had been established, by the 14th week, no further changes occur within the joint; except for an increase in size (FURSTMAN, 1963). At about that time interstitial and appositional growth of the condyle was supplemented by endochondral bone formation (YUODELIS, 1966). The attachments of the masseter and internal pterygoid muscles were noted, by FURSTMAN (1963), to occur concurrently with the appearance of the endochondral bone formation.

The condyle continued to have rapid embryonic cartilage growth, as well as continuous endochondral bone formation until maturity, at the age of about 20 years. This growth allowed for an increase in the size of the condyle and for an elongation of the ramus of the mandible.

During the growth and maturation of the condyle, the glenoid fossa was developing at a similar rate to that of the condyle, such that the intramembranous bone formation in the temporal region had produced a well formed glenoid fossa by the 22nd week (FURSTMAN, 1963). At that time the meniscus had assumed its characteristic shape and consisted of dense fibrous tissue (FURSTMAN, 1963). The condyle grew by interstitial and appositional growth of cartilage and endochondral bone formation, whereas the glenoid fossa grew by membranous bone formation (MOFFETT et al 1964).

### III. Articular Disc (Meniscus.).

From an investigation of primitive mammalian embryos, GAUPP (1911) inferred that the homologue of the external pterygoid muscle, lay between the condylar and squamous elements of the developing joint and inserted into the dorsal end of the malleus. He postulated that this muscle, having been trapped by the developing condyle, gave rise to the articular disc. SYMONS (1952) and MOFFETT (1957) & (1962) supported this concept but FURSTMAN (1963), YUODELIS (1966) and BAUME and HOLZ (1970) have provided histological evidence to show that the external pterygoid did not form the primordium of the articular disc.

BAUME (1962 a,b) attributed the formation of at least the anterior part of the meniscus, the condylar cartilage, the aponeurosis of the external pterygoid muscle, and the capsular elements of the lower joint cavity to the dorsally developing condylar blastemata. He suggested that the ventrally developing temporal blastemata contributed to the articular structures of the superior joint cavity.

The primordial disc was found by BAUME (1962 a,b) and YUODELIS (1966) to be distinct, long before the skeletal elements were approximated. This contrasted with the observations of GAUPP (1911), SYMONS (1952) and MOFFETT (1957, 1962) who all suggested that the articular disc was developed from condensation of the external pterygoid muscle between the developing condyle and glenoid fossa. In the eighth week YUODELIS (1966) noted the formation of a band of fibrous cells above the condylar blastemata, below which during the tenth week he observed the formation of the clefts, that later formed the inferior joint space.

YUODELIS (1966) suggested that the central avascular part of the meniscus may be derived from the condylar blastemata, while the vascular mesoderm surrounding the interzone accounted for the anterior rim of the disc, the retrodiscal pad, the capsule, and the synovial membrane. GARDNER and GRAY (1953) and BARNETT et al (1961) both agreed that the intra-articular ligaments developed from the vascular mesenchyme that surrounds the primordial joint.