

Scanning Electron Microscopy of Developing Roots of Molar Teeth of the Laboratory Rat¹

K. S. LESTER AND A. BOYDE

*University College London, London W.C. 2, U.K., and Anatomy Department,
New York Medical College, New York, New York 10029*

Received January 13, 1970

Molar teeth of young rats were rendered anorganic and their developing roots were examined with the scanning electron microscope. It was possible to compare the morphology and ultrastructure of advancing root edges in various stages of development. It was found that the roots of any one tooth develop asynchronously and that the structure and composition of the tissues at the advancing edge of any one root alter in a characteristic way as development proceeds. The latter is due, in part, to the formation of a deep cleft which separates dentine and cellular cementum, and, in part, to the gradual overtaking of dentine by an increasing bulk of cellular cementum. The extensive, primary cleft is ultimately replaced by numerous, small, irregular clefts during closure of the root "apex." The findings add the necessary third dimension to present understanding of root formation in rat molars and emphasize the atypical nature of this process.

Raised developmental "seams" were found on all molars examined, extending over the undersurface of the crown and the contiguous (interradicular) surface of the roots. These seams would not be resolvable in their entirety by any other method presently available.

The role played by Hertwig's epithelial root sheath in cleft formation, and its likely role in seam formation is discussed.

Electron microscopic studies have shown that cells of Hertwig's epithelial root sheath are embedded between the advancing fronts of dentine and cementum during the phase in which cellular cementum is formed (7, 8). This means that the structural configuration of the mineralized tissues at the advancing edge during this mode of root formation is profoundly different from that normally encountered in mammalian teeth (12, 15). The study of rat molar root development therefore offers the investigator information concerning the formation and nature of dentine and cementum which, so far as we are aware, is not available from the study of other mammalian systems.

¹ This study was made possible by a grant from the U.K. Science Research Council, and was carried out in the Anatomy Department, University College London.

It is difficult to reconstruct the complex shape of the developing rat molar root from the study of thin sections by transmission electron microscopy. It is essential to have a more direct mode of electron microscope examination permitting sampling of intact specimens if one is to visualize the mineralized components of the developing roots in three dimensions—we regard this as necessary to a more complete understanding of the formative process. To this end, developing molar teeth of rats of suitable ages were rendered anorganic and their roots were examined directly with the scanning electron microscope.

MATERIAL AND METHODS

Sprague-Dawley rats were sacrificed so as to provide a developmental series from age 20 days to age 55 days after birth. The head and jaws were removed and fixed in 10 % neutral buffered formalin. The molar teeth were retrieved from their bony sockets by immersing the unflensed jaws in a 5 % solution of sodium hypochlorite (NaOCl) for 48 hours. There is no visible evidence of organic material at the end of this time and, in most instances, the molars have fallen free from their bony sockets. Some dissection of the anorganic tooth-bearing bone was needed in order to free individual teeth in some of the older specimens in which the roots had attained a greater length. The teeth were then carefully and extensively washed in warm running water to remove the remaining NaOCl, which would otherwise form crystals after drying and thus obscure the specimen surface. The teeth were dehydrated through a graded ethanol series, the ethanol was replaced with diethyl ether, and then the teeth were finally air-dried from the ether. The teeth were then glued to aluminum specimen stubs with the crown facing down so as to leave the roots standing free. Other specimens were fixed (in this same orientation) with a stiff colloidal carbon gel (Aquadag) to specially prepared carbon specimen stubs. The teeth were coated in a vacuum evaporator with ca. 200 Å carbon and ca. 300 Å gold, and examined in a scanning electron microscope (SEM—Cambridge Instrument Co. Stereoscan operated at 3 kV).

The undersurface of rat molars is such that considerable variation exists in the height and slope of specimen surfaces presented to the electron collector in the SEM. To help overcome the resulting preferential collection of electrons from some specimen surfaces, aluminum foil was adapted about the specimen so that it lay in a large “hole,” separated from the direct “line of sight” of the electron collector.

All six molar tooth-types were examined. Attention was, however, focused on the lower (right) 1st molar, partly because it was used in previous transmission electron microscope studies (7, 8), and partly because detailed examination of one tooth-type simplifies the direct comparison of different developmental stages.

OBSERVATIONS

A small, mineralized specimen such as an anorganic rat molar so lends itself to examination in the scanning microscope that a single image may be formed in which all developing roots are represented. It is apparent in such low magnification images

that the developing roots of any one tooth vary with respect to their degree of completion—generally, the smaller the root in any one tooth, the closer it is to completion (Fig. 1). Furthermore, there is an obvious lack of uniformity in the morphology of the advancing edge of any one developing root (Figs. 1 and 2). It is on this latter feature that we wish to concentrate in the present report.

It is worth emphasizing that only the mineral component of the teeth was available for examination. Thus, advancing edges of developing roots, when prepared in the manner described, are made up of the mineralized parts of cellular cementum on the external (periodontal) side (Fig. 3) and of dentine on the internal (pulpal) side (Fig. 4). The cellular cementum exhibits many depressions which, with their accompanying canaliculi, represent the sites of incorporation (forming lacunae) of the parent cells (Fig. 3). The rugged mineralizing front of the dentine (or predentine-dentine border) faces pulpally (Fig. 4). There is commonly a cleft between cellular cementum and dentine. The surfaces of the cementum and dentine forming the walls of the cleft are relatively smooth (Figs. 3 and 4).

Three features of the developing roots will be considered here:

- (i) the morphology of the advancing root edge;
- (ii) the morphology of the mineralizing fronts of dentine and of cellular cementum about the root edge; and

Key to abbreviations

<i>cc</i> mineralizing front of cellular cementum <i>cl</i> cleft (representing site of incorporation of Hertwig's epithelial root sheath cells) <i>d</i> mineralizing front of dentine	<i>l</i> cementocyte lacunae <i>p</i> developing pulpal cavity <i>s</i> developmental seam
---	--

All figures are scanning electron micrographs of anorganic developing rat molars taken at 3 kV (except Fig. 1 at 10 kV). Figs. 5, 14–16, 19–21, and 28 are stereo pairs (tilt angle 10°).

The easiest method of viewing the paired images stereoscopically is by means of a simple stereoviewer (available commercially) which consists of two lenses held at their focal distance from the images. The distance between the lenses should correspond to the interocular width of the observer. The use of the lenses relaxes the focus of the eyes to infinity when the viewing axes of the eyes also become parallel. With some practice, it is possible to separate the functions of focus and of convergence of the eyes so that the paired images may be seen stereoscopically without the aid of a viewer.

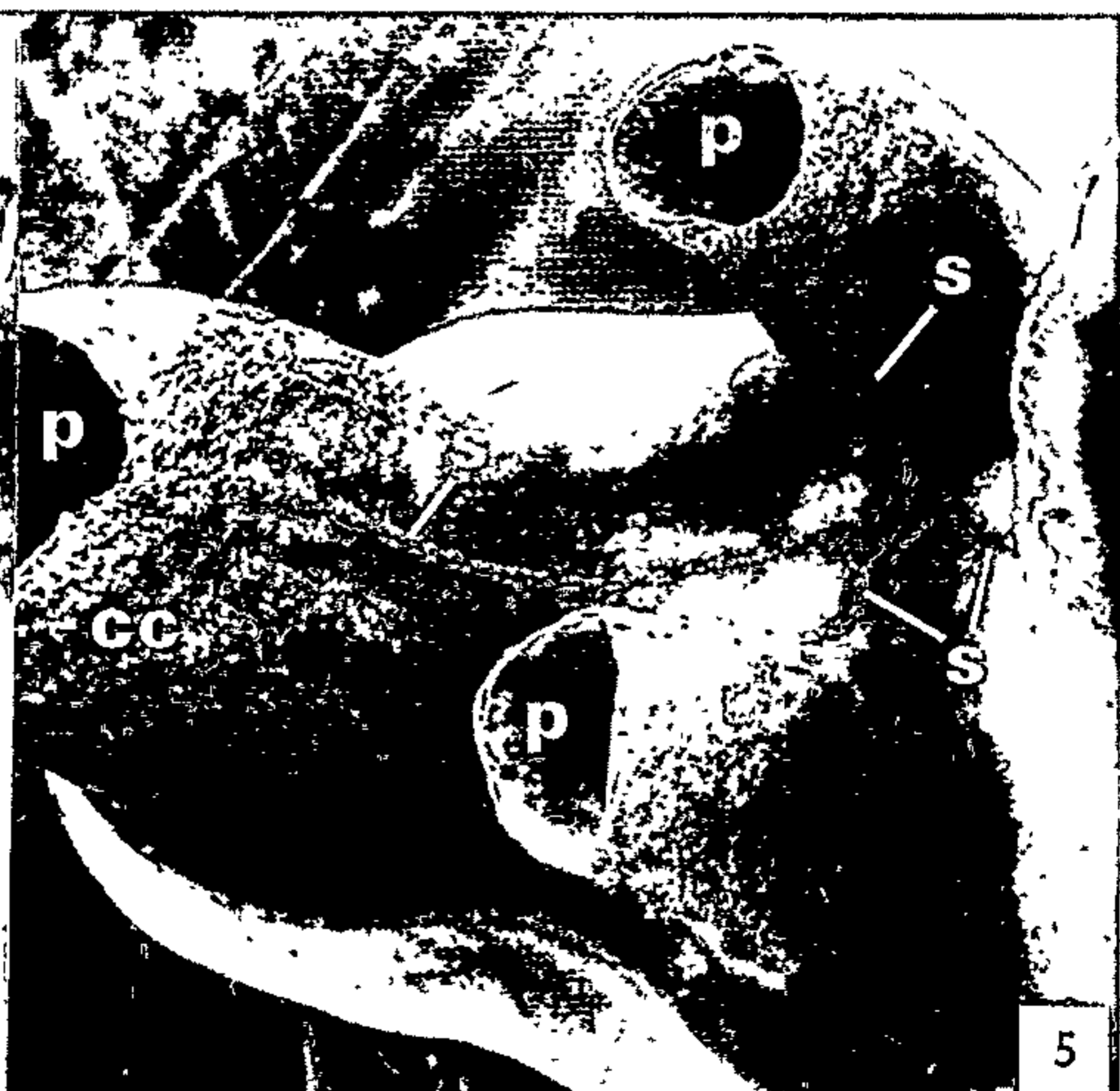

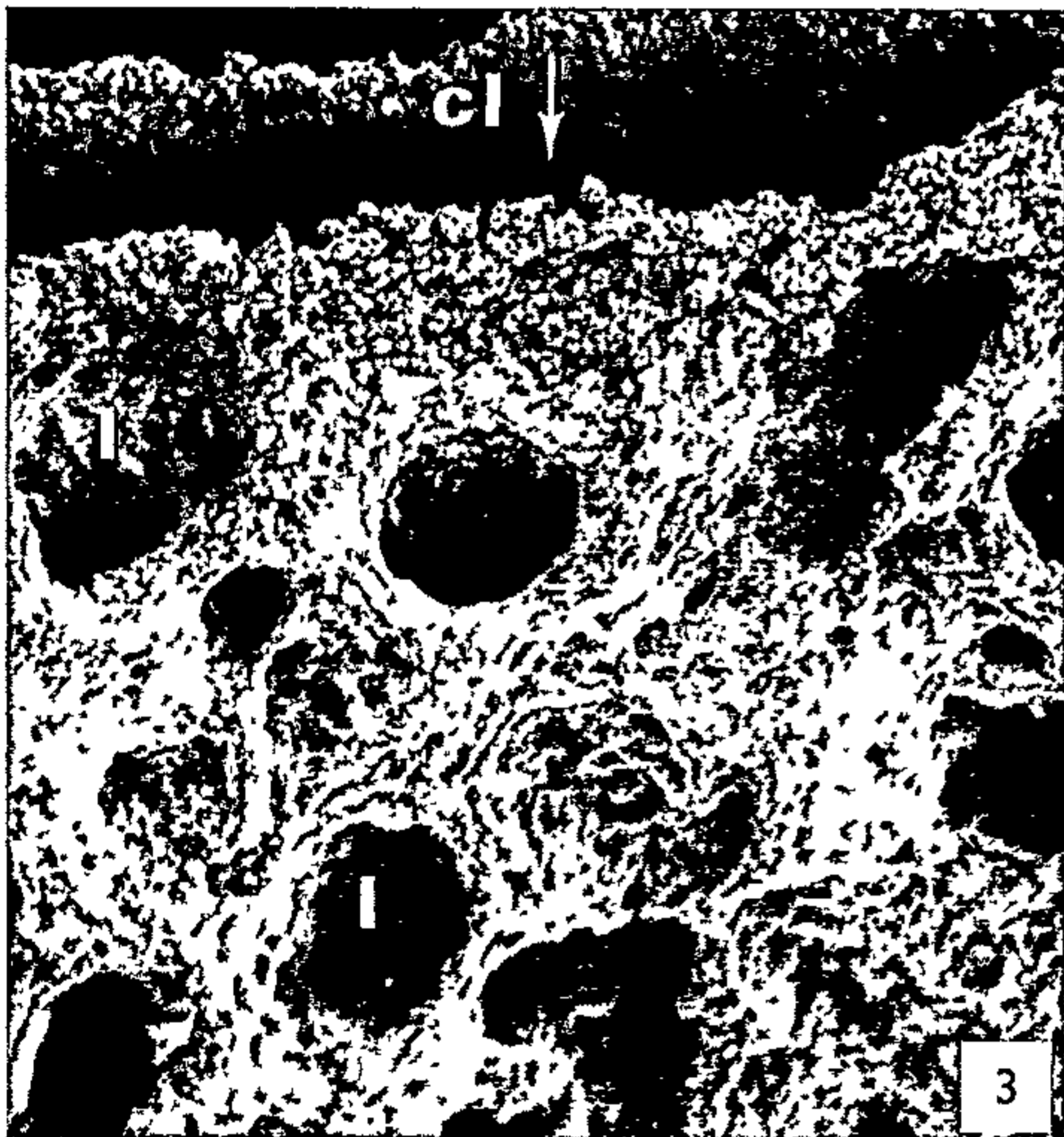
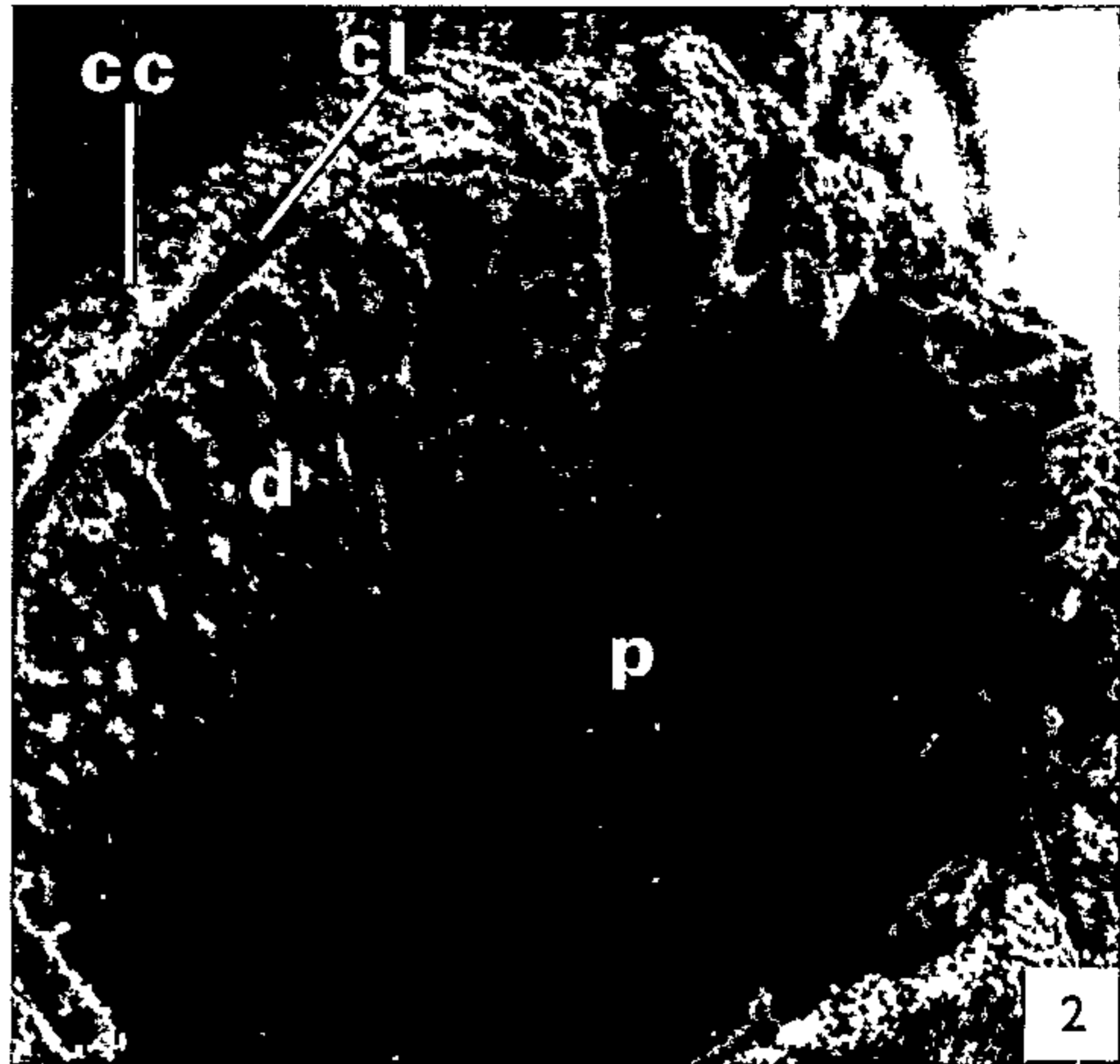
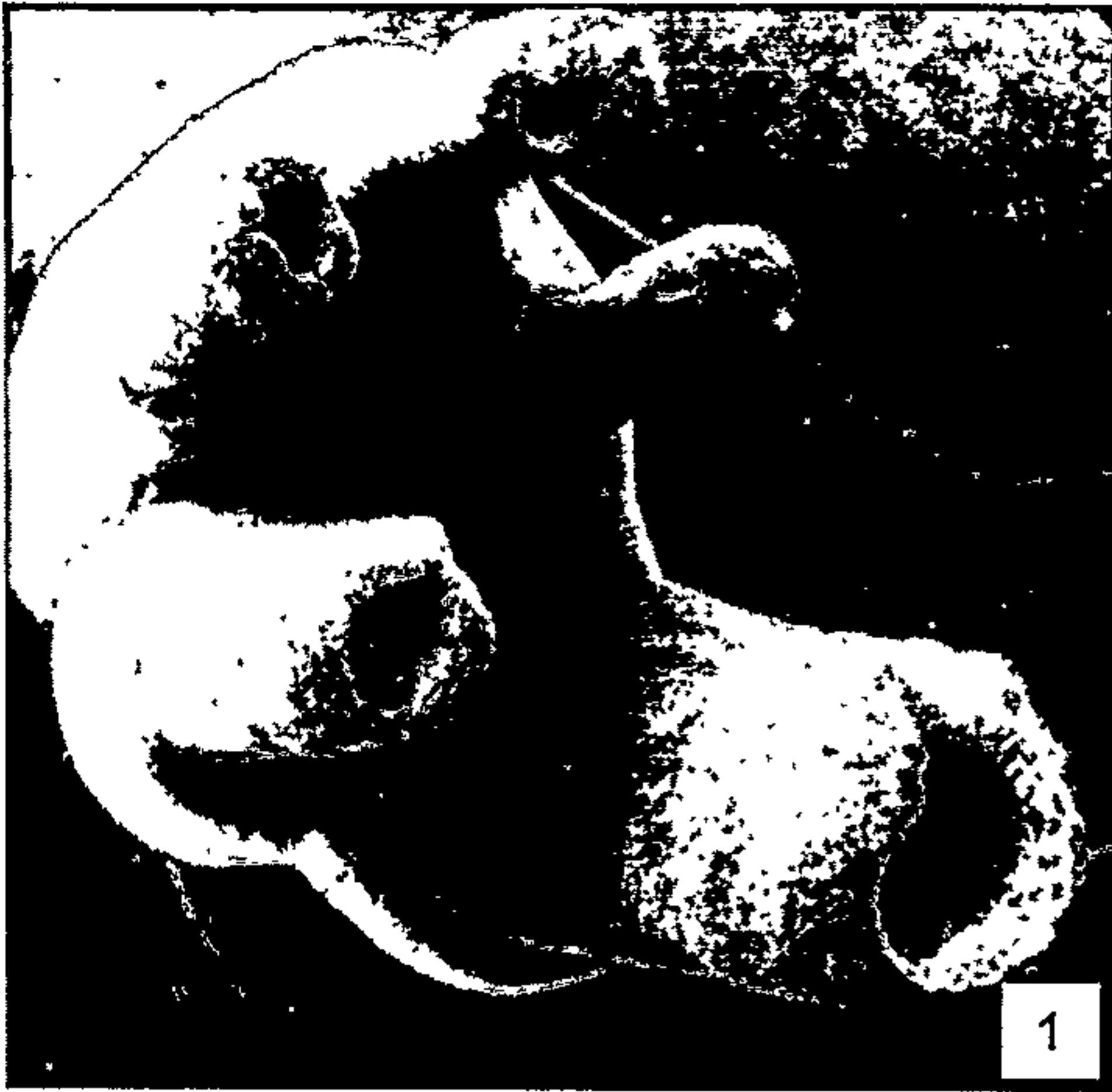
FIG. 1. Survey view of the undersurface of an upper left 1st molar at 53 days showing the developing roots at different stages of completion. $\times 21$.

FIG. 2. Developing edge of an upper left 1st molar root at 53 days. Note the irregularity of the developing edge especially with respect to the boundary area between dentine and cellular cementum. $\times 226$.

FIG. 3. Outer (periodontal) surface of developing root edge of a lower right 1st molar at 33 days showing the typical appearance of lacunae and canaliculi at the mineralizing front of cellular cementum. $\times 850$.

FIG. 4. Inner (pulpal) surface of the developing root illustrated in Fig. 3 showing the typically rugged appearance of the mineralizing front of dentine. $\times 500$.

FIG. 5. Stereo pair of a lower right 1st molar at 30 days to show developmental seams extending over the undersurface of the crown and along the adjacent (interradicular) surfaces of the roots. $\times 35$.



(iii) the location and structure of what we would term "developmental seams"—these occur on the developing roots and over the contiguous undersurface of the tooth crown (Fig. 5).

Morphology of the advancing root edge

The structure and composition of the tip of the advancing root edge alters significantly during development (cf. Figs. 6–8). The leading edge of the root is composed solely of dentine at the time of commencement of cellular cementum formation (by 25 days for the lower 1st molar) and for some time subsequently (e.g., Figs. 9 and 10). The cementum has no great bulk at this stage, and its advancing edge tapers gently toward the outer dentine surface. As may be judged by the depressions formed by them, the cells being incorporated into the cellular cementum are apposed directly against the outer surface of the dentine (Fig. 10).

The earliest indications of future cleft formation between dentine and cellular cementum may be seen in these specimens in the form of large cavities in the advancing front of the cellular cementum. These cavities are more extensive than the nearby cementocyte lacunae (Fig. 11) and their walls are not perforated by canaliculi as are those of the lacunae proper.

The bulk of cellular cementum increases with further development of the root (Figs. 12–15). The most outstanding feature of root development is, however, the cleft which develops between the mineralizing fronts of the dentine and of the cellular cementum. The cleft, which is present in all roots of the lower 1st molar by 30 days after birth, is rarely continuous around the circumference of a root edge (e.g., Figs. 2 and 12).

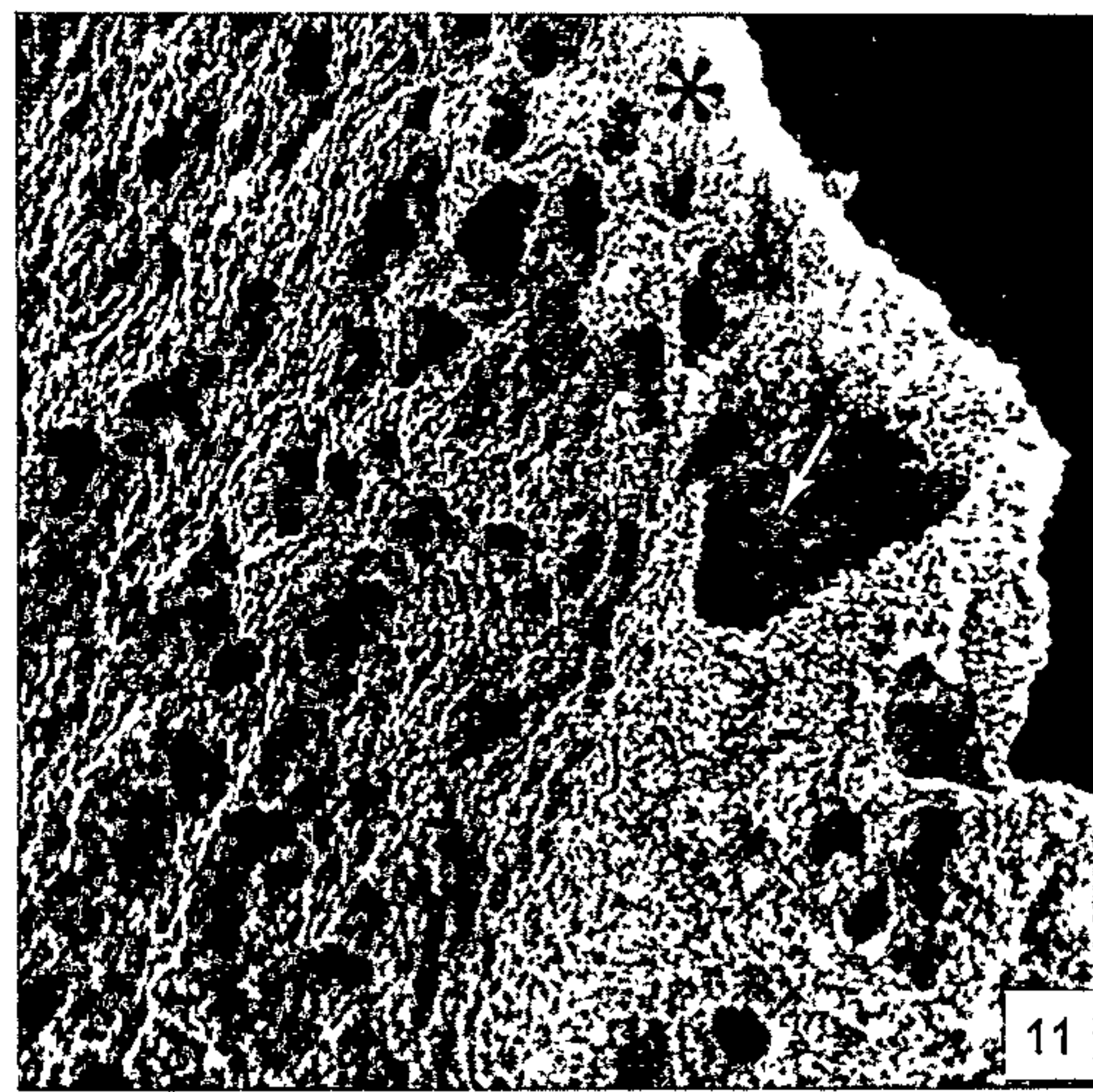
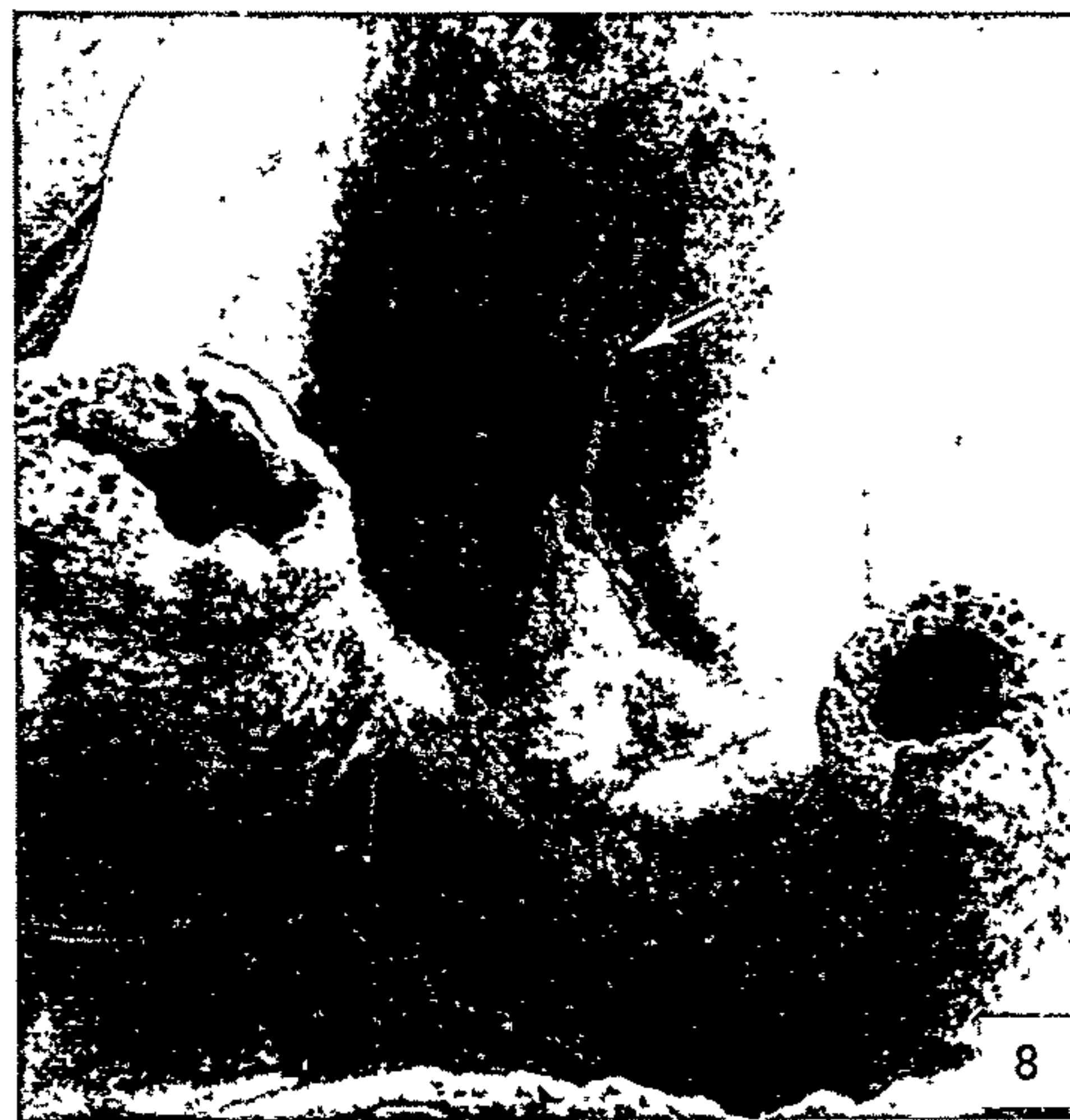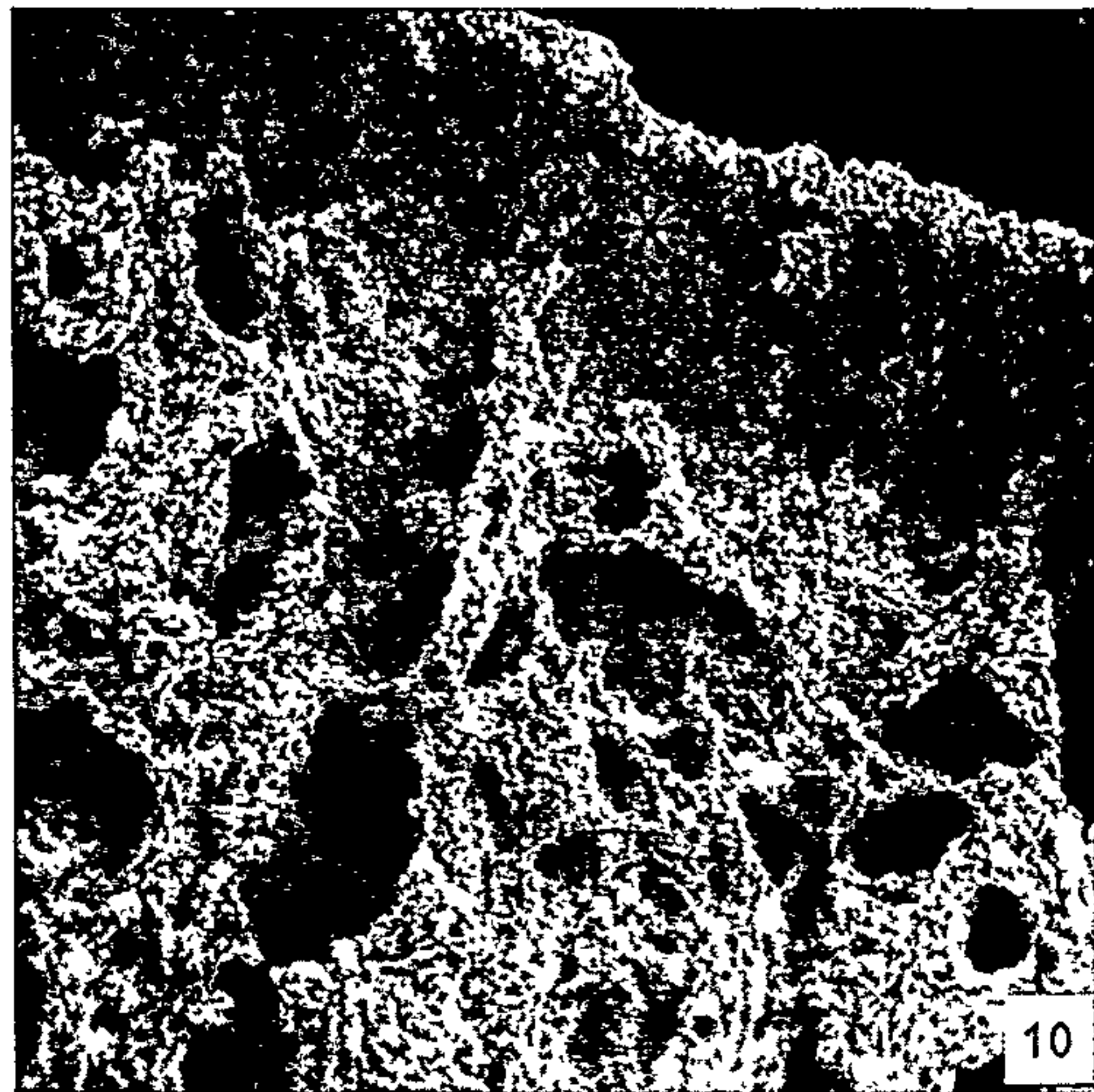
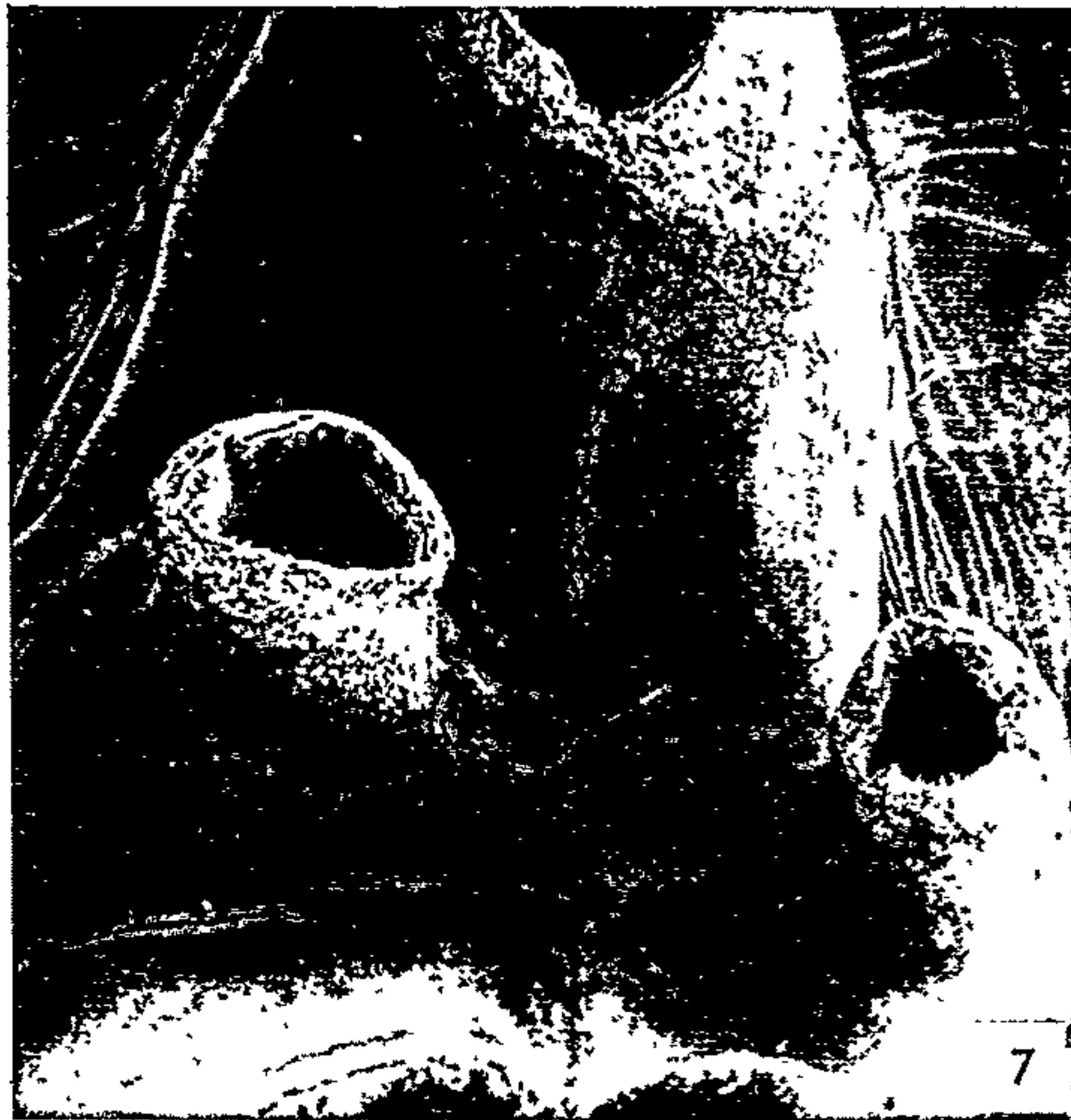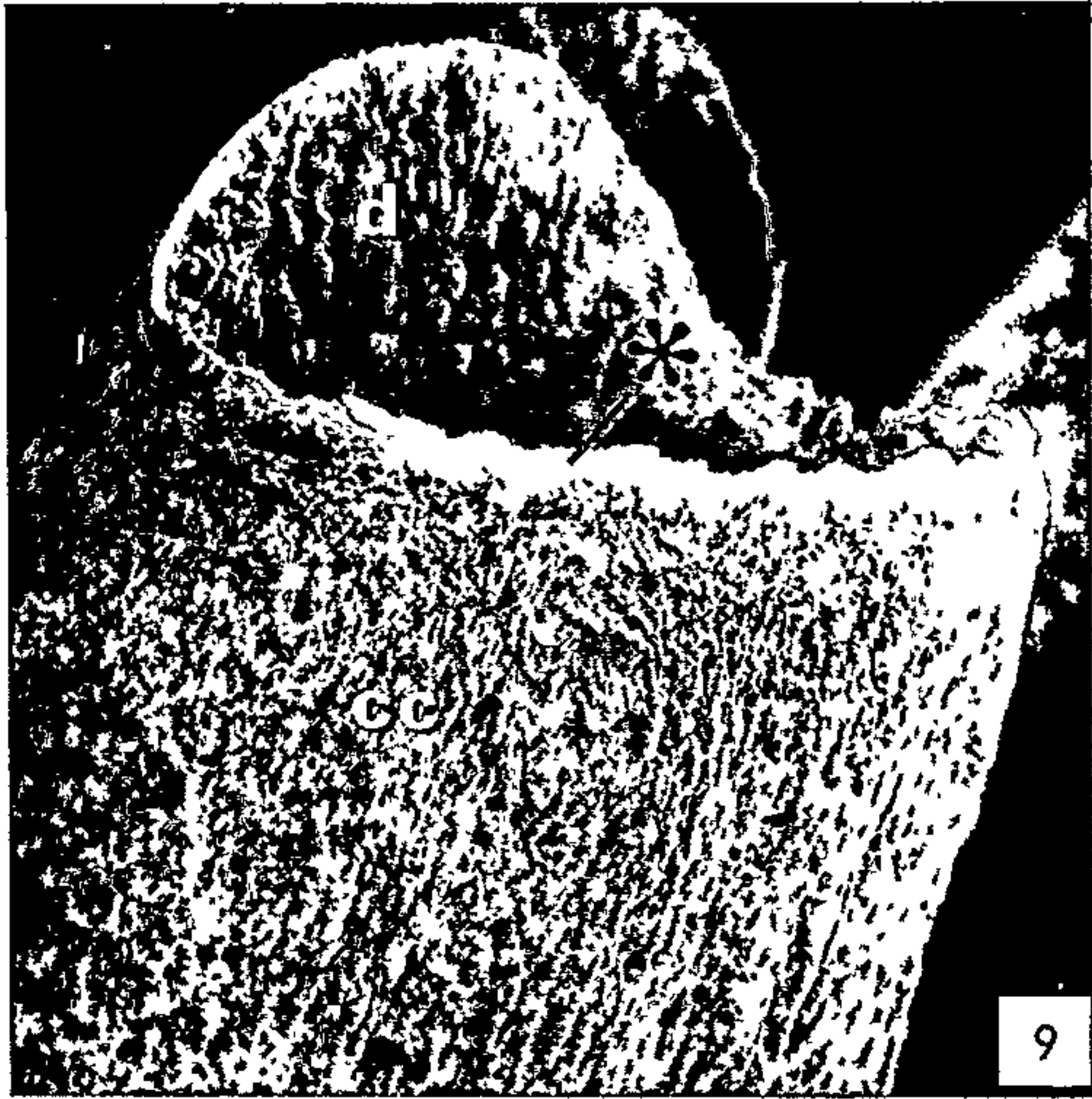
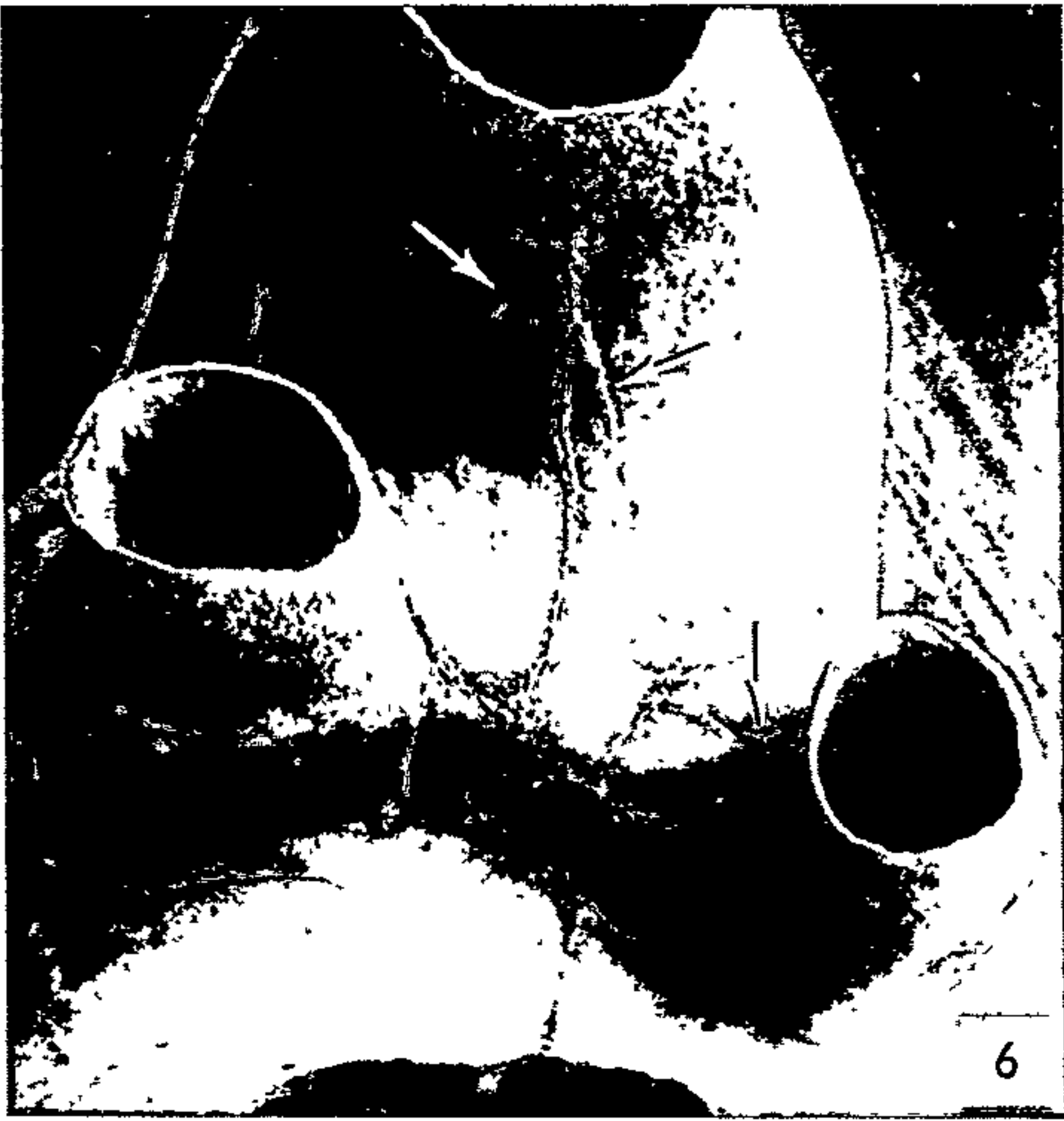The relationship between dentine and cellular cementum at the advancing root edge varies as development proceeds. As stated above, the usual relationship in younger teeth is that the cellular cementum does not extend as far as the edge of the dentine (Figs. 9 and 10). The cementum comes, however, to approach the level of the dentine and to extend beyond it in later stages (cf. Figs. 14 and 15). Indeed, it is not

FIGS. 6–8. Comparable views of developing roots of lower right 1st molars at different ages to show the increase in complexity of the root edge with time. Note also the increase in bulk of cellular cementum coincident with the closing of the root apex, and the slight variations (at arrows) in the pattern of the developmental seams. $\times 35$.

FIG. 9. Survey view of the developing end of a lower right 1st molar root at 31 days. Dentine (at asterisk) is in advance of cellular cementum at the root edge. $\times 82$.

FIG. 10. Higher magnification view of part of the root illustrated in Fig. 9 to show the outer (peri-odontal) surface of mineralized dentine (at asterisk) leading the cellular cementum. As judged by the depressions formed by them, cells being incorporated into the cellular cementum are apposed directly against the outer surface of the dentine. $\times 1110$.

FIG. 11. Another area of the root illustrated in Figs. 9 and 10 showing a large cleft between dentine and cellular cementum (at arrow) presumed to be the site of incorporation of groups of Hertwig's epithelial sheath cells. $\times 190$.



unusual for a single developing root edge to show all three of these relationships (e.g., by 41 days after birth for the lower 1st molar).

In the final stages of development, cellular cementum is the predominant tissue at the developing root end (e.g., by 47 days for the smaller buccal and lingual roots of the lower 1st molar). The leading edge of the cementum is extremely irregular at this time and is further complicated by a large number of irregularly distributed channels and clefts (Figs. 16 and 17). The advancing edge of the mineralizing dentine is usually obscured by cementum in these later stages.

Morphology of the mineralizing fronts

Two features of the mineralizing cemental front are worthy of note. The first is the remarkable porosity of cellular cementum at the advancing edge (Figs. 18 and 19). This presumably results from the incorporation of sheath cells and of cementoblasts. Second, it is not uncommon to find cellular cementum extending around the developing edge onto the inner (pulpal) aspect of the root in the later stages (e.g., by 41 days for the lower 1st molar) (Fig. 24). Such an overgrowth necessarily means the bridging of the cleft between the mineralizing fronts of cellular cementum and dentine.

The (pulpal) mineralizing front of dentine constituting the leading edge is relatively flat (Figs. 19–21). Slightly coronally, however, one invariably finds delicate projections of mineralized dentine extending pulpally (Figs. 18–21). The outermost tip of these stalk-like projections is often enlarged and flattened (Figs. 14 and 21). Still further coronally, these projections take one of two forms. Either, they form ever-widening ridges running predominantly in the long axis of the root (Figs. 20 and 22), or else they remain separate but increase in size and assume a flattened cone-like form (Figs. 21 and 23). In either case, there is a gradual progression in a coronal direction toward a flatter mineralizing front caused, it seems, by a gradual enlargement and coalescence of the projections.

Developmental seams

Raised "seams" (e.g., Figs. 5–8) were found on the undersurface of all teeth examined. These seams, four in the case of the lower 1st molar, run along the inner

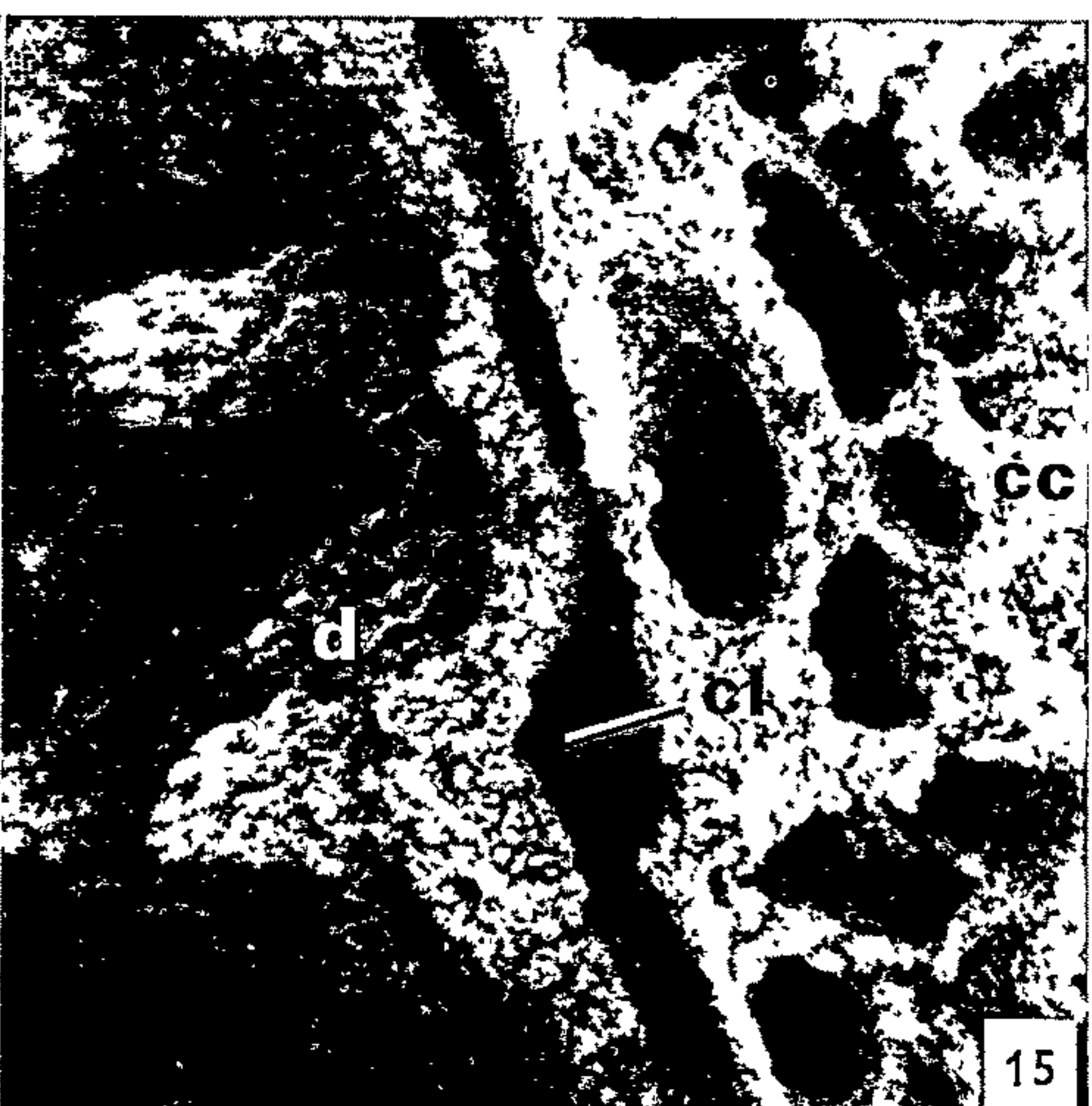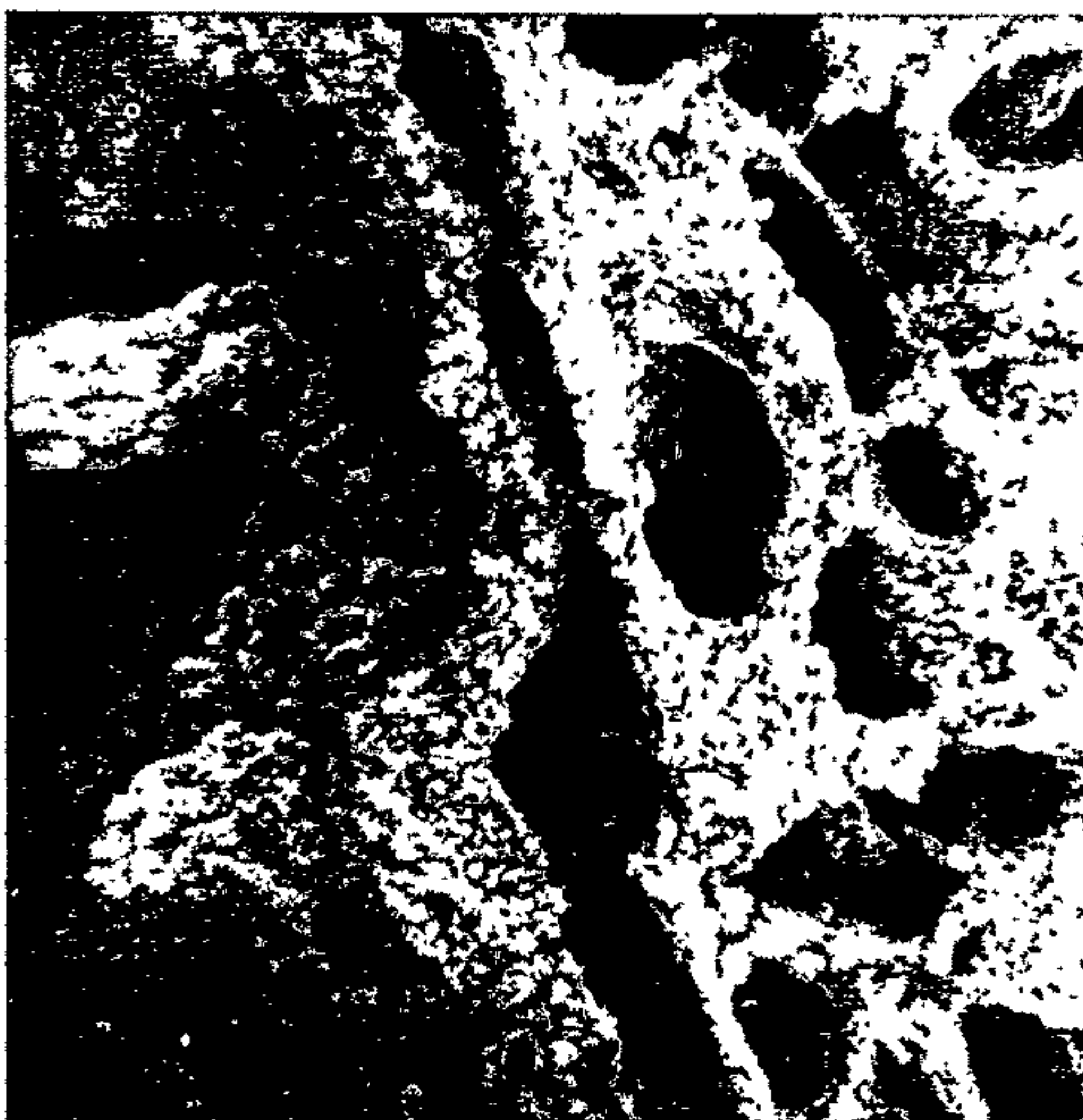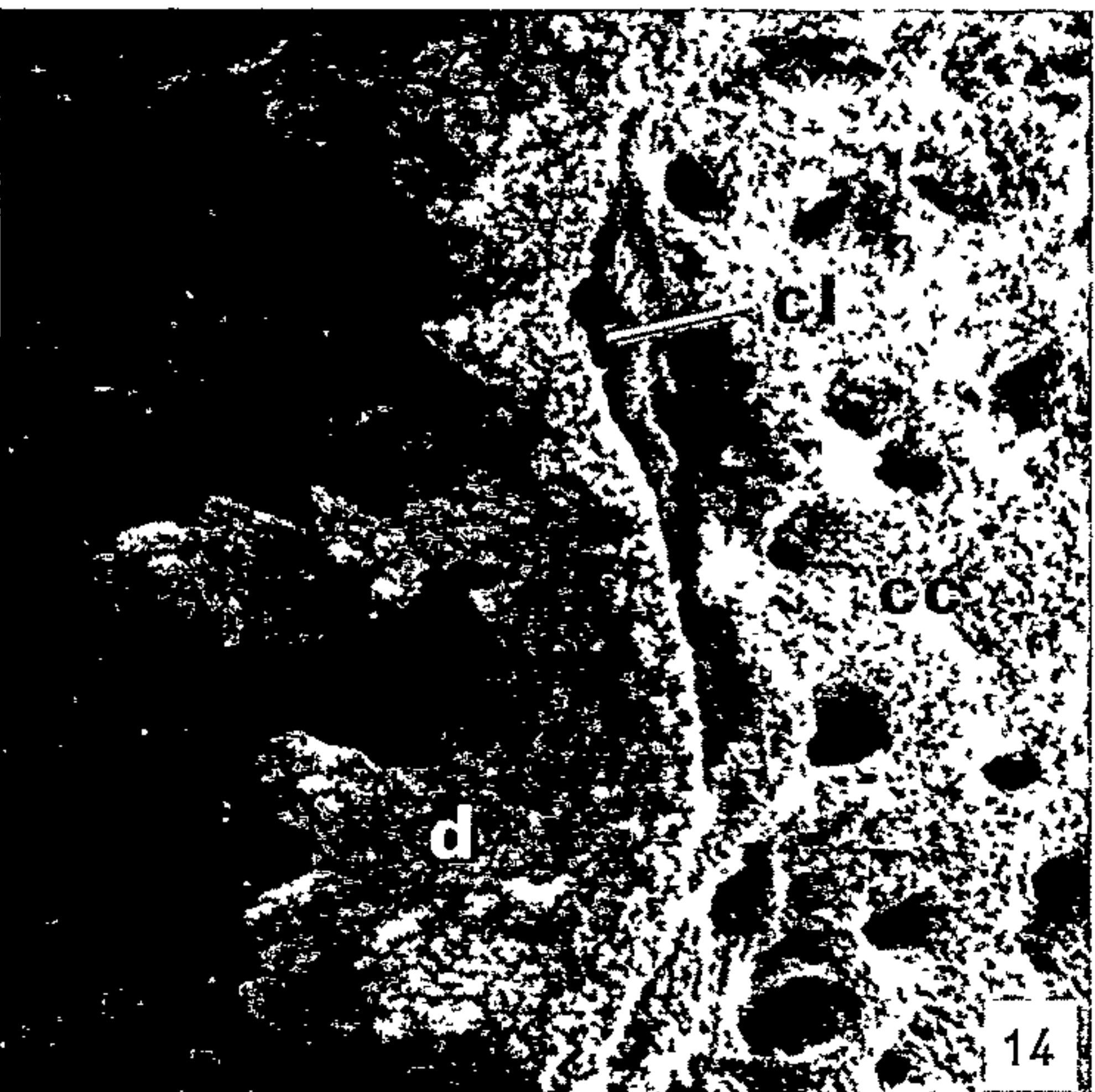
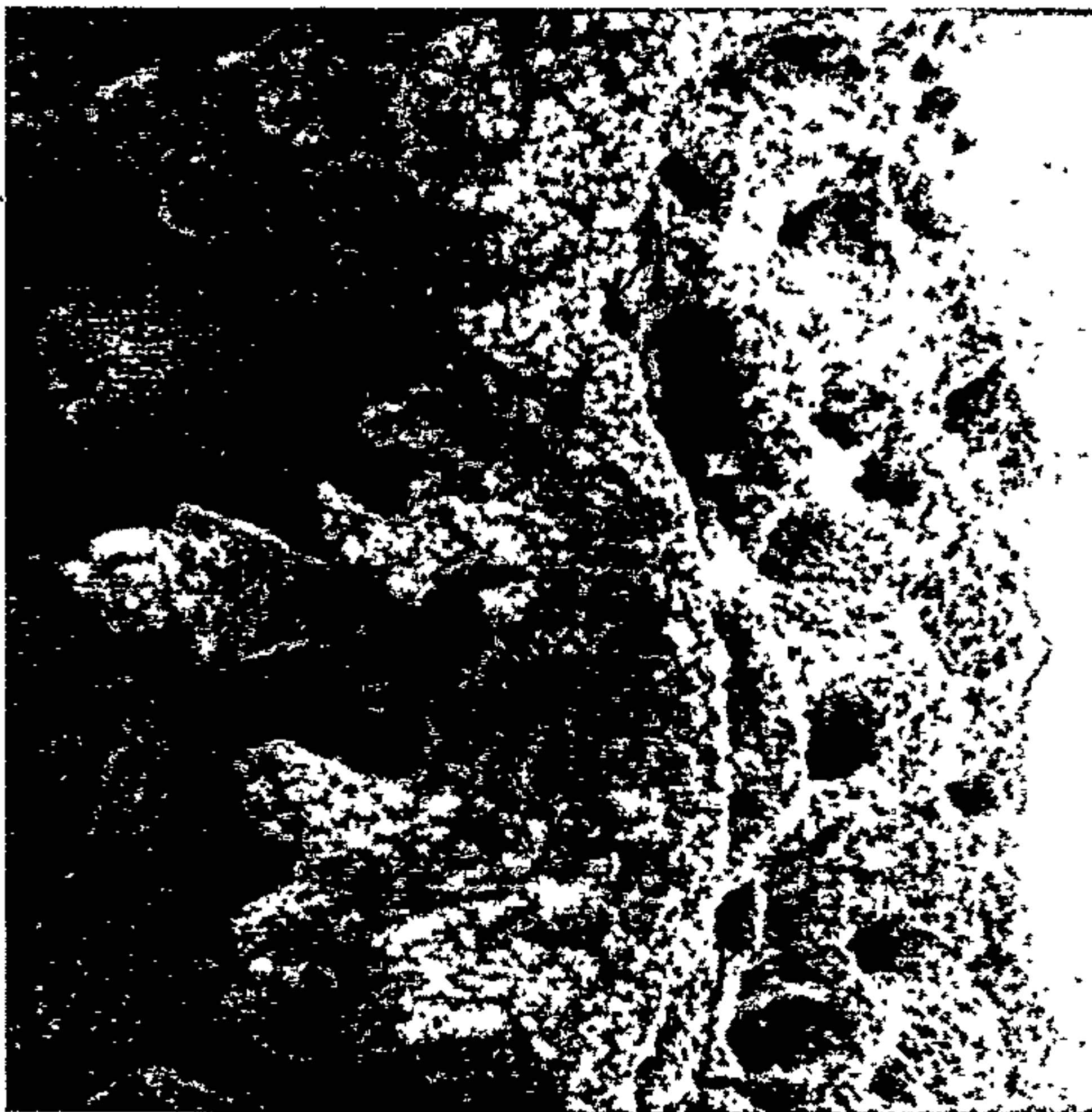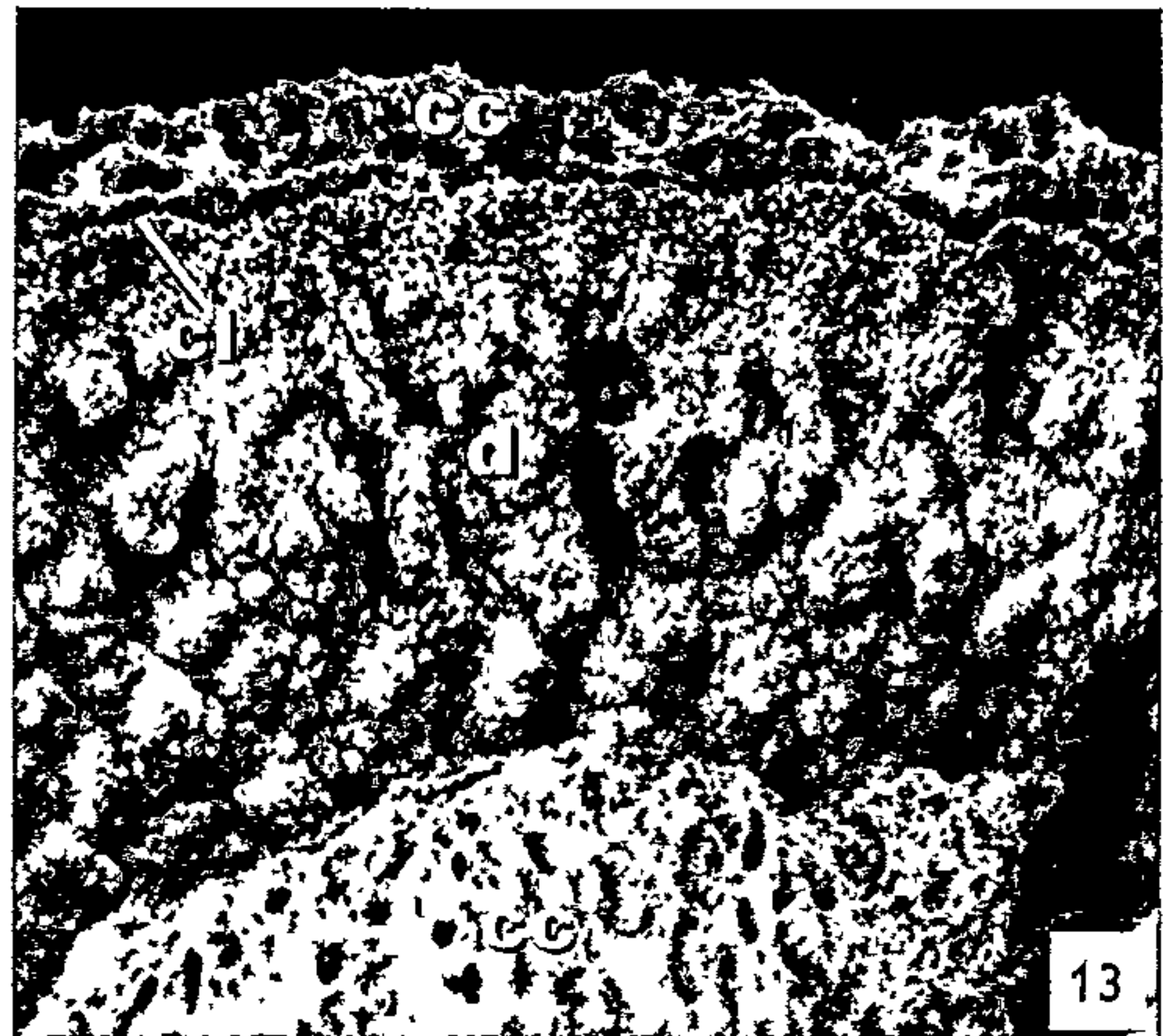
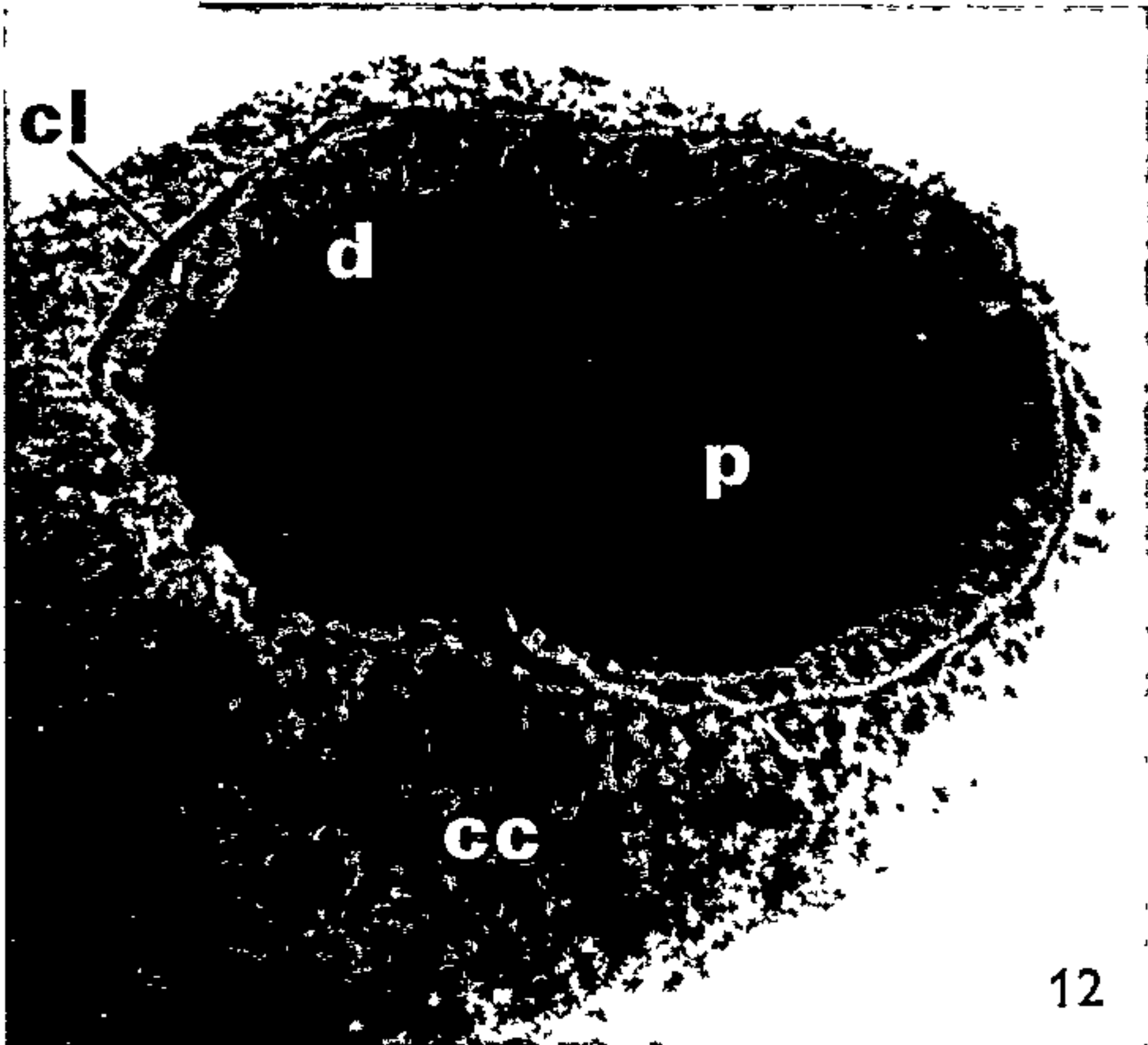
FIGS. 12–15. Different views of the developing edge of a lower right 1st molar at 41 days showing the variable relationship between cementum and dentine.

FIG. 12. Survey view showing the level of the cellular cementum to approximate that of the dentine; a cleft separates the two tissues with a varying degree of completeness. $\times 77$.

FIG. 13. Higher magnification view showing the cellular cementum covering the leading edge of dentine on the near side and extending beyond the dentine on the far side of the root. $\times 205$.

FIG. 14. Stereo pair showing dentine in advance of cellular cementum at the leading edge. Note the delicate projections of the mineralizing dentinal front. $\times 610$.

FIG. 15. Stereo pair showing cellular cementum in advance of dentine at the leading edge. Note the extent of the irregular cleft between the two tissues. $\times 840$.



(interradicular) surface of the roots from a common point on the undersurface of the crown. The seam pattern varies. Some roots have one or more "major" seams (Fig. 8), the several seams tending to converge toward the root apex. Other roots display short "minor" seams (Fig. 6).

The structure of the seam varies according to the site. Along the root surface, the seams take the form of an irregular furrow with raised edges: there is some cross-bridging (Figs. 25 and 26). On the undersurface of the crown, the substance of the seams is also raised above the surrounding surface but it is clearly a functional attachment-type of cellular cementum with Sharpey fibers [see reference (2) and compare Figs. 25, 27, and 28]. This cellular cementum-type of appearance is especially marked in the region of confluence of the seams. The seams extend to the level of the advancing root edge at the time of commencement of cellular cementum formation but tend to merge with the cellular cementum once a bulk of that tissue has formed (e.g., Fig. 7). However, there is often an irregularity in the advancing edge of the root at a point directly in line with an imaginary continuation of the seam (Figs. 7 and 8).

DISCUSSION

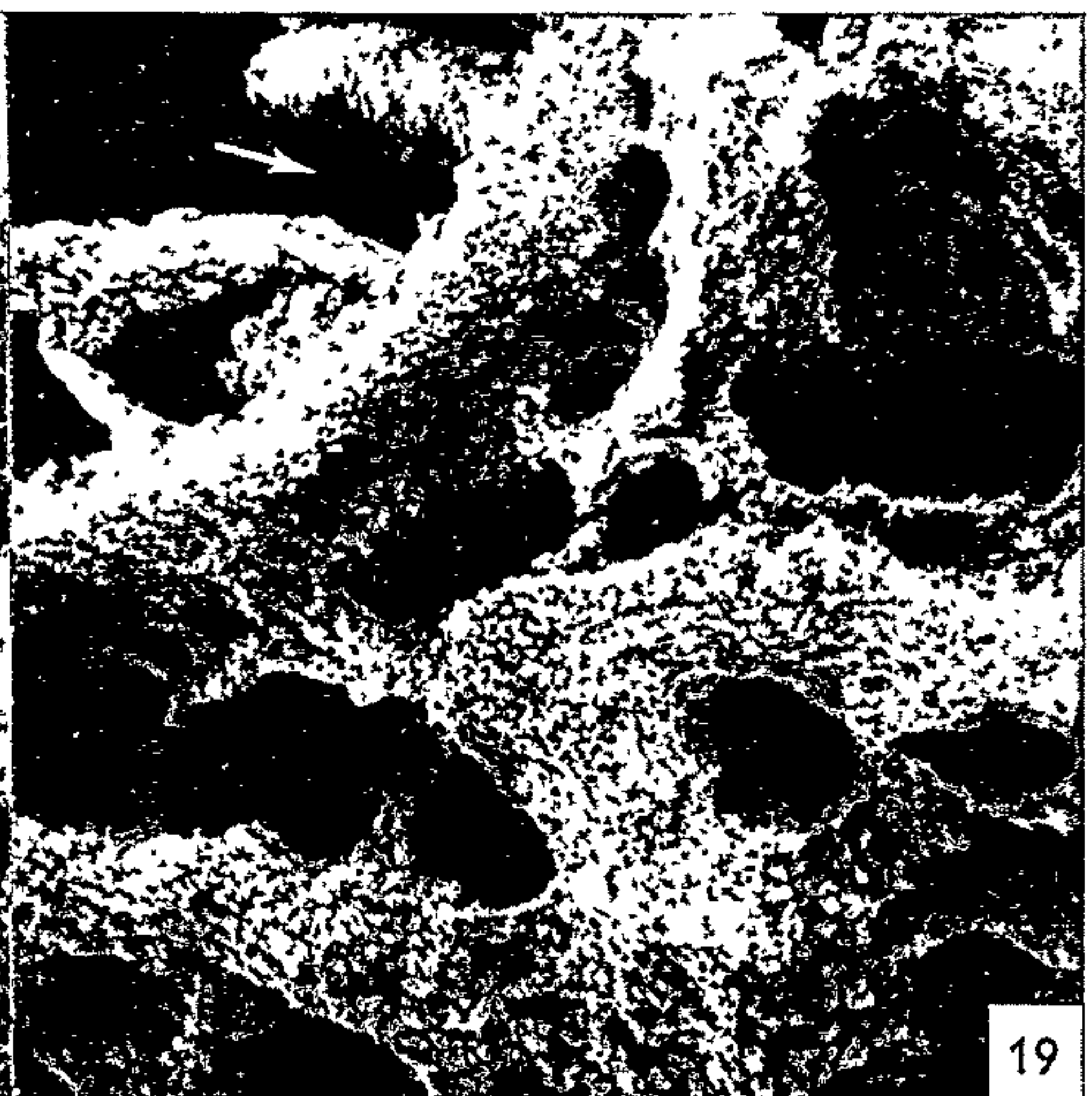
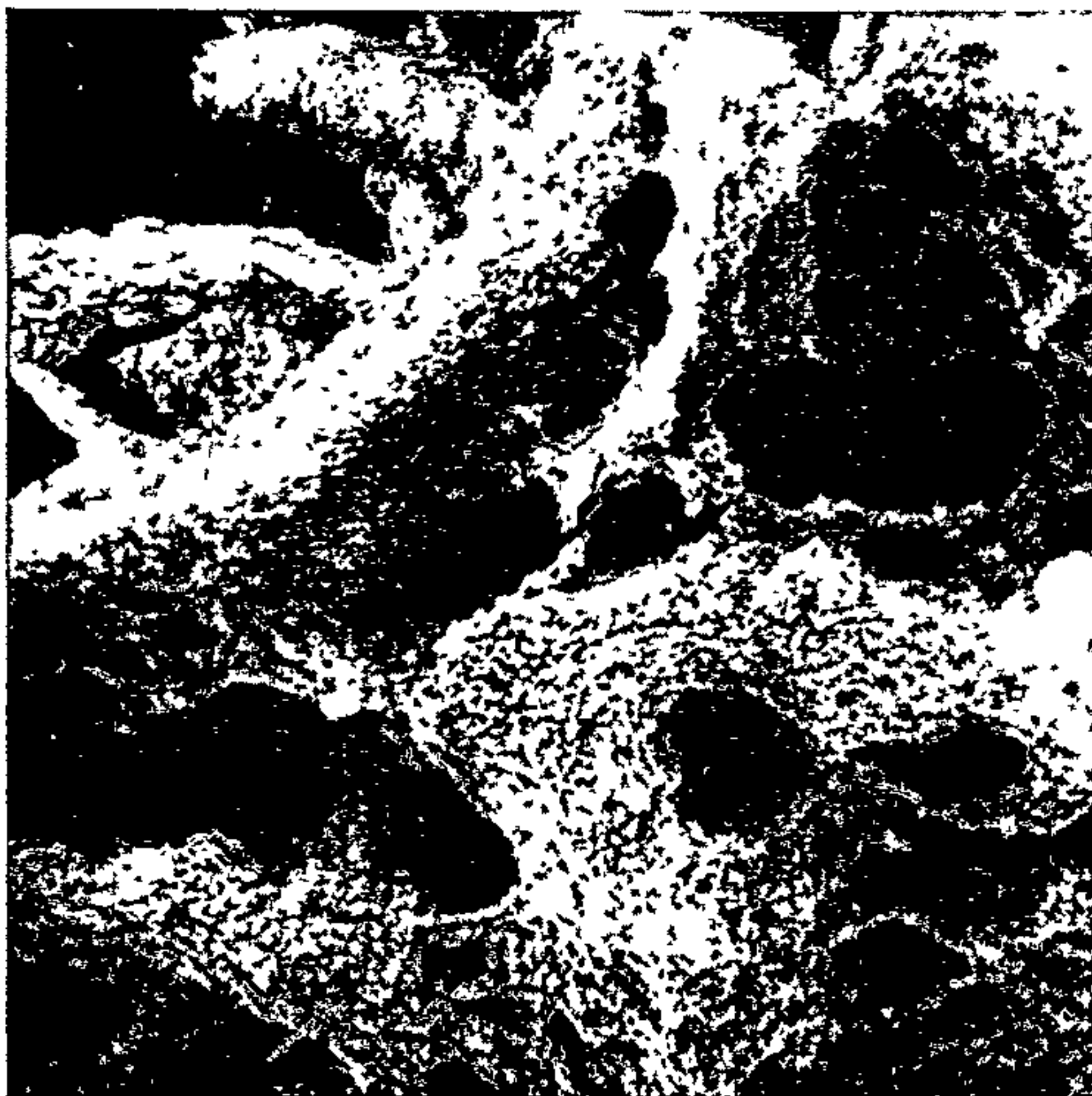
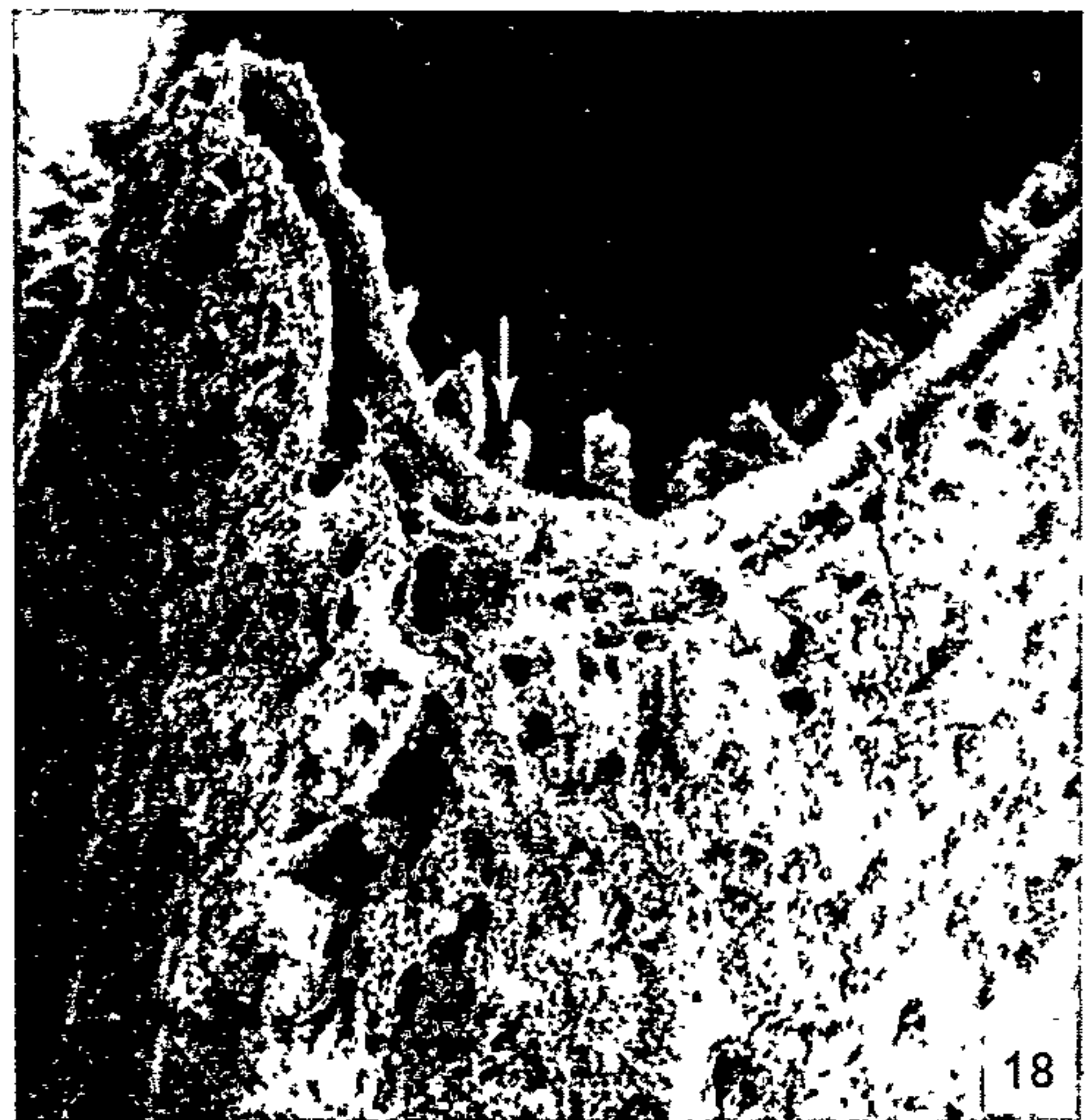
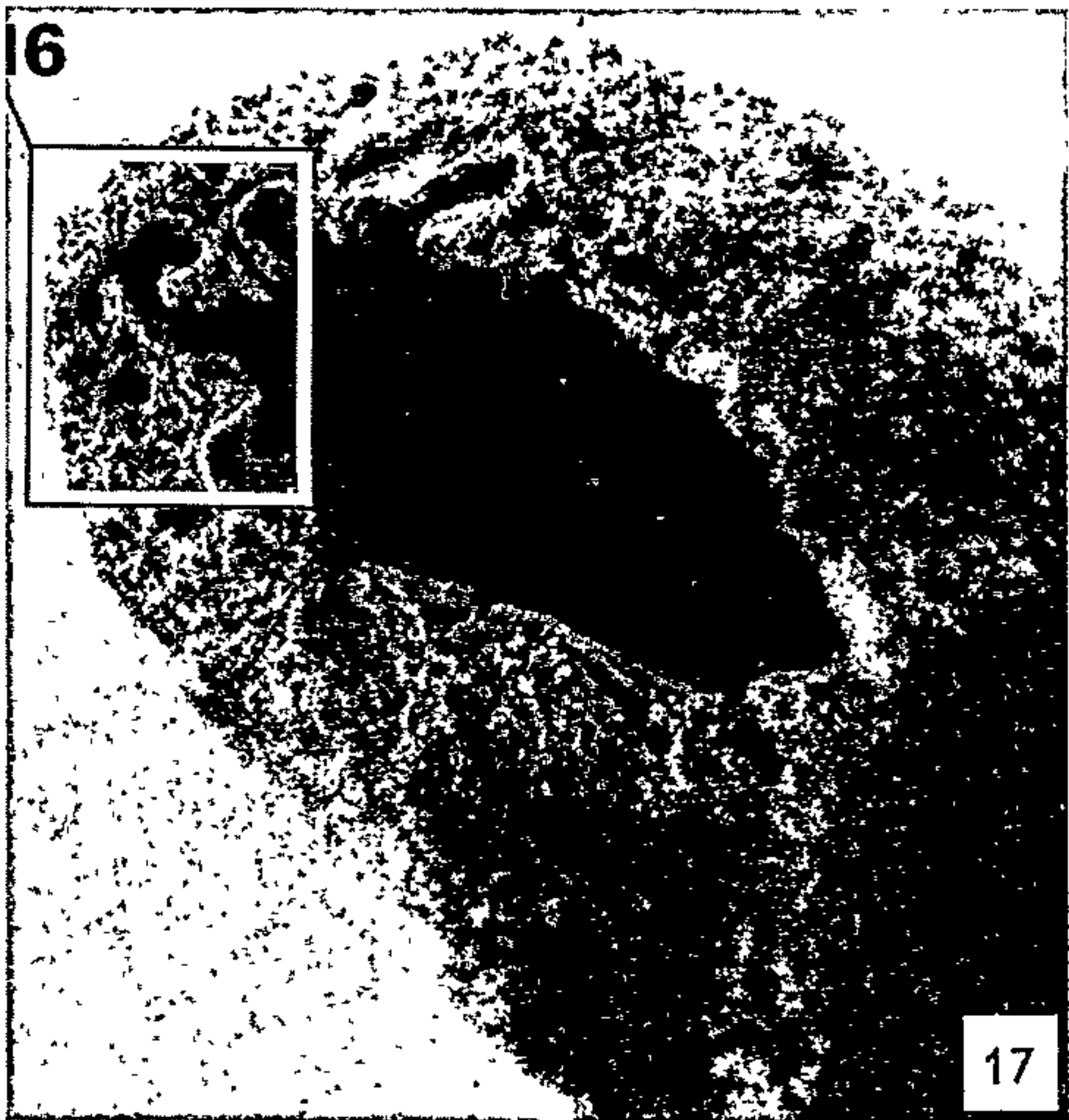
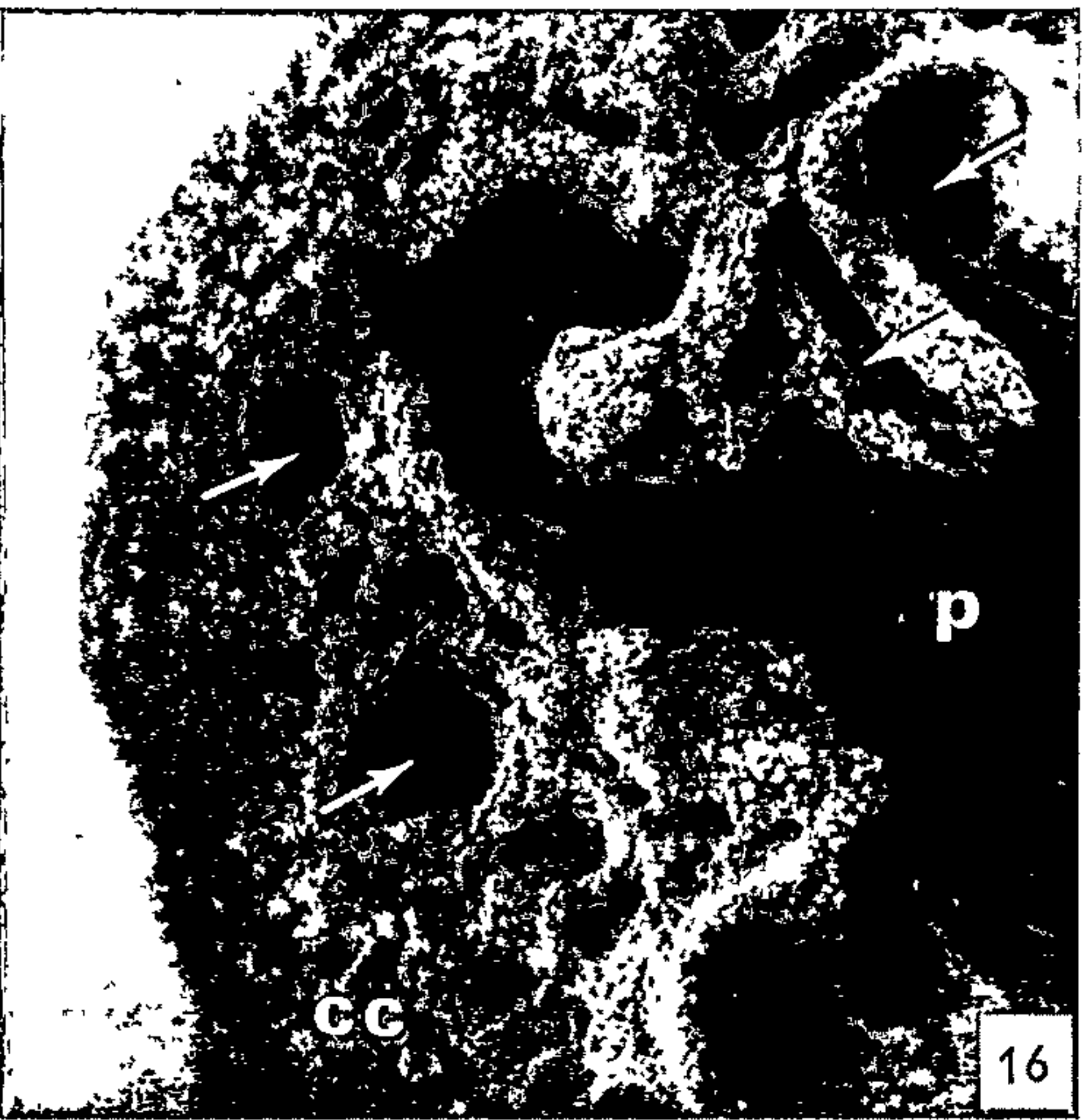
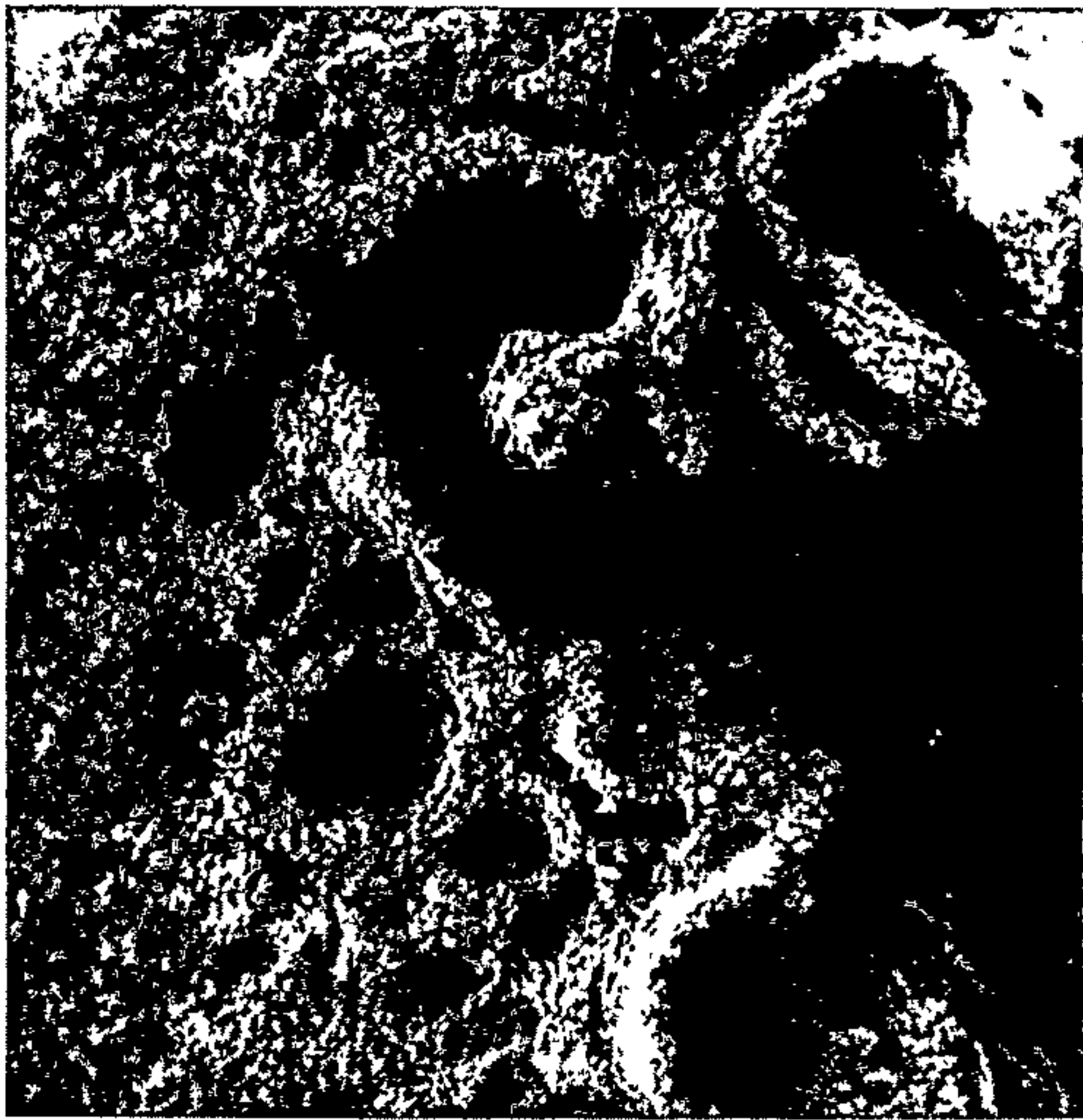The results confirm and extend earlier work (7, 8) on the relationship of cellular cementum to dentine at the advancing root edge during development. Thus, dentine alone forms the root end at first (Figs. 9-11), but is subsequently overtaken by an increasing bulk of cellular cementum (Figs. 13, 15, and 16). The most striking feature of rat molar root development, however, is the cleft which forms between the dentine and the cellular cementum. The present results illustrate the origin and structure of the cleft and demonstrate the extent to which it involves the total root edge during development (Figs. 2, and 11-15). The first indication of the cleft occurs with the onset of cellular cementum formation. The cleft becomes firmly established when the cellular cementum increases in bulk laterally and apically relative to the dentine. The cleft becomes increasingly complex in the final stages of root formation as the developing front of cellular cementum overtakes that of the dentine (Figs. 16 and 17). The morphology of the closing root apex is thus characteristically complicated by a

FIG. 16. Stereo pair of developing edge of a lower right 1st molar root at 47 days. Note the numerous channels and clefts (at arrows) and the irregularity of the developing edge. The cellular cementum obscures the dentine from view. $\times 475$.

FIG. 17. Low magnification view of the root end illustrated in Fig. 16 to show localization. $\times 133$.

FIG. 18. Part of the developing edge of a lower right 1st molar root at 39 days. Shown at higher magnification in Fig. 19. $\times 211$.

FIG. 19. Stereo pair of part of the root edge shown in Fig. 18 (image is at higher magnification and rotated 90° , the arrow points to the same area in both). Note the delicate projections from the mineralizing front of dentine and the porosity of the cementum-dentine junction. $\times 830$.



large number of irregular clefts and channels. As suggested by light microscope studies (4, 10) and demonstrated by electron microscopy (7, 8), the cleft is the site of enclosure of cells of Hertwig's epithelial root sheath; such incorporation is not a typical feature of mammalian tooth root formation. The irregular pattern of clefts representing the cementum-dentine junction during the final closure of the root end (apex) confirms the earlier suggestion that Hertwig's epithelial sheath is not in the form of a simple, gently tapering cylinder during closure of the rat molar root apex (8).

A previous description of the mineralizing front of rat molar dentine, by combined transmission and scanning electron microscopy (3), differs from the present one. In the earlier study, the mineralizing front of the first-formed (mantle) dentine was found to display a multitude of small, pointed projections. These spiked projections were held to represent the mineralizing von Korff fiber bundles. The projections were found to be replaced by a relatively flat mineralizing front and later by one showing large, individual calcospherites. However, the description referred to coronal dentine and it was noted that the mineralization pattern did not appear to correspond to that found in other mammals. The present study is of root dentine and the pattern of the mineralizing front, which almost certainly reflects the influence of von Korff fiber bundles in the early stages, is slightly more reminiscent of that of other mammals. The generalized mammalian pattern (1) is one of "calcospherites" of the mantle dentine fusing, as the dentine increases in thickness, to form increasingly larger calcospherites with a progressively lower profile.

As far as we are aware, the developmental seams have not been described previously. Indeed, it is unlikely that they would have been, as a combination of anorganic specimen and scanning electron microscope would seem to be the only satisfactory way at present of resolving them in their entirety. The seams extend from the areas of confluence of the roots toward the respective developing edges along the inner (or interradicular) aspect of the root surface. Although constant in occurrence, the seams are variable in number, pattern, and morphology. The seams disappear toward the apex at about the level of the cellular cementum.

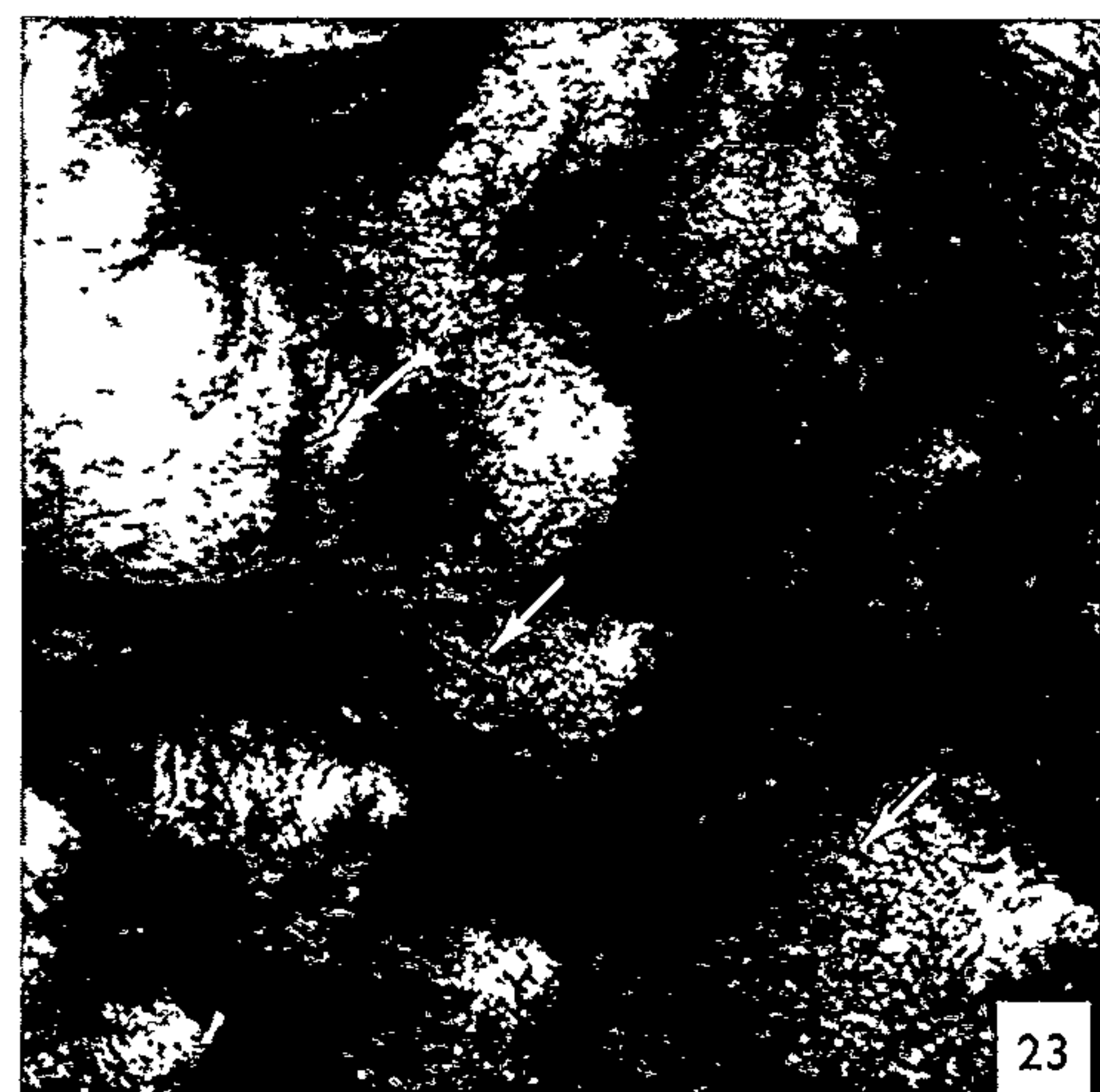
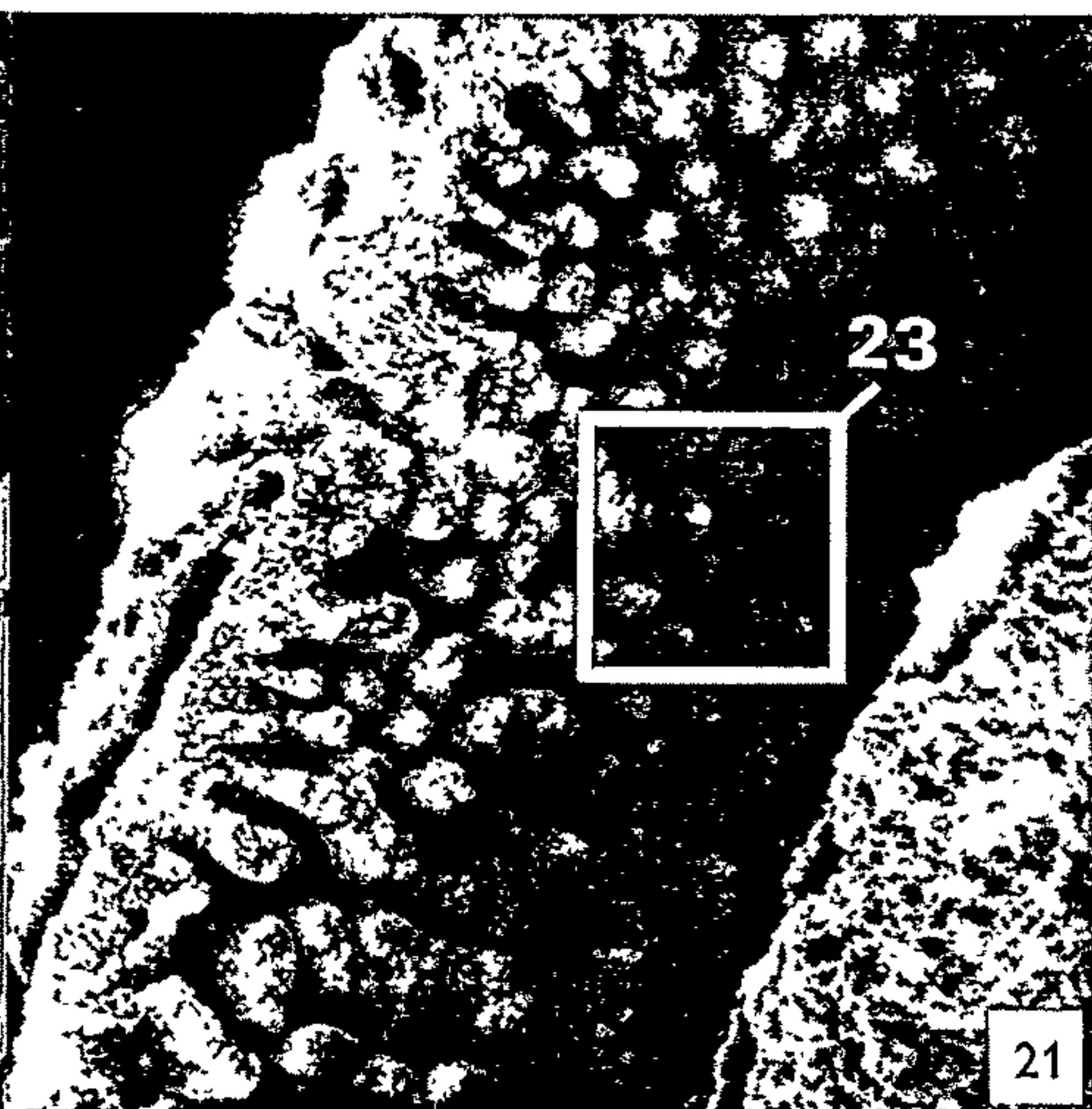
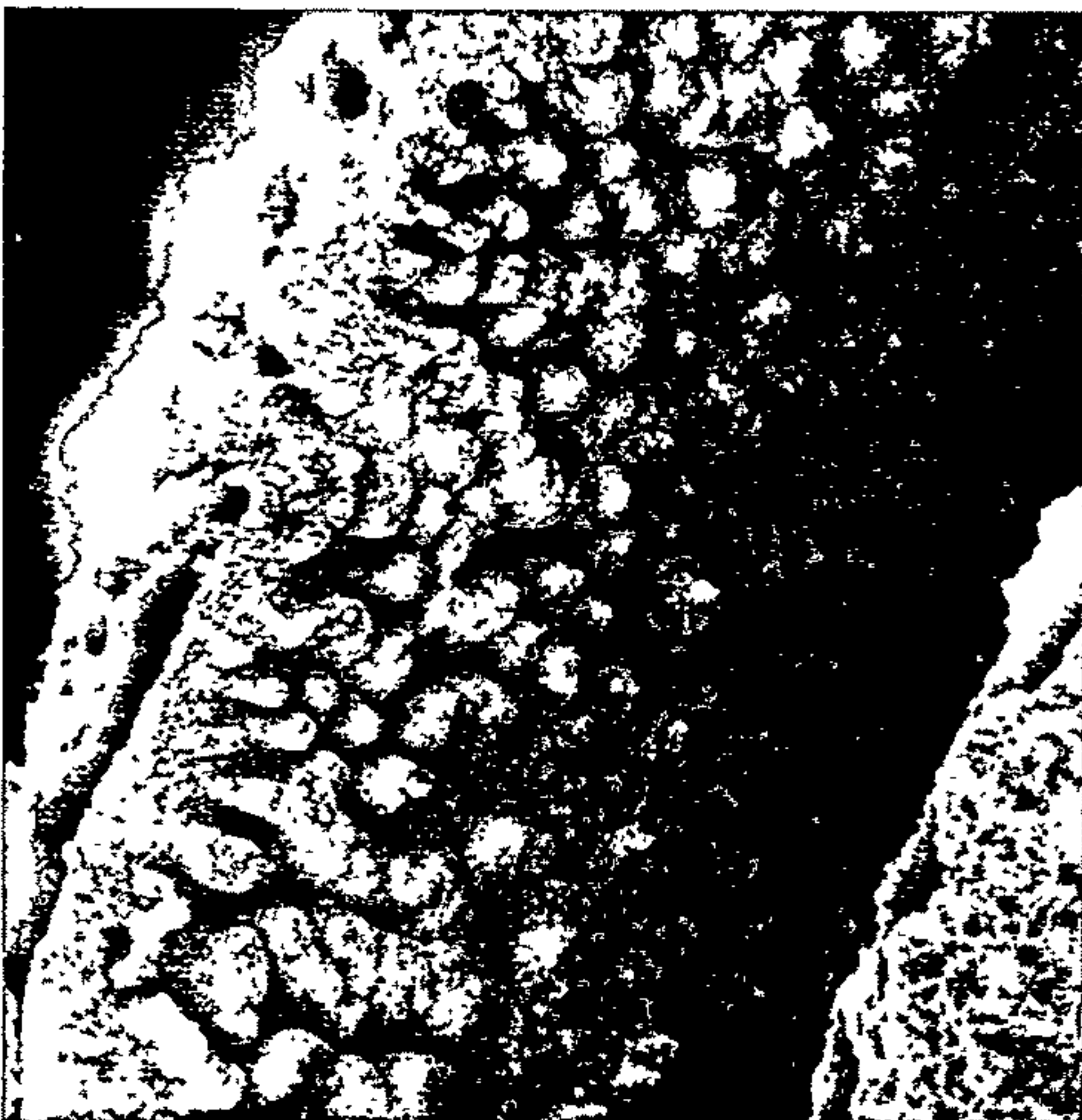
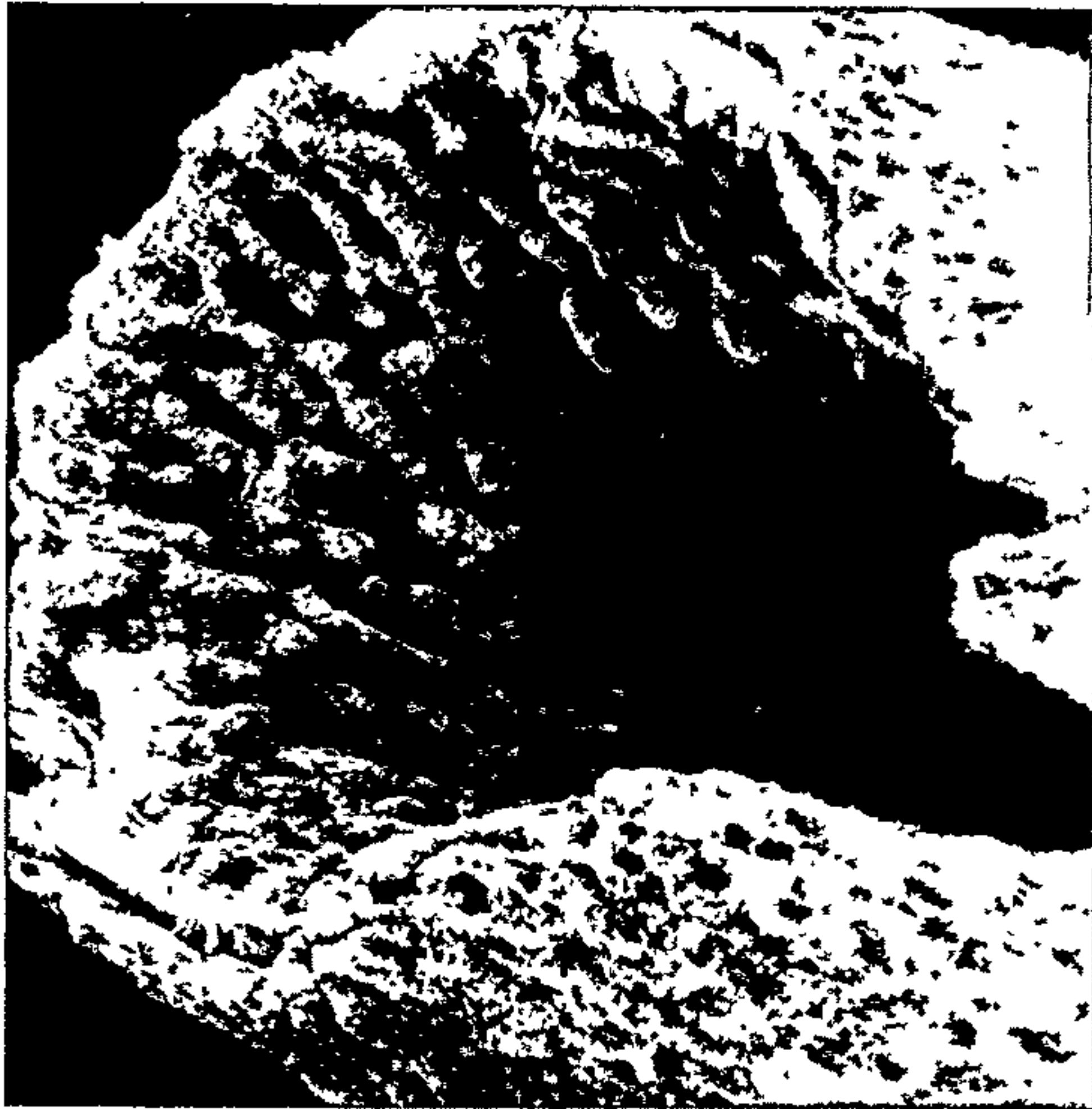
FIGS. 20-23. Views from the developing ends of two different roots of a lower right 1st molar at 39 days:

FIG. 20. Stereo pair of mineralizing front of dentine showing a ridged pattern. The longitudinal ridges increase in thickness away from the developing edge. The boxed area is seen in Fig. 22. $\times 145$.

FIG. 21. Stereo pair of mineralizing front of dentine showing cone-like projections. The projections are small and isolated near the developing edge, but thicker (and apparently coalesced) away from it. The boxed area is seen in Fig. 23. $\times 167$.

FIG. 22. Higher magnification view of the ridge pattern shown in Fig. 20. Note the rounded openings of the dentinal tubules (at arrows). $\times 775$.

FIG. 23. Higher magnification view of the cone-like pattern shown in Fig. 21. The dentinal tubules openings (at arrows) are more oblique and elongated on the sides of projections of the mineralizing front. $\times 730$.



On the basis of the site of occurrence of the seams, it is reasonable to suppose that their development is related in some way to the process of fusion of the ingrowths of Hertwig's epithelial root sheath. These horizontal ingrowths determine the size, number, and location of the roots (4, 9, 11). The major seams correspond to the anticipated sites of fusion of the various contributions of the sheath. The dentine at the site of the seam is not formed in as complete or regular a fashion as elsewhere. Presumably, the epithelial cells along the line of fusion of the approaching sheath segments are in some way incapacitated with respect to any role they might play in the progression of events leading to dentine formation [for discussion of the possible role of sheath cells in normal development of rat molar root, see (8)]. Cellular cementum formation does not seem to be similarly affected since this tissue bridges over parts of the seam on the undersurface of the tooth crown (Fig. 27) and because the seams do not continue over the cellular cementum ("apical") part of the root (Fig. 5).

Because the seams represent an incompleteness of "normal" structure (i.e., of dentine and cementum), one may tend to associate them with "abnormal" developmental clefts which occur elsewhere. The root seams were present, however, on all molars examined and can hardly be regarded as "abnormal." There is, in addition, a basic developmental difference. In the process of palatal fusion, for example, a mesodermal element fuses with its contralateral counterpart after disintegration of the covering epithelium (for E/M, see 6, 14). In root formation, however, the mesodermal component is not clothed by epithelium but rather, dentine lies on the one aspect of the epithelium and cementum on the other. Thus, it is not a matter of a mesodermal element (in this case the dentine) failing to become continuous as a result of incomplete breakdown of the sheath. Rather, it is a matter of dentine failing to form in a normal manner beneath a specific part of its epithelial template. Although we can relate that specific part to the line of fusion, the reason for the failure is unknown. The area could easily be examined, however, by transmission electron microscopy. It is reasonable to expect that atypical features would be discernible on the basis of the information presently available for this region.

FIG. 24. Developing edge of a lower right 1st molar at 41 days. In one area, cellular cementum (at arrows) bridges the cleft in the root edge, extending over it onto the dentinal surface. $\times 232$.

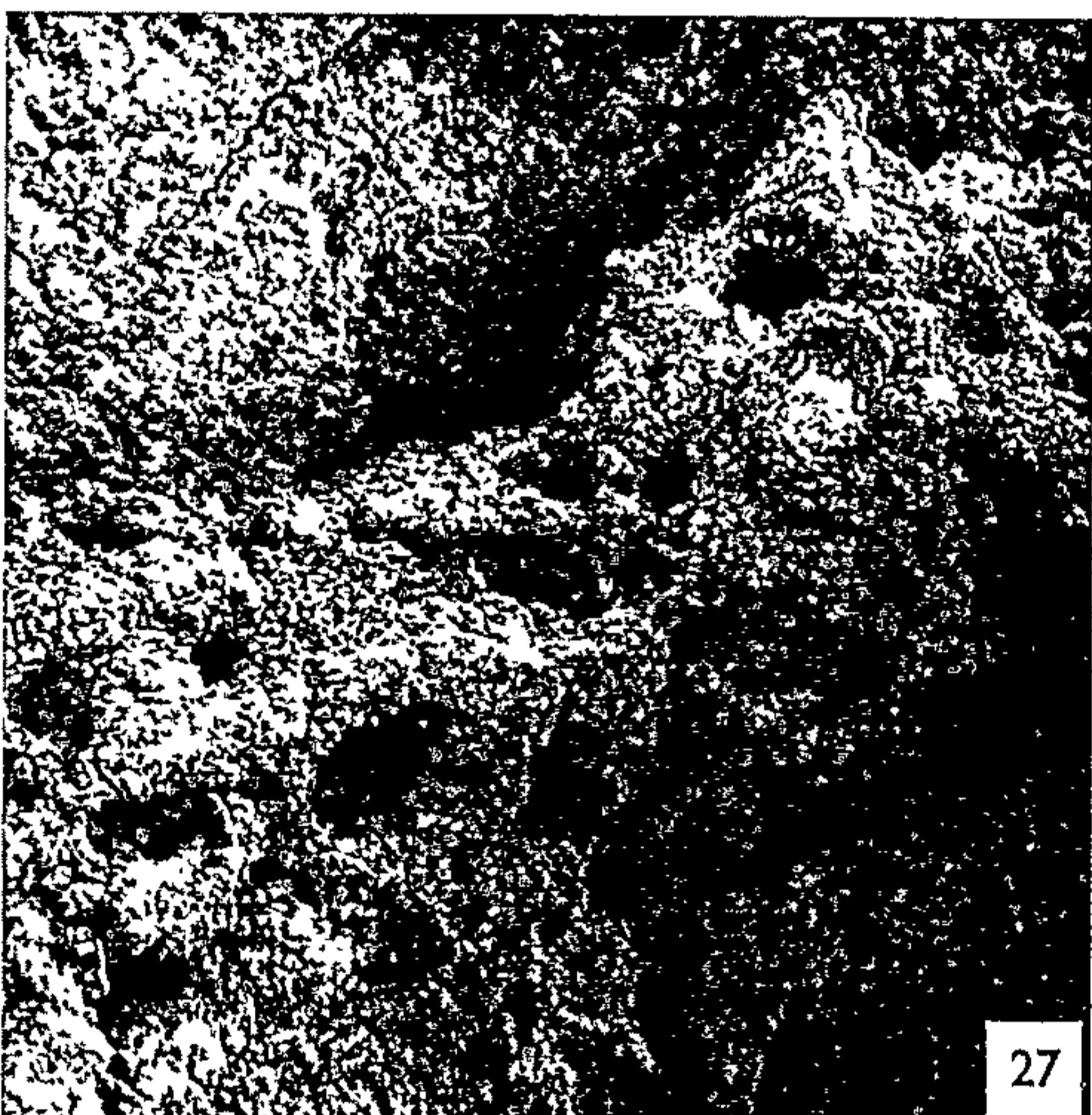

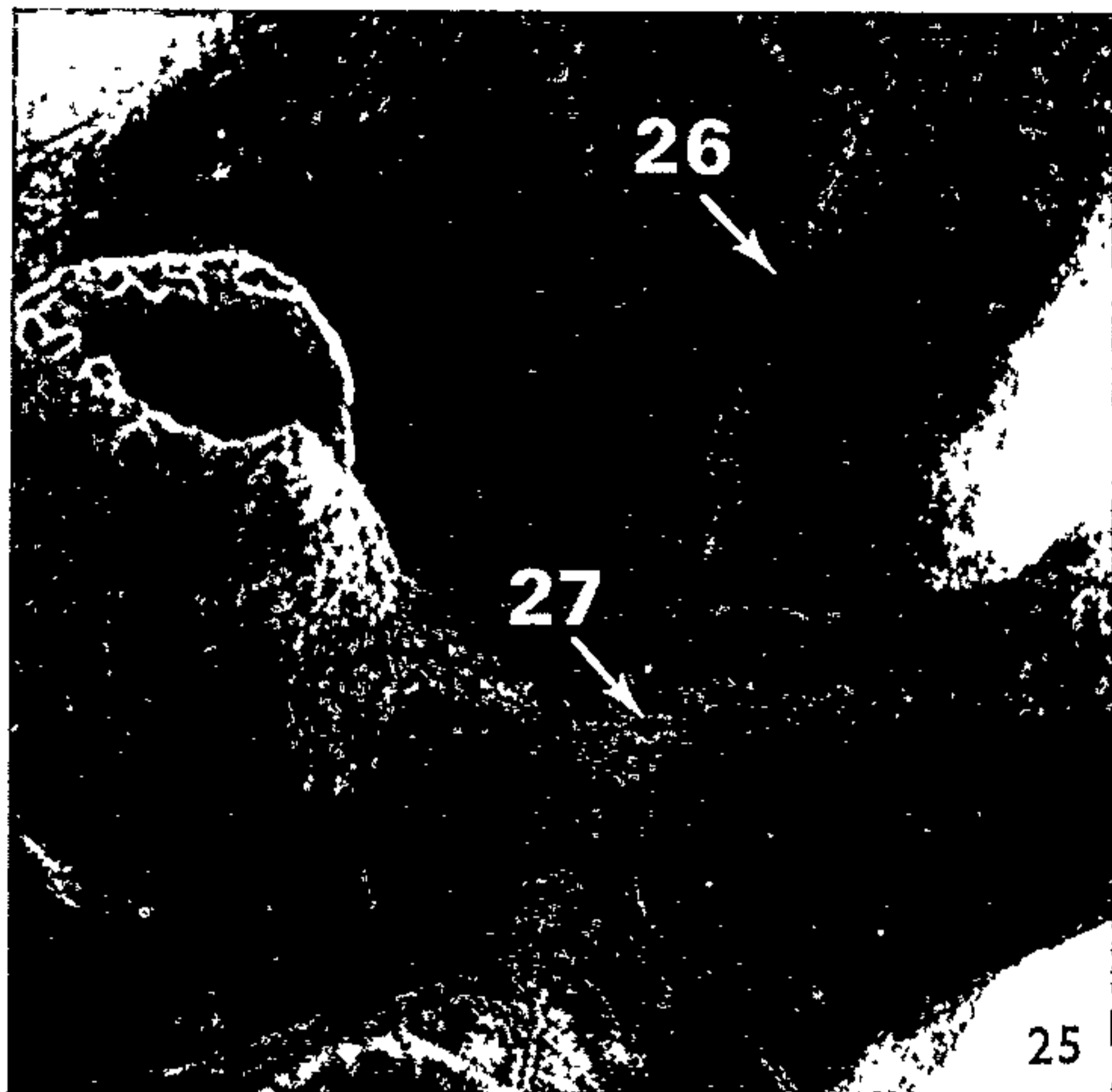
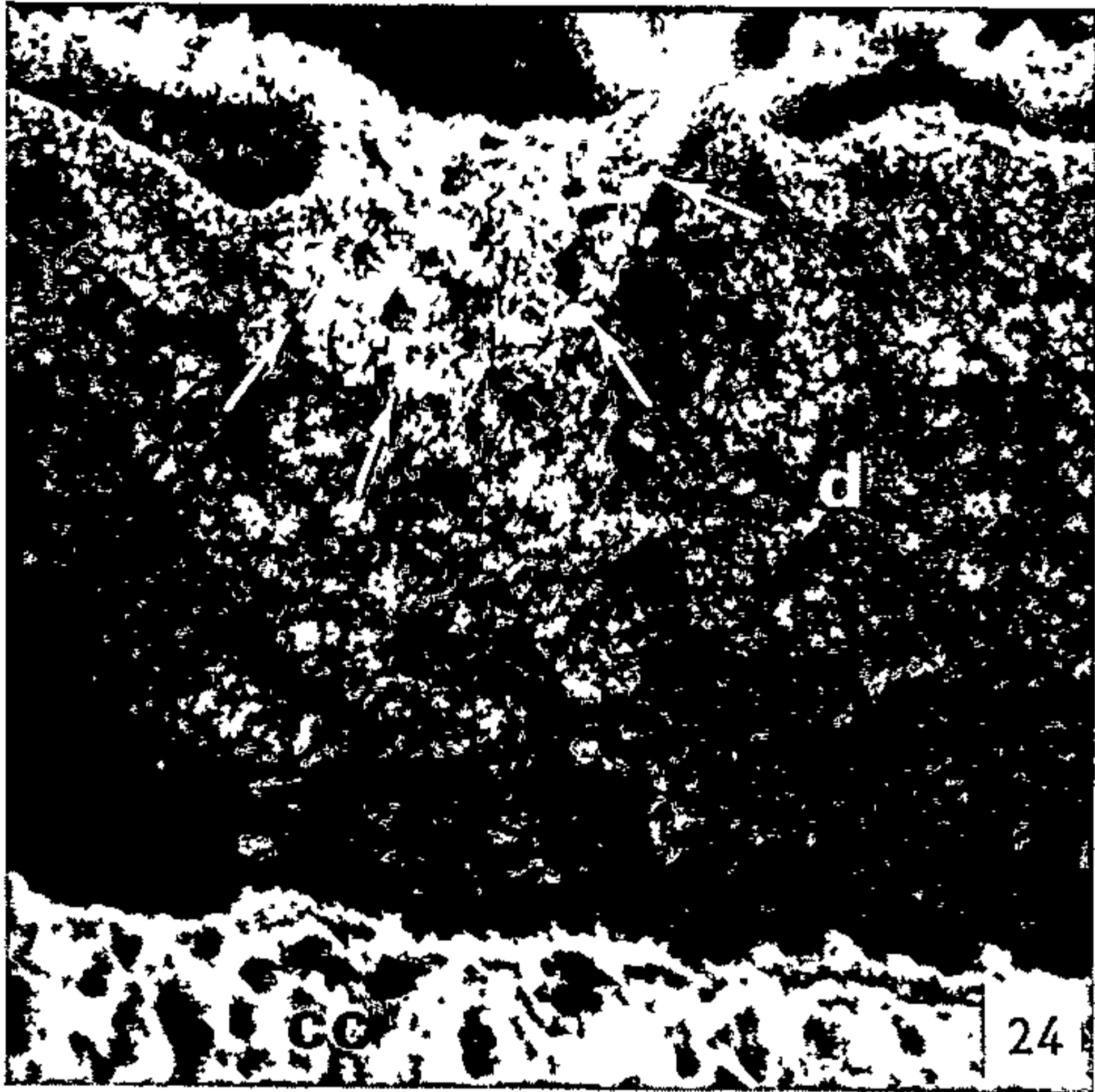
FIGS. 25-28. Undersurface of lower right 1st molar at 39 days.

FIG. 25. Survey view of pattern of seams and the two areas examined at higher magnification in Figs. 26 and 27. $\times 45$.

FIG. 26. Typical pattern of seam on roots—a central groove, with some cross-bridging, and relatively short ridges on either side (for localization see Fig. 25). $\times 890$.

FIG. 27. Typical pattern of seam on undersurface of crown (for localization see Fig. 25). Note the lacunae and the resemblance to functional cellular cementum (cf. Fig. 28). $\times 400$.

FIG. 28. Stereo pair of cellular cementum from the root surface. The cementum is of the functional attachment-type with its lacunae and mineralized Sharpey fiber bundles (at arrows). $\times 915$.



This study provides previously unobtained three-dimensional images of the developing rat molar root. The significance of the study rests with these images and the unique visual concept of the subject matter provided by them. The size of the rat molar together with the range of magnifications provided by the scanning microscope means that a single image may be formed in which all roots of any one tooth are represented, and that selected areas may be further examined at higher magnification. This kind of direct observation provides information on morphology as well as ultrastructure and simplifies the task of comparing a given area in a given tooth-type through different stages of development.

We are happy to thank Mr P. S. Reynolds for his obliging help with all aspects of the work. We also wish to acknowledge the continuing enthusiasm and support given us by Professor J. Z. Young and Dr J. A. G. Rhodin. We thank Mrs Betsey Stiepock and Mrs Jeanne Mills for their secretarial assistance. The Cambridge Instrument Co. *Stereoscan* was provided by the U.K. Science Research Council. The study was supported principally by a grant from the U.K. Science Research Council, and, in part, by a grant from the U.S. Public Health Service (DE-02274-06), and another from the U.K. Medical Research Council.

REFERENCES

1. BOYDE, A., *J. Dent. Res.* **47**, 1007 (1968).
2. BOYDE, A. and JONES, S. J., *Z. Zellforsch. Mikrosk. Anat.* **92**, 536 (1968).
3. BOYDE, A. and REITH, E. J., *Z. Zellforsch. Mikrosk. Anat.* **94**, 479 (1969).
4. DIAB, M. A. and STALLARD, R. E., *Periodontics* **3**, 10 (1965).
5. DIAMOND, M. and APPLEBAUM, E., *J. Dent. Res.* **21**, 403 (1942).
6. FARBMAN, A. I., *Develop. Biol.* **18**, 93 (1968).
7. LESTER, K. S., *J. Ultrastruct. Res.* **27**, 93 (1969 a).
8. ——— *ibid.* **28**, 481 (1969 b).
9. ORBAN, B. and MUELLER, E., *J. Amer. Dent. Assoc.* **16**, 297 (1929).
10. PAYNTER, K. J. and PUDY, G., *Anat. Rec.* **131**, 233 (1958).
11. SCHOUR, I. and MASSLER, M., *J. Amer. Dent. Assoc.* **27**, 1778 (1940).
12. SELVIG, K. A., *Acta Odontol. Scand.* **21**, 175 (1963).
13. ——— *ibid.* **22**, 105 (1964).
14. SMILEY, G. R. and DIXON, A. D., *Anat. Rec.* **161**, 293 (1968).
15. STERN, I. B., *Amer. J. Anat.* **115**, 377 (1964).

Retyped from The Endodontic Newsletter Vol. 1, No. 5, pages
12-18, November, 1972.

Molar Root Development in the Laboratory Rat:

Keith S. Lester, "Wyoming", 175 Macquarie Street,
Sydney, N.S.W. 2000.

Introduction:

The laboratory rat (Rattus norvegicus) is widely used as an in vivo substitute for man. The Rodentia are both the most successfully adapted and the most populous of the mammalian orders - and herein lies the basic rationale of their experimental use: availability and expendability. And yet it can be said, despite the wide diversity of adaptation found in the rodents, that the laboratory rat is dentally atypical of that order. The rat is monophyodont (develops one dentition only) whilst the rodent majority is diphyodont⁴⁰. The rat has brachyodont molars (the roots are longer than the crown) whilst the rodent majority has hypsodont molars.

Compared with Homo sapiens, in whose name and for whose welfare sacrifice is made, the rat is at best dentally dissimilar. The dental formula for the human is 2, 1, 2, 3

and for the rat 1, 0, 0, 3 (the rat having no canines or premolars but a large diastema between the incisors and molars used as a food pouch).

The rat incisor is continually forming and continually erupting) at a rate which achieves total replacement of its length in 45 days³⁴. The incisor is covered by enamel for only one third of its circumference, acellular cementum covering the remainder. The intricacy and complexity of the arrangement of the enamel rods is unique and permits, of itself, identification of some individual species. The outer layer of enamel in some rodent incisors contains an iron-based pigment.

Rat molars have enamel-free areas on the cusps as a result of isolated failure of ameloblast maturation rather than attrition. Heavy wear increases the size of these areas subsequently, however. Two aspects of the rat molar are of more immediate endodontic interest. Firstly, one third of the bulk of the root is composed of cellular cementum. Secondly, the mode of root formation differs from that described for the human^{21,22}. It is this latter feature which will be discussed further for it raises a number of

interesting issues.

Usual Sequence of Events in Mammalian Tooth Root Formation:

The classically held view of histological events leading to root formation in mammals is as follows^{9,16,28}:

- i) proliferation of the cells of the epithelial root sheath of Hertwig providing the future profile of the root;
- ii) differentiation of the cells of the dental papilla (future dental pulp) to odontoblasts;
- iii) deposition of dentine matrix and its mineralization;
- iv) degeneration of epithelial sheath cells;
- v) establishment of contact between mineralized dentine and cells of the dental sac (future periodontal membrane) resulting in the differentiation of cementoblasts;
- vi) deposition of cementum matrix and its subsequent mineralization.

Epithelial cells surviving the breakdown (iv above) migrate to the periodontal membrane where they are found in the adult as epithelial rests of Malassez^{26,41}.

Rat Formation in the Rat Molar:

A fundamentally different sequence of events has been found to occur in the cellular cementum phase of root formation in the rat molar^{21,22}. The essential difference is that cells of the epithelial root sheath do not degenerate and disperse in the normal way but are imbedded at the apically advancing edge of the developing root between cementum and dentine. Further, mineralization of the cellular cementum may actually precede that of the dentine. It follows that contact between the dental sac cells and the mineralized dentine is not a prerequisite to cementoblast differentiation and subsequent cementum production.

Discussion:

A number of interesting questions arise concerning the peculiarities of rat molar root formation.

1. Epithelial-connective tissue interaction:

From an ultrastructural point of view, the most interesting aspect of root development in the rat molar is the unusual relationship between the epithelial tissue and the connective tissue. In text-book accounts, it is the contact between dental sac cells and mineralized dentine that is held to induce dental sac cells to differentiate to cementoblasts^{30,33,35,36}. As stated above, this can not apply to the rat molar during cellular cementum formation. How then are dental sac cells induced to differentiate? There are two histological facts to consider:

- a) epithelial root sheath cells reach a previously unattained level of cyto-differentiation at about the time of cementoblast and odontoblast differentiation;
- b) the sheath basement lamina at this same level is often discontinuous, permitting juxtaposition of epithelial and connective tissue cells.

Both these considerations point to a possible mechanism for the direct exchange of information between the epithelial and connective tissue compartments. Such exchanges have been demonstrated and/or suggested in other developmental systems (eg. tooth bud initiation, enamel formation, dentine formation, palate formation, epidermal tumours and limb regeneration in amphibians 13,15,31,32).

2. Fate of epithelial cells:

Cells of the epithelial root sheath imbedded between cementum and dentine must degenerate and die if an effective cemento-dentinal junction is to be established. Evidence of this is found and, indeed, one could hardly expect epithelial cells surrounded by non-vascular mineralized tissues to behave otherwise²³. Secondly, if sheath cells are incarcerated, they obviously can not migrate to the periodontal membrane to take up residence as epithelial rests. This is borne out by the fact that only 5-8% of the total epithelial remnants residing in rat molar periodontal membrane are found in the apical region⁴².

3. Occlusal function and cementogenesis:

The peculiarity of root formation in the rat molar may be interpreted as a reversal of the characteristic differential in the rates of formation of dentine and cementum. From a relatively slow¹⁹, but typically mammalian, rate of formation during this acellular phase, the cementum comes to overtake and to precede the dentine at the advancing root edge during its final, rapid, cellular phase^{29,43}. This reversal of the relative rates of formation takes place for the first mandibular molar during the period of from 25-35 days after birth, from which time on cellular cementum constitutes the bulk of the developing root. 25 days after birth is the time at which the first molars are reported as having established initial occlusal contact or as having commenced functional occlusion^{5,8}. It is known that a relationship exists between continued cementum deposition and tooth function. The exact nature and "directness" of the relationship is not known although it has been the subject of considerable discussion eg. ^{1,2,27,37,43}. The timing, however, suggests that the final or cellular cementum phase of root formation in the rat molar is a response to initial

occlusal contact and is directed to the provision of an appropriate supporting apparatus.

4. Incorporation of cells by mineralized tissues:

It is possible to relate the speed of formation of mineralized connective tissues within the dental environment to the degree to which the immediately available cellular elements are incorporated during development. The mineralized connective tissues may be listed in order of their rate of apposition as follows: bone (the most rapid); cellular cementum; dentine; and acellular cementum (the slowest)^{17,18,19,29}. Now bone incorporates its formative cells as well as blood vessels; cellular cementum incorporates its formative cells; dentine incorporates part of the cytoplasm of its formative cells; and acellular cementum, of course, incorporates none of these. Osteocytes remain metabolically active in the adult^{4,6,7}; the long-term fate of odontoblast processes in the dentine is not at all clear^{14,20,24}; there is disagreement over the extent of continued viability of cementocytes^{3,38,39}; and there is evidence of the degeneration of epithelial cells imbedded in cellular cementum²³. It would seem, therefore,

that it is not only the need for a specific cell-type that prompts cell incorporation by a mineralized tissue, and that this process can reasonably be considered in more mechanical terms, namely, the rate at which the tissue forms.

Summary:

There are a number of points which, it is suggested, should be kept in mind when considering the use of the root of the rat molar as an experimental tool (eg. as in^{10,11,12,25}).

- i) The development of the rat molar differs from that described for other mammals.
- ii) The first cells incorporated into "cellular" cementum at the onset of its formation are epithelial.
- iii) At a later stage, the epithelial root sheath is embedded whole at the advancing root edge between cellular cementum and dentine.
- iv) Contact between dental sac cells and mineralized dentine does not occur prior to cementoblast differentiation, the inductive influence more

likely being mediated by the epithelial root sheath.

v) These differences in root development can be related to:

- a) the rapid rate of formation of cellular cementum;
- b) the functional requirements of an erupting tooth coming into initial occlusion.

Conclusion:

The purpose of this paper is to summarize briefly some of the differences between the teeth of rats and humans, more especially the differences in the development of the molar root.

These differences should not be looked upon as an unnecessary and unwelcome complication of endodontic research; a field already fraught with difficulties of specimen collection and preparation, of assessment and sampling, and of extrapolation of results to the clinical arena. Rather, this additional information should be regarded as a means of refining an already useful and rewarding experimental system.

References:

1. Anderson, B.G. et al, Yale J. Biol. Med. 9, 189 (1936).
2. Barton, J.M. and Keenan, R.M., Arch. Oral Biol. 12, 1331 (1967).
3. Bélanger, L.F., Anat. Record 160, 312 (1968).
4. Bélanger, L.F., et al, in Sognaes, R.F. (Ed.) Mechanisms of Hard Tissue Destruction, p. 531. Am. Assoc. Advan. Sci. Washington, D.C., 1963.
5. Bernick, S., Arch. Oral Biol. 2, 57 (1960).
6. Cameron, D.A., Clin. Orthopaed. 26, 199 (1963).
7. Cooper, R.R. et al, J. Bone Joint Surg. 48A, 1239 (1966).
8. Diab, M.A. and Stallard, R.E., Periodontics 3, 10 (1965).
9. Diamond, M. and Applebaum, E.J., J.Dental Res. 21, 403 (1942).
10. Erasquin, J. and Devoto, F.C., Oral Surg. 30, 105 (1970)
11. Erasquin, J. and Muruzábal, M., Oral Surg. 28, 567 (1970)
12. Erasquin, J. and Muruzábal, M., Oral Surg. 29, 91 (1970)
13. Farbman, A.I., Develop. Biol. 18, 93 (1968).
14. Frank, R.M., Arch Oral Biol. 11, 197, (1966).
15. Frei, J.V., J. Cell Biol. 15, 335 (1962).
16. Hertwig, O., Arch. Mikroskop Anat. 11, Suppl. (1874).
17. Hoffman, M.M. and Schour, I., J. Dental Res. 17, 307, (1938).
18. Hoffman, M.M. and Schour, I., Anat. Record 78, 233 (1940).

19. Hoffman, M.M. and Schour, I., Am. J. Orthodont. 26, 854 (1940).
20. James, W.W., Trans. Zool. Soc. London 29, 1 (1957).
21. Lester, K.S., J. Ultrastructure Res. 27, 63 (1969).
22. Lester, K.S., J. Ultrastructure Res. 28, 481 (1969).
23. Lester, K.S., Unpublished work.
24. Lester, K.S., and Boyde, A. in Symons, N.B.B. (Ed.) Dentine and Pulp: Their Structure and Reactions, p. 197, Livingstone, Edinburgh, 1968.
25. Levy, B., J. Dental Res. 47, 323 (1968).
26. Malassez, L., Arch. Physiol. Paris (Ser. 3) 309 and 379 (1885).
27. Michaeli, Y. and Weinreb, M.M., J. Dental Res. 47, 633 (1968).
28. Orban, B., J. Am. Dental Assoc. 15, 1004 (1928).
29. Paynter, K.J. and Pudy, G., Anat. Record. 131, 233 (1958).
30. Provenza, D.V., Oral Histology, p. 293, Lippincott, Philadelphia, 1964.
31. Reith, E.J., J. Ultrastructure Res. 17, 503 (1967).
32. Salpeter, M.M. and Singer, M., Anat. Record 136, 27 (1960).
33. Schour, I., Noyes' Oral Histology and Embryology, 7th. Ed. p. 165. Lea and Febiger, Philadelphia, Pennsylvania, 1953.
34. Schour, I. and Massler, M.J., in Farris, E.J. and Griffith, J.Q. (Eds.) The Rat in Laboratory Investigation, p. 104. Hafner, New York, 1962.

35. Scott, J.H. and Symons, N.B.B., Introduction to Dental Anatomy, 5th. Ed., p. 227. Livingstone, Edinburgh, 1967.
 36. Sicher, H., Orban's Oral Histology and Embryology, 5th. Ed. p. 165. Mosby, St. Louis, Missouri, 1962.
 37. Smith, N.H., Oral Surg. 25, 470 (1968).
 38. Stones, H.H., Brit. Dental J. 56, 273 (1934).
 39. Tagger, M., J. Dental Res. 43, 777 (1964).
 40. Tomes, C.S., A Manual of Dental Anatomy, 8th. Ed. Churchill, London, 1923.
 41. Valderhaug, J. and Nylen, M., J. Periodontal Res. 1, 69 (1966).
 42. Wentz, F.M. et al, J. Dental Res. 29, 637 (1950).
 43. Zander, H.A. and Hürzeler, B., J. Dental Res. 37, 1035 (1958).
-

Elemental Particles in Bone and Dentine

A. Boyde

Department of Anatomy and Embryology, University College London

K. S. Lester

"Wyoming", 175 Macquarie Street, Sydney

Received July 13, 1972

Key words: Particles — Bone — Dentine.

We refer to the communication by M. U. Nylen *et al.* (1972). They state that "only one investigator (Molnar, 1959) has described structures in a mineralizing tissue similar in size and appearance to the elemental particles of the synthetic ACP referred to above". We should like to point out that we have described calcium phosphate particles with a similar shape and size in transmission electron microscopic studies of replicas of peritubular dentine and also in pericanalicular, perilacunar and interlamellar bone (Boyde and Lester, 1967; Lester and Boyde, 1968). As, however, it is difficult to be certain about location with replicas of bone we would not wish to suggest that there is more than a slight indication that equidiametrical calcium phosphate particles are found in these "ground substance matrix locations" in bone. At the time of describing the morphology of the peritubular dentine mineral, we suggested that it might have some relevance to the "amorphous calcium phosphates" described by Termine and Posner (1967) and by Eanes (1970).

References

- Boyde, A., Lester, K. S.: The fine structure of peritubular dentine. *J. Anat. (Lond.)* **102**, 144–145 (1967).
- Eanes, E. D.: Thermochemical studies on amorphous calcium phosphate. *Calc. Tiss. Res.* **5**, 133–145 (1970).
- Lester, K. S., Boyde, A.: The surface morphology of some crystalline components of dentine in N. B. B. Symons (ed.) *Dentine and pulp: Their structure and reactions*. Edinburgh: Livingstone 1968.
- Molnar, A.: Development of the parietal bone of young mice 1. Crystals of bone mineral in frozen-dried preparations. *J. Ultrastruct. Res.* **3**, 39–45 (1959).
- Nylen, M. U., Eanes, E. D., Termine, J. D.: Molecular and ultrastructural studies of non-crystalline calcium phosphates. *Calc. Tiss. Res.* **9**, 95–108 (1972).
- Termine, J. D., Posner, A. S.: Amorphous/crystalline interrelationships in bone mineral. *Calc. Tiss. Res.* **1**, 8–23 (1967).

For reprints: Dr. K. S. Lester, "Wyoming", 175 Macquarie Street, Sydney 2000, Australia.