


**SURGICAL AUGMENTATION OF
THE ATROPHIC ANTERIOR MAXILLARY ALVEOLAR RIDGE
USING HYDROXYLAPATITE:
AN ANALYSIS OF TREATMENT RESULTS**

ALASTAIR ROWAN LOUIS STEVENSON

B.D.S. (London)
F.D.S. R.C.S. (Edinburgh)
F.R.A.C.D.S.
A.K.C.

A THESIS SUBMITTED IN PARTIAL REQUIREMENT
FOR THE DEGREE OF MASTER OF DENTAL SCIENCE

DEPARTMENT OF ORAL MEDICINE AND ORAL SURGERY
FACULTY OF DENTISTRY
UNIVERSITY OF SYDNEY
1988



In Chapter IV the preparation, physical properties and biocompatibility of the calcium phosphate ceramics - hydroxylapatite (HA) and tricalcium phosphate (TCP) - are discussed. The clinical application of these materials in a range of oral and maxillofacial surgical conditions is then described and the materials assessed for their potential role as suitable alloplastic bone substitutes in the facial skeleton and jaws.

Chapter V presents a review of published research into hydroxylapatite, both as granules and blocks, when used exclusively for atrophic ridge augmentation as a subperiosteal onlay. The problem of granule migration is discussed, as are special aspects of prosthodontic care required following the insertion of hydroxylapatite.

Chapter VI details the method and data analysis of 15 patients with anterior maxillary hypermobile tissue who have been treated by the writer using hydroxylapatite granules placed subperiosteally. The surgical technique and the pre- and postoperative care are described in detail, as are the methods of assessment.

Chapter VII presents the results obtained from this group of patients and in Chapter VIII these results are analysed and discussed.

It is concluded, subject to continuing satisfactory long term review, that hydroxylapatite is a useful material for restoring the hypermobile anterior maxillary ridge and in selected cases, offers significant advantages over alternative treatment options.

PREFACE

A man will turn over half a library to make one book.

Samuel Johnson (1709-1784)

The purpose of this thesis is to investigate a solution to the problems created for the patient, prosthodontist and surgeon by the edentulous maxilla which has developed anterior hypermobile alveolar ridge tissue - the so called "flabby ridge."

The objective is to discuss the suitability of hydroxylapatite as a graft material to stabilise and augment this hypermobile ridge, so providing an improved base for supporting a denture. To place the topic in context the following chapters will review the relevant prosthodontic and preprosthetic surgery literature.

Chapter I introduces the problem the profession continues to have in providing stable and retentive dentures on the atrophic ridge and the development of preprosthetic surgery as an interdisciplinary attempt to address some of the causes.

Chapter II will discuss the aetiological factors associated with the development of the atrophic ridge, particularly in the anterior maxilla, and the attempts which have been made to classify the various patterns of atrophy as a diagnostic aid for treatment planning. Factors associated with preprosthetic treatment planning are then discussed, as are the surgical options available to provide a satisfactory denture bearing area.

In Chapter III the early and current surgical procedures which have been developed for the atrophic maxilla are discussed, with particular reference to the hypermobile anterior ridge. Emphasis is placed on the range of graft materials employed.

ACKNOWLEDGEMENTS

I would like to express my particular appreciation to Associate Professor N.H.H. Smith who has acted as my supervisor and to whom I am indebted for providing perceptive advice, constant encouragement and a meticulous appraisal of the manuscript.

Others to whom I am indebted include:

Professor M. Jolly and Dr A. Punnia-Moorthy for providing insightful suggestions for improvements to the manuscript.

Dr B.W. Austin and my other colleagues in the Department of Oral Medicine and Oral Surgery at the University of Sydney, who have assisted me with the surgical procedures and collection of data.

The staff of both the Oral Surgery and Dressings departments of the United Dental Hospital (Chalmers Street, Surry Hills) for their assistance in the operative and postoperative care of the patients.

Drs H. Champion, J. Fisher and S.K. Lechner for providing prosthodontic care for the patients and valuable assistance with assessments.

Mr D. Taylor and the dental technicians of the United Dental Hospital who prepared the models and fabricated the surgical templates, splints and new dentures.

Dr T. Mori for her expertise with the Scanning Electron microscope and providing the scanning electron photomicrographs.

Dr C. Biro for providing the histology report.

Ms J. Matthews for invaluable assistance with graphics, references and the thankless task of proof reading.

Ms C. Reimer and Ms G. Kalmar for typing (and retyping) the manuscript.

Messrs P. Holloman and R. Van Luyn of the Audio-Visual department, Faculty of Dentistry, for assistance with photographic plates.

Sterling Pharmaceuticals Pty. Ltd. for donating the Alveograf HA granules used in the study.

Finally, and most importantly, I wish to express my gratitude to all the patients involved and from whom data was collected, without which this research would not have been possible.

*This thesis is dedicated to my wife Molly,
whose help and encouragement provided
the impetus to complete the project.*

'To steal from one source is plagiarism
To steal from many is research.'

Anonymous

TABLE OF CONTENTS

CHAPTER I

INTRODUCTION	1
1. THE PROBLEM OF THE ATROPHIC ALVEOLAR RIDGE	3
2. RESEARCH AIMS AND OBJECTIVES	9

CHAPTER II

THE ATROPHIC ALVEOLAR RIDGE: AETIOLOGY, DIAGNOSTIC CLASSIFICATION, TREATMENT PLANNING AND SURGICAL OPTIONS	10
1. AETIOLOGICAL FACTORS ASSOCIATED WITH ALVEOLAR RIDGE ATROPHY	12
1.1 Special aetiological factors resulting in the hypermobile anterior ridge in the edentulous maxilla	18
2. DIAGNOSTIC CLASSIFICATION OF THE ATROPHIC ALVEOLAR RIDGE	22
3. PREPROSTHETIC TREATMENT PLANNING	28
3.1 Aims and objectives	28
3.2 Joint consultation	30
3.3 Patient assessment	31
4. PREPROSTHETIC SURGICAL ALTERNATIVES	34

CHAPTER III

SURGICAL TECHNIQUES FOR CORRECTING MAXILLARY ALVEOLAR RIDGE ATROPHY, EXCLUDING THE USE OF CALCIUM PHOSPHATE CERAMICS	42
INTRODUCTION	44
1. REMOVAL OF HYPERMOBILE TISSUE - ALVEOLAR RIDGE CREST	46
2. ABSOLUTE AUGMENTATION	49
2.1 Onlay grafts	50
2.1.1 Autogenous bone - rib	
2.1.2 Autogenous bone - iliac crest	
2.1.3 Allogenuous materials (Allografts)	
2.1.3.1 Allogenuous bone	
2.1.3.2 Allogenuous cartilage	
2.1.4 Alloplastic materials	
2.1.4.1 Metals	
2.1.4.2 Polymers	
2.1.4.3 Ceramics	
Plaster of Paris	
Porous calcium aluminate	
Bioactive glass ceramic	

2.2	Interpositional grafts	69
2.2.1	Total Le Fort I (Sandwich) osteotomy	
2.2.2	Partial Le Fort I (Horseshoe) osteotomy	
2.2.3	Segmental Le Fort I (anterior) osteotomy	
2.3	Relative augmentation	75
2.3.1	Palatal vault osteotomy	
3.	CONCLUSION	78

CHAPTER IV

	CALCIUM PHOSPHATE CERAMICS: PREPARATION, PHYSICAL PROPERTIES, BIOCOMPATIBILITY AND CLINICAL APPLICATIONS	80
1.	HYDROXYLAPATITE (HA) AND TRICALCIUM PHOSPHATE (TCP)	82
1.1	Introduction	82
1.2	Preparation of calcium phosphate ceramics	83
1.2.1	Preparation of the powder	
1.2.2	Compaction and sintering	
1.2.3	Macroporosity - chemically induced	
1.2.4	Macroporosity - physically induced (Replamineform)	
1.3	Mechanical properties	87
1.4	Biocompatibility (tissue response)	88
1.4.1	Subcellular ceramic/bone interface	
1.4.2	Cellular ceramic/bone interface	
1.4.3	Osteogenic stimulation	
1.4.4	Ceramic/soft tissue interface	
1.4.5	Porous ceramics and tissue ingrowth	
1.4.6	Bioresorption	
1.5	Summary	107
2.	CLINICAL APPLICATIONS	109
2.1	Root implants	113
2.2	Periodontal surgery	115
2.3	Dentate ridge augmentation	117
2.4	Augmentation osteotomies	119
2.5	Combined onlay augmentation	121
2.6	Orthognathic and reconstructive surgery	122
2.7	Restoration of pathological tissue loss	125
2.8	Endosteal implants	127
2.9	Conclusion	127

CHAPTER V

	ONLAY AUGMENTATION OF THE ATROPHIC RIDGE WITH HYDROXYLAPATITE (HA)	129
1.	CLINICAL TRIALS OF HA ONLAY AUGMENTATION	131
1.1	Initial multicentre study - granules	131
1.1.1	Assessment	
1.1.2	Modifications	

1.2	Clinical data from other centres - granules	140
1.3	Radiographic evaluation	141
1.4	Maxillary augmentation - granules	144
1.5	Augmentation - HA and TCP blocks	146
2.	CONTROL OF GRANULE MIGRATION	150
2.1	Preoperative	150
2.1.1	Volumetric measurement	
2.2	Intraoperative - physical	151
2.2.1	Surgical splints	
2.2.2	Subperiosteal tissue expanders (STE)	
2.2.3	Mattress sutures	
2.3	Intraoperative - chemical	156
2.3.1	Collagen tubes	
2.3.2	Fibrin adhesives	
2.3.3	Polyglycolic acid	
2.3.4	Plaster of Paris	
3.	POSTAUGMENTATION PROSTHODONTICS	159
3.1	Prosthodontic problems	161
3.1.1	Granule diffusion	
3.1.2	Irregular granule distribution and extrusion	
3.1.3	Incorrect granule position	
3.1.4	Excess increase in alveolar ridge height	
3.1.5	Paraesthesia	
3.1.6	Granule settling and underlying bone resorption	

CHAPTER VI

ANTERIOR MAXILLARY AUGMENTATION USING HYDROXYLAPATITE: METHOD		165
1.	PATIENT SELECTION AND SURGICAL TECHNIQUE	167
1.1	Patient selection	167
1.2	Preoperative preparation	171
1.3	Surgical technique	178
1.4	Postoperative sequelae	189
1.5	Prosthodontic rehabilitation	192
2.	AQUISITION AND ANALYSIS OF DATA	195
2.1	Patient questionnaire	195
2.2	Prosthodontic questionnaire	197
2.3	Surgical evaluation	198
2.4	Histology	198
2.5	Radiographs	199
2.6	Study models	200

CHAPTER VII

ANTERIOR MAXILLARY AUGMENTATION USING HYDROXYLAPATITE: RESULTS AND OBSERVATIONS		208
1.	PATIENT QUESTIONNAIRE	210
2.	PROSTHODONTIC QUESTIONNAIRE	219
3.	SURGICAL EVALUATION	222
3.1	Surgical technique and complications	222
3.2	Surgical assessment	229

4. HISTOLOGY	237
5. RADIOGRAPHS	239
6. STUDY MODELS	253
6.1 Composite tracings	253
6.2 Measurements of cross-sectional areas	257

CHAPTER VIII

DISCUSSION AND CONCLUSION	268
-------------------------------------	-----

1. DISCUSSION	270
1.1 Surgical technique	270
1.2 Assessment	273
1.2.1 Subjective assessments - Patient, Prosthodontist and Surgeon	
1.2.2 Objective assessments - Histology, Radiographs and Study models	
2. CONCLUSION	293

REFERENCES	295
----------------------	-----

APPENDICES	320
----------------------	-----

I Companies manufacturing commercially available HA and TCP	321
II Patient questionnaire	322
III Prosthodontic questionnaire	323
IV Oral surgery assessment	324
V Specimen photocopy from which tracings were made	325
VI Specimen tracing	326
VII Patient questionnaire, summary of results	327
VIII Prosthodontic questionnaire, summary of results.	328
IX Oral surgery assessment summary	329

ENCLOSURES	330
----------------------	-----

I Stevenson ARL. Hydroxylapatite and its role in ridge augmentation and preservation. Aust Prosthodont J 1987; 1: 29-40	
II Stevenson ARL, Austin BW. Subperiosteal tissue expanders as an adjunct to alveolar augmentation with hydroxylapatite. 1988; Abstr. ANZOMS XIIIth conference	
III A description of the surgical techniques for HA augmentation of the anterior maxilla based on the conclusions reached in this thesis	

LIST OF TABLES

1	Possible aetiological factors associated with alveolar ridge atrophy.	17
2	Clinical features as indicators for selection of the appropriate preprosthetic surgical technique	35
3	Surgical options for correcting common maxillary prosthodontic problems	40
4	Maxillary preprosthetic surgical procedures	45
5	General characteristics of HA and TCP	108
6	Commercially available calcium phosphate ceramics.	110
7	Clinical indications for different HA products.	112
8a	Use of HA granules for orthognathic surgery.	123
8b	Use of textured dense HA blocks for orthognathic surgery	123
9	Basic data from the American multicentre study	135
10	Past medical histories and current medications of patients chosen for HA augmentation	168
11	Demographic data and past dental history of the patients chosen for HA augmentation	169
12	A summary of the patient data.	172
13	Submucous vestibuloplasty with anterior maxillary augmentation - surgical data.	175
14	A summary of the surgical data	190
15	The collection times of the patient and prosthodontic assessments following receipt of the new dentures	193
16	The postoperative months when radiographs, photographs and models were collected	196
17	Measurements from experimental model tracings.	207
18	Patient's comments on their old and new maxillary dentures	213
19	Complications associated with the surgical techniques of submucous vestibuloplasty and anterior maxillary HA augmentation	224
20	A summary of the intra- and postoperative complications	225
21	Complications associated with the HA granules	226

22	Radiographic measurements	240
23	Alveolar ridge cross-sectional areas	259
24	Percentage changes in cross-sectional area over 18 months	264
25	Percentage changes averaged for each cross-sectional area size group	265
26	Patients' general satisfaction with their postaugmentation dentures - a comparison	278
27	Comparison of the good and excellent categories for all patient assessment parameters postaugmentation	280
28	Prosthodontists' assessment of denture stability - a comparison	281
29	Prosthodontists' assessment of denture retention - a comparison	282
30	Clinical assessment by the Prosthodontists - a comparison	284
31	Assessment by the Oral Surgeons - a comparison	285
32	Retention of granules assessed radiographically - a comparison	288
33	Radiodensity (bone infiltration) assessed radiographically - a comparison	290

LIST OF FIGURES

1	The interdependence of retention, stability and support	5
2	The five clinical features associated with the 'combination syndrome'	19
3	Six additional features associated with the 'combination syndrome'	19
4	The Moses atrophic ridge classification	23
5	The Atwood atrophic ridge classification	23
6	The Leckholm and Zarb atrophic ridge classification.	23
7	A sagittal section to illustrate the wedge resection of anterior maxillary hypermobile ridge tissue	47
8	A sagittal section to illustrate the resection of anterior maxillary hypermobile ridge tissue via the sulcus	47
9	A coronal section through the lateral maxilla to illustrate the position of a transoral rib graft	52
10	An illustration of an autogenous onlay graft (iliac crest) secured with threaded endosteal implants	52
11	An illustration of the total Le Fort I osteotomy with interpositional bone graft (Sandwich).	72
12	An illustration of the onlay graft position in the partial Le Fort I osteotomy (Horseshoe)	72
13	A sagittal section showing the repositioning of the palate following the palatal vault osteotomy	77
14	A series of sagittal sections to demonstrate the rotated palatal pedical flap.	77
15	A sagittal section showing HA augmentation of the dentate maxillary ridge	118
16	An illustration of an anterior sandwich osteotomy with HA granules used posterior to the mental foramen	118
17	A histogram showing radiographic assessment of ridges augmented with HA and HA with bone	137
18	A histogram showing surgical and prosthodontic assessments of patients who received augmentation with HA alone.	137
19	A histogram of the patient's evaluation of general satisfaction with postaugmentation dentures	138

20	A histogram of the patient's evaluation of denture comfort	138
21	A histogram showing radiographic measurements of mandibular heights following augmentation with HA and HA with bone	143
22	An open tunnel technique for placement of HA granules	145
23	A sagittal section of the mandibular symphysis region showing the stages of an open tunnel technique	145
24	A labio-palatal section of the atrophic maxilla to show the position of a subperiosteal tissue expander (STE)	154
25	A labio-palatal section of the maxilla in the canine region	176
26	The position and extent of the submucous vestibuloplasty	177
27	The relative positions of the submucous vestibuloplasty and the subperiosteal tunnel	180
28	The position of the periosteal division.	181
29	The position of the reverse incisions into the hypermobile tissue	182
30	The position of the HA granules following augmentation.	184
31	The position of the surgical splint	188
32	A histogram of the patients' assessments of their ability to eat	212
33	A histogram of the patients' assessment of speech	212
34	A histogram of the patients' assessment of denture comfort.	214
35	A histogram of the patients' assessment of denture fit	214
36	A histogram of the patients' assessment of appearance	216
37	A histogram of the patients' assessment of their ability to taste	216
38	A histogram of the patients' assessment of general satisfaction	218
39	A histogram of the prosthodontic clinical assessment	218
40	A histogram of the prosthodontic assessment of retention	220
41	A histogram of the prosthodontic assessment of stability.	220
42	A histogram of the prosthodontic assessment of mucosal health	223
43	A histogram of the oral surgery assessment	223
44	Composite radiographic tracings; patients 1, 2 and 4	242

45	Composite radiographic tracings; patients 5-7.	243
46	Composite radiographic tracings; patients 8-10	244
47	Composite radiographic tracings; patients 11-13	245
48	Composite radiographic tracings; patients 14 and 15.	246
49	Composite study model tracings; patients 1-5.	254
50	Composite study model tracings; patients 6-10	255
51	Composite study model tracings; patients 11-15	256
52	Alveolar ridge cross-sectional areas over 18 months; patients 1-6	260
53	Alveolar ridge cross-sectional areas over 12 months; patients 7-10	261
54	Alveolar ridge cross-sectional areas over six months; patients 11-15	262
55	Initial and subsequent cross-sectional areas following augmentation relative to the preoperative area	267

PLATES

1	Seventeenth century print of a patient fitted with dentures retained by springs	5
2	An orthopantomogram (OPT) showing anterior maxillary bone loss associated with retained anterior mandibular teeth	26
3	A demonstration of augmentation heights dependent on the ridge width and cross-sectional shape.	26
4	A scanning electron photomicrograph of chemically induced macroporosity.	86
5	A scanning electron photomicrograph of physically induced macroporosity (Replamineform)	86
6	A photomicrograph of a bone/HA interface	91
7	A photomicrograph of HA granules within mature bone	91
8	A scanning electron photomicrograph of dense, smooth HA granules	99
9	A scanning electron photomicrograph of dense, irregular HA granules	99
10	A scanning electron photomicrograph of a TCP granule surface	105
11	A scanning electron photomicrograph of a dense HA granule surface	105
12	A lateral cephalometric radiograph demonstrating a subperiosteal tissue expander (STE)	154
13	A demonstration of maxillary ridge hypermobility prior to surgery.	174
14	The preparation of the patients' dentures for use as a surgical splint	174
15	Surgical technique - midline incision	176
16	Surgical technique - submucous vestibuloplasty	177
17	Surgical technique - subperiosteal tunnel	180
18	Surgical technique - division of the buccal periosteum	181
19	Surgical technique - incising the hypermobile tissue	182
20	Preparation of the HA granules	185
21	Surgical technique - placing the HA granules.	184

22	Surgical technique - placing the surgical template	185
23	Surgical technique - wound closure	187
24	Surgical technique - lining the surgical splint.	187
25	Surgical technique - fixation of the surgical splint	188
26	The distribution of postsurgical ecchymosis	191
27	The augmented ridge three weeks following surgery	191
28	Preparation of models prior to analysis	202
29	The models in place on a photocopier	202
30	The image analysis system and computer used for analysis	205
31	A detail of the digitizing pad	205
32	Patient 3; prior to augmentation	231
33	Patient 3; six months postaugmentation	231
34	Patient 5; prior to augmentation	232
35	Patient 5; 12 months postaugmentation.	232
36	Patient 7; prior to augmentation	233
37	Patient 7; six months postaugmentation	233
38	Patient 9; prior to augmentation	234
39	Patient 9; six months postaugmentation	234
40	Patient 10; prior to augmentation	235
41	Patient 10; 12 months postaugmentation	235
42	Patient 12; prior to augmentation	236
43	Patient 12; three months postaugmentation	236
44	A low power photomicrograph of the biopsy material (patient 11)	238
45	A high power photomicrograph of the biopsy material (patient 11)	238
46	Patient 2; a preaugmentation lateral cephalometric radiograph	248
47	Patient 2; a 12 month postaugmentation lateral cephalometric radiograph	248
48	Patient 10; a preaugmentation OPT	249
49	Patient 10; a six month postaugmentation OPT	249

50	Patient 10; a preaugmentation lateral cephalometric radiograph	250
51	Patient 10; a six month postaugmentation lateral cephalometric radiograph	250
52	Patient 11; a preaugmentation OPT	251
53	Patient 11; a one day postaugmentation OPT	251
54	Patient 11; a preaugmentation lateral cephalometric radiograph	252
55	Patient 11; a one day postaugmentation lateral cephalometric radiograph	252

LIST OF ABBREVIATIONS

AAA	autolyzed antigen-extracted allogenuous bone
ANS	anterior nasal spine
BMP	bone morphogenetic protein
CVA	cerebrovascular accident
CMI	Cornell medical index
HA	hydroxylapatite
LC	lateral cephalometric
MI	Myocardial infarct
OPT	orthopantomogram
p.s.i.	pounds per square inch
SMV	submucous vestibuloplasty
STE	subperiosteal tissue expander
TCP	tricalcium phosphate

NUMBERS

Throughout the text numbers from one to nine will be spelt out in full, numbers greater than nine will be presented as figures except where they start a sentence.

Exceptions to this rule have been made where the number refers to a length, volume, weight, concentration, magnification, temperature, per cent, patient number or in tables, figures, plates, statistics or a series of time (for example 3, 6, 12 and 18 months). In these cases the number will be expressed as a figure irrespective of the denomination.

Roman numerals are also used where appropriate.

CHAPTER I

INTRODUCTION

CHAPTER I

INTRODUCTION.	1
1. THE PROBLEM OF THE ATROPHIC ALVEOLAR RIDGE	3
2. RESEARCH AIMS AND OBJECTIVES	9

1. THE PROBLEM OF THE ATROPHIC ALVEOLAR RIDGE

Removing the teeth will cure something, including the foolish belief that removing the teeth will cure everything.

Anonymous

The provision of a stable prosthesis to replace the loss of natural teeth has been the aim of the dental profession for many centuries, as evidenced by the carved prostheses, secured by gold wire, from the time of the Etruscans and Phoenicians. The necessity for the gold wire, or other ligatures, used well into the 19th century, is confirmation that both retention and stability of the prostheses were the profession's major problems. This was particularly true for the edentulous state and it was common practice, until the late 19th century, for denture wearers to actually remove their teeth prior to eating, their value being purely cosmetic (Zarb 1985).

Confirmation is found in the following quotation, cited by Woodforde (1968) from an 1846 textbook of dentistry.

"That it is a much easier task to make artificial teeth ornamental than useful, may be inferred from the fact that in by far the greater number of cases, they are much too insecure in the mouth to admit of any attempt at complete mastication of the food without displacement."

Even the rich and powerful were not immune. George Washington, the first president of the United States of America, had a checkered dental history, never managing to replace his lost teeth with anything aesthetically or functionally satisfactory. Washington's dental problems are evident even today in the portrait of him reproduced on the current American one dollar note, his tight lips concealing cloth placed in the mandibular vestibule to enhance his profile (Woodforde 1968).

Pierre Fauchard, French surgeon of the 18th century, was the first to introduce springs to retain dentures and aid mastication. They were developed and used extensively during the 19th century and feature in both print (King Solomon's Mines by Rider Haggard 1885) and illustration (Plate 1).

Even after springs had been superseded by the application of 'atmospheric pressure' theory (the creation of a palatal vacuum), successful mastication was still a problem and Conan Doyle in one of his Sherlock Holmes novels, 'A Case of Identity', reflected early 20th century attitudes to dentures when he wrote

"He had drifted into the habit of winding up every meal
by taking out his false teeth and hurling them at his wife."

With the passage of time the dental profession has become more successful in the provision of satisfactory dentures. This advance, in part due to developments in both materials and techniques, now provides the majority of patients with dentures which are both functionally and cosmetically acceptable.

Despite the accomplishments of the well-trained prosthodontist there is still a large number of patients who experience significant prosthetic difficulties and some who find the wearing of dentures either a great burden or impossible.

A 1967 survey of United States denture wearers quoted by Rothstein et al (1984C) recorded a total of 37,700,000 people wearing dentures of whom 42 per cent admitted to trouble with their dentures. As over half of the total were complete denture wearers a conservative assessment can be made that eight million edentulous patients in the United States experience problems with their dentures.

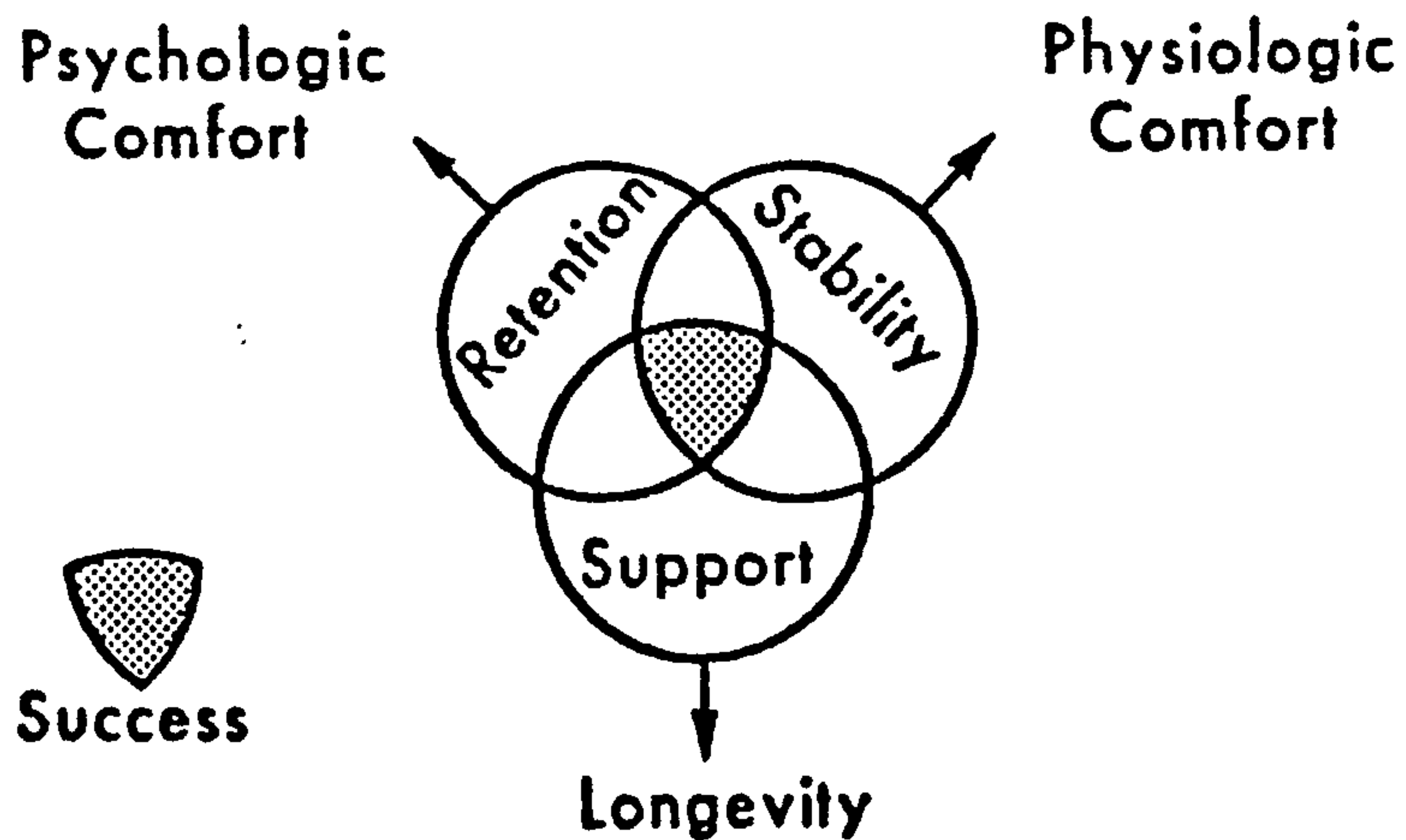
The view is taken in some quarters that this group will diminish significantly in number because the natural dentition is now being successfully retained. Unfortunately the ravages of caries and poor oral hygiene plus decades of poor treatment planning, unnecessary extractions,

PLATE I



A Rowlandson print (1811) of the French dentist, Dubois de Chemant, showing off the mouth of a woman fitted with a double row of his mineral paste teeth and gums. So wide is her smile, the springs between them can just be seen. A man in great need of dental treatment stares through a double lorgnette. (Woodforde 1968).

FIG. 1 THE INTERDEPENDENCE OF RETENTION, STABILITY AND SUPPORT



Jacobson and Krol (1983)

untreated periodontal disease and failed restorations have created a situation where many patients have been rendered edentulous by middle age. As life expectancy increases, they have the prospect of coping with unsatisfactory dentures for many years.

The profession has long recognised that the quality of the alveolar ridge and its overlying tissue is one of the many factors that contribute to the provision of a satisfactory denture. The alveolar ridge is crucial to retention, stability and support. (Retention is the resistance to displacement away from the ridge, stability the resistance to horizontal and rotational forces, and support the resistance to vertical movement towards the ridge.) These three factors, as graphically represented by Jacobson and Krol (1983), can each adversely affect the others if inadequate (Fig. 1).

Appreciation of the important role played by the supporting tissues and the prosthodontic problems engendered by their resorption and atrophy have generated extensive research. The sequence of progressive atrophy of the alveolar ridge, its possible aetiology and the various prosthodontic and surgical solutions have all received attention. Much of the work has tended to concentrate on the mandible. This must, in part, be due to the greater difficulty patients experience in controlling the mandibular denture when compared to the maxillary denture; and, in part, because mandibular resorption is more visible, the rate being four times that of the maxilla. (Tallgren 1972).

The maxilla also, however, is susceptible to prosthetic problems and one in particular is the development of the hypermobile anterior alveolar ridge often associated with retained natural mandibular anterior teeth. Hypermobile fibrous tissue, in its turn, can be the precursor for a range of other changes which are detrimental to successful dentures. These changes are more fully discussed in Chapter II.

Increased awareness of these prosthodontic problems has also led to the emergence of preprosthetic surgery as an expanding field in oral and

maxillofacial surgery.

Preprosthetic surgery is essentially the surgical preparation of either a fully edentulous or partially edentulous mouth prior to the construction of dentures (Lawson 1972). It has developed from the simple dento-alveolar correction of irregularities, exostoses and hyperplastic tissue, to the various vestibule lowering procedures, thence to the major surgery of onlay and inlay augmentations and then into a new era of scientifically tested and successful implants, which have been aptly labelled 'A third dentition?' by Taylor (1986).

Preprosthetic surgical procedures are however still viewed with suspicion by some prosthodontists. This reluctance may well be due to their lack of exposure to the various techniques that have been developed. A survey of members of the Federation of Prosthodontic Organisations conducted by Meador et al (1986) is evidence of this. When asked to name their preferred method for augmentation, of the specialist prosthodontists surveyed, 24 per cent admitted to having no experience of surgical augmentation in the maxilla and 9 per cent no experience of surgical augmentation in the mandible. Interestingly, of those with maxillary augmentation experience, 32 per cent chose augmentation with alloplastic materials, in preference to autogenous bone grafts (27 per cent) and implants (10 per cent).

In commenting on these and other results from the survey the authors concluded that in many areas there was no consensus on the parameters for the surgical management of the prosthodontic patient, such as a minimum adequate ridge height and the anatomical areas most appropriate for increasing vestibular depth.

It is to be hoped that a consensus can be reached by the profession as to the role of surgery in the provision of dentures. Having rendered a patient edentulous, the profession has the ethical responsibility to restore the dentition both functionally and aesthetically. With the range of surgical procedures ever increasing and taking into account the success of the newly

available implant systems, the profession must be aware of the range of surgical options available to answer the many and varied clinical problems. Zarb (1985) in discussing the nature and significance of the edentulous state, warned that

"In a clinical therapeutic context, the edentulous elderly patient with advanced residual ridge reduction presents one of the greatest challenges facing the dental profession today."

2. RESEARCH AIM AND OBJECTIVES

The recognition of the existence of a problem is the first step in its solution.

Martin Fischer (1879-1962)

The aim of this research is to investigate the suitability of the alloplastic material hydroxylapatite as a graft material for the augmentation and stabilisation of the hypermobile anterior maxillary alveolar ridge.

The objectives are to describe how the surgical procedure required to place the hydroxylapatite in the anterior maxilla is performed. Also how to minimise the complications, manage the postoperative sequelae and provide new dentures. A further objective is to present the methods developed for analysis of the surgical results and then to use the results to assess the value of the technique as a solution to the problem of hypermobile alveolar ridge tissue.

CHAPTER II

THE ATROPHIC ALVEOLAR RIDGE : AETIOLOGY, DIAGNOSTIC CLASSIFICATION, TREATMENT PLANNING AND SURGICAL OPTIONS

CHAPTER II

THE ATROPHIC ALVEOLAR RIDGE: AETIOLOGY, DIAGNOSTIC CLASSIFICATION, TREATMENT PLANNING AND SURGICAL OPTIONS	10
1. AETIOLOGICAL FACTORS ASSOCIATED WITH ALVEOLAR RIDGE ATROPHY	12
1.1 Special aetiological factors resulting in the hypermobile anterior ridge in the edentulous maxilla	18
2. DIAGNOSTIC CLASSIFICATION OF THE ATROPHIC ALVEOLAR RIDGE	22
3. PREPROSTHETIC TREATMENT PLANNING	28
3.1 Aims and objectives	28
3.2 Joint consultation	30
3.3 Patient assessment	31
4. PREPROSTHETIC SURGICAL ALTERNATIVES	34

1. AETIOLOGICAL FACTORS ASSOCIATED WITH ALVEOLAR RIDGE ATROPHY

Last scene of all...

Sans teeth, sans eyes, sans taste, sans everything.

Wm. Shakespeare (1564-1616), As You Like It.

Boucher (1960), in concluding his review of the then current status of prosthodontics, posed 23 questions pertinent to the future of that specialty. He asked 'How can the quality of bone for the support of dentures be determined accurately?' and later 'What are the specific cellular changes that occur when pressures are applied to denture-supporting tissues?'. Twenty eight years later, despite considerable research, answers to these questions are still being sought as atrophy proceeds unchecked in all unfortunate enough to have been rendered edentulous.

In the initial part of this literature review, theories pertaining to the aetiology of generalised alveolar bone atrophy will be discussed concluding with special emphasis on the anterior maxillary alveolar ridge.

Thoma and Holland (1951) discussed atrophy of the edentulous mandible and outlined various aetiological factors. They identified local causes such as disuse, pressure, the loss of teeth and their periodontal structures and systemic factors such as senile atrophy and endocrine influences. They felt that decreased function resulted in a diminished blood supply and consequently a reduction in the normal process of bone replacement, leading eventually to osteoporosis and atrophy.

Bradley (1981) confirmed that the blood supply to the mandible diminished with age but did not link it to decreased function. Pogrel et al (1987) demonstrated loss of arterial patency and hypothesised that a combination of this loss and denture pressure on the periosteal blood supply

could cause local ischaemia and subsequent bone loss. Atrophy under pressure seemed paradoxical to Thoma and Holland (1951). They held that functional pressure should stimulate the production of new bone and therefore patients without teeth or a full denture, they felt, should be more prone to atrophy when in fact their findings showed it was denture wearers who exhibited the greater degree of atrophy. They concluded that pressure beneath a complete denture must exceed the physiological limits to stimulate alveolar bone and consequently resorption predominates. They further conjectured that the bone loss initiated by advanced periodontal disease could continue even after the removal of the affected teeth, thereby hastening resorption. Today, in the light of our knowledge of periodontally induced bone loss, this latter statement can be discounted.

Lammie (1960) proposed a novel mechanism for ridge reduction. Resorption, he postulated, was due to pressure applied to the ridge by the atrophying overlying mucosa with the degree of resorption dependent on the 'resistance' from the bone itself. Therefore where bone 'resistance' was low and mucosal atrophy marked, for example at menopause and in the aged, ridge resorption would result. Lammie conceded that a complete denture base could play its part in the resorption force but as the force is intermittent rather than continuous, he felt, it was less likely to cause resorption. He did, however, concede that localized high incidences of pressure could cause circumscribed resorption and replacement of bone by fibrous tissue. He noted that this was most often seen clinically when a complete maxillary denture with porcelain teeth was opposed only by the natural lower anterior teeth. This ultimately led to the anterior maxillary region becoming both fibrous and hypermobile. He concluded that the mobile mucosa had no tendency to contract but the bone was resorbed directly as a result of excessive pressure. No confirmatory evidence to support Lammie's atrophic mucosal pressure hypothesis has been forthcoming and it therefore remains unproven.

Atwood (1971), in his classic paper on the resorption of residual ridges, pleaded for the recognition of alveolar ridge atrophy as a disease entity and discussed the pathogenesis, aetiology, treatment and prevention of this condition. He felt this disease (alveolar resorption) was chronic, progressive, irreversible and disabling with a multifactorial aetiology which he divided into four categories, anatomic, metabolic, functional and prosthetic.

Anatomic factors taken into account by Atwood included the size and shape of the ridge and the type of bone and mucoperiosteum. Metabolic factors included age, sex, hormonal balance and osteoporosis. Functional factors included the frequency, direction and amount of force applied to the residual ridge and prosthetic factors included the type of denture base, the form and type of teeth and the inter-occlusal distance. He did not however expand any further on the mechanisms by which these factors worked.

He found that in any individual the rate of resorption would vary at different times and at different sites and this could be related to the co-existence and inter-play of the various aetiological factors at that one time. The value of Atwood's research was to focus attention again on the possible multifarious causes of alveolar ridge resorption and to point out that resorption is an intermittent and not constantly progressive process.

Kelsey (1971) reviewed in detail the effects of denture wearing on alveolar ridge resorption. Following a discussion of the possible prosthetic aetiological factors, he stressed the importance of preventing resorption and recommended five objectives when providing dentures. These recommendations were essentially the basic rules taught to all during their early professional training but always bear repeating. They were:

- To create and maintain mucosal health.
- To avoid using anatomical posterior teeth which create a 'locked' occlusion.
- To provide a meticulous initial occlusal adjustment.
- To instigate a regular recall schedule and correction of any

malocclusion.

- To discourage denture wearing during sleep.

Despite these recommendations adding nothing new to our knowledge, they do emphasise how little can be done to slow the progress of ridge resorption.

Tallgren (1972) conducted a longitudinal study of residual alveolar ridge resorption over 15 years in a group of six patients and 25 years in a further group of 20 patients. Using standardised cephalometric radiographs taken over the 25 year period of wearing complete dentures, she showed that resorption continued throughout the whole observation period. After the initial rapid reduction observed in the first year, the resorption rates and resorption ratios between maxilla and mandible remained fairly constant with the lower ridge being reduced in anterior height by four times in comparison with the upper ridge. However, she found the pattern of alveolar bone loss showed great individual variation.

Tuncay et al (1984) also evaluated skeletal changes in denture wearers over a 10 year longitudinal study by means of standard cephalometric radiographs. They found a counter-clockwise rotation of the maxilla and mandible relative to the skull base, these changes occurring after complete dentures were inserted. They also found significant resorption of the mandibular residual ridges but no significant resorption in the maxilla. Neither did they find any correlation between resorption and the patients' sex, number of years edentulous, the wearing of the dentures at night or skeletal pattern.

Mercier and Vinet (1981) returned to the local and systemic classification of Thoma and Holland. They studied 95 female patients and made some very interesting observations. The local factors they identified as encouraging resorption included continuous wearing of dentures day and night, bruxism and facial (particularly muscular) morphology. They proposed two mechanisms linking resorption with facial morphology, the first related to

the inherent size and quantity of the bones and the second to the different bite force and denture loading generated by different facial types. Patients with a deep overbite and short lower face height (Brachycephalic) had more pronounced atrophy which Mercier and Vinet speculated was due to the greater vertical forces generated in these skeletal types causing excessive occlusal loading.

Turning to systemic factors, they studied the calcium and magnesium serum levels of their patients and found that low serum values for these elements correlated with retained alveolar bone compared with those who had normal calcium and magnesium levels. They concluded that individuals maintaining these good serum levels do so at the expense of their trabecular, including alveolar, bone.

Wical and Brussee (1979) studied the effect of daily calcium and vitamin D supplements on alveolar ridge resorption. Forty six immediate denture patients received either the supplement or a placebo for one year. The patients receiving the supplement showed a mean of 36 per cent less bone loss when compared to the placebo group. However, five patients receiving the placebo had normal calcium-phosphorus ratios and still exhibited bone loss similar to the control patients. This indicates that for the supplement treatment to be effective serum calcium levels would have to be elevated above normal, possibly inducing ectopic calcification.

It is apparent from the foregoing review of alveolar ridge resorption that no single or defined group of aetiological factors has been identified, rather the consensus appears to favour an interrelationship of multiple factors both systemic and local, acquired and inherited (Bays, 1986) (Table 1). Clearly much remains to be done before our knowledge of the controlling factors of alveolar bone loss is clarified.

TABLE 1

**POSSIBLE AETIOLOGICAL FACTORS ASSOCIATED
WITH ALVEOLAR RIDGE ATROPHY**

Systemic Factors

Sex

Race

Bone Diseases

Osteoporosis

-

Senile

-

Postmenopausal

Osteomalacia

-

Primary

-

Secondary to renal failure

Endocrine Disorders

Diabetes mellitus

Primary + Secondary hyperparathyroidism

Drug Therapy

Long term corticosteroids

Heparin

Anticonvulsants

Alcohol

Nutritional Disorders

Low calcium and high phosphate diets

Local Factors

Morphology

Facial height

Facial musculature

Trauma

Exodontia technique

Prosthetic

Pressure loading

Occlusal balance

Parafunctional activity

Poorly fitting dentures

(Bays 1986)

1.1 Special aetiological factors resulting in the hypermobile anterior ridge in the edentulous maxilla

The retention of lower standing anterior teeth in an otherwise edentulous mouth has long been identified as one of the local causes contributing to the creation of the hypermobile anterior maxillary ridge (Carlsson et al 1967). (Plate 2, page 26)

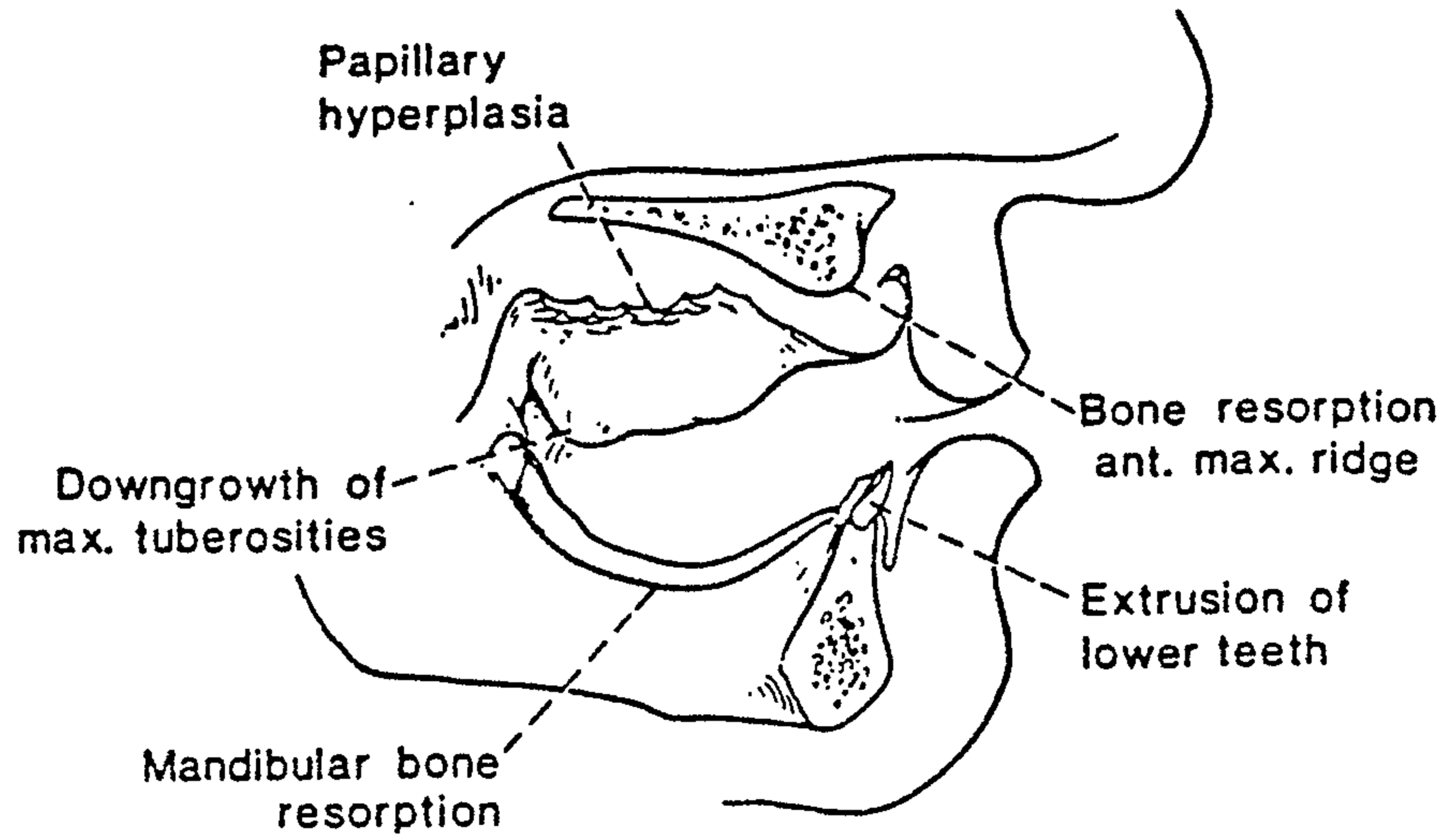
The compressive and rotational forces generated by the standing teeth, transmitted to the maxilla via the maxillary denture, cause resorption of the underlying alveolar bone to a point where the anterior nasal spine can become level with the ridge crest and dehiscence in the bone of the nasal floor can take place. Concurrent resorption of the labial aspect of the alveolar bone causes the ridge crest to move posteriorly and in turn these changes affect upper lip support, culminating in the typical skeletal class III facial form. Thus the prosthodontist is confronted with a denture supporting base that has little vestibular depth, a shallow palate and an anterior ridge composed of fibrous tissue.

Carlsson et al (1967), in a study of contour changes under immediate maxillary dentures, noted that the anterior alveolar changes correlated with the dental status of the lower jaw. Patients with either full lower dentures or a completely dentate lower arch showed less anterior maxillary resorption than patients with only lower anterior teeth standing. This was irrespective of whether a lower partial denture was worn or not.

Kelly (1972) also identified and studied this problem of anterior maxillary resorption and designated the sequelae associated with retained anterior mandibular teeth the 'combination syndrome'. He enumerated five characteristic changes (Fig. 2):

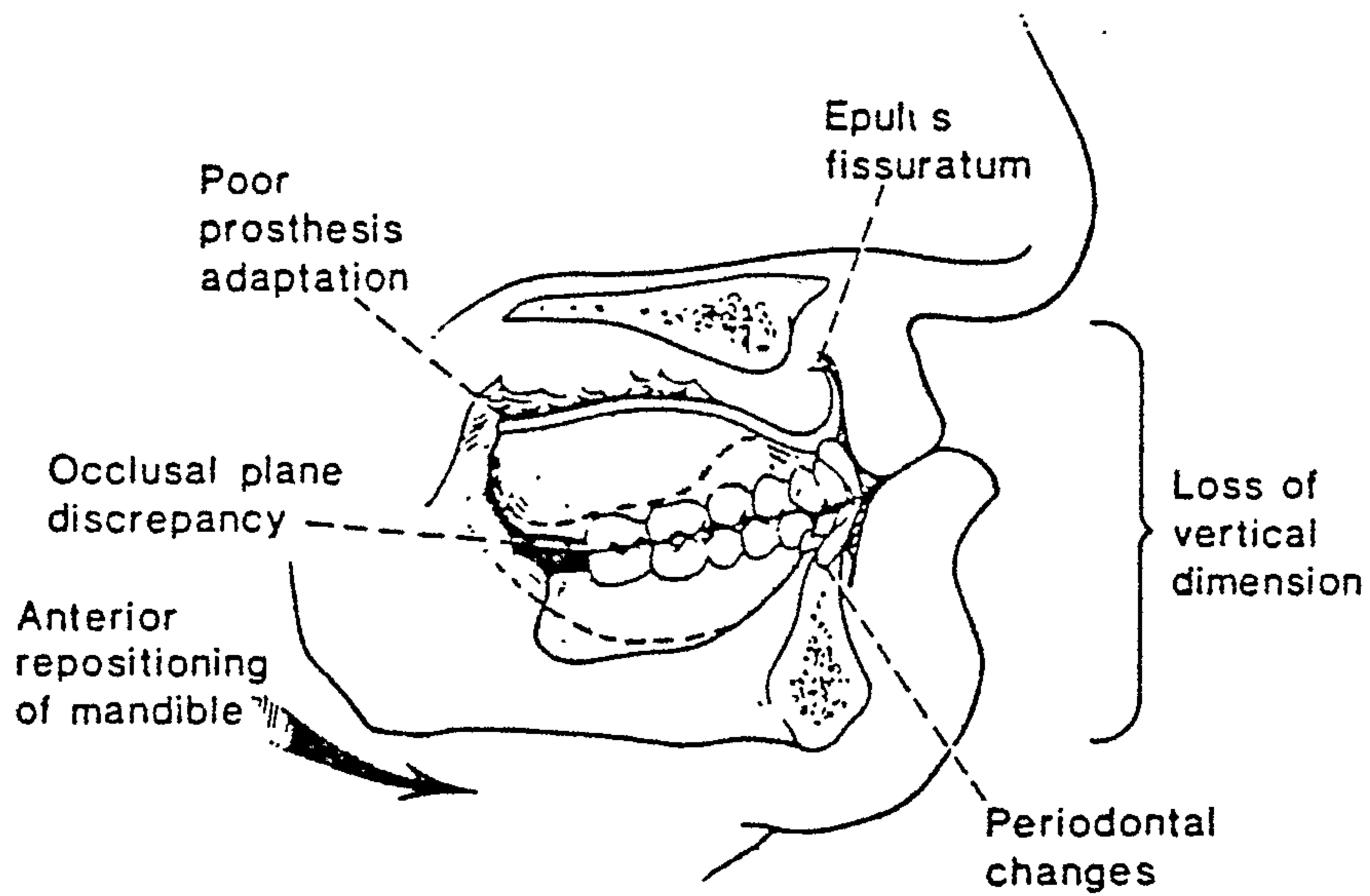
- Loss of bone from the anterior part of the maxillary ridge.
- Overgrowth of the tuberosities.
- Papillary hyperplasia in the hard palate.
- Extrusion of the lower anterior teeth.

FIG. 2



The five clinical changes associated with the 'combination syndrome' as enumerated by Kelly (1972). (From Saunders et al 1979).

FIG. 3



Six additional changes associated with the 'combination syndrome' as enumerated by Saunders et al (1979).

- The loss of distal bone under the partial lower denture.

He found that the early loss of bone from the anterior maxilla, as a result of the uneven occlusal pressure, was the precursor of the other changes. The resulting hypermobile tissue did not support the denture base and folded forward and upwards; the denture would then rotate creating a void posteriorly into which the tuberosities would enlarge and palatal papillary hyperplasia develop. There would then be superior movement of the anterior occlusal plane with corresponding inferior movement posteriorly creating a posterior premature contact. Kelly found that the hypermobile anterior tissue and the fibrous tuberosities were histologically similar, the difference in their mobility being due to the presence or absence of underlying bone. To support his 'combination syndrome' hypothesis, he studied six patients over three years using cephalometric analysis. All patients showed a loss of anterior ridge height with an increase in tuberosity height and extrusion of the lower teeth. He concluded that they all exhibited early signs of the syndrome. To avoid the development of the 'syndrome' he recommended the retention of the mandibular posterior teeth however compromised, the use of a mandibular overdenture and, if necessary, corrective surgery to reduce enlarged tuberosities and remove any papillary or other hyperplastic tissue.

Saunders et al (1979) found Kelly's combination syndrome most appropriate in describing the changes associated with retained mandibular anterior teeth and added six further sequelae they had noted (Fig. 3):

- Loss of vertical dimension.
- A posterior occlusal plane downward rotation.
- Anterior repositioning of the mandible.
- Poor adaption of the denture.
- Epulis fissuratum in the maxillary vestibule.
- Periodontal changes to the remaining anterior mandibular teeth.

They also linked the severity of the resorption to systemic factors such as diabetes, osteoporosis and a skeletal class III jaw relationship. Their

clinical solution was to restrict the function of the anterior maxillary teeth to cosmetic and phonetic purposes, with no incisal contact in centric occlusion and only minimal contact in eccentric positions, always protected by simultaneous posterior contact.

In conclusion, it can be appreciated that the hypermobile anterior ridge in the edentulous maxilla is the forerunner of a set of deleterious changes of considerable consequence and whose ultimate outcome is only now coming to be understood. Particular mention must be made again of Mercier and Vinet's (1981) finding that short faced (Brachycephalic) people are doubly disadvantaged, having less alveolar height and higher biting forces. This has implications for early accelerated resorption compounded subsequently by the resulting loss of vertical dimension. The retention of the mandibular anterior teeth in such a morphological situation would further compromise the maintenance of the anterior maxillary alveolar bone. Any research into resorption preventive systems such as root retention or hydroxylapatite (HA) root implants should concentrate at least initially on this anthropo-morphological group.

2. DIAGNOSTIC CLASSIFICATION OF THE ATROPHIC ALVEOLAR RIDGE

An occasional patient will present with maxillae where at first glance the dentist would think it would be far easier to lay a board up against the ceiling and expect it to stay there, than it would be to construct a denture that will render satisfactory service. Here is where the ingenuity of the dentist is put to the test.


Worman F.F., Dental Cosmos, 1928

Ridge form is an important factor in successful prosthetic function and for this reason prosthodontists have attempted to develop a useful classification of ridge forms as a diagnostic aid to treatment.

Moses (1953) classified all ridge shapes into three categories with sub-groups (Fig. 4). Generally these were not related to treatment but it is interesting to note that he had intended to include the flabby ridge as a distinct category. He felt however, that as his mucostatic impression technique was so successful, a flabby ridge did not hinder the provision of a stable or retentive denture.

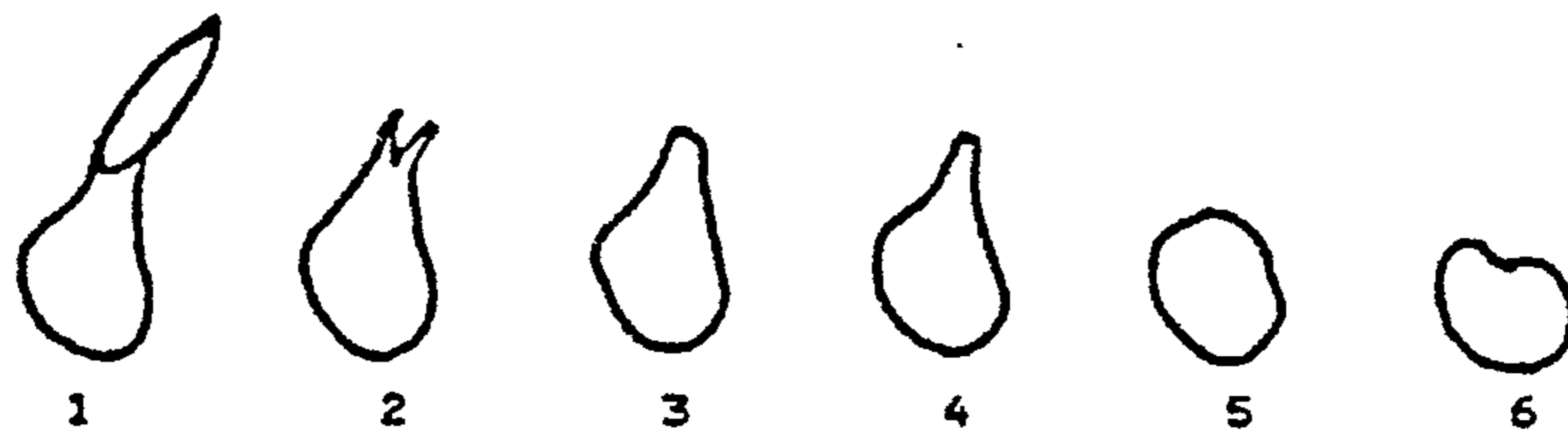
Further classifications based on the morphology of the underlying alveolar bone include those of Atwood (1971) (Fig. 5) and Lekholm and Zarb (1985) (Fig. 6). Atwood classified the bone loss into six stages beginning with the dentate and concluding with the concave or depressed edentulous ridge form. He described external surface resorption with endosteal deposition as the mode of bone loss, a mechanism found similarly in long bones. Following tooth extraction the well rounded ridge starts to resorb on both labial and lingual aspects, ultimately becoming knife-edged. This knife-edge becomes shorter and eventually disappears leaving a rounded or flat ridge

FIG. 4 THE MOSES CLASSIFICATION (1953)



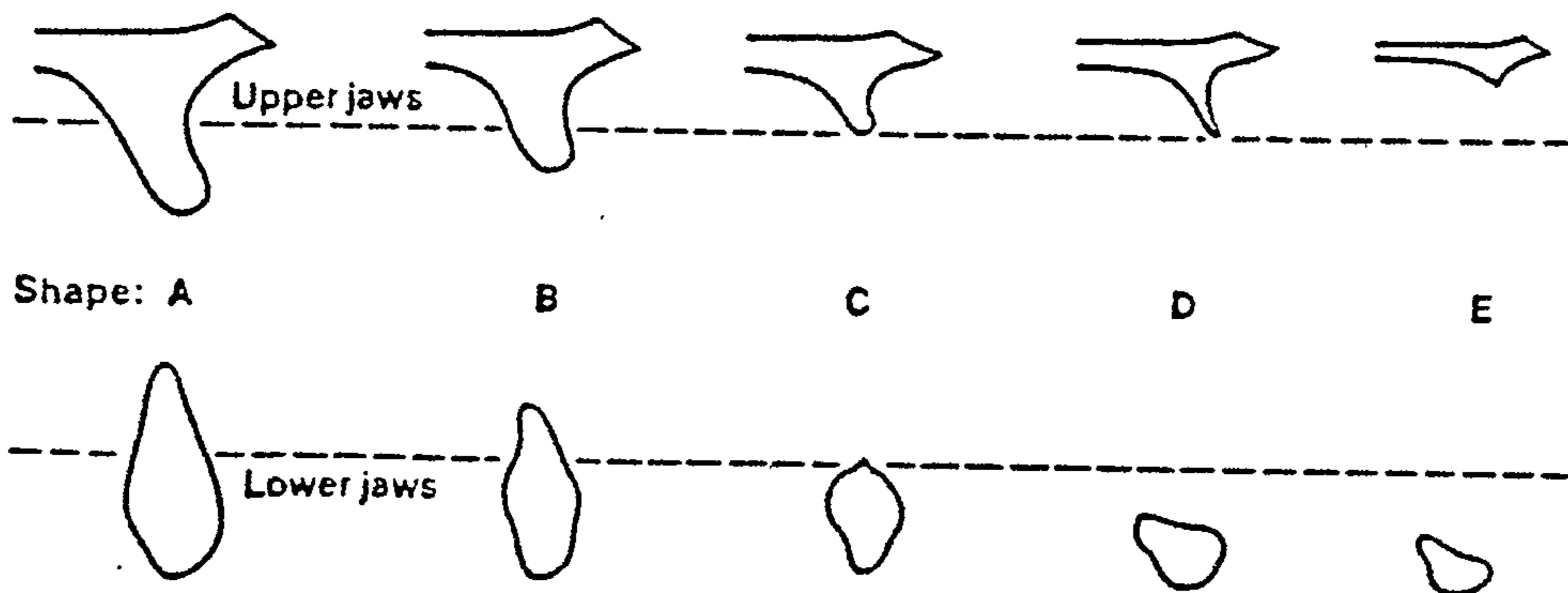
- 1A Inverted U
- 1B Flat inverted U
- 1C U
- 2 Inverted V
- 3A Parallel walled, thin crested
- 3B Parallel walled, broad crested

FIG. 5 THE ATWOOD CLASSIFICATION (1971)



- 1. Pre-extraction
- 2. Post-extraction
- 3. High well rounded
- 4. Knife edge
- 5. Low, well rounded
- 6. Depressed

FIG. 6 THE LECKHOLM AND ZARB CLASSIFICATION (1985)



- A. Most of the alveolar ridge present
- B. Moderate ridge resorption
- C. Advanced ridge resorption
- D. Some basal bone resorption
- E. Extreme basal bone resorption

(The interrupted lines indicate approximate junction of alveolar and basal bone).

which in turn resorbs slowly to a concave form.

Lekholm and Zarb advocated a classification based on five morphological types and linked these to data on bone quality, resulting in a composite classification applicable to the placement of osseointegrated implants.

Mercier and Huberdeau (1985) adopted a different approach with a classification taking into account the soft tissue nature of the ridge, using three groups as a guide to deciding which preprosthetic surgical procedures may be required:

- Group 1 - High crestal muscles and non-resorbed ridge requiring a vestibuloplasty.
- Group 2 - A painful atrophic ridge requiring augmentation and vestibuloplasty.
- Group 3 - Complete absence of the residual ridge requiring augmentation alone.

Beumer et al (1986) also outlined a classification that assessed both the bony ridge form and the quality of the overlying tissue but did not link them to treatment. The ridge form groups outlined were:

- I. Adequate bone and well contoured alveolar ridge.
- II. Localized or generalized partial alveolar deficiency with variable contour (as an undercut ridge).
- III. Loss of most of the alveolar process usually with poor contour (as a knife-edge or no ridge).
- IV. Generalized loss of the alveolar process and much of the body (as a very resorbed mandible).

This initial classification was then supplemented by a further one which included common soft tissue variables and could be combined with the above groups:

- A. Shallow facial vestibule.
- B. Shallow lingual vestibule or palate.

- C. Mobile tissue covering the ridge.
- D. Excessive tissue covering the ridge.
- E. Interarch discrepancy secondary to skeletal malrelation.

This allows, for example, the hypermobile anterior maxillary alveolar ridge to be graded as IIIC so identifying the dual nature of the anatomical problem.

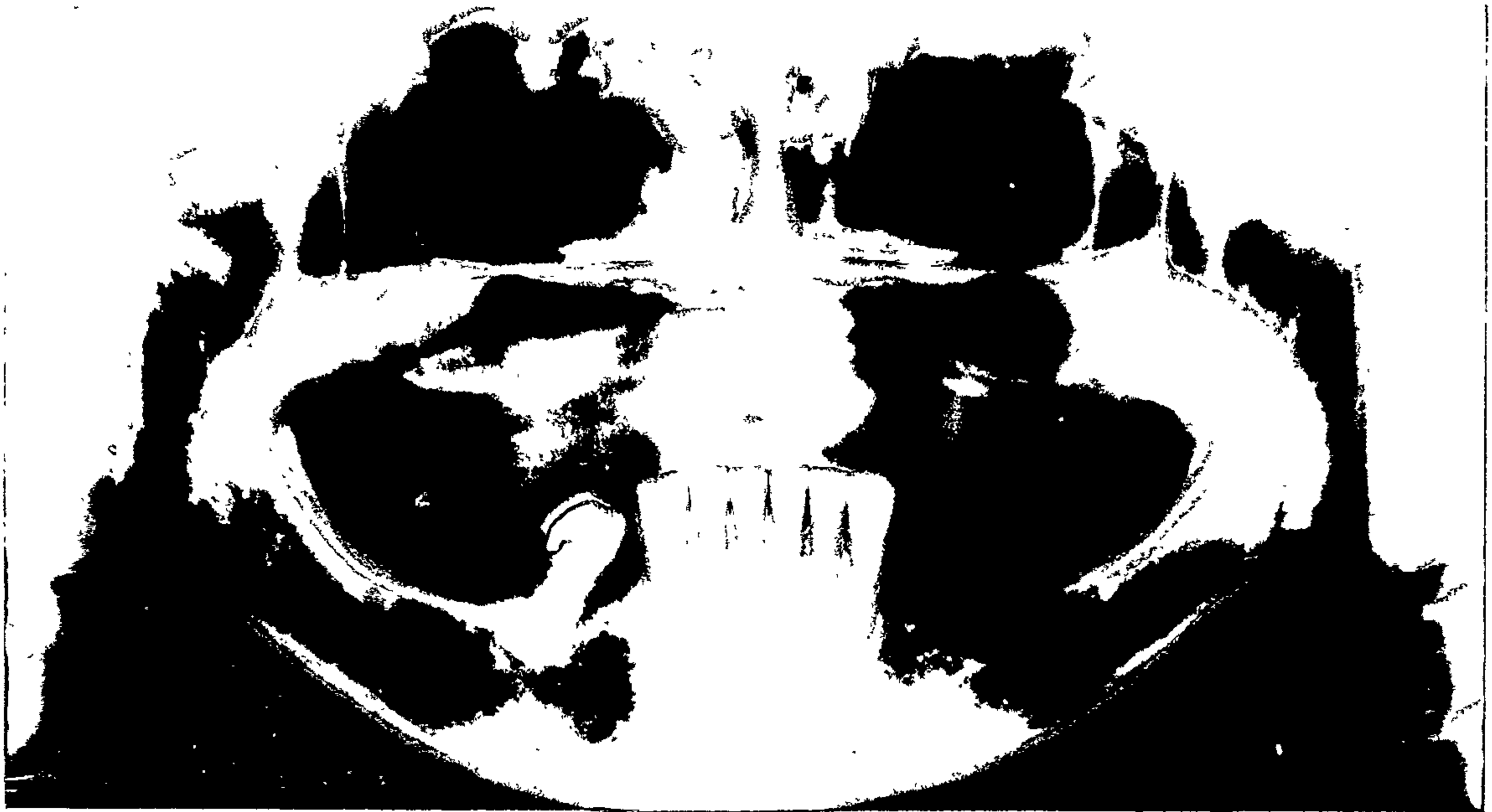Kent et al (1982), in their original article on the technique of HA augmentation, proposed a classification suited for the assessment of ridges prior to HA augmentation. It is again based on ridge morphology and is similar to the classifications of both Lekholm and Zarb and Beumer et al:

- Class 1. A ridge adequate in height but inadequate in width, usually with lateral deficiency or undercuts.
- Class 2. A ridge deficient in both height and width.
- Class 3. A ridge resorbed to the level of the basal bone producing concave form on the posterior areas of the mandible and a sharp bony ridge form with bulbous mobile soft tissue in the maxilla.
- Class 4. Resorption of the basillary bone producing a pencil thin, flat mandible or maxilla.

In this thesis the value of this classification is recognised and it has been used in the preoperative assessment of the clinical cases presented in this study.

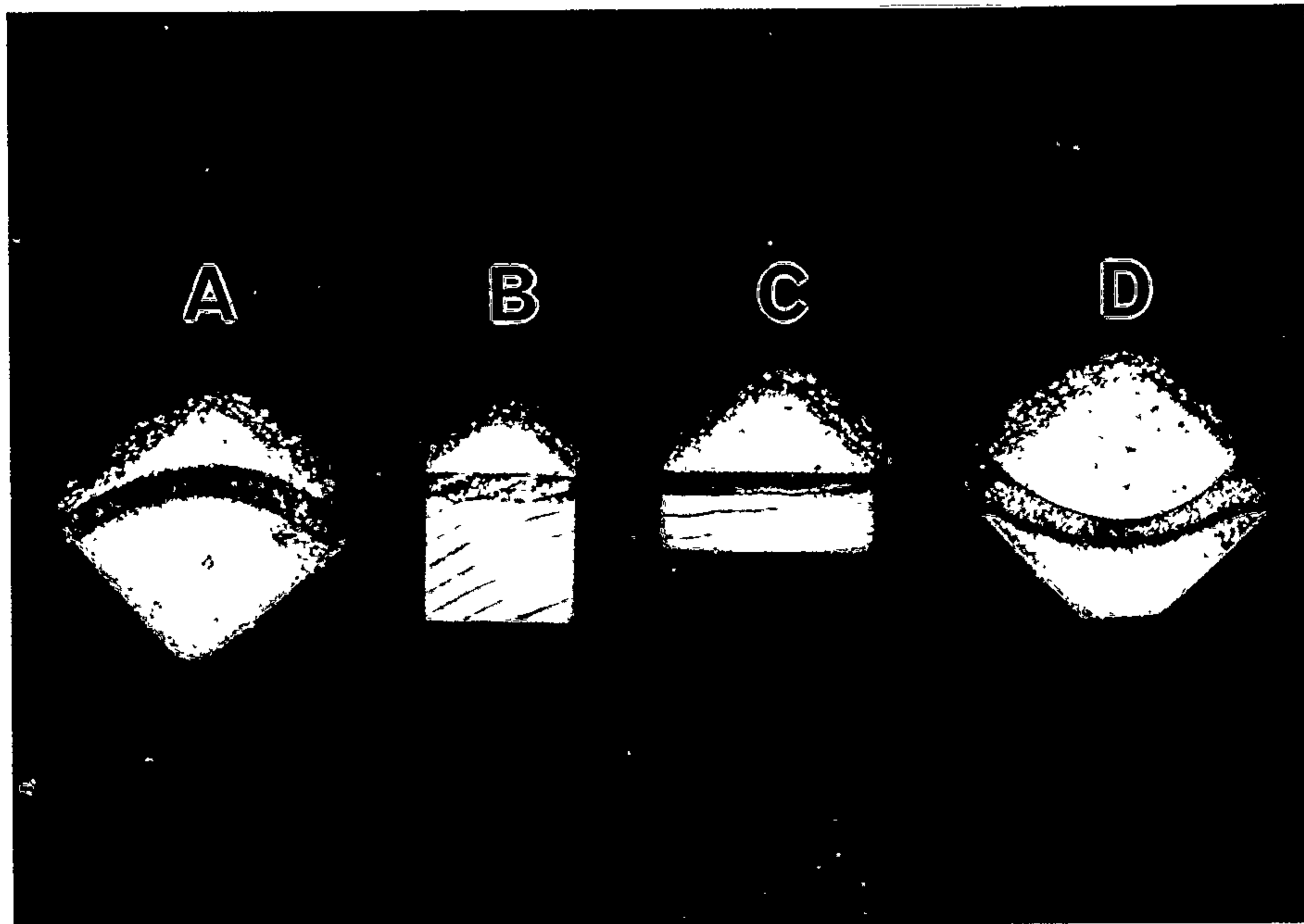
Unfortunately none of the classifications, including Kent's, help in assessment of the potential height gain achievable with HA granules. This gain is a product of the ridge's cross-sectional surface shape and total surface width. In Plate 3 dry sand has been dropped onto wood lengths of varying shapes and widths, simulating mandibular ridge cross-sections, to compare the relative augmentation gains achievable with a material similar to HA granules. It is immediately obvious that the wider and more concave the ridge (C and D), the greater the augmentation height achieved. Conversely a convex ridge (A) provides a very poor ridge shape for HA augmentation as

PLATE 2



An orthopantomogram (OPT) showing the correlation between the retention of mandibular anterior teeth and the loss of alveolar ridge in the anterior maxilla (Patient 4 (EF), Chapter VI).

PLATE 3



A demonstration of the augmentation heights achieved by placing dry sand on wood lengths of varying widths and cross-sectional shape. (From Stevenson 1987).

does one which is deep and narrow (B). Not illustrated is the knife-edged ridge that retains no sand at all.

There are many other factors, particularly the containing ability of the overlying soft tissue, which influence the augmentation height achievable with HA granules and any ridge can possess a variety of widths and shapes over its length. For example, a mandible could easily have the posterior form of D and an anterior form of A, providing an environment for satisfactory height gain with HA granules posteriorly but not anteriorly. It must also be realised that even with the broadest and most concave surface the height gain achievable is modest being only about half of the surface width.

Useful as the classifications are in diagnosis and treatment planning, their limitations are apparent. For a realistic assessment of an atrophic ridge prior to augmentation they need to be used in conjunction with a clinical assessment of the width and surface shape of the ridge in the areas to be augmented. Only then can a realistic outcome to a procedure be formulated.

3. PREPROSTHETIC TREATMENT PLANNING

God gave you ears, eyes, and hands; use them on the patient in that order.

Sir William Kelsey Fry (1889-1963).

3.1 Aims and objectives

The provision of a denture for a patient must meet three rehabilitation criteria: a good aesthetic result, a good functional result, particularly for mastication and speech and be non-destructive to the supporting tissues.

These criteria can best be achieved by the creation and preservation of the ideal ridge which offers:

- Adequate bony support via a broad convex ridge form devoid of undercuts or sharp ridges.
- Healthy, resilient mucosa over the support area which is sufficiently thick and firm to withstand pressure without significant movement.
- Adequate facial sulci allowing for substantial flange extension.
- An arched palatal vault to aid retention and resist both anterior-posterior and lateral movements.
- Substantial tuberosities with sufficient post-tuberosity depression to create a posterior denture seal.
- Minimal destabilising frenal attachments or scars.
- Absence of any mucosal or bone pathosis.

The initial provision of this ideal ridge is the responsibility of the surgeon who renders the patient edentulous. It is inevitable that atrophy will affect the newly created ridge form in time but initial care can alleviate this to some degree.

Lawson (1972), in concluding his article on preprosthetic surgery, said:

"Much of the need for surgery is due to bad surgery at the time of tooth extraction, and indeed many dental surgeons create their own future prosthetic problems by a lack of foresight during earlier stages of treatment."

He was referring to a number of iatrogenic factors that dictate the final ridge form. These include:

- The provision of careful, atraumatic exodontia with a minimum of bone loss, either as a fractured labial plate, or by excessive alveolectomy.
- The maintenance of the sulcus depth by not oversuturing the sockets. It is better to allow the area over the sockets to heal by secondary intention than mobilise the buccal tissue and achieve a primary closure at the expense of sulcus depth.
- The early extraction of compromised, periodontally involved teeth to preserve remaining bone.
- The retention of healthy roots under a denture to preserve ridge form. (This particular concept has been taken further by the development of dense hydroxylapatite (HA) root implants, which possibly have the capacity, as do retained roots, to prevent the labio-palatal collapse of a ridge if inserted at the time of extraction. If successful in the long term, the technique could alter the pattern of alveolar atrophy and herald an era of preventive preprosthetic surgery. The subject is dealt with in more detail in Chapter IV, Section 2.1.)
- The identification and removal of overerupted teeth that are impinging on and traumatising the opposing jaw, hastening resorption.
- The continuing maintenance of the denture, particularly with concern for the underlying mucosa. Mucosal health depends on good hygiene and absence of denture trauma to prevent

irritation and infection. This is particularly true following the provision of immediate dentures which, if never reviewed, inevitably create hyperplastic folds of excess tissue.

3.2 Joint consultation

The provision of preprosthetic surgery must be the result of consultation between the surgeon, the prosthodontist and patient in order to identify accurately the problems and tailor the treatment accordingly. This maximises the possibility of patient satisfaction.

Taylor (1986) encapsulated this succinctly when he wrote:

"the oral surgeon who extracts the teeth and surgically prepares the basal seat for dentures and the prosthodontist who constructs the dentures and becomes responsible for the patient's welfare thereafter should have the same objectives."

To achieve this objective requires an understanding not just of the surgical techniques available but must also take into account the patient's age, general health, dental history, motivation and personality. The last two being important, difficult to gauge and often neglected.

Taylor identified the lack of communication between prosthodontists and surgeons as one cause of surgical failure, especially with augmentation. This communication breakdown could be due, in part, to the different perspectives that the two specialists adopt when examining an edentulous mouth. The majority of surgical procedures for the atrophic ridge are directed to increasing retention and only indirectly to creating better stability or support. It is stability and support, however, which are of prime importance to the prosthodontist with retention being achievable through denture design. Hypermobile tissue, which so adversely affects the stability of a denture, is therefore a problem of great concern to the prosthodontist

which has received scant attention from the oral surgeon.

Castleberry (1982) used the hypermobile tissue of the anterior maxilla as an example of the problem confronting prosthodontists when called upon to construct a denture on a movable base. He commented that a procedure such as augmentation with HA, which increased the retentive area and stabilised the tissues, treated the two problems of retention and stability simultaneously. When pressed on the quality of this stabilised tissue following HA augmentation (Laskin 1982), he commented that movable tissue was converted to non-movable tissue and unattached tissue converted to attached tissue.

3.3 Patient assessment

As previously mentioned, factors which must be considered when assessing a patient's suitability for preprosthetic surgery include age, general health, dental history, motivation and personality.

Life expectancy in the developed world has continued to increase over the traditional 'three score years and ten'. Thus a person rendered edentulous in their forties can now expect to be wearing dentures for at least a further thirty years. The ensuing rate of resorption is also a spasmodic and unpredictable factor and rapid resorption in a young patient would require a different surgical approach from the same degree of resorption in someone of eighty.

Preprosthetic surgical procedures range from the minimally invasive to those that create a large degree of morbidity. Surgical morbidity is further compounded by the fact that the majority of patients are in middle or later life and therefore suffering from the common geriatric disorders. Any condition or medication that prolongs bleeding, delays healing, causes immuno-suppression or affects a patient's ability to manage a denture would militate against major surgical procedures such as inlay osteotomies or onlay

grafting using autogenous material. In these cases a less invasive compromise would be advantageous.

The complexity and length of surgery, as well as patient preference, also dictates whether the procedure should be performed under local or general anaesthetic, assuming that the patient's fitness to undergo a general anaesthetic allows the choice.

In selecting patients as likely candidates for ridge augmentation, experience has shown that the clinician must take into account the prospective patient's expectation of the outcome of treatment. This depends partly on the individual's previous history of wearing dentures, their willingness to tolerate the procedure and an objective assessment of the patient's complaint that the existing dentures are unsatisfactory. For example the person who wishes to bite into an apple may be disappointed even by a technically successful augmentation procedure.

The identification and management of 'problem' patients was explored by Swoope (1973). He felt that good communication between patient and specialist was the key, with emphasis on listening to the patient's problems, both clinical and emotional, and then reciprocating with honest opinions that avoid building unreal expectations in the patient's mind. He warned against the placebo effect of providing treatment that only gave short term relief to problems and advocated using practical diagnostic procedures, such as temporary changes to existing dentures to pinpoint problems, before definitive treatment is undertaken.

Levin and Landesman (1976) devised a questionnaire to ascertain the patient's psychological attitude, noting the lack of psychological training provided for dental undergraduates as a handicap. The questionnaire posed a series of questions based on the patient's attitude to their dentures, positive responses indicating a greater potential for denture acceptance. Koper (1973), discussing the human factor in prosthodontics, indicated that success with a difficult patient hinged on 'trust, time and tenderness'; factors that

sometimes get forgotten in the rush to provide treatment both in hospitals and busy practices.

The provision of surgical and prosthodontic treatment is a commitment in time, effort and resources for both the clinicians and patient. Provision of treatment where none is required or where it is inappropriate is a waste of those resources. Successful treatment requires a detailed understanding of the specific problems. Without time spent on this crucial stage of problem identification, the treatment plan and resulting treatment can be a disappointment to both patient and clinician.

4. PREPROSTHETIC SURGICAL ALTERNATIVES

Be not the first by whom the new are tried,
Nor yet the last to lay the old aside.

Alexander Pope, (1688-1744), An Essay on Criticism

The preprosthetic surgical options currently available can be broadly categorised into:

- Correction of localised hard or soft tissue abnormalities (tori, hyperplastic tissue).
- Vestibuloplasty (sulcus deepening procedures).
- Implants.
- Augmentation (onlay and inlay grafts).

The localised problems, such as the presence of tori, are surgically straightforward and require only a decision as to whether or not removal is necessary for the comfort, retention or stability of the denture. The decision concerning vestibuloplasty, augmentation and implants, however, is not as clear cut with advocates of the various techniques even disagreeing on their relative indications (Harle and Hopkins 1984).

The various factors that preclude one procedure or indicate a preference for another have been summarized in Table 2. The clinical features listed influence the choice of surgical options and help indicate which of the three major surgical modalities are most appropriate. Conversely each technique also has its own complications, contraindications and problems.

Vestibuloplasty is the treatment of choice when muscle attachments are high on the residual ridge, thus creating a shallow sulcus and a destabilising effect on the denture. Various procedures have been advocated to deepen the buccal, labial and lingual sulci. The prerequisite for the technique is

TABLE 2

CLINICAL FEATURES AS INDICATORS FOR SELECTION
OF THE APPROPRIATE PREPROSTHETIC SURGICAL TECHNIQUE

Clinical Features	Vestibuloplasty	Augmentation	Implant
Mandibular bone height at symphysis			
> 15mm	I	N	N
< 15mm	N	I	I
'Knife-edged' ridge	N	I	N
Bone density (Radiograph)			
Good	N/A	N/A	I
Poor	N/A	N/A	N
Mobile ridge tissue	I	I	N
High muscle attachments	I	N	N
Rapid resorption in young patients	N	I	I
Large interarch distance	N	I	I

Technique Indicated = I
 Not Indicated = N
 Not Applicable = N/A

adequate residual alveolar bone height; adequate being defined in the anterior mandible as 15mm or more of basal bone height measured at the symphysis on a lateral cephalometric radiograph. In the maxilla the alveolar height is less critical laterally where vestibule depth can be gained on the lateral aspect of the maxilla anterior to the zygomatic buttress. A vestibuloplasty is contraindicated anteriorly however if resorption has progressed to the point where the anterior nasal spine and piriform aperture are directly beneath the sulcus mucosa.

A vestibuloplasty increases the area of alveolar ridge available for the denture base and thereby aids retention, stability and support. However, it has some serious disadvantages even when sufficient residual bone is present.

Firstly, necessary stripping of the muscle attachments increases the alveolar bone resorption rate, partly due to disruption of the overlying periosteum and partly from the loss of stimulus generated by function of the attached muscle.

Secondly, the resulting mucosal defect needs to be grafted. The absence of a graft (healing by secondary epithelialisation) leads to almost complete loss of the sulcus depth over time. The surgical alternative is either a split thickness skin graft or a mucosal graft, both requiring donor sites and therefore increasing surgical morbidity, particularly in the case of skin.

Finally, in the anterior mandible where the technique is most applicable, there is a risk of damage to the mental nerves, resulting in a dysaesthesia or anaesthesia.

Implants, in contrast, are favoured where there is insufficient residual bone height. They require a substantial width of ridge and thickness of cortical bone to allow for the large implant to bone interface necessary for successful integration. They are ideally suited for the anterior mandible where either endosteal or transosseous implants can be inserted. Their use

in other areas must be more circumspect because of the anatomical limitations dictated by the inferior dental nerve and maxillary sinuses. In the anterior maxilla the combination of poor cortical bone coupled with a resorption pattern leading to a 'knife-edge' ridge limits their use.

Once successfully inserted they provide excellent stability and retention leading to improved masticatory function by virtue of their ability to anchor a fixed prosthesis in an edentulous jaw.

There are, however, some disadvantages. The placement of pure titanium implants, pioneered by Branemark et al (1985), has proved, to date, to be the most successful implant system, but it requires two surgical procedures. Initially, the endosteal portion of the implant is inserted and covered by mucoperiosteum, for at least three months in the mandible and six months in the maxilla. This allows osseointegration to take place. Only then is the transmucosal portion of the implant fitted as a second surgical procedure. Following a further (much shorter) period of healing, prosthodontic work can proceed but the prosthodontic stage can also be long and demanding due to the precision required. The technique is therefore not only costly in time, resources and finance but the patient has to wait at least six months from the initial surgery to the provision of a mandibular prosthesis, and as long as 10 months for a maxillary prosthesis.

The large gap between the prosthodontic superstructure and the alveolar ridge which is needed to keep the transmucosal section of the implant plaque free requires some compromise in aesthetics and speech. The tissue at the gingival/implant interface also has to be attached mucosa to provide a gingival cuff around the implant. The absence of sufficient attached mucosa over the residual ridge is therefore a contraindication to the provision of implants, unless mucosal grafts can be employed.

A final, but significant consideration for the provision of implants is their current experimental status and uncertain long term prognosis. The prognostic assessment of a technique is based on previous experience with

the procedure. The outcome of tried and tested techniques can usually be accurately predicted and the patient reassured; with newer experimental procedures this is not possible. A conference to discuss the benefits and risks of implants was held in the United States in 1978 (Schnitman and Shulman 1979) in an effort to apply scientific criteria for their appraisal. After much deliberation a consensus was reached that:

"to be considered successful the dental implant should provide functional service for five years in 75 per cent of cases."

Albrektsson et al (1986), drawing on their long research with osseointegrated implants, found this compromise unacceptable and proposed:

"a successful rate of 85 per cent at the end of a five-year observation period and 80 per cent at the end of a ten-year period be a minimum criterion for success."

They also reviewed the published literature on various implant systems and found that only the Branemark osseointegrated screw and the Small transosteal staple met their criteria. With the profession still divided on the worth of implants and the merits of different systems, it is imperative that the patient understands the experimental nature of new implants and implantation techniques.

Augmentation, the third of the major preprosthetic surgical options, also has its share of advantages and disadvantages. It involves either onlaying or inlaying a graft material onto or into the atrophic alveolar bone. The various techniques range from simple subperiosteal tunnelling to extensive osteotomies which increase appreciably the postsurgical morbidity.

A substantial height gain is achieved but unfortunately this is often not maintained in the long term. Problems originate from the choice of graft materials available. Autogenous rib and iliac crest, allogeneous bone and cartilage and various alloplastic materials, all considered in detail in Chapter III, have been used, but none found to provide a permanent solution.

Autogenous bone tends to resorb quickly; for example, using onlayed rib up to 56 per cent of the graft resorbs in the first three years slowing to a further 10 per cent over the next 10 years (Davis et al 1984), and using iliac crest up to 89 per cent of the graft is lost by the fourth year (Wang et al 1976). Allogenuous and alloplastic materials are vulnerable both to the host's immune response and to infection.

When compared with onlays, the inlaying of grafts delays resorption. There is, however, a large increase in surgical time with the consequent postoperative morbidity. The resulting ridge also often requires a secondary vestibuloplasty increasing the time interval before a denture can be provided. A high incidence of mental nerve dysaesthesia following mandibular procedures is a further complicating factor.

With the development of hydroxylapatite (HA) as a graft material, the technique of onlay augmentation has been revived and applied in situations where other existing methods are inappropriate, such as the atrophic anterior maxilla with hypermobile tissue. Neither a vestibuloplasty, implant nor interpositional graft can correct directly the problem created by hypermobile tissue. With HA augmentation the mobile tissue is used to advantage to contain the material and the HA can be placed as a simple outpatient procedure under local anaesthesia. There is minimal surgical morbidity and no donor graft site is needed. The ridge is also healed and firm enough to allow denture construction within two months.

Table 3 summarizes the common prosthodontic problems that present in the maxilla and relates them to the most appropriate preprosthetic surgical options.

In conclusion the importance of thorough treatment planning must be re-emphasised. The aims and objectives of the surgeon must be coincident with those of the prosthodontist and patient before any treatment is commenced.

TABLE 3

SURGICAL OPTIONS FOR CORRECTING
COMMON MAXILLARY PROSTHODONTIC PROBLEMS

A shallow labial vestibule and good bony ridge	
- with sufficient mucosa	Submucous vestibuloplasty
- with insufficient mucosa	Vestibuloplasty with skin or mucosal graft
Mobile ridge tissue	Excision Onlay augmentation
An inadequate ridge	Onlay augmentation Le Fort I osteotomy
A poor ridge with no palatal vault	Onlay augmentation Palatal vault osteotomy Partial Le Fort I osteotomy
Poor lip and cheek support	Le Fort I osteotomy
An inadequate ridge of dense bone	Osseointegrated implants

Hopkins (1987) drew attention to the responsibility placed on the surgeon when he wrote in the preface to his book on preprosthetic surgery:

"The tragedy of a poor surgical result is that the patient is left in a worse situation and the prosthetist more convinced of the negative value of surgical assistance."

CHAPTER III

**SURGICAL TECHNIQUES FOR CORRECTING
MAXILLARY ALVEOLAR RIDGE ATROPHY,
EXCLUDING THE USE OF CALCIUM PHOSPHATE CERAMICS**

CHAPTER III

SURGICAL TECHNIQUES FOR CORRECTING MAXILLARY ALVEOLAR RIDGE ATROPHY EXCLUDING THE USE OF CALCIUM PHOSPHATE CERAMICS	42
INTRODUCTION	44
1. REMOVAL OF HYPERMOBILE TISSUE - ALVEOLAR RIDGE CREST	46
2. ABSOLUTE AUGMENTATION	49
2.1 Onlay grafts	50
2.1.1 Autogenous bone - rib	
2.1.2 Autogenous bone - iliac crest	
2.1.3 Allogenuous materials (Allografts)	
2.1.3.1 Allogenuous bone	
2.1.3.2 Allogenuous cartilage	
2.1.4 Alloplastic materials	
2.1.4.1 Metals	
2.1.4.2 Polymers	
2.1.4.3 Ceramics	
Plaster of Paris	
Porous calcium aluminate	
Bioactive glass ceramic	
2.2 Interpositional grafts	69
2.2.1 Total Le Fort I (Sandwich) osteotomy	
2.2.2 Partial Le Fort I (Horseshoe) osteotomy	
2.2.3 Segmental Le Fort I (anterior) osteotomy	
2.3 Relative augmentation	75
2.3.1 Palatal vault osteotomy	
3. CONCLUSION	78

INTRODUCTION

It is generally agreed that a well-formed 'U' shaped alveolar process covered by firm attached moderately compressible gingiva would be the ideal denture base. To establish this condition one must consider first, corrections of the bone, second, corrections of the covering tissues and third, improvement of the relationship between the two.

Obwegeser H.L., J. Oral Surg. 1964

This comment by Obwegeser, one of the founding fathers of modern preprosthetic surgery, still holds true today and a multitude of preprosthetic procedures have been developed to correct the less than ideal ridge and its overlying tissue.

The maxillary bone changes that lead to an unacceptable ridge form can broadly be categorised as:

- Total alveolar atrophy (with or without an acceptable palatal shape).
- Segmented anterior or posterior atrophy.
- Labial resorption.
- Undercuts.

Table 4 lists the various hard and soft tissue surgical procedures currently available for the preparation of the maxilla prior to the provision of a denture. In this review discussion will be limited to those procedures (marked in bold type in Table 4) that primarily correct either the hypermobile anterior maxillary ridge or the grossly resorbed anterior maxillary ridge. However reference will also be made to other maxillary and mandibular procedures where appropriate.

TABLE 4

MAXILLARY PREPROSTHETIC SURGICAL PROCEDURES

SOFT TISSUE

1. **Removal of hyperplastic tissue**
 - alveolar ridge crest
 - labial epulides
 - papillary (palatal)
2. Removal of fibrous tuberosities and ridges
3. Frenectomy
4. Submucosal tunnels
5. Mucosal inserts
6. **Vestibuloplasty (Relative Augmentation)**
 - Submucosal
 - Secondary epithelialisation
 - Grafted
 - mucosa
 - skin

HARD TISSUE

1. Removal of exostoses, tori and undercuts
2. Removal of large bony tuberosities
3. Reduction of prominent malar buttress
4. Celesnik tuberoplasty
5. **Absolute augmentation**
 - Onlay Grafts**
 - Autogenous Bone**
 - Rib
 - Iliac Crest
 - Allogenuous Materials**
 - Bone
 - Cartilage
 - Alloplastic Materials**
 - Interpositional Grafts**
 - Le Fort I Osteotomy**
 - Total (Sandwich)
 - Partial (Horseshoe)
 - Segmental (Anterior)
 - Relative augmentation**
 - Palatal Vault Osteotomy**
6. **Implants**
 - Subperiosteal
 - Osseointegrated
 - Magnets
 - Dense hydroxylapatite root forms

1. REMOVAL OF HYPERPLASTIC TISSUE - ALVEOLAR RIDGE CREST

The best of friends fall out, and so his teeth had done some years ago.

Thomas Hood (1799-1845)

The simplest and most time honoured treatment for hypermobile alveolar ridge tissue is surgical excision. Mentioned early in the century by Crane (1921) and Kazanjian (1924) it is a solution which is still described in standard texts on oral surgery (Howe 1985) and preprosthetic surgery (Hopkins 1987).

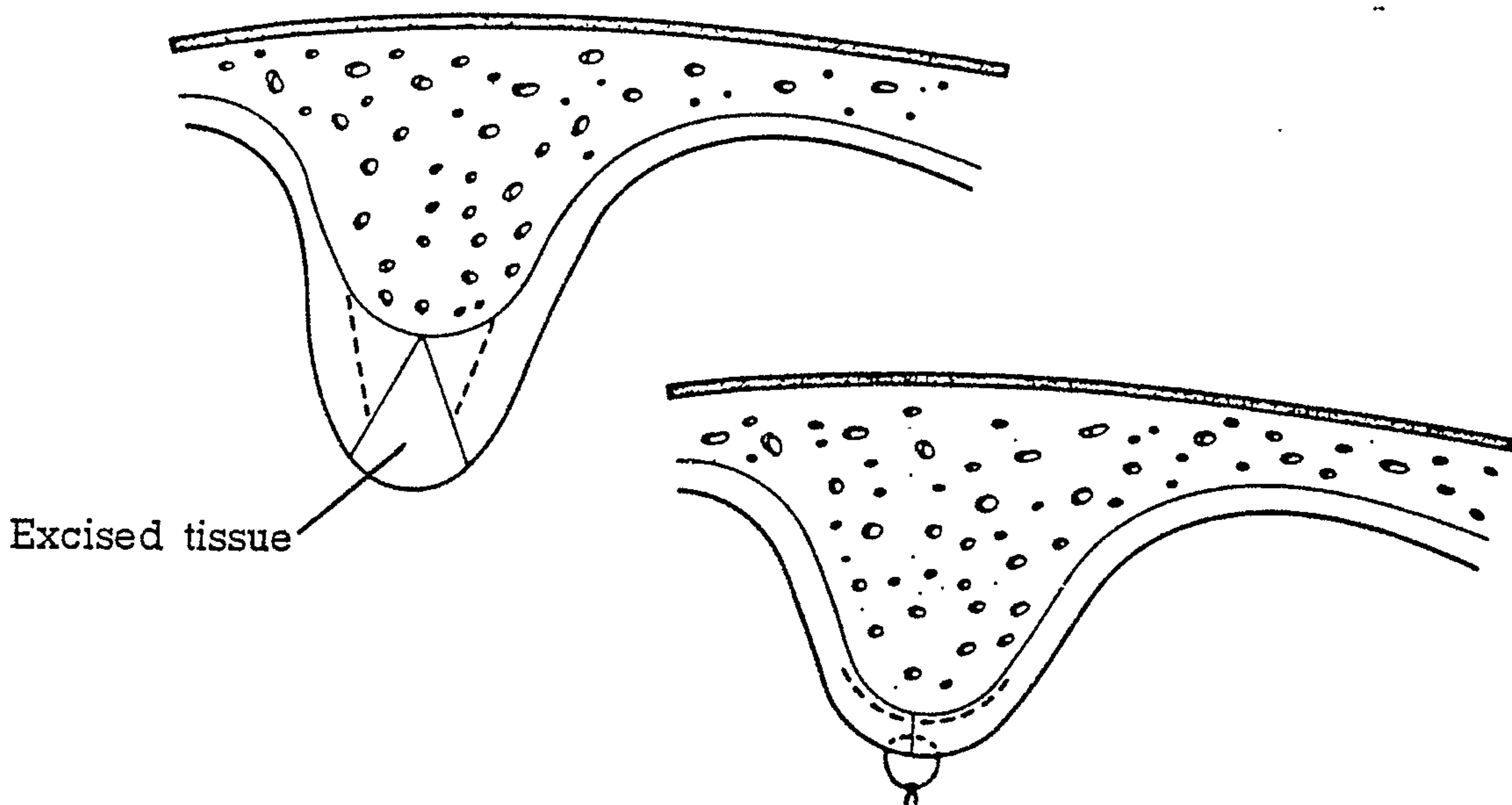
The technique involves removing an ellipse of the mobile tissue from the ridge crest, tapering the incisions to meet at the crestal bone. The redundant tissue (triangular in cross section) is removed and discarded. The wound margins are then approximated and sutured (Fig. 7).

The disadvantages of this simple technique include the loss of a large area of attached mucosa, the reduction in height of the remaining ridge, the loss of sulcus depth and the impossibility of removing all the mobile tissue.

Obwegeser (1958) advocated the technique in combination with either a submucosal or secondary epithelialisation vestibuloplasty where there is adequate alveolar ridge height. Smedley (1941), rather than excise the attached mucosa, undermined the buccal and palatal tissue through a crestal incision and attempted to displace this mobilised tissue into the sulcus and palate by using loose sutures and an overextended denture flange. The resulting crestal defect heals by secondary intention.

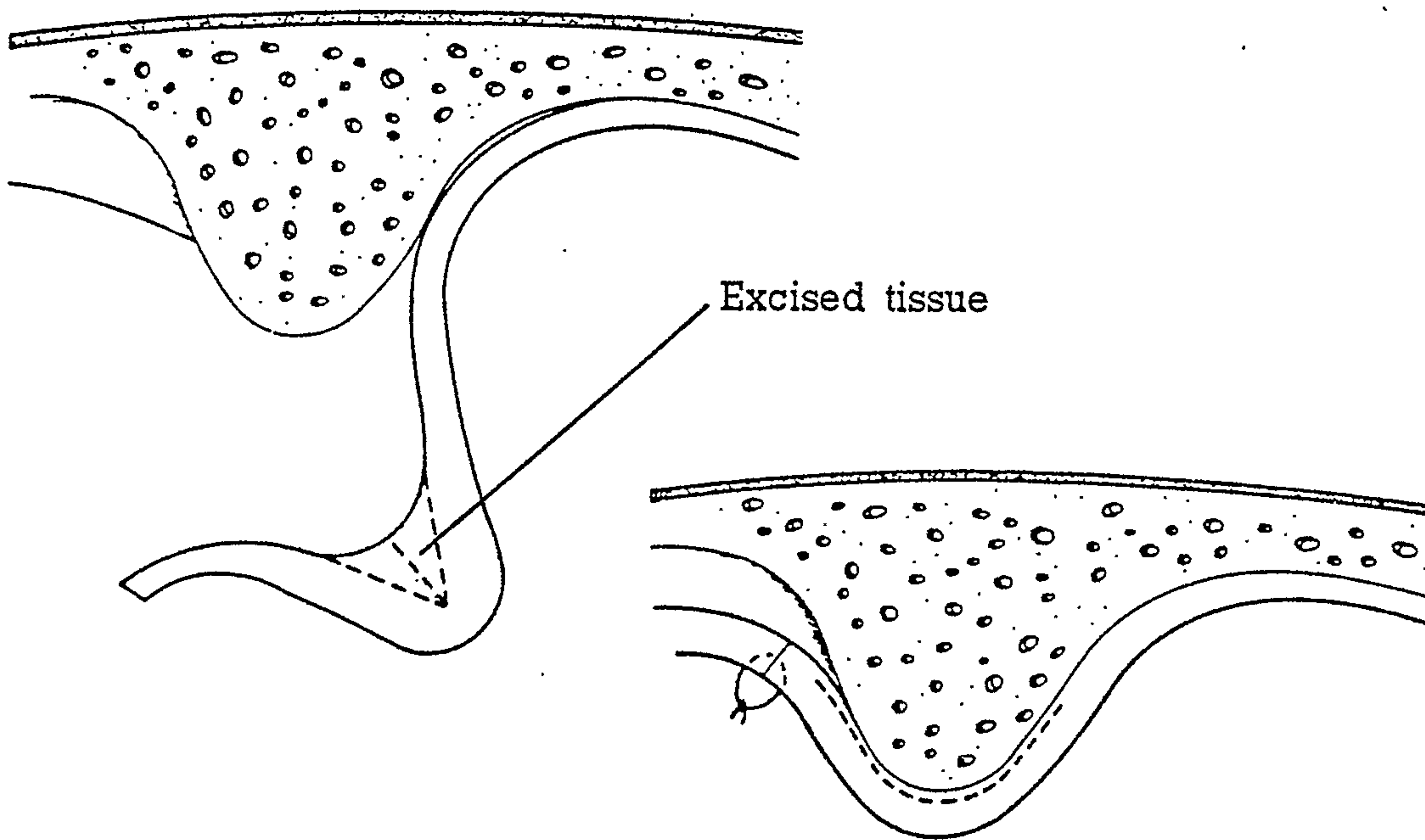
An alternative technique was described by Kazanjian (1935). He filleted the tissue from beneath, after the ridge was mobilised and reflected via a buccal sulcus incision and supraperiosteal dissection. The overlying mucosa is left intact and stretched, allowing it to be repositioned higher into the

FIG. 7



A sagittal section through the anterior maxilla to illustrate the wedge resection of hypermobile ridge tissue. (From Hopkins 1987).

FIG. 8



A sagittal section through the anterior maxilla to illustrate the resection of hypermobile ridge tissue via a sulcus incision as described by Kazanjian (1935). (From Hopkins 1987).

sulcus creating a deeper buccal vestibule (Fig. 8).

Gongloff and Woodard (1981) described a variant of this technique. A partial thickness (supraperiosteal) flap was raised over the ridge on a vestibular, rather than a palatal pedicle and apically repositioned creating a deeper vestibule. The exposed fibrous ridge was then trimmed and allowed to re-epithelialise by secondary intention. They used the technique on 12 patients and reported successful results with little vestibular depth loss up to two and a half years postoperatively.

The success of all these techniques is dependant on the presence of an adequate underlying bony alveolar ridge. They all decrease the alveolar ridge height and cannot be used in cases of gross alveolar resorption, particularly if combined with a flat palate and shallow sulcus. In such cases absolute augmentation is required.

2. ABSOLUTE AUGMENTATION

When the maxillary ridge resorption is so extreme that the alveolar bone has completely disappeared and the maxillary height has been reduced to the point that a nearly flat surface exists between vestibule and palate and the piriform aperture lies just beneath the gingiva, soft tissue vestibuloplasty cannot be undertaken until there has been a replacement of the necessary supportive bone.

MacIntosh RB., and Obwegeser HL.,

J. Oral Surg 1967

Traditionally the problem of extreme maxillary alveolar ridge resorption has been approached by absolute augmentation. Absolute augmentation is, in essence, either the onlaying or inlaying of various graft materials to increase the ridge height. Autogenous and allogeneous bone, allogeneous cartilage and alloplastic materials have all been used as graft materials with varying degrees of success. Discussion in this section will be limited to these augmentation procedures.

Vestibuloplasties, which create a relative augmentation by lowering the surrounding vestibular or mouth floor soft tissue, are therefore beyond the scope of this review but mention will be made of the palatal vault osteotomy which is a hard tissue relative augmentation of the anterior maxilla.

Similarly endosteal implants which have also been used to overcome the problem of gross resorption are beyond the scope of this review.

2.1 ONLAY GRAFTS

The onlaying of a bone graft or bone replacement material directly onto the residual alveolar bone is an attractive procedure due to the surgical simplicity and obvious postoperative ridge height improvement. It is employed in situations of severe alveolar ridge atrophy in combination with a poor (flat) palatal vault. The advantages of the procedure include a true gain in ridge height, a better palatal vault and some correction of any class III skeletal discrepancy, because the graft can be placed buccal to the residual ridge.

The necessity for a secondary vestibuloplasty and the inability of the patient to wear a denture for at least six months are disadvantages. The greatest difficulty, however, has been finding a graft material that maintains the augmentation height long term without displacing, dehiscing or resorbing. This search is still being conducted.

There are four general terms used to describe tissue grafts or transplants currently available.

Autografts which are grafts from one region to another in the same person, e.g. autogenous (autogenetic, autogenic) rib or iliac crest.

Isografts which are grafts from one person to a genetically identical person (identical twins).

Allografts which are grafts from one person to a genetically non-identical person of the same species, e.g. allogenuous (allogeneic, allogenic) bone or cartilage.

Xenografts which are grafts between one species and another, e.g. bovine bone or collagen.

2.1.1 Autogenous bone - rib

The autogenous thoracic rib is a convenient graft material. It can be easily removed with the minimum of complications, additional ribs can be harvested if required and if the periosteum is left intact, the resected portion

will regenerate. The earliest description of the use of an autogenous rib for maxillary augmentation was by MacIntosh and Obwegeser (1967). They described an open onlay technique using a split rib, contoured to the maxilla, packed around with medullary bone pulp and stabilised by intraosseous wires.

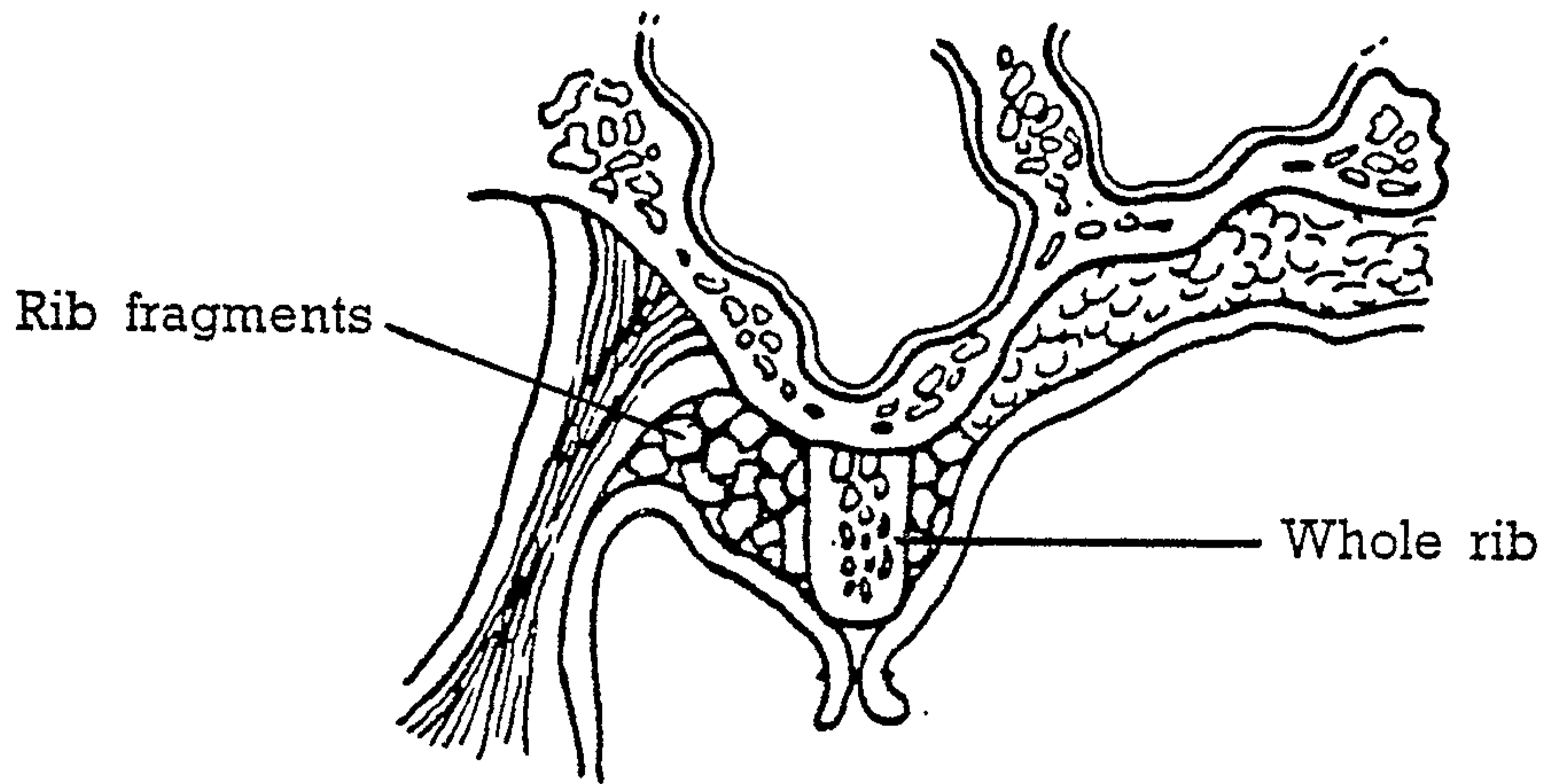
Schroder (1967) also used a rib, including the cartilagenous portion, to augment an atrophic maxilla following the failure of a subperiosteal implant. The mixed graft was placed into a surgically created subperiosteal tunnel without complications but only one case was described. Two further cases were mentioned but no long term follow up was included. Despite this limited experience he concluded that grafts of autogenous material were especially appropriate in the maxilla.

Terry et al (1974) also described the use of two ribs placed as an open onlay. One rib was contoured to the ridge shape while the other was reduced into chips and packed around the first, to improve the contour and eliminate dead space, as previously described by MacIntosh and Obwegeser. They reported the use of this technique on two patients who both, subsequently, had vestibuloplasties, one submucosal and the other by secondary epithelialisation. Both patients were reported to have coped well with dentures but like Schroder (1967), no long term follow up was included.

Topazian (1975) also discussed the technique and its use in one patient (Fig. 9). He found that after one year there had been no loss of bone height or decrease in vestibular depth either clinically or radiographically. He conceded, however, that resorption of the grafts was likely to occur over time as demonstrated in the mandible by Davis et al (1970, 1975). Further long term follow up of onlay grafts in the mandible (Davis et al 1984) has confirmed this continuous resorption.

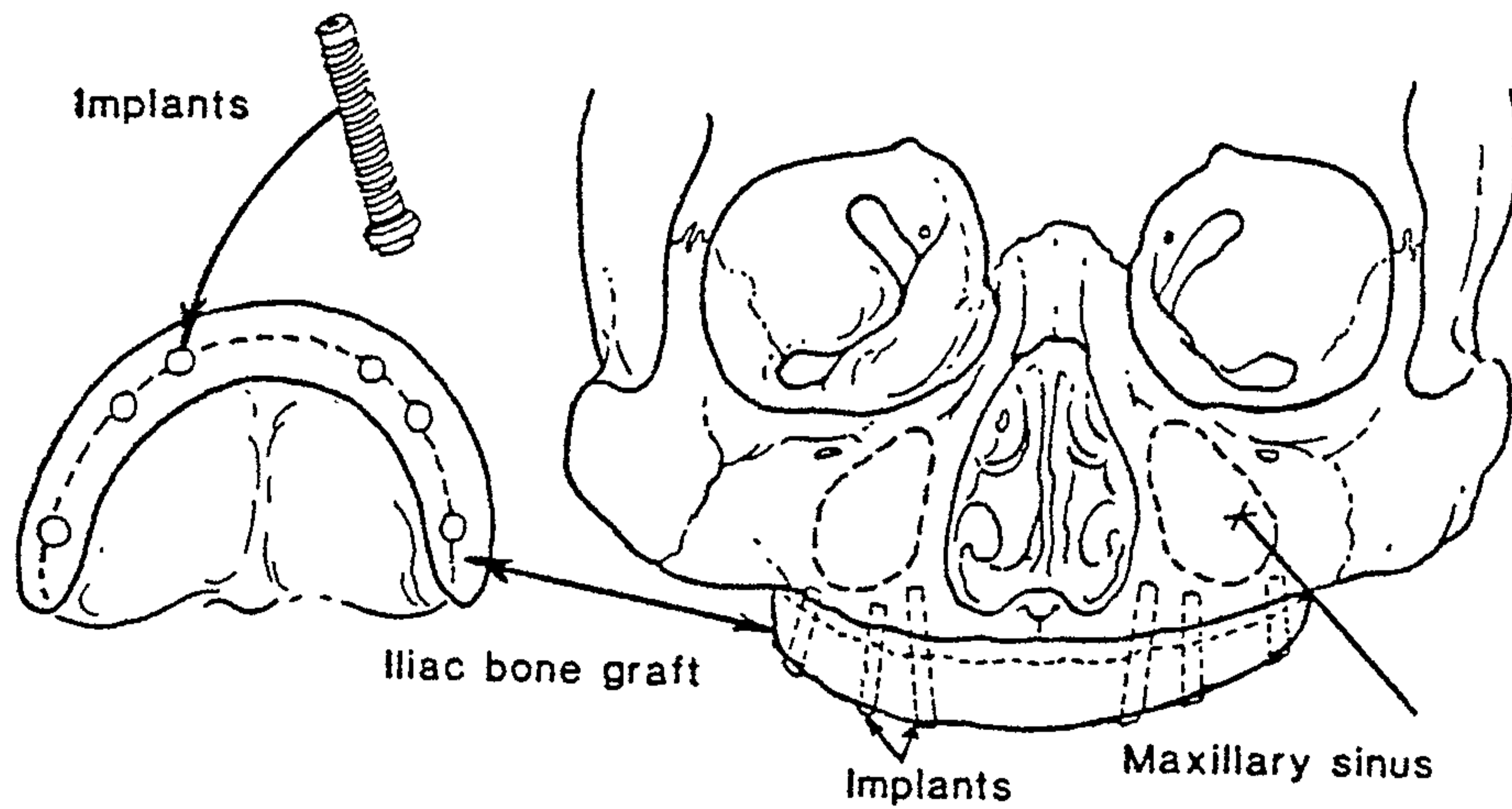
Baker and Connole (1977) discussed the use of onlay rib grafts in both maxilla and mandible, and included the results of 15 patients treated and reviewed a mean of two and a half years postsurgery, (seven received

FIG. 9



A coronal section through the lateral maxilla to illustrate the position of the transoral rib graft and fragments. (From Topazian 1975).

FIG. 10



An illustration of an autogenous onlay graft (iliac crest) secured with threaded endosteal implants. (From Keller et al 1987).

maxillary onlays). On the maxilla, instead of placing the contoured rib on the ridge crest, it was placed lateral to the buccal plate with the lower border parallel to the occlusal plane. It was then secured with four intraosseous wires and any remaining defect between the ridge and rib, often prevalent in the anterior maxilla, was packed with bone chips. They also paid particular attention to maintaining the integrity of the palatal flaps which were vascularised by only a small amount of attached muscle tissue. A surgical splint stabilized the graft and protected the mucosa.

Postoperative complications included graft malposition, dehiscence following wound infection, sequestration and donor site complications. In the maxilla two incidences of graft sequestration took a long time to heal but did so without significant loss of the augmented height. Conceding that they could only make limited observations, they felt that there was a tendency for less remodelling of the graft in the maxilla when compared to the mandible and that a significant improvement in retention and stability of the dentures had resulted.

2.1.2 Autogenous bone - iliac crest

The iliac crest is an alternative source of autogenous bone for onlay grafts and its use in the maxilla has been reported as early as 1948 by Pichler and Trauner (1948) who cited Clementschitsch's work. Like autogenous rib, it has not become popular for onlay procedures again because of the high resorption rate of the predominantly cancellous bone.

Keller et al (1987) described an interesting technique for the atrophic maxilla utilizing iliac bone in combination with Branemark implants in nine patients. The graft was either onlayed and transfixed to the underlying residual bone using the implants in a one stage procedure (five cases) (Fig. 10) or placed as an interpositional graft following a Le Fort I osteotomy, the implants being fitted at a subsequent operation six to 18 months later (four cases). The submerged implants were then uncovered after about eight

months and fixed prostheses constructed. In the onlay cases they found that the implant appeared to osseointegrate better when engaged in both grafted and residual bone rather than grafted bone alone, which occurred in cases where minimal residual bone was present. Surprisingly the implants placed as a secondary procedure after interpositional grafting had a slightly higher rate of failure than the ones placed in the onlay grafts. They attributed this, in their small group of patients, to the compromised overlying mucosal tissue. Keller et al concluded that the Le Fort I technique was indicated in young healthy patients with an interarch discrepancy and the onlay graft procedure was indicated in elderly, medically compromised patients, as surgical morbidity was reduced.

Iliac crest cancellous bone has also been used in combination with titanium mesh trays. Gongloff et al (1986A) described both a two and one stage technique. In the two stage procedure the mesh tray was fabricated on a study model with an idealised ridge. The mesh tray filled with cancellous bone chips was then secured over the residual ridge by a single mid-palatal titanium screw. Ten weeks later the mesh was re-exposed, removed and the wound closed. The one stage technique was used where hypermobile fibrous tissue was present. After similar fabrication of the tray, a split thickness flap extending from the palate was developed pedicled on the vestibular mucosa, a technique described previously in Section 1 for reduction of hypermobile tissue (Gongloff 1981). The periosteum was incised buccally, raised on a palatal pedicle and the titanium mesh tray complete with the cancellous bone chips placed and again secured with a palatal screw. The split thickness flaps then allowed wound closure without tension, and the mesh was left *in situ*. Eight patients received the two stage technique and five the one stage modification. Follow up ranged from one to four years with one single stage case requiring removal of the titanium tray following dehiscence. The average height gain in the two stage technique was 5mm, increased to 8mm after vestibuloplasty. In the one stage technique

the average height gain was 7mm.

With the exception of Baker and Connole (1977) the clinical data associated with autogenous bone onlay grafting in the maxilla is limited and short term. It must be supposed that the poor results obtained with these materials as onlay grafts in the mandible where they have been used more extensively has precluded the use of the technique in the maxilla.

2.1.3 Allogeneous materials (Allografts)

Allografts, as previously mentioned, are tissues transferred between genetically dissimilar individuals of the same species. The genetic diversity inevitably creates an antigenic immune response from the host. This disadvantage is balanced by the elimination of surgical morbidity at the donor site which is inherent in the use of an autogenous graft. The various techniques of allograft production, such as freezing, freeze-drying, irradiation, chemosterilization and the chemical extraction of antigenic substances have also been found to reduce the grafts antigenicity to varying degrees.

2.1.3.1 Allogeneous bone

The most commonly researched bone allograft for augmentation has been freeze-dried (lyophilized) bone. The bone is harvested from selected cadavers under aseptic conditions, sectioned into convenient sizes and freeze-dried in a series of procedures over three weeks. At each stage bacteriological cultures are taken to check for contamination. On completion of the procedure the specimen retains less than 5 per cent of its original moisture. It is then vacuum packed and stored at room temperature (Marx et al 1981). The tissue viability is not retained but the morphology, solubility and chemistry of the bone is preserved and its antigenicity reduced. Prior to use the bone is reconstituted by soaking in a sterile isotonic saline

solution, the soaking time being dictated by the specimen size and the degree of manipulation required. Three hours is sufficient if the specimen needs to be cut, drilled or contoured.

More recently autolyzed antigen-extracted allogeneous (AAA) bone has been advocated because it retains bone morphogenetic protein (BMP). This protein, which is destroyed by freeze-drying, stimulates or induces osteogenesis (Urist and Strates 1971). This research is discussed in more detail in Chapter IV Section 1.4.3. Kiel bone (a bovine bone treated with hydrogen peroxide) is a xenograft rather than an allograft material which enjoyed some early popularity as an onlay graft but was found to be unacceptably antigenic.

Boyne and Cooksey (1965), using predominantly freeze-dried bone and occasionally cartilage, placed 10 grafts in six patients via an open onlay technique. They subsequently developed a subperiosteal tunnel approach and after initial success with the procedure in six dogs, they placed a further 17 grafts in eight patients using this tunnel technique. Clinical and radiographic evaluation up to four and a half years postoperatively assessed 19 (of 27 total) as excellent, four as good and four as fair, the last being grafts that had been either partially exfoliated or warped. They concluded that the graft material integrated and was capable of supporting mastication.

Yeager and Boyne (1969) further researched the use of freeze-dried bone, placing it via an extra-oral approach on the edentulous ridges of 10 dogs. The freeze-dried bone was either used alone or in combination with fresh autogenous marrow. They found that the presence of the marrow enhanced the early formation of new woven bone.

Pike and Boyne (1974) expanded this technique of combining the two graft materials to treat artificially created mandibular defects. They cross transplanted surface decalcified allogeneous mandibular blocks filled with autogenous marrow into six Rhesus monkeys. Two grafts were unsuccessful as a result of deficiencies in surgical technique but the remaining four

showed rapid union to the host bone.

Kelly and Friedlaender (1977), using radionuclide data from implanted Beagle dogs, showed significantly greater levels of osteogenic activity when fresh autogenous cancellous bone was mixed with freeze-dried allografts than when the allografts were used alone. They followed this quantitative work with an analysis of a questionnaire distributed to surgeons who had used freeze-dried allogeneous bone supplied by the U.S. Navy Tissue Bank. Of the 15 patients identified from the questionnaire, 14 had received mandibular and only one maxillary augmentation, in nine of the cases autogenous cancellous bone was also used. Dehiscence was the most common problem, affecting eight patients, predominantly the cases where the allograft had been used alone. They concluded, despite the short follow up time of the patients (average six months), that allogeneous augmentation could be an alternative to autogenous grafting but that the addition of autogenous cancellous bone would be desirable in most instances.

Marx et al (1981) also reviewed a series of 36 cases where allogeneous bone had been used, again unfortunately only one had received maxillary augmentation. The majority of the grafts were either inlayed following an osteotomy or placed within cyst cavities. The maxillary augmentation healed without complications and generally they achieved good clinical results with minimal morbidity and complications. They concluded that allogeneous bone was a suitable graft material.

Maletta et al (1983), using monkeys, compared freeze-dried allogeneous rib grafts to autogenous rib grafts placed on the edentulous maxilla. Their results indicated that healing and revascularization was similar, but that resorption of the allografts was slower than the autografts. They also concluded that both grafts had minimal osteogenic potential and produced less augmentation than a similar sized graft inlayed as part of a Le Fort I osteotomy.

It would certainly appear that the success of an allogeneous bone graft is enhanced by the presence of fresh autogenous marrow but the surgical morbidity associated with its collection seems to negate one of the major factors in favour of allogeneous grafting, the avoidance of a donor site. Another advantage, despite its inability to stimulate osteogenesis, is the provision of a stable matrix for new bone formation by a process of resorption and 'creeping substitution'.

Potential problems associated with allogeneous bone grafts, such as disease transmission from the donor cadaver, graft infection during processing and the generation of an aggressive immune response by the host, all seem to have been overcome by rigorous production standards. However with the experience of infectious diseases being transmitted via blood transfusions or graft materials such as lyophilized dura, and the unfounded scare over the infection potential of serum derived Hepatitis B vaccine, the use of cadaver derived tissue may cause anxiety for patients undergoing an elective procedure.

2.1.3.2 Allogeneous cartilage

Cartilage is a further tissue which is amenable to preparation by freeze-drying and its use in maxillo-facial procedures including preprosthetic surgery was discussed by Sailer (1983) but he detailed no clinical cases.

Blackstone and Parker (1956) compared the results of using freeze-dried cartilage with similarly treated bone and aorta. They onlayed a total of 45 grafts (14 of aorta, 13 of bone and 18 of cartilage) onto the edentulous alveolar ridges of dogs and achieved success rates, judged by graft fixation to the underlying bone, of 50 per cent, 30 per cent and 60 per cent respectively. They felt the poor results with bone were due to its dense cortical nature and the difficulty of getting good apposition to the host tissue and mentioned that the failures with cartilage were due to postoperative trauma. However there was no explanation of why this was not a factor with the other graft

materials. They presented a clinical case report of mandibular onlay augmentation using freeze-dried cartilage but no postoperative follow up was included.

Their paper demonstrates well the difficulty of extrapolating animal data to the human situation. The conclusion that cartilage was the most satisfactory graft material while bone was the least satisfactory was supported by the data but does not reflect the clinical situation where allogeneous bone has been found superior to allogeneous cartilage as a graft material. Neither has freeze-dried aorta gained any acceptance as a human graft material for augmentation despite their results. The difficulty of reproducing experimentally in animals the physiological and mechanical environment of the human mouth and particularly the edentulous ridge in function must lead to a very guarded interpretation of any results.

There are three problems associated with the assessment of allogeneous grafts for augmentation. Firstly, there have been relatively few animal studies, often with statistically insignificant numbers and as noted earlier it is often hazardous to extrapolate any of the data into a clinical setting. Secondly with the exception of the work by Boyne and Cooksey (1965) and Kelly and Friedlaender (1977) most clinical reports are limited to a single case with only short term follow up. Finally there has been little published directly comparing allogeneous and autogeneous materials allowing no comparisons of results, complications or morbidity rates.

2.1.4 Alloplastic materials

Alloplastic materials are synthetic products unrelated to biological tissues. They are usually available in large quantities, are readily manufactured and have the surgical advantage of not requiring a donor site. Broadly they can be classified into metals, medical polymers and ceramics.

The metals and polymers are essentially nonresorbable (nondegradable) but ceramics can be either nonresorbable or resorbable. Each group has some favourable characteristics for a bone substitute, although none fully satisfy the criteria of the ideal bone graft material which include being:

- nontoxic.
- nonantigenic.
- biologically inert.
- similar in strength and flexibility to bone.
- able to interface directly with living bone.
- readily available.
- inexpensive.
- easily fabricated.
- resistant to infection.

(Laskin 1982)

2.1.4.1 Metals

The use of metals as internal prostheses is widespread in orthopaedic surgery. However, their use in alveolar augmentation has been slight. Holland (1953), in only one case, used tantalum mesh which he rolled and placed subperiosteally in mandibular buccal undercuts. The mesh extended from the left to right molar region, being stabilised to the bone directly with tantalum sutures.

The use of metals in such situations as the subperiosteal, staple or osseointegrated implant techniques are beyond the scope of this review.

2.1.4.2 Polymers

A variety of polymeric alloplastic materials which have been investigated for ridge augmentation were reviewed by Topazian et al (1971). These include polymethyl methacrylate (acrylic resin), polyethylene, silicone rubber (Silastic), polyvinyl resin (Ivalon), gelatin sponge (a denatured animal collagen)

and porous polytetrafluoroethylene (PTFE) (Proplast).

Thoma (1969) referred to Flohr's work of 1953 in which acrylic resin was fabricated preoperatively on a study model. The resin was then cured and fenestrated to allow tissue ingrowth and inserted into a submucosal tunnel created via a midline incision. Moore et al (1953) used gelatin sponge (Gelfoam) in 120 patients. It was placed subperiosteally to eliminate undercuts and became firm. Understandably there was minimal increase in the vertical height of the ridge and neither was there elimination of the knife-edge ridge. It was suspected that some new bone had formed as a result of the implantation but this was not supported by radiographic evidence.

Lewin-Epstein (1960) implanted polyvinyl alcoholic sponge (Ivalon) subperiosteally in the anterior mandible of seven patients. Observations up to 21 months postimplantation showed no inflammation but fibrous encapsulation of the implant. The presence of foreign body giant cells was evidence of an immune response. There was also a tendency for the sponge to dehiscence through the incision line and to exhibit slight resorption, possibly as a result of phagocytosis by the foreign body giant cells.

Gatewood (1968) implanted Silastic covered with a Dacron mesh subperiosteally in 12 patients. The silicone-Dacron implant was created preoperatively, the Dacron being formed to the idealised augmented ridge shape, the liquid silicone then being cured within. The resulting flexible implant was autoclaved and inserted into a subperiosteal crestal tunnel. Results from 15 patients showed an average increase in ridge height of 5mm, with 12 of the patients tolerating dentures by six months. However, 11 of the 15 experienced some mental nerve neuropathy which, in some cases, took up to five months to recover. Concurrent histological studies in animals showed a mild foreign body response and fibrous encapsulation of the implant.

More recent evidence of the host tissue response to Silastic, in this case within the temporomandibular joint (Bronstein 1987), showed that in a weight bearing situation the implant disintegrated provoking a foreign body

response, bone erosion and clinical symptoms.

Kent et al (1972) used the porous implant material Proplast (polytetrafluoroethylene, PTFE) in a number of oral and maxillofacial procedures including alveolar ridge augmentation. Initial animal studies showed stability of the Proplast blocks three to four weeks postimplantation. Histologically, collagen formation was observed within the entire implant with no significant inflammatory response evident. Eight patients subsequently underwent alveolar ridge augmentation with Proplast. Initially placed via a crestal incision, dehiscence through the incision line prompted a change to a subperiosteal tunnel technique. The blocks of Proplast were carved preoperatively and inserted via small vertical incisions, unfortunately only one maxillary implant was placed. The blocks became fixed to the adjacent tissues and, apart from one minor dehiscence which healed spontaneously and 'varying amounts' of lip paraesthesia, there were no other complications and dentures were constructed after six weeks. Kent et al concluded that Proplast showed encouraging results in many areas of oral implantology, either alone as an augmentation material or as a coating for other metallic implants.

Moos et al (1978) also reported on the use of Proplast implants in oral and maxillofacial surgery. They assessed 49 patients up to two years post-implantation in a variety of clinical sites including the orbit margin, forehead, temporal regions, malar and chin. Intraorally they detailed three cases of mandibular alveolar ridge augmentation and eight of maxillary/nasal augmentation. Unfortunately, they lost to oral commensal infection four of the maxillary implants, with a fifth becoming unstable. These poor results were in contrast to the genial augmentations. Despite the graft being placed via an intraoral approach, only one of 11 genial implants became infected. They could not explain this contrast but alluded to the poor quality of the maxillary mucosal tissue. Unfortunately in the case of mandibular augmentations which failed, pain and discomfort continued even after implant removal. It was

concluded that Proplast did have a role to play in restoration of facial contour but that ridge augmentation results were disappointing, a comment that must be construed as an understatement.

Hecht (1950) introduced the idea of using sulphonamide tablets as a fibrosing agent in alveolar undercuts. Laskin (1970) developed the concept using a sclerosing solution to fibrose hypermobile tissue. Although not technically an augmentation, the procedure has been shown to maintain ridge height and decrease mobility. A 5 per cent solution of sodium morrhuate was injected supraperiosteally either into hypermobile ridge tissue or areas of recurrent hyperplastic tissue. Transient swelling and pain followed the injection and tissue movement was restricted for six weeks to allow the sclerotic area to become firm enough to permit denture construction. Fifty eight patients were followed for up to seven years and it was shown that the initially firm fibrous ridges slowly lost this firmness. The option of re-injection was seen as a possibility but not pursued.

Desjardins and Tolman (1974) also discussed the use of sclerosing agents classifying them into four groups:

- Hypertonic solutions.
- Protoplasmic solutions e.g. quinine and phenol.
- Surface active soap solutions e.g. sodium morrhuate.
- Synthetic surface active solutions e.g. sodium tetradecyl sulphate.

They used the same solution and technique as Laskin for 10 patients with hypermobile tissue and followed them up for a post-injection period of five years. Minor tissue slough was evident in two patients post-injection but all patients had a firm ridge crest by six weeks. At review after one year the sclerosed tissue appeared to be less firm than at six weeks with the increased mobility being severe enough to consider further injections for two patients. Interestingly the increase in mobility did not progress after this initial observation and the secondary injections were postponed indefinitely. Histologically the lamina propria and the submucosa were found to be

composed of dense fibrous connective tissue (similar to scar tissue) with normal overlying epithelium. Desjardins and Tolman concluded that sclerosing agents could be the treatment of choice for hyperplastic tissue in preference to surgical removal which leaves no residual ridge and soft tissue attachments close to the ridge crest.

A more physiologically acceptable material for augmentation by injection was discussed by Mishkin et al (1985). They used soluble bovine collagen, an injectable xenograft, for alveolar augmentation in a small group of rats. They found it to be histologically biocompatible with no significant evidence of an immune response but no human studies were undertaken.

It is clear that despite the long history associated with the development and use of alloplastic materials for bone replacement, no material has to date closely approached the ideals outlined by Laskin (1982).

It became evident when reviewing the published results of alloplastic materials used for augmentation, that the initial encouraging, sometimes euphoric, predictions for the alloplast under review were not sustained. Long term reports were rarely published and instead a new material was reviewed and championed. The hostile environment of the atrophic ridge therefore continues to challenge the production of a suitable material.

Topazian et al (1971) in the conclusion to their review on alloplastic materials highlighted the reason why the majority of materials are less than ideal for augmentation when they wrote:

"One of the chief reasons alloplastics have not been widely used is extrusion of the implant. Their failure to become structurally and physiologically united with the surrounding living tissue is one of the major barriers to the wider use of alloplastics."

2.1.4.3 Ceramics

Ceramics are non-metallic minerals and traditionally included such diverse materials as graphite, glass, Portland cement and plaster of Paris (Topazian et al 1971).

A new era in allograft ceramics was opened, however, when the previously accepted bioinert materials were replaced by ones labelled 'bioactive'. These materials, most notably the calcium phosphate ceramics, interact with and ultimately become an integral part of vital bone; becoming either totally enveloped or resorbed by the host bone, depending on their structural characteristics.

Central to this ability is the predominance of calcium and phosphate ions contained within crystal structures very similar to the natural bone material hydroxyapatite.

In this section discussion will be limited to the ceramics that have been employed for ridge augmentation with the exception of the 'bioactive' calcium phosphate ceramics, tricalcium phosphate (TCP) and hydroxylapatite (HA). They will be discussed in greater detail in Chapters IV and V.

Plaster of Paris

Bahn (1966) in a review of plaster as a bone substitute noted that plaster had been investigated numerous times since the 19th century in an attempt to find a filler for bone defects. Initially the plaster was mixed fresh, at the time of operation, and introduced into the wound in a liquid state. It was, however, difficult to apply and retain. Peltier et al (1957) developed a process where the plaster was formed into blocks and tablets prior to implantation. They then implanted this solid plaster into the long bones of dogs and confirmed that the material was well tolerated by the tissues. They concluded, however, that it did not stimulate osteogenesis and was readily resorbed, usually before total bone regeneration. Bahn also noted this rapid rate of resorption but without the expected foreign body giant cell reaction.

He concluded that plaster could play a role in the restoration of normal anatomical contour and be used to rebuild the atrophic alveolar ridge. He even suggested that it could be employed as a medium to carry pharmaceutical compounds, allowing prolonged release of the compound into the implanted area.

Radentz and Collings (1965) implanted freshly mixed plaster of Paris into intra-bony periodontal pockets created in ten dogs. On histological comparison with control defects, healing was found to be very similar with plaster having the slightly better healing pattern. They concluded that the implanted plaster was amenable to osseous regeneration because it was tissue tolerant and produced no ill effects for the host. They felt also that during resorption and bone replacement it provided an environment conducive to healing.

Ferraro (1979) commenting on the use of plaster felt that the large surface area of the minute calcium sulphate crystals allowed resorption to take place quickly, before bone had enough time to regenerate and fill the void.

Frame et al (1987) included an investigation of HA mixed with plaster in a wider study of osteogenesis around porous and non-porous HA granules. Using six dogs they augmented edentulous ridges with porous and non-porous granules both alone or mixed with either autogenous bone or plaster. The plaster was found to be biocompatible and rapidly degraded, the majority being resorbed in the first four weeks. It also did not interfere with healing but provided no osteogenic stimulus.

Porous calcium aluminate

This material, developed only recently, appears to have already been superceded by the calcium phosphate ceramics.

Smith (1963) produced a ductile ceramic material using a porous calcium aluminate and impregnated the pores with an epoxy resin producing

a flexible, but hard and corrosion free graft material. Using animals he implanted the material into subcutaneous tissue, skeletal muscle and knee joints. He found, predictably, that the subcutaneous and skeletal implants were surrounded by fibrous tissue but that some of the joint prostheses were firmly held in a bed of new bone. However, he was unable to demonstrate ingrowth of either new bone or fibrous tissue. Welsh and Macnab (1971) using a similar composite material of ceramic and epoxy resin achieved comparable results with fixation by fibrous encapsulation but they noted a breakdown of the impregnating polymer. They concluded that it was an unsatisfactory implant material in that form.

Driskell et al (1972) developed three different calcium aluminate ceramic implants for specific surgical problems; phosphate bonded alumina foam to fill hard tissue voids, a porous ceramic coated metal implant to bridge bone defects and a ceramic tooth root implant.

Using Rhesus monkeys they demonstrated histologically that the porous ceramic foam placed in maxillary defects filled with new bone, however, the majority of implants had disappeared within the four months prior to sacrifice, probably due to sequestration following infection. The ceramic coated plates used to bridge mandibular defects also gave mixed results showing some bone integration in one specimen but exfoliation in others. Three different surfaces were used for the root shaped implants, either a low surface porosity, a high surface porosity or a particulate coating. However, little detail was presented on their relevant merits, the only comment being that they all seemed rigidly bound in their sockets.

Hammer et al (1973) used unimpregnated porous calcium aluminate ceramic blocks in dogs to augment edentulous mandibular ridges. Subsequent histological examination showed the calcium aluminate to be biocompatible with connective tissue, osteoid and bone penetrating the pores. They noted proliferation of bone around the implant margins and also that there was no evidence of underlying bone resorption. Within the pores there

were a number of foreign body giant cells containing ceramic debris. Hammer et al anticipated that these cells would eventually undergo karyolysis leaving the ceramic particles to be incorporated in the advancing osteoid. The same group subsequently used calcium aluminate in six patients, four resulting in successful augmentation. Traumatic movement and underlying bone resorption were responsible for the loss of the implants from the other two patients.

Pederson (1976) used porous aluminum oxide (Al_2O_3) for ridge augmentation in four patients with some initial success. Two required mandibular augmentation and two restoration of localised maxillary defects. Healing was uneventful and the implants firm by three weeks allowing denture construction. One mandibular implant dehisced after four weeks but after removal and reinsertion 24 days later healed normally. No subsequent pathosis was noted clinically or radiographically up to 15 months postimplantation.

A follow up after three and a half years (Pederson 1980) included one further mandibular case. In contrast to the favourable initial study he reported two cases of implant dehiscence, leading to removal of the implant after two and a half years in one case and spontaneous exfoliation after three and a half years in the other. One patient also had a degree of unilateral mental paraesthesia. There was no evidence clinically or radiographically of any tissue reaction to the remaining implants. However histological examination of the removed block showed only inflammatory exudate within the pores and signs of inflammation and a foreign body reaction in the surrounding tissues. Pederson concluded that despite the material's biocompatibility the failure of tissues to penetrate the pore system made it very vulnerable to infection. The solution he proposed was for a solid (dense) implant with porous coating to allow peripheral ingrowth.

Bioactive glass ceramic

Glass ceramic materials form a direct chemical bond to bone assisted by their silica component and are therefore classed as bioactive. They also release calcium and phosphorus ions causing a precipitation of hydroxyapatite crystals within the collagen matrix (Schoen 1980). Due to the active chemical bond it is unnecessary for these materials to be porous to gain stability and they can also be used as a coating for other implant materials.

Bunte and Strunz (1977) used a bioactive glass ceramic in both animal and clinical trials. They found it was incorporated into bone and nonresorbable. Clinically it was used only in the mandible, being inlayed anteriorly and stabilised by transfixing screws. Attempts to use the material for subperiosteal onlay augmentation failed due to dehiscence. They reported initial aesthetic and functional improvement of the denture following the osteotomy but no long-term follow up was included.

Bioglass, although biocompatible and bioactive, appears to have no advantages over synthetic hydroxylapatite and its development as an onlay augmentation agent appears to have been eclipsed by the availability of hydroxylapatite (HA) blocks and granules which are clinically more versatile.

2.2 INTERPOSITIONAL GRAFTS

The inlaying of a graft material between two surfaces of host bone is known as interpositional grafting. It can be used as an alternative to onlays for absolute augmentation and has certain advantages over the onlay technique.

In the maxilla interpositional grafts can be used in conjunction with a range of osteotomies. The Le Fort I osteotomy mobilises the total alveolar ridge and palatal vault and is employed in cases of ridge atrophy where the palatal vault form is good.

The partial Le Fort I osteotomy mobilises only the alveolar ridge, being employed where the palatal vault form is poor. The segmental Le Fort I osteotomy mobilises only the anterior maxilla and is used when there has been a disproportionate amount of anterior resorption as in the 'combination syndrome' (Chapter II, Section 1.1).

The advantages of the interpositional graft procedures when compared with the onlay techniques include:

- Greater stability postoperatively.
- The opportunity to correct skeletal or interarch discrepancies in all dimensions.
- A reduction in the graft resorption rate.
- The ability to use allogenuous bone grafts with less complications.
- The protection of the graft from direct loading.
- The graft being rapidly vascularised as it is in contact with two rather than one surface of the host bone (Fonseca et al 1986).

2.2.1 Total Le Fort I (Sandwich) osteotomy

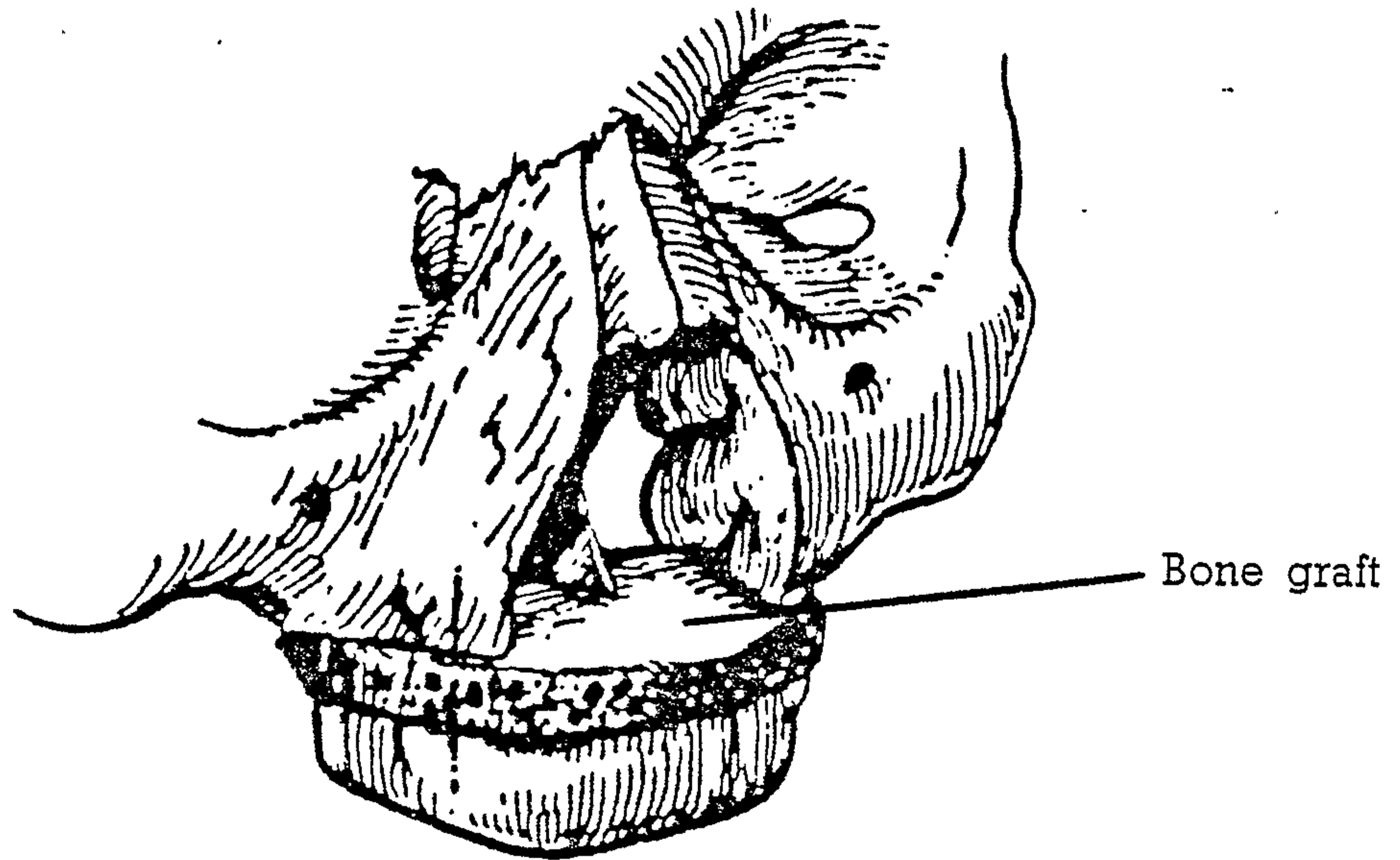
Wassmund originally described the Le Fort I osteotomy to mobilise from the midface, the alveolar and palatal processes of the maxilla. This mobilisation allows the fragment to be repositioned in a more advantageous position and the technique has gained wide acceptance as an orthognathic surgical procedure for patients with a dentate hypoplastic maxilla. It can equally be used to treat total or partial maxillary atrophy. Bell et al (1975) showed, using Rhesus monkeys, that the palatal mucosa in combination with buccal mucosa provides an adequate nutritional pedicle for the procedure as a single stage total maxillary osteotomy. This is the key to the success of the procedure.

Farrell et al (1976) utilised the Le Fort I osteotomy in combination with an interpositional autogenous bone graft and vestibuloplasty in a case of severe maxillary atrophy. Preoperative planning, similar to that used for orthognathic

surgery, allowed construction of an acrylic splint which duplicated the size and shape of the graft needed to restore the ridge. This template acted as a guide during the harvesting of the cortico-cancellous iliac crest graft. The maxillary segment was mobilised and secured to the prepared splint. The graft was then inserted between the mobilised segment and the midfacial bones, the cortical surface being placed superiorly to form the new nasal floor. Direct transosseous and infraorbital suspension wires provided immobilisation. Minimal resorption of the augmented ridge was observed 14 months postoperatively and there was also a significant improvement in facial profile and contour and satisfaction with the new dentures. Farrell et al stated that the advantages of this technique included the elimination of a secondary vestibuloplasty, the early ability to provide a denture and the ability to reposition the maxilla in a more advantageous relationship to the mandible.

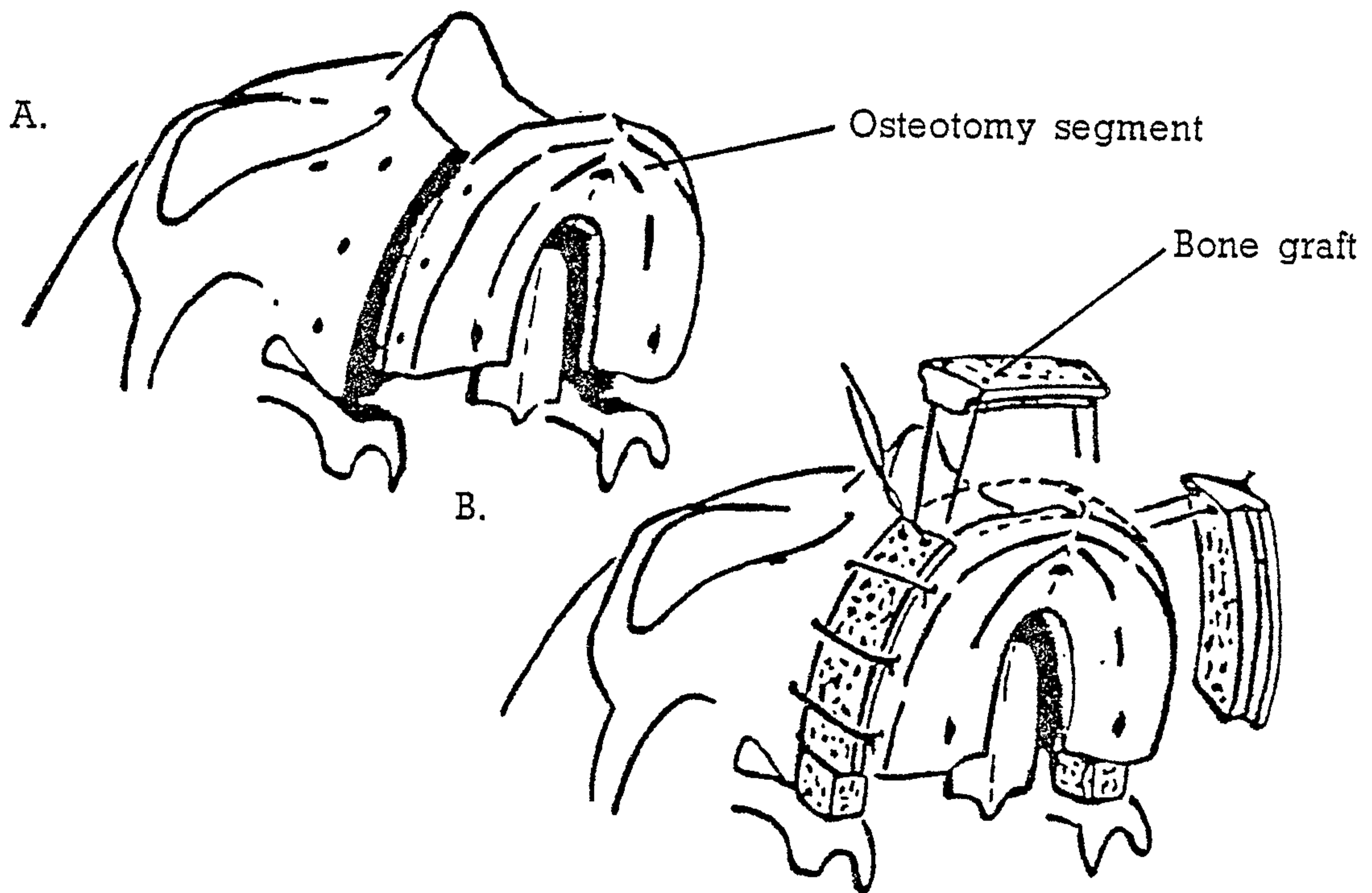
Bell et al (1977) outlined a similar technique but initially used bilateral interpositional bone grafts, changing subsequently to a single graft as outlined by Farrell et al. In the single case reviewed they demonstrated early consolidation of the grafted bone with minimal resorption of the repositioned segment and no decrease in the height of the augmented ridge although follow up was restricted to just two months. They commented that the technique eliminated the problems of dehiscence and exfoliation of the graft commonly seen in onlay cases. Bell and Buckles (1978) detailed further experience with this technique (Fig. 11). Reviewing six cases of maxillary interpositional augmentation, they detailed their complications, which included two instances of inappropriate fracture during maxillary mobilization. These fractures occurred at the junction of the horizontal plate of the palatine bone and posterior part of the maxilla, thus making subsequent mobilization more difficult. They agreed with Farrell et al that a secondary vestibuloplasty was unnecessary and that the use of a splint was contraindicated as pressure from the flange was liable to create ischaemia. They found excellent short term

FIG. 11



An illustration of the Le Fort I osteotomy with interpositional bone graft (Sandwich). (From Bell and Buckles 1978)

FIG. 12



An illustration of the onlay graft position in the partial Le Fort I osteotomy (Horseshoe)

A. Following osteotomy

B. Onlay grafts being positioned

(From Farmand 1986)

stability, but the patients had worn their new dentures for less than a year and they concluded that long term follow up studies would be necessary. Unfortunately these have not become available.

Piecuch et al (1984) again described the use of the Le Fort I osteotomy with interpositional autogenous bone graft in three cases. Drawing on previous work and a two year follow up of their cases they stressed that stability was a characteristic of this procedure. This was despite significant relapse in one of their three patients as the result of using multiple small grafts. Even so, they felt that the bicortical graft described by Farrell et al was not justified (Farrell et al actually described only a cortico-cancellous graft). Firstly because it was not necessary for stability, secondly because of the morbidity associated with harvesting such a large piece of bone and thirdly because cancellous rather than cortical bone in contact with the lateral sinus walls led to a more rapid revascularisation of the graft. They preferred the use of cortico-cancellous bone to alloplastic materials and concluded that the procedure provided rehabilitation to patients who had previously been unable to wear a denture.

A quest for an alternative to autogenous bone graft led Frost et al (1982) to use allogeneous freeze-dried bone in interpositional osteotomies. In a study using six monkeys, they found that the graft functioned as a scaffold while the host bone bridges the osteotomy site. The healing times were comparable with non-grafted areas but they noted the graft had minimal osteogenic potential and was not incorporated into the host tissues. They also feared that allografts placed in proximity to the antrum were predisposed to infection and recommended the prolonged use of antibiotics.

Eppley and Sclaroff (1984) described a case in which allogeneous (freeze-dried) bone was used in an interpositional maxillary augmentation, which resulted in the formation of an oro-nasal fistula. The initial interpositional grafting procedure healed uneventfully, the fistula only forming subsequent to a secondary vestibuloplasty. The conclusion was reached that

the vascular supply to the overlying periosteum was compromised during the vestibuloplasty leading to sequestration of the graft and formation of the oro-nasal fistula.

Despite the obvious benefits that can result from this procedure certain disadvantages can be recognized. The extensive nature of the surgery, the necessity for a donor site and the corresponding increase in postoperative morbidity make the procedure a serious surgical undertaking for the geriatric, possibly medically compromised patients who would most benefit. Neither are long term results of factors such as the rate of resorption, denture comfort or antral disturbance available.

2.2.2 Partial Le Fort I (Horseshoe) osteotomy

Farmand (1986) described a horseshoe modification to the Le Fort I osteotomy (Fig. 12). His technique leaves the palate attached to the midface with the horseshoe alveolar section being moved inferiorly and anteriorly, creating a deeper palatal vault. This technique provides a solution to the problem encountered when the total Le Fort I osteotomy is used on patients with a poor (flat) palatal vault form. Farmand used either iliac crest or rib as the grafting material, the rib being lightly decorticated and scored on one side so that it could be bent and interposed between the mobilised alveolar process and the mid-facial bones. A vestibuloplasty was then used to mobilise the vestibular tissue. Fifteen patients were treated and reviewed over 15 months. Three cases of superficial mucosal necrosis and two cases of palatal fistulae, treated successfully by resuturing were noted and in half the cases the nasal mucosa was also damaged, but without consequence. An average of 10mm increase in the bony height of the alveolar process, with a good mucosal contour was evident postoperatively. In three cases the vestibuloplasty was not successful and had to be repeated.

An improvement in palatal vault profile was noted but no figures were

given. An average resorption rate of 1mm to 2mm was found during the first year, the maximum being in the initial postoperative months. Two reasons for the diminished resorption when compared with onlay grafts were put forward. The first was the possibility of providing prosthetic rehabilitation within three to four weeks and the second because the 'sandwiched' graft was being vascularised from both segments. Farmand concluded that this osteotomy was the method of choice in the case of extreme maxillary atrophy. There have, however, been no other reports of the technique published.

2.2.3 Segmental Le Fort I (anterior) osteotomy

Segmental osteotomies are used in orthognathic surgery primarily to correct localised deformities. Liposky (1979) adapted the technique and applied it in a case of anterior maxillary atrophy. He designed a stepped osteotomy that allowed a pedicled anterior fragment to be repositioned inferiorly while still maintaining bony contact laterally. A bone graft harvested from the malar eminence was placed in the midline inferior to the nasal septum to assist stability. An 18 month postoperative follow up revealed satisfactory function and stability of the new dentures.

No further studies using this technique have been reported but stability could be improved if a more substantial interpositional graft were used. This would have the added advantage of decreasing the size of the piriform aperture and supporting the upper lip and nasal base (Fonseca et al 1986).

2.3 RELATIVE AUGMENTATION

2.3.1 Palatal vault osteotomy

The technique of palatal inclusion was originally described over 50 years ago but has never gained popularity. The superior repositioning of the palatal vault causes a relative augmentation of the anterior maxilla which is particularly effective in resisting anterior/posterior denture movements. It can

ideally, however, only be employed where an adequate alveolar ridge is present.

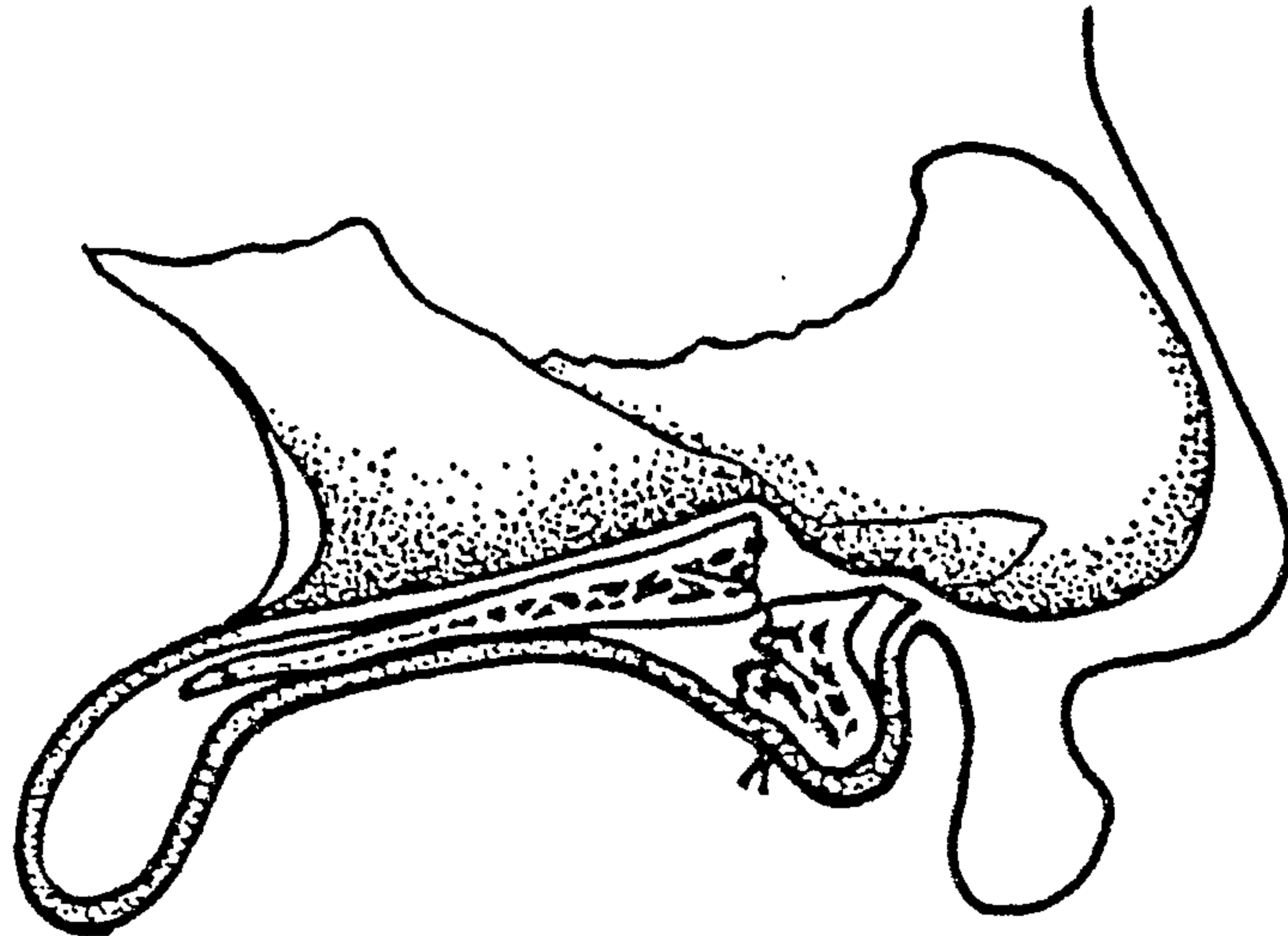
Charest and Goodyear (1976) described a palatal osteotomy technique in which a complete soft tissue palatal flap was raised. An osteotomy of the hard palate was then completed and downfractured, exposing the nasal mucosa and inferior aspect of the septum. Sufficient bone and cartilage was then resected from the septum to allow superior repositioning of the palatal fragment. By placing the anterior aspect of the fragment higher than the posterior it allows better anterior ridge form and posterior flow of nasal secretions (Fig. 13). Adequate mobilisation of the palatal tissue allowed primary closure and stability was achieved by securing the patient's denture, lined with compound, to the maxilla. They reported no major postoperative complications and an increase in the vault depth of 8 to 10 mm. However no case details or length of follow up time was included.

Leonard and Howe (1978) reported their experience with the same technique used for five patients. Initially they combined the procedure with a submucous vestibuloplasty and resection of mobile ridge tissue. However, unsatisfactory results prompted them to complete the mobile tissue resection three weeks prior to osteotomy. They reported an average ridge height of 5mm which provided 'great assistance' to the prosthodontists.

This technique has the advantage of simplicity while achieving increased denture stability from the relative augmentation of the alveolar ridge. However the mobilised palatal bone is vulnerable to necrosis because of its poor blood supply and neither are long term results available.

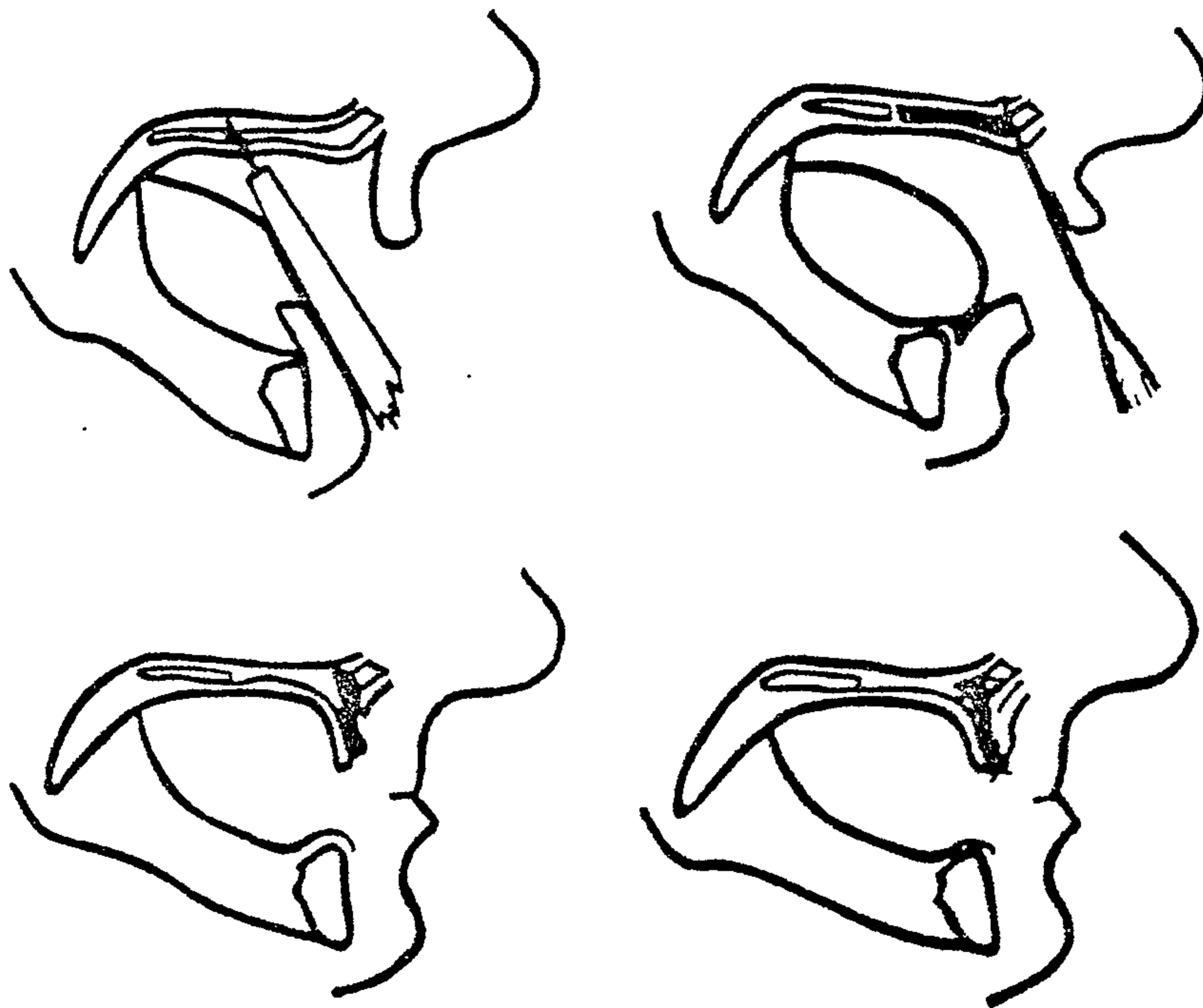
Barros-St. Pasteur (1983) detailed a further interesting palatal osteotomy for use in the atrophic maxilla (Fig. 14). He mobilised the palate anterior to the molar region and rotated the fragment inferiorly and anteriorly so that the transpalatal margin of bone became the alveolar ridge crest. However, only the technique was described with no results from clinical cases.

FIG. 13



A sagittal section showing the repositioning of the palate following the palatal vault osteotomy. (From Leonard and Howe 1978)

FIG. 14



A series of sagittal sections to demonstrate the rotated palatal pedicle flap. (From Barros-St Pasteur 1983)

3 CONCLUSION

I will follow the system of regimen which, according to my judgement, I consider for the benefit of my patients and abstain from whatever is deleterious.

Hippocrates (460-357 B.C.)

It has become apparent in this review that neither the onlaying nor inlaying procedures that have currently been developed for the atrophic maxilla and hypermobile ridge tissue provide the complete solution.

Onlay procedures provide genuine augmentation height but it is of a transitory nature if either autogenous or allogeneous tissues are used as the graft. Equally the currently available allografts do not provide a physiological repair, acting predominantly as fillers being retained in place by fibrous tissue rather than integrating with the host bone. There is current optimism that allogeneous bone treated to retain bone morphogenic protein (autolyzed antigen-extracted allogeneous [AAA] bone) will prove to be the solution because of its osteogenic capacity. However, to date the clinical results are not of sufficient duration for an opinion to be formed.

Interpositional (inlay) procedures, irrespective of the graft material, retain their augmentation height gain for longer than the onlay procedures. Unfortunately the procedures all require a high degree of surgical skill and hospital resources in conjunction with patients who are medically fit enough to withstand the increased surgical morbidity inherent with the surgery.

In an effort to solve the dilemma posed by maintaining the augmentation height gain without the postsurgical morbidity research has been focussed on the discovery of an ideal graft material.

This material must be biocompatible, bioactive and osteogenic, be able to provide long term augmentation and stability without resorption and be

placed without complicated surgery or the necessity of a donor site. The calcium phosphate ceramics, although not possessing all the necessary attributes, are at the forefront of this research.

CHAPTER IV

CALCIUM PHOSPHATE CERAMICS: PREPARATION, PHYSICAL PROPERTIES, BIOCOMPATIBILITY AND CLINICAL APPLICATIONS.