

CHAPTER 13PIN SYSTEMS

- 13.1 Introduction
- 13.2 Parallel pin technique
- 13.3 Non-parallel pin technique
- 13.4 Retention of the restoration by the use of "non-parallel" pins
 - 13.4.1 Introduction
 - 13.4.2 Factors influencing the retention of "non-parallel" pins in tooth structure
 - 13.4.3 Factors influencing the retention of "non-parallel" pins in restorative materials
 - 13.4.4 Summary
- 13.5 Stress-induced effects of pins
 - 13.5.1 Dentinal damage due to pin channel preparation
 - 13.5.2 Stress concentration and damage to tooth structure due to pin insertion
 - 13.5.3 Load distribution by retentive pins
 - 13.5.4 Summary
- 13.6 Microleakage in pin-retained restorations
- 13.7 Influence of retentive pins on the strength of the restorative material
 - 13.7.1 Influence of retentive pins on the strength of amalgam
 - 13.7.2 Influence of retentive pins on the strength of composite resin
 - 13.7.3 Summary

13.1 Introduction

For many years pins have been used to assist in the retention of restorations in both vital and pulpless teeth. A pulpless tooth, that has had multiple restorations, extensive caries or fracture, and a large endodontic access cavity may have insufficient tooth structure, even with the aid of root canal post(s), to retain the core foundation. One of the principal functions of a post is to distribute occlusal stresses over as wide an area in the root as possible (5.2); where circumstances allow, post retention is the preferred method of retaining the core foundation. Therefore, most commonly pins are only used in the restoration of an endodontically-treated tooth to provide additional retention for the core foundation; the use of a pin or pins may also enhance the resistance to rotational forces of the post-core foundation. When the use of posts is

either impractical or impossible for reasons outlined in 5.3.22, the rationale for the use of pins becomes a more important consideration.

Retentive pins are used clinically in different ways. The parallel pin technique is employed in conjunction with cast restorations and relies on a cementing agent for retention; the pins form an integral part of the cast restoration. Non-parallel pins are either cemented, threaded or driven into the tooth structure to retain plastic restorative materials such as amalgam or composite resin (Moffa, 1971). Threaded pins used in conjunction with a luting cement are also sometimes used to supplement the retention of cast restorations in the cross-pinning technique (Courtade, 1966; Fusilier, 1974). Different sizes and shapes of pins are available; some provide superior retention, others may distribute occlusal stresses more evenly.

The purpose of this chapter is to evaluate the benefits and possible hazards associated with various pin techniques. An attempt is made to establish guidelines for the selection of a pin-retention technique suitable for use in pulpless teeth, taking into consideration the physical differences in the tooth structure between a vital and an endodontically-treated tooth.

For some years, the design of pin-retained restorations was largely empirical. Research, in recent years, has provided a scientific basis for the design of conservative pin-retained restorations (Moffa, 1971). These scientifically established principles are discussed under the separate headings of pin retention (13.4), stress-induced effects of pins (13.5), microleakage (13.6), and the effect of pins on the strength properties of the restorative material (13.7).

The majority of research comparing the different types of pins was carried out in the late 1960's and in the early 1970's. Presumably because of the popularity of the self-threading pins, recent investigations have

concentrated on the various designs of self-threading pins (Barkmeier et al, 1978; Eames and Solly, 1980; Garman et al, 1980).

13.2 Parallel pin technique

The development of intra-oral paralleling devices, improvements in the accuracy of the indirect technique for the fabrication of cast restorations, and a standardization of the armamentarium have probably contributed to the simplification of this technique (Moffa, 1971, p.4). Basically, there are two types of pins used in parallel pin procedures. The first type of pin is made of cast gold and has a relatively smooth surface. The technique was originally introduced by Shooshan (1960) and involves the use of nylon pins which are incorporated into the wax pattern and subsequently burned out and cast as an integral part of the gold restoration. The shape and the surface details of the cast pin are influenced principally by the shape and the surface roughness of the nylon pin and by the type of investment used.

The second type of pin commonly used in this technique is the preformed, wrought precious metal pin made of alloys of gold, platinum-palladium, or platinum-iridium. The surfaces of these pins have been deformed or roughened by the application of threaded or knurled patterns. The pins are included in the wax pattern; their high melting point and tarnish resistance enable them to be incorporated within the final gold casting without any ill-effects.

A laboratory study by Moffa and Phillips (1967) demonstrated the effect of the length and the surface characteristics of the pin on the tensile load required to cause displacement of pin-retained gold castings. Threaded, wrought pins were found to be 20 to 30 per cent more retentive than the smooth cast pins. Retention of the cemented pin castings was found to increase as the number of pins, and the length and the diameter of the pins increased. When the length of the pin was greater than

1.0 mm, it was found that there was frictional resistance to withdrawal of the casting, even after the cement bond had broken. Clinically, this secondary retentive effect could potentially mask the presence of restorations in which the cement bond has failed; the frictional resistance to withdrawal may be adequate to maintain the restoration in position, but inadequate to prevent marginal microleakage or secondary caries. The principles of pin retention are discussed in more detail in 13.4.

13.3 Non-parallel pin technique

Three types of pins are available for use in this technique. Each type has certain advantages and disadvantages for the clinician; no single system can be considered superior in all aspects.

i. *Cemented pins*

The cemented pin system employs serrated, metal pins cemented into over-sized pin channels. Various pin-channel size combinations are available. In early articles (Markley, 1958; Courtade, 1963; Wing, 1965) in which this technique was described, as many as eight to ten pins were cemented into pin channels prepared in the dentine to a depth of 2-5 mm deep. The pins are usually cut to size from a length of serrated stainless steel wire and can be contoured and tried in the cavity before cementation (Fig. 13.1,a and 13.2,a).

ii. *Friction-locked pins*

Goldstein (1966) described a retentive pin technique in which a 0.022 inch diameter pin was driven into an under-sized pin channel of 0.021 inch diameter. The pin was held in by friction, utilising the elasticity of the dentine (Fig. 13.1,b and 13.2,b).

iii. *Self-threading pins*

The self-threading pin system also relies on the resiliency of the dentine for retention. Threaded pins are screwed into under-sized pin

channels. Several pin sizes are available for this technique. As with friction-locked pins, the length and contour of these pins are usually adjusted after insertion into the tooth. (Fig. 13.1,c and 13.2,c).

13.4 Retention of the restoration by the use of "non-parallel" pins

13.4.1 *Introduction*

Since, in the restoration of endodontically-treated teeth, pins are principally used to assist in the retention of the core foundation, an evaluation of the factors that may affect their retention in tooth structure and their ability to retain the restorative material should assist in the selection of the most appropriate pin technique for this purpose.

As stated by Moffa et al (1969), "although pins are not adhesive by nature, the factors involved in their successful use are mutually dependent and may be considered as a system which is no stronger than its weakest link". They suggested that retentive pin failure may occur in any one of five locations (Fig. 13.3):

1. fracture within dentine
2. at the pin-dentine interface (pin pulls out of dentine)
3. pin fracture (stresses in excess of the ultimate tensile strength of the pin)
4. at the pin-restorative material interface (pin pulls out of restorative material)
5. fracture within the restorative material.

13.4.2 *Factors influencing the retention of "non-parallel" pins in tooth structure*

The following parameters are known to affect the retention of pins in the tooth structure: pin type, pin diameter, length of pin embedded in dentine, the number of pins used, and the use of cavity varnishes and various cements (Collard et al, 1970).

1. Pin type

Studies by Dilts et al (1968) and Moffa et al (1969) found cemented pins to be the least retentive of the three types of pins tested. The friction-locked pins were intermediate in retention and were up to 2-3 times as retentive. The self-threading pins demonstrated the greatest retentive potential and were found to be as much as 5 to 6 times more retentive than cemented pins in dentine.

2. Pin diameter

For both the cemented and self-threading pins, there was a tendency for increased retention as the diameter of the pin increased (Dilts et al, 1968; Moffa et al, 1969). Friction-locked pins were only available in one size and the effect of pin diameter on retention was not tested.

3. Length of pin embedded in dentine

In two studies (Dilts et al, 1968; Moffa et al, 1969) a positive correlation was found, for all three types of pins, between retention and the length of pin embedded in the dentine. For cemented pins, it was found that there was a linear relationship between pin length — up to a length of 4 mm — and retention. For the friction-locked and self-threading pins, the rate of increase in retention lessened when the length of the pin exceeded 2.0 mm.

4. Number of pins used

According to Collard et al (1970) overall retention of the restoration increased with the number of pins used for all three types of pins. They suggested that the amount of tooth loss and the morphology of the tooth in question should determine the maximum number of pins used. The incorporation of an excessive number of pins may interfere with the placement of the restorative material and result in a restoration or core foundation of inadequate strength (Moffa et al, 1969).

5. Effects of cavity varnish and cementing agent

Since cavity varnishes minimize microleakage (Swartz and Phillips, 1961), their use in conjunction with retentive pins may be beneficial. In a study by Moffa et al (1968), it was found that when varnish was applied to the pin-hole before insertion of the cemented pin, the amount of microleakage around the pin was reduced; however, the retention of the pin was reduced by 46 per cent. The application of cavity varnish did not have any significant effect on the retention of friction-locked and self-threading pins and the leakage associated with these pin types was virtually eliminated.

Of the three cementing media investigated by Dilts et al (1968) — calcium hydroxide, zinc oxide-eugenol and zinc phosphate cements — zinc phosphate cement offered the greatest retention. A subsequent study by Moffa (1971, p.20), compared the ability of ten commercially available, modified zinc oxide-eugenol cements and a zinc phosphate cement, to retain pins. The tensile force required to dislodge a pin cemented in dentine with zinc phosphate cement was approximately double that required for the zinc oxide-eugenol cements. Although no significant difference in retention was demonstrated between posts cemented with zinc phosphate, polycarboxylate and glass ionomer cements, the possible benefits associated with the use of the latter two cementing agents deserve further investigation.

13.4.3 *Factors influencing the retention of "non-parallel" pins in restorative materials*

The ability of a pin to retain the restorative material may be influenced by the strength characteristics of the pin material and the restorative material, the surface characteristics of the pin, the length of pin embedded in the restorative material (Moffa, 1971, p.20-21) and the adaptation of the restorative material to the pin (Chan et al, 1977).

1. Strength of pin and restorative material

The retention of a pin in a pin-retained restoration is limited by the ultimate strength of the pin material as well as that of the restorative material. When the level of occlusal stresses exerted on the pin-retained restoration exceeded the ultimate tensile strength of the pin, the pin may fracture because of its relatively small size (Moffa et al, 1969; Welk and Dilts, 1969; Lugassy et al, 1972; Dilts et al, 1973). The mechanical properties of stainless steel (the most commonly used pin material) and the restorative materials most commonly used in conjunction with pins — amalgam and composite resin — have already been discussed in some detail in a previous chapter (6.8, 6.12 and 6.13).

2. The surface characteristics of the pin

Research by Moffa et al (1969) and Welk and Dilts (1969) indicated that the friction-locked pins were not as retentive in amalgam as the cemented and the self-threading pins. According to Moffa et al (1969), the increased retention of the amalgam provided by the cemented and self-threading pins may be a result of the greater number of surface deformations on these pins. Welk and Dilts (1969) found that, even when a right-angle bend had been placed, friction-locked pins could be straightened and pulled out of the amalgam without fracturing the pins; it was suggested that the ease of removal was related to the relatively low number of deformations on the surface of the pins.

Lugassy et al (1972) reported that, to that time, only the self-threading pins had been used in experiments on composite resin. Failure did not occur at the pin-composite resin interface but occurred, instead, either because of the fracture of the restorative material or fracture of the pin.

3. Length of pin embedded in restorative material

A linear relationship was found by Moffa et al (1969) between the pin length and the retention of amalgam by friction-locked pins. For the

cemented and self-threading pins, evidence has suggested that there is no advantage in placing these pins deeper than 2 mm into amalgam because, during testing, these pins fractured when the depth of embedment in the material exceeded 2 mm (Moffa et al, 1969; Welk and Dilts, 1969).

For the retention of composite resin, 2-3 mm has been found to be the optimal length of pin embedment for the self-threading pins. In the research by Lugassy et al (1972), it was found that, at this length, failure was a result either of the fracture of the composite resin or fracture of the pin itself. When Dilts et al (1973) embedded the stainless steel self-threading pins 4 mm into the composite resin, all were broken during testing and none were pulled out of the resin. The retention of the other types of pins in composite resin was not investigated.

4. Adaptation of the restorative material to the pin

In order to provide maximum retention for the restorative material, "the close adaptation of the restorative material to the pin is necessary" (Chan et al, 1977). These researchers examined the adaptation of three amalgams and three composite resins to the three basic pin types — cemented, friction-locked and self-threading. The adaptation of all the materials studied to the three types of pins was found to be consistently excellent.

13.4.4 *Summary*

For a given diameter and length of pin insertion, self-threading pins are the most retentive in both dentine and amalgam. Increasing the diameter of cemented and self-threading pins results in increased retention. Increasing the length of the pin embedded in dentine has a similar effect. For friction-locked and self-threading pins, the optimum depth of insertion in dentine is 2-3 mm; for cemented pins, the depth in dentine should be 3-4 mm. Provided there is adequate retention, the

number of pins used should be kept to a minimum. The use of cavity varnish greatly reduces the retentive properties of cemented pins. Because the use of cavity varnish minimizes the microleakage around friction-locked and self-threading pins (13.6), and has no effect on their retention in dentine, its routine use with these types of pins is recommended. Zinc phosphate cement was found to offer the greatest retention of the different types of cement tested (Moffa, 1971, p.20). Retention of the pins provided by more recently developed luting agents (such as glass ionomer cements) needs further investigation. Increasing the number of deformations on the pin surface improves the retention of the pin in the restorative material. Optimum retention of the pin in the restorative material can be provided by a pin length of 2 mm for the cemented and the self-threading pins.

13.5 Stress-induced effects of pins

As described in the previous section, the friction-locked and self-threading pin techniques involve the insertion of retentive pins in undersized pin channels in dentine. These techniques rely on the elastic properties of dentine for retention. Because of the relatively inelastic nature of enamel, care should be taken not to employ such techniques close to the dentino-enamel junction (Moffa, 1971, p.11). Stresses are generated in the tooth structure when retentive pins are used to retain a restoration. In an endodontically-treated tooth, the remaining dentine may become more brittle due to its lowered moisture content (Khera et al, 1978; Boyde and Lester, 1979); when selecting a pin technique for use in pulpless teeth, it is necessary therefore, to carefully weigh the benefits of the higher retention against the possible detrimental effects of the stress concentration generated. Dentinal defects associated with the use of retentive pins and twist drills are also considered in the following discussion.

13.5.1 *Dentinal damage due to pin channel preparation*

In a study by Standlee et al (1970), twist drills were found to cause dentinal cracks during pin channel preparation. When a new twist drill was used, no dentine faults were evident in the first 25 pin holes. It may be concluded that if a dull drill is used, the pressure necessary to prepare the channel and, possibly, the excess heat generated during preparation may lead to this type of dentine failure.

13.5.2 *Stress concentration and damage to tooth structure due to pin insertion*

1. Insertion of a single pin

Photoelastic analysis of retentive pin insertion procedures conducted by Standlee et al (1969) revealed that high installation stresses can develop during insertion of self-threading and friction-locked pins. When self-threading pins were used, lateral stress fields of low magnitude were observed around the individual threads; when the pin engaged the bottom of the pin channel, severe apical stress concentration was generated. Occasionally, crazing actually emanated from the base of the pin channel in the plastic photoelastic models. The severity of crazing appeared to be related to the amount of force with which the pin was driven against the base of the pin channel. Friction-locked pins transferred stress primarily in a lateral direction; no installation stresses were associated with cemented pins. Because of the potential for dentinal crazing with the use of self-threading pins, Caputo and Standlee (1976) suggested that these pins be inserted just short of the bottom of the channel.

This may be accomplished by threading the pin into the channel until resistance is encountered, then reversing or "backing off" one half turn — a type of control that cannot be accomplished with mechanical insertion of a pin.

An investigation of retentive pin insertion procedures in extracted human teeth was carried out by Standlee et al (1970) to determine the occurrence and nature of dentinal defects in the areas of stress concentrations shown in the 1969 study which used photoelastic models. Of the three types of pins tested, self-threading pins showed a tendency to generate the most dentinal cracks or crazing. These defects were evident in the apical one third of the pin channel and at the "corners" or "ramps" at the base of the channel. Localized "crushing" effects adjacent to the threads were detected at all levels beside the pin. In a series of 40 specimens, Standlee et al (1970) found two types of dentinal defects associated with the insertion of friction-locked pins:

1. lateral cracks perpendicular to the long axis of the pin, and
2. "shearing" or "flaking" of dentine apical to the leading edge of the pin.

There was a tendency for this type of pin to gouge into the channel wall and the pins very rarely reached the base of the pin channel. After testing another group of 60 specimens following the insertion of cemented pins, Standlee et al reported that "the cemented pins showed no tendency to cause any dentinal damage of any kind".

A laboratory study was conducted by Moffa and Razzano (1971) to determine the influence of cemented, friction-locked, and self-threading pins on the production or aggravation of crazing in the enamel. Since it was extremely difficult to obtain extracted human teeth with no evidence of prior cracks or craze patterns, a penetrant fluorescent dye technique was employed to visualize and photograph the cracks in the teeth before and after the insertion of the three types of pins. When inserted to a depth of 2.0 mm, the cemented pins did not cause any crazing in the enamel even when the pins were placed at the dentino-enamel junction

(Table 13.1). The self-threading pin technique demonstrated a definite potential for causing crazing at the dentino-enamel junction; however, this technique appeared to be relatively safe at a distance of 0.5 to 1.0 mm from the junction. In this test, it was the friction-locked pin technique that presented the greatest likelihood of cracking and craze formation in the enamel. Even at a distance of 1.0 mm from the dentino-enamel junction, there was a tendency for crazing of the enamel to occur. As a result of this research, these researchers recommended that, when clinical conditions demanded that the retentive pin be placed at or very close to the dentino-enamel junction, the cemented pin technique should be used. Boyde and Lester (1979) did caution, however, that considerable hydrostatic pressure could be generated during pin insertion with a viscous cementing medium.

Chan et al (1974) compared the influence, on the development of dentinal crazing, of hand insertion and mechanical insertion techniques for self-threading pins. They reported a lower incidence of dentinal crazing with the mechanical insertion technique using a reduced-speed, contra-angle handpiece equipped with a 10 to 1 reduction gear*. In contrast with the findings of Chan et al (1974), Guerrero (1979) observed that mechanical insertion of self-threading pins produced cracks of a more severe type than those produced by slow hand insertion.

A study by Pameijer and Stallard (1972) used a replica technique to examine, with a scanning electron microscope, the effects of the insertion of self-threading pins into dentine. They concluded that the cracks observed in the dried specimens were the result of specimen preparation procedures. Although Boyde and Lester (1979) also concluded in their study that the small cracks in the dentine around the self-

*Auto-Klutch, Whaledent International, New York, N.Y., U.S.A.

threading pins were artefacts of drying, they emphasized that these were areas of high stress in the dentine resulting from the deformation caused by inserting the pin. In conflict with these results, Guerrero (1979) reported the presence of cracks in the dentine around self-threading pins using the replica technique. She attributed this difference to the variation in the method of specimen preparation. Moreover, cracks have been observed by other workers using other techniques (Dilts et al, 1970; Standlee et al, 1970; Moffa and Razzano, 1971; Caputo et al, 1973; Chan et al, 1974; Khera et al, 1978) and the majority opinion holds that screwing pins into dentine damages it (Boyde and Lester, 1979).

2. Insertion of multiple pins

As mentioned previously, retention increases with the number of pins used (for each of the three types of pins). A photoelastic study of installation stresses associated with retentive pin techniques (Standlee et al, 1969) showed that, when multiple self-threading pins were inserted, the individual apical stress fields "interacted" laterally and apically. "Interaction" was most pronounced at spacings between pins of 2 mm or less. When multiple friction-locked pins were inserted, the stresses were accentuated as the lateral stress fields "interacted" between the pins. The stress "interaction" of self-threading pins was later studied in freshly extracted teeth (Standlee et al, 1970). At a depth of 2 mm, communication cracks were observed with both 1 mm and 2 mm spacing between the pins.

In a more recent study, Khera et al (1978) examined the crazing effects on dentine of self-threading pins* of three different sizes — 0.019 inch (Minikin), 0.023 inch (Minim), and 0.031 inch (Regular) diameter. They found that all three sizes of self-threading pins caused

*Thread Mate System, Whaledent International, New York, N.Y., U.S.A.

dentinal crazing and, when two or more pins were placed in the same tooth, the potential for dentinal damage increased. Of the three sizes, the smallest pins (Minikin) caused the least amount of crazing. The optimum and safe inter-pin distance suggested by this study was 3 mm, when using the Minikin pins, and 5 mm when using the Minim or Regular pins. However, these authors suggested that, in endodontically-treated teeth, where the remaining dentine might be dehydrated and less resilient than normal, it would be advisable:

1. to use only the smallest self-threading pins, and
2. possibly, to increase the inter-pin distance if two or more pins were to be used.

Because of the potential for damage of the dentine by self-threading pins, some authors (Boyde and Lester, 1979) recommended the use of cemented pins in endodontically-treated teeth.

13.5.3 *Load distribution by retentive pins*

To be able to use retentive pins effectively, Caputo et al (1973) suggested that the clinician required a knowledge of the manner by which masticatory forces were transmitted to the remaining tooth structure by the pins. In order to study this process of load distribution, Caputo and his co-workers used plastic photoelastic models into which the three different types of pins — cemented, friction-locked and self-threading — were placed. Compressive and shear forces were applied to these specimens.

When subjected to compression, all three types of pins showed an increase in the apical concentration of stress. The increase in apical stress concentration was much more pronounced for the friction-locked and the self-threading pins than for cemented pins. Both the distance between pins and the length of the pin supported by tooth structure appeared to have an effect on the distribution of compressive loads applied to the tooth structure by way of the pin-retained restoration.

The maximum apical stress generated by the application of compressive loads to all three pin types decreased with increased spacing and with increased depth of pin insertion. Lateral "interactions" were most severe with friction-locked pins and least severe with cemented pins. Similarly, lateral "interactions" decreased with increased depth of pin insertion and spacing of the pins.

When a compressive load was applied to a specimen with pins inserted at 45° to the dentine-restoration interface, a different stress-transfer phenomenon was observed. In all three types of pins, there were "interactions" between one pin and the occlusal portion of the next adjacent pin. When the pins were closely placed, this "interaction" was most intense at the pin-dentine-restoration interface.

When the specimens were subjected to shear forces, the principal stresses transferred to the simulated dentine by all types of pins were lateral stresses. There was also a tendency for lower stress concentration to have occurred with increased depth of insertion and spacing between the pins.

Caputo et al (1973) concluded that the forces of mastication could result in the propagation of cracks induced during pin insertion, and could develop sufficient intensities of stress to initiate cracks.

13.5.4 *Summary*

Cemented pins have been found to provide a more uniform distribution of occlusal loads into dentine than do friction-locked and self-threading pins. For all types of pins, an increased depth of pin insertion resulted in more even stress distribution. Increasing the spacing between pins resulted in smaller inter-pin stresses and also lowered the maximum level of stress created in the dentine. Because of the increased potential for dentinal crazing associated with the use of the friction-locked or self-threading pin technique, the cemented pins were recommended for use in endodontically-treated teeth (Boyde and Lester, 1979).

13.6 Microleakage in pin-retained restorations

Restorative materials commonly used in conjunction with retentive pins are not adhesive and do not effectively seal the cavity preparation (Moffa et al, 1968). Marginal adaptation and microleakage occurring around composite resin (Al-Hamadani and Crabb, 1975; Eliasson and Hill, 1977; Luscher et al, 1978; Hormati and Chan, 1980) and amalgam restorations (Wing and Lyell, 1966; Massler, 1978, p.40-43; Hormati and Chan, 1980) are well documented in the literature. In a pulpless tooth, marginal leakage might contribute to recurrent caries, corrosion of the pin and/or the core material, dissolution of the luting agent and loss of retention of the cemented pin (Moffa et al, 1968). In addition, leakage between the amalgam and the pins may be associated with corrosion in the interface region and leakage between the composite resin and the pins may cause discolouration of the material (Chan et al, 1980).

Moffa et al (1968) investigated the microleakage that occurred around the three different types of pins and the effectiveness of cavity varnish in reducing or eliminating the microleakage. Without cavity varnish, all three types of pin exhibited microleakage. Although the cemented pins exhibited the least leakage initially, after a period of six months, the leakage which occurred at the cement-dentine interface had actually affected the cementing medium to an extent that the retention of the pin was no longer acceptable. When cavity varnish was applied to the pin holes prior to pin insertion, there was a definite decrease in microleakage with each type of pin. The cavity varnish was effective in inhibiting microleakage for the three types of pins up to a period of thirty days. After six months, the cavity varnish remained effective in assisting to inhibit microleakage only around the friction-locked and self-threading pins; there was evidence of leakage around the cemented pins.

As mentioned in 13.4.3, Chan et al (1977) examined the adaptation of three composite resin materials and three amalgams to the three basic types of pins. They reported consistent and excellent adaptation of all the materials studied to all pin types. A more recent study (Chan et al, 1980), was conducted to investigate the microleakage between retentive pins and three composite resin materials, and between the pins and three amalgams. All the amalgams and composite resins tested showed excellent sealing properties when used with the three types of pins studied — cemented, friction-locked and self-threading pins.

13.7 Influence of retentive pins on the strength of the restorative material

Since Markley (1958) described the cemented pin technique for the provision of additional retention for amalgam restorations in teeth with substantial loss of the clinical crown, retentive pins have become an indispensable part of restorative dentistry. Techniques using the various types of pins with amalgam in vital teeth have been described (Wing, 1965; Zarb, 1965; Going, 1966; Johns, 1969; Winstanley, 1971). These techniques were modified somewhat for use in pulpless teeth either with (Baraban, 1972; Newburg and Pameijer, 1976; Kantor and Pines, 1977; Locke, 1977) or without (Markley, 1966; Lovdahl and Nicholls, 1977; Brown et al, 1979) the aid of root canal posts.

Although composite resin was introduced as a restorative material in the 1960's, it was not until the early 1970's that techniques designed specifically for the placement of pin-retained composite resin restorations appeared in the dental literature (Ambrose et al, 1971; Spalten, 1971; Janis and Lugassy, 1972; McPhee, 1974). Subsequent authors described the use of this material with retentive pins and posts for the restoration of endodontically-treated teeth (Baraban, 1972; Spanauf, 1972; Moll et al, 1978; Lorey, 1980).

For some time after Markley (1958) described the cemented pin technique, it was thought that the threaded stainless steel pins actually reinforced and strengthened the amalgam restoration similar to the manner whereby steel rods reinforce concrete. Since then, many studies (13.7.1) have been conducted to test this hypothesis and to determine the influence of pins on the compressive, tensile, and transverse strength characteristics of amalgam. Because of the limited use of composite resin as a restorative material in the posterior region of the mouth, and the introduction of the enamel-etching technique for retaining this material in anterior teeth, pin-retained composite resin restorations have not been used as widely as pin-retained amalgam. However, because of the potential, for clinical use, of pin- or post-retained composite resin as a foundation for cast restorations, recent studies have examined the affects of pins on the physical properties of the resins.

13.7.1 *Influence of retentive pins on the strength of amalgam*

13.7.11 Compressive strength

The compressive strength of amalgam specimens containing different numbers of pins — 0 to 4 pins, each 2-3 mm in length — was studied by Wing (1965). The compressive strength was determined at one hour, and at seven days when the amalgam was fully set. He found that the compressive strengths of the two amalgams tested were reduced when retentive pins were included. The reduction was evident both in the one-hour and the seven-day specimens and varied with the number of stainless steel pins used. When only one pin was used, the change in the compressive strength of the amalgam was negligible. However, when three or four pins were incorporated, the one-hour strength of the amalgam was reported to be only approximately one third of the strength of the control specimens with no pins; the seven-day strength was approximately two thirds of the normal strength of the amalgam.

In an early study by Going (1966), it was also found that the compressive strength of the amalgam specimens decreased with the inclusion of an increased number of retentive pins. However, even with the incorporation of seven pins in the specimens, there was only a reduction of ten per cent in the compressive strength of the amalgam. Subsequent studies by Going and other researchers did not find any significant difference in the seven-day compressive strength between specimens with four, one or no pins. (Going et al, 1968). Contrary to the findings of Wing (1965), Going and Nostrant (1969) found no significant difference in the early compressive strength of amalgam specimens containing no pins, four 2 mm short pins, or four 10 mm long pins. Strength determinations were carried out at 30 minutes and two hours.

Welk and Dilts (1969) confirmed that the presence of retentive pins did influence the strength properties of amalgam. With no retentive pins present, the amalgam specimens had a compressive strength of approximately 397 MPa. When from one to six pins were included, there was a reduction in compressive strength ranging from approximately 4.8 to 15.8 MPa. The opinion was expressed that a decrease in the compressive strength of amalgam of this magnitude was probably of no clinical significance.

Although the amount of reduction in compressive strength of amalgam due to the presence of retentive pins has, therefore, been a somewhat controversial issue, it has generally been agreed that pins definitely *do not* reinforce amalgam or increase its compressive strength (Wing, 1965; Going, 1966; Going et al, 1968; Going and Nostrant, 1969; Welk and Dilts, 1969).

13.7.12 Transverse and tensile strength

Several investigators (Mahler, 1958; Rodriguez and Dickson, 1962; Mahler and Mitchem, 1964; Going, 1966) have suggested that either the

transverse strength or the tensile strength of amalgam, or both strengths, may be more important clinically than the compressive strength. Welk and Dilts (1969) tested the influence of threaded stainless steel pins and friction-locked pins on the transverse strength of amalgam. They found that the presence of these pins significantly decreased the transverse strength of the amalgam.

The diametral loading method was used by Going and co-workers (1968) to test the tensile strength of amalgam specimens containing no pin, one pin or three retentive pins. The orientation of the retentive pins to the tensile load appeared to have a much more pronounced effect on the tensile strength of the amalgam than the number of pins present. The most pronounced reduction in tensile strength occurred when the specimens were stressed in a direction that was perpendicular to the direction of the pin, a less pronounced reduction occurred when stressed at a 45 degree angle, and no significant reduction occurred when the specimens were stressed parallel to the long axis of the pins. These findings were consistent with those of Cecconi and Asgar (1968) who also investigated the effect of pin location on the tensile strength of amalgam.

Duperon and Kasloff (1973) tested the effect of three types of pins — serrated stainless steel, smooth stainless steel, and silver-plated, platinum-gold-palladium pins — on the tensile strength of amalgam. When the pins were placed in a position that was perpendicular to the tensile force, there was a significant decrease in the tensile strength of the amalgam as the number of pins increased; this decrease was evident in specimens tested at one hour and those tested at twenty four hours. However, when the pins were positioned parallel to the tensile stress, their results were a little different from those of the earlier investigations (Cecconi and Asgar, 1968; Going et al, 1968). At one hour, the serrated stainless steel pins and the silver-plated, platinum-gold-

palladium pins were responsible for a significant increase in the tensile strength of amalgam; the increase in strength was greater when the number of pins increased from one to three. When the same tests were conducted 24 hours after condensation, the increase in tensile strength of the specimens which contained pins was only slight. It appeared that the strengthening effect of the embedded pins on the amalgam specimens was a function of their retention within the amalgam. These researchers hypothesized that the pins increased the resistance of the amalgam to the splitting tensile force by "stapling the two halves of the specimen together".

Earlier attempts had been made (Moffa, 1971) to develop a true, adhesive bond between the pin and the amalgam, either by silver-plating or gold-plating the stainless steel pin or by fabricating the pin in silver. Microscopic examination of the pin-amalgam interface, however, revealed the presence of voids and no adhesive bond to amalgam was able to be demonstrated; compared with the control specimens, neither the silver nor the silver-plated stainless steel pins had any significant effect on the compressive strength of the amalgam. When the nature of the fracture was examined, it was found that the specimens containing the stainless steel pins (either plated or unplated) usually fractured through the pin-amalgam interface while the silver pins remained enclosed within the matrix and the fracture passed at some distance from them.

13.7.2 *Influence of retentive pins on the strength of composite resin*

The effect of the inclusion of retentive pins on the compressive and tensile strengths of composite resin was investigated by Lugassy et al (1972) and Dilts et al (1973). When retentive pins are used clinically with composite resins — in the restoration of an extensively broken-down tooth or in a core foundation designed to support a cast restoration — they may be subjected to stresses, induced during finishing of the composite

resin, preparation for the crown, or during impression procedures, before polymerization has been completed. For these reasons, in order to determine the influence of pins on the early and fully-set strength properties of the composite resin, compressive and tensile strength tests were performed on specimens at 10 minutes and at 24 hours (Lugassy et al, 1972), and at 30 minutes and one week (Dilts et al, 1973).

Both at 10 minutes and at 24 hours, Lugassy et al (1972) reported a significant increase of approximately 20 per cent in the compressive strength associated with the inclusion of the self-threading pins. In agreement with these findings, Dilts et al (1973) also reported a significant increase in the compressive strength of specimens containing pins; the compressive strength of the resin material increased as the number of pins increased. Although the increase was statistically significant, these authors observed that an increase of this magnitude was probably of little clinical significance. Acknowledging the fact that comparable studies performed on amalgam specimens demonstrated an opposite effect, Lugassy et al (1972) suggested that it was probably the structural nature of the amalgam matrix, the low elasticity, and the high susceptibility to crack propagation of the amalgam that were responsible for the reduction in the compressive strength with amalgam. They suggested that the self-threading pins in the composite resin may play a dual role — to reduce the amount of stress applied on the resin and to act as reinforcing beams supporting some of the load applied on the specimen. The presence of the pins in the composite resin specimen which was subjected to compression may have, to a certain degree, acted as a "damping mechanism" against the propagation of cracks in the material and thereby helped in resisting higher compressive loads (Lugassy et al, (1972).

The effect of pins on the tensile strength of the composite resin was a little different. The inclusion of pins placed perpendicularly to

the direction of load application resulted in a definite reduction in the tensile strength of the specimens in both studies (Lugassy et al, 1972; Dilts et al, 1973). Although there were differences in the amount of reduction in strength between the different brands of composite resin materials tested, Dilts et al (1973) considered that the decrease in the tensile strength of these materials was probably too small to be of clinical significance.

In the study of Dilts et al (1973), the inclusion of up to three pins in the composite resin specimens did not appear to have any significant effect on the transverse strength of the material.

13.7.3 *Summary*

Since the inclusion of retentive pins does not contribute to the strength of amalgam or composite resin to any significant extent, the number of pins used should be kept to a minimum as long as adequate retention is provided for the restorative material.

Table 13.1

Incidence of crazing in enamel with different pin techniques
(from Moffa and Razzano, 1971)

Pin type	Distance of pin from the dentino-enamel junction (mm)	Number of teeth tested	Number of teeth with evidence of enamel crazing
cemented (0.025 inch)	0	10	0
	0.5	10	0
	1.0	10	0
friction-locked (0.022 inch)	0	10	10
	0.5	10	7
	1.0	10	2
self-threading (0.023 inch)	0	10	3
	0.5	10	0
	1.0	10	0

Fig. 13.1 Schematic drawing of the three pin systems.

a. cemented pin.

b. friction-locked pin.

c. self-threading pin.

(from Caputo and Standlee, 1976)

Fig. 13.2 Retentive pin insertion techniques.

a. cemented pin — 1. slow speed handpiece.

2. short lentulo spiral used to introduce
the luting cement into the pin holes.

3. grooved self-locking tweezers.

4. pin with right angle bend before
insertion.

b. friction-locked pin —

1. mallet.

2. pin holder.

c. self-threading pin —

1. wrench.

2. pin may be shortened before insertion.

(adapted from Going, 1966)

Fig. 13.3 Possible sites of retentive pin failure.

(from Moffa et al, 1969)

Fig. 13.1; 13.2; 13.3

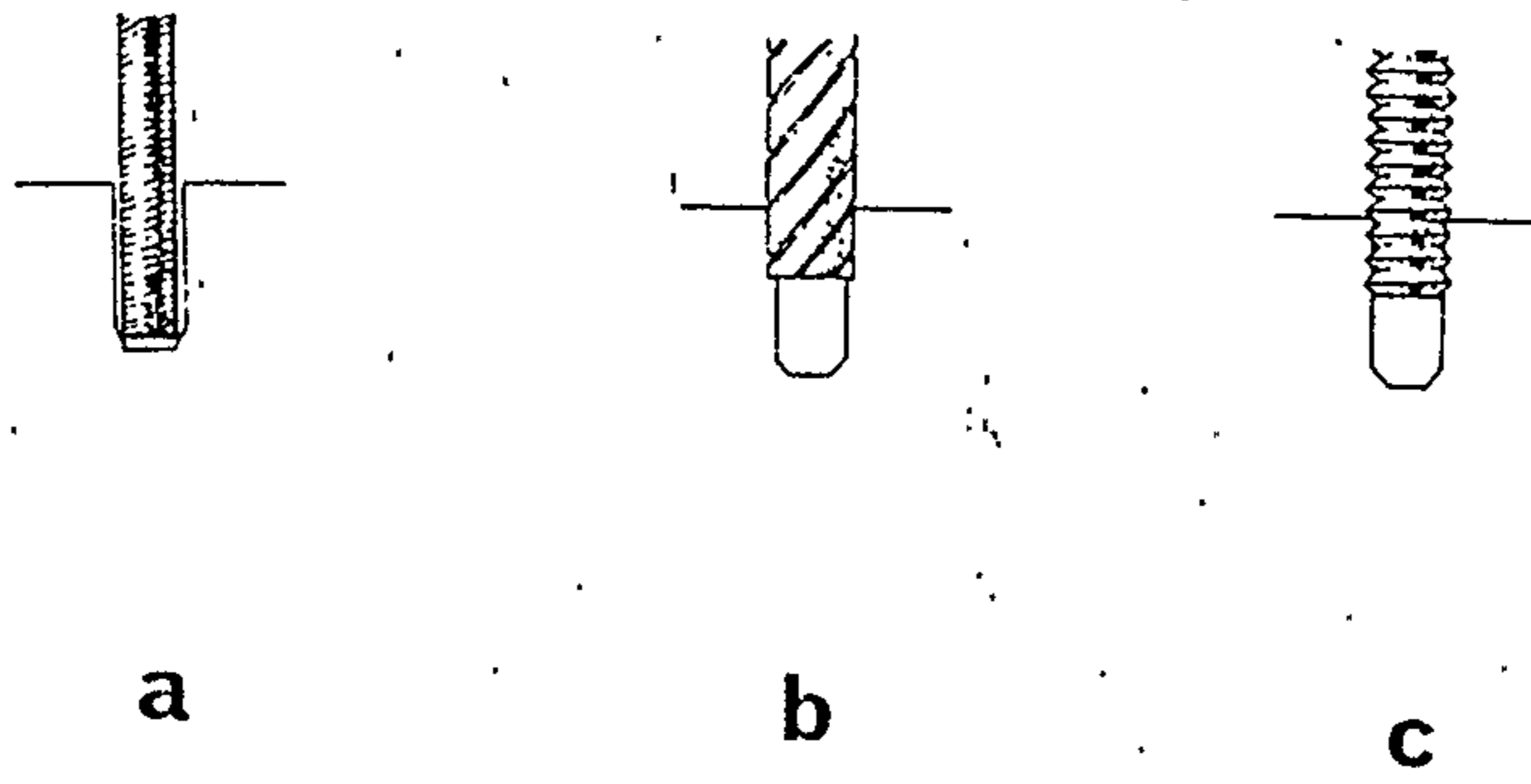


Fig. 13.1

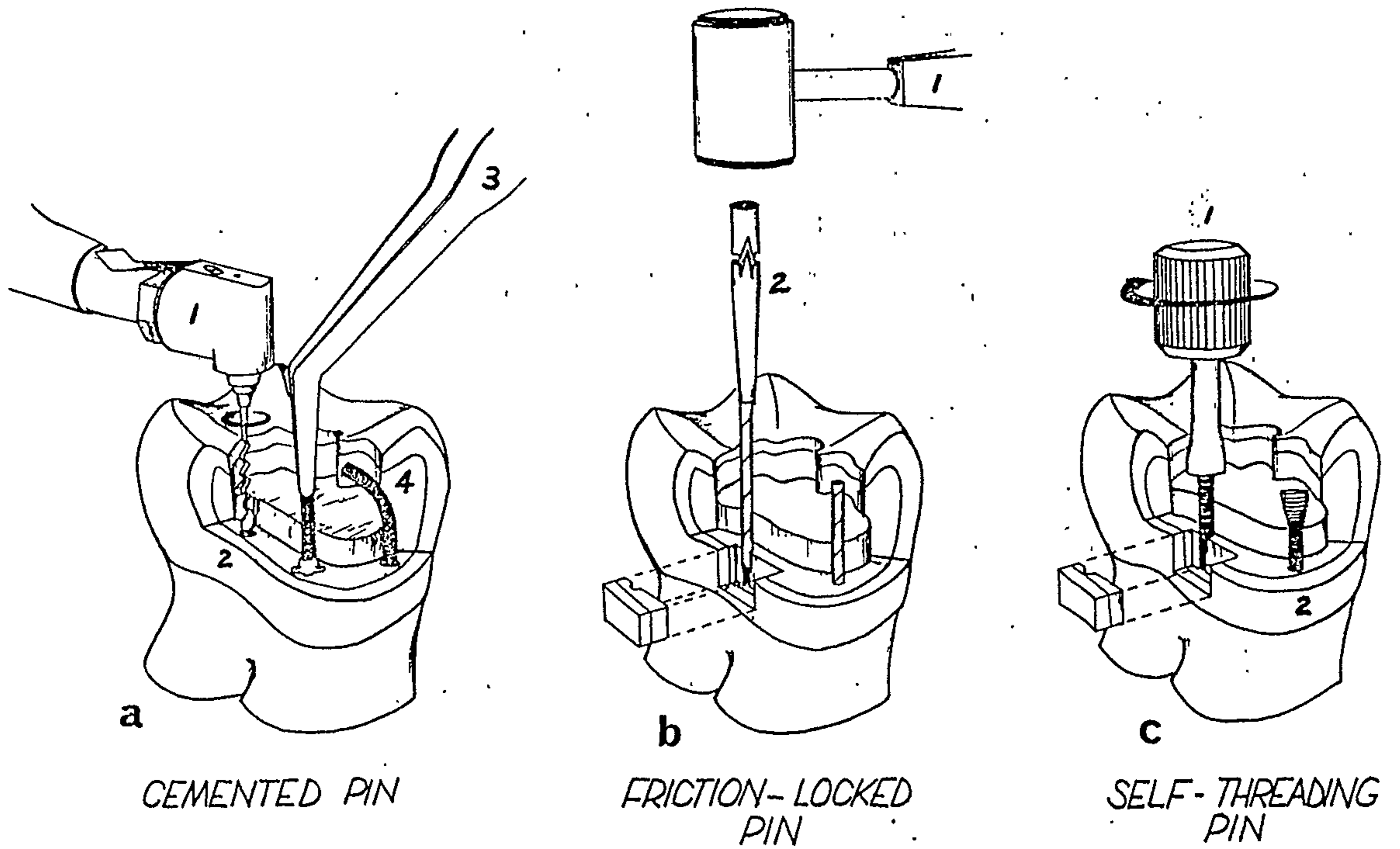


Fig. 13.2

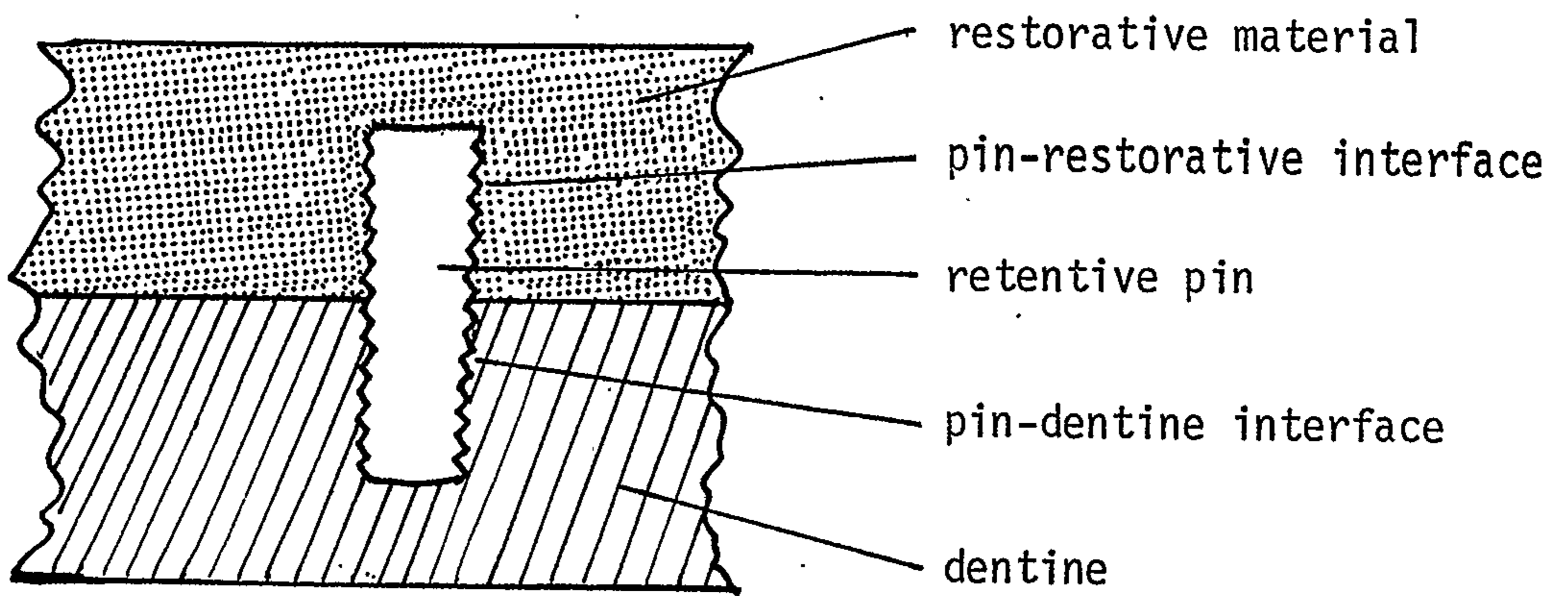


Fig. 13.3

CHAPTER 14THE CORE FOUNDATION

- 14.1 Introduction
- 14.2 Selection of the core material
- 14.3 Laboratory research
 - 14.3.1 The resistance to occlusal forces of core foundations in anterior teeth
 - 14.3.2 The resistance to occlusal forces of core foundations in posterior teeth
 - 14.3.3 Microleakage
 - 14.3.4 Retention of cast gold crowns cemented to amalgam and composite resin cores
- 14.4 Discussion
- 14.5 Secondary intention post-core foundations
 - 14.5.1 Introduction
 - 14.5.2 Fracture of the tooth preparation
 - 14.5.3 Pulp death underneath a crown or bridge

14.1 Introduction

When there is substantial loss of tooth structure in the clinical crown of a pulpless tooth, it has generally been considered preferable that treatment should be accomplished by a two-stage process in which a separate final restoration is placed over a core foundation (5.5.5). Several types of core foundations have been used for both anterior and posterior endodontically-treated teeth (Fig. 14.1):

1. Cast gold post-cores are commonly used on anterior teeth but, because of root canal direction and size, have been less popular than alternative techniques in the restoration of posterior teeth.
2. Amalgam or composite resin cores retained by prefabricated metal posts which have been placed into the prepared root canals. Retentive pins may be used for additional retention and stability.
3. Amalgam, composite resin, or cast metal cores retained by self-threading, cemented, or cast pins.

14.2 Selection of the core material

It has been commonly acknowledged that the cast gold post-core is a reliable method of providing a foundation for the final coronal

restoration (Rosen, 1961; Nicholls, 1963; Silverstein, 1964; Gentile, 1965; Baraban, 1967; Sheets, 1970; Colman, 1979). However, the relative complexity of the technical procedures involved in its fabrication, and the marked increase in the price of noble metals in recent years have probably resulted in the search for satisfactory alternative techniques. This situation is particularly apparent in multi-rooted posterior teeth where the clinical and laboratory procedures involved in the fabrication of a multiple-unit, interlocking cast gold post-core, are often difficult and time-consuming (Rosen, 1961; Nicholls, 1963; Skurnik, 1965; Baraban, 1967; Perel and Muroff, 1970; Abdullah et al, 1974; Wearn, 1974; Henry and Bower, 1977, a; Caruso et al, 1978, p.488-500; Michnick and Raskin, 1978; Welsh and Priddy, 1978). The cost of this type of post-core foundation, particularly when added to the cost of the endodontic treatment and the final coronal restoration, may, in some cases, become the deciding factor as to whether a pulpless tooth is to be saved.

Markley (1958) suggested the use of amalgam core foundations retained by cemented stainless steel pins as a simple, "more satisfactory" and more economical alternative to the traditional cast gold post-core. As the development of prefabricated post systems progressed, many clinicians (Courtade, 1963; Abdullah et al, 1974; Wearn, 1974; Tidmarsh, 1976; Henry and Bower, 1977, a; Leggett, 1979) have indicated their preference for the use of root canal posts whenever possible, for the support of the amalgam foundation. Leggett (1979) thought that the use of auxiliary pins, whether threaded or cemented into prepared pin holes, would "inevitably further weaken the remaining tooth structure and render it more liable to splitting".

In recent years, composite resin core foundations retained by root canal posts (and in some cases, additional retentive pins) have been recommended for use in anterior (Baraban, 1972; Steele, 1973; Federick, 1974; Federick and Serene, 1975; Stern and Kochavi, 1977;

Colman, 1979; Lorey, 1980) and posterior endodontically-treated teeth (Baraban, 1972; Spanauf, 1972; Eissmann and Radke, 1976, p.551-555; Johnson et al, 1976; Tidmarsh, 1976; Lorey, 1980; Behrend, 1981).

The potential for crown preparation of composite resin cores immediately after polymerization, within the same appointment, has been considered a primary advantage of this material.

The selection of the materials and method of construction of a post-core foundation for a particular case is dependent on a consideration of several factors.

The intensity, direction and duration of occlusal stresses to which the pulpless tooth is likely to be subjected (Locke, 1977; Ross, 1980; McKerracher, 1981,a). According to Malone et al (1978, p.105) forces are placed on teeth from a "myriad of angles". These may result from "mastication, bruxism, biting habits, a demanding dietary intake, and a host of intangible, unpredictable stresses". In order to support the final coronal restoration, the material, or combination of materials used for the post-core foundation must be able to withstand adequately the functional and non-functional stresses applied to the tooth. The four main types of stresses present on restorative components in the oral cavity are tension, compression, shear and torque (Greener et al, 1972, p.45). These are illustrated in Fig. 6.1.

Several authors (Harper and Lund, 1976; Colman, 1979) have indicated that, in most clinical cases, the nature of occlusal stresses applied to anterior and posterior teeth are somewhat different. Anterior teeth in a "normal overbite/overjet" relationship are likely to be subjected to more transverse stresses than posterior teeth; in general, occlusal forces are more vertically oriented in the posterior areas of the mouth (Colman, 1979). Therefore, the occlusal forces applied to a post-core foundation in an endodontically-treated posterior tooth are likely to have a higher compressive component. Similarly, the shear and

tensile components of occlusal forces applied to anterior teeth are probably greater than those applied to posterior teeth. Thus, the clinical performance of the different types of core foundations may depend, to a certain degree, on the ability of the particular material to withstand the types of occlusal forces present in that part of the mouth.

The mechanical properties of the core foundation

The ability of the core foundation to resist occlusal forces depends on two important factors:

- a. the strength of the post, pin and core materials, and
- b. the retention of the core foundation in the prepared pulpless tooth.

a. The strength of the core foundation is influenced by the following factors:

- i. the type of material used — that is, the type of casting alloy, amalgam or composite resin.
- ii. the quality of the casting and the adequacy of the manipulative techniques used in the condensation of the amalgam and the placement of the composite resin.
- iii. in the case of amalgam and composite resin, the provision of an adequate bulk of the material to provide maximum strength.
- iv. the presence of metal posts and/or pins in the amalgam or composite resin core material.

b. The retention of the core foundation in the pulpless tooth is affected

- by:
- i. the number, the length and the direction of posts and/or pins used,
 - ii. the accuracy of the internal adaptation of the core foundation,
 - iii. presence of undercuts in the tooth preparation, and
 - iv. the ability of the material to bond to the remaining tooth structure.

14.3 Laboratory research

14.3.1 *The resistance to occlusal forces of core foundations in anterior teeth*

Because of the greater demand for the restoration of endodontically-treated anterior teeth (than posterior teeth), several studies have specifically examined post or pin-retained core foundations in anterior teeth (Lovdahl and Nicholls, 1977; Moll et al, 1978) or single-rooted teeth (Kantor and Pines, 1977). Force was applied at angles of either 130 or 135 degrees to the long axis of the tooth. Kantor and Pines (1977) chose an angle of 135 degrees because they considered that it approximated a combination of forces which was likely to be exerted on teeth, rather than a purely compressive or shear force. Lovdahl and Nicholls (1977) chose an angle of 130 degrees to simulate the average angle of contact found in Class I occlusions between maxillary and mandibular anterior teeth.

Kantor and Pines (1977) compared the failure of cast gold post-cores and stainless steel post-retained composite resin cores, with both a non-reinforced and a steel post-reinforced tooth. All the single-rooted teeth were prepared to a "standardized form" but no crown was placed during testing.

Lovdahl and Nicholls (1977) compared pin-retained amalgam cores and cast gold post-cores with an unrestored, but endodontically prepared tooth. No crowns were placed and the cores were prepared to approximately normal tooth contour. Moll et al (1978) compared the strength of specimens prepared using either a pin-retained composite resin post-core or a cast gold post-core; a metal crown was cemented to the cores before testing. All the teeth used in the two experiments were maxillary anterior teeth. The findings of these two studies and the merits of using either posts or pins for the support of the core foundations are discussed in 5.3.22.

Although the results obtained by Kantor and Pines (1977) indicated that the specimens with the cast gold post-cores were able to withstand slightly higher loads than the stainless steel post-retained composite resin cores, there was a tendency for the gold post-cores to split the pulpless tooth vertically when subjected to the test force. In contrast, the composite resin cores failed by fracturing away from the stainless steel post and the tooth. Because of the lower strength of the composite resin, these researchers recommended against the use of the material in a "strategic abutment".

Although certain materials and methods of core construction have been found to provide stronger or more retentive core foundations than others, their use may also be associated with a higher incidence of root fracture. It was suggested (Lovdahl and Nicholls, 1977) that: "if failure does occur in the oral environment the least amount of damage to tooth structure is desirable". Because any substantial damage to the pulpless tooth may prevent further repair and may lead to the loss of the tooth, the additional strength or retention gained should be weighed against the higher risk of root fracture.

14.3.2 *The resistance to occlusal forces of core foundations in posterior teeth*

Amalgam has been widely accepted as a satisfactory alternative to cast gold alloys as a core material in endodontically-treated posterior teeth. The introduction of composite resins for the same purpose has given the clinician a wider choice of restorative techniques. Amalgam and composite resin "build-ups" are relatively inexpensive and less complex than the conventional cast gold post-core foundations (Malone, 1982) particularly in multi-rooted posterior teeth.

There is a relatively small number of clinical or laboratory studies in this area of restorative dentistry. The difficulty experienced in minimizing the number of variables in experiments with multi-rooted

endodontically-treated posterior teeth may have been partly responsible for this relative lack of research. These variables may include factors such as:

- a. the amount of sound tooth structure left in the pulpless posterior tooth,
- b. the age and the moisture content of the tooth,
- c. the number, the size and the direction of the roots, and
- d. the variable use of root canal posts, retentive pins and cast coronal restorations as suggested by different clinicians.

To overcome some of the problems in evaluating the efficiency of several types of core foundations commonly used in the restoration of endodontically-treated posterior teeth, two laboratory studies (Newburg and Pameijer, 1976; Chan and Bryant, 1982), designed to approximate the clinical loading of posterior teeth, have made use of single-rooted premolar teeth.

In the study by Newburg and Pameijer (1976), the "more reliable" cast post-core foundation was compared with composite resin cores retained by a variety of post-pin combinations. All the tooth specimens were severed at the cemento-enamel junction, perpendicular to the long axis of the tooth, leaving a flat root surface. Five types of core foundations were prepared.

Group 1. A cast metal post-core was prepared from a technique casting alloy* with strength and hardness similar to those of type III gold alloys. The tapered post preparation was carried out with a No. 702 carbide bur to a depth of 10 mm.

Group 2. A serrated and vented, parallel-sided stainless steel post[®] of 1.5 mm diameter was cemented into the root canal to a depth of

*Technic Casting Alloy, J. M. Ney Co., Bloomfield, Conn., U.S.A.

[®]Para-Post System, Whaledent International, New York, N.Y., U.S.A.

10 mm. It was not stated whether any anti-rotational preparation around the cemented post was carried out before the placement of the composite resin* core foundation.

Group 3. A 1.5 mm serrated, stainless steel post and two self-threading pins[®] were placed into the dentine to a depth of 10 mm and 2 mm respectively. A composite resin core was added as above.

Group 4. The root canal orifice was blocked with zinc phosphate cement, making a continuous root surface. Four self-threading pins, of the type described above were then used to retain a composite resin core.

Group 5. The root canals were enlarged to "about half the diameter of the remaining dentinal walls" with an inverted cone bur to provide undercuts. Then a "self-supporting" all-composite resin post-core foundation was made.

Details of the preparation of the core foundations for the final coronal restorations were not supplied. Although a complete crown was recommended as the final coronal restoration, none was placed on the specimens before subjecting them to the different test loads. Stated loading speeds were 0.01 inch/minute (0.25 mm/min) for the tensile and shear loads, and 1.0 inch/minute (25.4 mm/min) for the torsional forces. The angle of force application was not available. Five specimens of each type of core foundation were subjected to a tensile force. Three specimens were tested in each of the five groups of core foundations for their resistance to shear forces and torque.

A significantly greater force was required for the separation of the core foundation from the teeth (application of tensile force) in Groups 3 and 4 — composite resin cores retained either by a stainless

*Adaptic, Johnson & Johnson Dental Products Co., East Windsor, N.J., U.S.A.

[®]TMS Minim (0.023 inch), Whaledent International, New York, N.Y., U.S.A.

steel post and two pins or by four self-threading pins. There were no significant differences between the other groups.

The resistance to shear forces of the all-composite resin post-cores (Group 5) was significantly lower than the other groups. Data obtained from the specimens subjected to torque indicated that the all-composite resin post-cores and the composite resin cores retained by a single cemented post had the lowest resistance to torsional forces. Root fractures associated with the use of self-threading pins were reported by the authors although few details were provided.

Newburg and Pameijer (1976) concluded that the resistance to displacement of composite resin cores, retained by either four self-threading pins or a cemented post and two pins, compared favourably with other accepted techniques. A composite resin core retained solely by a cylindrical post provided poor resistance to torque.

Another laboratory study was conducted by Chan and Bryant (1982) to compare the resistance to fracture and the failure characteristics of restored, endodontically-treated posterior teeth with substantial loss of tooth structure. Fifty five single-rooted, mandibular premolar teeth were restored using individually fabricated cast metal crowns supported by one of the following types of post-core foundations:

1. Cast gold post-cores fabricated in a type III casting gold alloy. A serrated and vented, parallel-sided, plastic casting post* and Duralay[®] resin were used for the direct fabrication of the post-core pattern. The diameter of the post was 1.5 mm and the cast gold post-cores were cemented with zinc phosphate cement.
2. Amalgam post-cores were prepared using a serrated and vented, parallel-sided, stainless steel post* (1.5 mm diameter) cemented

*Para-Post System, Whaledent International, New York, N.Y., U.S.A.

[®]Reliance Dental Mfg. Co., Worth, Ill., U.S.A.

with zinc phosphate cement. Sharp angles on the head of each post were lightly rounded, to reduce stress concentration, before the placement of the Dispersalloy* amalgam core.

3. Composite resin post-cores were prepared in a similar manner (to amalgam post-cores) using the stainless steel posts[®] and black Adaptic* core resin as the core material.

A diagrammatic representation of the test method is shown in Fig. 14.2,a. An adequate anti-rotational lock was prepared in each specimen and, following the cementation of the stainless steel post, this area was cleared of the excess cement. The amalgam or the composite resin was carefully condensed into this anti-rotational preparation during the initial stages of the core "build-up".

A cast full veneer crown, with optimal fit and retention, was subsequently constructed individually for each specimen using a coin-silver alloy with characteristics similar to the cast gold alloy. The occlusal surfaces of the crowns were provided with flat buccal and lingual cuspal inclines, at approximately 115° to the long axis of the tooth. Since neither the retention of the crowns nor the strength of the luting agent was under direct examination, the crowns were not cemented; this facilitated removal after testing.

Each specimen was mounted in a test bracket by means of acrylic resin and the socket was relined with a silicone impression material approximately 0.25 mm thick, as described by Lovdahl and Nicholls (1977). Using a Hounsfield Tensometer[#] and a cross-head speed of 0.16 mm/min, force was applied, by a metal plunger, to the lingual cuspal incline of the buccal cusp of each crown until failure occurred (Fig. 14.2,b).

*Johnson & Johnson Dental Products Co., East Windsor, N.J., U.S.A.

[®]Para-Post System, Whaledent International, New York, N.Y., U.S.A.

[#]Tensometer Ltd., Croydon, England

The mean load at failure for each of the three types of specimens and the failure characteristics are shown in Table 14.1.

Fifteen cast gold specimens, twenty amalgam specimens and twenty composite resin specimens were tested. The mean loads at failure were 75.4, 92.2 and 91.6 kilograms force (kgf), respectively.

After failure, all fifteen cast-gold specimens showed evidence of dislodgement of the post-core, indicating failure at the site of cementation; thirteen specimens showed visible evidence of root failure which extended beyond the coronal one third of the root in four of these cases. Examples of the cast gold specimens, after failure and removal of their metal crowns, are shown in Fig. 14.3.

Of twenty amalgam specimens, sixteen showed evidence of fracture of the amalgam core, the cemented metal post and the amalgam core had been dislodged from their original location in eight cases; of the eight specimens showing evidence of root fracture, the fracture extended beyond the coronal one third of the root in four cases. The variation in failure characteristics of the amalgam specimens, after removal of their metal crowns, is illustrated in Fig. 14.4.

Failure of the composite resin specimens occurred in several ways (Fig. 14.5). Root fracture occurred less frequently and was less extensive than in the other specimens. Core fracture was a common finding and nine of the twenty specimens showed evidence of post-core dislodgement.

Of the three types of post-core foundations, the amalgam and the composite resin post-cores were able to resist higher occlusal loads before failure occurred. After statistical analysis it was found that differences, between the failure loads of either cast gold and amalgam specimens or between cast gold and composite resin specimens, were not significant at a 99 per cent confidence level but did achieve a lower (98 per cent) level of confidence. Ratios, of the load at failure to a measure of the root face dimensions, were derived in an effort to allow

for variations in tooth size. Differences between the ratios for cast gold and amalgam and between the ratios for cast gold and composite resin were significant at a relatively low 95 per cent level of confidence.

Direct comparison of these findings with those of Newburg and Pameijer (1976) is difficult because of the variation in the loading speed and possibly the direction of force application, the length of the post, the inconsistent use of pins and anti-rotational locks in the post-core preparation, and the use of a full veneer crown over the post-core foundation.

The benefits of condensing the core material around the cemented post was demonstrated by Christian et al (1981). This procedure was found to enhance the strength of the post-retained amalgam core foundation in their laboratory study. As a result, they suggested that the use of self-threading pins for resistance against torque may often be eliminated.

Chan and Bryant (1982) found that cylindrical posts (of the Para-Post System) of a 1.75 mm diameter were often too large for mandibular premolars at the 7 mm post length; 1.5 mm diameter posts were therefore used at a length of 7 mm. The use of a 1.5 mm diameter cylindrical post to a depth of 10 mm, as in Newburg and Pameijer's (1976) study, increased the risk of root perforation.

A full veneer crown has been recommended (Newburg and Pameijer, 1976) as the final restorative treatment to ensure a more even distribution of occlusal stresses to the entire post-core foundation and to protect any remaining coronal tooth structure from fracture.

14.3.3 *Microleakage*

The mechanical properties of the post and core materials are important factors influencing their clinical performance. However, of probably equal importance to the success of the final restoration, is

the ability of these materials to adapt closely to the tooth structure, thereby keeping microleakage and the potential for recurrent caries to a minimum.

Leakage around crown margins may have a significant effect on the success or failure of a cast restoration; this could result in the loss of retention and recurrent caries in the endodontically-treated tooth. Marginal leakage under crowns is closely related both to the adaptation of the casting to the cavo-surface margin and to the integrity of the cementing medium (Hormati and Denehy, 1980). This integrity may be affected by the solubility and dimensional change of the cementing agent as well as its adaptation to the tooth surfaces involved (Norman et al, 1963). Hormati and Denehy (1980) suggested that, should leakage occur around the crown margins, the core should, ideally, serve to arrest this leakage. There are other clinical situations where the margins of the core foundation may be exposed to the oral fluids. These include imperfectly adapted temporary crowns, a core foundation which must serve as an interim restoration, and core foundations with subgingival margins that are apical to the margins of the final crown restoration.

Hormati and Denehy (1980) conducted a laboratory study to compare the microleakage of pin-retained amalgam and composite resin bases. Cavity varnish was not used under the amalgam bases, and the teeth to be restored with composite resin were not etched. Using a crystal violet dye, these authors found that the depth of dye penetration at the amalgam base interface was significantly less than that for the composite resin bases.

The effectiveness of the acid-etching of enamel in controlling the marginal leakage around composite resin restorations has been demonstrated in many studies (6.13.3). However, the acid-etch technique is usually either not applicable or less successful in the cervical region due to the lack of sufficient, regular oriented enamel. Even if originally

present, any acid-etched enamel margins would be partially or totally removed during crown preparation (Hormati and Denehy, 1980). The acid-etch technique has been found to be less effective on dentine and cementum than on enamel in controlling marginal leakage (Andrews and Hembree, 1978).

Margins of an amalgam base exposed to oral fluids were found to be less susceptible than composite resin base margins to microleakage (Hormati and Denehy, 1980). As the amalgam restoration ages, there is a gradual reduction of marginal leakage due to the accumulation of corrosion products in the amalgam-tooth interface (Phillips, 1973, p.302). The use of a cavity varnish has also been shown to be effective in the early reduction of marginal leakage around amalgam restorations (Andrews and Hembree, 1978).

Schmidt and Lutz (1977) conducted an *in vitro* study on the marginal adaptation of cast gold, amalgam and composite resin cores. With the aid of dye penetration tests and scanning electron microscopy, they found that composite resins, when properly used, were "superior" to gold and comparable to amalgam in core fabrication for endodontically-treated teeth from the standpoint of marginal adaptation and the reduction of microleakage at the composite resin-dentine interface.

A recent study (Larson and Jensen, 1980) on the microleakage beneath crowns, prepared on pin-retained amalgam or composite resin cores, has suggested an alternative mechanism for the failure of a restoration placed on well-prepared core foundations. Test specimens were prepared from ninety maxillary premolar teeth. Whaledent* self-threading pins were used to retain the thirty composite resin and the thirty amalgam cores. Neither the acid-etch technique nor cavity varnish was used for the composite resin and the amalgam specimens. The sixty pin-retained

*TMS Pins, Whaledent International, New York, N.Y., U.S.A.

core foundations and the remaining thirty teeth were subsequently prepared for a complete cast crown restoration, the margins of which were established in enamel, gingival to the margin of the core foundation. Complete cast crowns were individually fabricated for each specimen using a Type II gold alloy and cemented with a fine grain, zinc phosphate cement.

The specimens were randomly divided into three groups of thirty teeth — ten composite resin cores, ten amalgam cores, and ten regular crown preparations. The first group of thirty teeth was cycled 100 times between a 60°C bath of 2% fluorescein dye and a 4°C bath of 2% fluorescein dye. The teeth were placed in each bath for 30 seconds; the total immersion time was 100 minutes. A similar group of thirty teeth that has been aged (stored in water) for two years after cementation was also cycled in this manner. The third group of thirty teeth was immersed in a 37°C fluorescein dye bath 24 hours after cementation of the gold crowns.

Larson and Jensen's findings (1980) indicated that some significant differences do exist between the regular crown preparations and the amalgam and composite resin core preparations with regard to microleakage. With thermal cycling, the regular crown preparation were able to resist leakage at the crown-tooth interface better than either the composite resin core or the amalgam core preparations. It was considered that the differences in the coefficients of linear expansion between the components of the restored tooth — tooth structure ($11.4 \text{ mm/mm/}^{\circ}\text{CX}10^{-6}$), amalgam ($25 \text{ mm/mm/}^{\circ}\text{CX}10^{-6}$), composite resin ($30 \text{ mm/mm/}^{\circ}\text{CX}10^{-6}$), and Type II casting gold ($14 \text{ mm/mm/}^{\circ}\text{CX}10^{-6}$) — may be responsible for the varying degree of microleakage found in the test specimens. When cycled between 4°C and 60°C, the core material (either amalgam or composite resin) may expand and contract more than either the gold crown or the tooth. It was suggested that since the core is enveloped by the gold crown, the

expansion that occurs in the core may tend to force the crown off the tooth. This excessive expansion and contraction of the core material during thermal cycling may result in the premature loss of the cement seal at the margin between the gold crown and the tooth resulting in microleakage. Clinically, amalgam has been found to corrode at the amalgam-tooth interface; this corrosion has the effect of sealing the amalgam-tooth interface against microleakage.

When used properly, both amalgam and composite resin may be considered as satisfactory core materials. Since the sealing ability of composite resin is somewhat inferior to that of amalgam, it is suggested that the margins of the crown should routinely be extended gingivally, beyond the composite resin-tooth interface. When possible, this should also be done when amalgam is used; however, this is not imperative due to the "self-sealing" mechanism of amalgam. The long-term clinical significance of the galvanic corrosion that takes place in the amalgam due to its contact with the cast gold crown is not fully understood.

14.3.4 *Retention of cast gold crowns cemented to amalgam and composite resin cores*

The build-up of extensively destroyed teeth to a "classical preparation" before the construction of the coronal restoration has been recommended (Kafalias, 1969). In the restoration of a pulpless tooth, the use of post-retained, or pin-retained, amalgam or composite resin cores has become common practice. Since, to a large extent, the cast coronal restoration is supported by the core material, the choice of core material may affect the retention of cast crowns cemented to the final tooth-core preparation (Hormati and Denehy, 1981).

In a recent laboratory study (Hormati and Denehy, 1981), the resistance to displacement by a tensile force of cast gold complete crowns cemented to either amalgam or composite resin cores was compared.

Test specimens included thirty six identical models simulating teeth prepared with a 7 degree taper for cast complete crowns. Eighteen models were made with amalgam* and eighteen with composite resin[@]. Cast complete crowns were fabricated for each model using the indirect technique and were subsequently cemented with zinc phosphate. The specimens were randomly divided into three groups — each consisting of six amalgam and six composite resin samples — and were tested at 1-week, 1-month, and 3-month intervals. Prior to testing, each sample was thermally cycled 200 times between $50^{\circ}\pm 5^{\circ}\text{C}$ and $0^{\circ}\pm 5^{\circ}\text{C}$ for 30 seconds in a water bath at each temperature. A tensile force, parallel to the long axis of the "tooth", was applied to each specimen with an Instron testing machine at a cross-head speed of 1 mm/min.

Although zinc phosphate cement has been found to approach its ultimate strength in one day (Phillips, 1973, p.478), Hormati and Denehy (1981) found that the retention of the cemented crowns to the composite resin cores increased significantly between the 1-week, the 1-month and the 3-month periods. The mean load required to displace the cast gold complete crowns cemented to the composite resin cores were 32.9 kg, 54.2 kg and 66.4 kg at 1-week, 1-month and 3-months, respectively. Some unknown reaction between the composite resin and the zinc phosphate cement was considered to be responsible for this trend. The cement in the specimens tested at one week and at one month retained its original colour; only the cement in the three months' old specimens took up the colour of the composite resin core — which was purple in this case.

The mean loads required to displace the cast gold crowns from the amalgam cores were similar for the 1-week and 3-month periods — 58.9 kg and 57.1 kg, respectively. However, the significantly higher retention

*Tytin, S.S. White Dental Products International, Philadelphia, PA., U.S.A.
[@]Prosthodont, Lee Pharmaceuticals, South El Monte, CA., U.S.A.

(78.5 kg) provided by the one month old specimens could not be explained.

With this limited evidence available, it is difficult to predict in the long term, whether there is any clinically significant difference in the amount of retention provided by these two core materials.

14.4 Discussion

To a certain extent, the selection of a material for the core foundation is a matter of personal preference on the part of the clinician. For many years, casting gold alloys have been used almost routinely for this purpose. However, since the introduction of amalgam and composite resin for core construction, the selection of a suitable core material for a particular clinical case requires more careful consideration.

Although alternative techniques are commonly used today, cast gold post-core foundations have remained the "standard" against which newer techniques have been compared. The main advantages of the casting gold alloys as a core material include their high strength properties and excellent corrosion and tarnish resistance. Other types of core materials, such as amalgam or composite resin, require a certain bulk in order to resist fracture or distortion. For this reason, it may be advisable to use cast gold alloys for the core foundation in pulpless teeth with small clinical crowns (for example, maxillary lateral incisors and mandibular incisors).

Within reason, a mal-aligned pulpless tooth may be "up-righted" (McKerracher, 1981,b) by placing a crown at a different path of insertion from the post-core foundation; this is best achieved by using a cast gold post-core (Pickard, 1964; Baum et al, 1981, p.544) in which the core section is angled to provide the most favourable support for the overlying crown (Fig. 14.6).

Particular requirements for cast gold cores — for example, the extra appointment required, the cost of the noble alloys and the laboratory fees — may, in some cases, influence the practitioner to

consider alternative core foundations. According to Markley (1966), a cast post-core foundation has two major disadvantages. First, it has a greater tendency to cause root fracture and, secondly, because of its dependence on the luting agent for retention, there is a greater risk of recurrent caries should the casting become loose. Therefore, if a cast post-core foundation with adequate retention and resistance form cannot be constructed, alternative techniques should be considered.

Amalgam has several desirable qualities as a core material. It is relatively simple to use and provides ample working time for proper condensation of the material even around multiple posts and pins. Although amalgam is not as strong as the cast gold alloys, when applied properly, it has sufficient strength to withstand the stresses to which the pulpless tooth is likely to be subjected. Being a plastic material, it can enhance the retention of the core foundation by engaging minute undercuts in the walls of the post-core preparation. The "self-sealing" property of amalgam, due to the accumulation of corrosion products in the amalgam-tooth interface, minimizes microleakage and provides protection for the underlying tooth preparation against recurrent caries. If, for financial reasons, the placement of a cast coronal restoration must be delayed, a properly designed, post-retained, amalgam "core/restoration" can also serve as a satisfactory long-term temporary restoration.

The long term clinical significance of the galvanic reaction that might take place when an amalgam core foundation comes in contact with a cast gold restoration is still uncertain. Although clinical symptoms in a vital tooth, attributable to this reaction, have been infrequently reported in the dental literature (Carter, 1965), problems of this nature appears to be rare in endodontically-treated teeth.

As mentioned previously in 6.12, there has been some controversy as to whether the preparation for the final restoration should be carried

out soon after the initial set of the amalgam core foundation. If a fast-setting amalgam alloy is used, some clinicians (Shillingburg et al, 1970; Johnson et al, 1976; Reuter, 1977; Hormati and Denehy, 1980; Nayyar et al, 1980) have suggested that the amalgam core may be prepared for the final restoration, without any "harmful effects", immediately after the initial set of the amalgam has occurred. Other clinicians (Baraban, 1972; Henry and Bower, 1977, a; Wing, 1981) have recommended that the amalgam core be allowed to set for a longer period of time before completion of the coronal preparation. Although different strength tests have been used, there is evidence to indicate that amalgams have relatively low early strengths (at 30 minutes) compared to their final strengths while composite resins have relatively high early strength properties compared to their final strengths. However, because several of the single melt high copper amalgam alloys (for example, Tytin) have 30 minute strength properties which may be comparable to those of composite resin at this time, it is possible that further clinical evidence will demonstrate clearly that these amalgams may be prepared for crowns at this time. Furthermore, a controlled laboratory study might be able to determine the minimum time after placement before the amalgam core foundation can be prepared, with rotary instruments, without harmful effects.

Unlike the controversy associated with the setting rate of amalgam, there is little disagreement over the preparation of a composite resin core foundation immediately after the polymerization of the material. A study by Forsten and Strömberg (1976) found that ten minutes after the beginning of the mixing procedure, the transverse strength of the four brands of composite resin tested — Adaptic*, Concise[®], Cosmic[#] and

*Johnson & Johnson Dental Products Co., East Windsor, N.J., U.S.A.

[®]3M Dental Products Co., St. Paul, MN., U.S.A.

[#]Amalgamated Dental, England.

Nuva-Fil* — were one half to two thirds that of their final strength (after 24 hours). Although acknowledging the difficulties inherent in testing amalgam at 15 minutes, Bryant (1978) found that the compressive strength of a composite resin at 15 minutes, of 280 MPa, compared favourably with the compressive strengths at this time of several types of amalgam — 65 MPa (dispersion modified amalgam), 70 MPa (conventional lathe-cut amalgam), 115 MPa (conventional spherical) and 210 MPa (single melt high copper amalgam). This rapid setting reaction, more than any other properties of composite resin, is probably responsible for the popularity of this material for core construction. While the ultimate physical properties of the composite resin, in terms of compressive and tensile strengths and hardness, are not equal to those of amalgam, they are, in general, more than sufficient to withstand functional stresses to which the post-core foundation is likely to be subjected (Baraban, 1972). A relatively new composite resin[®], specially designed for core construction, has been claimed (Anderson, 1981) to have tensile and compressive strength properties comparable to "quality amalgams". Because aesthetics is not an important consideration for core construction, the manufacturer has been able to produce a light blue composite resin which is more densely filled than conventional composite resins; this increased quantity of filler is responsible for the improved strength properties of the material.

Being a non-metallic material, the potential for galvanic corrosion is eliminated (Spanauf, 1972). Some clinicians (Johnson et al, 1976) have observed that, during trial insertion of the final cast restoration, interferences are readily recognized by definite markings on the surface of the composite resin core foundations.

*The L.D. Caulk Co., Milford, DE., U.S.A.

[®]Coreform Composite Resin, Sybron/Kerr, Romulus, Michigan, U.S.A.

Compared to amalgam, composite resin is less efficient in eliminating microleakage at the tooth-restoration interface. With this in mind, it has been suggested that the use of composite resin cores be restricted to cases where there is sufficient tooth structure remaining, to permit the placement of the crown margins gingival to the tooth-composite resin junction (Lorey, 1980). In the experience of the author, void elimination is not a major problem in core construction when a properly adapted matrix is used and the material is kept under pressure during polymerization. In 1980, a new pre-shaped, polyester core matrix system* was introduced. With a selection of twenty shapes, this matrix system was designed to simplify the construction of composite resin cores.

No study has reported sufficient clinical evidence of the failure rate of adequately prepared post-core foundations to enable a clinically based assessment of the long-term merits of available techniques. In addition, it is necessary to be cautious in evaluating the importance of laboratory research. Ross (1980) warned that forces exerted on the tooth specimens in laboratory studies were often in excess of those present in the mouth during masticatory function and parafunction; as a result, the tests may have favoured certain techniques or materials. Long-term clinical evaluation of the different types of post-core foundations is required. However, until this information is available, the clinician must make an individual decision for each case on the basis of the current evidence from research, the requirements of the particular case and the experience of other clinicians.

*Coreform, Sybron/Kerr, Romulus, Michigan, U.S.A.

14.5 Secondary intention post-core foundations

14.5.1 *Introduction*

Although, under normal circumstances, the coronal restoration for an endodontically-treated tooth is usually constructed after the placement of a post-core foundation, it is not uncommon for endodontics to become necessary sometime after the insertion of a crown or a fixed bridge. This may be associated with a number of eventualities, ranging from pulpal necrosis and periapical pathosis of a bridge abutment to the fracture of a single crown preparation (Henry and Bower, 1977, b). While most cases of single crown fracture require total remake following root canal therapy, many of the otherwise satisfactory pre-existing crowns or bridges may be restored to normal function following endodontic treatment.

Several factors may influence tooth strength when previously restored teeth undergo endodontic treatment (Federick and Serene, 1975):

- i. Alteration of endodontic access. Because the restoration often masks the true underlying anatomic form of the tooth, the access cavity through the restoration usually has to be enlarged to give the clinician more direct vision into the pulp chamber. This procedure often results in the loss of a considerable quantity of the tooth structure that forms the underlying support for the restoration.
- ii. Decalcification of dentine. Calcified or obliterated canals are often found in previously restored teeth. Chelating agents (such as 10 to 15 percent EDTA) used as an aid to endodontic instrumentation may decrease the strength of the residual preparation.
- iii. Canal flaring. Techniques employing gutta percha as the primary filling material usually require the flaring of the coronal one-third of the root canal — a procedure which may further weaken the tooth.

14.5.2 *Fracture of the tooth preparation*

Fracture of the tooth preparation underneath a restoration resulting in pulp exposure may occur where the initial preparation was inadequate, where the dentine has become brittle, in cases of severe occlusal overload such as bruxism (Henry and Bower, 1977, b) as a result of traumatic injuries. Although a new restoration is usually required after root canal therapy, occasionally the crown (or bridge) may be re-used provided it is satisfactory in all aspects and that "the fracture line does not violate marginal integrity" (Henry and Bower, 1977, b).

Techniques of construction of a post-core foundation to fit a completed but uncemented restoration are basically the same as those used for fractured crown preparations which resulted in pulp exposures. The use of a post-retained composite resin core (Federick, 1974) or a cast gold post-core (Richardson and Padgett, 1974; Henry and Bower, 1977,b;Shirdel et al, 1977) in these cases, has been described by several clinicians. In this technique the existing coronal restoration is used as a matrix during the formation of the post-core pattern and the placement of the composite resin core material. Final adaptation of the restoration to the post-core foundation may be verified by using water-soluble indicating dyes*, or a silicone indicator paste[®].

14.5.3 *Pulp death underneath a crown or bridge*

Once the success of the endodontic treatment has been determined, a pre-fabricated metal post may be cemented into the root canal of the pulpless tooth in order to distribute functional and para-functional occlusal stresses into the root. Because it is often difficult to

*Liqua-Mark, The Wilkinson Co., U.S.A.

[®]Fit-Checker, G-C Dental Industrial Corp., Tokyo, Japan.

ascertain the extent of the loss of tooth structure underneath the restoration, Henry and Bower(1977,b)suggested that the post should be as long as possible, limited only by "the dictates of apical endodontic seal".

Following the insertion of the post into the root canal, both the pulp chamber and the access cavity may be sealed with amalgam (Henry and Bower,1977,b) or composite resin (Federick and Serene, 1975). Alternatively, a cast gold post-core may be used in single-rooted pulpless teeth. Henry and Bower(1977,b)suggested that when amalgam or composite resin is used as the core material in the pulp chamber, the access cavity may be restored with a gold inlay or with gold foil for "improved aesthetics and reduced corrosion" (as illustrated in Fig. 14.7).

Mean failure loads and failure characteristics of specimens

TABLE 14.1

Core Material	Number of specimens	Root face dimensions (B-L)+(M-D) (mm)	Load at failure (kgf)	Ratio of load: (B-L)+(M-D)	Failure characteristics (Number of specimens)		
					Core fracture	Post-core dislodged	Root fracture
Cast gold	15	12.2 (0.8)*	75.4 (16.2)	6.2	0	15	13
Amalgam	20	12.7 (0.8)	92.2 (21.8)	7.3	16	8	8
Composite resin	20	12.5 (0.6)	91.6 (19.6)	7.3	17	9	4

*Standard deviation in parentheses

Fig. 14.1 a. to c. stainless steel post-amalgam core foundation for a fractured pulpless incisor tooth.

d. cast gold post-core foundation.

e. and f. composite resin core foundation for a root-filled molar tooth.

g. to i. fractured lateral incisor tooth restored with a stainless steel post and pin-retained composite resin core foundation and a temporary acrylic resin crown.


Fig.14.1



a



b



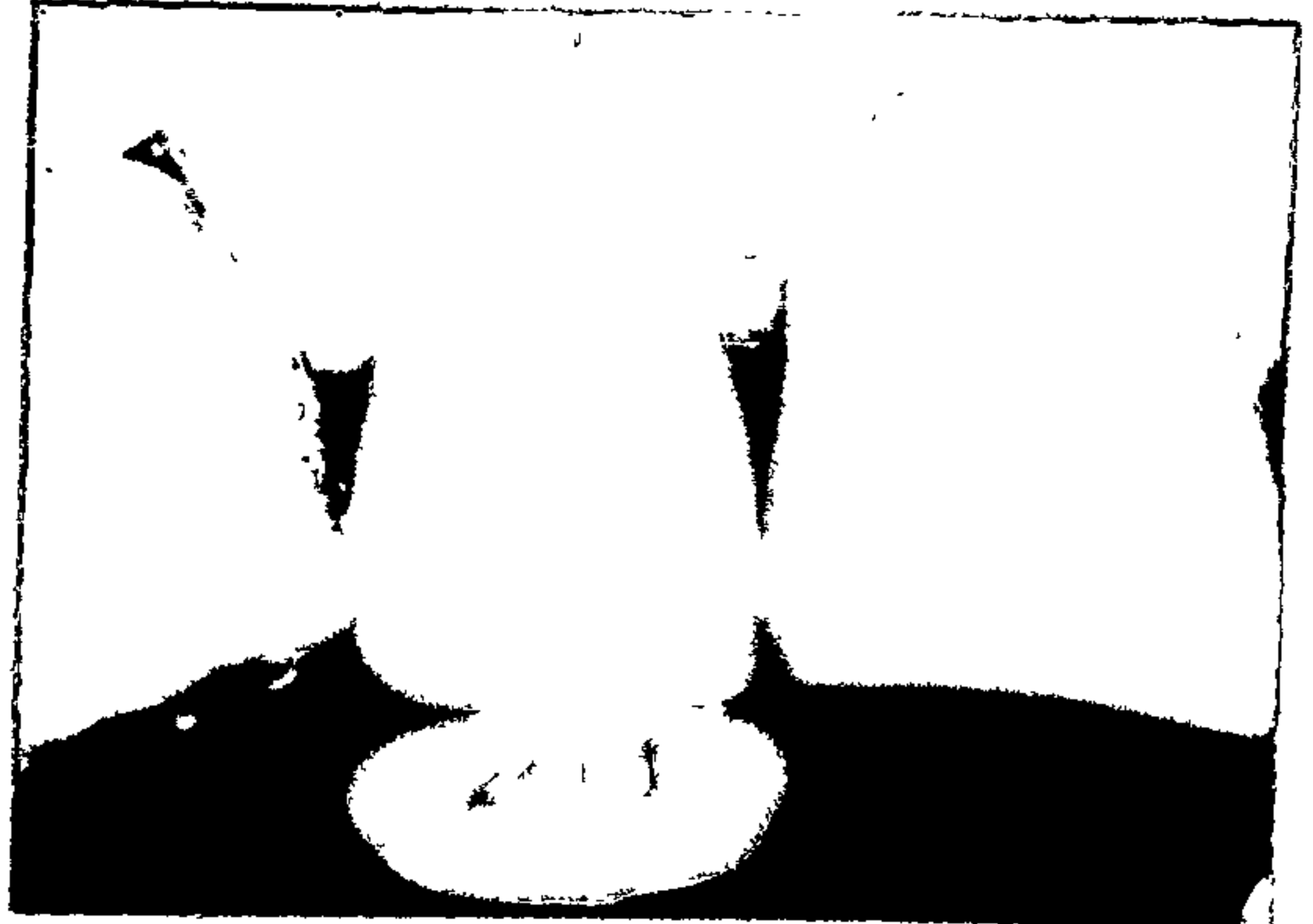
c




d



e



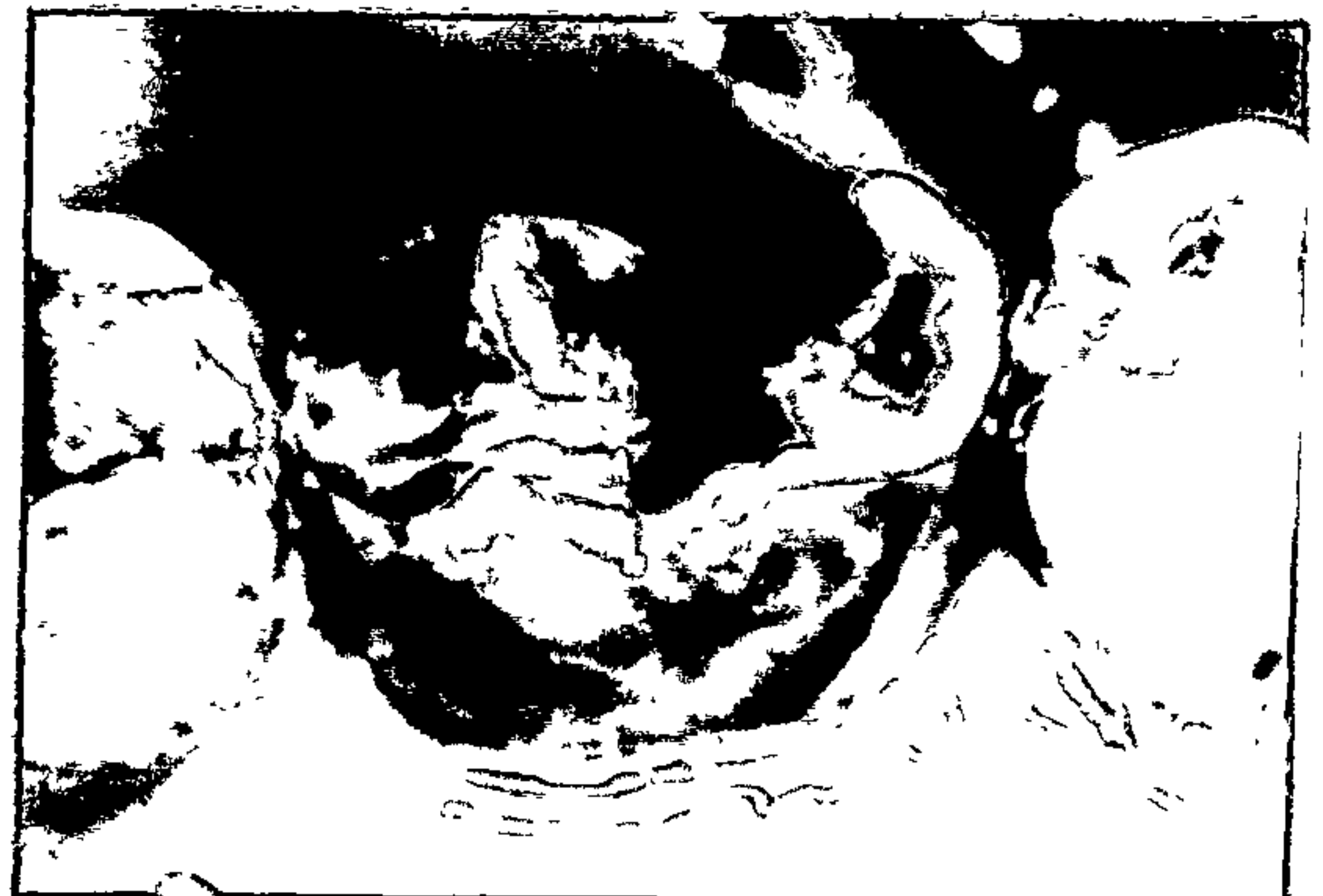f



g



h




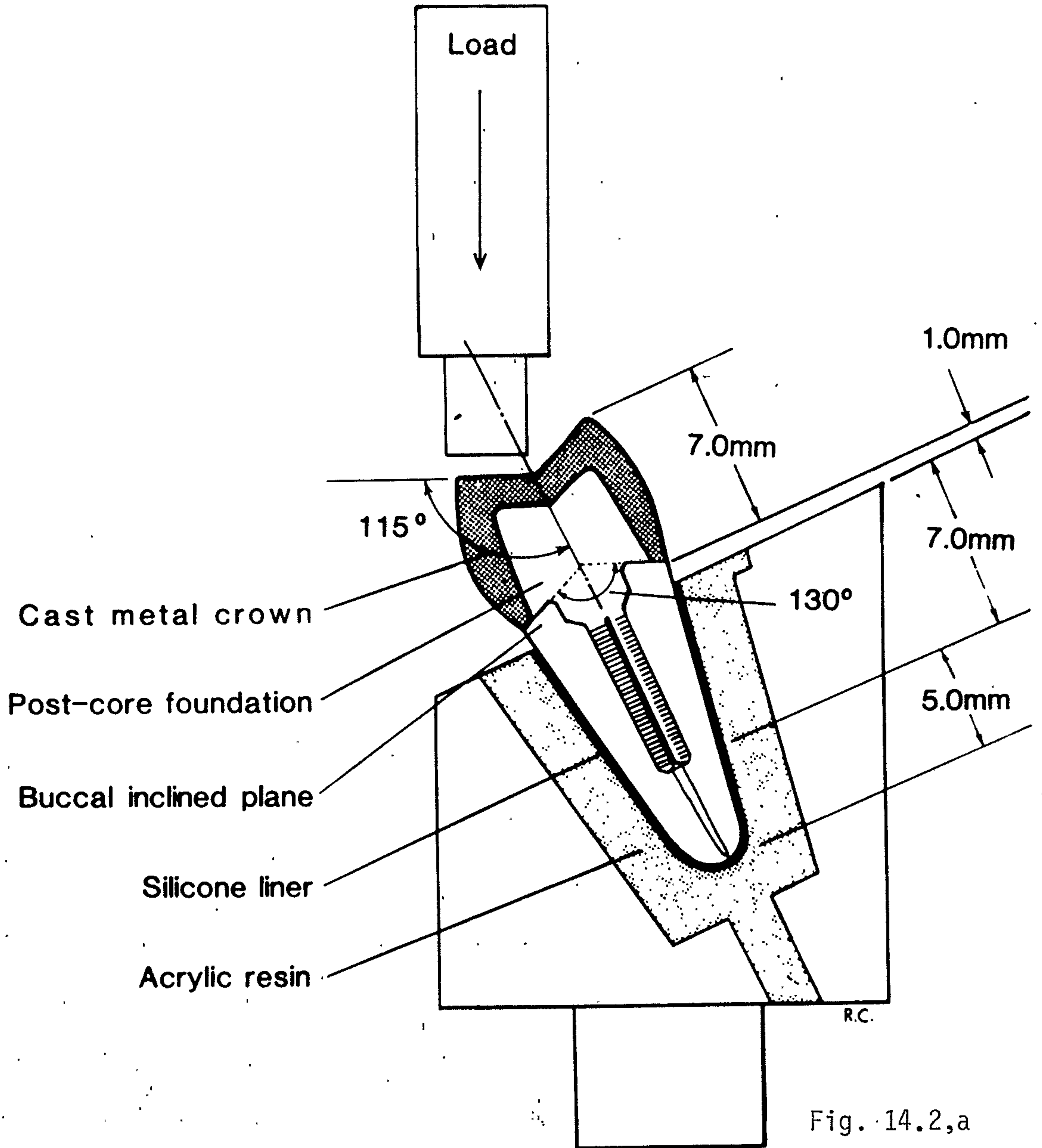
i

Fig. 14.2 a. Diagrammatic representation of test method.
b. Specimen mounted for testing A, metal plunger. B, Brass
bracket for attachment to testing machine.

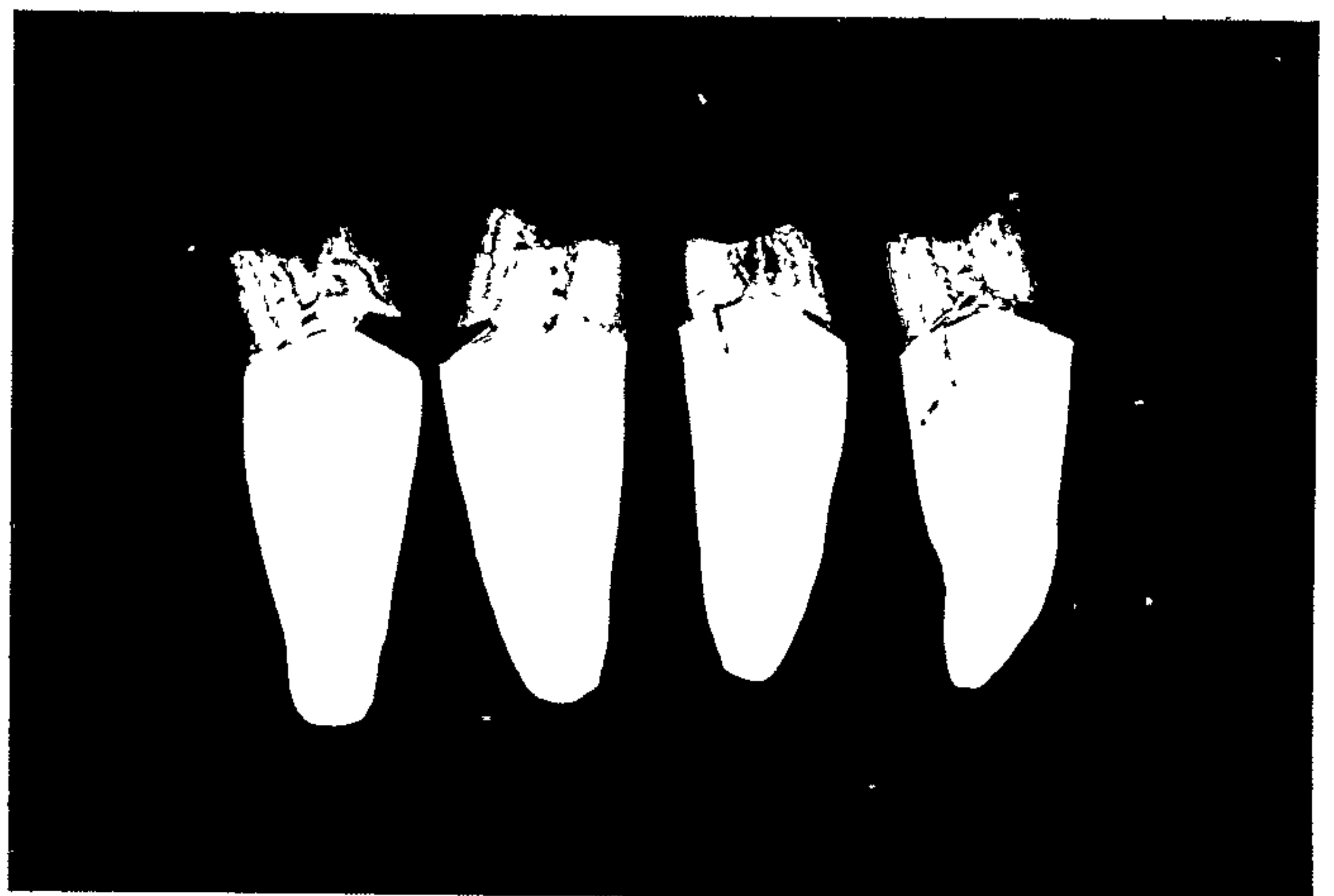
Fig. 14.3 Examples of failed cast gold specimens after removal of
metal crowns.

(from Chan and Bryant, 1982)

Fig. 14.2; 14.3



14.2,b



14.3

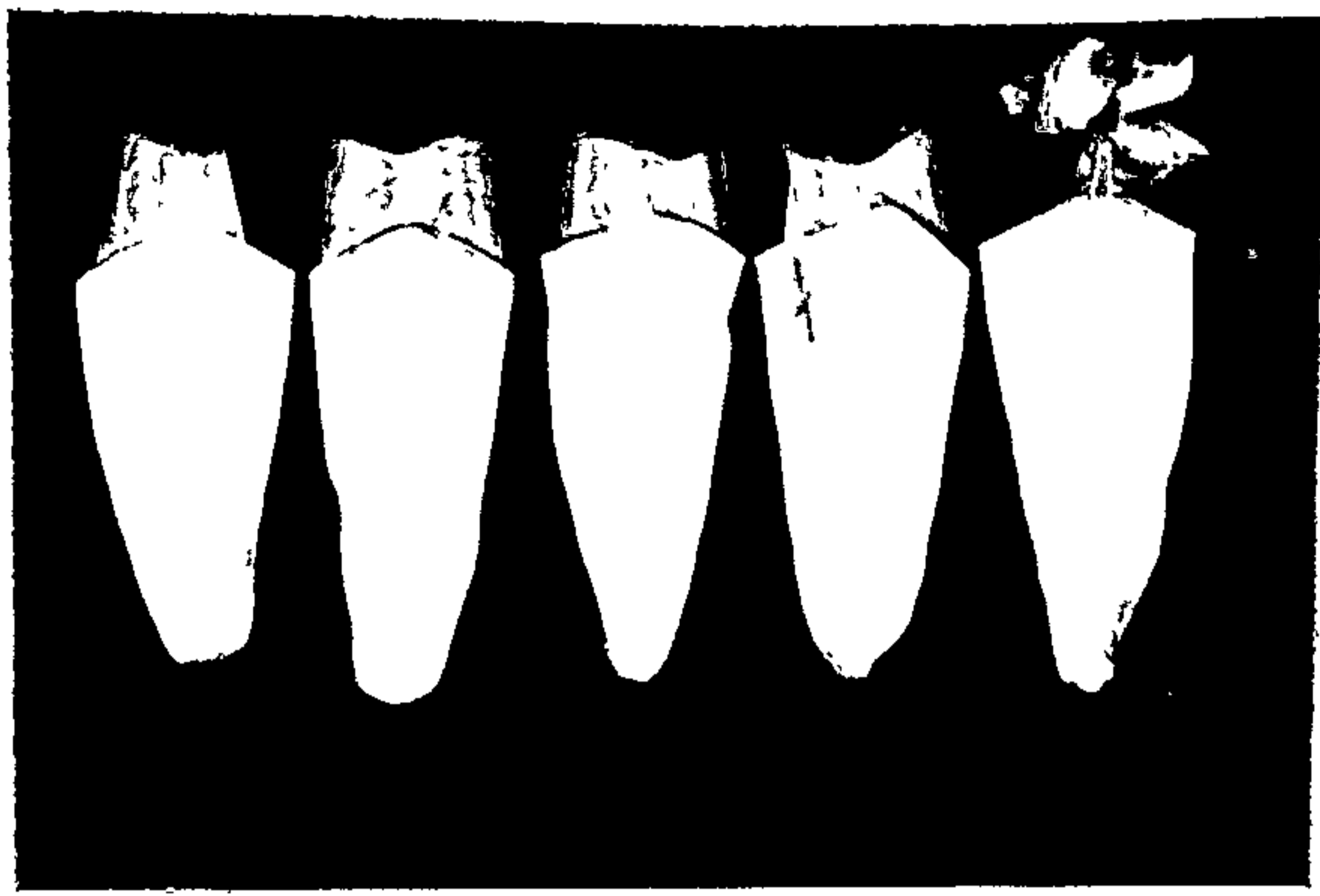
Fig. 14.4 Examples of failed amalgam specimens after removal of metal crowns.

Fig. 14.5 Examples of failed composite resin specimens after removal of metal crowns.

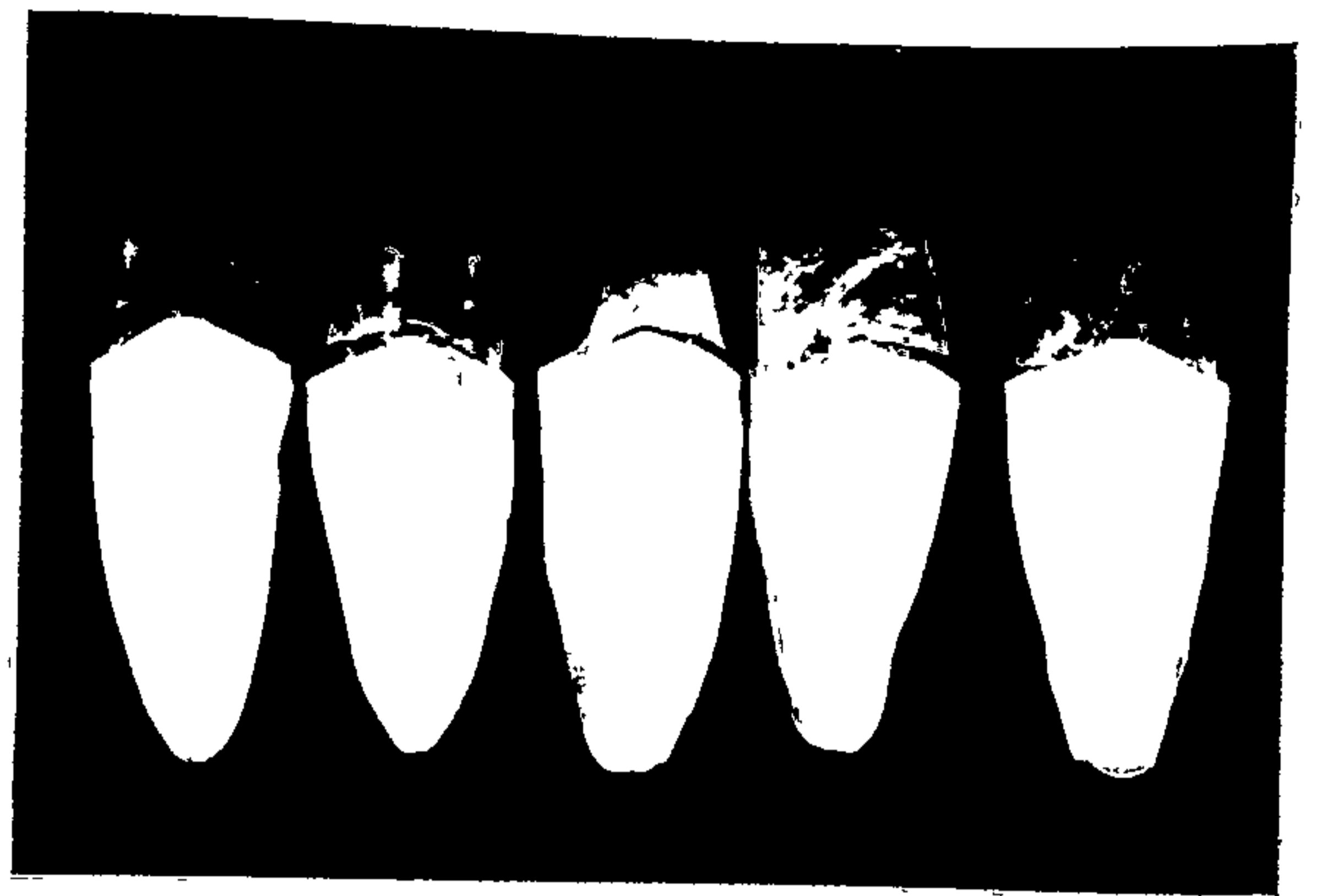(from Chan and Bryant, 1982)

Fig. 14.6 These protruded maxillary pulpless teeth were restored with cast gold post-cores and ceramo-metal crowns in order to improve their aesthetic appearance.


Fig. 14.4; 14.5; 14.6



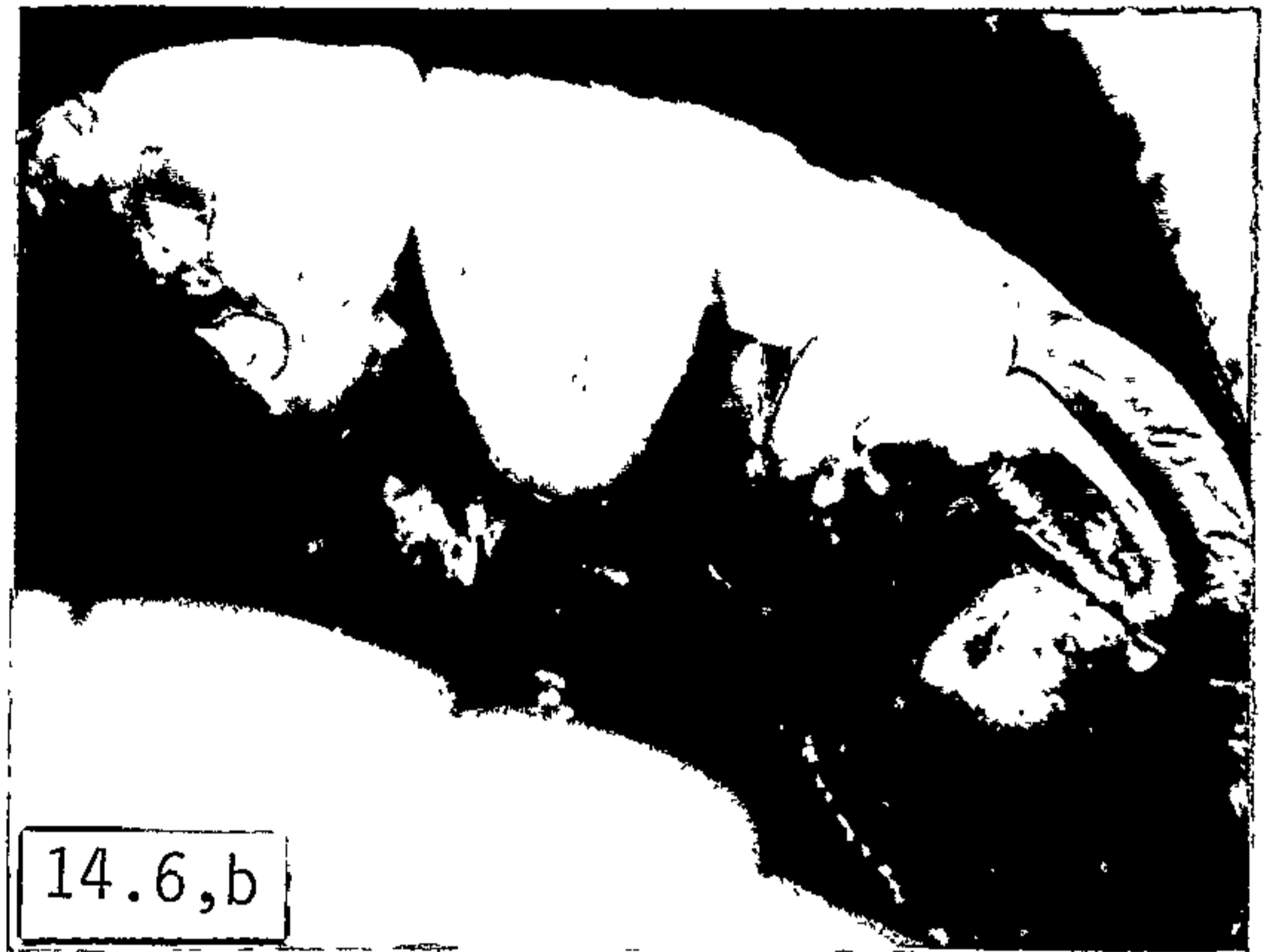14.4



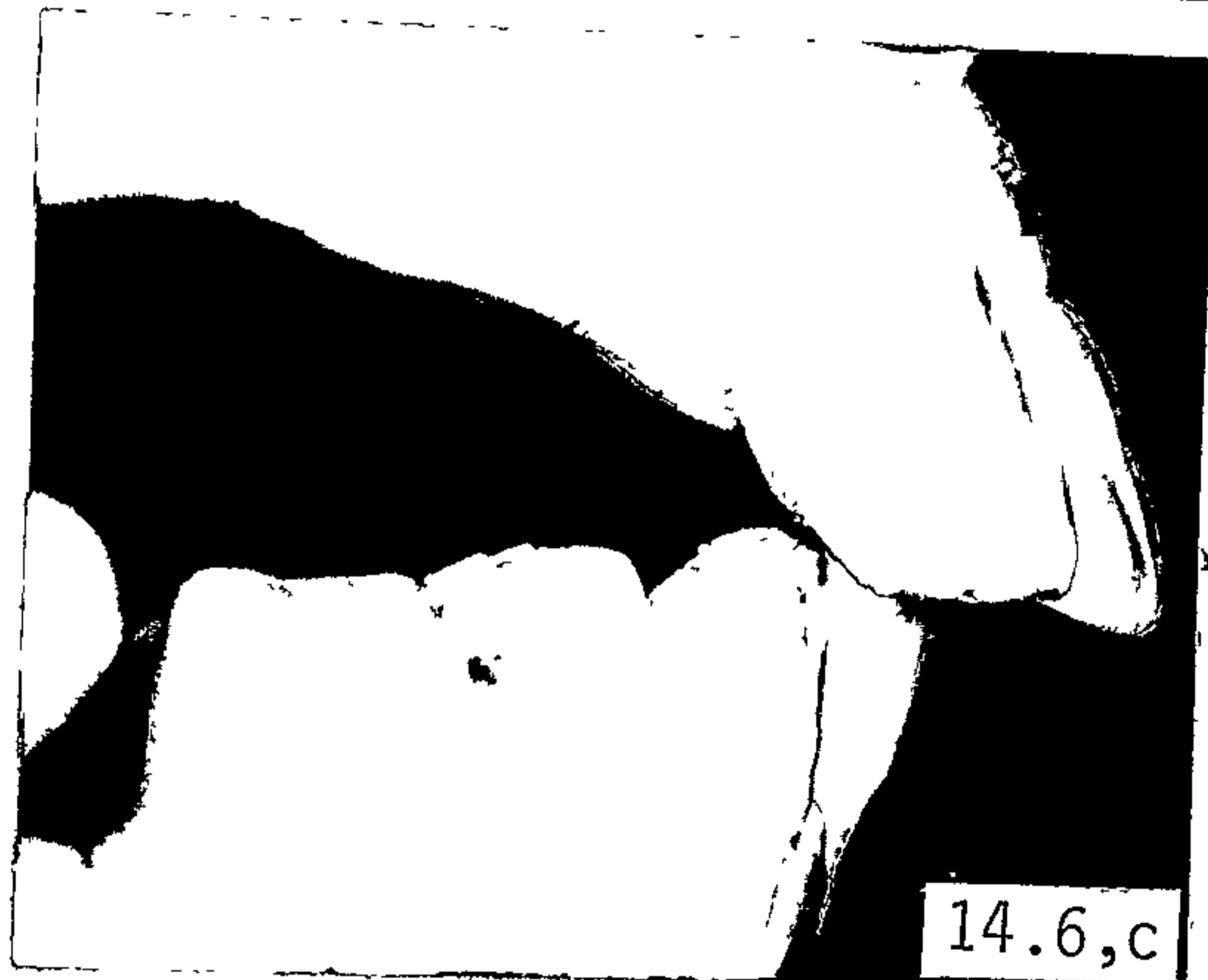
14.5



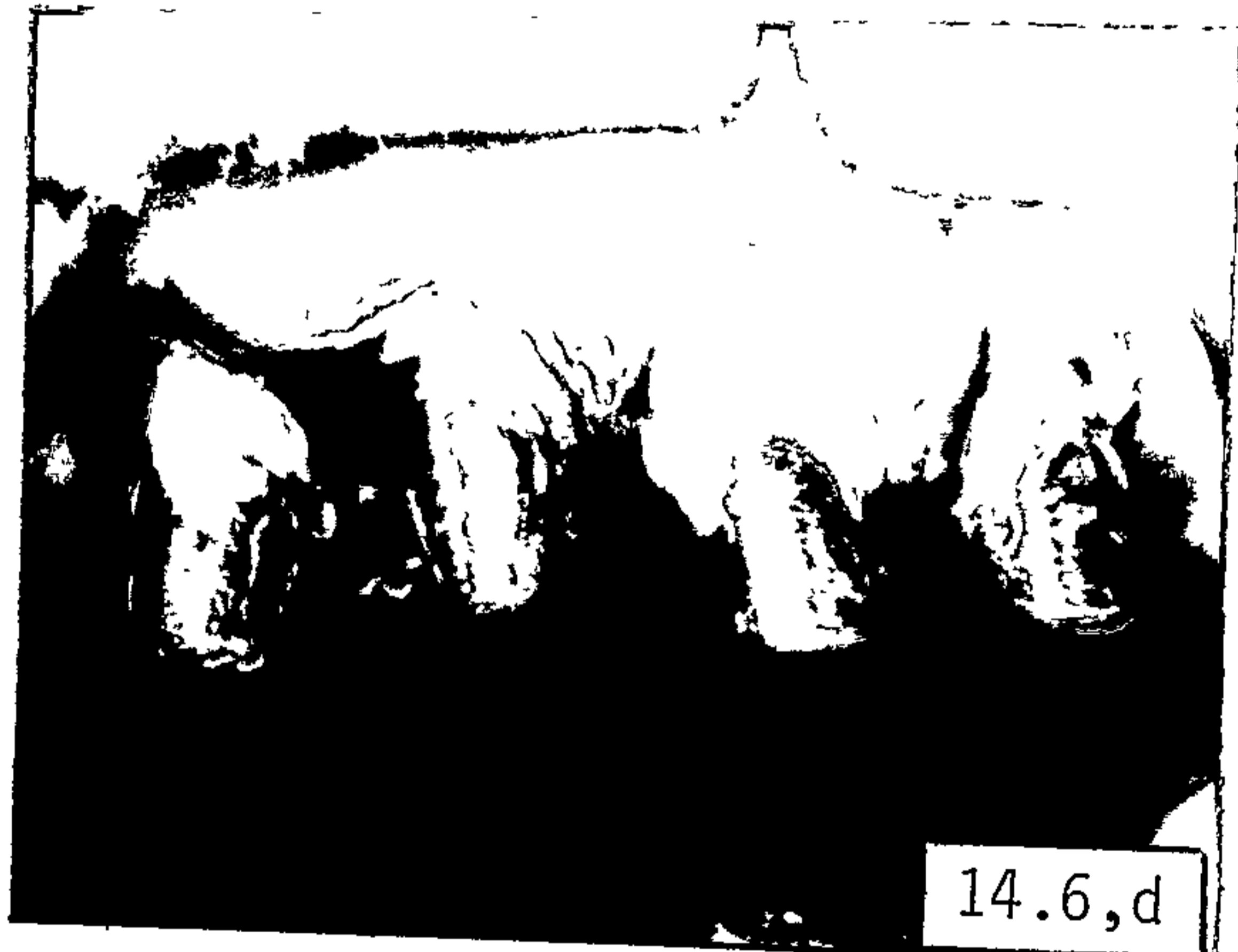14.6,a




14.6,b




14.6,c



14.6,d

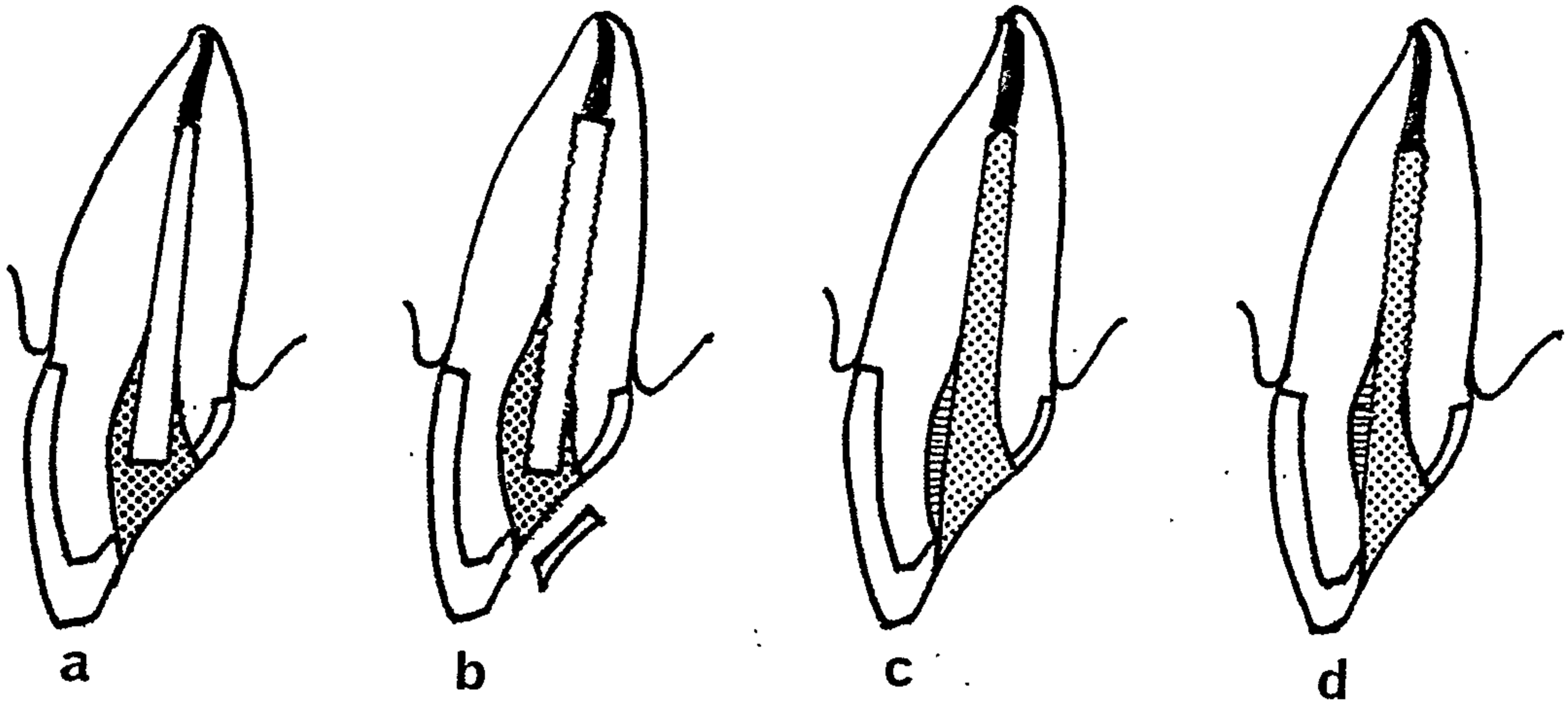


14.6,e



14.6,f

Fig. 14.7



Secondary intention post designs

- a. tapered steel post and amalgam seal
- b. cylindrical steel post and amalgam seal (or gold inlay)
- c. cast gold core on tapered post
- d. cast gold core on cylindrical post

(from Henry and Bower, 1977, b)

CHAPTER 15THE CORONAL RESTORATION

- 15.1 Functions of the coronal restoration
- 15.2 Timing of restoration
 - 15.2.1 Introduction
 - 15.2.2 Criteria indicative of successful root canal therapy
 - 15.2.3 Period of post-operative observation
 - 15.2.4 Timing of restoration
- 15.3 Design of the restoration
 - 15.3.1 Introduction
 - 15.3.2 Use of the remaining clinical crown
 - 15.3.3 Location of gingival finishing lines
 - 15.3.4 The overall treatment plan
- 15.4 Restorations for endodontically-treated anterior teeth
 - 15.4.1 Anterior teeth with relatively intact clinical crowns
 - 15.4.2 Anterior teeth with extensive loss of clinical crown
- 15.5 Restorations for endodontically-treated posterior teeth

15.1 Functions of the coronal restoration

After the completion of the root canal therapy and the placement of a post-core foundation — when it is indicated (5.3) — the treatment of an endodontically-treated tooth is finished by the placement of a coronal restoration. The functions of a post-core foundation and the advantages of restoring an endodontically-treated tooth by a two-stage procedure are considered in 5.2 and 5.5.5, respectively.

The aims (Rosen, 1961) of the final restoration may be (depending on the particular case):

1. to restore form and function,
2. to protect the remaining tooth structure from functional and non-functional stresses,
3. to protect the pulpless tooth from recurrent caries,
4. to restore the aesthetic appearance whenever possible, and
5. to prepare the tooth as a possible abutment for a fixed or removable prosthesis.

Whether it is due to dehydration of the remaining tooth structure or the structural weakening of the pulpless tooth for endodontic access,

it is generally agreed that a pulpless tooth is more likely to fracture than one with a vital pulp. Baraban (1969) therefore emphasized the need to design the coronal restoration so as to provide maximum strength to protect the endodontically-treated tooth from future complications. In situations where there is minimal tooth loss, the provision of maximum strength to protect the pulpless tooth may not be necessary.

15.2 Timing of restoration

15.2.1 *Introduction*

Since it is usually much more difficult, and in some cases impossible, to re-treat a root canal by way of the pulp chamber, after the placement of a coronal restoration, particularly if root canal posts are used, the clinician should evaluate the endodontically-treated tooth carefully to determine the prognosis of the endodontic treatment before a permanent restoration is placed. This evaluation requires a consideration of:

1. the criteria indicative of successful root canal therapy (15.2.2), and
2. the period of post-operative observation (15.2.3).

15.2.2 *Criteria indicative of successful root canal therapy*

Bender et al (1966) outlined some disadvantages of relying entirely on radiographic interpretation and emphasized the need to evaluate clinical signs and symptoms as well. They demonstrated how a change in the angulation can give the impression of a healing lesion by foreshortening vertically or by changing the angulation horizontally. Conversely, if a lesion is small or is not apparent on the pre-operative radiograph, a change in angulation can produce a misleading image of an enlarging lesion. Differences in exposure and developing time can also produce differences in film density giving a false impression of success or failure. At times it is possible to have an apparently normal appearance on the radiograph in the presence of pain and swelling — if

the labial plate is extremely thin and the amount of bone destroyed is not great enough to produce a contrast that can be visualized on the radiograph.

In patients with certain systemic diseases (such as hyperparathyroidism, multiple myeloma, Paget's disease, polyostatic fibrous displasia and uncontrolled diabetes), periapical areas of radiolucency which are unrelated to endodontic conditions may manifest themselves around some teeth and these areas will only disappear after the generalized disease is recognized and treated (Bender et al, 1966).

These authors suggested the following criteria indicative of successful endodontic treatment:

1. absence of pain and swelling
2. disappearance of fistula
3. no loss of function
4. no evidence of tissue destruction
5. radiographic evidence of an eliminated or arrested area of rarefaction after a post-treatment interval of from six months to two years.

Although complete osseous regeneration following root canal therapy is desirable (Harty et al, 1970; Jokinen et al, 1978), it is not always achieved. In other parts of the body healing often occurs by formation of scar tissue or tissue that bears no resemblance to the original tissue, without loss of function (Bender et al, 1966). In the periapical region, as Pennick (1961) and Grossman (1978, p.316) have pointed out, repair might be by connective tissue rather than by bone regeneration. In these cases the bony defect seldom fills in and thus results in a persistent periapical area in the radiograph. It has, therefore, been suggested (Seltzer et al, 1967) that endodontically-treated teeth with arrested areas of radiolucency which are functioning

adequately and without adverse clinical symptoms should be regarded as successfully treated and should be retained indefinitely.

Endodontically-treated teeth in the "questionable" category may be observed for a longer period of time provided that the lesion is not becoming larger and there are no adverse clinical symptoms. As long as the tooth is kept under observation, it remains as a functioning unit in the mouth (Bender et al, 1966).

An unsuccessful case is one in which an area of radiolucency has developed where none was present initially, or in which an initial area of radiolucency has become larger, or in which the pulpless tooth developed adverse clinical symptoms (Jokinen et al, 1978). If possible, a conservative approach — re-treatment of the root canal by way of the pulp chamber — should be attempted before resorting to surgical treatment or extraction.

15.2.3 *Period of post-operative observation*

"A certain period of time must elapse before roentgenographic evaluations of endodontic success or failure can be made" (Bender et al, 1966). The period of post-operative observation advocated by various authors varies from six months to four years and longer. Both Nicholls (1963) and Ingle (1965) considered, as a general rule, that a two-year period of observation was adequate. Strindberg (1956) claimed that a four-year observation period was needed. Bender et al (1966) and Seltzer et al (1967) found, in their studies, that most complications or failures occurred within six months to two years after the completion of treatment.

15.2.4 *Timing of restoration*

It is evident therefore that there is considerable doubt as to the length of time that should elapse before the restoration of the endodontically-treated tooth is commenced. When the clinical crown of

the pulpless tooth is relatively intact and only a simple restoration is required, there is little to be lost by placing the restoration as soon as possible after obturating the root canal (Nicholls, 1963).

The situation is somewhat different when a more complex form of treatment such as a crown or a fixed or removable prosthesis is planned; considerable time, effort and financial cost would be wasted should extraction of the pulpless tooth become necessary due to endodontic failure.

Where it is possible to correct an endodontic failure by periapical surgery, Nicholls (1963; 1977, p.325) suggested that the restoration of the pulpless tooth may be carried out approximately one week after the completion of the root canal therapy. Until the pulpless tooth is properly restored, there is a greater risk of tooth fracture. However, if the apex of the tooth is not accessible to periapical surgery, Nicholls recommended deferring the placement of the final restoration for "a few months until radiographs indicate the maintenance of a normal periapex or the regeneration of bone within a periapical lesion". If the pulpless tooth is to be used as an abutment for a bridge or a removable partial denture, possible interference with periapical healing, from the increased stresses on the pulpless tooth, may also be avoided by deferring the construction of the appliance for several months.

In anterior teeth, Grossman (1978, p.316) advocated waiting at least a week before placing a permanent restoration since, in general, any unfavourable clinical reaction, if it was to occur, would usually take place within twenty-four hours after root canal obturation. Where periapical bone was normal before endodontic treatment, it was stated that a period of observation was not necessary before proceeding with the restoration. It was suggested, however, that it may be advisable

to observe posterior abutment teeth with periapical lesions for a period of at least six months until there was evidence that the rarefied area was reducing in size.

While it may be desirable in many cases, to allow for a period of observation before placing the final restoration, the risk of fracture of an unrestored endodontically-treated tooth should also be considered. In general, endodontically-treated teeth that require complicated forms of treatment have lost a substantial amount of tooth structure and it is not always possible to protect these teeth adequately with temporary restorations during a prolonged period of observation. The restorative procedures can certainly be further complicated should there be recurrent caries, crown or root fracture, or a deterioration of the periodontal condition during the period of observation. For these reasons, several authors (Frank, 1965, p.612; Herschman and Weine, 1972, p.385; Morse, 1974, p.516) have advocated the placement of the final restoration as soon as possible after the completion of the root canal therapy.

Johnson et al (1976) reviewed the literature and, to assist the clinician, listed the following criteria which should be met by the pulpless tooth before proceeding with the permanent restoration:

1. There should be radiographic evidence of a proper apical seal.
2. The tooth should not be sensitive to pressure applied from any direction.
3. There should be an absence of drainage or exudate if a fistula was present.
4. The tissue over the apical region should not be sensitive to palpation.
5. All clinical signs of active inflammation should be absent.

Where there is any doubt about the prognosis of the endodontic treatment, and particularly in cases which are very difficult or

impossible to correct by periapical surgery, a waiting period of six months or longer was recommended by Johnson et al' (1976). It was suggested by Waliszewski and Sabala (1978) that, at the time of restoration, there should be an absence of clinical symptoms, and radiographic evidence of a return to normal architecture — no periapical radiolucency, an intact lamina dura and a normal periodontal ligament space. Others have suggested that there should at least be radiographic evidence that the periapical lesion is becoming reduced in size before any complicated restorative procedures are commenced (Nicholls, 1977, p.325; Grossman, 1978, p.316).

Apart from the prognosis of the endodontic treatment, Grundy and Glyn Jones (1981) suggested that the risk of future trauma to the pulpless tooth should also be considered. If, for example, pulpal involvement was initially due to some sporting accident, and future trauma from this activity was still possible, they recommended postponing the final restoration of these pulpless teeth until contact sports are no longer played because "a blow to a post-crowned tooth is quite likely to shatter the root, thus making extraction inevitable". These authors appeared to assume that, normally, only the clinical crown of an unrestored pulpless tooth would fracture making it possible to restore the remaining root.

It is reasonable, therefore, to suggest (Nicholls, 1977, p.325) that if the restoration is to be deferred for an appreciable length of time, the endodontically-treated tooth should be adequately protected against possible fracture. The temporary restoration should be properly contoured for easy plaque control, to minimize the risk of recurrent caries and the possibility of tilting, and to prevent over-eruption or movement of opposing or adjacent teeth.

15.3 Design of the restoration

15.3.1 *Introduction*

The choice of the restorative material and technique used in the restoration of endodontically-treated teeth depends largely on the amount of remaining sound tooth structure (Baraban, 1967; Nicholls, 1977, p.326). Clinically, the decision — whether a more conservative or a more radical approach is to be adopted — may be influenced by one or more of the following factors:

1. The role of the pulpless tooth in the overall treatment plan (Baraban, 1967). The tooth may be restored as a single unit or it may be used as a major or minor abutment for a fixed or removable prosthesis.
2. The occlusion and occlusal habits of the patient (Baraban, 1967). If the anticipated occlusal load on the tooth is large the restoration should be designed to provide maximum strength and protection.
3. The demand for aesthetics in that part of the mouth.
4. The periodontal condition of the tooth and the necessity for splinting.
5. The ability and motivation of the patient to control plaque.
6. The age of the patient.
7. The financial cost of the restoration may also be a limiting factor in some cases.

Over the years, many restorative materials and techniques have been used to restore endodontically-treated teeth with varying degrees of success. Because the aesthetic requirements and the nature of occlusal stresses are usually different, the restoration of anterior teeth (15.4) is considered separately from posterior teeth (15.5). Several basic principles are, however, applicable for both anterior and posterior pulpless teeth (15.3.2, 15.3.3 and 15.3.4).

15.3.2 *Use of the remaining clinical crown*

With the aid of post-retained or pin-retained, cast gold, amalgam or composite resin core foundations, it is usually possible to build up the remaining clinical crown to enable the achievement of an ideal or "classical" preparation (Kafalias, 1975) for the final coronal restoration (Colman, 1979). The alternative method of attaining the necessary retention and resistance form by utilizing only the available remaining sound tooth structure is usually only a compromise.

15.3.3 *Location of gingival finishing lines*

Regardless of the type of core material used, whenever possible, the margins of the final coronal restoration should be placed on sound tooth structure apical to the junction of the post-core foundation and the tooth (Colman, 1979; Lester, 1981). This is particularly important for composite resin core foundations because of their somewhat inferior long-term marginal integrity compared to amalgam (14.3.3). This procedure offers several advantages. The preparation is more retentive because of the greater length of the axially-directed walls, there is only one set of exposed margins and, in general, the aesthetics can be improved (Colman, 1979). If a full crown is used, this apical extension of the coronal restoration will also provide a coping or "ferrule" effect to protect the remaining root from vertical fracture (Rosen, 1961; Eissmann and Radke, 1976, p.538). In cases of extensive loss of sound tooth structure, it may be more practical to establish part or all of the margins of the final restoration on the post-core foundation itself (Colman, 1979). Periodontal surgery may occasionally be necessary to expose sound tooth structure. In the cases where the core material is exposed on the surface of the restored tooth, only cast gold or amalgam should be used for the core foundation.

15.3.4 *The overall treatment plan*

The absence of vital pulp tissue and the availability of the root canal for the retention of core foundations and prosthetic appliances increase the number of options available to the restorative dentist.

With the use of properly designed post-core foundations, many restorations used for the treatment of vital teeth can also be used to restore endodontically-treated teeth with little or no modification to cavity design. Malaligned teeth can have their restored clinical crowns placed in a more aesthetic and functional position in the arch (Fig. 14.6) than is often possible when a vital pulp is present (Pickard, 1964). Within reason, abutment preparations for a fixed prosthesis can also be paralleled by the use of a properly designed post-core foundation (Nicholls, 1963). More space can be made available for a thicker porcelain veneer which increases the strength of the crown and produces a better aesthetic result (Kafalias, 1975). Root caps, with or without attachments, used in conjunction with overlay dentures, are a useful adjunct in the prosthodontic treatment of partially edentulous patients. Because the "retained teeth" are shortened and covered by the overdenture, only very rarely is this technique possible in teeth with vital pulps (Frank et al, 1976, p.788-796).

Although Kafalias (1975) noted that, where necessary, "non-vital teeth make tremendously good abutments and indeed may be ranked equal to vital teeth in crown and bridge circumstances", it should be the aim of every clinician to preserve the vitality of a tooth whenever possible. Because of the inevitable weakening of the tooth, intentional devitalization should only be employed when alternative forms of treatment are either impractical or less desirable to the overall treatment plan, or when the long-term maintenance of pulp vitality is very doubtful.

The following discussion on the different types of restorations used in anterior (15.4) and posterior (15.5) endodontically-treated teeth

is divided into two sections according to the physical condition of the pulpless tooth:

- i. The clinical crown is relatively intact.
- ii. There is extensive loss of tooth structure in the clinical crown.

15.4 Restorations for endodontically-treated anterior teeth

15.4.1 *Anterior teeth with relatively intact clinical crowns*

15.4.11 Introduction

Apart from the endodontic access cavity, the clinical crown of an endodontically-treated tooth in this category is relatively intact; a small proximal lesion or a small incisal fracture due to trauma may be present. The indications for the use of root canal posts in these teeth have already been considered in 5.3.21 — unless the pulpless tooth is going to be an abutment for a fixed bridge or is to be subjected to excessive occlusal stresses, a simple restoration is usually all that is required. Discolouration of an endodontically-treated tooth is a common occurrence which, in many cases, can be prevented (or at least minimized) by proper attention to the tooth during various stages of the root canal therapy (2.5). Unfortunately, the possibility of using bleaching techniques to correct this aesthetic problem is often overlooked and many relatively intact discoloured pulpless teeth are restored with post-core foundations and some form of full veneer crowns. For this reason, the causes, the prevention and the treatment of discoloured endodontically-treated teeth are considered first, followed by a discussion of the restoration of these pulpless teeth.

15.4.12 Bleaching of discoloured, endodontically-treated teeth

Although it is desirable to prevent discolouration of the pulpless tooth in the first place (Sommer et al, 1966, p.490), it is not possible in some clinical situations. An understanding of the causes of tooth

discolouration will assist in the prevention of discolouration, in the selection of cases for treatment and in the actual bleaching procedures.

A. Causes and prevention of discolouration

Several factors have been known to cause tooth discolouration:

i. Pulpal haemorrhage caused by trauma

Pulpal haemorrhage has been described as the most common cause of *severe* tooth discolouration (Sommer et al, 1966, p.489). This haemorrhage may be associated with vital pulp extirpation or may be the result of traumatic injuries (Nutting and Poe, 1967).

According to Grossman (1978, p.323), traumatic injury of a tooth may cause the rupture of blood vessels in the pulp with diffusion of blood into the dentinal tubules. Such teeth often become stained almost immediately after the accident. The released erythrocytes subsequently undergo haemolysis and the iron, made available by the degeneration of haemoglobin, combines with hydrogen sulphide produced by bacteria, to form a black compound, iron sulphide. The penetration of the dentinal tubules by this pigment is considered to be the prime factor in the darkening of the tooth in these cases.

Because pulpal haemorrhage caused by trauma cannot be prevented, there is frequently discolouration already in the tooth by the time the patient presents for treatment. In these cases, the clinician should attempt bleaching as soon as possible (Frank, 1976, p.529).

ii. Haemorrhage following pulp extirpation

Extirpation of a vital pulp is frequently associated with excessive haemorrhage and subsequent discolouration unless prompt action is taken by the clinician. If blood, having penetrated into dentinal tubules, is allowed to remain and deteriorate, discolouration comparable with that associated with trauma-induced haemorrhage occurs. In a young tooth, with a large pulp chamber, a wide root canal and wide dentinal tubules, the possibility of discolouration tends to be greater

(Frank, 1976, p.529; Grossman, 1978, p.324). Grossman (1978, p.323) therefore recommended that during endodontic treatment:

- a. the pulp chamber and the root canal should be thoroughly irrigated to prevent diffusion of blood into the dentinal tubules, and
- b. pulpal remnants that might lead to further haemorrhage in the root canal should be completely removed.

iii. Necrotic material in the pulp chamber

The decomposition of pulp tissue is a common cause of tooth discolouration — particularly if the pulp is putrescent (Grossman, 1978, p.322). In general, this type of staining is less severe than that caused by haemorrhage. Because of the frequent occurrence of slow, relatively symptom-free pulp death and the slow formation of tooth-staining compounds, it is probable that many teeth remain untreated for some months, or even years, after pulp death. There is evidence of a direct relationship between the length of time these compounds are allowed to remain within the pulp chamber and the degree of discolouration (Frank, 1976, p.529); Frank suggested that this delay before treatment might influence the prognosis of the subsequent bleaching procedures.

iv. Medicaments and sealing agents

Certain medicaments and sealing agents used in root canal therapy may cause tooth discolouration (Frank, 1976, p.529; Grossman, 1978, p.323). Root canal medicaments known to cause staining to tooth structure include iodides, iodoform, silver nitrate, mercuric chloride and silver-containing paste, sealing materials. Frank (1976, p.529) suggested that root canal medicaments and sealing agents should be selected not only on the basis of their effectiveness but also with regard to their potential for staining.

v. Inadequate endodontic access

If the endodontic access cavity into the pulp chamber is inadequate, a large portion of the pulp horns remain inaccessible to mechanical and chemical debridement. Blood, necrotic debris, offending medicaments and sealing agents may become trapped in this inaccessible space and remain unobserved (Fig. 15.1,a). This can lead to crown discolouration as well as the recontamination of the root canal during endodontic treatment (Sommer et al, 1966, p.489; Frank, 1976, p.530; Grossman, 1978, p.324).

vi. Restorative materials

Discolouration of the remaining tooth structure by restorative materials is dependent upon the type of material used (Grossman, 1978, p.323). Amalgam, which is often used to restore the lingual access cavity in anterior teeth, has been reported to produce, in these pulpless teeth, a dark grey to bluish-black stain depending on the type of alloy used and the amount of marginal leakage that has occurred. Although gold is seldom responsible for discolouration, it may combine with the products of dental caries to produce a dark brown stain. Acrylic resin, composite resin and silicate cement restorations may be associated with coronal discolouration after gross marginal leakage has occurred.

vii. Extrinsic and intrinsic factors

A miscellaneous collection of other factors, of either extrinsic or intrinsic origin, may occasionally be responsible for the discolouration of tooth structure (Frank, 1976, p.530-531).

Extrinsic factors contributing to tooth discolouration include the prolonged use of staining food and fluids, such as tea and coffee, and the use of tobacco (chewing and smoking). The stain is normally confined to the tooth surface and can usually be controlled by a combination of oral hygiene at home and periodic prophylaxis in the dental office.

Discolouration, of an intrinsic origin, may be caused by certain systemic conditions affecting the individual during the stages of tooth formation. The colour and degree of staining vary according to the condition and its duration. Examples of these intrinsic factors include congenital porphyria, dentinogenesis imperfecta, cystic fibrosis of the pancreas, erythroblastosis foetalis, jaundice and endemic fluorosis (Zegarelli et al, 1967; Frank, 1976, p.531; Grossman, 1978, p.322). Chemotherapy, by administration of many of the tetracycline group of antibiotics, has frequently been responsible for a characteristic discolouration of the dentition (Cohen and Parkins, 1970; Arens et al, 1972).

B. Case selection

The prognosis for the bleaching procedure is influenced principally by the cause and the severity of the tooth discolouration. Discolouration caused by the products of pulp degeneration, haemorrhage and debris usually presents a reasonably good prognosis (Frank, 1976, p.531). If the stain is caused by the penetration and precipitation of metallic salts and silver-containing medicaments, sealers and restorative materials, and has been present for a long time, the prognosis is generally poor (Sommer et al, 1966, p.497; Nutting and Poe, 1967; Frank, 1976, p.531; Grossman, 1978, p.322) — for example, Fig. 15.1,b (20 years).

Before proceeding with the bleaching procedure, several factors should also be considered. First, the type and quality of the root canal filling. Bleaching is contra-indicated if the apical seal is inadequate because of the presence of a poorly condensed gutta percha root filling, a paste sealer or a silver point root filling (Fig. 14.1,c and d). It has been suggested that oxygen released during the bleaching process may work its way along an inadequate root filling up to the periapical region

and cause discomfort to the patient (Sommer et al, 1966, p.498; Nutting and Poe, 1967). Secondly, consideration should be given to the condition of the remaining tooth structure. If the crown has been restored many times or has defects such as fractures, cracks or hyperplastic enamel, the final result is likely to be aesthetically poor even though bleaching is effective. In these cases, a full coverage restoration is probably the most judicious treatment (Nutting and Poe, 1967).

C. Bleaching agents

The bleaching of the crowns of discoloured teeth is not new. Over a hundred years ago, Chapple (1877) advocated the use of oxalic acid as a bleaching agent. In 1878, Taft suggested the use of calcium hypochlorite and Harlan, in 1884, was probably the first to suggest the use of hydrogen peroxide for bleaching (Stewart, 1965). In 1895, Westlake referred to the use of Pyrozone for bleaching pulpless teeth and it wasn't until 1918 that Superoxol was introduced by Abbot (Stewart, 1965). In 1961, Spasser reported success with a technique using sodium perborate as the bleaching agent; Nutting and Poe (1967) found that Amosan was equally effective when combined with hydrogen peroxide.

Superoxol* is a 30 per cent aqueous solution of hydrogen peroxide. It is a clear, colourless and odourless liquid usually supplied in light-proof amber bottles. The solution retains sufficient potency for a period of three or four months if refrigerated and kept isolated from contact with organic material. Superoxol should not be exposed to heat because of the risk of explosion and care should be taken to prevent contact with the eyes, the skin as well as the oral mucosa; an unpleasant

*Merek & Co., Inc., Rahway, N.J., U.S.A.

(but short-lasting) pain may result from a Superoxol burn. The tissues around the tooth to be bleached should therefore be covered with petroleum jelly or cocoa butter for protection, and all bleaching with Superoxol must be done under a rubber dam (Sommer et al, 1966; p.490-491; Grossman, 1978, p.324-325). In an experiment by Sommer et al (1966, p.490), no difference in the degree of bleaching was observed when hydrogen peroxide solutions of higher concentrations (50 per cent and 90 per cent) were used.

Pyrozone is 25 per cent hydrogen peroxide in 75 per cent ether. The advocates of Pyrozone (Dietz, 1957; Pearson, 1958) stated that it is more effective than Superoxol because ether has a lower surface tension and may penetrate deeper into the dentinal tubules. However, ether is flammable and can be explosive; its odour can be nauseating to some individuals and it has a very limited shelf-life even when refrigerated. The same precautions should be taken as with Superoxol (Nutting and Poe, 1967).

Sodium perborate is stable in the dry (powder) state; in solution with water, it decomposes into sodium metaborate, hydrogen peroxide and oxygen and has been found to be an effective bleaching agent (Spasser, 1961). Some clinicians (Nutting and Poe, 1967) prefer Superoxol as the liquid instead of water reasoning that the combination of the two chemicals should be more effective since both compounds release oxygen. Amosan* is a convenient form of sodium perborate (sodium perborate - 68.6%, sodium bitartrate - 29.4%) available commercially.

D. Bleaching techniques

The techniques currently advocated for the bleaching of endodontically-treated teeth are based on the use of oxidizing agents —

*Cooper Laboratories, Brookvale, N.S.W., Australia

chemicals that directly release oxygen. The main difference between them is the method whereby oxygen is released (Frank, 1976, p.531).

The "*walking bleach*" technique suggested by Nutting and Poe (1967) was, in effect, a modification of Spasser's technique in which a paste of sodium perborate and water was sealed in the pulp chamber between appointments. Instead of water, Nutting and Poe (1967) used Superoxol with the sodium perborate. According to Frank (1976, p.532) "it is the best technique for non-vital teeth". The clinical procedures are simple, require a minimum of chairside time and no special armamentarium is required.

The clinical procedures as outlined by Nutting and Poe (1967) and Frank (1976, p.532) are basically as follows:

1. Record the shade of the discoloured tooth with a shade guide for later evaluation before placing rubber dam.
2. Protect the gingival tissues with petroleum jelly (or cocoa butter) if Superoxol is used. Isolate the discoloured tooth with a rubber.
3. Remove all materials from the pulp chamber to a level 2 to 3 mm apical to the gingival margin. Remove all caries and defective restorations.
4. A small amount of the surface layer of dentine in the pulp chamber may be removed with a slowly rotating round bur. The freshened dentine permits easier penetration of the bleaching agents.
5. If the root canal has been obturated with a silver point, place a 1 mm layer of accelerated zinc oxide/eugenol cement over the canal orifice. This helps to prevent leakage of the bleaching agents to the apical region. Allow the cement to set before proceeding with the next step. This step is unnecessary if a well-condensed gutta percha root filling is present.

6. To ensure the cleanliness of the modified pulp chamber, Sommer et al (1966, p.492) suggested the use of a solution made up of one part of chloroform in three parts of 90 per cent ethyl alcohol. They found that this was a very effective dehydrating agent; in addition, the chloroform content tended to dissolve away any fatty or oily substances which may be present in the pulp chamber. The cavity is then dried with blasts of warm air.

7. Mix the sodium perborate and water (or Superoxol) to a thick paste and place into the pulp chamber. Clean the margins of the access cavity and leave a cotton pellet in place.

8. Seal the cavity with a temporary filling material (for example, Cavit*, or zinc phosphate cement) and hold firmly in place until set; otherwise the liberation of oxygen will cause escape of the chemical.

9. The bleaching takes place at body temperature after the bleaching agents have been sealed in the discoloured tooth. The result is examined in four to seven days. If inadequate bleaching has occurred, a fresh mix of bleaching agent is placed in the pulp chamber. If possible, it is desirable to overbleach the discoloured tooth slightly in case some colour regression occurs. Once the desired shade is obtained, the final coronal restoration is placed.

Several materials have been suggested for the prevention of re-discolouration after bleaching. Sodium fluoride (Dietz, 1957) and clear acrylic resin monomer (Pearson, 1958; Nutting and Poe, 1967) may be applied to the walls of the pulp chamber before the placement

*Cavit, ESPE, Oberbay, W. Germany.

of the restoration, to seal the dentinal tubules and prevent discolouration by leakage. Grossman (1978, p.329) recommended the use of a silicone fluid to restore the translucency of the tooth structure before placing the final restoration.

An alternative technique commonly used to achieve bleaching is the *thermocatalytic technique* (Frank, 1976, p.532) in which heat is used to release the oxygen from the 30 per cent hydrogen peroxide solution. The discoloured pulpless tooth is prepared for bleaching in a manner similar to that described for the "walking bleach" technique (steps 1 to 6). Depending on the type of heat source, additional protection of the soft tissues and adjacent teeth from the heat generated may be necessary. Water-moistened gauze pads may be placed under the rubber dam to cover the lips and soft tissues. Cotton pellets loosely packed in the pulp chamber are saturated with the hydrogen peroxide solution. Heat is then applied to activate the bleaching process.

Over the years, a variety of heat sources have been used to activate the hydrogen peroxide. These have been described in detail and include:

1. electric light bulbs in lamps of different designs (Pearson, 1958; Sommer et al, 1966, p.495-496; Grossman, 1978, p.325-328)
2. heated ball burnisher (Frank, 1976, p.532)
3. heated root canal plugger (Stewart, 1965)
4. ultra-violet light (Howell, 1981)
5. soldering iron insulated with asbestos (Cohen and Parkins, 1970)
6. coagulate ball electrode of an electrosurgical unit
(Whaledent International, 1979)

When using the thermocatalytic technique, local anaesthetic should never be used. The patient should be totally aware and be able to respond

if the heat becomes uncomfortable in order to avoid unnecessary damage to the pulps of adjacent teeth and surrounding soft tissues. In addition, if leakage of the hydrogen peroxide occurs, the patient will be able to feel a burning sensation. One major advantage of this method is that some improvement is usually apparent within twenty to thirty minutes of the commencement of treatment. If the desired shade is not obtained during the first appointment, a bleaching agent can also be sealed in the pulp chamber until the following appointment.

E. Possible complications associated with the bleaching of endodontically-treated teeth

A report of several clinical cases of external resorption of the cervical region of crown and root structure (Harrington and Natkin, 1979) has suggested that these complications may have been caused by the bleaching of the endodontically-treated teeth. It was suggested that in the cases reported, the bleaching agent (Superoxol) could have diffused through the patent dentinal tubules into the cervical periodontal ligament during the bleaching procedure and initiated an inflammatory resorptive process.

15.4.13 The coronal restoration of relatively intact endodontically-treated anterior teeth

When there is only a small loss of tooth structure mesially or distally, in addition to the endodontic access cavity, the entire defect may be restored with an acid-etched composite resin restoration (Nicholls, 1977, p.326). If the cavity is confined to the lingual aspect of the tooth, a light shade of material is used to counteract any discolouration of the dentine which may occur later.

Due to the potential for staining of the dentine by amalgam, the use of this material should be avoided in anterior pulpless teeth (Frank, 1976, p.534). If needed, metallic restorations should only be used in

teeth with considerable bulk bucco-lingually, such as maxillary canines, so that discolouration of the clinical crown is avoided (Nicholls, 1977, p.327). The pulp chamber is first filled with composite resin, a light shade silicate cement or zinc phosphate cement; the gold foil or amalgam restoration is only placed just "pulpal" to the dentino-enamel junction.

15.4.2 *Anterior teeth with extensive loss of clinical crown*

Provided there is no objection to the appearance of gold in this part of the mouth, gold inlays may be used to restore small to moderate size defects (Healey, 1957). However, if the clinical crown is weakened to such a degree by the preparation that a post may be necessary to prevent fracture, other forms of treatment should be considered.

The use of post inlays in anterior pulpless teeth with moderate loss of tooth structure was discouraged by Barker (1963). Because the post and the coronal inlay must have a common path of insertion, there is usually an excessive display of gold. In addition, the need for extensive facings and the discolouration of the remaining tooth structure in a relatively short time often make this type of inlay a "temporary" restoration. The removal of such an inlay with a post of proper length can be a hazardous and very difficult procedure. Therefore, if the use of a post is indicated, it is preferable to complete the post-core foundation first before proceeding with the construction of the coronal restoration. The many advantages of following such a sequence have been outlined in 5.5.5. For these reasons the use of one-piece post-crowns such as the Richmond, Davis and the more modern porcelain fused to metal post-crowns, is discouraged. Details of the tooth preparation and the construction of these types of post-crowns have been described in several publications (Goslee, 1903; Baker, 1960; Barker, 1963; Tylman, 1965, p.776-785; Sommer et al, 1966, p.500-524) and are not discussed here.

Since the use of a post is usually indicated in broken down endodontically-treated teeth, a full crown placed over a post-core

foundation probably offers the most suitable form of treatment in many cases. The selection of the material and design for the crown restoration is, in principle, similar to that for vital teeth. Precious and non-precious alloys, porcelain, acrylic resin and more recently, composite resin, have been used for the construction of anterior full crowns. Amongst these, the porcelain bonded to metal crowns and the porcelain jacket crowns are probably the most commonly used. Details of the principles of their use, their design and construction is beyond the scope of this discussion; the reader may refer to textbooks on fixed prosthodontics for additional information.

Where only a small number of periodontally sound teeth remain in the arch, they can often be useful for the support of an overlay denture. Following endodontic treatment and the removal of the clinical crown the remaining root can be restored with simple amalgam restorations or cast gold root caps with or without precision retaining devices incorporated. Information on these techniques can be obtained by referring to textbooks and publications on prosthodontics (Lord and Teel, 1974; Frank et al, 1976, p.788-796; Crum, 1978, p.569-586).

15.5 Restorations for endodontically-treated posterior teeth

"Vertical fracture of a posterior tooth in a mesio-distal plane is resisted by the roof of the pulp chamber and by the marginal ridges which together serve to join the buccal and lingual aspects of the tooth" (Nicholls, 1977, p.327). In the posterior region of the mouth, pulpal degeneration due to trauma is uncommon when compared with anterior teeth; in addition, carious lesions large enough to cause pulpal degeneration rarely involve only the occlusal surface of the tooth. On the rare occasions where a posterior tooth has been treated endodontically through a conservative access cavity but is otherwise intact, a simple amalgam restoration would probably be adequate (Tidmarsh, 1976; Nicholls, 1977, p.327).

The importance of cuspal protection in the design of the coronal restoration for posterior pulpless teeth has been emphasized by many authors (Healey, 1954; Frank, 1959; Gilmore and Lund, 1973, p.260-265; Frank et al, 1976, p.778; Herschman et al, 1976, p.445; Tidmarsh, 1976; Nicholls, 1977, p.327-328). Where one of the marginal ridges has been lost, a gold restoration with full cuspal coverage is indicated to prevent fracture of the remaining crown (Fig. 15.2). When both marginal ridges are missing, provided the remaining cusps are adequately supported, an MOD onlay capping the buccal and lingual cusps would generally provide adequate protection against vertical crown fractures (Frank et al, 1976, p.778; Nicholls, 1977, p.327-328). If the cost of the cast gold restoration is a problem, amalgam may be used as an alternative to provide cuspal protection although cast gold is generally better because of its superior strength and lack of flow under load (Tidmarsh, 1976). Because of the lack of strength of amalgam in thin sections, more tooth structure has to be removed to ensure adequate strength in the amalgam restoration. Prefabricated metal posts may be cemented into the prepared root canals prior to the placement of the amalgam restoration and this may serve as an interim post-core restoration until a cast coronal restoration is placed (Fig. 15.3). Brown et al (1979) suggested the use of pin-retained amalgam restorations when the prognosis of the endodontic treatment is questionable. This allows the re-treatment of the root canals by way of the pulp chamber should it become necessary at a later date.

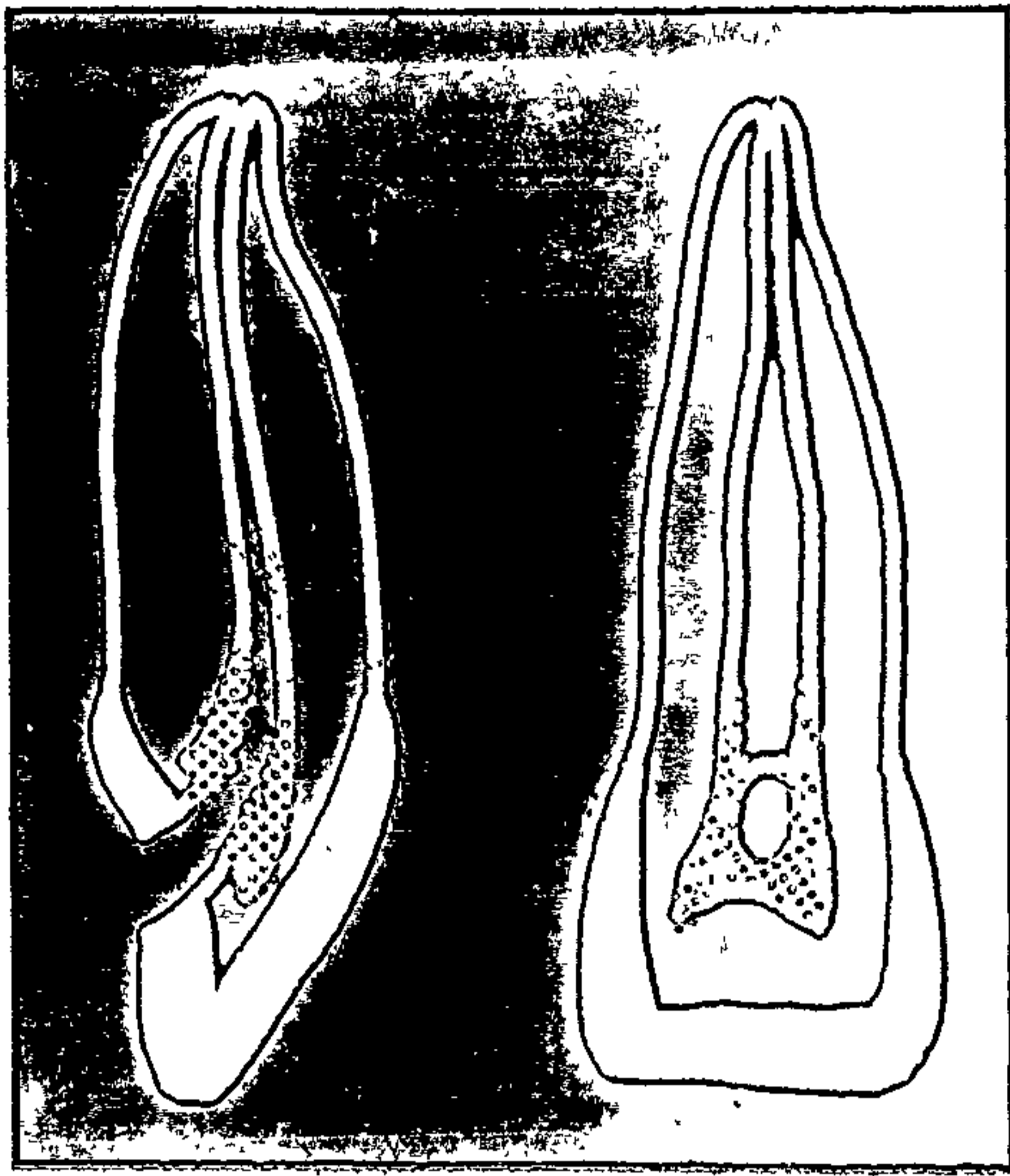
When the loss of coronal tooth structure is more extensive and a three quarter crown or full crown (metal or ceramo-metal) is indicated, it is usually preferable to build up the clinical crown first with a post-core foundation (with either amalgam or composite resin) before proceeding with the construction of the crown (Fig. 15.4 and 15.5). One-piece post-crowns like that described by Lister (1972) are generally not recommended.

- Fig. 15.1
- a. An inadequate endodontic access cavity creates a harbour for bacteria and necrotic debris which may cause crown discolouration and possibly failure of the root canal therapy.
 - b. This pulpless tooth has been discoloured for over 20 years and was found to be resistant to bleaching.
 - c. Central incisor with a poorly condensed root filling and an inadequate access cavity before treatment.
 - d. Same tooth 2 years after re-treatment and obturation of the root canal with gutta percha points and sealer and bleaching with sodium perborate. The lingual access cavity was restored with a light-coloured acid-etched composite resin.

Fig. 15.2 Adequate restoration with cuspal protection may have prevented the fracture of these endodontically-treated posterior teeth. The prognosis of the fractured molar in Fig. 15.2, b is poor.

- Fig. 15.3
- a. Extensively restored molar requiring endodontic treatment.
 - b. Clinical condition of the tooth following endodontic treatment.


Fig. 15.1; 15.2; 15.3,a and b




15.1,a



15.1,b



15.1,c




15.1,d



15.2,a



15.2,b



15.3,a



15.3,b

Fig. 15.3 c. Occlusal view of the prepared tooth ready for insertion of root canal posts. Buccal and lingual cusps have been reduced sufficiently to provide bulk in the coronal amalgam restoration.

d, e and f. Completed coronal amalgam restoration several weeks after endodontic treatment. This may be used as a foundation for a cast restoration in the future.

Fig. 15.4 a. This root-filled mandibular premolar abutment for a removable partial denture was inadequately restored with a pin-retained amalgam restoration.

b. The existing restoration and recurrent caries around the pins were removed and as much of the buccal cusp as possible was retained. A stainless steel post of adequate length was cemented into the root canal and to support an amalgam core foundation. A complete cast metal crown will complete the restoration of this abutment tooth.

Fig. 15.5 An endodontically-treated molar restored with a post-retained amalgam core foundation and a $\frac{3}{4}$ veneer crown.

Fig.15.3,c to f; 15.4; 15.5



15.3,c



15.3,d




15.3,e



15.3,f



15.4,a



15.4,b



15.5,c



15.5,a



15.5,b

BIBLIOGRAPHY

- Abdullah, S.I., and Bjorndal, A.M. — A cast gold base for endodontically treated molar roots where divergent form precludes parallel posts construction. *Dent. Dig.*, 76:187-189 (Apr.) 1970.
- Abdullah, S.I., Mohammed, H., and Thayer, K.E. — Restoration of endodontically treated teeth. A review. *Can. Dent. Assoc. J.*, 40:4, 300-303 (Apr.) 1974.
- Abrams, L., and Trachtenberg, D.I. — Hemisection - technique and restoration. *Dent. Clin. North Am.*, 18:2, 415-444 (Apr.) 1974.
- Al-Hamadani, K.K., and Crabb, H.S.M. — Marginal adaptation of composite resins. *J. Oral Rehabil.*, 2:1, 21-33 (Jan.) 1975.
- Ambrose, E.R., Leith, D.R., Pinchuk, M.L., and Hwang, P.J. — Manipulation and insertion of a composite resin for anterior and posterior cavity preparations. *J. Can. Dent. Assoc. J.*, 37:5, 188-195 (May) 1971.
- American Dental Association — Alloys for restorative and prosthetic dental procedures. *in* Guide to Dental Materials and Devices, 8th ed., Chicago, American Dental Association, 1976-1978 (Chapter 11).
- Anderson, I.A. — Kerr Coreform. *Gunz Gazette*, Vol:28 (Oct.) 1981.
- Anderson, J.N. — Applied Dental Materials. Oxford, Blackwell Scientific Publications, 1972.
- Andrews, J.T., and Hembree, J.H. Jr. — Microleakage of several amalgam systems: an animal study. *J. Prosthet. Dent.*, 40:4, 418-421 (Oct.) 1978.
- Angmar-Månsson, B., Omnell, K.A., and Rud, J. — Root fractures due to corrosion. Metallurgical aspects. *Odont. Revy*, 20:3, 245-265 (Sept.) 1969.
- Appleton, I.E. — Restoration of root-resected teeth. *J. Prosthet. Dent.*, 44:2, 150-153 (Aug.) 1980.
- Arens, D.E., Rich, J.J., and Healey, H.J. — A practical method of bleaching tetracycline-stained teeth. *Oral Surg.*, 34:5, 812-817 (Nov.) 1972.

- Arvidson, K., and Wróblewski, R. — Migration of metallic ions from screwposts into dentine and surrounding tissues.
Scand. J. Dent. Res., 86:3, 200-205 (May) 1978.
- Baker, C.R. — The dowel crown.
J. Am. Dent. Assoc., 61:4, 479-483 (Oct.) 1960.
- Baraban, D.J. — The restoration of pulpless teeth.
Dent. Clin. North Am., 11:4, 633-653 (Nov.) 1967.
- Baraban, D.J. — A simplified method for making posts and cores.
J. Prosthet. Dent., 24:3, 287-297 (Sept.) 1970.
- Baraban, D.J. — Immediate restoration of pulpless teeth.
J. Prosthet. Dent., 28:6, 607-612 (Dec.) 1972.
- Barker, B.C.W. — The restoration of non-vital teeth with crowns.
Aust. Dent. J., 8:3, 191-200 (June) 1963.
- Barkmeier, W.W., Frost, D.E., and Cooley, R.I. — The two-in-one self-threading, self-shearing pin - efficacy of insertion techniques.
J. Am. Dent. Assoc., 97:1, 51-53 (July) 1978.
- Barkmeier, W.W., and Williams, H.J. — Surgical methods of gingival retraction for restorative dentistry.
J. Am. Dent. Assoc., 96:6, 1002-1007 (June) 1978.
- Baum, L., Phillips, R.W., and Lund, M.R. — Reinforcement of the endodontically treated tooth.
in Textbook of Operative Dentistry, Philadelphia, W.B. Saunders Co., 1981 (Chapter 19).
- Beech, D.R. — Adhesion and adhesives in the oral environment.
Ann. R.A.C.D.S., 5:128-135 (June) 1977.
- Beech, D.R. — Glass ionomer cement as a luting agent (Current notes No. 58).
Aust. Dent. J., 25:3, 185 (June) 1980.
- Beech, D.R. — Lecture presented to the Aust. Dent. Assoc., Sydney, 1981.
- Beheshti, N. — Fabricating a post and core to fit an existing crown.
J. Prosthet. Dent., 42:2, 236-239 (Aug.) 1979.

- Behrend, D. — Lecture presented to the Aust. Soc. Endod. (N.S.W. Branch), Sydney, 1980.
- Behrend, D. — Lecture presented at the University of Sydney, Sydney, 1981.
- Bender, I.B., Seltzer, S., and Soltanoff, W. — Endodontic success - a reappraisal of criteria.
Part 1: Oral Surg., 22:6, 780-789 (Dec.) 1966.
Part 2: Oral Surg., 22:6, 790-802 (Dec.) 1966.
- Black, G.V. — A method of grafting artificial crowns on the roots of teeth.
Mo. Dent. J., 1:233-236, 1869.
- Black, G.V. — Operative Dentistry, Vol. 1, 8th ed., Illinois, R.E. Blackwell Medical Publishing Co., 1948.
- Blair, H.A. — The role of endodontics in restorative dentistry.
Dent. Clin. North Am., 15:3, 619-626 (July) 1971.
- Bourgeois, R.S., and Lemon, R.R. — Dowel space preparation and apical leakage.
J. Endod., 7:2, 66-69 (Feb.) 1981.
- Bowen, R.L. — News from the United States.
Aust. Dent. J., 27:4, 263 (Aug.) 1982.
- Bower, R.C., and Henry, P.J. — Periodontal considerations in the restoration of non-vital teeth.
Aust. Dent. J., 21:6, 527-531 (Dec.) 1976.
- Boyde, A., and Lester, K.S. — Scanning electron microscopy of self-threading pins in dentine.
Operative Dent., 4:2, 56-62 (Spring) 1979.
- Brännström, M., and Nyborg, H. — The presence of bacteria in cavities filled with silicate cement and composite resin materials.
Sven. Tandlak Tidskr, 64:149-155 (Mar.) 1971.
- Brännström, M., and Nyborg, H. — Pulpal reaction to composite resin restorations.
J. Prosthet. Dent., 27:181-189 (Feb.) 1972.
- Bravin, R.V. — A functional stress analysis of post reinforcement.
J. Calif. Dent. Assoc., 66-71 (Dec.) 1976.

- Brown, D.R., Barkmeier, W.W., and Anderson, R.W. — Restoration of endodontically treated posterior teeth with amalgam.
J. Prosthet. Dent., 41:1, 40-44 (Jan.) 1979.
- Brunell, G. — Clinical and technical aspects of dowel and core retention.
in Proceedings of the Second International Prosthodontic Congress, Edit. W. Lefkowitz, St. Louis, C.V. Mosby Co., 1979, 146-148.
- Bryant, R.W. — Lecture presented to the Aust. Dent. Assoc. Congress, 1978.
- Bryant, R.W. — The strength of fifteen amalgam alloys.
Aust. Dent. J., 24:4, 244-252 (Aug.) 1979.
- Bryant, R.W. — Notes on composite resin restorative materials,
University of Sydney, 1980.
- Bryant, R.W. — Personal communication, 1982.
- Bryant, R.W., and Wing, G. — Bases for gold inlays and crown restorations.
Aust. Dent. J., 20:6, 392-396 (Dec.) 1975.
- Burnell, S.G. — Improved cast dowel base for restoring endodontically treated teeth.
J. Am. Dent. Assoc., 68:1, 39-45 (Jan.) 1964.
- Burns, B.B. — Letter to editor — post systems.
Aust. Dent. J., 22:3, 216 (June) 1977.
- Caputo, A.A., Standlee, J.P., and Collard, E.W. — The mechanics of load transfer by retentive pins.
J. Prosthet. Dent., 29:4, 442-449 (Apr.) 1973.
- Caputo, A.A., and Standlee, J.P. — Pins and posts - why, when and how.
Dent. Clin. North Am., 20:2, 299-311 (Apr.) 1976.
- Carter, R. — Electrolyte action in the presence of gold crowns placed over amalgam restorations.
Aust. Dent. J., 10:4, 317-319 (Aug.) 1965.
- Caruso, J.L., Morganelli, J.C., Sawyer, H.F., and Young, A.T. — Coronal-radicular stabilization of endodontically treated teeth for restorative dentistry.
in Theory and Practice of Fixed Prosthodontics, 7th ed., Edit. S.D. Tylman and W.F.P. Malone, St. Louis, C.V. Mosby Co., 1978 (Chapter 21).

- Cecconi, B.T., and Asgar, K. — Pins in amalgam: a study of reinforcement.
I.A.D.R. paper 120, 1968.
- Cendres & Métaux — Manufacturer's product information, 1978.
- Chan, K.C., Chalkley, Y., and Reinhardt, J.W. — Leakage between retentive pins and restorations.
J. Prosthet. Dent., 44:3, 270-272 (Sept.) 1980.
- Chan, K.C., Denehy, G.E., and Ivey, D.M. — Effect of various retention pin insertion techniques on dentinal crazing.
J. Dent. Res., 53:4, 941 (July-Aug.) 1974.
- Chan, K.C., Fuller, J.L., and Khowassah, M.A. — The adaptation of new amalgam and composite resins to pins.
J. Prosthet. Dent., 38:4, 392-395 (Oct.) 1977.
- Chan, R.W., and Bryant, R.W. — Post-core foundations for endodontically treated posterior teeth.
J. Prosthet. Dent., 48:4, 401-406 (Oct.) 1982.
- Chapple, J.A. — Restoring discoloured teeth to normal.
Dental Cosmos, 19:499 (Sept.) 1877.
- Charlton, G. — A prefabricated post and core for porcelain jacket crowns.
Br. Dent. J., 119:9, 452-456 (Nov.) 1965.
- Christensen, G.J. — Cementing media in restorative dentistry.
in Tylman's Theory and Practice of Fixed Prosthodontics, 7th ed., Edit. S.D. Tylman and W.F.P. Malone, St. Louis, C.V. Mosby Co., 1978 (Chapter 20).
- Christian, G.W., Button, G.L., Moon, P.C., England, M.C., and Douglas, H.B. — Post core restoration in endodontically treated posterior teeth.
J. Endod., 7:4, 182-185 (Apr.) 1981.
- Christy, J.M., and Pipko, D.J. — Fabrication of a dual-post veneer crown.
J. Am. Dent. Assoc., 75:6, 1419-1425 (Dec.) 1967.
- Clinical Research Associates — Clinical Research Associates Newsletter, 5:3 (Mar.) 1981.
- Cohen, S., and Parkins, F.M. — Bleaching tetracycline-stained vital teeth.
Oral Surg., 29:3, 465-471 (Mar.) 1970.

- Collard, E.W., Caputo, A.A., and Standlee, J.P. — Rationale for pin-retained amalgam restorations.
Dent. Clin. North Am., 14:1, 43-51 (Jan.) 1970.
- Colley, I.T., Hampson, E.L., and Lehman, M.L. — Retention of post crowns.
Br. Dent. J., 124:11, 63-69 (Jan.) 1968.
- Colman, H.L. — Restoration of endodontically treated teeth.
Dent. Clin. North Am., 23:4, 647-662 (Oct.) 1979.
- Cooke, M.S., and Scheer, B. — Extrusion of fractured teeth.
Br. Dent. J., 149:2, 50-53 (July) 1980.
- Courtade, G.L. — Creating your own "dentine".
Dent. Clin. North Am., 7:4, 805-822 (Nov.) 1963.
- Courtade, G.L. — Pin Pointers II - venting and cross pinning.
J. Prosthet. Dent., 16:5, 978-980 (Sept.-Oct.) 1966.
- Courtade, G.L., and Timmermans, J.J. — Pins in Restorative Dentistry.
St. Louis, C.V. Mosby Co., 1971.
- Craig, R.G., and Peyton, F.A. — Restorative Dental Materials, 5th ed.,
St. Louis, C.V. Mosby Co., 1975.
- Crocker, P.C. — Lecture presented to the Sydney Study Group, Sydney, 1981.
- Crocker, P.C. — Personal communication, 1982.
- Crum, R.J. — Tooth-supported prostheses (overdentures).
in Tylman's Theory and Practice of Fixed Prosthodontics, 7th ed., Edit. S.D. Tylman and W.F.P. Malone, St. Louis, C.V. Mosby Co., 1978 (Chapter 23).
- Dadmanesh, J. — Endodontic access for metal veneered crowns for anterior teeth.
J. Prosthet. Dent., 31:3, 297-302 (Mar.) 1974.
- Dale, J.W., and Moser, J. — A clinical evaluation of semiprecious alloys for dowels and cores.
J. Prosthet. Dent., 38:2, 161-164 (Aug.) 1977,a.
- Dale, J.W., and Moser, J.B. — Semiprecious alloys for cast restorations - a preliminary report.
J. Prosthet. Dent., 38:6, 627-631 (Dec.) 1977,b.

- Dawson, P.E. — Pin-retained amalgam.
Dent. Clin. North Am., 14:1, 63-71 (Jan.) 1970.
- De Domenico, R.J. — Technique for the fabrication of a cast post and core with non-precious metal.
J. Am. Dent. Assoc., 94:6, 1139-1141 (June) 1977.
- Dérand, T. — Corrosion of screwposts.
Odont. Revy, 22:371-378, 1971.
- Dickey, D.M., el-Kafrawy, A.H., and Mitchell, D.F. — Clinical and microscopic pulp response to a composite restorative material.
J. Am. Dent. Assoc., 88:108-113 (Jan.) 1974.
- Dietz, V.H. — The bleaching of discoloured teeth.
Dent. Clin. North Am., (Nov.) 1957.
- Dilts, W.E., Podshadley, A., and Neiman, R. — Effects of pins on some physical characteristics of composite resins.
J. Am. Dent. Assoc., 87:3, 595-599 (Sept.) 1973.
- Dilts, W.E., Welk, D.A., Laswell, H.R., and George, L. — Crazeing of tooth structure associated with placement of pins for amalgam restorations.
J. Am. Dent. Assoc., 81:1, 387-391 (Aug.) 1970.
- Dilts, W.E., Welk, D.A., and Stovall, J. — Retentive properties of pin materials in pin-retained silver amalgam restorations.
J. Am. Dent. Assoc., 77:5, 1085-1089 (Nov.) 1968.
- Dimashkieh, M.R., Davies, E.H., and von Fraunhofer, J.A. — Measurement of the cement film thickness beneath full crown restorations.
Br. Dent. J., 137:281-284 (Oct.) 1974.
- Duperon, D.F., and Kasloff, Z. — The effects of three types of pins on the tensile strength of dental amalgam.
J. Can. Dent. Assoc. J., 39:2, 111-119 (Feb.) 1973.
- Durney, E.C., and Rosen, H. — Root fracture as a complication of post design and insertion: a laboratory study.
Operative Dent., 2:90-96, 1977.
- Eames, W.B., and Solly, M.J. — Five threaded pins compared for insertion and retention.
Operative Dent., 5:66-71, 1980.

- Eames, W.B., Strain, J.D., Weitman, R.T., and Williams, A.K. — Clinical comparison of composite amalgam and silicate restorations.
J. Am. Dent. Assoc., 89:5, 1111-1117 (Nov.) 1974.
- Ehrmann, E.H., and Feiglin, B. — The obturation of the entire root canal with a dowel crown.
J. Endod., 6:8, 696-701 (Aug.) 1980.
- Eissmann, H.F., and Radke, R.A. Jr. — Postendodontic Restoration.
in Pathways of the Pulp, Edit. S. Cohen and R.C. Burns, St. Louis, C.V. Mosby Co., 1976 (Chapter 20).
- Eliasson, S.T., and Hill, G.L. — Cavosurface design and marginal leakage of composite resin restorations.
Operative Dent., 2:2, 55-58 (Spring) 1977.
- Erickson, P.M., and Vande Voorde, H.E. — A combined post, core, and endodontic endosseous implant.
J. Endod., 1:9, 310-312 (Sept.) 1975.
- Eriksen, H.M., and Buonocore, M.G. — Marginal leakage with different composite restorative materials *in vitro* effect of cavity design.
J. Oral Rehabil., 3:4, 315-322 (Oct.) 1976.
- Federick, D.R. — An application of the dowel. A composite resin core technique.
J. Prosthet. Dent., 32:4, 420-424 (Oct.) 1974.
- Federick, D.R., and Serene, T.P. — Secondary intention dowel and core.
J. Prosthet. Dent., 34:1, 41-47 (July) 1975.
- Forsten, L., and Strömberg, K. — Early strength of composite resins.
Proc. Finn. Dent. Soc., 72:6, 196-198 (Dec.) 1976.
- Frank, A.L. — Protective coronal coverage of the pulpless tooth.
J. Am. Dent. Assoc., 59:5, 895-900 (Nov.) 1959.
- Frank, A.L. — Protective coronal coverage of the pulpless tooth.
in Endodontics, J.I. Ingle, 1st ed., Philadelphia, Lea & Febiger, 1965 (Chapter 17).
- Frank, A.L. — Improvement of the crown-root ratio by endodontic endosseous implants.
J. Am. Dent. Assoc., 74:3, 451-462 (Feb.) 1967.

- Frank, A.L. — Bleaching of vital and non-vital teeth.
in Pathways of the Pulp, Edit. S. Cohen and R.C. Burns, St. Louis, C.V. Mosby Co., 1976 (Chapter 19).
- Frank, A.L., Teel, S., and Wands, D. — Restoration of the pulpless tooth and preparation for the overdenture.
in Endodontics, 2nd ed., Edit. J.I. Ingle and E.E. Beveridge, Philadelphia, Lea & Febiger, 1976 (Chapter 18).
- Fujimoto, J., Norman, R.D., Dykema, R.W., and Phillips, R.W. — A comparison of pin-retained amalgam and composite resin cores.
 J. Prosthet. Dent., 39:5, 512-519 (May) 1978.
- Fusilier, C.N. — Cross-pinning for added retention.
 J. Prosthet. Dent., 31:4, 397-402 (Apr.) 1974.
- Garman, T.A., Binon, P.P., Averette, D., and Talman, R.G. — Self-threading pin penetration into dentine.
 J. Prosthet. Dent., 43:3, 298-302 (Mar.) 1980.
- Gentile, D. — Direct dowels for endodontically treated teeth.
 Dent. Dig., 71:500-501 (Nov.) 1965.
- Gerstein, H., and Burnell, S.C. — Prefabricated precision dowels.
 J. Am. Dent. Assoc., 68:6, 787-791 (June) 1964.
- Gilmore, H.W., and Lund, M.R. — Operative Dentistry, 2nd ed., St. Louis, C.V. Mosby Co., 1973.
- Gilmore, H.W., Lund, M.R., Bales, D.J., and Verneti, J. — Operative Dentistry, 3rd ed., St. Louis, C.V. Mosby Co., 1977.
- Going, R.E. — Pin-retained amalgam.
 J. Am. Dent. Assoc., 73:3, 619-624 (Sept.) 1966.
- Going, R.E., and Mitchem, J.C. — Cements for permanent luting: a summarizing review.
 J. Am. Dent. Assoc., 91:1, 107-117 (July) 1975.
- Going, R.E., Moffa, J.P., Nostrant, G.W., and Johnson, B.E. — The strength of dental amalgam as influenced by pins.
 J. Am. Dent. Assoc., 77:6, 1331-1334 (Dec.) 1968.
- Going, R.E., and Nostrant, G.W. — Early strength of dental amalgam as influenced by pins.
 J. Dent. Res., 48:489 (June) 1969.

- Goldstein, P.M. — Retention pins are friction-locked without use of cement.
J. Am. Dent. Assoc., 73:1103, 1966.
- Goslee, H.J. — Porcelain crowns.
Items of Interest (Prosthodontia), 161-172, 1903.
- Greener, E.H., Harcourt, J.K., and Lantenschlager, E.P. — Material Science in Dentistry, 1st ed., Baltimore, Williams & Wilkins Co., 1972.
- Greenwald, A.S. — Cast gold post and crown restoration.
Dent. Surv., 41:47-50 (Apr.) 1965.
- Grimaldi, J. — Measurement of the lateral deformation of the tooth crown under axial compressive cuspal loading.
Thesis, University of Otago, Dunedin, New Zealand, 1971.
- Grossman, L.I. — Endodontic Practice, 9th ed., Philadelphia, Lea & Febiger, 1978.
- Grossman, L.I., Shepard, L.I., and Pearson, L.A. — Roentgenologic and clinical evaluation of endodontically treated teeth.
Oral Surg., 17:3, 368-374 (Mar.) 1964.
- Grundy, J.R., and Glyn Jones, J.C. — Crowning pulpless teeth.
Part 1: Br. Dent. J., 150:307-312 (June) 1981.
Part 2: Br. Dent. J., 150:347-350 (June) 1981.
- Guerrero, L.P. — S.E.M. investigation of possible effects of self-threading pins on the dentine.
M.D.Sc. Thesis, University of Sydney, 1979.
- Gutmann, J.L. — Preparation of endodontically treated teeth to receive a post-core restoration.
J. Prosthet. Dent., 38:4, 413-419 (Oct.) 1977.
- Guzy, G.E., and Nicholls, J.I. — *In vitro* comparison of intact endodontically treated teeth with and without endo-post reinforcement.
J. Prosthet. Dent., 42:1, 39-44 (July) 1979.
- Hannah, C.M. — Prefabricated post and core patterns.
J. Prosthet. Dent., 30:1, 37-42 (July) 1973.
- Hanson, E.C., and Caputo, A.A. — Cementing mediums and retentive characteristics of dowels.
J. Prosthet. Dent., 32:5, 551-557 (Nov.) 1974.

- Harper, R.H., and Lund, M.R. — Treatment of the pulpless tooth during post and core construction.
Operative Dent., 1:2, 55-60, 1976.
- Harrington, G.W., and Natkin, E. — External resorption associated with bleaching of pulpless teeth.
J. Endod., 5:11, 344-348 (Nov.) 1979.
- Harty, F.J., and Leggett, L.J. — A post-crown technique using a nickel-cobalt-chromium post.
Br. Dent. J., 132:10, 394-399 (May) 1972.
- Harty, F.J., Parkins, B.J., and Wengraf, A.M. — Success rate in root canal therapy.
Br. Dent. J., 128:2, 65-70 (Jan.) 1970.
- Healey, H.J. — Restoration of the effectively treated pulpless tooth.
J. Prosthet. Dent., 4:6, 842-849 (Nov.) 1954.
- Healey, H.J. — Coronal restoration of the treated pulpless tooth.
Dent. Clin. North Am., 1:3, 885-896 (Nov.) 1957.
- Heithersay, G.S. — Combined endodontic-orthodontic treatment of transverse root fractures in the region of the alveolar crest.
Oral Surg., 36:3, 404-415 (Sept.) 1973.
- Helper, A.R., and Melnick, S., and Schilder, H. — Determination of moisture content of vital and pulpless teeth.
Oral Surg., 34:4, 661-669 (Oct.) 1972.
- Henry, P.J. — Photoelastic analysis of post core restorations.
Aust. Dent. J., 22:3, 157-159 (June) 1977.
- Henry, P.J. — Lecture presented at the Australian Dental Congress, Perth, 1982.
- Henry, P.J., and Bower, R.C. — Post core systems in crown and bridgework.
Aust. Dent. J., 22:1, 46-52 (Feb.) 1977,a.
- Henry, P.J., and Bower, R.C. — Secondary intention post and core.
Aust. Dent. J., 22:2, 123-131 (Apr.) 1977,b.
- Herschman, J.B., and Weine, F.S. — Endodontic Therapy, Edit. F.S. Weine, St. Louis, C.V. Mosby Co., 1972.

- Herschman, J.B., Weine, F.S., and Strauss, S. — Restoration of the endodontically treated tooth.
in Endodontic Therapy, 2nd ed., Edit. F.S. Weine, St. Louis, C.V. Mosby Co., 1976 (Chapter 15).
- Heuer, M.A. — Instruments and Materials.
in Pathways of the Pulp, Edit. S. Cohen and R.C. Burns, St. Louis, C.V. Mosby Co., 1976.
- Hicks, S.M. — Lecture presented at the University of Sydney, Sydney, 1978.
- Hirschfeld, Z., and Stern, N. — Post and core - the biomechanical aspect.
Aust. Dent. J., 17:6, 467-468 (Dec.) 1972.
- Hormati, A.A., and Chan, K.C. — Marginal leakage of compacted gold, composite resin, and high-copper amalgam restorations.
J. Prosthet. Dent., 44:4, 418-422 (Oct.) 1980.
- Hormati, A.A., and Denehy, G.E. — Microleakage of pin-retained amalgam and composite resin bases.
J. Prosthet. Dent., 44:5, 526-530 (Nov.) 1980.
- Hormati, A.A., and Denehy, G.E. — Retention of cast crowns cemented to amalgam and composite resin cores.
J. Prosthet. Dent., 45:5, 525-528 (May) 1981.
- Hotz, P., McLean, J.W., Sced, I., and Wilson, A.D. — unpublished report, 1976.
- Howell, R.A. — The prognosis of bleached root-filled teeth.
Int. Endod. J., 14:22-26, 1981.
- Ingber, J.S. — Forced eruption: Part 1. A method of treating isolated one and two wall infrabony osseous defects - rationale and case report.
J. Periodontol., 45:4, 199-206 (Apr.) 1974.
- Ingber, J.S. — Forced eruption: Part 2. A method of treating non-restorable teeth - periodontal and restorative considerations.
J. Periodontol., 47:4, 203-216 (Apr.) 1976.
- Ingber, J.S., Rose, L.F., and Coslet, J.G. — The biological width - a concept in periodontics and restorative dentistry.
Alpha Omegan, 10:62-65 (Dec.) 1977.

- Ingle, J.I. — Endodontics, 1st ed., Philadelphia, Lea & Febiger, 1965.
- Ingle, J.I. — Letter to the editor.
The Washington Post, Jan. 4, 1976.
- Ingle, J.I., and Beveridge, E.E. — Endodontics, 2nd ed., Philadelphia, Lea & Febiger, 1976.
- Janis, J.N., and Lugassy, A.A. — Pin-retained composite resin buildup for extensively broken-down vital teeth.
J. Am. Dent. Assoc., 85:2, 346-350 (Aug.) 1972.
- Johns, R.B. — Intra-coronal pins.
Br. Dent. J., 127:12, 580-582 (Dec.) 1969.
- Johnson, J.K., and Sakumura, J.S. — Dowel form and tensile force.
J. Prosthet. Dent., 40:6, 645-649 (Dec.) 1978.
- Johnson, J.K., Schwartz, N.L., and Blackwell, R.T. — Evaluation and restoration of endodontically treated posterior teeth.
J. Am. Dent. Assoc., 93:3, 597-605 (Sept.) 1976.
- Jokinen, M.A., Kotilainen, R., Poikkeus, P., Poikkeus, R., and Sarkki, L. — Clinical and radiographic study of pulpectomy and root canal therapy.
Scand. J. Dent. Res., 86:5, 366-373, 1978.
- Jørgensen, K.D. — The relationship between retention and convergence angle in cemented veneer crowns.
Acta Odont. Scand., 13:35-40, 1955.
- Jørgensen, K.D. — Factors affecting the film thickness of zinc phosphate cements.
Acta Odontol. Scand., 18:479 (Dec.) 1960.
- Judy, K.W.M., and Weiss, C.M. — Improved technique of endodontic stabilization - biofunctional considerations.
Oral Health, 65:4, 36-44 (Apr.) 1975.
- Kafalias, M.C. — Abutment preparation in crown and bridgework.
Aust. Dent. J., 14:1, 1-7 (Feb.) 1969.
- Kafalias, M.C. — The non-vital tooth as an abutment.
Austral. Soc. Prosthodontists Bulletin, 5:2, 38-40 (Dec.) 1975.

- Kantor, M.E., and Pines, M.S. — A comparative study of restorative techniques for pulpless teeth.
J. Prosthet. Dent., 38:4, 405-412 (Oct.) 1977.
- Kantorowicz, G.F. — Inlays, crowns and bridges, 2nd ed., Baltimore, Williams & Wilkins Co., 1970 (Chapter 7).
- Kayser, A.F. — Prosthodontic aspects of endodontics.
J. Prosthet. Dent., 21:6, 645-649 (June) 1969.
- Khan, H., Fishman, J., and Malone, W.F. — A simplified method for constructing a core following endodontic treatment.
J. Prosthet. Dent., 37:1, 32-36 (Jan.) 1977.
- Khera, S.C., Chan, K.C., and Rittman, B.J. — Dentinal crazing and interpip distance.
J. Prosthet. Dent., 40:5, 538-543 (Nov.) 1978.
- Kronfeld, M. — Mouth Rehabilitation, Vol. 1, St. Louis, C.V. Mosby Co., 1967.
- Krupp, J.D., Trabert, K.C., and Standlee, J.P. — Dowel retention with glass ionomer cement.
J. Prosthet. Dent., 41:2, 163-166 (Feb.) 1979.
- Kurer, H.G., Combe, E.C., and Grant, A.A. — Factors influencing the retention of dowels.
J. Prosthet. Dent., 38:5, 515-525 (Nov.) 1977.
- Kurer, P.K. — Retention of post crowns - a solution of the problem.
Br. Dent. J., 123:4, 167-169 (Aug.) 1967.
- Land, C.H. — Porcelain dental art.
Dental Cosmos, 45:6, 437-444 (June) 1903.
- Landwerlen, J.R., and Berry, H.H. — The composite resin post and core.
J. Prosthet. Dent., 28:5, 500-503 (Nov.) 1972.
- Larson, T.D., and Jensen, J.R. — Microleakage of composite resin and amalgam core material under complete cast crowns.
J. Prosthet. Dent., 44:1, 40-44 (July) 1980.
- Lau, V.M.S. — The reinforcement of endodontically treated teeth.
Dent. Clin. North Am., 20:2, 313-328 (Apr.) 1976.
- Lee, H.L. Jr. — Adhesion between living tissue and plastics. I. Adhesion of epoxy and polyurethane resins to dentine and enamel.
J. Biomed. Mat. Res., 3:349-367 (June) 1969.

- Lee, H.L. Jr., and Swartz, M.L. — Scanning electron microscope study of composite restorative materials.
J. Dent. Res., 49:149-158 (Jan.-Feb.) 1970.
- Lee, H.L. Jr., Swartz, M.L., and Smith, F.F. — Physical properties of four thermosetting dental restorative resins.
J. Dent. Res., 48:526-535 (July-Aug.) 1969.
- Leggett, L.J. — Restoration of non-vital posterior teeth.
J. Br. Endod. Soc., 12:2, 73-82 (July) 1979.
- Leinfelder, K.F., Sluder, T.B., Santos, J.F.F., and Wall, J.T. — Five year clinical evaluation of anterior and posterior restorations of composite resin.
Operative Dent., 5:57-65, 1980.
- Leinfelder, K.F., Sluder, T.B., Sockwell, C.L., Strickland, W.D., and Wall, J.T. — Clinical evaluation of composite resins as anterior and posterior restorative materials.
J. Prosthet. Dent., 36:4, 407-416 (Apr.) 1975.
- Lester, K.S. - Lecture presented to the Sydney Study Group, Sydney, 1981.
- Levin, H.J. — Access cavities.
Dent. Clin. North Am., 11:4, 701-710 (Nov.) 1967.
- Lindén, L.A. — Microscopic observations of fluid flow through cementum and dentine.
An *in vitro* study on human teeth.
Odont. Revy, 19:367-381, 1968.
- Lister, A.E.A. — A post crown for molars with divergent roots.
Br. Dent. J., 133:4, 161 (Aug.) 1972.
- Locke, J. — Protection of endodontically treated teeth.
Aust. Endod. Newsletter, 4:2-5 (Feb.) 1977.
- Lord, J.L., and Teel, S. — The overdenture: patient selection, use of copings, and follow-up evaluation.
J. Prosthet. Dent., 32:41-51 (July) 1974.
- Lorey, R.E. — Abutment considerations.
Dent. Clin. North Am., 24:1, 63-79 (Jan.) 1980.

- Lovdahl, P.E., and Nicholls, J.I. — Pin-retained amalgam cores versus cast-gold dowel cores.
 J. Prosthet. Dent., 38:5, 507-514 (Nov.) 1977.
- Lugassy, A.A., Moffa, J.P., and Hozumi, Y. — Influence of pins upon some physical properties of composite resins.
 J. Prosthet. Dent., 28:6, 613-619 (Dec.) 1972.
- Luks, S. — Gutta percha versus silver points in the practice of endodontics.
 N.Y. State Dent. J., 31:8, 341-350 (Oct.) 1965.
- Luscher, B., Lutz, F., Ochsenein, H., and Muhleman, H.R. — Microleakage and marginal adaptation of composite resin restorations.
 J. Prosthet. Dent., 39:4, 409-413 (Apr.) 1978.
- Mahler, D.B. — An analysis of stresses in a dental amalgam restoration.
 J. Dent. Res., 37:516, 1958.
- Mahler, D.B., and Mitchem, J.C. — Transverse strength of amalgam.
 J. Dent. Res., 43:1, 121-130 (Jan.-Feb.) 1964.
- Malcolm, P. — Cast restoration and cusp flexibility.
 Thesis, University of Otago, Dunedin, New Zealand, 1973.
- Malone, W.F.P. — Editor's comment.
 J. Prosthet. Dent., 48:4 (Oct.) 1982.
- Malone, W.F.P., Mazur, B., Tylman, S.D., and Sawyer, H.F. — Biomechanical considerations of tooth preparation for fixed prosthodontics.
in Tylman's Theory and Practice of Fixed Prosthodontics, 7th ed., Edit. S.D. Tylman and W.F.P. Malone, St. Louis, C.V. Mosby Co., 1978 (Chapter 5).
- Mannerberg, F. — Isosit, a new material for restoration of anterior teeth.
 Quintessence Int., 8:1-10 (Aug.) 1977.
- Markley, M.R. — Pin reinforcement and retention of amalgam foundations and restorations.
 J. Am. Dent. Assoc., 56:5, 675-679 (May) 1958.
- Markley, M.R. — Pin-retained and pin-reinforced amalgam.
 J. Am. Dent. Assoc., 73:6, 1295-1300 (Dec.) 1966.

- Martin, A.P. — Amalgam substructure for crowning of fractured anterior teeth.
Aust. Dent. J., 11:4, 233-235 (Aug.) 1966.
- Martin, F.E. — Marginal leakage and adaptation of composite resin restorations.
M.D.S. Thesis, University of Sydney, 1980.
- Massler, M. — Biologic aspects of crown and bridge prosthodontics.
in Tylman's Theory and Practice of Fixed Prosthodontics, Edit. S.D. Tylman and
W.F.P. Malone, St. Louis, C.V. Mosby Co., 1978 (Chapter 2).
- McKerracher, P.W. — Ratinal restoration of endodontically treated teeth. I. Principles,
techniques and materials.
Aust. Dent. J., 26:4, 205-208 (Aug.) 1981,a.
II. Preparations for crowns.
Aust. Dent. J., 26:5, 282-286 (Oct.) 1981,b.
- McLean, J.W., and Wilson, A.D. — The clinical development of the glass-ionomer cements.
I. Formulations and properties.
Aust. Dent. J., 22:1, 31-36 (Feb.) 1977,a.
The clinical development of the glass-ionomer cement. II. Some clinical applications.
Aust. Dent. J., 22:2, 120-127 (Apr.) 1977,b.
The clinical development of the glass-ionomer cement. III. The erosion lesion.
Aust. Dent. J., 22:3, 190-195 (June) 1977,c.
- McPhee, E.R. — Pin-retained composite resin cores for posterior teeth.
J. Prosthet. Dent., 31:5, 566-569 (May) 1974.
- McSpadden, J.T. — Presentation at the Am. Assoc. Endod. Meeting, Atlanta, 1979.
- Messing, J.J., and Wills, D.J. — Investigation of resistance to stress of screw-
threaded crown posts.
J. Prosthet. Dent., 30:3, 278-282 (Sep.) 1973.
- Metrick, L. — Root canal obliteration with a post crown. Case report.
Can. Dent. Assoc. J., 27:9, 585-586, 1961.
- Michnick, B.T., and Raskin, R.B. — A multiple post-core technique.
J. Prosthet. Dent., 39:6, 622-626 (June) 1978.
- Milas, V.B. — History.
in Pathways of the Pulp, Edit. S. Cohen and R.C. Burns, St. Louis, C.V. Mosby
Co., 1976 (Chapter 23).

- Moffa, J.P. — Rationale for the use of pins based on research.
in Pins in Restorative Dentistry, Edit. G.L. Courtade and J.J. Timmermans,
 St. Louis, C.V. Mosby Co., 1971 (Chapter 2).
- Moffa, J.P. — Alternatives to Gold Alloys in Dentistry (Conference proceedings),
 Edit. T.M. Valega, U.S. Department of Health, Education and Welfare,
 Maryland (Jan.) 1977.
- Moffa, J.P., and Phillips, R.W. — Retentive properties of parallel pin restorations.
 J. Prosthet. Dent., 17:4, 387-400 (Apr.) 1967.
- Moffa, J.P., and Razzano, M.R. — unpublished data.
from Moffa, J.P., Rationale for the use of pins based on research
in Pins in Restorative Dentistry, Edit. G.L. Courtade and J.J. Timmermans,
 St. Louis, C.V. Mosby Co., 1971 (Chapter 2).
- Moffa, J.P., Razzano, M.R., and Doyle, M.G. — Pins - a comparison of their retentive
 properties.
 J. Am. Dent. Assoc., 78:3, 529-535 (Mar.) 1969.
- Moffa, J.P., Razzano, M.R., and Folio, J. — Influence of cavity varnish on microleakage
 and retention of various pin-retaining devices.
 J. Prosthet. Dent., 20:6, 541-551 (Dec.) 1968.
- Moll, P.J.F., Howe, D.F., and Svare, C.W. — Cast gold post and core and pin-retained
 composite resin bases: a comparative study in strength.
 J. Prosthet. Dent., 40:5, 642-644 (Dec.) 1978.
- Morse, D.R. — Clinical Endodontology, Illinois, Charles C. Thomas, 1974.
- Myers, G.E. — Status report on zinc oxide-eugenol and modified cements.
 J. Am. Dent. Assoc., 76:1053 (May) 1968.
- Nayyar, A., Walton, R.E., and Leonard, L.A. — An amalgam coronal-radicular dowel and
 core technique for endodontically treated posterior teeth.
 J. Prosthet. Dent., 43:5, 511-515 (May) 1980.
- Neagley, R.L. — The effect of dowel preparation on the apical seal of endodontically
 treated teeth.
 Oral Surg., 28:5, 739-745 (Nov.) 1969.
- Newburg, R.E., and Pameijer, C.H. — Retentive properties of post and core systems.
 J. Prosthet. Dent., 36:6, 636-643 (Dec.) 1976.

- Nguyen, N.T. — Obturation of the root canal system.
in Pathways of the Pulp, Edit. S. Cohen and R.C. Burns, St. Louis, C.V. Mosby Co., 1976 (Chapter 7).
- Nicholls, E. — The restoration of root-filled teeth.
Dent. Pract. Dent. Rec., 13:11, 459-469 (July) 1963.
- Nicholls, E. — Endodontics, 2nd ed., Bristol, John Wright & Sons Ltd., 1977.
- Nitkin, D.A., and Asgar, K. — Evaluation of alternative alloys to type III gold for use in fixed prosthodontics.
J. Am. Dent. Assoc., 93:3, 622-629 (Sept.) 1976.
- Norman, R.D., Swartz, M.L., and Phillips, R.W. — Studies on film thickness, solubility, and marginal leakage of dental cements.
J. Dent. Res., 42:950, 1963.
- Nutting, E.B., and Poe, G.S. — Chemical bleaching of discoloured endodontically treated teeth.
Dent. Clin. North Am., 11:4, 655-662 (Nov.) 1967.
- O'Leary, T.J., Standish, S.M., and Bloomer, R.S. — Severe periodontal destruction following impression procedures.
J. Periodontol., 44:1, 43-48 (Jan.) 1973.
- Orlay, H. — Splinting with endodontic implant stabilizers.
Dent. Prac. Dent. Rec., 14:481, 1964.
- Osborne, J.W., Gale, E.N., and Ferguson, G.W. — One year and two year clinical evaluation of a composite resin versus amalgam.
J. Prosthet. Dent., 30:5, 795-800 (Nov.) 1973.
- Palomo, F., and Kopczyk, R.A. — Rationale and methods for crown lengthening.
J. Am. Dent. Assoc., 96:2, 257-260 (Feb.) 1978.
- Pameijer, C.H., and Stallard, R.E. — Effect of self-threading pins.
J. Am. Dent. Assoc., 85:4, 895-899 (Oct.) 1972.
- Parvinen, T., Yli-Urpo, A., and Aitasalo, K. — Corrosion of a dental alloy in the mouth - a case report.
Proc. Finn. Dent. Soc., 72:6, 210-212 (Dec.) 1976.
- Pearson, H.H. — Bleaching of the discoloured pulpless tooth.
J. Am. Dent. Assoc., 56:1, 64-68 (Jan.) 1958.

- Pennick, E.C. — Periapical repair by dense fibrous connective tissue following conservative endodontic therapy.
Oral Surg., 14:2, 239-242 (Feb.) 1961.
- Penny, R.E., and Kraal, J.H. — Crown-to-root ratio: its significance in restorative dentistry.
J. Prosthet. Dent., 42:1, 34-38 (July) 1979.
- Pere1, M.L., and Muroff, F.I. — Clinical criteria for posts and cores.
J. Prosthet. Dent., 28:4, 405-411 (Oct.) 1972.
- Peterson, K.B. — Longitudinal root fracture due to corrosion of an endodontic post.
Can. Dent. Assoc. J., 37:1, 66-68 (Jan.) 1971.
- Phillips, R.W. — Skinner's Science of Dental Materials, 7th ed., Philadelphia, W.B. Saunders Co., 1973.
- Phillips, R.W. — Alternatives to Gold Alloys in Dentistry (Conference proceedings), Edit. T.M. Valéga, U.S. Department of Health, Education and Welfare, Maryland, (Jan.) 1977.
- Phillips, R.W. — Skinner's Science of Dental Materials, 8th ed., Philadelphia, W.B. Saunders Co., 1982.
- Phillips, R.W., Avery, D.R., Mehra, R., Swartz, M.L., and McCune, R.J. — Observations on a composite resin for class II restorations: 3-year report.
J. Prosthet. Dent., 30:6, 891-897 (Dec.) 1973.
- Phillips, R.W., Swartz, M.L., and Norman, R.D. — Zinc oxide and eugenol cements for permanent cementation.
J. Prosthet. Dent., 19:144-150 (Feb.) 1968.
- Pickard, H.M. — Variants of the post crown.
Br. Dent. J., 117:12, 517-526 (Dec.) 1964.
- Pinkley, V.A., and Morris, D.R. — Use of nonprecious metal for cast dowel and core.
J. Prosthet. Dent., 32:1, 78-79, 1974.
- Price, C., and Whitehead, F.I.H. — Impression materials as foreign bodies.
Br. Dent. J., 133:1, 9-14 (July) 1972.
- Reuter, J.E. — One appointment amalgam core and crown preparation.
Br. Dent. J., 146:6, 213-214 (Sept.) 1977.

- Richardson, J.T., and Padgett, J.G. — Repair technique for a fractured, crowned anterior tooth.
J. Prosthet. Dent., 31:4, 409-410 (Apr.) 1974.
- Rodriguez, M.S., and Dickson, G. — Some tensile properties of amalgam.
J. Dent. Res., 41:840, 1962.
- Rose, L.A. — Composite build-up offers advantages in crown procedures.
Dent. Surv., 49:50-51 (Feb.) 1973.
- Rosen, H. — Operative procedures on mutilated endodontically treated teeth.
J. Prosthet. Dent., 11:5, 973-986 (Sept.-Oct.) 1961.
- Rosen, I.S. — The protection and reinforcement of devitalized teeth.
N.Y. J. Dent., 34:3, 99-100 (Mar.) 1964.
- Rosenberg, P.A., and Antonoff, S.J. — Gold posts - common problems in preparation and technique for fabrication.
N.Y. State Dent. J., 37:10, 601-606 (Dec.) 1971.
- Ross, I.F. — Fracture susceptibility of endodontically treated teeth.
J. Endod., 6:5, 560-565 (May) 1980.
- Roush, J.W. — The Silicates: with a reference to zinc phosphate cements.
J. Am. Dent. Assoc., 28:9, 1421-1426 (Sept.) 1941.
- Rud, J., and Omnell, K.A. — Root fractures due to corrosion - diagnostic aspects.
Scand. J. Dent. Res., 78:397-403, 1970.
- Ruemping, D.R., Lund, M.R., and Schnell, R.J. — Retention of dowels subjected to tensile and torsional forces.
J. Prosthet. Dent., 41:2, 159-162 (Feb.) 1979.
- Samani, S.I.A., and Harris, W.T. — A procedure for repairing fractured post-core restorations.
J. Prosthet. Dent., 39:6, 627-631 (June) 1978.
- Sandrik, J.L., and Sawyer, H.F. — Impression materials for cast metal restorative procedures.
in Tylman's Theory and Practice of Fixed Prosthodontics, 7th ed., Edit. S.D. Tylman and W.F.P. Malone, St. Louis, C.V. Mosby, 1978 (Chapter 8).
- Sapone, J. — Endodontic abutment prosthesis.
J. Prosthet. Dent., 29:2, 210-216 (Feb.) 1973.

- Sapone, J. — Orthodontic-endodontic treatment.
in Pathways of the Pulp, Edit. S. Cohen and R.C. Burns, St. Louis, C.V. Mosby Co., 1976 (Chapter 18).
- Scharwatt, B.R. — The general practitioner and the endodontist.
Dent. Clin. North Am., 23:4, 747-766 (Oct.) 1979.
- Schilder, H. — Filling root canals in three dimensions.
Dent. Clin. North Am., 11:4, 723-744 (Nov.) 1967.
- Schilder, H. — Future.
in Pathways of the Pulp, Edit. S. Cohen and R.C. Burns, St. Louis, C.V. Mosby Co., 1976 (Chapter 24).
- Schmidt, D., and Lutz, F. — Use of composite materials in core restorations.
Schweiz Monatsschr Zahnheilk, 87:705-711 (Aug.) 1977.
- Schnell, F.J. — Effect of immediate dowel space preparation on the apical seal of endodontically filled teeth.
Oral Surg., 43:3, 470-474 (Mar.) 1978.
- Scully, B.R. — The tapered dowel pin as a post and core.
J. Prosthet. Dent., 27:3, 289-291 (Mar.) 1972.
- Seltzer, S., and Bender, I.B. — The Dental Pulp, 2nd ed., Philadelphia, J.B. Lippincott Co., 1975.
- Seltzer, S., Bender, I.B., Smith, J., Freedman, I., and Nazimor, H. — Endodontic failures - an analysis based on clinical, roentgenographic, and histologic findings. Parts 1 and 2.
Oral Surg., 23:4, 500-530 (Apr.) 1967.
- Shadman, H., and Azarmehr, P. — A direct technique for fabrication of posts and cores.
J. Prosthet. Dent., 34:4, 463-466 (Oct.) 1975.
- Sheets, C.E. — Dowel and core foundations.
J. Prosthet. Dent., 23:1, 58-65 (Jan.) 1970.
- Shillingburg, H.T., Fisher, D.W., and Dewhurst, R.B. — Restoration of endodontically treated posterior teeth.
J. Prosthet. Dent., 24:4, 401-409 (Oct.) 1970.
- Shiloah, J. — Clinical crown lengthening by vertical root movement.
J. Prosthet. Dent., 45:6, 602-605 (June) 1981.

- Shirdel, K., Azarmehr, P., and Raoufi, M. — Construction of a post and core to fit a completed restoration.
J. Prosthet. Dent., 38:2, 229-231 (Aug.) 1977.
- Shooshan, E.D. — A pin ledge casting technique - its application in periodontal splinting.
Dent. Clin. North Am., 189 (Mar.) 1960.
- Sickelmore, F.A. — Post crowns - some weaknesses.
Br. Dent. J., 10:7, 306-308 (Nov.) 1959.
- Silverstein, W.H. — The reinforcement of weakened pulpless teeth.
J. Prosthet. Dent., 14:2, 372-381 (Mar.-Apr.) 1964.
- Simon, J.H.S. — Periodontal-Endodontic Treatment.
in Pathways of the Pulp, Edit. S. Cohen and R.C. Burns, St. Louis, C.V. Mosby Co., 1976 (Chapter 15).
- Simonsen, T.L., Nilsen, G.N., and Hals, E. — A follow-up study of post or pin-retained amalgam fillings with special reference to possible corrosion.
Scand. J. Dent. Res., 81:415-424, 1973.
- Skurnik, H. — Rehabilitation rationale for pulpless teeth.
J. Prosthet. Dent., 15:3, 528-542 (May) 1965.
- Smith, D.C. — A new dental cement.
Br. Dent. J., 125:381 (Nov.) 1968.
- Smith, D.C. — Dental cements.
Dent. Clin. North Am., 15:3 (Jan.) 1971.
- Sommer, R.F., Ostrander, F.D., Crowley, M.C. — Clinical Endodontics, 3rd ed., Philadelphia, W.B. Saunders Co., 1966.
- Spalten, R.G. — Composite resins to restore mutilated teeth.
J. Prosthet. Dent., 25:3, 323-326 (Mar.) 1971.
- Spanauf, A.J. — Dowel and core foundations using the composite Adaptic.
Quintessence Int., 3:9, 45-47 (Sept.) 1972.
- Spasser, H.F. — A simple bleaching technique using sodium perborate.
N.Y. J. Dent., 27:332, 1961.
- Spasser, H.F. — Proper protection and restoration of endodontically treated teeth.
N.Y. State Dent. J., 29:6, 247-252 (June) 1963.

- Stahl, G.J., and O'Neal, R.B. — The composite resin dowel and core.
J. Prosthet. Dent., 33:6, 642-648 (June) 1975.
- Standford, J.W., Weigel, K.V., Paffenbarger, G., and Sweeney, W.T. — Compressive properties of hard tooth tissues and some restorative materials.
J. Am. Dent. Assoc., 60:6, 746-756 (June) 1960.
- Standlee, J.P., Caputo, A.A., Collard, E.W., and Pollack, M.H. — Analysis of stress distribution by endodontic posts.
Oral Surg., 23:6, 952-960 (June) 1972.
- Standlee, J.P., Caputo, A.A., and Hanson, E.C. — Retention of endodontic dowels: effects of cement, dowel length, diameter, and design.
J. Prosthet. Dent., 39:4, 401-405 (Apr.) 1978.
- Standlee, J.P., Caputo, A.A., Holcomb, J., and Trabert, K.C. — The retentive and stress-distributing properties of a threaded endodontic dowel.
J. Prosthet. Dent., 44:4, 398-404 (Oct.) 1980.
- Standlee, J.P., Collard, E.W., and Caputo, A.A. — Evaluation of factors in pin retention utilizing photoelastic techniques.
Presented at I.A.D.R. 47th General Meeting, Houston, Texas, U.S.A. (Mar.) 1969.
- Standlee, J.P., Collard, E.W., and Caputo, A.A. — Dentinal defects caused by some twist drills and retentive pins.
J. Prosthet. Dent., 24:2, 185-192 (Aug.) 1970.
- Steele, G.D. — Reinforced composite resin foundations for endodontically treated teeth.
J. Prosthet. Dent., 30:5, 816-819 (Nov.) 1973.
- Stern, N., and Becker, A. — Forced eruption: biological and clinical considerations.
J. Oral Rehabil., 7:395-402, 1980.
- Stern, N., and Kochavi, D. — Immediate restoration of an endodontically treated tooth by means of a screw-post and composite materials.
Gen. Dent., 25:26-28 (Feb.) 1977.
- Stewart, G.G. — Bleaching discoloured pulpless teeth.
J. Am. Dent. Assoc., 70:2, 325-328 (Feb.) 1965.
- Strindberg, L.Z. — The dependence of the results of pulp therapy on certain factors.
Acta Odontol. Scand., 14:21, 1956.

- Strock, A.E., and Strock, M.S. — Methods of reinforcing pulpless anterior teeth.
J. Oral Surg., 1:1, 252-255 (July) 1943.
- Swartz, M.L., and Phillips, R.W. — *In vitro* studies on the marginal leakage of restorative materials.
J. Am. Dent. Assoc., 62:1, 141-151 (Feb.) 1961.
- Tidmarsh, B.G. — Restoration of endodontically treated posterior teeth.
J. Endod., 2:12, 374-375 (Dec.) 1976.
- Trabert, K.C., Caputo, A.A., and Abou-Rass, M. — Tooth fracture - a comparison of endodontic and restorative treatments.
J. Endod., 4:11, 341-345 (Nov.) 1978.
- Trabert, K.C., Caputo, A.A., Collard, E.W., and Standlee, J.P. — Stress transfer to the dental pulp by retentive pins.
J. Prosthet. Dent., 30:5, 808-815 (Nov.) 1973.
- Tylman, S.D. — Theory and Practice of crown and bridge prosthodontics, 5th ed., St. Louis, C.V. Mosby Co., 1965.
- University of Sydney, Department of Operative Dentistry — Technique Crown and Bridgework and Ceramics, 2nd ed., 1972.
- Vajda, T.T. — Endodontic-endosteal implants.
J. Implant Dentistry, 54:1, 22-29 (Nov.) 1978.
Endodontic-prosthetic anchorage and stabilisation system for overdentures and fixed bridgework.
J. Implant Dentistry, 6:1, 9-24 (Nov.) 1979.
- Volker, J.F., Gilda, J.E., and Ginn, J.T. — Radiophosphorus metabolism of pulpless teeth.
J. Dent. Res., 21:3, 322-323 (June) 1942.
- von Fraunhofer, J.A. — Oral Implants.
in Scientific Aspects of Dental Materials, Edit. J.A. von Fraunhofer, London, Butterworths, 1975 (Chapter 12).
- Wakai, W.T. — Case selection.
in Pathways of the Pulp, Edit. S. Cohen and R.C. Burns, St. Louis, C.V. Mosby Co., 1976 (Chapter 2).

- Waliszewski, K.J., and Sabala, C.L. — Combined endodontic and restorative treatment considerations.
J. Prosthet. Dent., 40:2, 152-156 (Aug.) 1978.
- Wassermann, F., Blayney, J.R., Groetzinger, G., and Dewitt, T.G. — Studies on the different pathways of exchange of minerals in teeth with the aid of radioactive phosphorus.
J. Dent. Res., 20:389-398, 1941,a.
Further studies in mineral metabolism of human teeth by the use of radioactive phosphorus.
J. Dent. Res., 20:559-563, 1941,b.
- Watson, R.J. — The amalgam core.
J. Prosthet. Dent., 19:5, 500-505 (May) 1968.
- Wearn, D.I. — Posts and cores in divergent canals.
Aust. Dent. J., 19:5, 346-348 (Oct.) 1974.
- Wechsler, S.M., Vogel, R.I., Fishelberg, G., and Shovlin, F.E. — Iatrogenic root fractures: a case report.
J. Endod., 4:8, 251-253 (Aug.) 1978.
- Weine, F.S. — Endodontic Therapy, 2nd ed., St. Louis, C.V. Mosby Co., 1976.
- Weine, F.S., Kahn, H., Wax, A.H., and Taylor, G.N. — The use of standardized tapered plastic pins in post and core fabrication.
J. Prosthet. Dent., 29:5, 542-548 (May) 1973.
- Welk, D.A., and Dilts, W.E. — Influence of pins on the compressive and transverse strength of dental amalgam and retention of pins in amalgam.
J. Am. Dent. Assoc., 78:1, 101-104 (Jan.) 1969.
- Welsh, S.L., and Priddy, W.L. — Direct fabrication of interlocking endodontic posts.
J. Prosthet. Dent., 39:1, 115-117 (Jan.) 1978.
- Whaledent International — Instruction manual for Strobex Mark III electro-surgical unit, 1979.
- Wheeler, R.C. — Pulp cavities of the permanent teeth.
Philadelphia, W.B. Saunders Co., 1976.
- Whiteside, W.D. — A simplified dowel crown technique.
J. Prosthet. Dent., 23:5, 554-559 (May) 1970.

- Williams, D.F., and Cunningham, J. — Materials in Clinical Dentistry.
Oxford University Press, Oxford, 1979.
- Wilson, A.D., and Batchelor, R.F. — Zinc oxide-eugenol cements II. Study of erosion and disintegration.
J. Dent. Res., 49:593-598, 1970.
- Wing, G. — Pin retention amalgam restoration.
Aust. Dent. J., 10:1, 6-10 (Feb.) 1965.
- Wing, G. — Modern concepts for the amalgam restoration.
Dent. Clin. North Am., 15:1, 43-56 (Jan.) 1971.
- Wing, G. — Personal communication, 1981.
- Wing, G., and Lyell, J.S. — The marginal seal of amalgam restorations.
Aust. Dent. J., 11:2, 81-86 (Apr.) 1966.
- Winstanley, R.B. — Pin-retained amalgam restorations.
Br. Dent. J., 130:327-333 (Apr.) 1971.
- Yuodelis, R., and Morrison, K. — Full coverage restoration of pulpless anterior and bicuspid teeth.
Can. Dent. Assoc. J., 32:9, 516-521, 1966.
- Zagarelli, E.V., Kutscher, A.H., Denning, C.R., and Ragosta, J.M. — Discolouration of the teeth in a 24-year-old patient with cystic fibrosis of the pancreas not primarily associated with tetracycline therapy.
Oral Surg., 21:1, 62-64 (July) 1967.
- Zarb, G.A. — Pin reinforcement in restorative dentistry.
Can. Dent. Assoc. J., 31:6, 363-368, 1965.
- Zmener, O. — Adaptation of threaded dowels to dentine.
J. Prosthet. Dent., 43:5, 530-535 (May) 1980,a.
- Zmener, O. — Effect of dowel preparation of the apical seal of endodontically treated teeth.
J. Endod., 6:8, 687-690 (Aug.) 1980,b.

