

HYPOADRENOCORTICISM.

This manifests itself in either an acute form, or a chronic form.

HYPOADRENOCORTICISM. (adrenal crisis, adrenal apoplexy, Waterhouse-Friderichsen syndrome.)

This is relatively rare, and usually manifests itself in association with chronic Addison's Disease, in both untreated cases and as a result of therapy. Adrenal apoplexy, is a sudden haemorrhage into an adrenal tumour causing an abrupt failure in cortical secretions.

The Waterhouse-Friderichsen syndrome, (purpera fulminans) is a dangerous illness consisting of bilateral adrenal haemorrhages, with fulminating purpera and is a complication of acute rapid and overwhelming sepsis with a high temperature, usually caused by septicaemia (primarily meningococcal). About 200 cases have been reported chiefly in children. Clinical features are cyanosis, petachae, purpera, abdominal pains, convulsions, finally circulatory failure and death within 24-28 hours of onset. (Shafer, Hine and Levy (1963) state that death occurs within 48-72 hours). Treatment is calculated to deal with the sepsis (antibiotics), vascular collapse (transfusions) adrenal failure (intravenous hydrocortisone), Lisser and Escamilla (1962).

Acute adrenal crisis, can also occur in patients under stress. Streat (1959), refers to three types of adrenocortical insufficiency in relation to the stress caused by surgical trauma;

1. Adrenal insufficiency resulting from excessive surgical trauma,
2. Adrenal insufficiency following mild surgical trauma because of impaired adrenal function in patients previously treated with adrenocortical steroids or corticotropin.
3. Adrenal insufficiency in patients with a greater or lesser degree of non-drug induced adrenal hypofunction who have less than optimal adrenal response to stress.

Streat (1959) also remarks that prolonged treatment with even

moderate doses of cortisone or similar acting compounds, may result in adrenocortical insufficiency.

See "Dental Surgery and Stress" under "The Adaptation Syndrome" for further details and also under "Treatment of Addisons Disease adrenal crisis"




Fig. 28

Addison's Disease, showing pigmentation of the gingivae in a moderate and severe form, and also of a scar on the forearm. Lissner and Escamilla (1962).



Fig. 29.

Addison's Disease, showing pigmentation of the lips and oral mucosa. Shafer, Hinc, and Levy (1963).

CHRONIC HYPOADRENOCORTICISM. - ADDISON'S DISEASE.

Addison, first described this disease in (1835) in a monograph entitled "on the constitutional and local effects of disease of the Suprarenal glands" and modern medicine can add little to his description of the disease.

Addison's Disease is a chronic disease, characterised principally by weakness, fatigue, brownish-black pigmentation of the skin and mucous membranes, hypotension and gastrointestinal irritability. Loss of function of the adrenal cortex is the significant factor, medullary failure being relatively unimportant.

Aetiology;

Addison rightly ascribed the cause of it to primary disease of the adrenal glands, which were most often destroyed by tuberculosis. This accounted for 70-80% of cases formerly but now, with present day reduction in the incidence of tuberculosis, this causative factor, has diminished. About half of the cases are of unknown origin. More rarely it may be due to either tumour tissue, (metastatic, carcinoma, leukaemia, amyloidosis, histoplasmosis, blastomycosis, or granulomatous processes) partly or completely destroying the adrenal glands. Chronic amebiasis is also reported as a cause.

Up to (1952) approximately 100 cases of Addison's Disease in children had been reported. The disease generally occurs in adults. Lisser and Escamilla (1962).

Sloper (1955) analysed 37 necropsies in an attempt to ascertain the role of the adrenal, thymus, thyroid, pancreas and pituitary glands in Addison's Disease. He found that the adrenal and the pituitary glands are always affected, but pathological changes in the thymus thyroid and pancreas are variable and inconsistent. In anterior pituitary involvement, there was a tendency toward hypopituitarism; involvement in about half of the 36 cases of the thyroid; there was an absence of enlargement of the thymus in most cases; and in two cases there was the presence of small pancreatic islet-cell adenomata.

Sloper (1955) also differentiated between the tuberculous and idiopathic types of Addison's Disease, which he said was important,

because of the possibility that cortisone therapy may activate a tuberculous lesion. The presence of tuberculosis in other parts of the body, favours a tuberculous aetiology. There is a greater tendency towards thyroid involution in the idiopathic type and a greater destruction of adrenal tissue (especially the medulla) in the tuberculous type which renders it less responsive to treatment.

Clinical Findings;

1. Weakness and fatigue.
2. Pigmentation which is probably due to an excess of melanocytic stimulating hormone (MSH) from the intermediate lobe of the pituitary gland. It appears firstly on exposed parts, then mostly on pressure areas. The lips and gums are common sites of the pigmentation.
3. Gastrointestinal disturbances, nausea, vomiting, diarrhoea, pain.
4. Craving for salt which sometimes is extreme.
5. Weight loss occurs in most patients, but not so much as in Simmond's Disease.
6. Nervous and mental symptoms.
7. Hypotension. Systolic blood pressure is under 100mg. Hg, usually with hypothermia.
8. Sclerotic thickening of the ear pinnae (Thorn's sign)
9. Sparse or absent axillary or pubic hair and amenorrhoea in women. Lisser and Escamilla (1962).

Laboratory Findings;

1. Urinary 17-hydroxycorticoid excretion is low (below 4mg/24 hours.
2. Urinary 17-ketosteroid is also low.
3. Circulating eosinophil count is high-normal or high, which fails to drop following ACTH stimulation (ACTH test).
4. Serum sodium and chlorides is decreased, and serum potassium is increased.
5. Water excretion test, shows tendency to hypoglycaemia.

There are other tests of lesser importance, which are occasionally helpful but the ones mentioned are the important ones, Lisser and Escamilla (1962).

Changes in the Oral Region.

Pigmentation of the oral mucosa is a common sign and occurs early. The dentist may discover it before the other symptoms are recognised. The pigmentation varies greatly from pale brown to deep brown and black. It is observed at the vermillion border of the lips, the tongue and gingivae, and it may spread in a fan-like manner from the angle of the mouth over the cheeks. It usually occurs in spots or streaks. Thoma and Goldman (1960), Blackburn (1955), remarks that pigmentation of the buccal mucosa is characteristic of Addison's Disease.

Sloper (1955) states that buccal pigmentation was present in nearly all of the 37 cases of Addison's Disease he studied. Shafer, Hine and Levy (1963) comment that the buccal pigmentation may be the first evidence of the disease. Conybeare and Mann (1952), and Wheeler and Jack (1963), in their text-books of Medicine, comment that the pigmentation is not only on the buccal mucosa, but also on the lips, gums and palate. Gard et al (1939), reported a case of Addison's Disease in which the maxillary gingivae from the left canine to right canine, and extending to the areolar gingivae, showed some bluish pigmented areas and others tinted with a very deep brown stain, which was especially marked over the left incisors. The entire palate and buccal mucosa of cheeks were covered with a lightly brown film. The authors pointed out that the systemic conditions greatly aid arriving at a correct diagnosis. These are insidious in their development.

Nieddu (1958) states that in addition to pigmentation on the oral mucosa, there is increased caries activity and green stains commonly occurring on the teeth. However, this possibly is due to oral neglect.

Teuscher (1958) comments that children with Addison's Disease have to be handled with great care to avoid the precipitation of an adrenal crisis. Little danger however, exists if proper hormonal therapy is instituted. Cohen (1957) gives a list of precautions to be observed in such patient's undergoing dental treatment;

- 1) Dental surgery should be postponed till patient's condition is more satisfactory if possible.
- 2) Extractions should be done at a hospital.

- 3) A high calorie or carbohydrate diet should be ingested for a week, prior to dental surgery, and also Vitamin C should be administered over that period.
- 4) Cortisone is given three days prior to surgery, and half hour before.
- 5) Vitamin K is given one day before surgery.
- 6) Sedation and a light breakfast is provided the morning of operation.
- 7) Nitrous oxide-oxygen analgesia is advised during local anaesthetic administration to minimise stress.
- 8) Post-operative care involves a wholesome diet at three hour intervals, cortisone and penicillin administration.

Histopathology;

Biopsy from the case described by Oard et al (1939) showed elongation of the rete pegs and focal acanthosis. Silver staining showed the pigment to occur in the cells of the stratum germinativum and adjacent to the stratum spinosum. There were occasional chromatophores in the corium.

Wheeler and Jack (1963) remark that the pigment is a melanin deposit in the malpighian layer of the skin. It used to be thought to be formed by the action of tyrosinase upon the tyrosin which is, as it were "redundant" because the damaged adrenal medulla cannot use it for the formation of adrenaline. However, pigmentation can occur after the modern operation of bilateral adrenalectomy for carcinoma of the breast. It may be due to anomalies in ACTH secretion.

Differential Diagnosis;

Lisser and Escamilla (1963) list the following conditions which must be considered;

1. Conditions causing weakness and asthenia such as hypothyroidism, pernicious anaemia, tuberculosis, malignancy, and neurasthenia, do not show the characteristic blood chemistry pattern, diminished blood and urine corticoids, interference with water diuresis or high eosinophil count which fails to drop following ACTH of stimulation, seen in Addison's Disease.
2. Other causes of increased pigmentation such as haemochromatosis, steatorrhoea, including Whipple's Disease and argyria, occasionally

require differentiation, but blood chemistry and other studies as above, distinguish.

3. Primary pituitary disease with secondary adrenal cortical insufficiency may be confusing, early loss of sexual function suggests primary pituitary disease and radiographs of the sella turcica may demonstrate a pituitary tumour. Low urinary and blood corticoids do not respond to ACTH stimulation. The adrenal cortical insufficiency however must be treated, whether primary or secondary.

Treatment.

1. Cortisone, may suffice alone but combined therapy with desoxycorticosterone or fluorocortisone is somewhat safer, and may achieve a sense of well being. Addisonians should always carry a few tablets of cortisone for emergency use, in case of extra stress, infection etc. Side effects of cortisone are numerous, Lisser and Escamilla (1962), Blackburn (1955), and include provocation of psychotic behaviour, fluid retention, obesity, diabetes, hypertension, chronic peptic ulcer de novo or reactivation of a previously existing ulcer. Sloper (1955) refers to the definite possibility of reactivation of tuberculous lesions in patients under cortisone. Blackburn (1955) states that the side effects of cortisone therapy involves a frightening list. He states that some 40 percent of such patients develop mental aberration, and comments that osteoporosis and poor wound healing are to be considered also.

2. Hydrocortisone, fluorocortisone acetate, desoxycortisosterone have all been used with success.

3. Salt, in extra amounts added to food or taken as tablets.

4. Adjuvant therapy. Anabolic properties of androgens, such as methyltestosterone is occasionally helpful. Also antituberculosis therapy is relevant.

5. Adrenal crisis, may occur and immediate treatment is necessary. Usual symptoms are shock, gastrointestinal upset, hyperexia, hypoglycaemia. Start treatment with saline infusion, containing glucose (ten percent) and hydrocortisone (100mg). Levophed is given to maintain the blood pressure. Use potassium phosphate if anuria

occurs and antipyretics and antibiotics if necessary. Lisser and Escamilla (1962). Prunty, McSwiney and Nice, (1955) show that aldosterone is a useful replacement therapy steroid for Addison's Disease.

Prognosis.

Prognosis is poor in untreated Addison's Disease, and usually terminates in fatal crisis or hypoglycaemic attack within three years of recognition.

With adequate treatment, however, patients can usually lead fairly normal lives even though substitution therapy must continue with its side effects. Patients often died of tuberculosis in the past, rather than adrenal failure. Lisser and Escamilla (1962).

EXPERIMENTAL HYPERADRENOCORTICISM AND HYPOADRENOCORTICISM.Effect on Dental Caries Incidence;

Besic et al (1959) studied the caries incidence of cortisone treated white rats. He concluded that, whilst no definite results can be drawn from the small group that he studied, there was an average 40 percent increase to caries score and number, which suggests justification for further study.

Sweeney (1960) studied the effect of adrenalectomy on experimental dental caries, with and without cortisone, on caries susceptible rats. He found no statistically significant difference in caries incidence in the five groups of rats he compared.

The effect on attrition and extrusion rates of rat incisors, of hydrocortisone, was studied by Solkowski and Southgall (1960). They found that the daily administration of hydrocortisone caused a significant increase in the extrusion rate within five days, but a dose response was not evident till the tenth day. The attrition rate effect was not consistent throughout the administration period.

Effect on the Salivary Glands.

It seems that saliva secretion depends on nervous and hormonal factors which was first observed by Heidenhain (1868), and up till recent times has been commented on, Babkin (1950), etc.

Langley (1901), demonstrated that adrenal hormones increase salivary secretion. Hammerli (1920), observed in a man at autopsy a striking hypertrophy of the parotid and submaxillary glands, associated with adrenal hypertrophy.

Raynaud (1946-1947) found in castrated and adrenalectomised mice, a greater atrophy of submaxillary gland tubules than in castrated mice alone.

Bixler et al (1955-6) observed that the adrenal glands of rats from which the salivary glands had been removed, exhibited an increased lipid activity and marked cellular atrophy of the fasciculata. In adrenalectomised cats the submaxillary glands may show striking atrophy. Kahlson and Renvall (1956), obtained a

28 percent reduction in submaxillary gland weight, whilst Osorio (1960), in his DDD-treated dogs found a 31 percent reduction.

Osorio (1960) studied the role of the adrenal cortex in salivary secretion by producing gradual corticoadrenal atrophy in dogs, (by administration of Rhothane, DDD). He found parallel changes in the submaxillary glands; decreased weight, histologic lesions including atrophy of granular acini and vascular thrombosis, and a decreased salivary flow which could be evoked by pilocarpine.

Pregmore and Shannon (1960) discovered that under the influence of ACTH administration, altered parotid fluid steroid levels in healthy young male adults closely paralleled increases seen in serum and urine, 17-OHCS conc. A decreased steroid concentration in parotid fluid, serum and urine followed the oral administration of triamcinolone. These findings, they state, further solidify the concept that steroid levels in parotid fluid can be used as an indicator of adrenocortical status.

Effect on the Periodontium and Alveolar Bone;

Becks et al (1944) reported that ACTH inhibites bone growth of rats experimentally. Applebaum and Seelig (1955) reported a loss of septal bone after three months of daily injection of 2.5mg of cortisone to rats.

Goldsmith (1953) said that rats receiving 3mg of cortisone daily, for a year showed an increase in the amount of alveolar bone and a marked narrowing of the marrow space. He said that the appearance may be the result of a retardation of endosteal resorption. In the periodontal membrane, a disorganisation of the arrangement of the fibres and their attachment to the bone was seen.

Glickman et al (1954) injected twenty mice with 0.5mg cortisone for periods up to 43 days. Microscopic examination of the periodontal tissues revealed osteoporosis of alveolar bone, characterised by reduction of alveolar bone, oedema of the periodontal membrane with reduction in the number of fibroblasts and collagen fibres, and degeneration of the collagen fibres. These changes occurred unrelated to gingival inflammation associated with local irritation. The bone loss was attributed to a disturbance in the

corticosteroid hormone balance responsible for the anabolic equilibrium essential for the maintenance of bone.

Glickman and Shklar (1954) injected a group of twenty animals with 25mg of cortisone acetate daily, another twenty were given 25mg of cortisone acetate daily, and one weekly injection of 600 rat units of oestradiol benzoate, and oestrogenic hormone. Another group of ten, was given daily saline injections and another group was not injected. At the end of a 35 day experiment, microscopic study showed that the administration of systemic oestrogen affected a modification of the osteoporosis effect observed when cortisone is given alone. Douglas and Kresbery (1956), however point out that the dosages used by Glickman in his experiments was twenty times larger than that given to human beings, in proportion, and refer to a statement by Kerr (1955) who said that there are dangers in applying the results of experiments on animals as being valid for human beings.

Batcliff (1956) found that in the later stages of the stress reaction, there occurred sloughing of the gingival epithelium, desquamation of the periodontal membrane and a reduction in osteoblastic activity in rats.

Glickman, Stone and Chawla, (1956) administered cortisone acetate to white mice, and found a resultant osteoporosis of the skeletal system, including the alveolar bone, capillary dilatation, and engorgement due to haemorrhage in the periodontal membrane and gingivae and a reduction of the number of fibres in the periodontal membrane.

Loving (1960) found that there was a relationship between acute necrotising ulcerative gingivitis and stress factors as measured by the total 17-OHCS levels in the blood stream of naval recruits. Emotional stress has been described as a contributing cause of necrotic ulcerative gingivitis. Emotional stress may elicit an endocrine response affecting the gingivae as the above study may show.

Effect on Wound Healing;

An experimental study by Shafer (1954) on the healing of extraction wounds in rats receiving cortisone showed that the healing of such wounds is delayed. See further remarks under "hypercortisonism and Hypocortisonism and wound healing"

THE ADRENAL MEDULLA.HYPERADRENALISM.

Of the rare medullary tumours there is the neuroblastoma, arising in sympathetic ganglion cells, occurring in childhood and is intensely malignant, and the pheochromocytoma, of which of some 200 have been reported, and is the only tumour which gives rise to endocrine manifestations. It is a tumour of the chromaffin cells, and produces attacks of hypertensive crises, when large amounts of adrenaline or non-adrenaline are secreted and the blood pressure rises to 300/150mmhg. Occasionally, sustained hypertension occurs and Shakiness, intense pallor, profuse sweating, headache, dyspnoea and pain in the chest and extremities occurs during the hypertensive attacks, and death may occur from cardiac failure, cerebral haemorrhage or lung oedema.

Diagnosis is best confirmed by the measurement of the catechol amines in the urine. The normal level of below 200mcg/ fourteen hours may be elevated between 500 and 2,500 mcg/24 hours following a paroxysm. Certain blood pressure tests have been used, but the catechol amine test is the most reliable, Lisser and Escamilla (1962).

Treatment. Is to remove the tumour early but extreme care is necessary to avoid a discharge of adrenaline from the tumour during surgery, as it may be fatal. Selye (1949), Conybeare and Mann (1952), Wheeler and Jack (1963), Lisser and Escamilla (1962)

Changes in the Oral Region.

Nieddu (1958), states that there is pallor of the oral mucosa, which would be expected from the vasoconstriction effect of the adrenaline.

Glycosuria is frequent with pheochromocytoma, and actual diabetes mellitus may be associated with it, Lisser and Escamilla (1962), and if so, would produce similar changes in the oral cavity as mentioned in connection with diabetes mellitus.

Selye (1949) remarks that patient's with pheochromocytoma, are

extremely sensitive to stress due to the greatly increased adrenaline secretion, and that in many cases death has ensued following a minor surgical operation such as tooth extraction.

Hyperadrenalism and Stress.

Increased adrenaline secretion occurs in the Stress Reaction as mentioned by Selye, and has already been discussed under "Stress and the Adaptation Syndrome"

THE GONADS.

INTRODUCTORY.

The gonads (testis and ovary) have both an exocrine and an endocrine function. The exocrine function is to produce the sperm and the ovum, whilst the endocrine function is the production of sex hormones.

The testes are nearly symmetrically paired glands in the male, and oval shape ($4 \times 2\frac{1}{2} \times 1\frac{1}{2}$ cm in size), consisting of seminiferous tubules separated by the septum of the testis, and the interstitial cells of Leydig (which lie in the loose connective tissue between the seminiferous tubules, and elaborate the internal secretion), and connected to its duct, the much twisted and contorted epididymis, all being enclosed within the tunica vaginalis.

The ovaries are of somewhat smaller size than the testes, in the female ($30 \times 15 \times 10$ mm, in size average) consisting of a stroma with the enclosing ovarian epithelium. This epithelium produces the ovum which develops within the ovarian follicle (Graafian follicle) until it is finally discharged through eruption of the follicle. The corpus luteum, is what the ruptured follicle develops into, which slowly degenerates unless impregnation has occurred, when it then enlarges. The internal secretions of the ovary are produced by the Graafian follicle (oestrogenic hormones), and the corpus luteum, (progestin or progesterone). Cunningham (1948), Ham (1953) Hawker (1950).

The Hormones of the Gonads.

1. Testosterone is the true male sex hormone, secreted by the Leydig cells of the testes. It is ^{an} androgen, whose main properties is the promotion of male sex characteristics (including skeletal moulding), anti-oestrogenic and anabolic. It is inactive when given by mouth, and its effect is very transient when given by injection. It is only useful in therapy when implanted as pellets in the body. Many synthetic derivatives have been produced having similar effects

as testosterone in therapy, such as testosterone propionate, methyltestosterone, etc., Bishop (1961). It is a steroid, similar to those produced by the adrenal cortex, and is very closely related to them.

2. Oestrogen, is the folliculoid hormone of the female produced by the Graafian follicles of the ovary, under the stimulation of the gonadotrophic pituitary hormone (Follicular stimulating hormone FSH). The oestrogens effect the uterus, vagina, fallopian tubes, indirectly on the ovary, the anterior pituitary, the mammary glands the mating instinct (libido or oestrus), and particularly the secondary female sex characteristics. Oestrogen has extragenital effects which also are often underestimated. A foremost function is regulation of metabolism notably through anabolic or nitrogen retaining effect. An example is calcification of bone through stimulation of osteoblastic activity. Oestrogen is also important in carbohydrate metabolism, mobilising glucose reserve, and distributing glucose to the tissues, Griffith (1956-1963). High levels of oestrogen stimulates epithelial growth and inhibits mesenchymal growth, Ziskin (1938), Rogers and Kean (1954), Pfeffer (1960).

It was isolated from the urine of pregnant women first, by Doisey and Butenandt (1929),

3. Progesterone, (or progestin), the luteoid hormone of the female produced by the corpus luteum, after ovulation, under the stimulation of anterior pituitary luteotrophic hormone (LH), It is concerned with the preparation of the uterus for the implanation of the ovum. It was isolated in (1929), and prepared in pure form in (1934), Hawker (1950).

In addition, other hormones are produced from the placenta, and others found in the urine in pregnancy, and from the amniotic fluid of cattle.

The gonads of both sexes are considerably under the control of the anterior pituitary, and probably by other glands, also, so that when dysfunction occurs, it frequently is of pituitary origin. Stones (1954).

Selye (1949), points out that it must be kept in mind that the same steroid (all the sex hormones, whether produced by the adrenal

glands, gonads or placenta, are steroids closely related) may be elaborated by several endocrines (eg gonads, adrenal cortex, placenta hence many steroids as well as their metabolites, cannot be regarded as specific products of any one gland. Furthermore there is a considerable overlap between the pharmacologic actions of the chemically different steroids. The folliculoid hormones are found in the testis and placenta, as well as in the ovary. Selye (1949), in view of the above remarks uses the nomenclature, corticoid, folliculoid, luteoid, and testoid hormones to describe the sex hormones rather than be too specific as to where they are produced.

An important function of testoid and folliculoid hormones is the inhibition of somatic growth, by reducing growth in length of the long bones, due to closure of the epiphyses. Selye (1949).

Greep (1956) states that it is well known that oestrogen causes proliferation of bone trabeculae. It has been demonstrated by McLean that the injection of oestrogen in mice results in endosteal activity to make the bone solid. Testosterone has different effects on different animals being instrumental in bringing about epiphyseal closure in some, but not others. Although hormones may exert rather specific effects on bones, bone growth is not the function of any one or two hormones, but rather of a very complex and highly co-ordinated interaction of several hormones.

Henneman (1956) comments that oestrogen certainly has an effect on bone in the human female. The best evidence of this, is seen in postmenopausal women when an amount of calcium equal to 5-10 percent of the total body calcium may be retained, in a year while receiving oestrogen therapy. No one has demonstrated increase in bone density radiographically in women so treated but maybe it simply is not marked enough to show by this method.

HYPERGONADISM. (Precocious puberty in boys and girls.)

Increased secretion of the gonadal hormones may be due to a tumour or hyperplasia of the adrenal cortex, (which results in the adrenogenital syndrome), to some tumours of the ovary or to tumours of the midbrain, Stones (1954). Lisser and Escamilla (1962) also refer to types due to an interstitial cell tumour of the testes, and familial and constitutional causes.

The adrenogenital syndrome and pineal gland tumours have been considered elsewhere, and this account will be restricted to the precocious puberty syndrome with direct gonadal aetiology.

Interstitial cell tumour of the Testis, this is quite rare, with only 22 cases having been reported up to (1957). Age of onset in all cases was before the age of seven years. All boys were tall for their age, with accelerated bone age and muscular habitus. 17-ketosteroids were abnormally high in all cases determined and fell to normal after removal of the tumour by orchiectomy. In all cases so far, the tumour has been benign and bilateral in only one case. Symptoms and signs are very similar to those caused by adrenal cortical tumours.

It can be differentiated from adrenocortical tumours, congenital adrenal cortical hyperplasia, pineal tumours with macrogenitostomia praecox, neurogenic cerebral sexual precocity from encephalitis, constitutional sexual precocity, familial hereditary sexual precocity and sexual precocity due to an malignant hepatoma, Lisser and Escamilla (1962).

Granulosa Cell Tumour of the Ovary, Is also very rare. Only 5-10% of this type occurs before puberty. Thecomas and luteomas of adults are rarely seen in children. It is characterised by rapid precocious sexual development, with vaginal bleeding resembling menstruation commencing as early as the first six months of life, very early breast development, sexual hair, etc. There is a greatly advanced bone age. A girl of twelve years shows epiphyseal

closure and general bone development of a girl of seventeen years old is described. Urinary oestrogens are very high. Surgical removal of the ovarian tumour is mandatory. Malignancy is rare in these tumours.

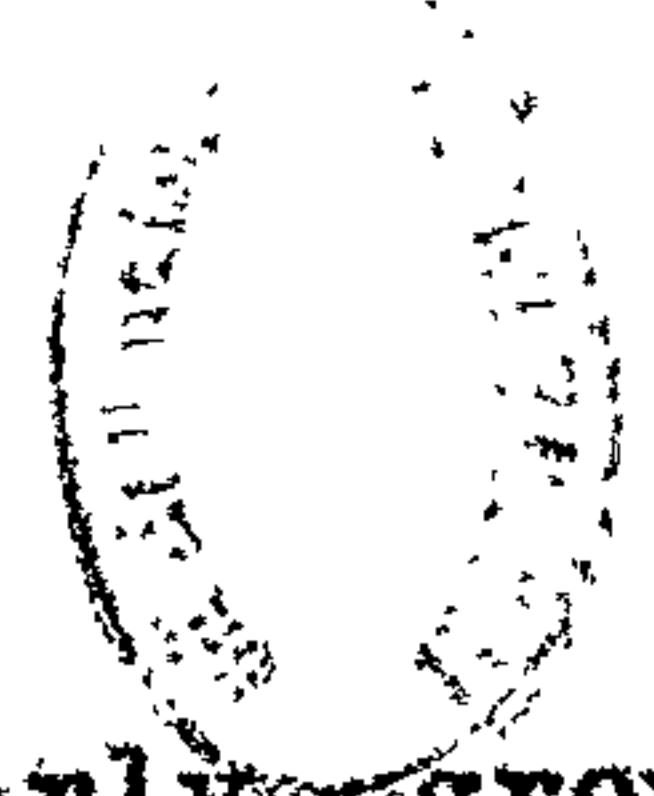Differentiation must be made from Constitutional sexual precocity (the "Novak" type) which is far more common and represents idiopathic early physiological maturity. Very rapid bone growth acceleration, and sexual development occurs. True menstruation, can appear as early as five years of age, and Wilkins (1950) even refers to a girl who began menstruating at the age of three years, became pregnant at four years ten months, delivered by caesarian section a six and a half pound son at five years seven months. Lisser and Escamilla (1962), refers to a case also of a girl aged five years seven months with a height age of ten years eight months, all associated with very early sexual precocity. No pelvic tumour is felt or found in these cases, so treatment is by hormones such as methyltestosterone, but growth cannot be augmented if the epiphyses have already closed.

Polyostotic fibrous dysplasia (Albright's Syndrome) must also be distinguished from ovarian sexual precocity. It occurs almost exclusively in girls, and is characterised by segmental disseminated fibrous dysplasia replacing medullary structures of bone, pigmentation of the skin and sexual precocity. The adrenogenital syndrome, hypothalamic neurogenic disorders must also be differentiated, Lisser and Escamilla (1962).

Familial Sexual Precocity.

This is very rare; Lisser and Escamilla (1962), remark that only nine cases have been reported up to (1956).

Constitutional Sexual Precocity, is seen in both boys and girls. The type found in boys corresponds to the Novak type of idiopathic sexual precocity of girls above described. Such cases need not partake of a familial or hereditary pattern, Lisser and Escamilla (1962).



Cranio-facial Development in Hypergonadism.

In all these cases, where the condition commences early, growth processes progress rapidly during the first five to six years, and then is arrested by premature closure of the epiphyses. All parts of the body participate in the overgrowth but perhaps the osseous system is most marked, due to early recognition.

The early union of the epiphyses results in underdevelopment of the long bones and makes for a short stocky build with the upper measurement longer than the lower. Masculine stature is developed in the female and adiposity and pigmentation in some cases.

The head may undergo enlargement, and the facies of the female, also may show male characteristics due to thickened skin and hypertrichosis, Thoma and Goldman (1960).

Schour, and Massler (1943), remark that the cranio-facial development corresponds to, and is in harmony with the rest of the body.

Dental Development.

Thoma and Goldman (1960) state that there is often a peculiar growth of the maxillae, with spacing of the teeth, and enlargement of the nose and chin similar to that seen in acromegaly.

The teeth are likely to be much larger than in the average person, with strong dentine formation, and may erupt earlier. The deciduous teeth may erupt before the age of six months and a case has been reported in which the permanent teeth erupted two years prematurely. White and Breschet (1815, 1820) reported a case of a boy sexually matured at two years, who possessed a complete deciduous dentition at the age of one year, with a change to the permanent dentition at the age of three years. Early shedding of the deciduous teeth and early eruption of the permanent teeth, occurs frequently, Thoma and Goldman (1960).

Lisser (1903), reports a case of a boy, sexually matured at five and a half years of age, with teeth like those of a boy of fifteen years old. Hedman (1901), cited a case of a boy sexually matured at the age of four and a half years who shed the deciduous teeth and erupted the permanent teeth at four years of age, and Peacock (1839-40) saw a girl, who menstruated at the age of five

years, and who was in possession of her permanent incisors and molars.

However, Schour and Massler (1943) remark that tooth development (formation of enamel and dentine and eruption) is much less affected than in skeletal development, which is in contrast to pituitary gigantism where there is marked acceleration of development, Rushton (1941), McCulloch and Resch (1941).

Rushton (1948) describes a female of nearly seven years of age, with precocious sexual development whose size is equal to one of twelve years and whose dentition is equal to ten years.

Lisser and Escamilla (1962) report another case of a girl five years seven months with idiopathic constitutional precocious sexual development, whose height, bone, and dental ages are ten years eight months, eleven to twelve years, and eight to nine years, respectively.

Nieddu (1958) remarks that hypergonadism also causes a tendency to periodontopathies and caries. This is due to hormonal imbalances occurring during menstruation, pregnancy, and menopause, to be considered later.

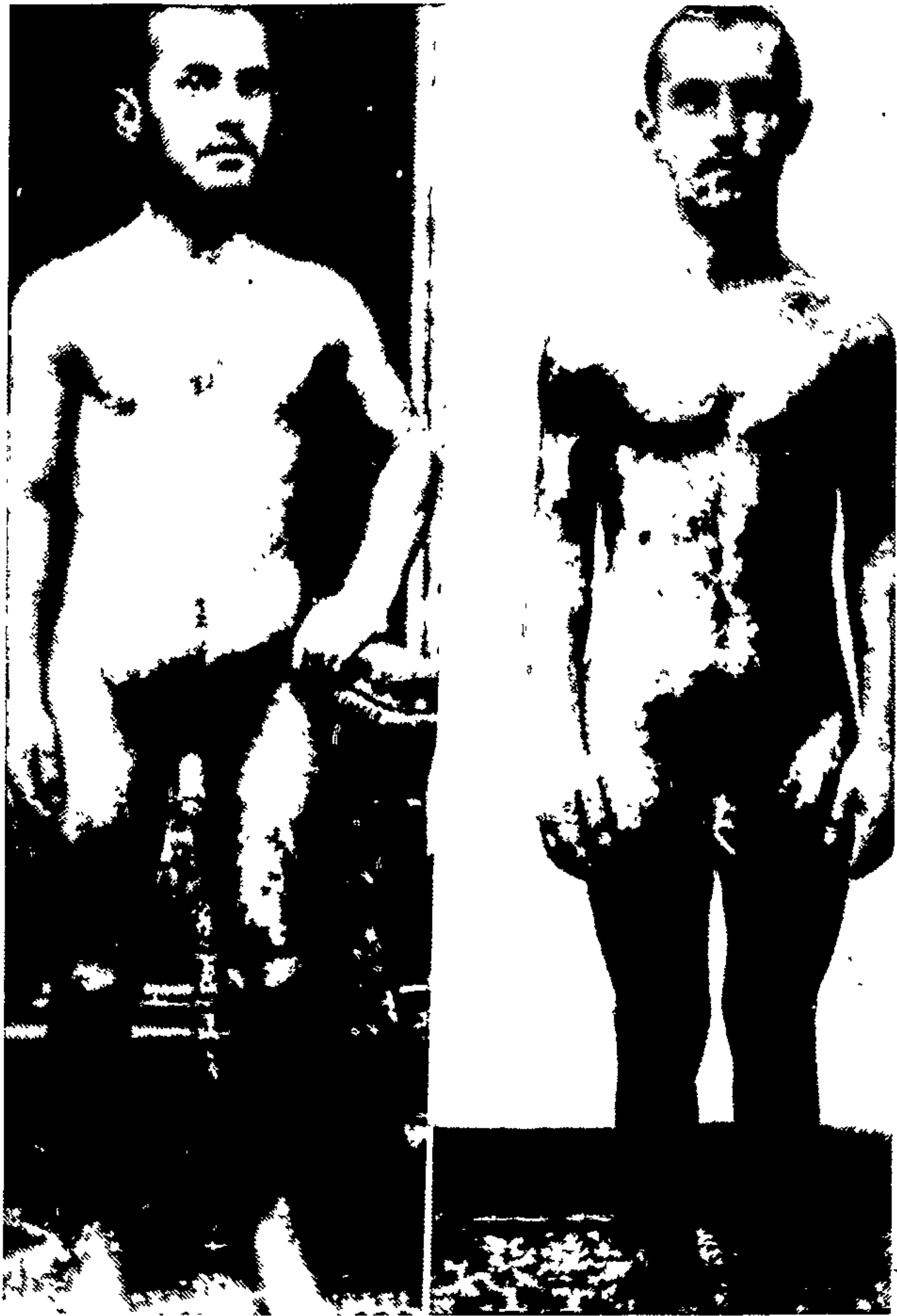

Fig. 30

Hypergonadism, Precocious Puberty. Age 9yrs 11mths. Symptoms began at age of 5. Height 4' 8½". Except for short stature looked fully 20 yrs. older than actual age. Interstitial cell tumour of the testis necessitated orchietomy. Above photograph was taken 15 days after orchietomy, and 4 months after, respectively. Beard and body hair began to fall out one month postoperatively, and there was a considerable regression of sexual development generally. Lissner and Escamilla, (1962).

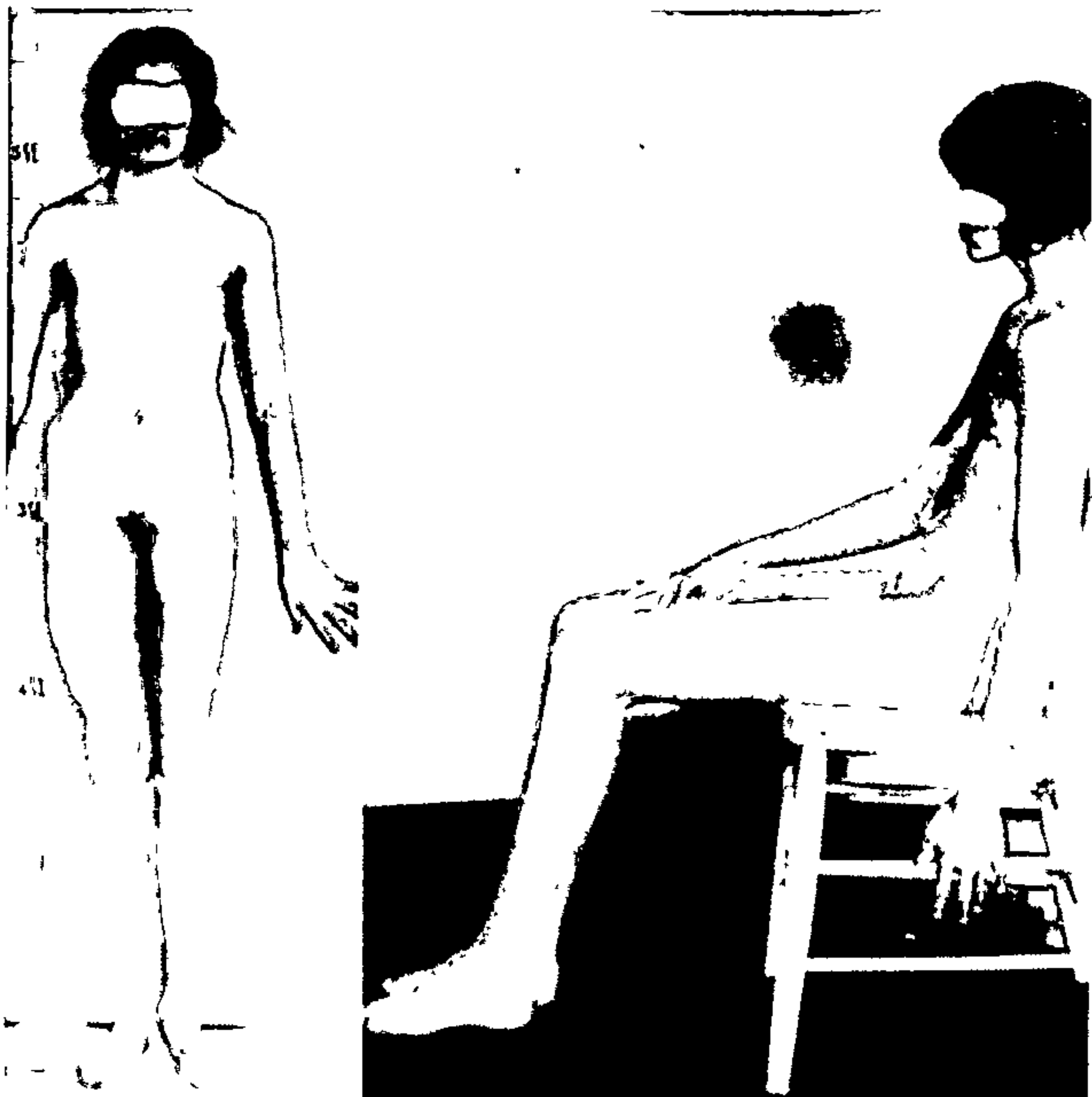



Fig. 31

Female preadolescent eunuchoidism. Age 21yr. Height 5' 7", span 5'10" weight, 103lb. Never menstruated, bone age of 12yr. Continued to grow and at age 23 reached a height of 5'7" and span of 6'2". Note disproportionate growth, and the absence of lateral incisors, which is a common finding. Lissner and Escamilla, (1962).



HYPOGONADISM.

The syndrome occurring under this heading are eunuchoidism, eunuchism, gonadal dysgenesis and the climacterium (menopause). Hormonal imbalances also occurs at puberty, menstruation and pregnancy

EUNUCHOIDISM.

This is a preadolescent condition due to deficient function of the gonads, either as primary testicular or ovarian insufficiency or secondary hypogonadism resulting from inadequate anterior pituitary stimulation through the gonadotrophic hormone. Urinary FSH is high in the former and low in the latter which serves to distinguish between the two. Otherwise the two types are fairly similar. (See eunuchoid gigantism under hyperpituitarism for information on secondary hypogonadism).

Eunuchoidism closely resembles the syndrome following castration in boyhood, "preadolescent eunuchism". The degree of hypogonadism varies from being severe to only moderate. Replacement therapy may not be needed for long. In the primary type the testis or ovary may be ^{inactive} due to mumps, syphilis, hyperexia, x-irradiation, hormone medication or may be congenitally defective, but in most cases, the exact aetiology remains uncertain.

Symptoms include diminished or absent sexual development and function, continued growth beyond usual age due to failure of the epiphyses to close, feelings of inferiority, melancholia, inertia, Lisser and Escamilla (1962).

Clinical Features.

As recorded by Lisser and Escamilla (1962), they are as follows;

1. Unusual tallness (but not true gigantism) beyond usual age.
2. Eunuchoid proportions; span is several inches greater than height and the lower measurement is greater than the upper measurement.
3. Long tapering fingers, narrow wrists, long narrow feet,
4. Rather thin delicate skin with fine wrinkling about the corner of the eyes and lips. Absence of beard in men, and little or no public or axillary hair.

5. Occasional mild adiposity in men and lack of contour in women,
6. Small genitalia,
7. Small or absent lateral incisor teeth, which occasionally occurs.

Laboratory Findings.

These are low urinary 17-ketosteroids (particularly in hypopituitary hypogonadism), FSH is high in primary but low in secondary hypogonadism.

Cranio-facial Development.

The faces of the eunuchoid is childlike in its proportions, but oversized, and the craniofacial proportions corresponds with the chronological age, whilst the rest of the body is tall and gangling, Schour and Massler (1943).

The skin is thin, delicate, soft and velvety, with wrinkling about the lips, and there is an absence of a beard in men, Englebach (1934), Lissner and Escamilla (1962).

There appears to be an increased amount of bone formation, resulting in the jaws, tending to become massive and the ramus appears short, Tandler and Grosz, (1909), and Kranz (1914). The paranasal sinuses appear to be increased in size. The increase in bone formation, however, appears to be much less than in hyperpituitarism. In hypogonadism, there is thus more bone formation than in normal, but not the dysplastic effects of acromegaly, Schour and Massler (1943).

Dental Development.

The growth and calcification of the enamel and dentine and the eruption of the teeth appear to be normal. In some cases the eruption of the teeth seems to be more advanced than usual but cannot be said to be abnormal. Schour and Massler (1943), Stones (1954). However, Thoma and Goldman (1960), remark that there is evidence of poor calcification due to the effect of gonadal activity upon calcium metabolism. The teeth therefore decay early, and restorations may fall out, notwithstanding constant dental care. Often, all the teeth have to be extracted before the patient is 25 years of age. Hutton (1936) makes similar remarks.

The most marked findings in the oral cavity is small or absent lateral incisors, Rutton, (1936), Thoma and Goldman (1960), Lisser and Escamilla (1962).

Reynolds (1933), found hypogonadism, and combined hypogonadism and hypothyroidism in association with several of the 36 cases of periodontosis of apparent systemic origin he studied.

Treatment of Eunuchoidism.

Distinguishing between primary and secondary hypogonadism is of little value in determining treatment. Both respond to methyltestosterone and oestrogen administration, or other derivative preparations.

Prognosis.

Hypogonadism is itself no threat to life, but suicidal tendencies occasionally appear. Secondary type depends on degree of pituitary lesion. Prognosis of both types is good under treatment.

EUNUCHISM.

This represents complete absence of testicular or ovarian function due to total loss of gonads from surgery or accident. The resulting picture depends on when it occurred, which gives us two distinct types, prepuberal castration or prepuberal bilateral ovariectomy and postpuberal eunuchism.

Prepuberal Castration and Prepuberal Bilateral Ovariectomy.

This presents the same clinical picture as Preadolescent eunuchoidism, and requires the same treatment, Lisser and Escamilla (1962).

Schour and Massler (1943) comment that since castration is no longer practiced, hypogonadism is rarely found in the very young. It is doubtful, they state, if there are any effects on the teeth and there are none if it occurs after the sixth year.

Tandler and Grosz (1909), who studied eunuchs, found changes in the jaws, as mentioned previously, but as they were all castrated after the teeth had fully developed, no changes were reported, in the teeth themselves.

Postpuberal Eunuchism.

This may occur accidentally or become a surgical necessity, because of tuberculosis, syphilis, or tumour.

The skeleton usually remains unaltered but configuration in the male, may tend towards feminised obesity. There is usually a diminished sexual activity, and a slight to moderate loss of sexual characteristics. Vasomotor symptoms such as hot flushes, sweating, and dizziness vary in severity. Urinary FSH is elevated and 17-ketosteroids low. Schour and Massler (1943), Thoma and Goldman, (1960), and Lisser and Escamilla (1962).

In view of the skeletal system remaining unchanged in this condition due to it occurring after epiphyseal closure, there are no bone changes to be seen in the oral region, Schour and Massler, (1943)

GONADAL DYSGENESIS.

This manifests itself in the male (Klinefelter's Syndrome), and female (Turner's Syndrome). It is characterised by small atrophied or rudimentary gonads, sterility, primary amenorrhoea and gynecomastia in males. Elevated FSH is present. Cells in buccal smears, skin biopsies and vaginal smears reveal positive (female) sex chromosome pattern in males and the reverse in females, indicating a sex reversal.

Clinical findings include slow growth but not dwarfism, failure to develop sex characteristics at proper age, stocky muscular build, occasional webbing of neck due to osteoporosis, precocious senility with wrinkling of the skin and peppering of the face with moles is not uncommon.

Radiographs of the bones may show osteoporosis, including facial bones. The bone age is only slightly retarded, Selye (1949), Lisser and Escamilla (1962).

Oral manifestations, are seen in the ovarian dwarfism affecting the cranio-facial bones, and osteoporosis, also in the facial moles occurring as mentioned above.

Treatment, is to stimulate growth with testosterone-thyroid therapy if epiphyseal lines have not closed. Methyltestosterone and oestrogens should be administered after epiphyseal closure to stimulate development of secondary sex characteristics. Prognosis is good but sterility remains, Lisser and Escamilla (1962).

MALE PSEUDOHERMAPHRODITISM.

This remarkable clinical picture is encountered in varying degrees as hypospadias, or as testicular feminisation, (Goldberg-Maxwell Syndrome).

Testicular feminisation is characterised by external feminine features, but gonads which are immature/are foetal testes. Up to 1954, 22 cases had been reported. Whilst normal breast development

and female contouring occur, no menses appear there is no or little axillary and pubic hair, and there is usually only a short vagina and no uterus or ovaries. The immature testes may be where the ovaries would be, or in the labia. These patients illustrate the fact that ovaries do not always elaborate oestrogens, nor do the testes always produce androgens, Goldberg and Maxwell (1948), Lissér and Escamilla (1962).

Oral Manifestations, have been mentioned by Goldberg and Maxwell (1948), in a case they report of a girl aged nineteen years. Amongst the clinical features was found a narrow mandible with crowded lower teeth, and a high palatal arch.

Treatment, of these patients is usually difficult, because of psychic reasons. Sex rearing is important. Castration is usually indicated, and substitution therapy. Lissér and Escamilla (1962).

TRUE HERMAPHRODITISM. (Ovotestis)

This very unusual condition, involves the presence of both ovarian, and testicular components in one person. Up to 1958, 70 verified cases have appeared in the literature. It occurs in varying types of combination, such as, unilateral and bilateral ovotestis. In some, predominately male, and in others, female characteristics appear. A wide variety of clinical features have been reported. Lissér and Escamilla (1962).

There does not appear to be any record of specific oral manifestations in cases of ovotestis. It would depend somewhat on which (male or female) features predominated.

Treatment, is to choose the dominant sex, preferably before the age of two and a half years, and then a "psychological sex" is usually established by rearing and social environment. Surgery and castration may be needed. Lissér and Escamilla (1962).

PUBERTY.

Puberty represents a period of maturation accompanied by profound physical and psychic changes. At the same time, there is re-adjustment of the hormonal function affecting the whole body. Changes which occur, are development of the secondary sex characteristics, such as changes in body contour, subclinical anaemia, acne, anorexia etc. Schour and Massler (1943) remark that the dentist is confronted with problems of an increase in the incidence of dental caries, gingivitis, and even acute alveolar atrophy during this period of life.

Shafer, Hine and Levy (1963), remark that inflammatory gingival hyperplasia often occurs at puberty, particularly in girls. Some investigators believe it is due to an endocrine imbalance or re-adjustment in the endocrine balance at this particular stage of the patient's development. Others believe that at this stage, oral hygiene is poor, perhaps because of local irritation associated with tooth eruption. There may be nutritional inadequacies also so that the gingival condition may be only due to endocrine factors indirectly.

Engel (1952), refers to this not unusual generalised gingival hypertrophy in boys and girls, which he calls pubertal gingivitis. Coolidge (1941) cited several such cases. While this condition may be excited by poor oral hygiene of the hasty adolescent the predisposing factor, he states, is undoubtedly hormonal. The gingival condition is similar to that found in menstruation and pregnancy, and is transient, adjusting itself when the obscure endocrine imbalance corrects itself.

Ziskin and Silvers (1943) have described gingival lesions in young females of postpuberty age with varying stages of inflammation and hyperplasia.

Treatment, of pubertal gingivitis is best restricted to local measures, and removal of irritation causes, and restoration of oral hygiene. Mild astringents may help to some extent. Engel (1952)

Cohen and Goldman (1960) report a case of a girl at fourteen

years, who has not menstruated and was hypothyroid with low basal metabolic rate, who had a marked inflammatory hyperplasia of the gingivae. Thyroid therapy resulted in a substantial improvement. Such cases, they state are not uncommon.

Cohen and Goldman (1960) report two very interesting cases of systemic disease, difficult to define, but possibly an endocrine imbalance syndrome associated with the early postpuberal period, in a fifteen year old male, and sixteen year old female. Local therapy for gingivitis and periodontitis was unsuccessful until the systemic factors had been eliminated.

Puberty and Orthodontia.

Delayed puberty can result in definite changes affecting the dentist and orthodontist. Tager (1951) studied over 100 orthodontic cases, over a period of ten years for endocrine diseases, involving children aged nine to fifteen years. Approximately ten percent showed frank endocrinopathy. The greatest proportion of cases were under suspicion because of radiographic evidences of root resorption, alveolar osteoporosis, abnormalities of trabeculation of the bone or other evidence of bone dyscrasia. The impression was obtained that these changes were precipitated in a rapidly growing organism noteworthy by excessive acceleration of linear growth concomitant with a slow sexual maturation of puberty. This imbalance between somatic and sexual growth is a variant of the normal pubertal pattern and may be causative of skeletal defects as revealed by dental radiographs. The presence of hormone insufficiency as a possible cause, cannot be eliminated. See "Changes in the Oral Region", under Hypothyroidism.

MENSTRUATION.

The reproductive life of the human female is controlled primarily by the sex hormones. It commences with the first menstrual period (the menarche) during puberty (at twelve to fourteen years of age), and usually ends with the last menstrual cycle (the menopause) during the climacteric, (at 42-52 years of age). Both periods are accompanied by profound physical, mental and emotional changes which make each, a most trying time in the life of women. Massler (1951).

The menstrual period and its relation to systemic and dental health relate to the characteristic subclinical anaemia evidencing itself in pale gingivae and oral mucosa. Schour and Massler (1943).

Kutzleb (1957) refers to a condition of subacute gingivitis associated with the time immediately prior to menstruation (premenstrual tension).

The oral manifestations of menstruation, and the premenstrual tension period according to the literature would be; hyperaemia, of the dental pulp, (Thoma and Robinson 1955) which has been described as "menstrual toothache" (Norman 1959), (Mugnier 1959); swelling of the salivary glands, which according to Racine and quoted by Burket (1957), is due to a deficiency of the corpus luteum and is successfully treated with progesterone, (Knox 1957); pain, swelling and haemorrhage of the gingival which is described as stomatitis dysmenorrhoea; herpeslabialis and oral aphthous lesions.

Thoma and Robinson, (1955) stated that a cheilitis similar to that seen in vitamin B complex deficiency has been seen in patients with dysmenorrhoea. It may be associated with vaginitis and dermatitis, but usually there is no glossitis.

The association of outbreaks of aphthous ulceration with the onset of menstruation or the few days proceeding it, has long been recognised. Despite the apparent hormonal connection there is no definite explanation of the mechanism involved. Kronfield (1943), Thoma and Goldman (1960), Shafer, Hine and Levy (1963).

Page and Goode (1957), pointed out that cyclic neutropenia with oral ulceration may be associated with the menstrual cycle.

Moeller's glossitis is a rare chronic inflammation of the tongue characterised by the appearance of round patches which are tender, flat, and flabby, is said by some to be associated with hormonal factors in that it apparently becomes worse during menstrual periods and that there are remissions during pregnancy, Rattner (1947), Thoma and Goldman (1960).

Marked desquamation can be seen in buccal smears of women during the premenstrual period, Mugnier (1959), although the previous attempts to ascertain this by Papic and Glickman (1950), and Montgomery (1951), were unsuccessful. Such correlations between the gingival and vaginal mucosa changes during the female cycle, have been described by Nathansen and Weisberger (1939), Ziserman (1939), Jones (1940), and others.

Stomatitis Dysmenorrhoea.

This is a gingivitis that occurs periodically in patients with abnormal or difficult menstruation, and is due to endocrine dysfunction. It produces an oedema of the mucosa associated with hyperaemia and bleeding of the gingivae. Thoma and Goldman (1960).

A case of stomatitis intermenstrualis was described by Muhlemann (1948) in a 24 year old unmarried woman characterised by changes in the gingivae dependent on the rhythm of the menstrual cycle. These were either sharply defined cells without nuclei or less well marked polygenous cocci and other microorganisms. Other granular cells were found which stained violet with haematoxylin and eosin. The process in the pathogenesis of the gingivitis therefore is a desquamation extending into the stratum granulosum from which the last of these described cells are derived. Thoma and Goldman (1960) believe that this recurrent phenomenon is due to the hypophyseal gonadotrophic principle and is related to ovulation.

The clinical features of stomatitis dysmenorrhoea are hyperaemia and bleeding of the gingivae, habitual apthae, herpetic lesions, ptyalism (a case has been reported in which the increased salivation was so great that digestive disturbances resulted, Thoma and Goldman (1960). Biedle (1931), reports frequent gingivitis and

periodontal disturbance in women at such times. In some cases, the skin is affected as observed by Reifferscheich (1937), who described a case with itchy, reddish, urticarial and vesicular lesions about the mouth and chin. The forearms, back, and chest were also affected. There was oozing, crusting and pigmentation, and in the oral cavity the gingivae had a bloated congested appearance. Ziserman (1935), described a case in which just before menstruation, ulcers appeared on the gingivae and eventually healed without scarring. Goldman (Thoma and Goldman 1963), saw a 23 year old woman with dysmenorrhoea who periodically presented swollen, red gingivae, which was painful and bled easily when touched. The gingival margin projected from the teeth. Oestrogen was administered without giving marked relief.

Vicarious menstruation occurring in the mouth as well as in the uterus was described by Shelmire (1928) who presented a case of this unusual phenomenon.

Heinmann and Anderson (1945) reported a number of cases with case histories and careful physical examinations and treatment, given. One was an unmarried school teacher, 34 years of age, who had suffered from a very sore mouth and tongue for eight years, just prior to menstruation and occurring for a few days following it. Oestrogen administration (250,000 I. U. by mouth) brought relief within a few days. Heinmann and Anderson (1945) made the following comments in the treatment of stomatitis dysmenorrhoea;

1. The lesions could be reduced by oestrogen therapy, as above,
2. Temporary withdrawal resulted in recurrence of the stomatitis.
3. Dietary stilbestrol orally, 0.1mg dose for ten doses during one cycle failed to prevent development of the lesions,
4. A single intramuscular injection of progesterone caused an outbreak of lesions within 24 hours.

It seems that local gingival treatment is the best course to follow except in severe cases, when the above mentioned systemic therapy could be considered.

Menstruation and Dental Treatment;

The behaviour of the woman in the dental chair may be related to her menstrual cycle, (ed. Dental Digest, June 1960). Not only

does the menopause cause unusual behaviour and tension, but so does the premenstrual period. Premenstrual tension is common amongst women of child bearing age. It is related somehow to hormonal imbalance, and retention of fluid, which in turn is probably associated with the intake of sodium chloride. Whatever the mechanism, the syndrome is one of real distress to the patient who is not in the most ideal condition as a dental patient. Incidence varied from 95 percent of women in one study down to 36 percent in another. The author finds some 55 percent of patients involved in his practice. Appleby (1960), has described the condition and its management. Meprobamate, chlorothiazide, and progesterone derivatives have all been used to alleviate the condition. It is suggested that the dental assistant is in a favourable position to arrange appointments at favourable times for these patients, after questioning them as to their menstrual cycle. Thoma and Robinson (1955) also suggests this approach and states that only emergency treatment should be conducted in women during menstruation due to increased irritability. This, is especially true of the patient with disturbed menstruation. Some women have have an increased tendency to haemorrhage during menstruation, which may manifest itself with severe haemorrhage after extractions.

PREGNANCY.

Pregnancy involves profound hormonal changes and the associated problems of metabolism and diet, have been well recognised, and extensively studied. It is a period of physiologic, metabolic and psychic strain. The whole endocrine system is involved during pregnancy. There is evidence of heightened secretion of steroid hormones by the ovaries, adrenals, and placenta, and of increased production of anteriorpituitary like-hormones. In the later stages, the relaxation hormone (relaxin) may also be present. Engel (1952).

However, a good many misconceptions have arisen as to the effects of pregnancy on the teeth. Schour and Massler (1943). Hormonal upsets also occur at puberty and menstruation but are only of short duration which prevent extended manifestations to appear in the oral cavity. During pregnancy, the upsets last for a considerable period, hence the preponderance of oral conditions seen associated with it. Gridley (1954), Engel (1952), discusses at length the changes in connective tissue due to sex hormone blood level changes, as bearing on gingivitis.

In addition, the electrometric studies by Gans, Engel and Joseph, (1956), and histochemical studies by Turesky, Fisher and Glickman (1958), show that there are previously unknown, differences between the gingivae in pregnant, and non-pregnant individuals.

Gingivitis Gravidarum (Pregnancy Gingivitis).

This is a gingivitis beginning about the second month of pregnancy and lasting until the end of gestation, and even continuing during lactation. It is characterised by a stomatitis with varying degrees of hypertrophic gingivitis and so called "pregnancy tumours", Thoma and Goldman (1960).

The incidence of gingival changes during pregnancy, varies with reports, the average being about 50 percent.

Schmidt (1930) stated that pregnancy gingivitis occurs in about 50 percent of cases being due to either local causes or endocrine imbalances. Maier and Orban (1949), examined 530 cases, and found that nineteen percent had gingivitis, gravidarum and 0.5 percent

pregnancy tumour. Gridly (1954) examined 1,002 cases at the Obstetric Department of the University of Alexandria, Egypt, and found normal gingivae in fourteen percent, common gingivitis in 60 percent, gingivitis gravidarum in 23 percent, and pregnancy tumours in 2.7 percent. Hising (1952), studied 203 cases in Denmark, and found gingivitis gravidarum specific in 47 percent of cases, and gingivitis gravidarum non-specific in 53 percent. The condition was aggravated, he found, most during the eighth month, and was less aggravated in the ninth month. 29 percent of the cases of specific gingivitis gravidarum suffered lasting damage to the gingivae after parturition. He concluded that the majority of the 47 percent of cases of specific gingivitis gravidarum was an accentuation of another previous severe gingivitis.

Horsnell and Packer (1963), after examining 284 patients, at Queen Elizabeth Hospital, Woodville, South Australia, found the general periodontal condition poor, and a strong positive correlation between it and oral hygiene. They found no correlation between the periodontal conditions, and ascorbic acid blood levels. As no control group of non-parous women was examined simultaneously, it was not possible to state whether their periodontal index alteration arose directly from the pregnancy, or to associated conditions.

Kutaleb (1957) examined 427 pregnant women, and found 230 with gingivitis, 26 having serious complications.

Aetiology. It has been a subject of dispute for a long while whether the gingivitis gravidarum is due primarily to pregnancy or not. Cahn (1934) comments that it is usually associated with oral neglect during pregnancy together with mild systemic disturbances, and it does not occur in pregnant women with good systemic health and adequate oral hygiene.

Ziskin made several observations, and experiments (1933, 1937, 1938), and proved that the condition is caused by certain hormones. He injected follutin, and extract pregnancy urine, into normal female monkeys and produced conditions such as are seen in pregnancy gingivitis. (1938). He investigated in addition (1937) the effect of hormonal treatment in the gingivae and oral mucosa of six women. Three were injected with oestrogenic hormone, (progyon B) for

amenorrhoea, and then with extract of pregnancy urine (follutein) for prolonged bleeding (menstrual). The gingivae of the group receiving follutein showed swelling and an inflammation of a typical nature one of the patients presenting a Vincents infection (due to a possible predisposing relationship). Microscopic examination showed an inflammatory reaction and there was hydropic degeneration of the epithelium and destruction of keratin. The gingivae of the group receiving oestrogenic hormone were found to be in healthy condition, firm and not subject to easy bleeding on trauma. Biopsy showed the keratin layer in the gingivae to be firmer and definite; it did not strip off so easily as was the case in women receiving follutein. The prickle cell layer was thickened, and in all cases curls and pearls were seen in the alveolar gingivae. The oestrogenic group was therefore characterised by hyperkeratinisation and hyperplasia of the epithelium.

Maier and Urban (1949), who investigated a large number of cases histologically stated as a result that pregnancy cannot be regarded as an aetiological factor of gingivitis and that gingivitis in pregnancy cannot be regarded as specific. They felt that pregnancy is a conditioning factor, aggravating existing inflammatory changes in the majority of cases.

Hillming (1952), states that local irritation factors cannot be the cause of gingivitis gravidarum specific as the latter improves after parturition in spite of local factors being to the same extent still present. On the other hand, he states that local factors may condition gingival reactions and have an aggravating effect acting in connection with the primary aetiological factors. He found that vitamin C deficiency had no effect on the matter. He concluded that an hormonal aetiology was the primary factor in specific pregnancy gingivitis. This conclusion was also arrived at by Kutzleb (1957), following his examination of 230 cases of pregnancy gingivitis.

Gorvey (1954) presented a theory that the embryo activates all the tissues of the gravid woman, which are then influenced by the hormones.

Clinical Features; Ziskin (1938) classified the gingival upsets due to the imbalance of the sex-related hormones into five clinical classes;

1. The bleeding gingivae, with no other manifestations,
2. The mildly puffed gingivae,
3. The raspberry-red gingivae,
4. The hypertrophic gingivitis of pregnancy,
5. The pregnancy tumour.

Hilming (1952) made a similar classification;

No symptoms are to be found in cases of specific pregnancy gingivitis which cannot be found in cases of non-specific pregnancy gingivitis, as well as in the gingivitis of non-pregnant women. Ziskin et al (1933, 1946), Maier and Orban (1948, 1949), Hilming (1952).

Hilming (1952) adds that there are however, certain characteristic features in the symptomatology, the most common by far being subacute inflammation of the gingivae, hyperaemia and a tendency towards bleeding, which presumably commences early. The raspberry-red gums of excessive hyperaemia is perhaps the most characteristic phenomenon. Hypertrophy of the gingivae does not seem to be as characteristic a manifestation as was formerly believed, since about half of the cases examined did not show it. Vigorous hypertrophy appeared in about one quarter of the cases (so called epulis gravidarum or pregnancy tumours) which is in agreement with Maier and Orban (1948, 1949).

Gridley (1954) commenting on Ziskin's classification (1938), remarked that only the last two mentioned types of gingivitis could be considered due to pregnancy specifically, i.e. the hypertrophic gingivitis of pregnancy, and the pregnancy tumour. He said that on biopsy both of these conditions present the same picture, the only difference lying in the localisation and diffusibility of the lesion.

The buccal mucosa as well as the gingivae are affected in pregnancy and have been discussed by Mugnier (1959). He states that the buccal mucosa in pregnant women presents cyclic changes

analogous to those of the vaginal mucosa, but more discreet. Both are influenced by hormonal stimulation. Buccal smears, revealed thickening of the chorion and epithelium and intense vascularisation with tendency towards oedema. All pregnant women present some structural change in the buccal mucosa but not all have the gingivitis of pregnancy.

Johnanson (1955), described a case of primigravida with no evidence of a blood dyscrasia, who suffered two severe haemorrhagic episodes orally prior to labour which he considers was due to an alteration in the hormone level in the blood.

Gingivitis gravidarum usually subsides suddenly in a matter of days after delivery, often after the first appearance of milk. It disappears without leaving a trace provided there was no previous periodontal lesion. Mugnier (1959), Hilming (1952), remarks that in his studies there was a marked amelioration of the gingivitis during the ninth month of pregnancy. This occurred in about half of the cases of specific gingivitis/pregnancy, and may have some bearing on Ziskin and Nesse's (1946), demonstration of the re-appearance of slight keratinisation of the epithelium in most of their cases in the ninth month. The amelioration that takes place, after delivery is often very considerable.

Histopathology: The gingiva~~s~~ shows widely dilated blood vessels, and marked inflammatory infiltration. There is evidence of tissue proliferation characterised by numerous mitotic figures in the epithelium as well as in the endothelium and connective tissue, (fibroblasts). Thoma and Goldman (1960), Shafer, Hine and Levy, (1963) adds that diagnosis of the aetiological factors cannot be made by microscopic study.

Gridly (1954), remarks that the blood vessels of the corium may become so numerous that a diagnosis of haemangiomatous epulis or haemangioma may be made by the histopathologist, in cases of hypertrophy.

The histpathologic changes in mild, moderate, and severe pregnancy gingivitis has been extensively studied by Maier and Orban (1949), Biopsy of the interdental papilla between the lower right

canine and incisor of a six months pregnant woman with swollen, cyanotic, purple red-edged, irregular gingivae revealed on microscopic examination an epithelial covering grooved at the surface partly destroyed by ulceration. The stratum spinosum showed hydropic degeneration while the basal layer was thickened with proliferation. The superficial vessels were thrombosed and surrounded by a heavy exudate. The endothelial cells were also swollen and contained numerous leucocytes. Mitotic figures in the endothelial cells indicated proliferation. The specimen gives the impression that we are dealing with a chronic fibrous type of inflammation.

Pregnancy Tumours.

There are an inflammatory hyperplasia of the gingivae, and are simply a severe form of the usual hypertrophy of pregnancy gingivitis Blum (1931), Gridly (1954), Gridly designates the lesion a "pregulis". Salman and Langel (1954) state they resemble a peripheral giant-cell tumour. Fabe (1954), refers to them as a form of cavernous haemangioma, Shafer, Hine and Levy (1963), as a pyogenic granuloma, and Thoma (1963) as a fibrohaemangioma.

Gridly (1954), remarks that the site of pregnancy tumours may be predetermined by some previous irritation or infection involving the interdental papilla, which may be done by tooth brushing, trauma, mouth breathing etc. He also states that the three main histopathological findings in a "pregulis" are an increase in the number of prickle cells, the absence of hydropic spaces in, and between the prickle cells and a corium rich in blood vessels. This is to be distinguished from a true fibrous epulis.

Gridly (1954) also remarks that following the examination of 27 pregnancy tumours, he concluded that the average age of occurrence was 27 years, average time commencement of the tumour, was the 25th week of pregnancy as noticed by the patient, and it occurred on the average on the fourth or fifth pregnancy (only in four cases did it appear in primiparas), the site of the tumour was in the front of the mouth in 85 percent, on the labial side of the teeth in 63 percent, both labial and lingial, 18.5 percent.

Pregnancy tumours are usually pedunculated and show a tendency to bleed easily, and may occur singly or in multiple forms, Thoma and Goldman (1960).

Malignant transformation of pregnancy tumours occurs occasionally. Thoma (1963). Sarcany (1950) reports such a case in a 21 year old woman, which after radical removal, was found to be a macrofusocellular sarcoma. It must be kept in mind that the growth of incipient malignant tumours may become accelerated by hormonal stimulation.

Salman and Langel (1954) remark that pregnancy tumours, generally disappear after parturition. However, if they had developed into pedunculated growths, they may recede after parturition, but usually not completely so. Faber (1954), refers to such a case, one of peculiar interest, because of its size, course and association with a former naevus, which did not recede spontaneously after seven months postpartum.

Thoma (1952), reports a case of an epileptic woman with a naevus on the face, treated for multiple pregnancy tumours. This was a case of Sturge-Kalisher-Weber Syndrome first described by Sturge (1879), and Kalisher (1901) and Weber (1922). It is thought that the vascular dysplasia of the gingival lesions is part of the syndrome. Weber's hypothesis was that the disease is present, congenitally, but only manifesting itself when aroused by some agency, which in this case would be hormonal.

Treatment of Stomatitis Gravidarum, and Pregnancy Tumours.

Ziskin (1937) recommended the use of oestrogenic hormone to correct the gingival conditions described, but this type of therapy is still in its experimental stage even today, Thoma and Goldman (1960). It has generally been regarded that the condition requires little or no treatment due to the expected disappearance after parturition. However, as Hilming (1952), points out, certain of the specific cases of pregnancy gingivitis leave permanent aggravation of the gingivae behind, even though there is some improvement after parturition. He recommends that treatment should commence at once with all means at hand.

Pregnancy tumours should be excised before parturition if they interfere with mastication or for other reasons, but after parturition is the best time for surgery, to avoid the possibility of recurrence. Electrosurgery is the best method, Salman and Langel (1954), Thoma (1963). Hamilton (1950) cites a case of a woman, with a large pregnancy tumour in the lower anterior region, who had similar tumours twice previously, which were surgically removed during pregnancy, but recurred after. The third one was surgically removed three months postpartum with success. Grich, (1950) describes a case of pregnancy tumour removed surgically with no recurrence.

It seems clear that in cases of the usual gingivitis gravidarum, local periodontal treatment is best advised, and the removal of all sources or irritation from the mouth, such as infection, caries, sharp edges, and tooth or filling, and ill-fitting dentures. Scrupulous oral hygiene is to be insisted upon. (See section under "Pregnancy and Dental Treatment").

Pregnancy and Salivation.

Increased salivation during pregnancy though common, is not of great significance, except that it may be troublesome to the dentist in operative work. The pH of saliva tends to become more acid, being almost usually below 7.0 during pregnancy. As to the possibility of a pregnancy test on saliva two separate studies have shown that no positive reaction can be obtained until the sixth or seventh month and then only if the foetus is male. During the last two weeks of pregnancy, chemical changes disturb this reaction, Magnier (1959), Rogers and Keen (1954).

Pregnancy and the Skin.

The modification of skin diseases during pregnancy is seldom striking. Less skin troubles occur during it than before it, with a few curious exceptions, affecting about 0.5 percent of patients. Pregnancy usually seems to have a beneficial effect on chronic acne, though occasionally the reverse is seen, when acne may occur from the first trimester till early puerperium. The melanocytes of the

skin seem to become active during pregnancy, possibly because of increased secretion, of pituitary MSH (melanin stimulating hormone) although progesterone and the androgens stimulate melanocytes also. Localised patchy pigmentation occurs at times on the cheeks, forehead and neck and seldom fades entirely after delivery. Enlargement or darkening of existing moles may also occur. It is fairly generally agreed that only one skin disease, herpes gestationis, is peculiar to pregnancy. It may begin during the third or fourth month and clears promptly on termination of pregnancy, Arnold (1961, 1963).

Pregnancy and Dental Caries.

There has been a good deal of confusion as to this relationship. The often repeated, though correct, saying "a tooth for every child" by both the medical and dental profession has left wrong notions in the minds of many persons. The "tooth for every child" aphorism was originally based on a number of erroneous concepts which have since been corrected by scientific investigation. The first of these is that there is calcium withdrawn from the teeth as well as the bone, which indicates ignorance as to the fundamental differences between the vascular bone, and avascular and acellular dentine and enamel of teeth. Another misconception is that caries is related to calcium metabolism. It is true that there is increased calcium demands on the mother during pregnancy, and there is a low calcium blood level, but the amount needed by the foetus is relatively small. The body of a full term infant weighing 3,000Gm contained approximately 24Gm of calcium. The average woman has from 2,000 to 2,500Gm of calcium of which 97 to 98 percent, is in the bones and less than one percent in the teeth. However, it is recommended that the calcium intake of the pregnant woman is maintained at a minimum of 1.5 Gm/day. It may be that the alveolar bone would suffer first, due to its viability, if there is any calcium deficiency. However, dental radiographs do not indicate that there is any bone destruction during pregnancy, Schour and Massler (1943).

Therefore while some maintain this, there is an increase in caries, during pregnancy, such as Gerson (1921), most feel that there is not.

Ziskin (1926) proved that clinical investigations showed that caries was no more prevalent in pregnant than non-pregnant women. When caries does occur during pregnancy, it can be almost always be related to poor oral hygiene associated with the presence of sordes and acid metabolites from the nausea and vomiting of pregnancy. Schour and Massler (1943).

The studies of Ziskin (1926) were on a group of 599 pregnant women most of whom were in the latter months of pregnancy, and a group of 205 nulliparous women. He found that the caries experience of the pregnant women increased with the age of the patient at a rate comparable to the nulliparous women. He found no relation between dental caries and pregnancy, or the number of pregnancies. He even pointed out that the slightly lower caries value in the pregnant group than the non-pregnant group, suggests a slight protection against caries.

Deakins (1943) and Deakins and Looby (1943) studied the specific gravity of dentine as an indication of its mineral content and found that there was no significant difference between pregnant and non-pregnant women's dentine in carious teeth. They concluded that there was no calcium withdrawal from sound dentine during pregnancy. A similar study was carried out by Dragiff and Karshan and Karshan (1943) using direct analysis of ash, with similar results. It is a fairly common clinical observation that a woman during the latter stages of pregnancy, or shortly after delivery, will manifest a significant increase in caries activity. In nearly all cases through questioning will reveal oral neglect because of the pressure on the mother's time attendant to the birth and care of the baby. Shafer, Hine and Levy (1963).

Mugnier (1959), state that various authors who have studied the problems of dental health in relation to maternity have concluded that 50 to 90 percent of pregnant women seen in maternity hospitals or clinics present a poor buccodental state. It is also generally agreed he states that calcium therapy is of little value in protecting the mother's teeth, but an adequate supply of calcium, phosphorus and fluoride in the maternal diet may have real significance for the foetus.

Another fact which most authors confirm, is that toothache, and caries is aggravated often during pregnancy. These observations seem to depend on neurovegetative dystonias and congestive disturbances with gingival and pulpal involvement. These effects seem to be more prevalent in women with less tolerance to hormonal imbalance. A woman who had toothache and gingival congestion during each premenstrual period had also these symptoms during pregnancy. Mugnier (1959), Pfeffer (1960).

It is of interest to note a very recent study on the problem of caries and pregnancy by Horsnell and Packer (1963). This study which included 284 patients, who were dentally examined in the second trimester of pregnancy, showed an increase in caries incidence throughout pregnancy. The average increase in DMF, was 0.75. They state that it was not possible to ascertain whether this was due directly to the pregnancy, or to its associated conditions. Their study also showed a greater incidence in caries in the first six postnatal months, than during pregnancy.

The conclusions reached from these observations, is that directly, pregnancy causes no increase in caries, but that it may do indirectly. It seems possible, that the gingival changes during pregnancy, would contribute to an increase in caries incidence.

Pregnancy and Alveolar Bone.

Demineralisation of the alveolar process is possible during pregnancy due to calcium deficiency, when calcium is absorbed from the mother's bone in the latter months. The alveolar bone is more viable, than most bone in the body, and effects of demineralisation possibly manifest themselves there first. If there is the normal calcium intake, no bone demineralisation will occur. Schour and Massler (1943), Rogers and Kean (1954).

Pregnancy and Dental Treatment.

Good oral hygiene is the best protection against the development of periodontal lesions and caries during pregnancy. Rogers and Kean (1954). It is generally advised that no dental treatment be carried out on pregnant women of a routine nature during the first

two to three months, Rogers and Kean (1954), Mugnier (1959), Pfeffer (1960). The most suitable time seems to be from the fourth to seventh month. All necessary conservative work should be completed, the appointments being of short duration and local anaesthesia used to lessen nervous strain, Rogers and Kean (1954), Pfeffer (1960). Thoma and Robinson (1955), state that in early pregnancy, but not during periods of nausea, the expectant mother should have a complete oral examination. All areas of dental and periodontal infection should be removed.

Tooth extractions should be done serially with local anaesthesia, and not general anaesthesia which is best avoided except in extreme cases.

General anaesthesia should not be administered except after consulting with the patient's physician, Thoma and Robinson (1955). Only "necessary" extractions should be done. There is a risk of abortion following extractions during the first three months. Extractions should be avoided if possible in patients with an acute infection, chronic nephritis, cardiac decompensation, diabetes or hypothyroidism in association with pregnancy. He is advised that the obstetrician be consulted in these cases. Some writers advise penicillin preoperatively. Rogers, and Kean (1954), Mugnier, (1959).

Oral foci of infection should be removed during pregnancy. If the patient is seen first in late pregnancy, it is best to eliminate oral sepsis by removal of gross caries and insert temporary dressings. Rogers and Kean (1954), Pfeffer (1960), Robinson (1961).

Radiographic examinations of the teeth need not be delayed till after pregnancy. By using fast film, and reducing the exposure time to a minimum, the risk of radiation of the pelvic region is practically nil, Pfeffer (1960).

Masticatory efficiency is important during pregnancy, for normal nutrition and body functioning. Satisfactory dentures should be constructed in edentulous patients if existing ones are inefficient, Rogers and Kean (1954).

Good dental health is essential for the complete nutrition of the mother and the child, while ill-health can be detrimental or even dangerous. Oral sepsis remaining during pregnancy may cause

bacteraemic nephritis, eclampsia and also predisposes the mother to puerperal sepsis immediately after birth. Rogers and Kean (1954).

Horsnell and Packer (1963) remark that this is an obvious need for greater collaboration between the medical advisors of pregnant women, and the dental profession - and they emphasise the need for instituting dental treatment, because of the increase, they state, of caries and periodontal conditions that occur, and the tendency for many of these patients not to undergo treatment.

LACTATION.

Hunscher (1930) studied calcium and phosphorus metabolism in three women during two successive lactations, and in addition, carried out complete oral examinations. He found no changes in caries activity during lactation.

Horsnell and Packer, (1963), found that there is an increase in caries for the first six months, greater than during pregnancy. However, this is probably due to oral hygiene neglect, due to extra demands made on the mother's time in caring for the infant. Studies relating to lactation and caries incidence are too few, to contribute any significant data, for clarifying the problem. Shafer, Hine and Levy, (1963).

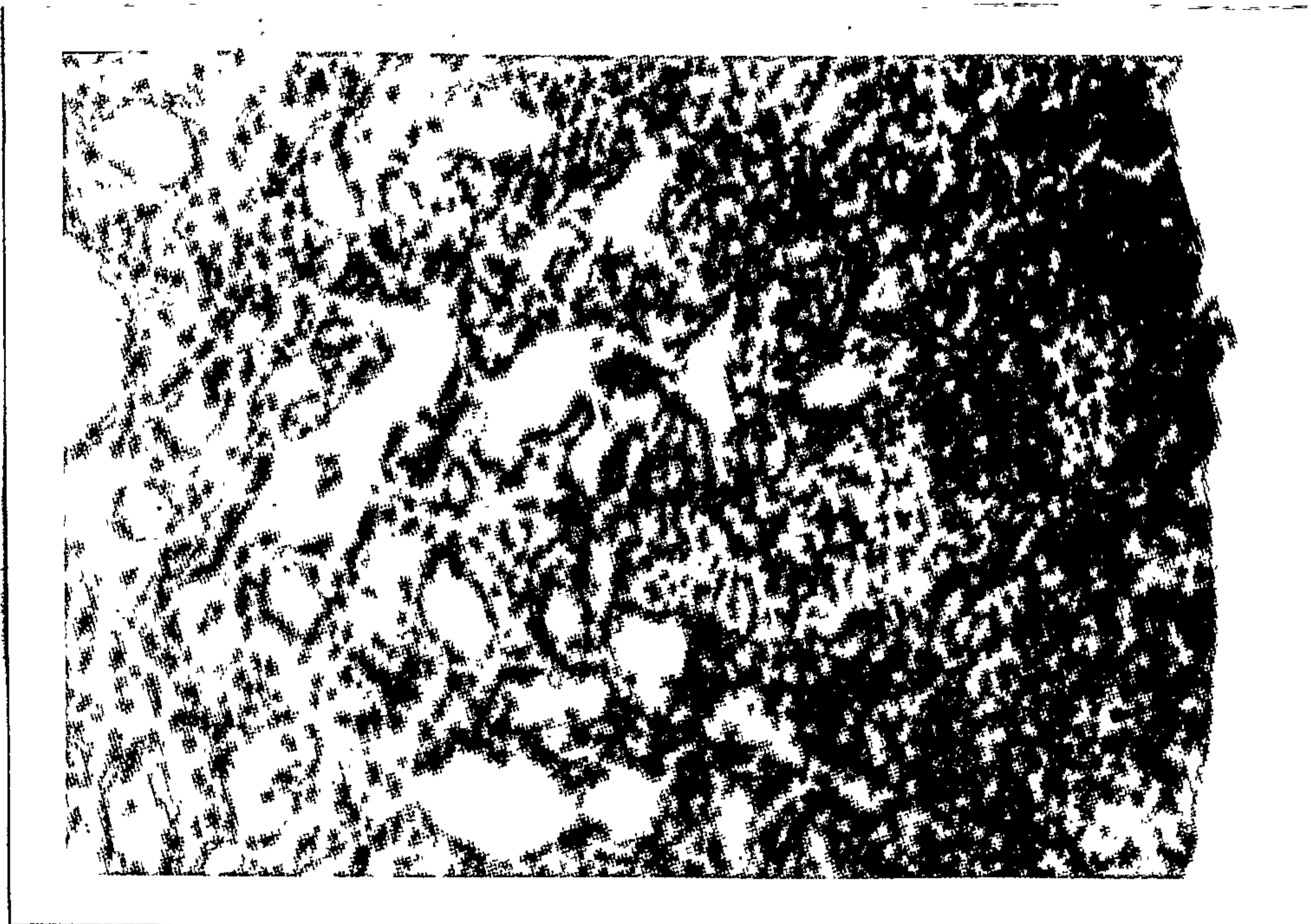


Fig. 34

Hormonal enlargement of Gingival papilla as seen in puberty, menstruation and pregnancy at times. X 90. Note vascularity of the tissues. Colby, Kerr, and Robinson (1961).




Fig. 35

Chronic Desquamative Gingivitis. Specimen from edge of red area on gingivae. X 100. Note intense inflammatory infiltrate extending to surface making it difficult to distinguish between epithelium and corium. No epithelium remaining on left side, which has reddened.

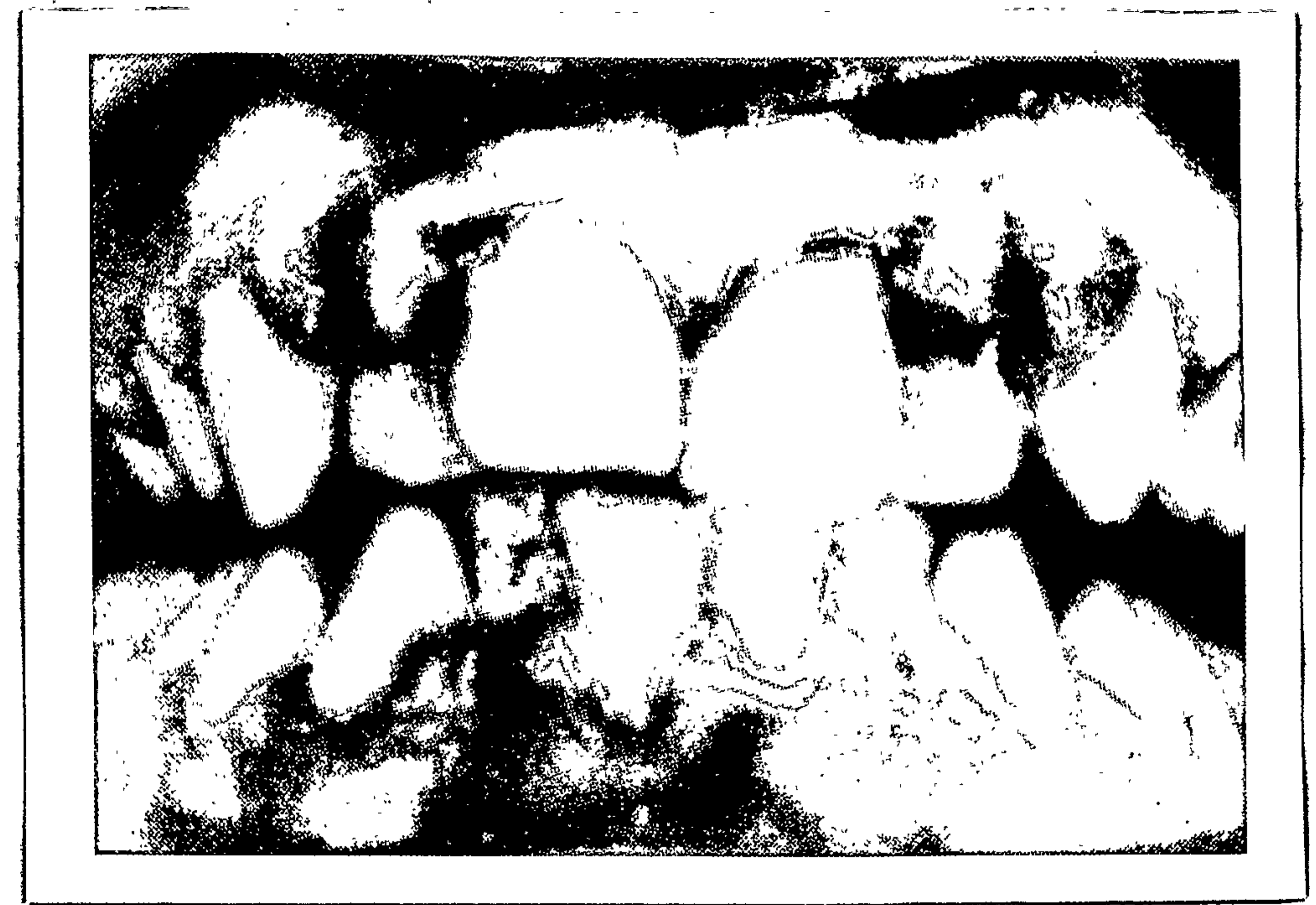

Fig. 32

Pregnancy; hypertrophic gingival enlargement which subsided after parturition. Colby, Kerr, Robinson (1961).

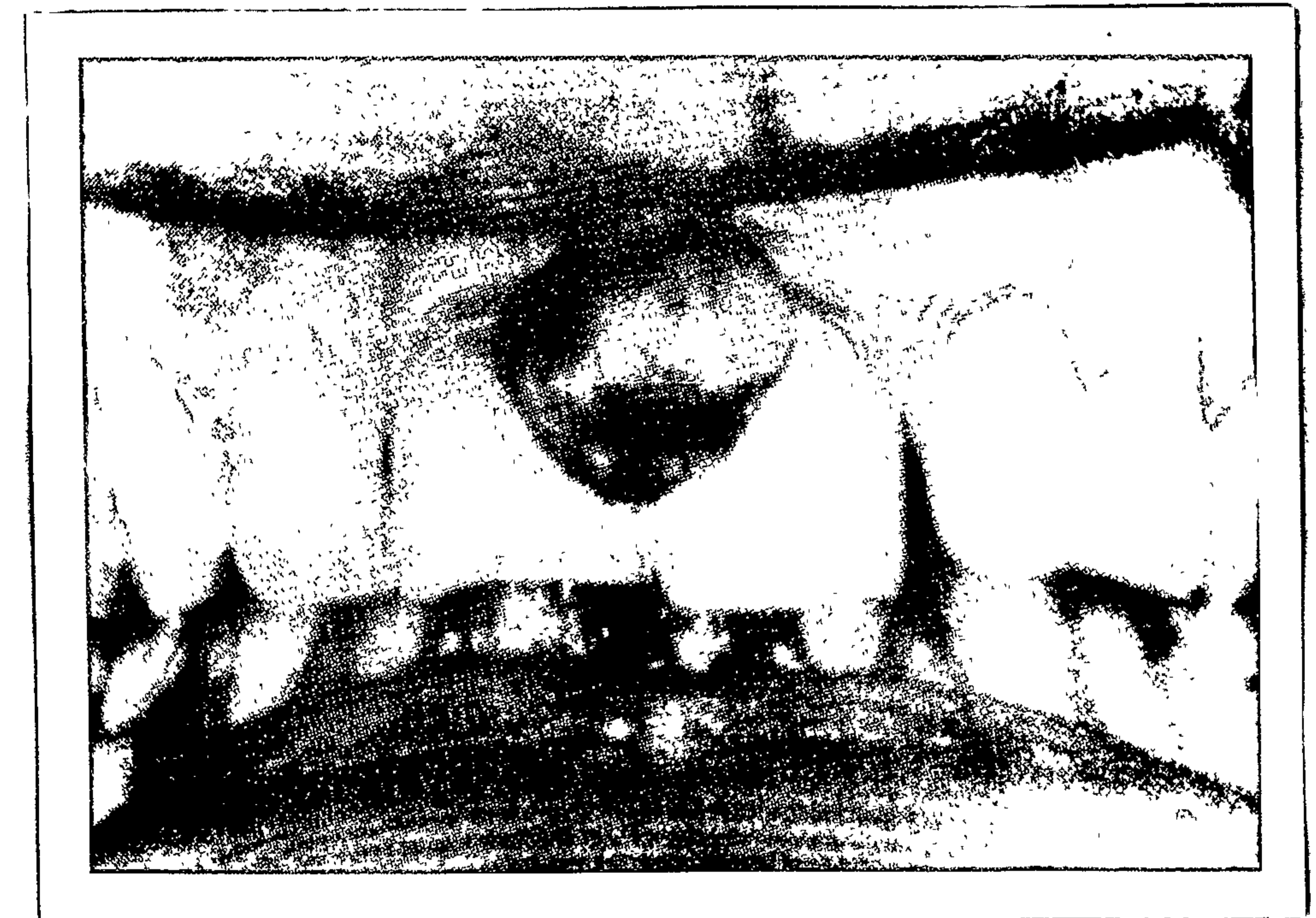

Fig. 33

Pregnancy Tumor. Two months post-partum. The pre-existing gingivitis had subsided and the lesion had decreased in size.

Colby, Kerr, and Robinson (1961).



Fig. 36

Chronic Desquamative Gingivitis. Note whitened areas of desquamated epithelium, and denuded darker (reddened) areas adjacent. See Fig. 35.

Colby, Kerr, and Robinson (1961).



Fig. 37

Chronic atrophic senile gingivitis in a post-menopausal woman. Note hyperkeratosis.

Colby, Kerr, and Robinson (1961).