

THE VASCULAR RESPONSE IN CHRONIC PERIODONTITIS

By

Hans Zoellner

*(see inside back cover
for emendations)*


*A thesis submitted in fulfilment of
the requirements for the degree of
Doctor of Philosophy*

DEPARTMENT OF
PREVENTIVE DENTISTRY

THE UNIVERSITY
OF SYDNEY

July 1990

© Hans Zoellner



ACKNOWLEDGEMENTS

There are many people who have given their time and advice, to assist me with this work. I am most grateful for their help, as well as for the friendship and camaraderie offered me by fellow investigators.

In particular, I wish to thank my supervisor Dr Neil Hunter, for his patient support and advice. His enthusiasm for the study of biology has been both infectious and inspiring. Also I must thank Professor K Knox, the director of the Institute of Dental Research, for allowing me the use of the Institute's facilities. Other Institute staff members who I wish to thank are: Dr T Higgins for his help in obtaining biopsies, Dr P Giffard for a gentle introduction to the mysteries of molecular biology; Dr N Jacques for his help in the preparation of manuscripts, Dr N Boyd for his interest, Mr P Williams for his assistance with experimental animals and Ms C Crocker for her help in the library.

I thank both Professor R O'Grady of the Dep of Cell Pathology at the University of Technology and Dr J Gibbins of the Dep of Pathology in the University of Sydney, for their unfailing encouragement. Also, I wish to thank Dr L Van Der Loon, Dr M Vesk and Mr T Joyce of the Electron Microscope Unit, and Mr E Smyth and Mr K Tsew of the Dep of Pathology, in the University of Sydney for their help with a range of procedures.

I am grateful for the advice of Dr O Dent of the Australian National University, which was most valuable in dealing with statistical problems.

Further, I thank Dr F Lee of the DNAX Research Institute Palo Alto for the generous gift of the plasmid pcD-hGM-CSF. Dr McCarthy and Professor Ng of the Department of Anatomical Pathology at the Royal Prince Alfred Hospital were also most helpful in providing paraffin blocks of human lymph nodes.

The support of the National Health and Medical Research Council, as well as of the Australian Dental Research Fund is gratefully acknowledged.

Finally, I thank my wife, children and parents, who have too often been without husband, father and son, in granting me the time to proceed with this work.

CONTENTS

Page Number

ACKNOWLEDGEMENTS

LISTS AND DECLARATION:

<i>Abbreviations</i>	L.1
<i>List of Tables</i>	L.2
<i>List of Figures</i>	L.3
<i>Publications of Work Described in this Thesis</i>	L.7
<i>Declaration</i>	L.7

SUMMARY S.1

CHAPTER 1: Vascular Endothelial Cells in Inflammation and Immunity 1.1

<i>Introduction</i>	1.1
<i>Angiogenesis</i>	1.2
<i>The Binding of Leukocytes to Endothelial Cells</i>	1.9
<i>Cytokines Made by Endothelial Cells</i>	1.15
<i>Questions Arising From The Literature</i>	1.17

CHAPTER 2: Periodontitis: Example of a Chronic Inflammatory Disease 2.1

<i>Introduction</i>	2.1
<i>Forms of Periodontitis</i>	2.4
<i>The Microbial Flora in Periodontitis</i>	2.6
<i>Role of the Immune Response in Periodontitis</i>	2.9
<i>Pocket Deepening</i>	2.11
<i>Questions Arising From the Literature</i>	2.12

CHAPTER 3: Expansion of the Vasculature with Periodontitis 3.1

<i>Introduction</i>	3.1
<i>Literature Review</i>	3.1
<i>Materials and Methods</i>	3.5
<i>Results</i>	3.8
<i>Discussion</i>	3.11

CHAPTER 4: Perivascular Hyaline Material in Inflamed Gingival Tissues 4.1

<i>Introduction</i>	4.1
<i>Literature Review</i>	4.1
<i>Materials and Methods</i>	4.3
<i>Results</i>	4.5
<i>Discussion</i>	4.7

CHAPTER 5: High Endothelial Like Venules in Gingival Tissues Exchange Polymorphs

<i>Introduction</i>	5.1
<i>Literature Review</i>	5.1
<i>Materials and Methods</i>	5.11
<i>Results</i>	5.14
<i>Discussion</i>	5.17

CHAPTER 6: Identification of the Endothelial Isoenzyme of Alkaline Phosphatase

<i>Introduction</i>	6.1
<i>Literature Review</i>	6.2
<i>Materials and Methods</i>	6.10
<i>Results</i>	6.13
<i>Discussion</i>	6.15

CHAPTER 7: Isolation and Culture of High Endothelial Cells

<i>Introduction and Literature Review</i>	7.1
<i>Materials, Methods and Results</i>	7.3
<i>Discussion</i>	7.16

CHAPTER 8: General Discussion: The Direction of Future Work

<i>Introduction</i>	8.1
<i>Endothelial Cells as Scavengers of Bacterial Products</i>	8.3
<i>Angiogenesis and Periodontal Pathogens</i>	8.4
<i>Perivascular Hyaline Material</i>	8.5
<i>High Endothelial Cell Culture</i>	8.8

APPENDIX: In Situ Hybridization

<i>Introduction</i>	A.1
<i>Materials and Methods</i>	A.3
<i>Results</i>	A.14
<i>Discussion</i>	A:15

REFERENCES

LISTS

LIST OF ABBREVIATIONS

AA	Actinobacillus actinomycetemcomitans
AP	Alkaline Phosphatase
APA	Alkaline Phosphatase Activity
BFGF	Basic Fibroblast Growth Factor
BL	Basal Lamina
BSA	Bovine Serum Albumin
CAP	Chronic Adult Periodontitis
CPM	Counts per Minute
CTEP	Collagenase Trypsin Enzyme Preparation
DEPC	Diethyl-pyrocarbonate
DPB	Dulbeco's Phosphate Buffered Saline
DS1	Diluting Solution for Percoll
E. Coli	Escherichia coli
EC	Endothelial Cell
ECM	Extracellular Matrix
FCS	Foetal Calf Serum
FEV	Flat Endothelial Vessel
FMLP	N-Formyl-L-Methionyl-L-Phenylalanine
FVIII	Factor VIII Associated Antigen
G-CSF	Granulocyte Colony Stimulating Factor
g-Inf	Gamma-Interferon
GJP	Generalized Juvenile Periodontitis
GM-CSF	Granulocyte-Macrophage Colony Stimulating Factor
HEC	High Endothelial Cell
HELV	High Endothelial Like Venule
HEV	High Endothelial Venule
IL1 α	Interleukin 1 alpha
IL1 β	Interleukin 1 beta
IL6	Interleukin-6
LFA-1	Lymphocyte Function Associated Antigen -1
LJP	Localised Juvenile Periodontitis
LBK	Liver/Bone/Kidney Isoenzyme of Alkaline Phosphatase
LPS	Lipopolysaccharide
Mab	Monoclonal Antibody
MBL	Multiple Basal Lamina
M-CSF	Macrophage Colony Stimulating Factor
MEV	Moderately High Endothelial Vessel
MF	36,000 Mr Macrophage Factor
Multi-CSF	Multi-Colony Stimulating Factor
PHEC	Periodontal High Endothelial Cell
PHLV	Periodontal High Endothelial Like Venule
PHyM	Perivascular Hyaline Material
PMN	Polymorphonuclear Leukocyte
PPME	Mannose-6-phosphate Rich Polysaccharide
RPP	Rapidly Progressive Periodontitis
SSC	Sodium Chloride-Sodium Citrate
SIP	Standard Isotonic Percoll Solution
TAF	Tumour Angiogenesis Factor
TE	Tris-EDTA
TBE	Tris-Borate-EDTA
TNF	Tumour Necrosis Factor

N.B. The suffix "s" following an abbreviation indicates the plural.

LIST OF TABLES

Table Number

CHAPTER 5:

*Results of Histochemical and Autoradiographic Studies
Comparing Periodontal High Endothelial Like Venules with
Lymph Node High Endothelial Venules.* 5.1

*Summary of the Data Derived from the Quantitative
Assessment of Leukocyte Emigration* 5.2

CHAPTER 6:

*Significance of Relative Differences in Percentage
Inhibition of Each Type of Alkaline Phosphatase Studied* 6.1

CHAPTER 7:

*Distribution of Radioactive Sulphate Through Centrifuge
Tubes with Different Starting Densities of Percoll* 7.1

LIST OF FIGURES

CHAPTER 2:	Figure Number
<i>Diagram of Periodontal Tissues in Health, and with Gingivitis and Periodontitis</i>	2.1
<i>Colour Photograph of Tooth with Periodontitis</i>	2.2a
<i>Colour Photograph of Tooth with Periodontitis with a Periodontal Probe Inserted into the Pocket Space</i>	2.2b
<i>Low Power Photomicrograph of a Gingival Biopsy From a Patient With Periodontitis</i>	2.3
<i>Electron Micrograph of Degenerate Plasma Cells in a Periodontal Lesion</i>	2.4
<i>Electron Micrograph of Bacterial Plaque in a Periodontal Pocket</i>	2.5
CHAPTER 3:	
<i>Diagram showing Division of Gingival Biopsies into Five Fields</i>	3.1
<i>Photomicrograph of a Periodontal High Endothelial Like Venules in a Gingival Biopsy</i>	3.2a
<i>Photomicrograph of Deep Gingival Venules with Alkaline Phosphatase Activity</i>	3.2b
<i>Photomicrograph of Flat Endothelial Vessels, Moderately High Endothelial Vessels and Periodontal High Endothelial Like Venules</i>	3.2c
<i>Photomicrograph of Vessels Labelled for Size</i>	3.2d
<i>Photomicrograph of Field 1 in Minimally Inflamed Tissue</i>	3.3a
<i>Photomicrograph of Field 1 in Periodontitis</i>	3.3b
<i>Photomicrograph of Field 2 in Periodontitis</i>	3.3c
<i>Photomicrograph of Field 3 in Periodontitis</i>	3.3d
<i>Photomicrograph of Field 4 in Periodontitis</i>	3.3e
<i>Photomicrograph of Field 5 in Periodontitis</i>	3.3f
<i>Number of Vessel Profiles in Each Type of Lesion</i>	3.4
<i>Size of Vessels in all Fields and Lesions Studied</i>	3.5

<i>Percentage Distribution of Vessel Types in all Fields and Lesions Studied</i>	3.6
--	-----

CHAPTER 4:

<i>Photomicrograph of Perivascular Hyaline Material</i>	4.1
<i>Photomicrograph of Perivascular Hyaline Material</i>	4.2
<i>Scattergram of the Distribution and Incidence of Perivascular Hyaline Material</i>	4.3
<i>Relative Percentage of Vessels affected with Perivascular Hyaline Material</i>	4.4
<i>Low Power Electronmicrograph of Perivascular Hyaline Material</i>	4.5
<i>Electronmicrograph of Perivascular Hyaline Material</i>	4.6
<i>Electronmicrograph of Perivascular Hyaline Material</i>	4.7
<i>Electronmicrograph of Perivascular Hyaline Material</i>	4.8
<i>Photomicrograph of Anti-Type IV Collagen Stain</i>	4.9
<i>Photomicrograph of Control for Anti-Type IV Collagen Stain</i>	4.10
<i>Photomicrograph of Anti-Keratin Stain</i>	4.11
<i>Photomicrograph of Anti-FVIII Stain</i>	4.12
<i>Photomicrograph of Control Stain</i>	4.13
<i>Diagram of Hypothesis of the Role of Perivascular Hyaline Material in Pocket Deepening</i>	4.14

CHAPTER 5:

<i>Photomicrograph of Typical Periodontal High Endothelial Like Venule</i>	5.1
<i>Autoradiograph of Rat Lymph Node Pulsed with Radioactive Sulphate</i>	5.2a
<i>Control Autoradiograph of Rat Lymph Node Tissue</i>	5.2b
<i>Autoradiograph of Periodontal High Endothelial Like Venule Pulsed with Sulphate</i>	5.2c

<i>Control Autoradiograph of Periodontal High Endothelial Like Venule Pulsed with Sulphate</i>	5.2d
<i>Percentage Distribution of Vessels with Flat and High Endothelial Cells, as well as of Intravascular Leukocytes</i>	5.3
<i>Percentage Distribution of Leukocytes in Periodontal High Endothelial Like Venules</i>	5.4
<i>Electronmicrograph of a Periodontal High Endothelial Like Venule</i>	5.5
<i>Electronmicrograph of a Periodontal High Endothelial Like Venule</i>	5.6

CHAPTER 6:

<i>Colour Photomicrograph of a Small Gingival Vessel Stained For Alkaline Phosphatase Activity</i>	6.1
<i>Colour Photomicrograph of Gingival Vessels Scored of Alkaline Phosphatase Activity Intensity</i>	6.2
<i>Composite Colour Photomicrograph of Rat Small Intestinal and Kidney Tissues Stained for Alkaline Phosphatase Activity at varying degrees of intensity</i>	6.3
<i>Inhibitor Profile of Endothelial Cell Alkaline Phosphatase Activity in Gingival and Rat Lymph Node Tissues</i>	6.4
<i>Inhibitor Profile of Rat Endothelial Cell Alkaline Phosphatase Activity and Rat Kidney Alkaline Phosphatase Activity</i>	6.5
<i>Inhibitor Profile of Rat Endothelial Cell Alkaline Phosphatase Activity and Rat Small Intestinal Alkaline Phosphatase Activity</i>	6.6

*Composite Photomicrograph of gingival blood vessels,
Rat Lymph Node Blood Vessels, Rat Kidney and Rat Small
Intestine, Stained for Alkaline Phosphatase Activity
in the Presence of the Inhibitors EDTA and Levamisole* 6.7

CHAPTER 7:

*Flow Diagram of Strategy for Isolating and
Culturing HECs* 7.1

*Composite Photomicrograph a section of Rat Lymph
Node and of Lymph Node Cell Preparations Stained
for Alkaline Phosphatase Activity and
Factor VIII Associated Antigen* 7.2

*Composite Autoradiograph of Rat Lymph Node and
Lymph Node Cell Preparations labelled with
Radioactive Sulphate* 7.3

*Composite Photomicrograph of Primary and Secondary
Adhesion Cultures of the Dense Cell Preparation,
Stained For Alkaline Phosphatase Activity
and Factor VIII Associated Antigen* 7.4

*Composite Autoradiograph of Primary and Secondary
Adhesion Cultures of the Dense Cell Preparation,
Labelled with Radioactive Sulphate* 7.5

APPENDIX:

Restriction Map of pcD-hGM-CSF A.1

*Photograph of Agarose Gel with pcD-hGM-CSF and
pcD-Xho-1* A.2

*Photograph of Hybond Membrane Blot with
Labelled Probes* A.3

*Photomicrograph of Gingival Biopsy Tested
for mRNA for IL1 alpha* A.4

*Photomicrograph of Lymph Node Specimen Tested
for mRNA for IL1 alpha* A.5

PUBLICATIONS OF WORK DESCRIBED IN THIS THESIS

Zoellner H and Hunter N. 1989. Perivascular hyaline deposits in inflamed gingival tissues. *J Oral Path Oral Med* 18:333

Zoellner H and Hunter N. 1989. High endothelial like venules in chronically inflamed gingival tissues exchange polymorphs. *J Path* 159:301

Zoellner H and Hunter N. 1989. Histochemical identification of the vascular endothelial isoenzyme of alkaline phosphatase. *J Histochem Cytochem* 37:1893

DECLARATION

The work presented in this thesis is wholly the work of Hans Zoellner done at the Institute of Dental Research between February 1986 and January 1990, towards the degree of Doctor of Philosophy (University of Sydney). To the best knowledge of the student, this work is original, and has not been published or presented elsewhere by other workers.

Hans Zoellner

SUMMARY

This thesis describes work done at the Institute of Dental Research in Sydney between February of 1986 and January 1990. The broad subject of the work is the role of vascular endothelial cells (ECs) in chronic inflammation. Periodontitis has been used as an example of chronic inflammatory disease, and provides the focus for this study of endothelial biology. In Chapter 1, aspects of the endothelial literature which provide relevant background information for work described in later chapters are reviewed. In Chapter 2, literature relating to the aetiology and pathogenesis of chronic inflammatory periodontal disease is discussed. To maintain relevance of literature reviews to experimental work, each subsequent chapter contains a small literature review of material relating to the subject of the specific chapter.

Early laboratory work is described in Chapter 3, and consisted of a morphological survey of the vascular changes occurring in gingival tissues with development of chronic periodontitis. Expansion of the vasculature and the appearance of phenotypically specialised high endothelial cells (HECs), were associated with progression of the disease. Vessels with HECs had a similar appearance to those known to be responsible for lymphocyte recirculation described in lymphoid tissues and chronic inflammatory sites.

In the course of performing this survey, a perivascular hyaline material was noted surrounding capillaries close to the bacterial plaque irritant. The incidence, distribution, extent, ultrastructure and immuno-histochemistry of this material was more closely investigated, and the possible pathogenesis and significance of the material discussed in Chapter 4.

In Chapter 5, the ultrastructural, histochemical and functional properties of gingival HECs are described, and compared with the well characterised HECs of rat lymph nodes. It was found that the periodontal vessels were very similar to those in rat lymph nodes, with the exception however, that the gingival vessels appeared to exchange polymorphonuclear leukocytes almost exclusively, while vessels with HECs in lymph nodes and other locations are known as sites of lymphocyte recirculation. This observation indicated that the function of HECs requires further investigation, with particular regard to the synthetic activity of the cells.

HECs were consistently alkaline phosphatase (AP) negative. The negative association between leukocyte emigration and AP activity (APA), as well as evidence

in the literature illustrating both the wide substrate specificity of this enzyme and the importance of phosphorylation in the control of protein activation, suggested that AP could play a role in regulating leukocyte emigration. A pre-requisite for the investigation of this possibility, is the identification of a rich source of the identical iso-enzyme of AP to that which is present in ECs. In Chapter 6, the sensitivity of endothelial AP to a panel of inhibitors is compared with that of a number of tissues for which the isoenzyme has been identified. Endothelial AP was identified as the liver/bone/kidney isoenzyme. This allows the use of kidney tissue as a relevant source of AP for use in further study of the role of this enzyme in EC biology.

It was clear that in order to study both the synthetic activity of HECs, as well as the role of AP in the control of leukocyte emigration, a method for obtaining high density primary cultures of HECs had to be established. Chapter 7 describes work done towards the development of such a culture system.

The availability in the latter phase of the work of suitable probes for the technique of in-situ hybridization allowed the possibility of testing the hypothesis that HECs are important cytokine producers. It was felt that this would provide some basis for the further study of these cells in-vitro. This work is described in the appendix.

The general discussion in Chapter 8, summarises the work, and develops potential areas of study arising from the findings of this thesis.

CHAPTER 1

VASCULAR ENDOTHELIAL CELLS IN INFLAMMATION AND IMMUNITY

INTRODUCTION

Vascular endothelial cells (ECs) form the innermost lining of the circulatory network, so that it is clear that ECs have an important structural role in the formation of blood vessels. Since ECs separate blood from the tissues, these cells define a critical surface for metabolic exchange. Nutrients, waste products, hormones and blood cells must cross this barrier in the course of normal tissue function (Cliff 1976). The ability of ECs to maintain a surface which actively resists the coagulation of blood, has been recognised as a property peculiar to these cells (Thorgeirsson and Robertson 1978).

The evolutionary pressures upon vascular systems which accompany the appearance of increasingly large and more complex animals have been described by others (Cliff 1976, Földi and Casley Smith 1983), and will not be reviewed here. However, it is worth noting that the complex biology of mammalian ECs probably reflects the prolonged evolution of the mammalian circulatory network.

Many early studies of microvascular endothelial biology were performed by observing blood vessels in living animals. This was done using whole mounts of thin membranous tissues *in-vivo* (Cohnheim 1889, Chambers and Zweifach 1940) and later using more elaborate tissue chamber techniques (Clark *et al.* 1930). This approach provided a wealth of information regarding physical aspects of the behaviour of blood vessels, particularly with regard to the changes occurring during the acute inflammatory response. Histological studies were also employed to more clearly examine the phenomena seen *in vivo* (Marchesi 1964, Majno *et al.* 1969), however, this approach could not be used to study ECs in isolation. With the advent of tissue culture techniques, and particularly the development of methods for the isolation and culture of ECs, the earlier *in-vivo* observational studies have been confirmed *in-vitro*, greatly expanding the literature describing functional properties of ECs.

Recent reviews and symposia reflect the focus of much of this work. The interaction of ECs with the coagulation and fibrinolytic pathways has been extensively

studied, with a view to understanding atherogenesis and thrombosis (Rodgers 1988). The vasoactive effects of EC products such as endothelin, endothelium-derived relaxing factor (nitric oxide), and at least one arachidonic acid derivative, have illustrated complex interactions between ECs and the surrounding smooth muscle cells, indicating that ECs have an important role in regulating blood flow through tissues (Furchgott and Vanhoutte 1989). Also, the control of vascular permeability has been extensively studied, both in terms of the physiological transport of materials across the vascular barrier, and with reference to the formation of inflammatory exudate (Grega 1986).

Of particular relevance to the work described in this thesis, have been studies investigating the role of ECs in some aspects of inflammation and immunity. ECs are involved in the regulation of supply of humoral and cellular defence factors to the tissues (Cotran 1987). Angiogenesis is an important component of many chronic inflammatory lesions, and may in part reflect the greater requirement for blood borne defence factors by injured tissues, as well as the formation of reparative granulation tissue. The cellular component of inflammatory and immune reactions is principally mediated by leukocytes entering affected tissues from the blood. To better understand this, a great deal of work has been done in studying the mechanisms whereby leukocytes adhere to the endothelial barrier, as a critical first step in the emigration of blood borne cells into the tissues. Further, ECs are active in defence, not only in providing access to the tissues for blood borne factors, but also in the synthesis of a range of inflammatory mediators which have the potential to affect both local and systemic responses. It is these areas which will be reviewed in the remainder of this chapter.

ANGIOGENESIS

Anatomical Changes During Angiogenesis

The formation of blood vessels is important during embryogenesis, wound healing, chronic inflammation, and tumour growth (Furcht 1986). Prior to the formation of new blood vessels, ECs become plump with cytoplasmic organelles, in preparation for division and migration (Schoefl 1963, Sholley *et al.* 1977). The basement membranes of pre-angiogenic vessels become fragmented (Ausprunk and Folkman 1977, Folkman 1984) and it is thought that this reflects the production of proteinases by ECs in response to angiogenic factors (Gross *et al.* 1983). Also, a dilation of existing vessels is reported in the earliest stages of angiogenesis (Schoefl 1963).

New vessels form by the budding and sprouting of capillary and small venular ECs from the existing microvascular bed. Division of ECs during the formation of sprouts occurs behind the leading edge of the developing sprout, so that cells at the tip of the developing vessel are migratory, while those at the base undergo maturation. The sprouts are at first solid cords of ECs, but quickly form luminal structures. Sprouts merge to establish patent vessel loops, confluent with the original microcirculation. Newly established vessels are highly permeable to their intravascular contents. Phenotypic specialisation of ECs, and regression of redundant new vessels occurs during the maturation of new microvascular beds (Cohnheim 1889, Schoefl 1963, Folkman 1984, Furcht 1986).

Angiogenic Factors

A large number of factors have been identified which contribute to angiogenic events. Not surprisingly, these factors seem to reflect the wide range of physiological and pathological circumstances in which angiogenesis occurs.

Angiogenic Factors Obtained From Normal Tissue Extracts

Tissue extracts from several normal tissues stimulate the proliferation of cultured ECs, and also induce angiogenesis *in-vivo*. Sources of such tissue factors include: brain tissue (Risau 1986, Thomas *et al.* 1985), embryonic kidney tissue (Risau and Ekblom 1986), retinal tissue (D'Amore *et al.* 1981), placental tissues (Moscateli *et al.* 1986) and salivary gland tissue (Hoffman *et al.* 1976). The physiological significance of factors obtained from adult tissues is difficult to understand, and it is possible that these factors have other unrelated functions in adult tissues, which have not as yet been determined.

Angiogenic Factors from Inflammatory Cells

Macrophages release factors which cause EC proliferation (Mostafa *et al.* 1980), as well as angiogenesis in the guinea pig corneal assay (Polverini *et al.* 1977). Decreased oxygen tension increases the production of angiogenic factors by macrophages, and it has been proposed that this may be one of the key factors in controlling angiogenesis in wound healing (Knighton *et al.* 1983). These authors note that the centres of tumours are often hypoxic, and that macrophages are often a major component of the cell population found in tumours (Alexander *et al.* 1976, Talmadge *et al.* 1981). The possibility that tumour related angiogenesis may be the result of hypoxic tumour macrophage products was raised by this work. Knighton *et al.* (1983) also noted that macrophages cultured under 3 to 5 mm of culture fluid in normal cell culture plates, are hypoxic, suggesting that the production of

angiogenic factors by "unstimulated" macrophages in other reports (Mostafa *et al.* 1980, Polverini *et al.* 1977) could be artifactual. It is also recorded that lactate at the concentrations expected in sites of wound healing, activates the release of angiogenic factors from macrophages (Jensen *et al.* 1986). These authors suggest that by removing lactate and increasing oxygen tension, newly formed blood vessels auto-regulate angiogenesis during wound healing.

Tumour necrosis factor α (TNF- α), a product of stimulated macrophages, is thought to be an important macrophage derived angiogenic factor. This cytokine causes new blood vessel formation *in-vivo*, as well as EC proliferation and differentiation *in-vitro* (Leibovich *et al.* 1987). These authors suggest that TNF- α could have conflicting roles in tumour biology, in that this cytokine may cause direct tumour cytotoxicity, and yet support the tumour by aiding the formation of new blood vessels. Granulocyte colony stimulating factor (G-CSF) and granulocyte-macrophage colony stimulating factor (GM-CSF) have been shown to induce EC proliferation and migration (Bussolino *et al.* 1989). The synthesis of these proteins by cultured ECs (Zsebo *et al.* 1988) raises the possibility that ECs may play an important role in the generation of angiogenic factors (Bussolino *et al.* 1989).

PMNs have also been implicated as potential sources of angiogenic factors (Fromer and Klintworth 1976), as have lymphocytes (Nishioka and Katayama 1978, Sidky and Auerbach 1979). Angiogenic activity has been noted in a number of immune lesions, an example of which is the developing and healing tuberculous lesion (Courtade *et al.* 1975). Sidky and Auerbach (1975) described the angiogenic response resulting from intradermal injection of immunocompetent lymphocytes into irradiated mice, and noted a great increase in vessel number. These authors described this response as lymphocyte induced angiogenesis. Also, cultured lymph node cells induce EC proliferation and migration *in vitro* (Watt and Auerbach 1986), as well as angiogenesis *in vivo* (Nishioka and Katayama 1978).

Platelet derived EC growth factor is a potent angiogenic factor, capable of inducing EC proliferation and migration, and the formation of new blood vessels in the chick chorio-allantoic membrane assay (Ishikawa *et al.* 1989).

Mast cells produce at least two EC proliferative factors, which are separable by dialysis. Histamine appears to be the dialysable factor, while the non-dialysable factor has not been characterised other than that it is known not to be heparin (Marks *et al.* 1986). However, mast cell derived heparin does induce EC migration, suggesting that this product may still be important in angiogenesis (Azizkhan *et al.* 1980). Also, heparin has angiogenic activity *in-vivo* (Taylor and Folkman 1982).

Apart from its chemotactic activity for ECs, heparin may have an indirect role in the control of angiogenesis, in that heparin binds many angiogenic factors (Folkman *et al.* 1988, Risau and Ekblom 1986, Risau 1986, Moscatelli *et al.* 1986). Heparin-like molecules in the extracellular matrix may thus act as an extracellular storage depot for angiogenic factors (Folkman *et al.* 1988, Moscatelli 1988). Heparin has been found to enhance the angiogenic activity of acidic fibroblast growth factor (Thomas *et al.* 1985), and is also chemotactic for ECs (Terranova *et al.* 1985). Further, angiogenesis is inhibited in some systems, when heparin is administered in combination with steroid hormones (Folkman *et al.* 1983, Crum *et al.* 1985). It is argued that the inhibitory effect of heparin in the presence of steroids varies due to differences in the heparin preparations used (Folkman *et al.* 1989). From this, the role of heparin in the control of angiogenesis is not yet clearly defined.

Fibrin is an important component of the extracellular environment during inflammatory responses and wound healing (Dvorak *et al.* 1984). By forming a three-dimensional structure, fibrin establishes a matrix into which endothelial and other cells are able to grow during angiogenesis. Apart from this purely mechanical function, however, fibrin gels have a direct effect upon ECs to induce an angiogenic response *in-vivo* (Dvorak *et al.* 1987). The molecular basis of this angiogenic stimulation is difficult to determine, since fibrin gels are unavoidably complexed with other blood plasma components, including fragments of degraded plasma proteins generated during gel formation. These authors also noted increased angiogenic activity for fibrin gels which were impregnated with zymosan-activated serum or N-formyl-methionyl-l-phenylalanine (FMLP) as compared with untreated fibrin gels, suggesting a role for bacterial products in angiogenesis in infected tissues and wounds.

The suggestion that factors likely to be encountered in wounds might help to stimulate angiogenesis as part of wound healing, supports the observations described earlier, that lowered oxygen tension and elevated lactate concentrations stimulate the production of angiogenic factors by macrophages (Knighton *et al.* 1983, Jensen *et al.* 1986).

Angiogenic factors from Tumours

Early observations of tumours suggested that neoplastic tissues might produce angiogenic factors necessary for the maintenance and growth of the tumour (Goldmann 1907). The presence of an angiogenic factor produced by tumour cells was eventually confirmed *in-vivo* by Greenblatt and Shubik (1968), who used a membrane to separate malignant melanoma cells from host tissues, and observed growth of blood vessels towards the tumour.

Tumour angiogenesis factor (TAF), has been isolated from tumours, and induces angiogenesis *in-vivo* (Folkman and Cotran 1976). However, the possibility that this factor is produced by infiltrating inflammatory cells was raised by Mostafa *et al.* (1980a). These authors found that TAF isolated from several human tumours was toxic to bovine aortic ECs in culture, and that the EC growth promoting effects of TAF were due to macrophages, for which TAF was chemotactic. The observation that tumour induced angiogenesis in the chick chorioallantoic membrane is accompanied by a dense mononuclear infiltrate supports the authors conclusion that TAF may act indirectly through macrophages (Mostafa *et al.* 1980b). However, direct effects of TAF upon ECs have been observed in culture (Dodd and Kumar 1984, Kumar *et al.* 1984) suggesting that despite the indirect effects mediated by macrophages, TAF may have some direct angiogenic effect upon ECs.

A number of factors that may play a role in angiogenesis in developing and healing tissues, have been isolated from tumours and characterised. It is possible that TAF is in fact one or all of these factors. Transforming growth factor- α is angiogenic in the hamster cheek pouch bioassay, and is produced by some tumour cells, as well as by embryonic tissues. This protein is related to epidermal growth factor (EGF), which also has some angiogenic activity (Schreiber *et al.* 1986). Other tumour-derived factors which have angiogenic activity are the chondrosarcoma-derived growth factor (Shing *et al.* 1984) and angiogenin (Fett *et al.* 1985).

Angiogenin is a factor isolated from HT-29 human colon adenocarcinoma cells (Fett *et al.* 1985). Studies examining the distribution of angiogenin throughout normal tissues, indicate that its production is maximal in the adult liver, and that the principle function of angiogenin in normal physiology may not be angiogenesis (Weiner *et al.* 1987). However, this does not exclude the suggestion that the normal reservoir for angiogenin is blood plasma, and that plasma leakage occurring as a result of tissue damage could result in local concentrations sufficient to elicit angiogenesis (Bicknell and Vallee 1988).

The Extracellular Matrix in the Control of Angiogenesis

The effects of extracellular matrix (ECM) components upon angiogenesis have been extensively studied, and have led to the concept that vascular morphogenesis is due to the combined effects of soluble angiogenic factors, and mechano-physical effects from insoluble ECM components (Ingber and Folkman 1989).

Cultured ECs initially form monolayers of cells with a cobble-stone morphology. With time, however, these cultures undergo morphological changes to

form tube like structures reminiscent of capillaries (Folkman and Haudenschild 1980, Maciag *et al.* 1982). An important factor in determining the acquisition of the capillary like phenotype by cultured ECs is the composition of the matrix upon which the cells are cultured (Madri and Pratt 1986). In cultures of microvascular ECs on substrata consisting of basement membrane collagens types IV and V, as well as on substrates such as matrigel prepared from a mixture of basement membrane components, ECs quickly organise into tube like structures. In contrast, with interstitial collagens types I and III, prolonged culture is necessary before limited capillary-like formations appear (Madri and Williams 1983, Grant *et al.* 1989).

Fibronectin is chemotactic for ECs in culture (Bowersox and Sorgente 1982), and it is suggested that since non-proliferative migration of ECs is an important component of the early angiogenic response, fibronectin could play an important role in controlling angiogenesis. It has also been suggested that this protein may have an additional role in the control of EC differentiation (McAuslan *et al.* 1980).

Laminin significantly enhances the proliferation of ECs (Form *et al.* 1986), and appears to be largely responsible for the induction of capillary-like tubule formation in EC cultures (Kubota *et al.* 1988). Specific domains of laminin have been identified that are responsible for the binding of the protein to ECs, as well as for activation of tube formation (Grant *et al.* 1989).

Basic fibroblast growth factor is a soluble cell growth factor. There is evidence, however, that in-vivo this factor is bound to heparan sulphate proteoglycans in basement membrane structures (Bar-Shavit *et al.* 1989, Folkman *et al.* 1988), and that this is important in supporting proliferation of ECs as an ECM component (Rogelj *et al.* 1989). It has been suggested that the ECM is a storage depot for basic fibroblast growth factor which is activated when basement membrane structures are degraded during morphogenic events (Rogelj *et al.* 1989, Moscatelli 1988).

The development of capillary-like structures in long term EC cultures, as well as the observation that basement membrane components, particularly laminin, are important in the induction of this phenotype in-vitro, has led to the suggestion that during angiogenesis, ECs influence their own development by the production of basement membrane materials (Grant *et al.* 1989). The synthesis of basic fibroblast growth factor by ECs (Vlodavsky *et al.* 1987), supports further the concept that EC auto-regulation via the ECM is important during angiogenesis.

Secretion of Proteinases by Endothelial Cells During Angiogenesis

For ECs to migrate from established blood vessels and form new vascular channels, it is necessary for these cells to escape from their vascular basement membrane, as well as to migrate through the extracellular material. Because of this, the synthesis of proteolytic enzymes by ECs is clearly an important component of the angiogenic response.

ECs are capable of producing several potent proteinases. These include interstitial and basement membrane collagenases (Moscatelli *et al.* 1980, Gross *et al.* 1982, Kalebic *et al.* 1983), stromelysin (Herron *et al.* 1986), and both the urokinase and tissue type plasminogen activators (Levin and Loskutoff 1982, Gross *et al.* 1982, Grøndahl-Hansen *et al.* 1989). In addition to this, ECs also synthesise proteinase inhibitors including a plasminogen activator inhibitor (Hekman and Loskutoff 1985, Sawdey *et al.* 1986)

The significance of collagenase and stromelysin production by migrating ECs during angiogenesis is largely self-evident, with the need for ECs to degrade connective tissue elements in order to migrate through the tissues. Plasminogen activator and plasminogen activator inhibitor production by ECs has clear relevance to the role of ECs in maintenance of a non-thrombogenic surface. However, the wide ranging proteolytic activity of plasmin, the product of the action of plasminogen activator upon plasminogen, implicates plasminogen activator in the proteolytic degradation of many proteins un-related to the control of fibrinolysis. Further, in wound healing and tumour growth, the ability of ECs to degrade fibrin through the release of plasminogen activator would be expected to assist in the migration of ECs through the fibrin mesh during angiogenesis.

Correlation has been noted between the synthesis of proteinases, and exposure of cultured ECs to angiogenic factors (Gross *et al.* 1983), as well as with chemotaxis of migrating ECs (Kalebic *et al.* 1983, Moscatelli *et al.* 1986). This is consistent with the in-vivo observation that an early component of the angiogenic response is degradation of the vascular basement membrane (Folkman 1984, Furcht 1986).

THE BINDING OF LEUKOCYTES TO ENDOTHELIAL CELLS

Leukocyte-Specific Integrins

Integrins are a family of structurally related, membrane bound polypeptides consisting of an α and β chain complex, which bind both intracellular and extracellular ligands. These complexes are thought to play an important role in controlling cell function in relation to the extracellular matrix (Ruoslahti and Piershbacher 1987). A sub-class of this family has been identified, which is found exclusively in leukocytes, and has been described as the leukocyte-specific integrins (Rosen and Gordan 1989). These integrins are unique in that the α chain has a conserved leukocyte-specific region which is absent in the α chains of other integrin molecules (Corbi *et al.* 1988). Three members of this group of leukocyte surface molecules have been identified in humans. These are the lymphocyte function associated molecule-1 (LFA), and the complement receptors CR3 and CR4.

LFA-1 is recognised by monoclonal antibodies (Mabs) CD11a/CD18. It has a broad distribution amongst leukocyte types, being present on monocytes, PMNs and T lymphocytes.

CR3 binds the iC3b fragment of the cleaved third component of complement, and is present on the surfaces of PMNs, monocytes, some macrophages and occasional large granular lymphocytes. This receptor is detected with Mabs CD11b/CD18 and is sometimes described as Mac-1 or Mo-1.

CR4 which is also a receptor for the iC3b fragment, is present on neutrophils and monocytes. CR4 is detected with Mabs CD11c/CD18 and is sometimes described as gp150,95 (Rosen and Gordan 1989, Horějsí' and Bazíl 1988).

The functional significance of these molecules is illustrated by the complex of immune deficiencies suffered by individuals lacking normal β chains, with defects in non-specific cell adhesion, aggregation and chemotaxis being apparent in-vitro (Anderson *et al.* 1984 and 1985, Anderson and Spinger 1987). The binding of PMNs, monocytes and lymphocytes to cultured ECs is partly mediated by this group of proteins, and particularly by LFA-1 (Harlan *et al.* 1985, Patarroyo *et al.* 1985, Mentzer *et al.* 1987, Haskard *et al.* 1986). ICAM-1 is a ligand for LFA-1-dependent adhesion of B, T and myeloid cells (Makgoba *et al.* 1988). The dependence on divalent cations, of leukocyte binding to both ECs and non-biological substrates, can perhaps be attributed to the presence of cation binding sites in the extracellular domain of the α chain (Pytela 1988).

Lymphocyte Specific Adhesion Mechanisms

Lymphocytes recirculate between the blood circulatory and lymphatic system by emigrating through specialised post-capillary high endothelial venules (HEVs) in lymphoid tissues (Gowans and Knight 1964). Similar high endothelial-like venules (HELVs) are found in many chronic inflammatory sites where large numbers of lymphocytes enter the inflamed tissues (Smith *et al.* 1970). The endothelial surfaces of these vessels are composed of HECs. The appearance of HECs differs from that of their flat endothelial counterparts, in that they are plump and bulge prominently into the vessel lumen. Also, the nuclei of these cells are large and vesicular, while the chromatin of flat ECs is condensed into narrow nuclei. Subsets of lymphocytes have been identified which enter specific lymphoid organs during physiological lymphocyte recirculation (Butcher *et al.* 1980, Stevens *et al.* 1982), leading to the concept of organ specific lymphocyte recirculation.

The ability of lymphocytes to enter lymphoid tissues *in-vivo* was shown to be trypsin sensitive by Woodruff and Genser (1968). This activity was, however, recoverable within 4 hours of treatment with trypsin. The development of a frozen section binding assay, in which cryostat sections of tissues containing HEVs were tested for their ability to bind lymphocytes, allowed investigation of lymphocyte to HEV interaction (Stamper and Woodruff 1976, Woodruff and Clarke 1987).

Antibodies used to Probe Organ Specific Recirculation

Chin *et al.* (1980a&b) purified a factor from the thoracic duct lymph of rats, which inhibited the binding of lymphocytes to HEVs in frozen sections. The distribution of this protein, as determined using a rabbit antiserum prepared against this factor, was limited to recirculating lymphocytes. The antiserum also inhibited the binding of lymphocytes in the frozen section assay. Binding to HEVs was more acutely inhibited by the antiserum in peripheral lymph node tissues than in mesenteric lymph nodes, with binding to Peyer's patches being unaffected. The authors concluded that there may be separate organ specific binding mechanisms, for each of these three sites of lymphocyte recirculation (Chin *et al.* 1982). A similar, but clearly separate, binding factor affecting the binding to Peyer's patch HEVs was later identified in rat thoracic duct lymph (Chin *et al.* 1984). A Mab against the lymph node HEC binding factor has been designated as HEBFLN(A.11), and inhibits binding of lymphocytes to rat lymph node HEVs (Rasmusen *et al.* 1985). Similarly, the Mab 1B.2 inhibits interaction of the Peyer's patch specific receptor (Chin *et al.* 1986).

An 80-90 kD glycoprotein identified on the surface of mouse lymphocytes and recognized by the Mab Mel-14, correlates strongly with the ability of lymphocyte

sub-sets and lymphoma cell lines to bind to peripheral lymph node HEVs in-vivo and in-vitro (Gallatin *et al.* 1983). The expression of this antigen by lymphocytes can be modified by mitogenic stimuli (Hamann *et al.* 1988). The Mel-14 antigen is ubiquitinated, and the site recognized by the Mab appears to be at the interface between the core protein and ubiquitin (Siegelman *et al.* 1986). It has been suggested that ubiquitination may either assist in the rapid removal and control of this binding complex, or that ubiquitin may stabilize adhesive interactions of the core protein (Siegelman 1986, St John *et al.* 1986). A further suggestion for the possible role of ubiquitin has been that ubiquitin assists in the release of lymphocytes from HEVs during emigration through the wall of the vessel (Jalkanen *et al.* 1988). The structure of the core protein of the Mel-14 antigen is unusual, in that it has a lectin domain, an epidermal growth factor-like region and an area with duplicated repeat units similar to those found in complement regulatory proteins (Siegelman *et al.* 1989a). The human homologue for this receptor has been identified and sequenced, revealing a high degree of conservation for this protein (Siegelman *et al.* 1989b).

A surface antigen (LPAM-1) associated with the binding of lymphocytes to Peyer's patch HEVs, has been isolated from a murine lymphoma cell line. A monoclonal antibody has been prepared against this receptor which inhibits binding of lymphocytes to Peyer's patches. The structure of LPAM-1 appears to be very similar to that of the integrin receptor VLA-4 (Holzmann *et al.* 1989).

Mabs LSRE-1 and Hermes-1, have been raised against a human lymphocyte homing receptor, and do not inhibit the binding of lymphocytes to HEVs (Jalkanen *et al.* 1985, Jalkanen *et al.* 1986a). When Hermes-1 was used as an antigen for the production of a new Mab, an effective blocking Mab (Hermes-3) was produced (Jalkanen *et al.* 1987). Hermes-3 blocks the binding of lymphocytes to Peyer's patch HEVs, and also recognizes a non-binding site on lymph node specific cell lines (Jalkanen *et al.* 1987). The Hermes-3 antigen appears to be either identical to, or closely related to that recognized by Hermes-1 (Jalkanen *et al.* 1987). Hermes-1 antigen is a sulphated glycoprotein, which is covalently linked to chondroitin sulphate (Jalkanen *et al.* 1988). The sequence of cDNA coding for Hermes antigen indicates that it is closely related to the cartilage link protein and the cartilage proteoglycan monomer (Goldstein *et al.* 1989). These authors also found that mRNA for this receptor was present in cells for which the antigen did not appear to play a role in binding to HEVs, and they suggested that activity and specificity was the result of post-translational modification of the core protein. It is interesting to note that the Mel-14 antigen is precipitated by the Hermes antibodies, (Jalkanen *et al.* 1987),

suggestive of some functional similarity between these adhesion molecules despite the clear difference in the structure of their core proteins.

Mabs that block the binding of lymphocytes to lymph node and Peyer's patch HEVs have not been effective in inhibiting binding to inflamed synovial tissue HEVs, suggesting that a synovium-specific mechanism exists (Jalkanen *et al.* 1986b).

From these studies, it is clear that at least three major classes of lymphocyte homing molecule exist: the Mel-14 antigen type receptor, with lectin, epidermal growth factor and complement binding domains; the Hermes type receptors with homology with the cartilage link protein; and the integrin receptor-like LPAM-1 receptor. Peripheral lymph node and Peyer's patch HEVs consistently appear to have separate specific binding mechanisms, with mesenteric lymph node HEVs displaying binding properties intermediate to both. Some of the Mabs which block lymphocyte binding to HEVs, do so for several species, and it has been suggested that this illustrates a degree of conservation of the mechanisms of tissue specific lymphocyte recirculation (Wu *et al.* 1988).

Vascular Addressins

EC molecules that act as tissue-specific lymphocyte adhesion molecules have been described as vascular addressins (Streeter *et al.* 1988a&b). A single antigen, defined by Mabs MECA-89 and MECA-367, has been identified in mouse mucosal HEVs. In the frozen section assay, MECA-367 was found to block lymphocyte binding to mucosal but not to peripheral lymph node HEVs, with vessels in mesenteric lymph nodes being partially deprived of lymphocyte binding by the antibody (Streeter *et al.* 1988a). A second vascular addressin in the peripheral lymph node HEVs of mice has been identified using the Mab MECA-79. This Mab selectively blocks the binding of lymphocytes to peripheral lymph node HEVs (Streeter *et al.* 1988b).

The Role of Polysaccharides in The Binding of Lymphocytes to Endothelial Cells

The possibility that cell-surface carbohydrates could play a role in the homing of lymphocytes into specific tissues was discussed as early as 1964 (Genser and Ginsberg 1964). Using the frozen section assay, Stoolman and Rosen (1983) found that a lectin-like molecule on the surface of lymphocytes was involved in the selective adhesion of cells to peripheral lymph node HEVs. It was demonstrated that lymphocytes pre-treated with solutions containing L-fucose, D-manose and fucoidan (an L-fucose rich sulphated polysaccharide) had reduced adhesion for HEVs. The suggestion that lectin-like interactions might play a role in lymphocyte recirculation

was supported by the observation that lymphocyte binding to HEVs in peripheral lymph nodes, but not in Peyer's patches, was reduced when cryostat sections of these tissues were pre-treated with sialidases (Rosen *et al.* 1985). This *in-vitro* experiment was supported by *in-vivo* experiments, in which the injection of sialidases reduced lymphocyte recirculation through lymph nodes (Rosen *et al.* 1989). However, the value of the frozen section assay in the study of lymphocyte to HEV interaction was called into question by experiments testing the effects of a panel of sulphated polysaccharides upon lymphocyte recirculation *in-vivo* (Brenan and Parish 1986). In sharp contrast to Stoolman and Rosen (1983), these authors noted that blocking of lymphocyte binding by fucoidan and other sulphated polysaccharides, occurred at the level of the vascular endothelium. It has been suggested that a lymphocyte surface lectin responsible for rosetting with autologous red blood cells, may also play a role in adhesion to HEVs (Parish *et al.* 1984). These authors, however, acknowledged the presence of this lectin on the surface of lymphoid cells which do not bind effectively to HEVs, and considered that these lectins may play a further role in positioning lymphocytes within lymphoid tissues.

Further studies revealed the presence of a mannose-6 phosphate rich polysaccharide (PPME) binding lectin on the surface of lymphocytes, which appeared to be similar if not identical to the Mel-14 antigen (Yednock *et al.* 1987a&b). Mannose-6 phosphate is also reported to be a significant anti-inflammatory agent in experimental allergic encephalomyelitis (Willenborg *et al.* 1989). These authors suggest that mannose-6 phosphate effects its anti-inflammatory role by inhibiting lymphocyte membrane-bound enzymes involved with migration of the cells into brain tissues. However, it is further possible that this phospho-sugar could more directly inhibit migration into inflamed brain tissues, by binding to similar or perhaps identical molecules as those described for lymphocyte binding to HEVs.

The Effect of Inflammatory Cytokines and Bacterial Products On Leukocyte Binding to Endothelial Cells

Several cytokines and some bacterial products are known to increase the binding of leukocytes to ECs. For example, chemotactic factors such as leukotriene B₄, C5a and the bacterial peptide FMLP have been variously reported to increase, or decrease the binding of PMNs to EC cultures, depending upon the concentration of the agent (Gimbrone 1984, Tonnensen *et al.* 1984, Charo *et al.* 1986, Webster *et al.* 1986).

Interleukin-1 (IL1), TNF, platelet activating factor and lipopolysaccharide (LPS)

increase the binding of PMNs to cultured ECs (Gamble *et al.* 1985, Pohlmann *et al.* 1986, Breviario *et al.* 1988). Alternatively, the potentially angiogenic factor TGF β , reduces the binding of PMNs to ECs, and it is suggested that this may be important in protecting sites undergoing EC regeneration from inflammatory cell damage (Gamble and Vadas 1988). Also, the binding of lymphocytes to EC cultures is enhanced by gamma-Interferon (g-Inf), IL1, interleukin-2 and LPS, (Yu *et al.* 1985 & 1986, Cavender *et al.* 1986, Haskard *et al.* 1986, Damle *et al.* 1987). Although the molecular basis of EC to leukocyte binding has not been fully described, there has been considerable progress in relating the expression of known leukocyte adhesion mechanisms, to specific cytokine stimuli.

Expression of Leukocyte Specific Integrins in Response to Inflammatory Mediators

IL1, TNF and LPS all increase the binding of PMNs to human umbilical vein ECs in a partially LFA-1 dependent manner (Pohlman *et al.* 1986). Similarly, antibodies against the CDw18 ag block the increased binding of eosinophils to EC cultures which occurs in response to PAF, FMLP, IL1, TNF, LPS and phorbol esters (Kimani *et al.* 1988, Lamas *et al.* 1988).

Haskard *et al.* (1986 and 1989), found that the increased binding of lymphocytes to EC cultures in response to treatment with IL1, TNF and LPS, was only slightly depressed by anti-LFA-1 antibodies, while phorbol ester stimulated and baseline binding of lymphocytes to ECs was strongly inhibited by anti-LFA-1. Also, TNF-stimulated lymphocyte binding to EC cultures does not seem to be mediated by an LFA-1 dependent mechanism (Cavender *et al.* 1987a). It has been suggested that LFA-1 has an accessory role in the stabilisation of EC to lymphocyte binding (Pals *et al.* 1988), and the high levels of expression of ICAM-1 by HECs (Dustin *et al.* 1986), as well as the independence of lymphocyte binding from cytokine activation outlined above, supports the suggestion of such an accessory role. More recent observations however, suggest that LPS, IL1 and TNF can increase the adhesion of lymphocytes to ECs by an LFA-1/ICAM-1 dependent mechanism, while an LFA-1 dependent/ICAM-1 independent mechanism is responsible for basal levels of lymphocyte binding, independent of cytokine stimulation (Dustin and Springer 1988). These authors also conclude that there must be at least one additional binding mechanism which is LFA-1 independent, but upregulated by cytokines.

ELAM-1 is Expressed by Activated ECs as a PMN Specific Adhesion Molecule

An antigen termed ELAM-1, which is recognised by Mabs H4/18 and H18/7, and expressed by ECs stimulated with IL1 and TNF, plays a role in the binding of PMNs to ECs (Bevilacqua *et al.* 1987). This protein has a similar structure to the

core protein of Mel-14, in that lectin, epidermal growth factor-like and tandem complement binding protein segments are found in ELAM-1. A second member of this group of molecules is the protein GMP-140, found in platelets and Weibel-Palade bodies (Bevilacqua *et al.* 1989, Gamble and Vadas 1988). The role for this protein in the binding of leukocytes is, however, still unclear. It is suggested that these molecules may have evolved as members of an as yet incompletely described class of leukocyte docking molecules.

CYTOKINES MADE BY ENDOTHELIAL CELLS

The active role that ECs may have in inflammatory foci is particularly illustrated by the ability of cultured ECs to synthesise a large number of factors which are suspected to be of importance in the development of inflammatory lesions (Mantovani and Dejana 1989). Although little is known about the extent to which such factors influence the course of events during inflammatory and immune responses *in-vivo*, the location of ECs at the interface between tissues and the systemic circulation suggests that through the production of relevant inflammatory signals, ECs could affect both local and systemic aspects of inflammatory and immune responses.

Interleukin-1

IL1 occurs in two forms, that is IL1 α and IL1 β . This cytokine has a wide range of biological activities, including a role in activation of lymphocyte and fibroblast proliferation, pyrexia, muscle wasting, stimulation of osteoclastic activity and activation of the synthesis of a wide range of acute phase proteins *in-vivo* (Gery *et al.* 1981, Oppenheim *et al.* 1982, Schmidt *et al.* 1982, Dinarello *et al.* 1986, Barocos *et al.* 1983, Thomson *et al.* 1986, Dinarello *et al.* 1984). Both forms of the protein are produced by ECs in culture (Kurt-Jones *et al.* 1987). Factors which stimulate the synthesis of IL1 by ECs are, LPS (Miosec *et al.* 1986), lymphotoxin (Kurt-Jones *et al.* 1987), and TNF (Libby *et al.* 1986). Further, TNF induced IL1 synthesis by ECs is enhanced by g-Inf (Miosesec and Ziff 1986). IL1 can be secreted from ECs into the culture medium, or it may be expressed on the surface of the cell as membrane-associated cytokine (Kurt-Jones *et al.* 1987). The significance of such membrane-associated material is unclear, but does suggest a role in modification of cell to cell interactions, as may occur during antigen presentation (Kurt-Jones *et al.* 1987) or leukocyte emigration.

Other Inflammatory EC Cytokines

Of some interest, is the observation that IL1 stimulates ECs to synthesise a number of other cytokines. For example, IL1 stimulates the production of G-CSF, GM-CSF, Macrophage-CSF (M-CSF) (Zsebo *et al.* 1988) and multilineage CSF (Multi-CSF) (Segal *et al.* 1987) by ECs. Also, TNF exerts an additive effect to this response, in the synthesis of GM-CSF by ECs (Broudy *et al.* 1986, Seeleentag *et al.* 1987).

Also, IL1 increases the constitutive production by ECs of IL6 (Sironi *et al.* 1989), and an eosinophil survival factor (Lamas *et al.* 1989). Similarly, enhanced EC secretion of the non-protein mediators, prostaglandin I₂ (PGI₂) (Rossi *et al.* 1985) and platelet activating factor (Bussolino *et al.* 1986), occurs in response to IL1. Further, IL1, along with LPS and TNF stimulate EC cultures to produce a neutrophil chemotactic factor (Streiter *et al.* 1989), and IL1 also induces the production of a retroviral P15E-related chemotactic inhibitor, potentially acting as an element in a negative feedback loop in the control of leukocyte emigration (Wang *et al.* 1989).

An additional complication in this web of cytokine production by ECs is the observation by Kurt-Jones *et al.* (1987), that ECs produce IL1 in response to IL1 itself. The possibility that IL1 may be a key cytokine in the auto-regulation of EC cytokine synthesis can not be ignored. Methods for describing complex dynamical systems have been described (Prigogine and Stengers 1984, Gleick 1987) but have not found wide application in the study of cytokine networks. It is possible that such complex systems could be better understood through the use of these analytical methods.

The third component of the complement system, can be made by ECs (Ueki *et al.* 1987). Also, a range of arachidonic acid metabolites are produced by ECs, including prostaglandins E₂, and I₂ (Gerritsen 1987). ECs are also capable of converting PMN-derived leukotriene A₂ into the potent acute inflammatory mediators leukotrienes B₄, C₄, D₄ and E₄ (Claesson and Haeggström 1988).

QUESTIONS ARISING FROM THE LITERATURE

Considerable progress has been made towards understanding the role of ECs in inflammation and immunity. However, there are many issues arising from the work described above, which require further investigation.

Many of the anatomical features of angiogenesis are now known (Schoefl 1963, Folkman 1984). Also, a large number of angiogenic factors have been identified, as have some of the factors responsible for the formation of capillary like structures *in-vitro* (Hoffman *et al.* 1976, Mostafa *et al.* 1980, Folkman and Cotran 1976, Grant *et al.* 1989). Also, the importance of EC proliferation, migration and proteinase synthesis in the formation of new blood vessels has been established (Bussolino *et al.* 1989, Gross *et al.* 1983). However, the signals responsible for vascular specialisation to arterioles, capillaries and venules have not been defined. Also, the means whereby blood vessels orientate themselves within the tissues has not been explained. In as much as many angiogenic factors are characterised, physiological signals limiting angiogenesis in newly formed and mature tissues have not been identified. The significance of angiogenic factors isolated from tissues not undergoing angiogenesis (Hoffman *et al.* 1976) remains to be explained.

Although much information is now available regarding the presence, structure and function of many leukocyte molecules involved in the adherence of leukocytes to vascular ECs, the exquisite specificity with which different leukocyte types enter tissues at differing times during the inflammatory response is as yet unexplained. For example, although the Mel-14 antigen is clearly an important mediator of lymphocyte emigration into lymph node tissues, the presence of this antigen in large amounts on the surface of PMNs, monocytes and eosinophils, as well as its activity as an adhesion blocker for PMN binding to inflamed synovial and dermal ECs, suggests that additional factors are important in controlling leukocyte emigration (Lewinsohn *et al.* 1987). The post-translational modification of Hermes antigen suggested by Goldstein *et al.* (1989), may be a specific example of a general mechanism of control of activity and specificity, and the ubiquitination of Mel-14 antigen may be a further example of such control. Although the probable identity of Mel-14 antigen as the PPME binding lectin has been established (Yednock *et al.* 1987a&b), the further identity of the sialidase sensitive EC molecule (Rosen *et al.* 1985 & 1989) is not as yet known. The possibility that the lectin ELAM-1 may, like the Mel-14 antigen, prove to be an important lectin in the binding of leukocytes has yet to be established. Mabs have been an important and useful tool in the identification of leukocyte docking molecules. However, their production depends largely upon the antigenicity

of the molecules involved, so that the presence of other important mechanisms can not be excluded. In order to avoid omission of other binding molecules, it is necessary that other means of identifying surface determinants involved in leukocyte binding to ECs be established and applied. Since leukocyte emigration occurs only in the PCVs, the response of these ECs to factors known to affect the adhesion of leukocytes to other ECs is of some interest. However, it has not been possible to study the behaviour of these cells, as methods for the isolation and culture of PCV ECs have not been established.

ECs have been shown to be active in the synthesis of many inflammatory cytokines and mediators (Mantovani and Dejana 1989). As such they can no longer be viewed as pipes carrying blood to the tissues, but must be considered as active participants in the development of inflammatory and immune lesions. However, the physiological significance of cytokines synthesised by ECs has yet to be established, particularly with regard to the quantitative impact that these may have both locally and systemically.

CHAPTER 2

PERIODONTITIS: AN EXAMPLE OF A CHRONIC INFLAMMATORY DISEASE

INTRODUCTION

Progression of Gingivitis to Periodontitis

A number of periodontal lesions have been classified as differing forms of periodontitis. This thesis is concerned particularly with chronic inflammatory disease and discussion will be limited to chronic periodontitis. The acute periodontal lesions, such as pericoronitis and periodontal abscesses will not be discussed. These acute lesions have a separate pathogenesis from the chronic inflammatory lesion and are essentially independent from chronic periodontal disease. Similarly, to avoid confusion with the unrelated acute forms of gingivitis, for the remainder of this thesis, gingivitis will be defined as that form of gingival inflammation which is due to the accumulation of bacterial plaque in the gingival sulcus. A description of the various forms of gingival and periodontal inflammatory disease is provided in the review by Higgins *et al.* (1985).

Periodontitis is a common chronic inflammatory disease of the supporting tissues of the teeth and is a major cause of tooth loss (Figure 2.1). In health the gingival soft tissues are minimally inflamed, and attach to the tooth at the junction of the crown and root. In the absence of regular mechanical cleansing, the gingival sulcus is quickly colonised by oral commensal organisms. These form a dense plaque with a complex microbial ecology. Gingival tissues become inflamed in response to prolonged exposure to this plaque, establishing the non destructive lesion of gingivitis.

Clinically, tissues affected with gingivitis are erythematous and swollen with oedema fluid (Loe *et al.* 1965). Superficially, periodontitis lesions appear similar to gingivitis lesions, but when examined with a periodontal probe are found to have periodontal pockets (Figures 2.2a and 2.2b).

Page & Schroeder (1976) outlined a widely accepted model for the development of periodontitis. This model is based on histological observations of experimental lesions, and does not attempt to explain so much as to describe the development of the advanced periodontal lesion. A low power photomicrograph of a gingival biopsy

from a patient with periodontitis is shown in Figure 2.3. It is clear that a dense cellular infiltrate is in close proximity to the bacterial plaque irritant, which is thought to provoke the disease. The progression of the lesion as detailed by Page and Schroeder (1976) is described below.

The Initial Lesion

In experimental gingivitis induced by abstinence from normal oral hygiene practices, the initial gingivitis lesion is characterised by an acute inflammatory reaction. In this initial lesion, large numbers of PMNs are seen to emigrate from vessels into the tissues, and the gingival sulcus is "washed" by a constant flow of inflammatory exudate, referred to as gingival fluid. Gingival fluid continues to flow until the lesion is resolved, either by treatment or loss of the tooth. This lesion is typical of what would be expected in an acute inflammatory reaction, and progresses gradually to become the early lesion.

The Early Lesion

Within a month the "initial lesion" is seen to progress to the "early lesion". In this early lesion, large numbers of lymphocytes and some plasma cells are found in the tissue immediately subjacent to the sulcular epithelium. Loss of much collagen from the gingival soft tissues accompanies this cellular infiltrate. Cytopathic changes have been noted in fibroblasts at this stage of the disease, and it has been suggested that cellular hypersensitivity may contribute to the early lesion. The cellular and fluid exudate are increased as compared with the initial lesion, with PMNs, monocytes and lymphocytes migrating in large numbers into the tissues.

The Established Lesion

The established lesion appears at a variable time after the onset of inflammation, and is characterised by the appearance of large numbers of plasma cells, some of which are degenerate (Figure 2.4). The degeneracy of plasma cells is difficult to explain, since it would normally be expected that such cells are removed by scavenging macrophages. These plasma cells are not only present in the connective tissues immediately beneath the sulcular epithelium, but are also found surrounding vessels deeper in the tissues. The sulcular epithelium is also seen to proliferate and migrate into the connective tissues in long cords, and may proliferate to some extent along the root of the tooth.

The Advanced Lesion, Periodontitis

With the advent of periodontal pocket formation and bone loss, the lesion of periodontitis is established, and in the context of the progressive gingivitis lesion, periodontitis has been described as the "advanced lesion". Histologically the advanced lesion is essentially similar to the established lesion, other than that there has been obvious loss of bony support with extension of the epithelium along the root of the tooth, accompanied by the formation of a periodontal pocket.

The established lesion is apparently stable in most patients. However, in some patients there is progression of gingivitis (the established lesion) to periodontitis (the advanced lesion) in which the supporting periodontal ligament and alveolar bone are lost with the formation of a periodontal pocket. The factors controlling the transition of the relatively benign gingivitis lesion, to the destructive disease of periodontitis are not understood.

Periodontal pockets deepen over a period of many years, and if unchecked, result in the eventual loss of the affected tooth (Figures 2.1 and 2.2). Interestingly, rather than progressing slowly at a constant rate, it has recently become apparent that periodontal pockets deepen during short bursts of active tissue destruction. These discrete episodes are interspersed by prolonged periods of apparent stability (Goodson *et al.* 1982, Socransky *et al.* 1984). Also, these bursts of activity occur independently in different pockets within individuals, so that it is difficult to explain these episodes of tissue destruction on the basis of transient deficiencies in systemic host defence systems. The cause of these localised burst of activity is unknown.

It is generally accepted that the persistent bacterial plaque occupying the pocket space, drives the destructive chronic periodontitis lesion.

Minimally Inflamed
or Gingivitis

Periodontitis

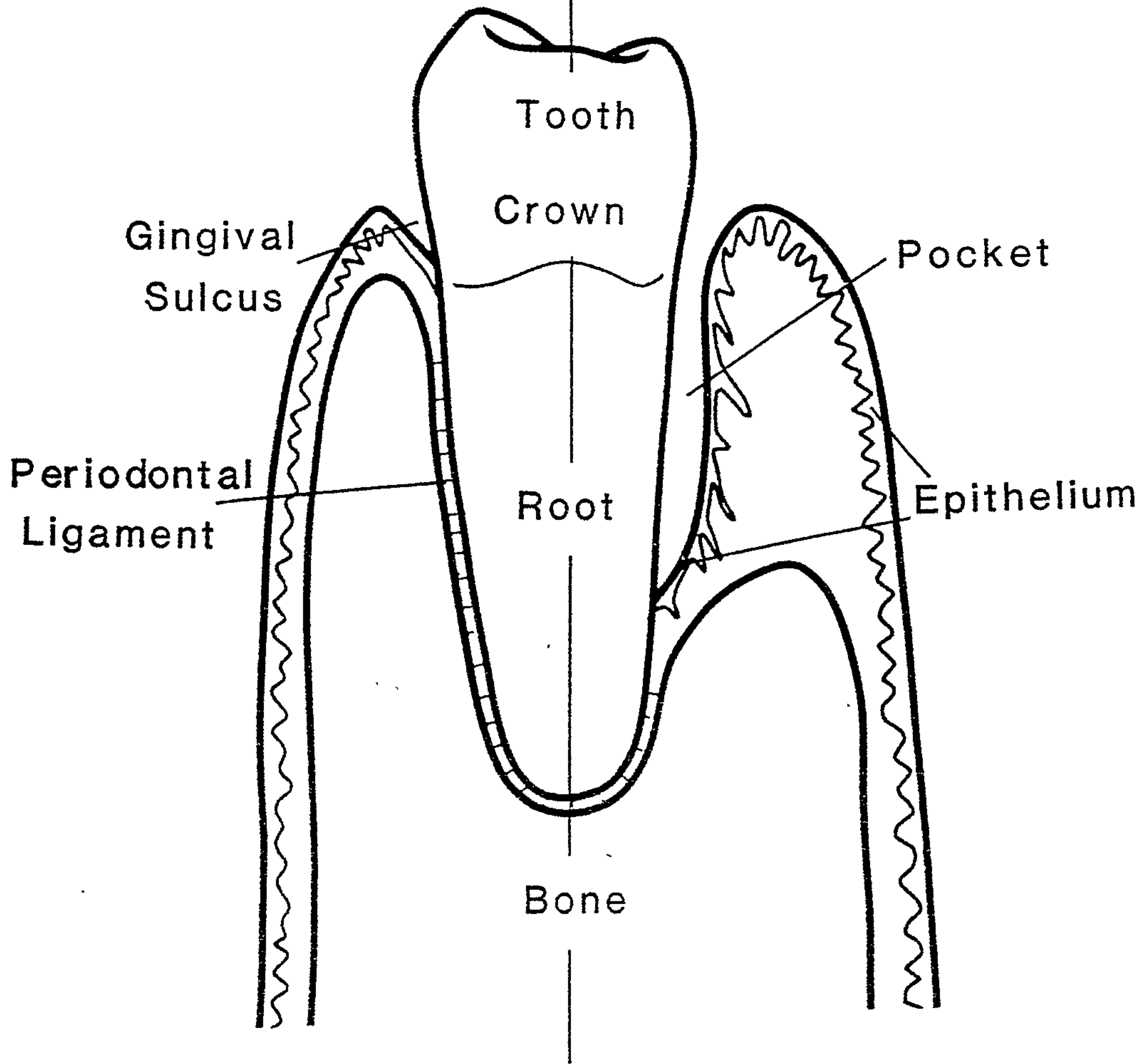


Figure 2.1

Diagram comparing the anatomy of tissues which are minimally inflamed or have gingivitis, with those affected by periodontitis.

In health the gingival soft tissues are minimally inflamed and attach to the tooth at the junction of the crown and the root. With the accumulation of bacterial plaque in the gingival sulcus, the gingival soft tissues become inflamed, establishing the non destructive lesion of gingivitis. In some patients there is progression of gingivitis to periodontitis, with destruction of the supporting periodontal ligament, loss of alveolar bone and pocket formation over a period of many years.

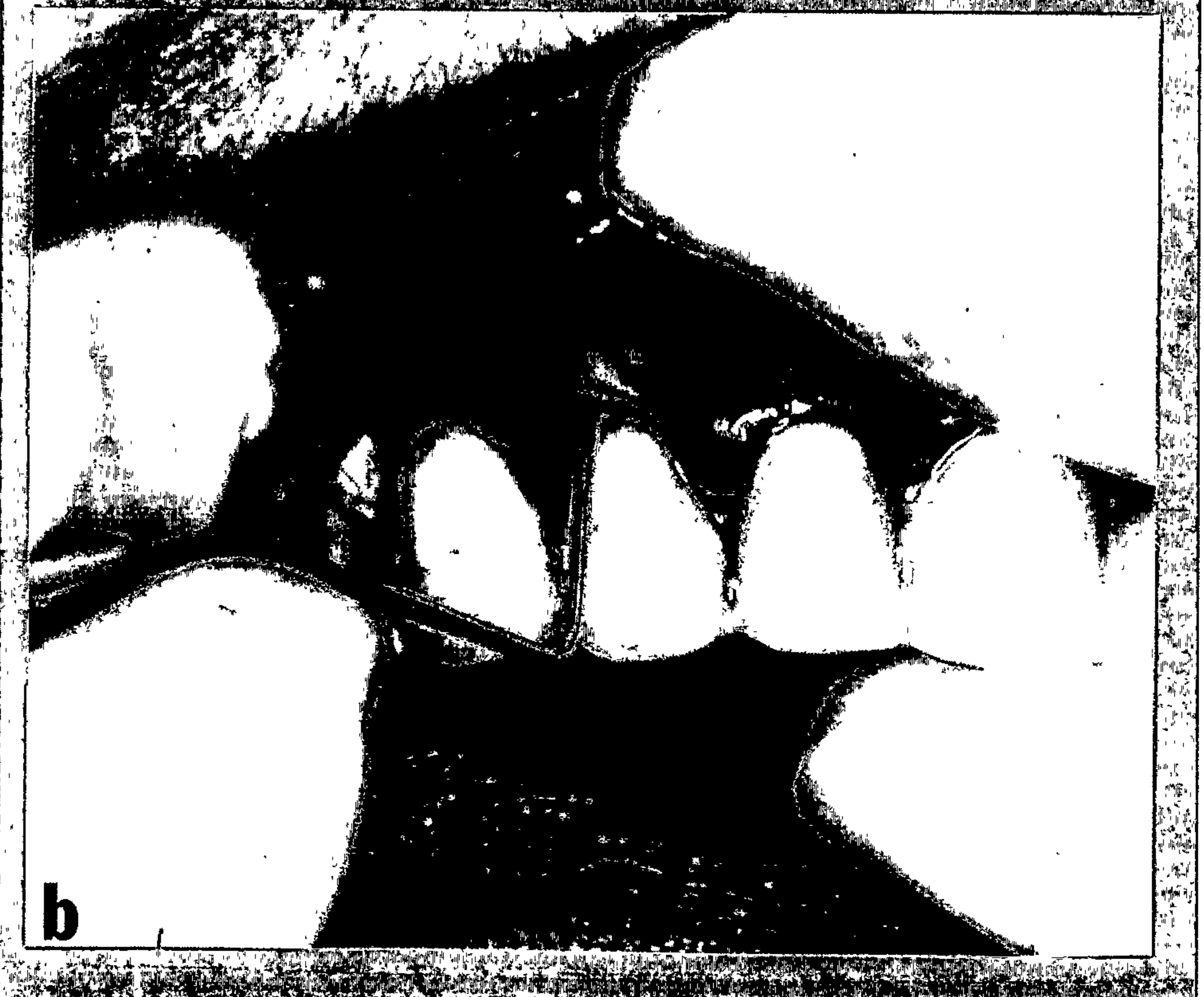
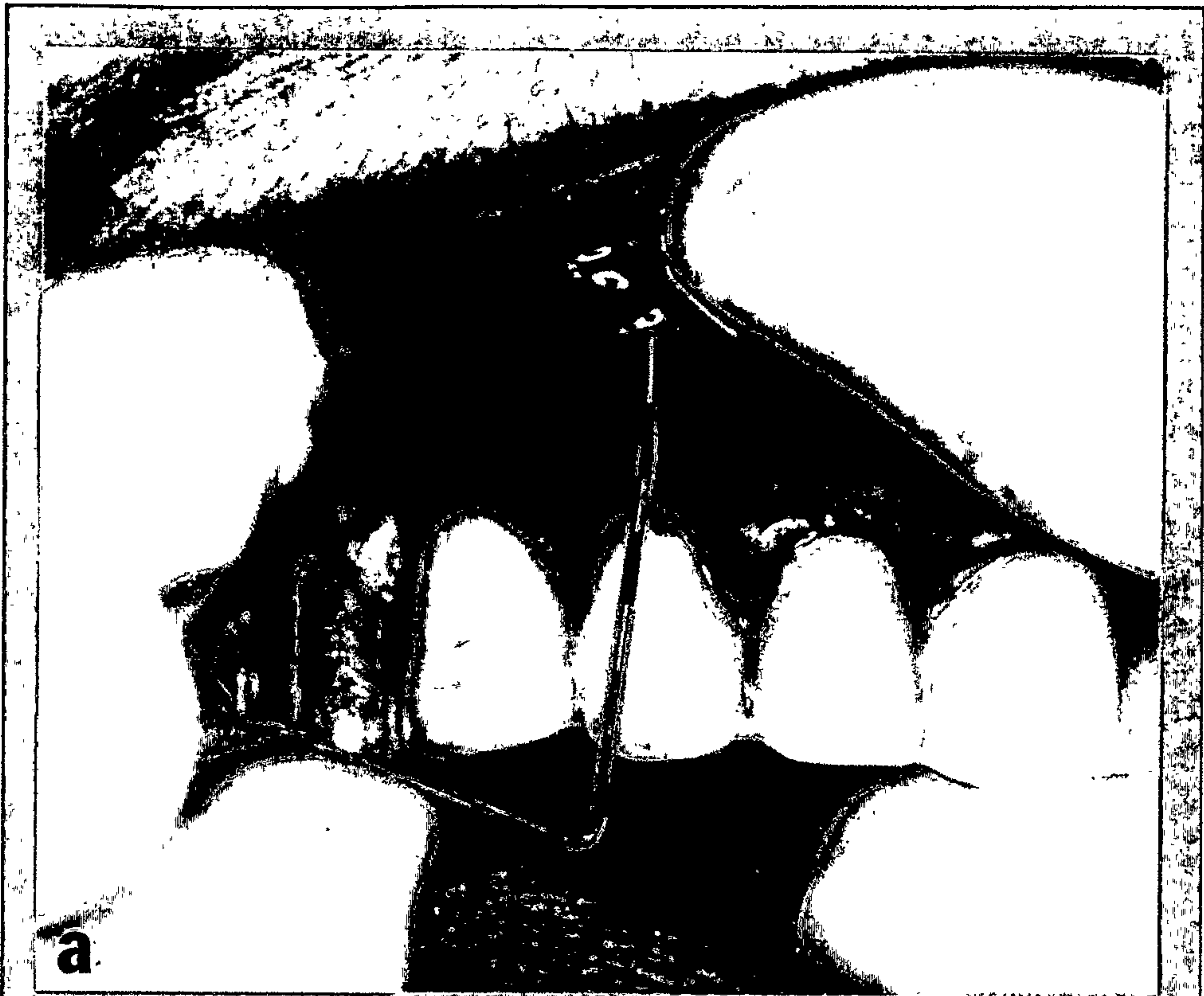


Figure 2.2a

Colour photograph of a tooth with periodontitis, and a periodontal probe.

Superficially, the gingiva appears normal, other than that the margin of the tissue is slightly swollen and erythematous. The most reliable method for the detection of periodontal pockets is gentle probing of the gingival sulcus with a periodontal probe.

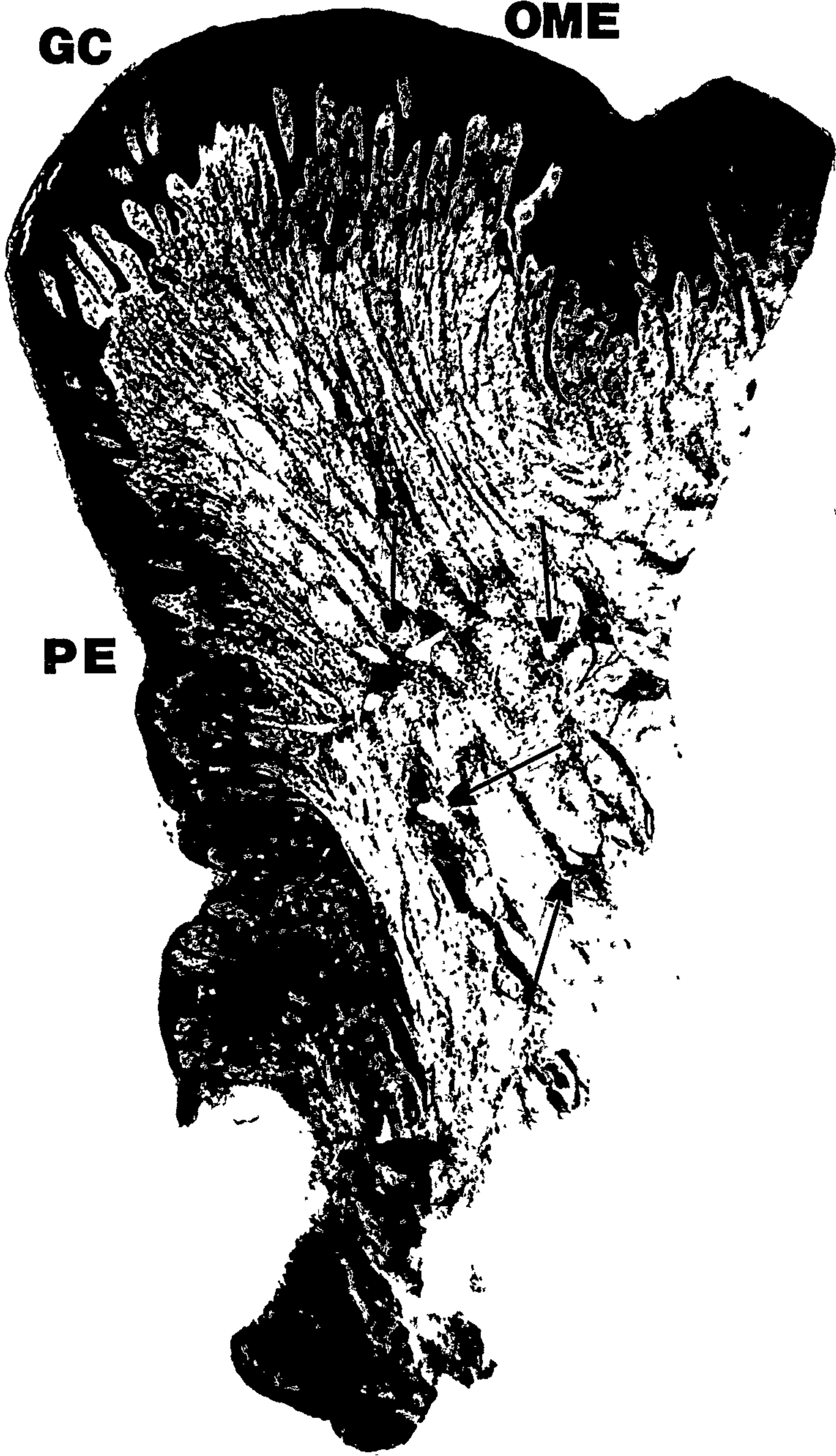
Figure 2.2b

Colour photograph of the same tooth shown in 2.2a, with the periodontal probe inserted into the periodontal pocket space.

From the depth to which the probe is able to penetrate into the space between the soft tissues and the tooth, it is clear that there has been extensive destruction of the supporting tissues.

GC

OME



PE

Figure 2.3

Low power photomicrograph of a gingival biopsy from a patient with periodontitis.

The oral mucosal epithelium (OME) reflects over the gingival crest (GC) to become continuous with the pocket epithelium (PE). The pocket epithelial wall separates the underlying connective tissues from the bacterial plaque. In response to this, the connective tissues supporting the pocket epithelium are heavily infiltrated with inflammatory cells. In this biopsy, the pocket epithelium is clearly thicker in that part of the pocket wall close to the gingival crest, while deeper into the pocket, the epithelium is attenuated. Large blood vessels draining the sub-epithelial vessels are followed by cords of inflammatory cells (arrows). (Toluidine Blue X 30)

FORMS OF PERIODONTITIS

Chronic Adult Periodontitis

Periodontitis has been sub-classified into several forms. These are distinguished by clinical criteria, particularly the age of onset and rate of progress of the disease (Higgins *et al.* 1985). Chronic adult periodontitis (CAP), is the most common and slowly progressive form, occurring in adults over the age of 30.

Rapidly Progressive Periodontitis

Some adult patients have rapidly progressive periodontitis (RPP), which may commence between puberty and the age of 30. RPP often results in the loss of teeth at an early age. It has been established that many patients with RPP suffer with systemic polymorphonuclear (PMN) dysfunctions. For this reason, conditions such as cyclic neutropenia (Cohen and Morris 1961), Chediak-Higashi syndrome (Temple *et al.* 1972) and diabetes (McMullen *et al.* 1981) are often associated with RPP.

Early Onset Periodontitis

Two further forms of RPP have been identified. These are localised juvenile periodontitis (LJP), and generalised juvenile periodontitis (GJP). These forms of the disease are sometimes grouped together as early onset periodontitis. LJP and GJP appear to be very similar other than that in LJP, the disease affects selected teeth within the mouth more severely than others. GJP on the other hand, affects most teeth equally and is more severe, leading to the alternate clinical description of severe juvenile periodontitis. Defects in PMN function have also been associated with the early onset forms of periodontitis, suggesting that together with RPP, PMNs are important in protecting the host against periodontitis.

PMN Defects are Found in RPP, LJP and GJP, but not in CAP

PMNs have a critical role in defence against bacterial infections. For PMNs to fulfil their protective function, they must first emigrate from the blood into infected tissues. This makes endothelial-PMN adhesion an important first step in the functioning of PMNs. Once adherent, PMNs must exercise normal chemotaxis so as to find the offensive microorganism. Phagocytosis of the organism, followed by intracellular killing of the microbe, completes the task of these leukocytes. A number of defects in one or more of these critical steps in PMN function, have been associated with LJP, GJP and RPP.

Some authors have noted a layer of varying thickness of PMNs, separating

the body of the bacterial plaque from the pocket epithelial wall (Listgarten 1976, Frank 1980). It is reasonable to suggest that this is a "first line" of defence against plaque bacteria.

As discussed in Chapter 1, the leukocyte-specific integrins play an important role in adhesive interactions between ECs and leukocytes. It is reported that deficiency in these receptors is associated with RPP (Waldrop *et al.* 1987).

Defective chemotaxis is reported for PMNs from patients with diabetes melitis (McMullen *et al.* 1981), a group that also suffers from RPP. In LJP and GJP, most patients have defective chemotaxis and phagocytosis (Ciancola *et al.* 1977, Cogen *et al.* 1986). Also, LJP patients have a specific intracellular killing defect for the putative pathogen Actinobacillus actinomycetemcomitans (AA) (Kalmar *et al.* 1987). PMN phagocytosis is reported to be defective in patients with RPP, as compared with patients with CAP and periodontally healthy individuals (Katsuragi *et al.* 1988). In drug-induced agranulocytopenia (Bauer 1946), and cyclic neutropenia (Cohen and Morris 1961) the decrease in PMN number is associated with destructive periodontitis. Finally, a number of conditions such as Chediak-Higashi syndrome (Temple *et al.* 1972), and Papillon Le Fevre syndrome (Van Dyke *et al.* 1984) are associated with PMN dysfunction and destructive forms of periodontal disease. Neutrophil defects in diabetic and granulocytopenic rats (Ramamurthy *et al.* 1979, Pindborg 1949), as well as in minks and mice with Chediak Higashi syndrome (Lavine *et al.* 1976) are associated with rapidly destructive periodontitis.

The observation that PMN defects are correlated with the formation of periodontal pockets in a number of aggressive forms of the disease, although providing a focus for study of these rare conditions, poses a problem for the understanding of CAP. This is because there are no reports of systemic PMN dysfunctions in patients with this most common form of periodontitis.

A possible variable in the environment of the gingival crevice which might help account for the disease in otherwise healthy patients is the microbial plaque. To this end, much effort has been directed towards an understanding of the complex ecology of the microbial plaque associated with gingivitis and periodontitis lesions.

THE MICROBIAL FLORA IN PERIODONTITIS

The Non-Specific and Specific Plaque Hypotheses

Observations on the development and resolution of gingivitis lesions indicated that the disease was causally related to the accumulation of bacterial plaque in the gingival sulcus (Löe *et al.* 1965). Similarly, the severity of periodontitis was found to be related to the amount of bacterial plaque and calculus (calcified plaque) associated with the affected tooth (Russel 1967). This association between microbial mass and disease gave support to the non-specific plaque hypothesis, in which the sheer mass of microbial irritant is proposed to be sufficient to drive the chronic periodontal lesion (Loesch 1976).

Recently, however, the strong association between the presence of some species of plaque micro-organisms with various forms of periodontitis, has suggested that specific bacterial species may be responsible for the development of the advanced periodontal lesion. Further, it has been suggested that periodontitis may be a transmissible disease, in which the periodontopathic organism colonises gingivitis lesions in susceptible patients (Genco *et al.* 1988). This approach is sometimes referred to as the specific plaque hypothesis.

Potential Periodontopathic Microorganisms

The early plaque of healthy gingival tissues is composed principally of Gram positive organisms. These are mostly aerobic and facultative non motile rods and cocci of the genera *Streptococcus* and *Actinomyces* (Listgarten and Hellden 1978, Slots 1977a). With the development of gingivitis and periodontitis, there is a change in the composition of the bacterial plaque, resulting in a predominance of Gram negative, anaerobic, motile rods and spirochaetes (Slots *et al.* 1978, Slots 1977b).

Spirochaetes

Despite the fact that the number of spirochaetes found in plaque is strongly correlated with the severity of gingivitis and periodontitis (Listgarten and Helden 1978, Lindhe *et al.* 1980), there is relatively little information relating to the possible role of spirochaetes in the development of periodontitis. This is largely due to difficulties in isolating and culturing spirochaetes from plaque samples (Loesche 1988). Of some interest is the observation that *Treponema denticola* and *Treponema vincentii* inhibit some PMN functions (Boehringer *et al.* 1986, Taichman *et al.* 1982).

Actinobacillus Actinomycetemcomitans

The microbial flora associated with LJP has been intensively studied. AA, a small non motile, facultative, Gram negative rod, has been consistently found in large numbers in isolates from periodontal pockets in these patients (Slots *et al.* 1980, Slots and Listgarten 1988). This organism has also been isolated from the periodontal pockets of some patients with RPP (Mashimo *et al.* 1983) as well as with CAP (Slots *et al.* 1980 and 1986) suggesting that AA may play a role in the development of periodontal pockets amongst patients with differing forms of the disease. Some virulence factors that may contribute to the development of the disease have been described for AA. AA is known to produce a leukotoxin which is highly toxic to PMNs (Tsai *et al.* 1984), an immuno suppressive factor (Shenker *et al.* 1982), as well as collagenolytic enzymes (Robertson *et al.* 1982).

Bacteroides Species

Bacteroides gingivalis and *Bacteroides intermedius* are both members of the black pigmented bacteroides family of micro-organisms, and are obligate anaerobic, non-motile, Gram negative rods. Like AA, these organisms have been isolated from patients with LJP, but are also cultivated in large numbers from the subgingival microbial flora of patients with GJP (Wilson *et al.* 1985), CAP (Slots *et al.* 1986) and RPP (DiMurro *et al.* 1987). Inoculation of the monkey gingival crevice with *Bacteroides gingivalis* results in an accelerated rate of periodontal destruction and elevated levels of serum specific antibody levels (Holt *et al.* 1988). Again, the bacteroides species have potential virulence factors which may contribute to the development of the disease. The production of proteolytic enzymes (Slots 1981, Toda 1984), and anti-chemotactic and phagocytic factors has been documented (Slots and Genco 1984) for these species.

Invasion of Tissue by Periodontal Pathogens

There is immuno-histological and electron microscopic evidence for invasion of the gingival soft tissues by AA and *Bacteroides gingivalis* in sites affected with periodontitis. It was noted that the number of these invasive microorganisms was significantly higher in periodontal pockets which were active, as against sites in the same patients that were stable (Saglie *et al.* 1987). Earlier observations by the same group (Saglie *et al.* 1982) of tissues from a patient with LJP were consistent with their conclusion that bacterial invasion may play a role in pocket deepening. This is in contrast to the observations of Liakoni *et al.* (1985), who found few micro-

organisms in gingival biopsies from patients with CAP and LJP, and concluded that since the few organisms present were supposedly non motile, that they must have invaded passively, and were not a major factor in the development of the lesion. It must be noted, however, that Liakoni *et al.* (1985) did not have any information regarding the relative activity of the lesions studied.

The Complexity of the Microbial Ecology

Species other than AA and the bacteroides have also been found in relation to advancing lesions. Examples of these are: Eiconella corrodens, Fusobacterium nucleatum and Capnocytophaga ochracea. In total over 325 separate microbial species have been isolated from periodontal pockets (More 1987). As can be seen in Figure 2.5, the ecology of bacterial plaque as revealed by microscopy is clearly very heterogeneous, varying from site to site within a single periodontal pocket (Soames and Davies 1974). It is apparent that the plaque ecology is very complex, with simultaneous interactions occurring between many species as well as with the host.

With such a complex system, it is very difficult to determine whether the species apparently related to the appearance of periodontal pockets are the causative agents of pocket progression, or are simply opportunistic commensals, benefiting from the ecological niche provided by the pocket space. For example, in as much as AA may be causally related to LJP, it is also possible to interpret the large number of AA cells associated with this lesion as reflecting the specific resistance of AA to intracellular killing by PMNs from LJP patients as reported by Kalmar *et al.* (1987). Similar arguments apply for other species which are canvassed as periodontal pathogens. It is also now accepted that differences in isolation and culture techniques in different laboratories yield very different results and conclusions from similar raw material (More 1987).

Finally, since periodontitis is a long term chronic inflammatory disease, direct comparison of the microbial ecology of different lesions must be interpreted in relation to time. The age of lesions studied within a single patient may vary by decades. Also, the time elapsed since the last burst of pocket deepening will vary from site to site, and is impossible to assess without the aid of detailed clinical records. These considerations make meaningful interpretation of the microbial studies aimed at identifying causative agents of periodontitis, very difficult.

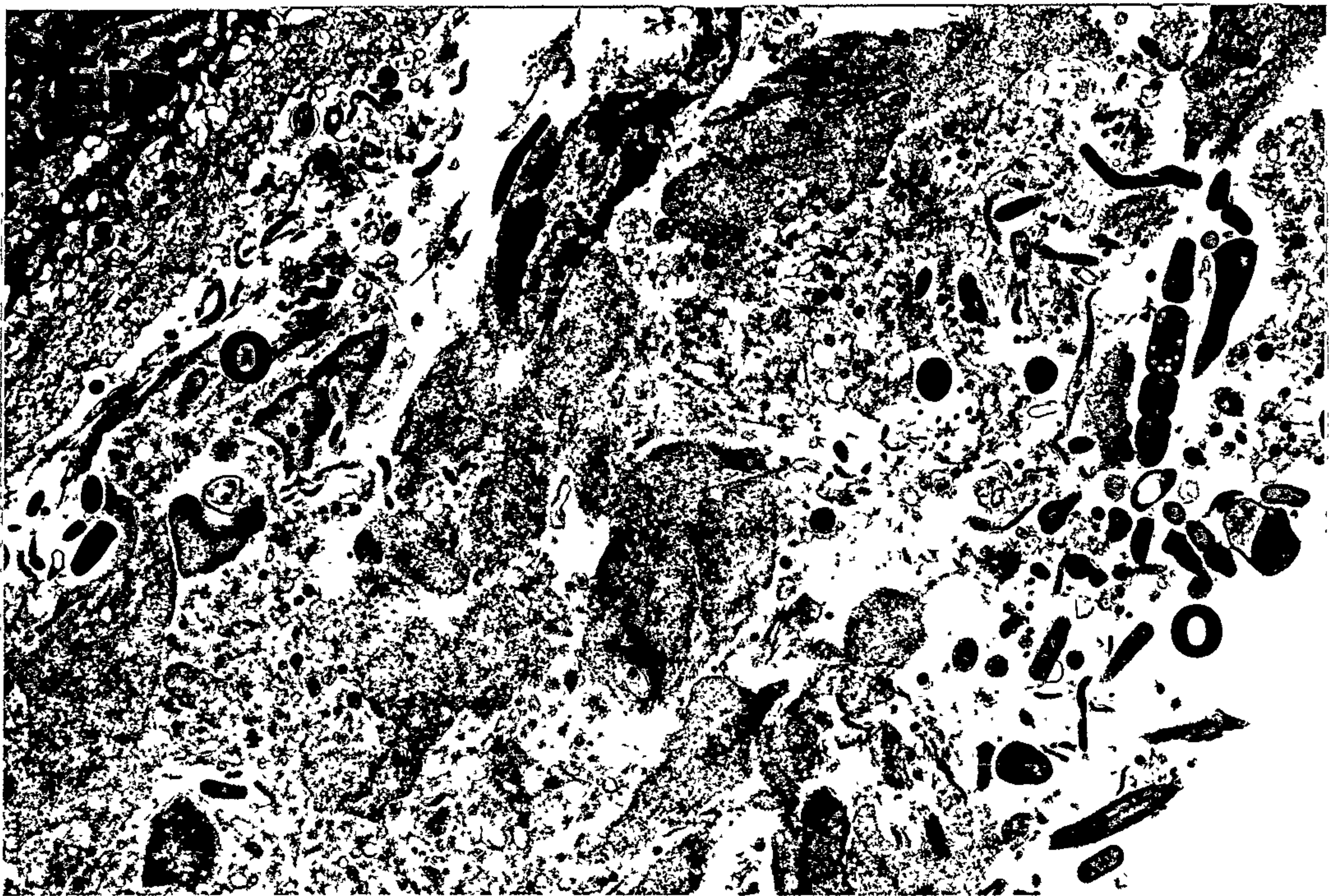
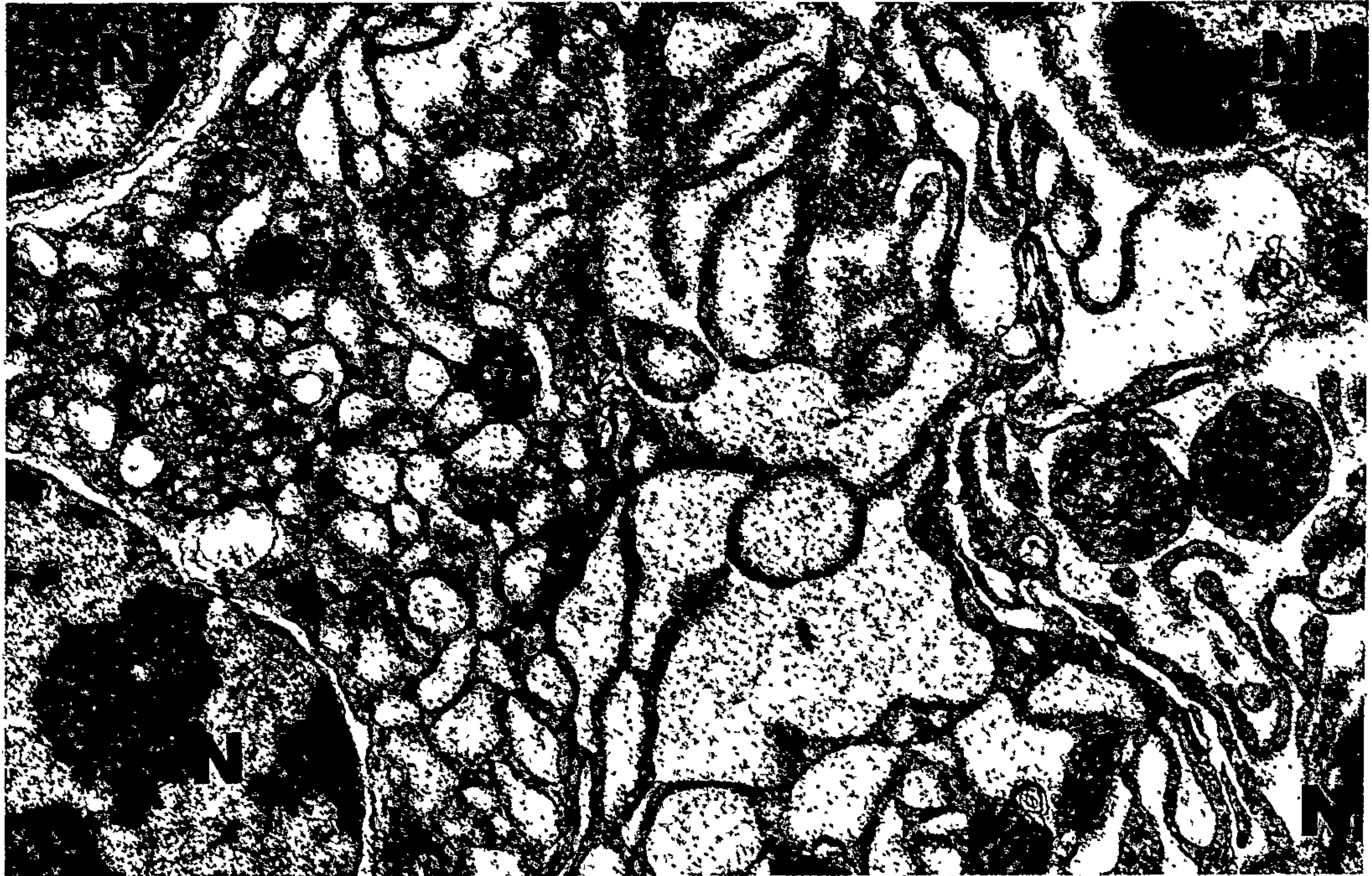


Figure 2.4

Electron micrograph of degenerate plasma cells in a gingival biopsy from a patient with periodontitis.

The nuclei of four plasma cells (N) can be seen, as can the membranes of swollen endoplasmic reticulum. Ribosomes are not seen on the endoplasmic reticulum. Continuity of the plasma membranes of the four cells has been lost, so that identification of the cell margins is not possible. It is suggested that these cells are non vital, but have escaped removal from the tissues by normal scavenging mechanisms. This could reflect the close proximity of bacterial plaque, which by the release of strong chemotactic factors, could commit macrophages to entering the plaque, rather than fulfilling their duties in debridement of the tissues. (TEM X 25,000)

Figure 2.5

Electron micrograph of organisms (O) in bacterial plaque adjacent to the pocket epithelium (Ep).

The complexity of the bacterial plaque in close apposition to the pocket epithelium (Ep) is clearly reflected by the morphological heterogeneity of the organisms seen in this field. The identity of the amorphous material separating groups of micro-organisms is difficult to determine, but is probably extracellular polysaccharide produced by the organisms. (TEM X 12,000)

ROLE OF THE IMMUNE RESPONSE IN PERIODONTITIS

The Antibody Response Against Periodontal Pathogens

As part of the effort to identify clinically relevant periodontal pathogens, and to understand the role of the humoral immune system in the development of the disease, much work has been done investigating the antibody response against potential periodontal pathogens, in patients with different forms of periodontitis.

Correlation between serum levels of antibodies against a number of suspected periodontal pathogens, and the clinical severity of periodontal disease has been reported for patients with CAP (Naito *et al.* 1985). LJP patients almost invariably have antibodies against AA, whereas the incidence of anti-AA antibodies is from 8 to 10 percent in the periodontally healthy population (Genco *et al.* 1988). Also, serum antibody levels against periodontal pathogens have been shown to drop in patients with RPP and LJP following treatment (Vincent *et al.* 1987).

In contrast to these observations, however, are reports describing a negative association of specific serum antibody levels with periodontal lesions (Doty *et al.* 1982, Tew *et al.* 1985). A further complicating factor in the question of the role of antibodies in defence against periodontitis, is the relative significance of locally produced immunoglobulin in inflamed gingival tissues. Explant studies have confirmed that local specific antibody production could make a major contribution to the humoral response against periodontal pathogens (Martin *et al.* 1986).

The question of whether immunoglobulin is protective against periodontal disease, or, if by activating the complement cascade and neutrophils, specific antibodies may result in localised tissue damage, is unresolved (Listgarten 1987). It does, however, seem likely that such antibodies would act as opsonins aiding PMNs in the phagocytosis of periodontal pathogens. Also, it is possible that complement derived chemotactic agents play an important role in attracting PMNs from the connective tissues into the bacterial plaque. There is, however, no need to invoke a role for antibody in such chemotaxis, as LPS which is prevalent in the Gram negative plaque, is capable of activating complement directly via the alternate pathway (Roitt and Lehner 1980). It is possible that the secretion of proteinases by some potential periodontal pathogens could protect these organisms against opsonisation by degrading specific antibody which is bound to the bacterial surface.

Change in the Composition of the Lymphoid Infiltrate from a T to B Cell Dominance

Tissues of the early gingivitis lesion harbour large numbers of T lymphocytes, which are progressively replaced with an infiltrate of B lymphocytes and plasma cells with the development of the established and advanced lesions (Mackler *et al.* 1977, Seymour and Greenspan 1979). Also, advanced lesions which bleed and exude pus on gentle probing, have significantly increased numbers of plasma cells as compared with lesions which have a less inflamed clinical presentation (Davenport *et al.* 1982). These lesions have been described as being active, although it is not clear that they are representative of sites undergoing a burst of pocket deepening.

The association between lymphoid cells of B cell origin and the development of advanced disease, has led to the proposition that the balance between B and T lymphocytes is important in controlling the tissue destruction manifested as pocket deepening (Seymour *et al.* 1979a, Seymour 1987). The apparently lower helper to suppressor T cell ratio of the advanced periodontal lesion, as compared with peripheral blood and gingivitis specimens (Taubman *et al.* 1984, Seymour 1987), as well as a reduction in the autologous mixed lymphocyte reaction in patients with periodontitis (Tew *et al.* 1983), are observations presented as evidence for the contribution of immunoregulatory defects in the pathogenesis of periodontitis. Studies in athymic rats indicate that periodontitis is more severe in these animals as compared with their euthymic counterparts (Yoshie *et al.* 1985). Also, the lesion in athymic animals is essentially a B cell lesion, whilst euthymic animals have T cell dominated lesions. It is suggested that alterations in the local production of cytokines in inflamed tissues related to imbalances in immune regulation, could account for the appearance of destructive lesions (Seymour 1987).

Although it is probable that the immune response plays a role in the development of the periodontitis lesion, and that immune competence will affect the ability of the host to respond to periodontal pathogens, there is no clear evidence of a causal relationship between immune suppression, and human periodontal disease. Surprisingly, with the advent of the recent epidemic of the Acquired Immune Deficiency Syndrome, there are no reports of an increased rate of periodontal breakdown in patients suffering this condition. Also, gingival biopsies of periodontitis sites from patients with defective leukocyte specific integrins, are heavily infiltrated with lymphoid cells, but display a clear paucity of PMNs (Waldrop *et al.* 1987). This could be interpreted as emphasising the importance of PMNs in defence against periodontitis and suggesting a secondary role for the immune response.

The precise role of the immune response in periodontitis has yet to be established. It is likely that it plays a supportive role in defence by supplying opsonins. However, changes in immune competent cell type that are associated with development of the advanced lesion, may simply reflect changes in the microbial flora, and perhaps do not contribute significantly to the critical factors responsible for pocket deepening.

POCKET DEEPENING

The cardinal sign of periodontitis is the presence of periodontal pockets. Several mechanisms for the formation of such pockets have been proposed.

An early suggestion by Gottlieb (1946) was that periodontal pockets were the consequence of an imbalance in the formation of tooth cementum. In this model, loss of a continuously forming periodontal ligament occurs, allowing the epithelium of the gingival sulcus to proliferate and cover the affected cementum. It has also been argued that failure to replace of the reduced enamel epithelium surrounding newly erupted teeth with oral epithelium, could predispose teeth to the formation of periodontal pockets (Skillen 1930, Cohen 1959). These ideas are not widely accepted, since they seem to be inconsistent with the timing of tooth eruption as compared with the onset of periodontitis, as well as with the sporadic nature of pocket deepening.

The fact that the pocket epithelium clearly defines the depth of periodontal pockets, suggested to several early workers that pocket deepening could result from proliferation of the sulcular epithelium along the length of the root (James and Counsell 1927, Becks 1929). The almost invasive appearance of the pocket epithelium, with long cords of epithelial cells reaching deep into the connective tissues, supports the idea that epithelial proliferation is an important component of the disease process (Aisenberg *et al.* 1948).

Further, it has been suggested that plaque bacterial enzymes capable of degrading connective tissue elements, could produce defects into which epithelial cells may proliferate (Aisenberg and Aisenberg 1951). In this hypothesis, the emphasis was shifted from an aggressive, to a responsive role for the epithelium. In support of this suggestion have been reports of the production of collagenase and other proteinases by potential periodontal pathogens (Uitto *et al.* 1986, Robertson *et al.* 1982, Slots 1981, Toda 1984). Several workers have raised the possibility that the host response to periodontal pathogens consists of connective tissue degradation, followed by proliferation of the epithelium to form periodontal pockets (Seymour *et*

al. 1979, Shenker 1987). The precise mechanism responsible for pocket deepening is undetermined, and it is likely that several mechanisms are involved. However, changes in the microbial flora of periodontal pockets during bursts of pocket deepening (Tanner *et al.* 1984), as well as the independent timing of these destructive episodes in separate sites in individuals (Goodson *et al.* 1982), suggest that highly localised changes in host defence, and the resulting microbial changes, are important in pocket formation. It seems likely that the study of such localised changes will help to explain the development of periodontal lesions.

QUESTIONS ARISING FROM THE LITERATURE

The lengthy time course of periodontal disease, the destructive nature of the disease process, as well as the intractability of the bacterial plaque irritant, ensure that periodontitis lesions are truly long standing chronic inflammatory sites. This, coupled with the relative ease with which periodontal tissues can be obtained, makes periodontitis an interesting disease with which to study the vascular response in chronic inflammation in humans.

The clinical and many of the histological and microbiological characteristics of periodontal disease have been described (Page and Schroeder 1976, Higgins *et al.* 1985, More 1987). PMNs have been identified as playing a key role in defence against the disease, and some periodontal pathogens appear to have evolved strategies for evading PMNs (Ciancola *et al.* 1977, Cogen *et al.* 1986, Tsai *et al.* 1984). However, it is not known what the specific role of PMNs in defence against periodontitis is, nor has the absence of detectable PMN defects in patients with CAP been explained. Further, there is a paucity of information relating to the mechanism of pocket deepening, especially with regard to the sporadic nature of pocket deepening. Also, the complex ecology of the bacterial plaque leaves the identity of many potentially important periodontal pathogens undetermined.

CHAPTER 3

EXPANSION OF THE VASCULATURE WITH PERIODONTITIS

INTRODUCTION

In order to quantitate the vascular changes that occur with the development of periodontal disease, a histological survey of the vasculature was made using gingival biopsies from patients with minimally inflamed gingiva, gingivitis and periodontitis. A number of changes were observed in blood vessels, and these are detailed in the next three chapters. This chapter deals particularly with the anatomical changes in vessels, that are associated with increasing severity of the disease.

LITERATURE REVIEW

Structure of the Normal Gingival Vasculature

By using latex casting techniques, Kindlova and Matena (1962) established that the vascular supply to the gingival soft tissues of the rat molar is separate from that of the periodontal ligament. Arterioles supplying the ligament entered the soft tissues through foramina in the bony wall of the socket, whilst the gingival tissues obtained their supply from arterioles coursing on the outside of the alveolar bone. The venular exit of gingival blood was described as being predominantly into the soft tissues overlying the alveolar bone, and partly into the periodontal ligament.

This overall pattern of vascular supply and drainage has been confirmed in other species including the squirrel monkey (Folke and Stallard 1967), mice, guinea pigs, cats and dogs (Carranza *et al.* 1966). The sub-epithelial capillary networks of the gingival sulcus, crest and oral mucosa anastomose freely, and drain into venules deeper in the tissues. These deeper venules establish further venous anastomoses between the networks (Nuki and Hock 1974). The oral mucosal network forms regular hair-pin capillary loops between epithelial retepegs, whilst the gingival crest has a regular vascular structure, with vessels forming repeating units (Nuki and Hock 1974). The organisation of the sulcular network is less certain in that some variation is reported for these vessels. Most reports describe the sulcular vascular network as a flat vascular system parallel to the sulcular epithelium (Egelberg 1966a, Kindlova

and Trnkova 1972), while others report a network of looping vessels, often described as glomerular structures (Kindlova 1965a, Carranza *et al.* 1966). More recent studies of rat gingival tissues have suggested that the plexus of vessels beneath the sulcular epithelium consists of a flat vascular network associated with tortuous vascular loops (Weeks and Sims 1986, Sims *et al.* 1988).

Changes Occurring with Gingival Inflammation

De Almeida and Böhm (1979) suggested that gingival tissues provided a convenient model with which to study the vascular response in chronic inflammation. Despite this, most studies of inflamed gingiva have focused upon anatomical rather than functional changes in the gingival vasculature.

Dilation of vessels beneath the gingival sulcular epithelium, and replacement of the normal network with a dense vascular system is reported for inflamed gingivae in desalivated rats (Kindlova 1965 b). With the onset of gingival inflammation in dogs, transition in the structure of the sulcular vascular network from a flat planar system to one dominated by looping vessels, occurs (Egelberg 1966a).

Vital microscopy and histopathology of the gingival tissues of cats, dogs, ferrets, opossums and monkeys revealed no difference in the vascular response to inflammatory stimuli for these species (Hock and Nuki 1971). These authors also noted that the planar sulcular vascular network was changed to one dominated by vascular loops with the onset of gingival inflammation. Also dilation of these vessels was recorded by the authors. Five stages were identified in the anatomical transition of these vessels, and it was felt that histopathological changes, particularly with regard to epithelial proliferation and leukocyte emigration, occurred after the vascular changes.

The crestal network in dogs was also found to undergo anatomical changes with the onset of gingivitis. This was characterised by the loss of some smaller connecting vessels in the repeating crestal vascular units, with the remaining vessels becoming longer, more tortuous and dilated (Nuki and Hock 1974). Dilation of the vessels in the oral epithelial network is also reported during gingival inflammation in humans (Von Franke 1964).

Schroeder *et al.* (1975) observed degradation of the collagen fibres surrounding blood vessels in close association with the sulcular epithelium in gingivitis specimens, implying a possible role for ECs in degradative processes.

Studies of Gingival Blood Flow and Vascular Permeability

Egelberg (1966b), found that little or no gingival fluid was formed by dogs with clinically healthy gingiva, and that increased vascular permeability occurred only when an irritant was applied to the gingival tissues. Egelberg (1966c), also found that post-capillary venules draining sub-epithelial capillaries, were responsible for the vascular leakage induced by histamine, but that trauma caused leakage from capillaries as well. It was clear from the correlation between vascular labelling and gingival fluid formation, that the vasculature was the source of gingival fluid. In contrast to these findings, De Almeida and Böhm (1979), found that the gingival vessels of rats with clinically healthy gingiva are quite permeable to colloidal carbon. This included capillaries forming the crevicular network.

Gingival blood flow in dogs, as determined using radiolabelled microspheres, is proportional to the severity of gingival inflammation (Hock and Kim 1987). It has been suggested that the increased severity of gingival degenerative changes in arteriosclerotic rats, could be due to nutritional deprivation of the tissues (Lassila and Koivumaa 1980 & 1982). It is, however, likely that regardless of the nutritional impact of an insufficient blood supply to inflamed gingival tissues, a reduced supply of defensive leukocytes and serum factors to inflamed gingival tissues would be detrimental to the host.

The Vasculature of Clinically Healthy Gingiva Reflects Minimal Inflammation

A problem with defining the "baseline" of normal vascular anatomy and permeability for gingival tissues, is in the establishment of truly uninflamed tissues. Gingival tissues are, by virtue of their location at the margins of teeth, unlikely to ever be totally free of irritation. For this reason, clinically healthy gingiva are usually described as being minimally inflamed, rather than as un-inflamed gingival tissues. Attempts to describe baseline vessels have been made in some of the studies cited above. Nuki and Hock (1974) for example, studied gingival tissues surrounding newly erupted deciduous teeth, on the assumption that there would not be time for significant vascular changes to occur. These authors noted that three weeks after eruption, the three sub-epithelial vascular networks underwent change to establish greater anastomosis than during the period of study. Since it is accepted that bacterial plaque is the cause of gingival inflammation, Sims *et al.* (1988) used gnotobiotic rats to assess the gingival vasculature. However, the absence of bacteria does not preclude gingival inflammation from physical trauma and from antigens to which the gingivae are exposed during feeding. It is possible that the conflicting reports of the presence

or absence of vascular loops in the sub-crevicular network, and of vascular permeability in healthy gingiva, reflect differential exposure to irritants in varying sites and animals. From this perspective, vascular loops may be symptomatic of gingival inflammation, even though Sims *et al.* (1988) have established the presence of these structures in minimally inflamed gingiva.

Questions arising from the literature

The anatomical features of gingival blood vessels in both health and disease have been described for many animal species (Kindlova and Matena 1962, Folke and Stallard 1967, Nuki and Hock 1974, Sims *et al.* 1988, Kindlova 1965b, Hock and Nuki 1971, Schroeder *et al.* 1975). In many of these studies, vascular perfusion techniques revealed the structure of the gingival vascular bed. However, since such studies can not be performed in humans, comparatively little is known about the blood vessels of the human gingiva. Vital microscopy of gingival blood vessels has supported histological studies (Von Franke 1964, Hock and Nuki 1971), however, the limited access and resolution afforded by this technique disallows a more complete description of the human gingival vasculature. Also, there are few studies of blood vessels in advanced periodontitis, so that differences in the vasculature of sites affected with periodontitis as compared with gingivitis have not been defined.

One means of overcoming some of these difficulties, would be to perform a histometric survey of blood vessels in gingival biopsies taken from patients with healthy gingivae, as well as from patients with gingivitis and advanced periodontitis. The remainder of this chapter describes such a histological study.

MATERIALS AND METHODS

Materials

Freon 22 was obtained from Du Pont. JB4 resin for embedding was supplied by Polysciences, and all other chemicals used were supplied by Sigma.

Tissues

Fifty one gingival biopsies were obtained with informed consent from separate, randomly selected patients immediately before extraction of teeth for clinical reasons. These were classified into one of three groups. Biopsies from sites with a probing depth of more than 4 mm were classified as chronic periodontitis. Specimens with a probing depth of 3mm or less were classified as either chronic gingivitis, or minimally inflamed. Gingivitis lesions had a gingival bleeding index of 2 or more and a dense, extensive cellular infiltrate. Fifteen minimally inflamed gingiva, sixteen gingivitis and twenty periodontitis specimens were studied.

Patients with periodontitis had a mean age of fifty four years, those with gingivitis had a mean age of forty nine years while minimally inflamed tissues were obtained from patients having a mean age of forty one years.

Patients donating tissues for the study did not report a history of diseases known to affect the microcirculation and had no recent history of periodontal therapy, so that it is assumed that gingivitis and periodontitis lesions are representative of long standing disease.

Tissue Processing for Light Microscopy

All tissues were processed by both fixation and freeze-substitution. Tissues were fixed with paraformaldehyde-lysine-periodate in cacodylate buffer at pH 7.2, (Senoo 1978). The tissues were then dehydrated in graded acetones and infiltrated and embedded in JB4 resin. Sections were cut to a thickness of 2 μ m using glass knives in a Sorval JB4 microtome.

Freeze-substitution was performed on thin slices of tissues by snap freezing in liquid freon 22 cooled by liquid nitrogen. Frozen tissues were dehydrated with four changes of acetone at -40°C, before being infiltrated at -20°C and embedded in JB4 resin at 4°C. Sections were made in the same manner as for fixed tissues. Blocks and slides were stored desiccated at 4°C.

Quantification of General Characteristics of the Microcirculation

Division of the Biopsy into Five Fields

Slides were coded, and the gingival biopsy divided into five fields as shown in Figure 3.1. Within these fields, zones were selected at random and studied at a magnification of 312. Zones were defined by the border of a photographic graticule aligned against the basal surface of the pocket epithelium.

Staining to Assist in Determination of Vessel Type

The particular focus of this study is upon vascular ECs, so it was decided to classify blood vessels on the basis of the morphological appearance of the constitutive ECs of vessels. In pilot studies, vessels of a similar appearance to HEVs were found in many biopsies. These were classified as periodontal high endothelial like venules (PHELVs). Also, in preliminary studies using freeze-substituted tissues, it was found that PHELVs were alkaline phosphatase negative, whilst other blood vessels with more flat ECs had alkaline phosphatase activity (APA) (Figure 3.2a). EC APA was present in most vessels including large collecting venules deep in the tissues (Figure 3.2b), although the presence and intensity of deep venular EC APA was variable amongst different biopsies. The height of ECs in AP positive vessels varied, and on this basis, vessels could be categorised as either flat endothelial vessels (FEVs) or moderately high endothelial vessels (MEVs). It was decided that EC APA could be used to help to differentiate PHELVs from the more common MEVs, and for this reason tissues used in the quantitative study of vascular changes were stained for APA (Higuchi *et al.* 1979) and counterstained with haematoxylin. A problem with freeze-substituted specimens was that occasional patches of ice crystal damage made an effective random assessment of the vasculature impossible. To overcome this problem, fixed tissues were used in the quantitative assessment. Tissues processed by fixation gave excellent morphology, however some loss of EC APA occurred during fixation. Nonetheless, APA was still found to be a useful marker for MEVs, thereby indirectly assisting the identification of PHELVs. Figure 3.2c shows FEVs MEVs and PHELVs as they appeared in the fixed tissues used in the quantitative assessment.

With frequent use of a reference slide, vessels were classified on the basis of their endothelial height ranging from flat to medium to high. Also, the density of nuclear staining was graded as being dense, moderate or vesicular. The presence of APA was recorded, as was the vessel type as being an arteriole, capillary, small venule, or a collecting venule. Vessels with a predominance of HECs with large vesicular nuclei and prominent nucleoli, but lacking APA were classified as PHELVs, whilst other vessels were recorded as being FEVs or MEVs according to the height

of the majority of the constitutive ECs.

Vessel Size

With frequent use of a reference slide, the diameter of all vessels within these zones was recorded as being: small, small to moderate, moderate, moderate to large or large (Figure 3.2d). Arterioles were noted, but were few in number. To achieve a comparable number of vessels in all zones despite variability in the amount of space occupied by epithelium, the actual vessel number was multiplied by a correction factor determined as 100 divided by the percentage of space occupied by connective tissue in the zone.

Statistical Procedures

It was decided that a normal distribution of the data could not be assumed, so that non-parametric tests of significance were applied. These were Wilcoxon's Rank Sign test, the Mann-Whitney U test and the Chi-Squared test (Champion 1970). Data is summarised in histograms, and standard errors of a proportion are indicated where appropriate. When large numbers of Wilcoxon's and Mann-Whitney U tests were required, these were done using the SPSSx information analysis system on the Cyber computer at the University of Sydney. P values of statistical significance obtained using the SPSSx program are given as exact values of p. Remaining statistical tests were performed manually, and yield p values as being less than a given probability.

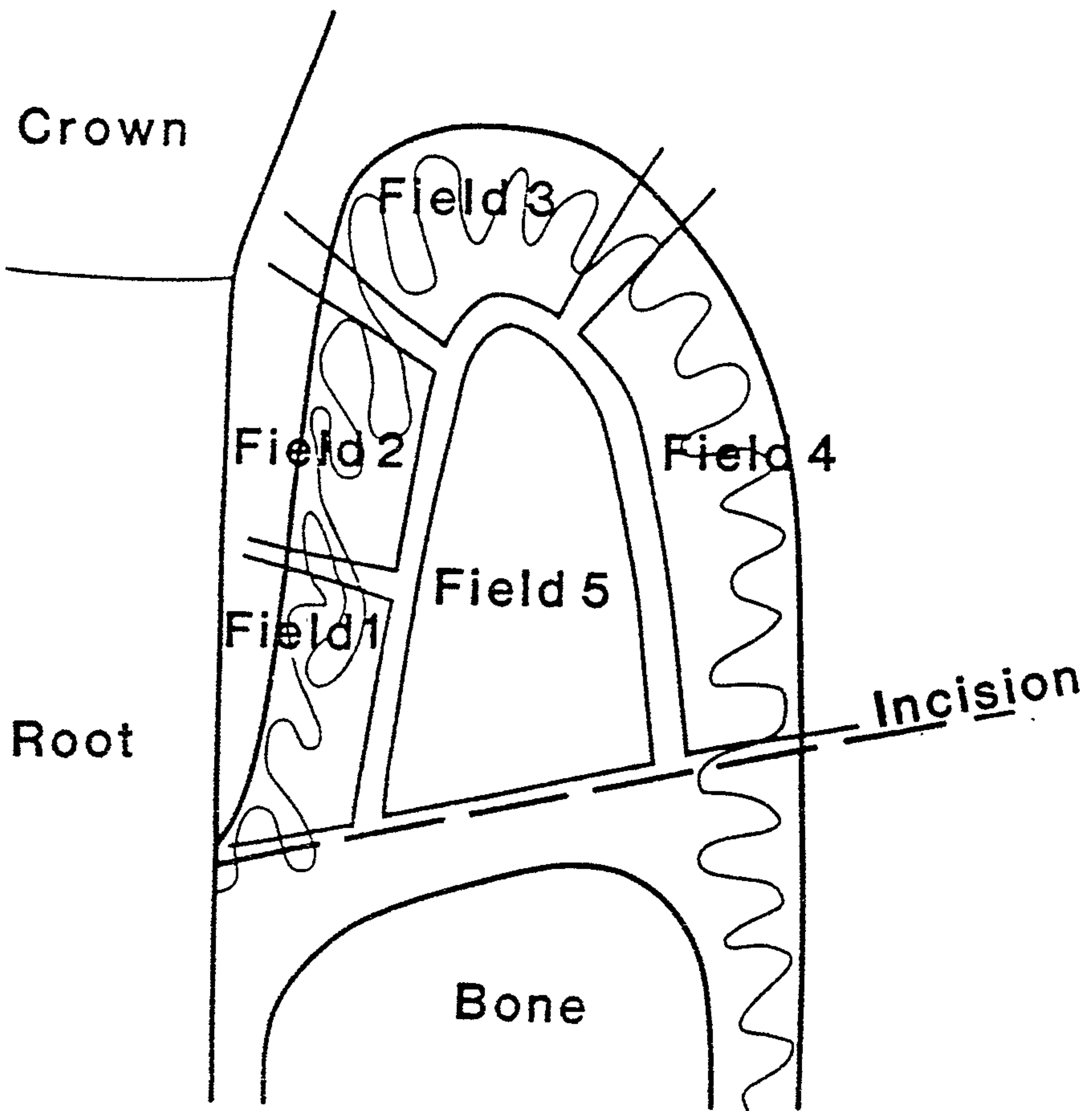


Figure 3.1

Diagram showing division into 5 fields of a gingival biopsy from a tooth with periodontitis.

The biopsy was obtained by excision of the gingival soft tissues to the depth of the periodontal pocket. Field 1 was the most apical half of the periodontal pocket wall. Since it is from here that pocket deepening must progress, it is assumed that Field 1 represents the active front of the advancing lesion. Field 2 was the most coronal half of the pocket wall, and was absent in gingivitis and minimally inflamed specimens since these tissues had insufficient sulcular depth to accommodate a second field. Field 3 represented the gingival crest, where the pocket or sulcular epithelium reflects onto the oral mucosal epithelium. Field 4 was the oral mucosal area. Field 5 consisted of the deep connective tissues of the gingival biopsy.

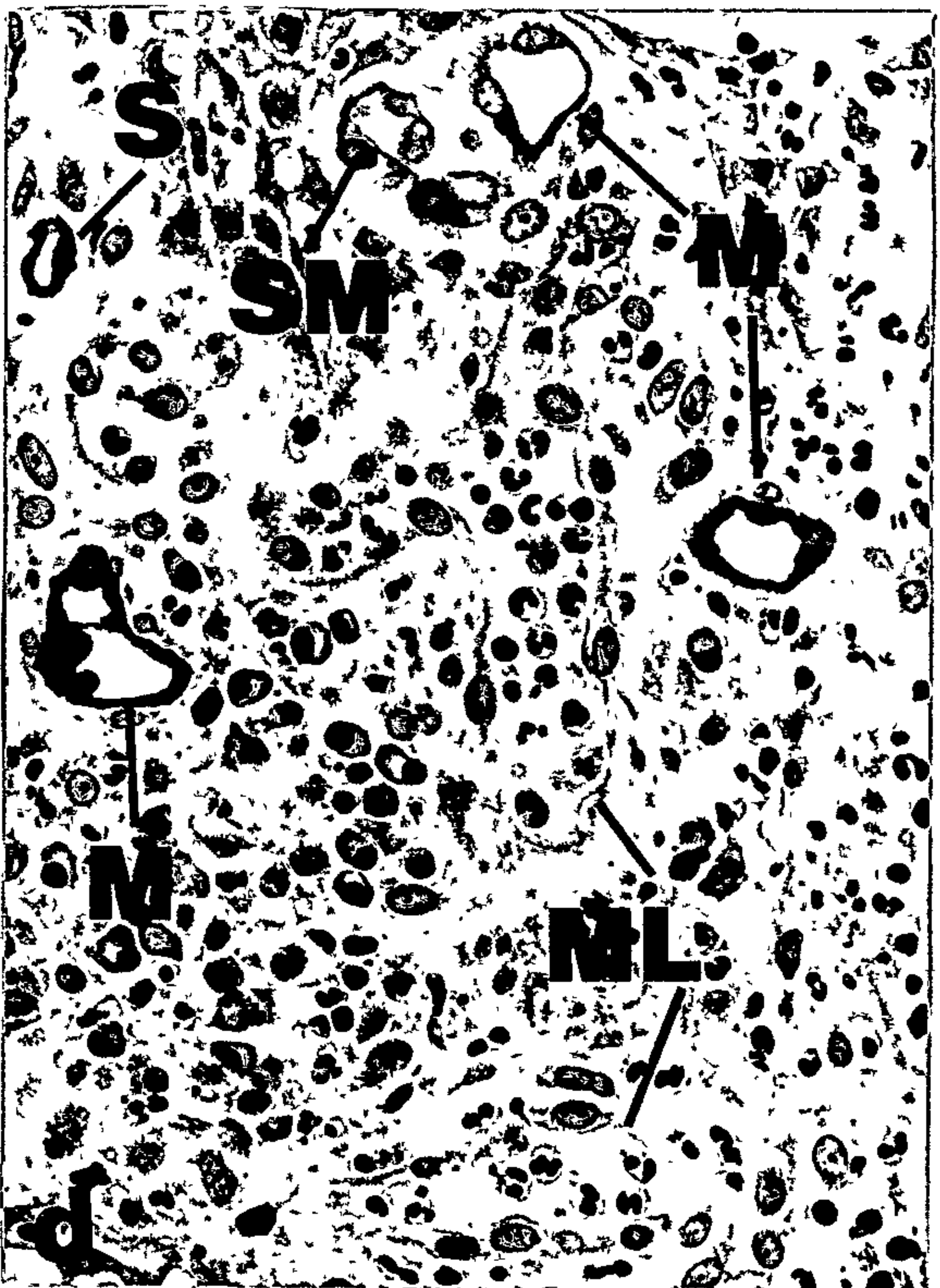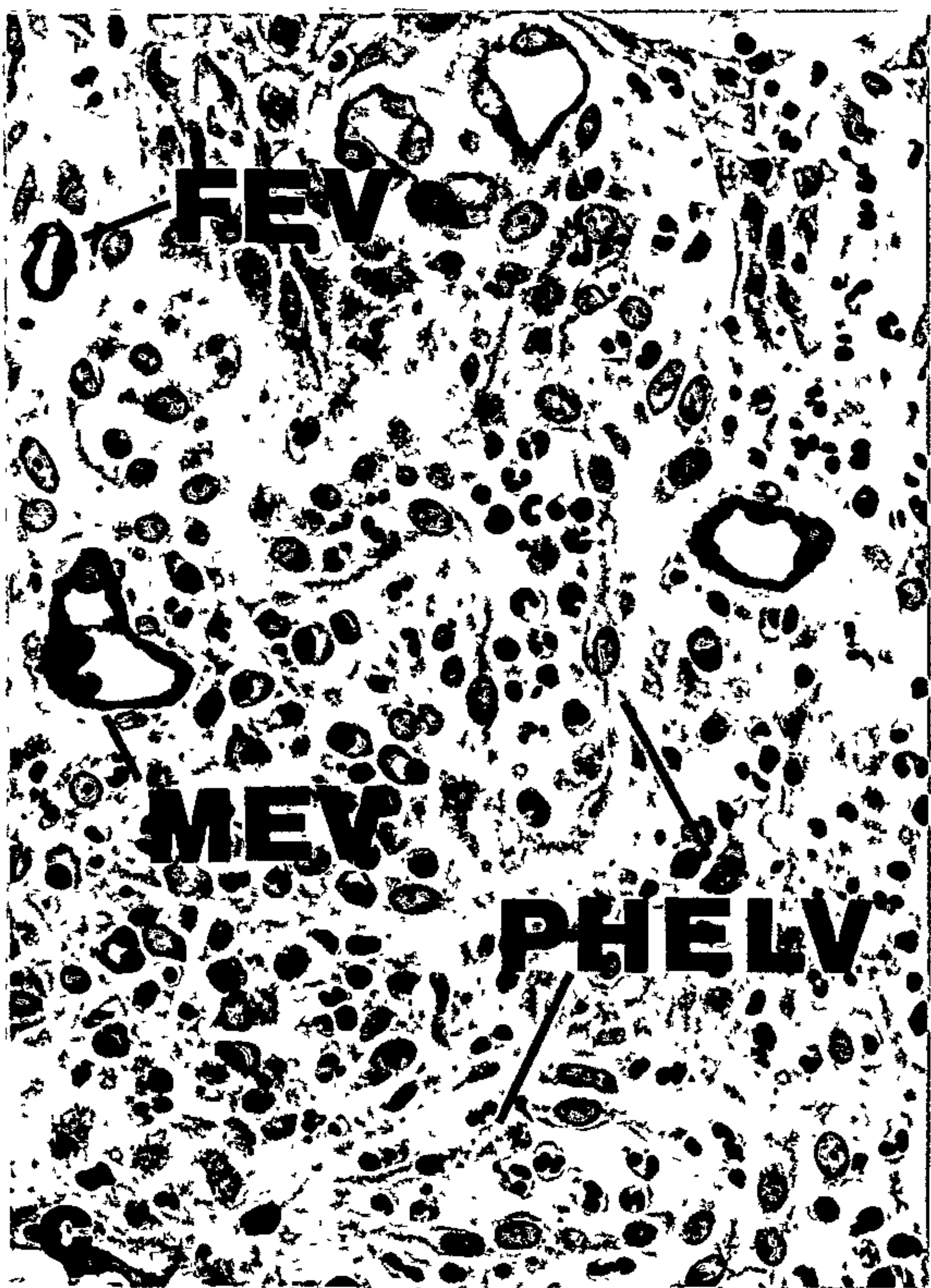
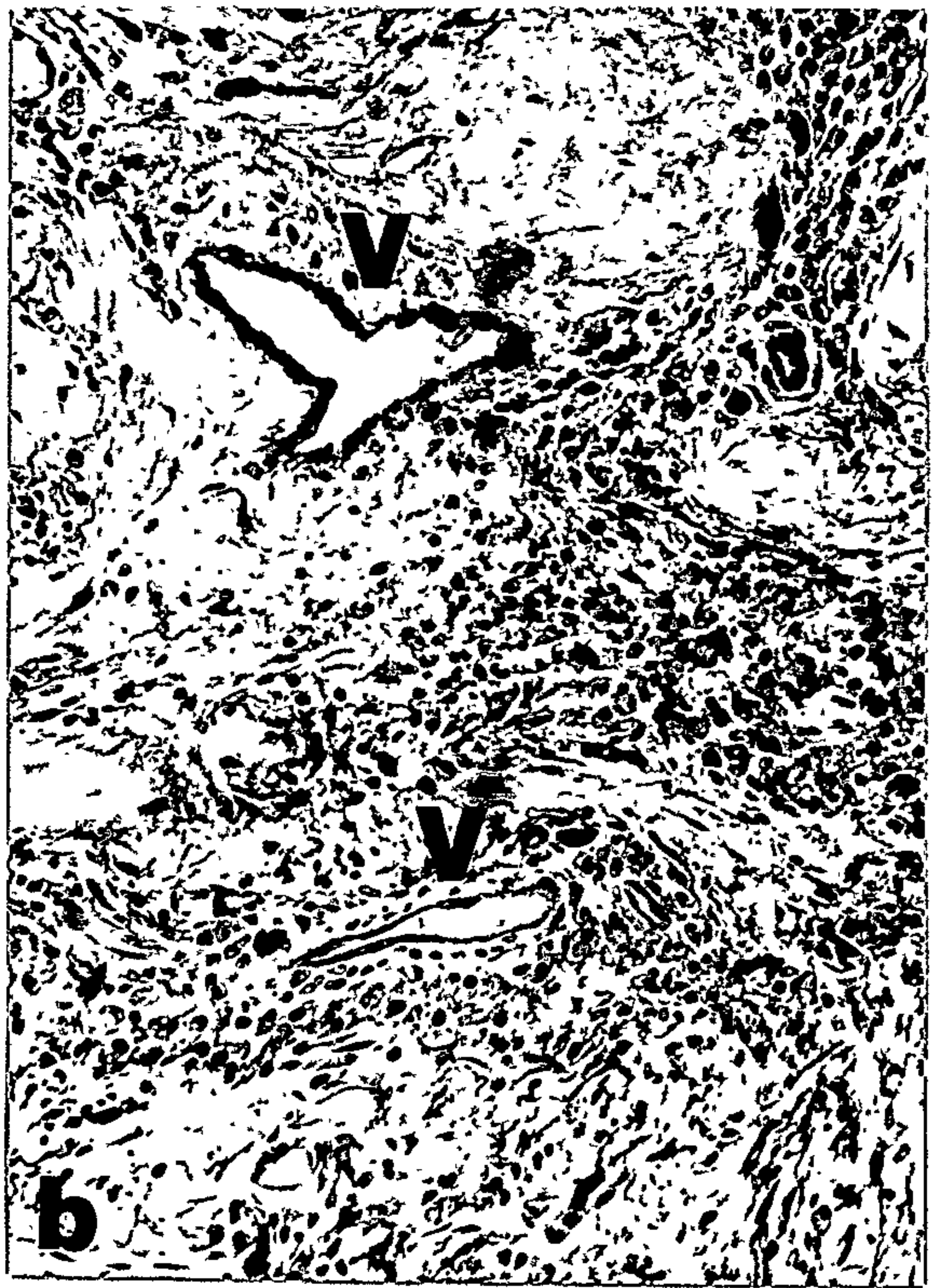

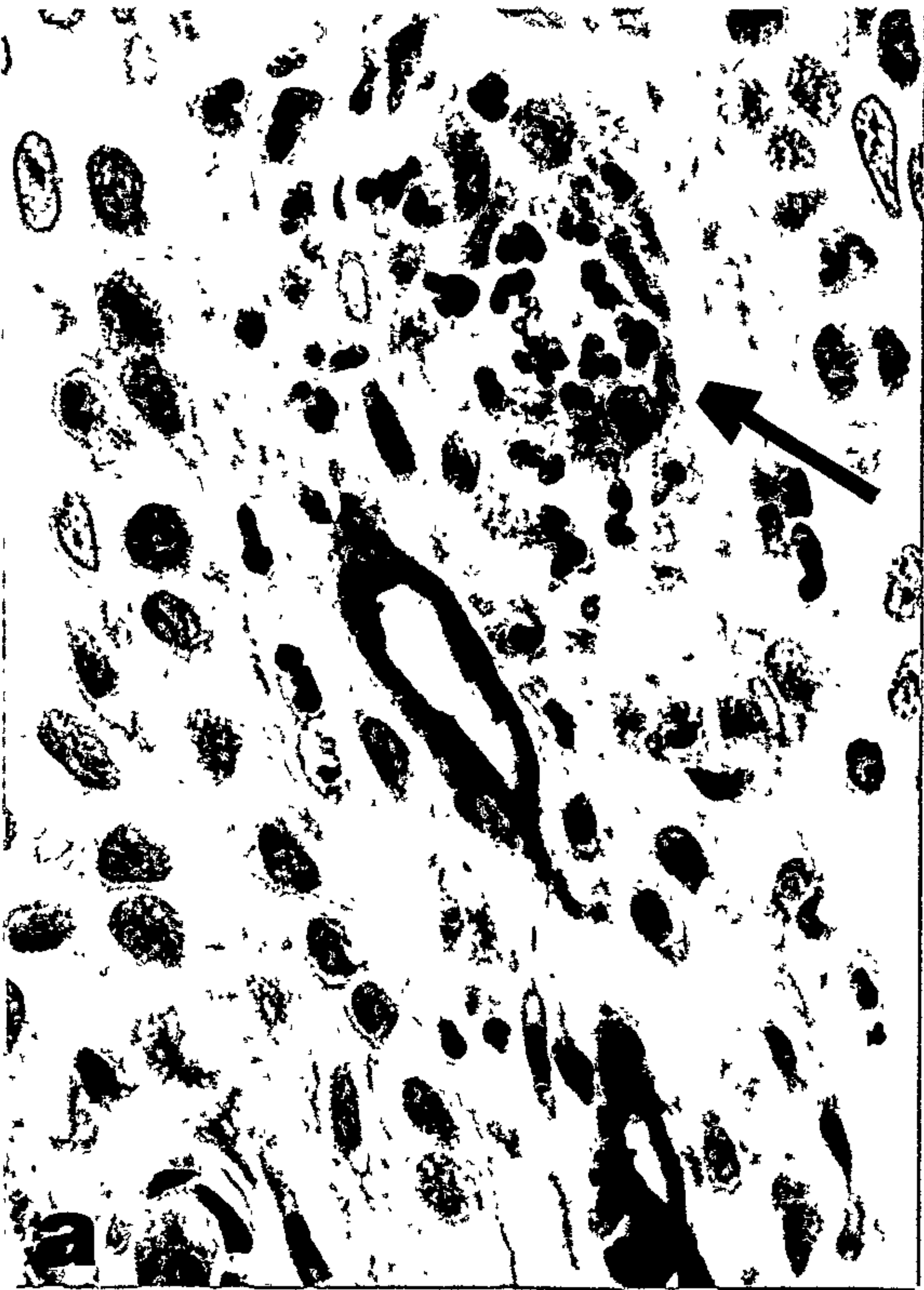
Figure 3.2a

Photomicrograph from a gingival biopsy, treated by freeze-substitution and stained for APA.

A PHELV (Arrow) is seen to lack APA, while more flat vessels are clearly APA positive. (Alkaline Phosphatase + Haematoxylin X 350)

Figure 3.2b

Photomicrograph from a gingival biopsy, treated by freeze-substitution and stained for APA.

APA was highly variable in these deep vessels (V), with both vessels indicated in this photomicrograph displaying very different degrees of activity. However, despite this, APA was consistently absent in PHELVs. (Alkaline Phosphatase + Haematoxylin X 280)

Figure 3.2c

Photomicrograph of blood vessels in a typical fixed gingival biopsy used in the quantitative study.

Vessels were classified as being flat endothelial vessels (FEVs), moderately high endothelial venules (MEVs) or periodontal high endothelial like venules (PHELVs), on the basis of the height of the most prevalent endothelial cell type in individual vessels. In this photo-micrograph, the intense APA of FEVs and MEVs is in clear contrast to the absence of the activity in PHELVs. (Alkaline Phosphatase + Haematoxylin X 312)

Figure 3.2d

Identical photomicrograph to that shown in Figure 3.2c, with vessels labelled according to size.

Small vessels (S), small to moderate (SM), moderate (M) and moderate to large (ML) are indicated. Vessels of sizes outside of the range of those shown in this photomicrograph were classified as either large or S vessels. (Alkaline Phosphatase + Haematoxylin X 312)

RESULTS

General Observations of the Microvasculature

Fields 1 and 2

In minimally inflamed tissues, the majority of vessels were capillaries close to the epithelium. The vessel profiles ranged from having a circular outline to elongated and elliptical profiles. The axis of elongated vessel profiles was often parallel to the sulcular epithelium, suggesting that these vessels formed a planar sub-epithelial network (Figure 3.3a). The sulcular epithelium appeared to have a greater thickness and less prolific rete pegs, as compared with gingivitis and periodontitis lesions.

Gingivitis and periodontitis specimens had a very similar appearance in Field 1 (Figure 3.3b). In these sites, the vasculature was dominated by a complex of capillaries in close association with the pocket or sulcular epithelium. The close proximity of circular and elliptical vessel profiles, often clustered into small groups, gave the appearance of a tortuous subepithelial complex of vessels. These superficial vessels drained into post-capillary venules which were often classified as PHELVs. Proliferation of the epithelium was evident in the form of long rete pegs which reached deep into the connective tissue. The sulcular epithelium in actual contact with the bacterial plaque was typically very thin and often had only one or two epithelial cell layers.

Field 2 of periodontitis often had a similar appearance to Field 1. However, on other occasions the vessels seemed to be less tortuous in Field 2 as compared with Field 1. Also, the epithelium was often thicker and had a less activated appearance as compared with Field 1 of the lesion (Figure 3.3c).

Few arterioles were found supplying Fields 1 and 2 in the lesions studied. Those arterioles that were found, approached the sub-epithelial network from deeper in the gingival tissues, and seemed to proceed in a perpendicular direction to the epithelial surface. The paucity of arterioles relative to other vessel types was a consistent feature in all fields and lesions studied.

Field 3

The appearance of Field 3 was similar in all three types of lesion studied (Figure 3.3d). Most vessel profiles consisted of capillaries cut along their length, perpendicular to the epithelial surface. This gave the impression of capillary loops within long connective tissue papillae, separating epithelial rete pegs. As in Fields 1 and 2, very few arterioles were found.

In gingivitis and periodontitis specimens, the inflammatory infiltrate of Fields 1 and 2 occasionally involved Field 3.

Field 4

Field 4 had a similar appearance in all lesions studied. Field 4 resembled Field 3, except that the epithelial retepegs were often shorter (Figure 3.3e).

Field 5

Field 5 had a similar appearance in all lesions studied, with the vasculature consisting mostly of venules draining the sub-epithelial capillary networks, as well as a small number of attendant arterioles. In inflamed tissues, many of the collecting venules in Field 5 were surrounded by plasma cell infiltrates (Figure 3.3f).

The Number of Vessel Profiles

As illustrated in Figure 3.4, there were differences in the number of vessel profiles between fields for each of the lesion types studied, with the number of vessel profiles generally decreasing with increasing field number. However, it was only in Field 1 that a clear difference in the number of vessel profiles was found between different lesion types. Here, periodontitis specimens were demonstrated to have more vessel profiles, as compared with minimally inflamed ($p = 0.001$) and gingivitis specimens ($p = 0.004$). This suggests that in periodontitis, there is an increase in either the number of vessels present, or that existing vessels have become more tortuous increasing the apparent vessel number.

Also, fewer vessels were found in Field 5 than in other parts of gingival biopsies, reflecting the relative avascularity of the deeper gingival connective tissues.

Vessel Size

The proportional distribution of vessels according to size for Fields 1 to 5 are shown graphically in Figure 3.5. Changes in the size of vessels were determined by noting differences in the distribution of vessels according to size within fields. Periodontitis specimens had larger vessels as compared with equivalent fields in gingivitis specimens ($p < 0.01$ in Field 1 and $p < 0.001$ for other fields) and minimally inflamed tissues ($p < 0.001$). Also, there were more larger vessels in gingivitis lesions than in minimally inflamed tissues ($p < 0.001$).

However, an exception to this pattern was found in Field 4, where vessels in minimally inflamed tissues were larger as compared with those in gingivitis specimens ($p < 0.01$).

Relative Proportions of Vessel Types According to Endothelial Cell Height

The percentage distribution of vessels according to EC height are shown in Figure 3.6. For each of the lesion types studied, PHELVs were always less prevalent as compared with MEVs ($p < 0.024$). Similarly, FEVs exceeded in number both MEVs ($p < 0.034$) and PHELVs ($p < 0.03$) in almost all fields and lesion types studied. Exceptions to this were in Field 4 of periodontitis and in Field 5 of gingivitis specimens, where no significant difference was demonstrated in the relative proportion of FEVs and MEVs. Also, in Field 5 of periodontitis specimens, MEVs exceeded FEVs in number ($p = 0.0421$).

Within fields, the incidence of FEVs varied slightly between the three types of tissue studied, so that in Fields 1 and 5, significant differences were demonstrated between periodontitis specimens and both gingivitis ($p < 0.017$) and minimally inflamed tissues ($p < 0.037$). Significant differences amongst different lesion types in the incidence of MEVs were only found in Field 4, where periodontitis specimens had more MEVs as compared with gingivitis specimens ($p = 0.0143$).

PHELVs varied in incidence for like fields according to lesion type in Fields 1 and 5. In Field 1, there were more PHELVs in periodontitis than in gingivitis specimens ($p = 0.0075$) and minimally inflamed tissues ($p = 0.0019$). Also, there were more PHELVs in Field 1 as compared with Field 2 of periodontitis lesions ($p = 0.0243$). In Field 5 there were significantly more PHELVs in periodontitis specimens than in both gingivitis ($p = 0.0008$) and minimally inflamed tissues ($p = 0.0099$).

It was concluded that PHELVs represent the smallest component of the vasculature as defined by EC height, and that these vessels are strongly associated with progression of inflammatory disease from health to periodontitis.


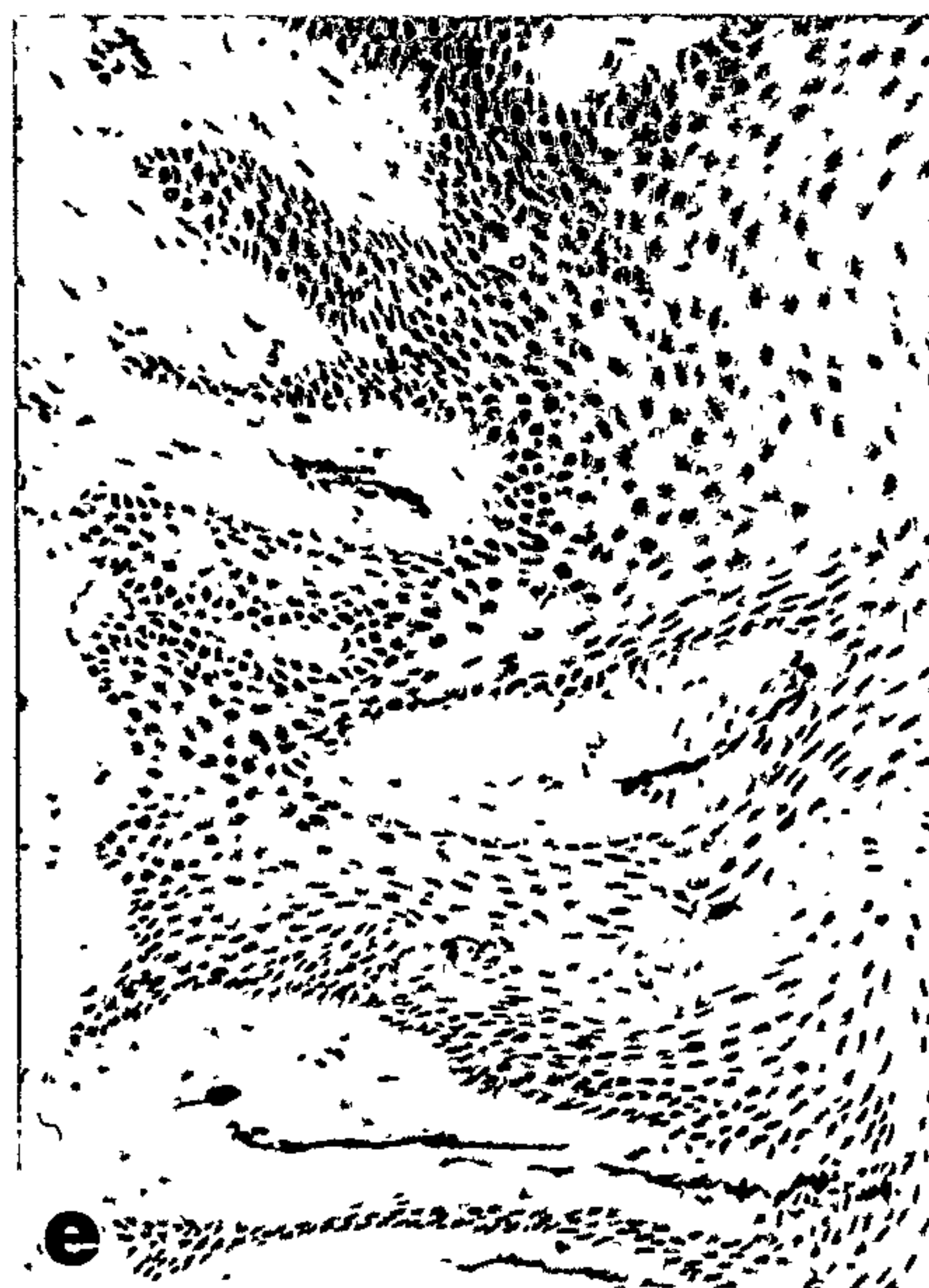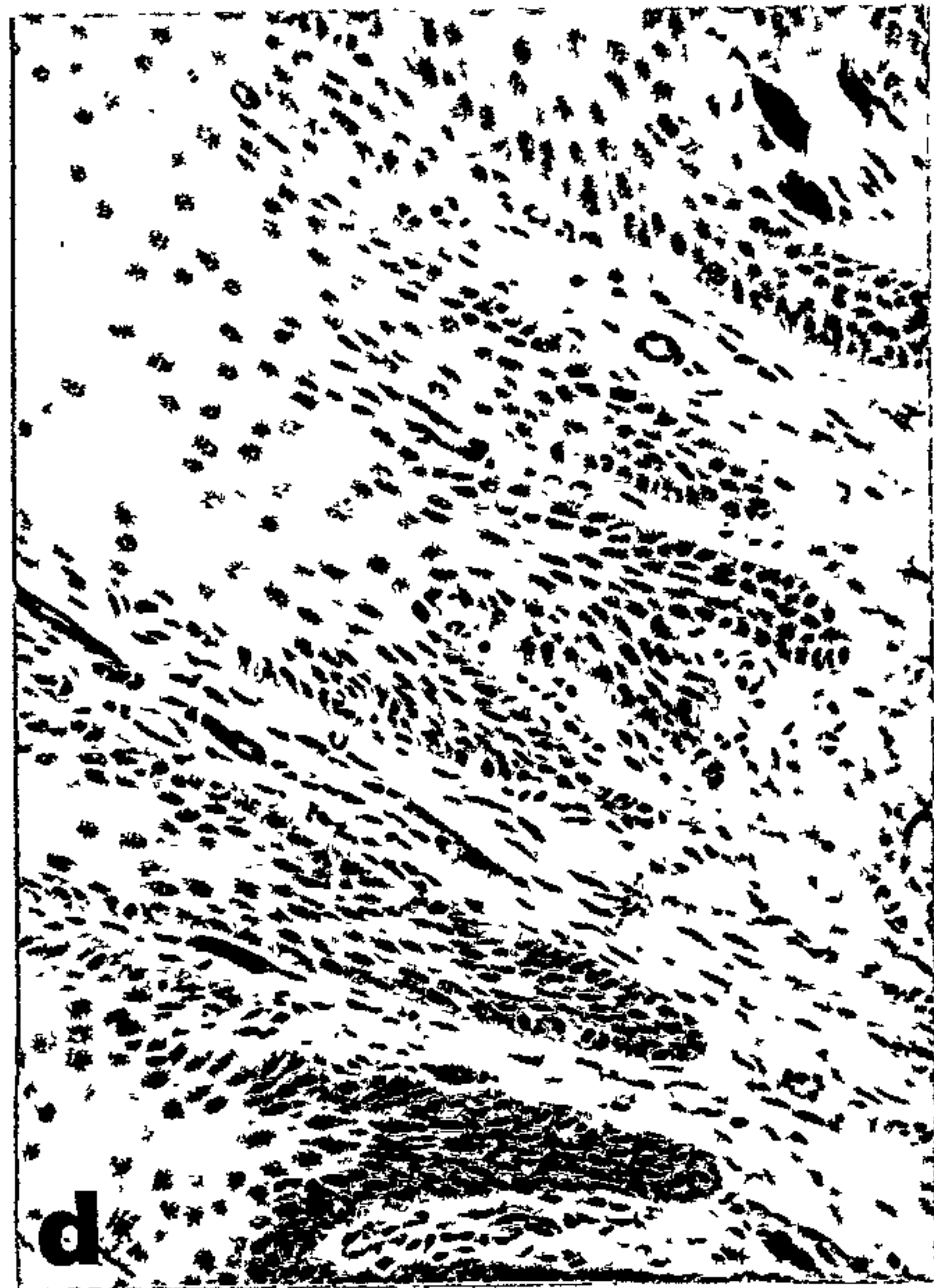
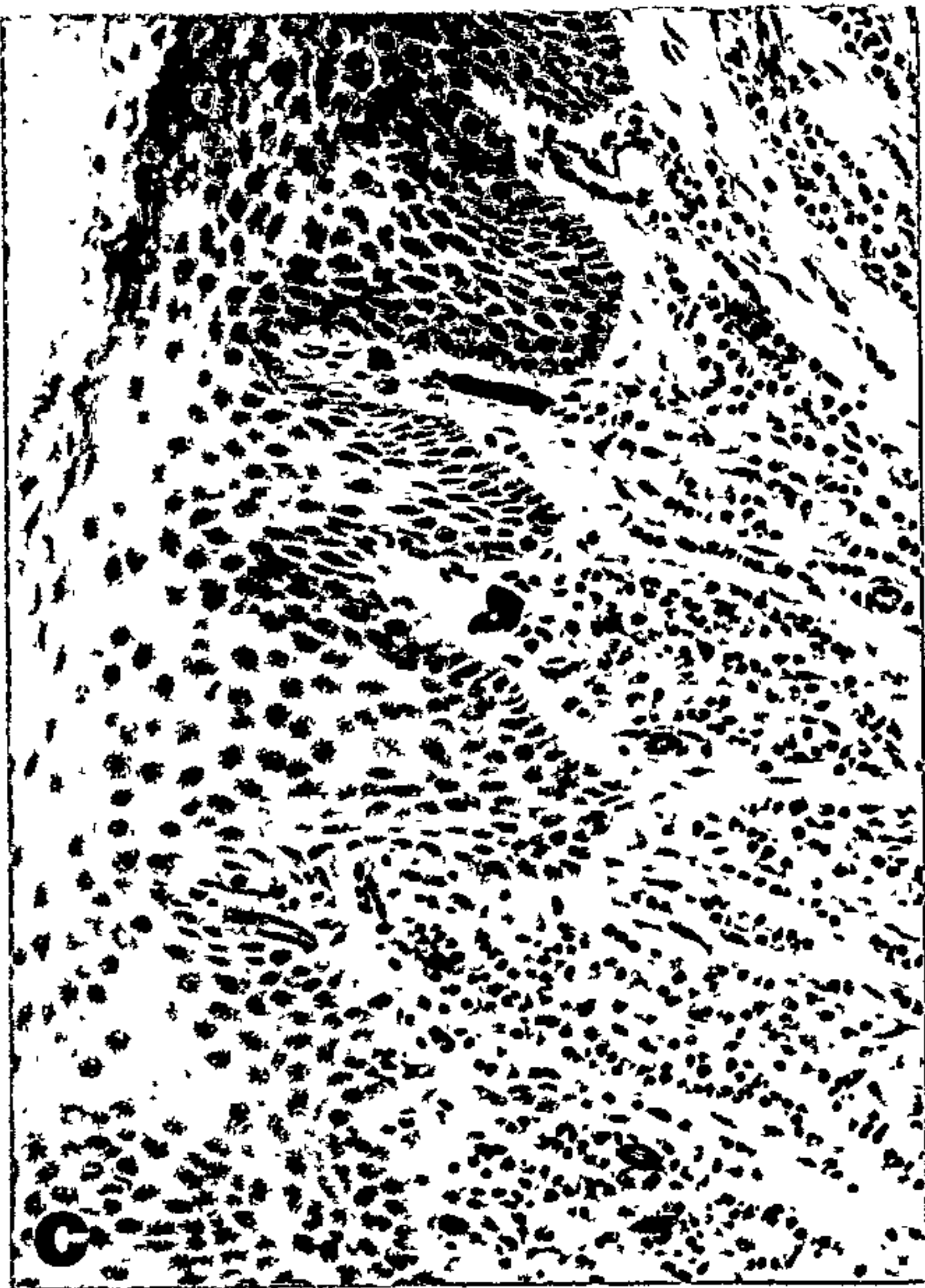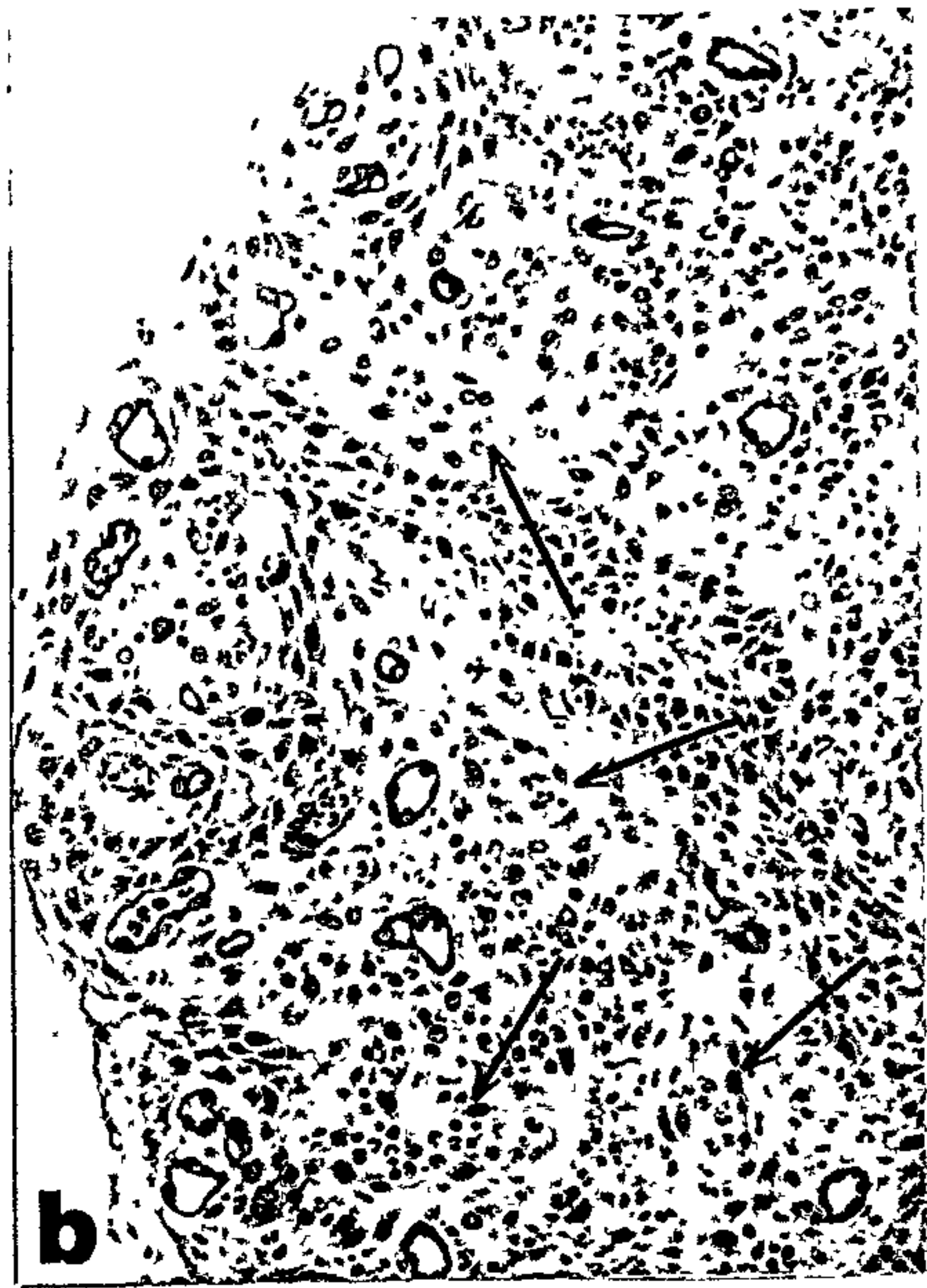
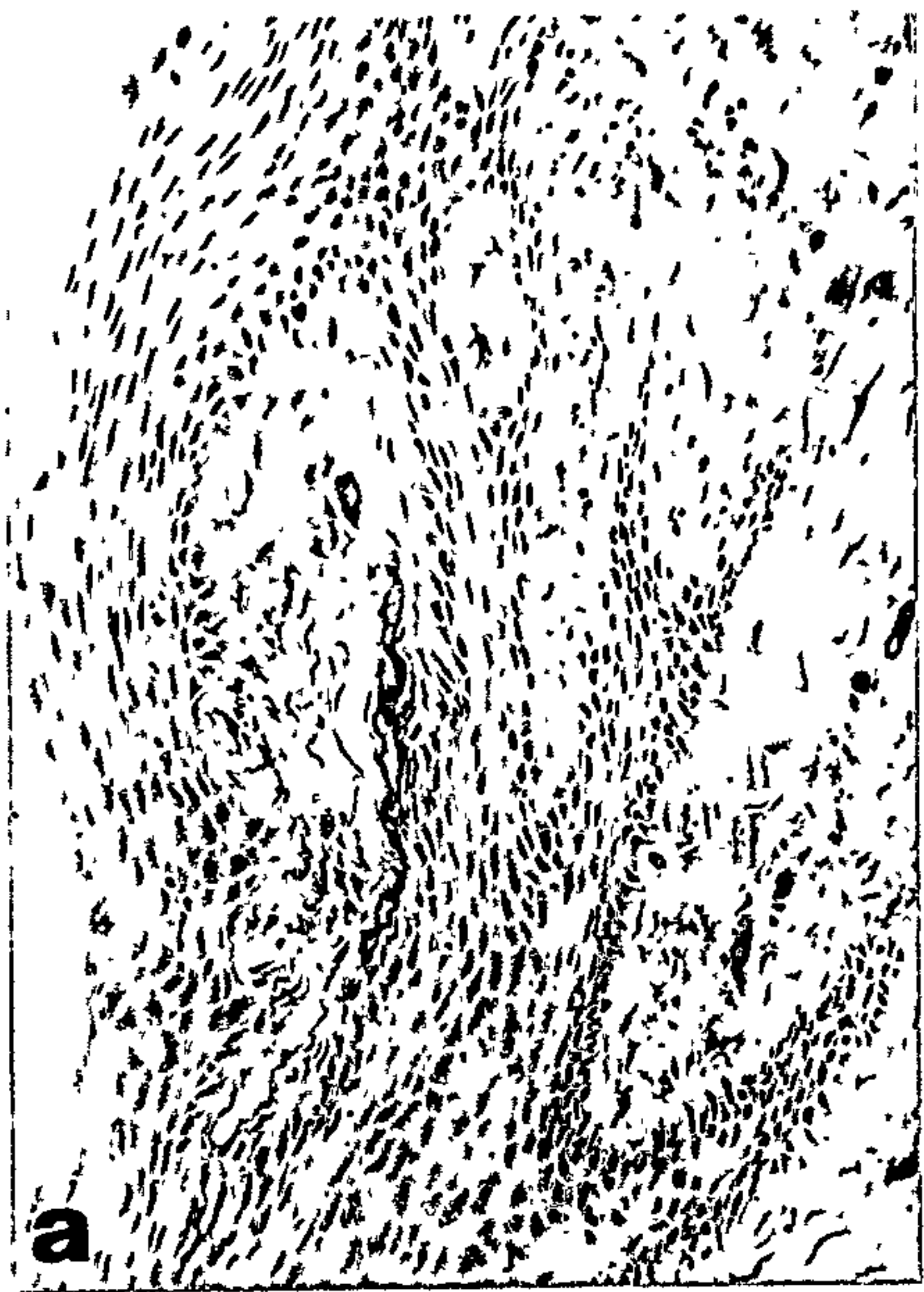


Figure 3.3a Representative photomicrograph of Field 1 of minimally inflamed tissues. There are few inflammatory cells in the tissues, and the sulcular epithelium is thicker with less pronounced rete-pegs as compared with inflamed tissues. The vasculature consists principally of a planar network of capillaries underlying the sulcular epithelium. (Alkaline Phosphatase and Haematoxylin x 312)

Figure 3.3b Representative photomicrograph of Field 1 of periodontitis and gingivitis specimens. The epithelium is clearly active, with long cords reaching into the underlying connective tissues. The connective tissues are heavily infiltrated with plasma cells, and PMNs are seen migrating in large numbers towards the bacterial plaque, often within the epithelial cords. PHELVs (Arrows) are present, draining a system of superficial capillaries. (Alkaline Phosphatase + Haematoxylin X 312)

Figure 3.3c Many periodontitis Field 2 sites had a similar appearance to field 1, however, on other occasions, Field 2 had a less active appearance. This photomicrograph is typical of these sites. Fewer inflammatory cells as compared with Field 1 were found. Also the epithelium was often thicker with less pronounced rete pegs as compared with Field 1. The vasculature in these sites seemed to have fewer PHELVs as compared to Field 1. (Alkaline Phosphatase + Haematoxylin X 312)

Figure 3.3d Representative photomicrograph of Field 3 in a periodontitis specimen. This field had an essentially similar appearance in all three types of lesions studied, with inflamed tissues having occasional collections of inflammatory cells within the connective tissues. The epithelial rete pegs had an elongated appearance, and the vasculature consisted mostly of hair-pin loop capillaries reaching high into the connective tissue papillae separating retepegs. (Alkaline Phosphatase + Haematoxylin X 312)

Figure 3.3e Photomicrograph of Field 4 from a periodontitis specimen. Field 4 had a similar appearance to Field 3 in all of the lesions studied, except in that the length of the epithelial retepegs was shorter, and inflammatory cells were rarely found in this field. (Alkaline Phosphatase + Haematoxylin X 312)

Figure 3.3f Photomicrograph of Field 5 from a specimen with periodontitis. Field 5 was relatively avascular in comparison to the other fields. Most vessels found in this area were larger collecting venules, and arterioles. In inflamed tissues, a dense perivascular infiltrate of inflammatory cells was often seen surrounding the collecting venules, while in minimally inflamed tissues, this infiltrate was absent. (Alkaline Phosphatase + Haematoxylin X 312)

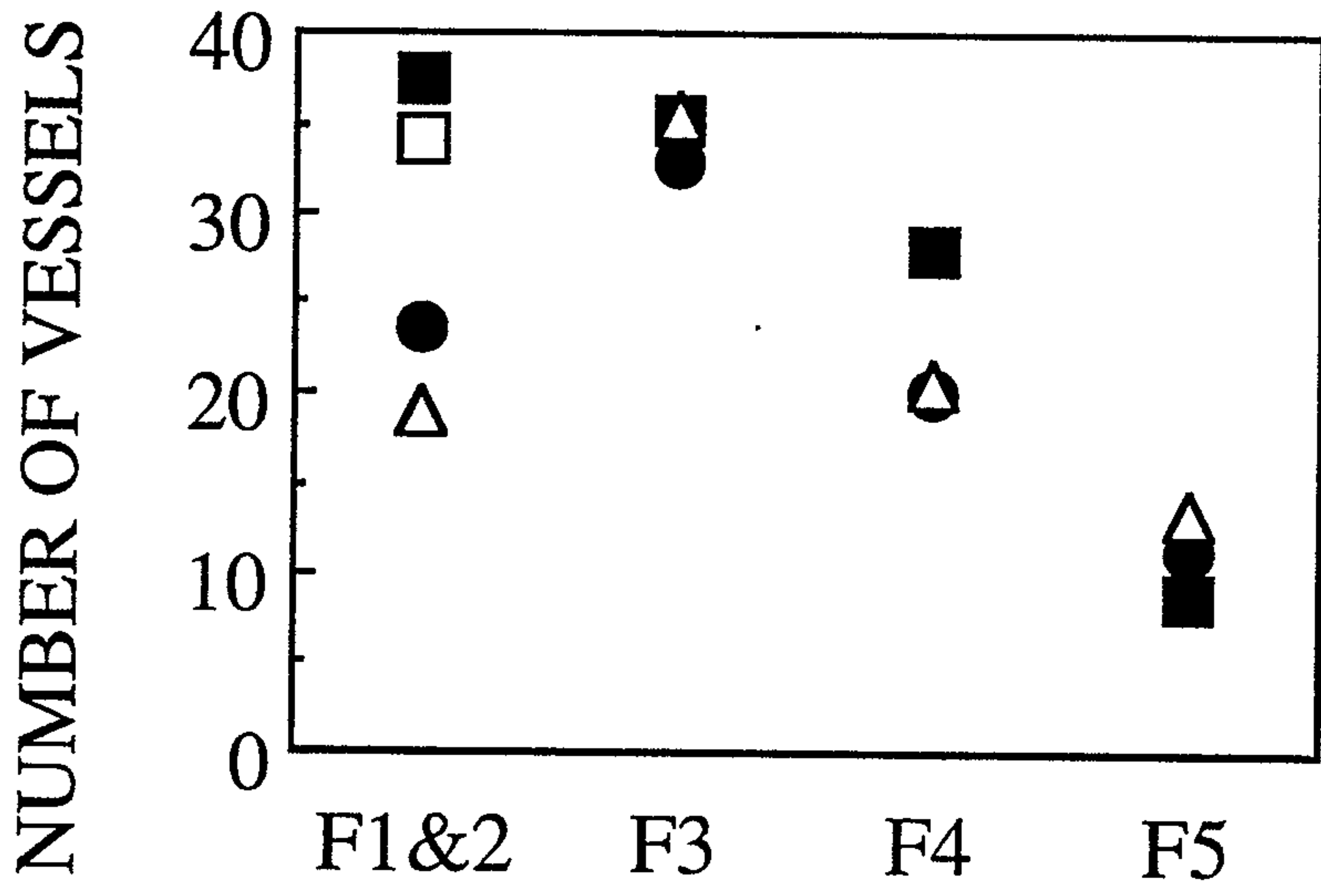


Figure 3.4

Scattergram showing the average number of vessel profiles per field in periodontitis (filled squares for Field 1, open squares for Field 2), gingivitis (filled circles) and minimally inflamed tissues (open triangles). Fields 1 and 2 are indicated as F1&2, while Fields 3,4 and 5 are indicated as F3, F4 and F5 respectively.

Considering separately each of the three types of tissue studied, the number of vessel profiles found was significantly different for almost all fields ($p < 0.026$). In periodontitis lesions, however, no difference was found between Fields 1 and 2 and Fields 1 and 3, while in gingivitis and minimally inflamed tissues no difference was found between Fields 1 and 3.

Significant differences in the number of vessel profiles between different lesion types within a single field could only be demonstrated for Field 1. In Field 1, periodontitis specimens had more vessel profiles than gingivitis ($p = 0.004$), and minimally inflamed tissues ($p = 0.0001$), with no difference between gingivitis and minimally inflamed tissues being found.

In summary, there were differences in the number of vessel profiles between fields for different lesion types, with the number of vessel profiles generally decreasing with increasing field number. However, it was only in Field 1 that a clear increase in the number of vessel profiles found in periodontitis specimens was demonstrated, as compared with minimally inflamed and gingivitis specimens. This suggests that in periodontitis, there is an increase in either the number of vessels present, or that existing vessels have become more tortuous increasing the apparent number of vessels found.

PERCENTAGE OF VESSELS

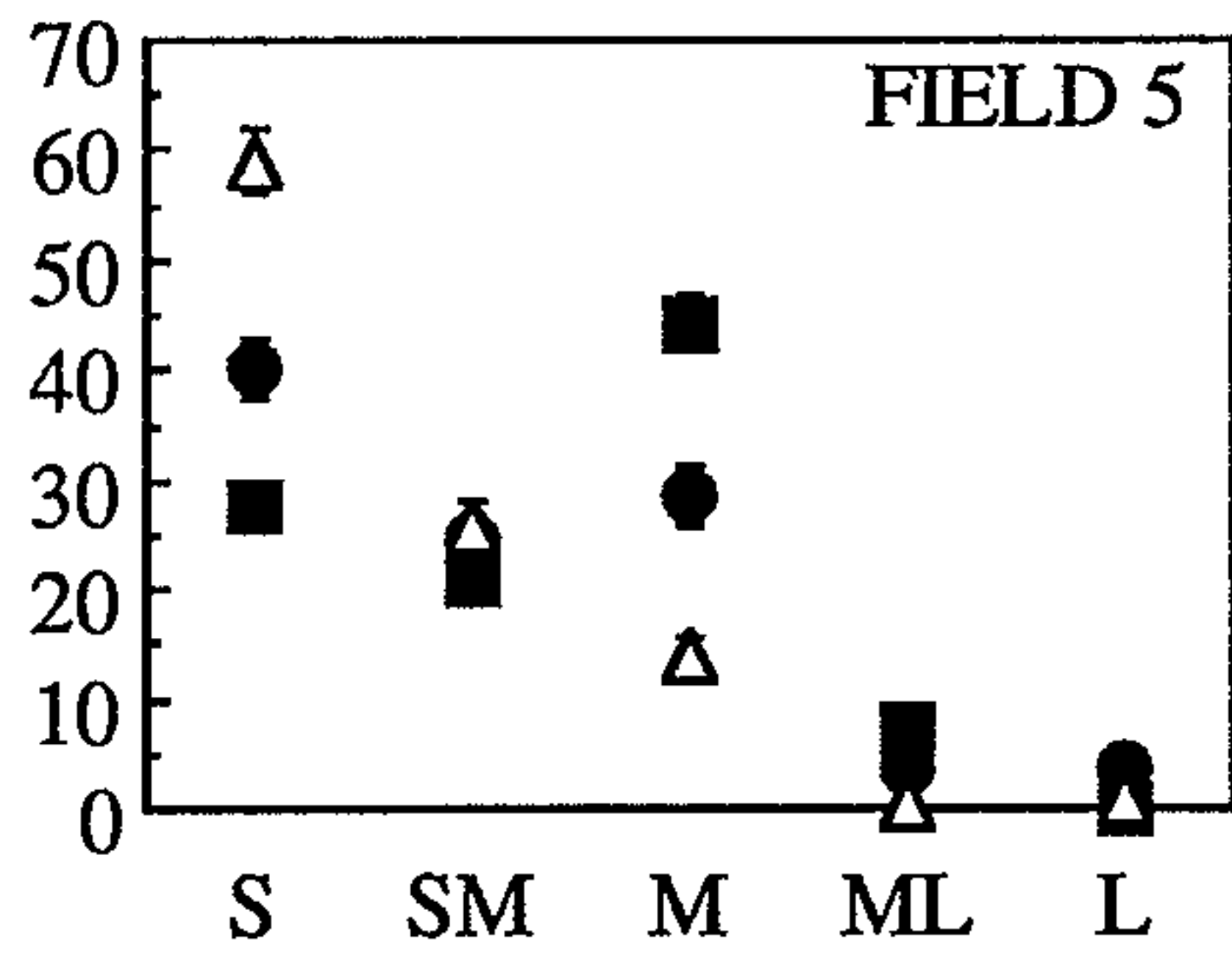
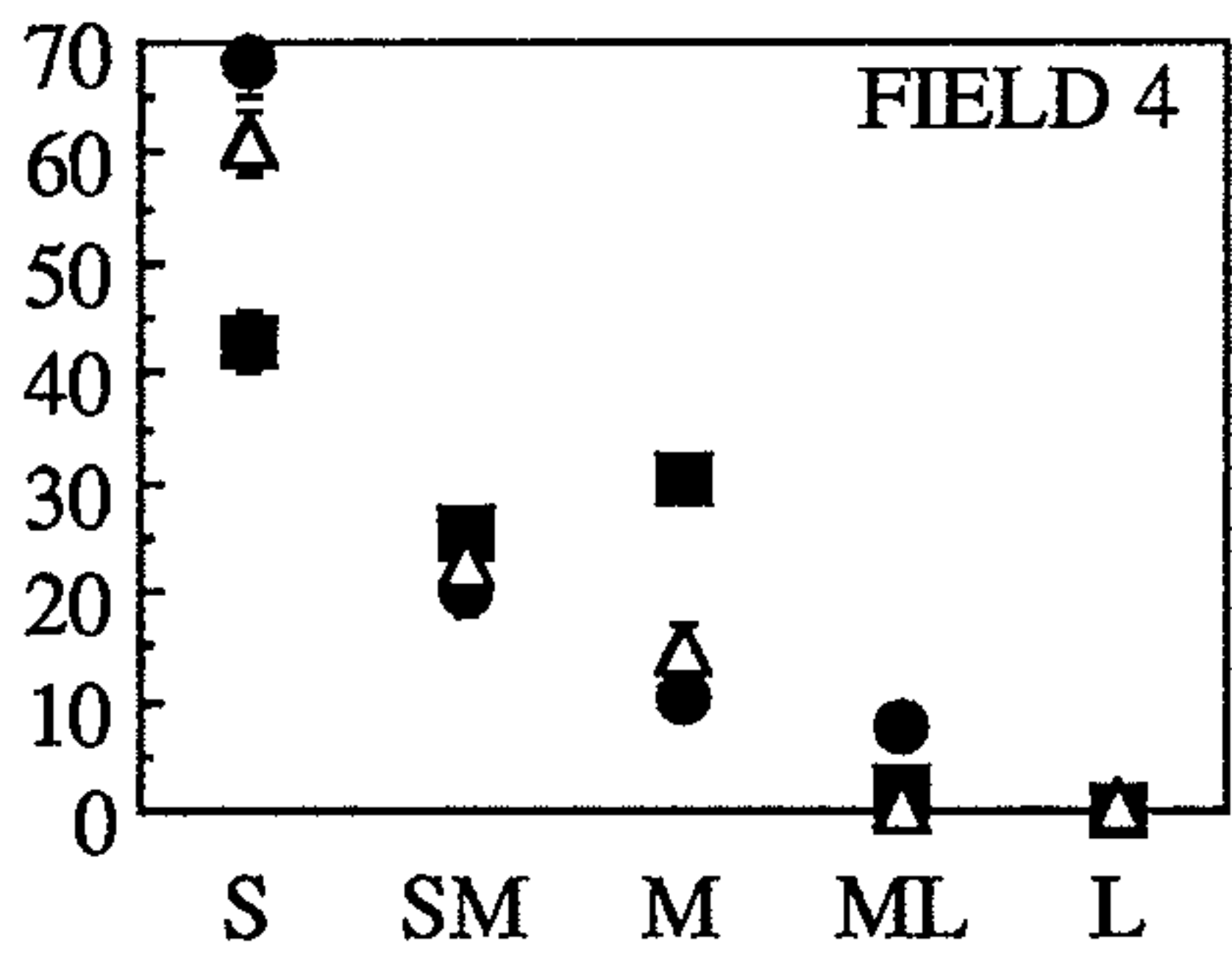
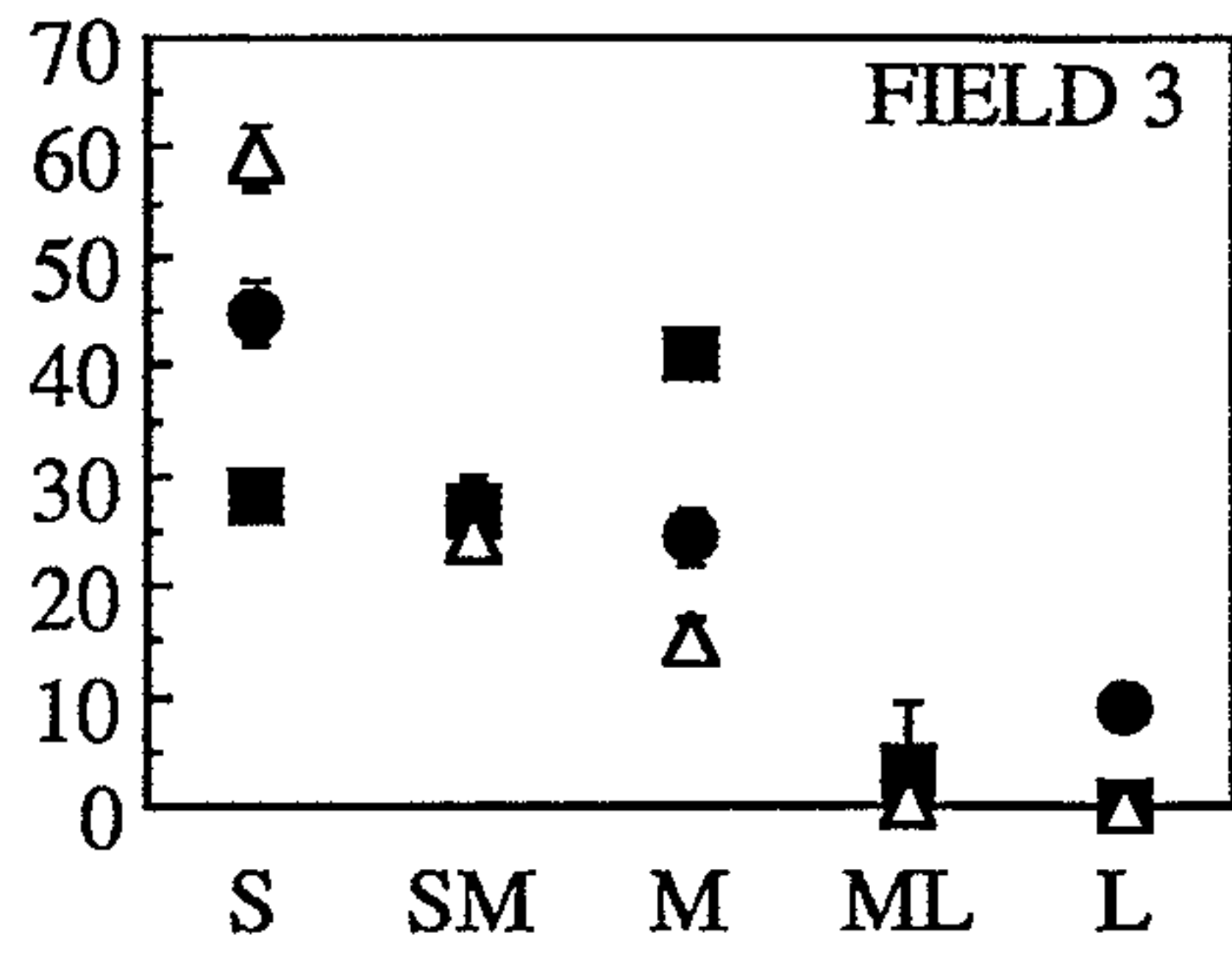
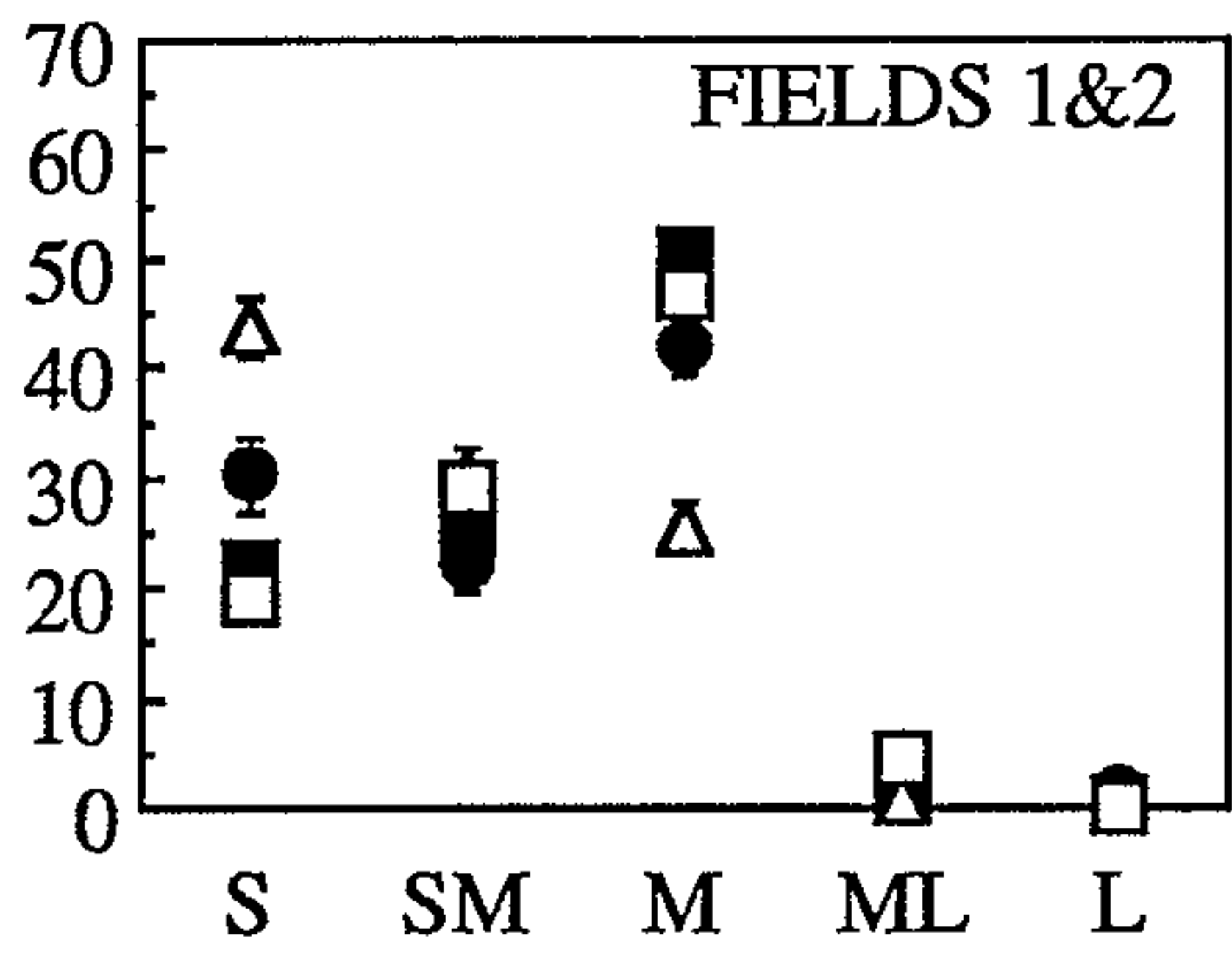


Figure 3.5

Scattergrams showing the percentage distribution of vessels according to size in all fields for periodontitis specimens (Field 1 closed squares, Field 2 open squares), gingivitis specimens (filled circles) and minimally inflamed tissues (open triangles). Vessel size ranges from small (S), small to moderate (SM), moderate (M), moderate to large (ML) and large (L).

Periodontitis specimens had larger vessels as compared with equivalent fields in gingivitis specimens ($p < 0.01$ in Field 1 and $p < 0.001$ for other fields) and minimally inflamed tissues ($p < 0.001$). Also, there were more larger vessels in gingivitis lesions than in minimally inflamed tissues ($p < 0.001$).

However, an exception to this pattern was found in Field 4, where vessels in minimally inflamed tissues were larger as compared with those in gingivitis specimens ($p < 0.01$).

It is clear that there is an increase in the width of gingival vessels with progression of the disease from health to periodontitis.

PERCENTAGE OF VESSELS

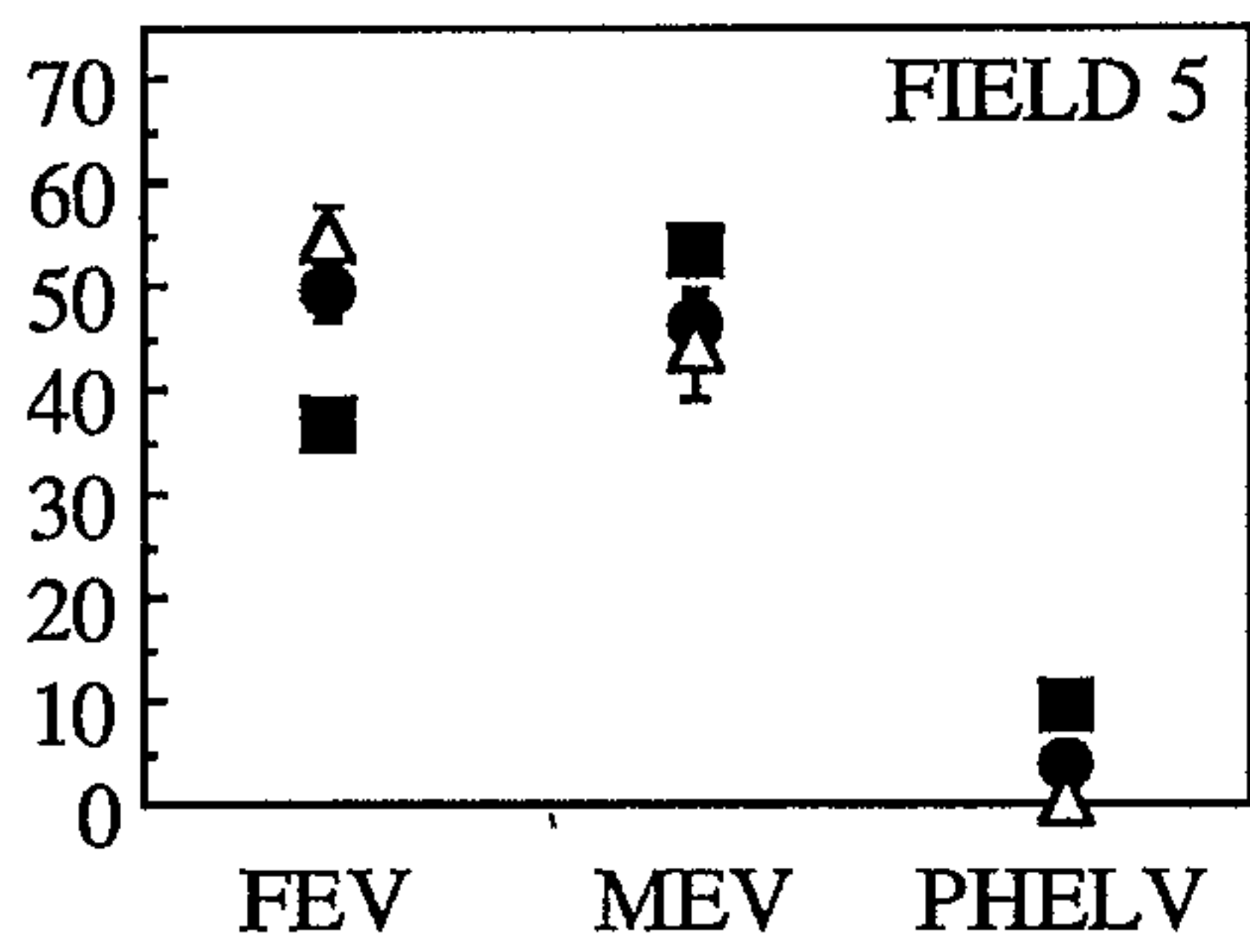
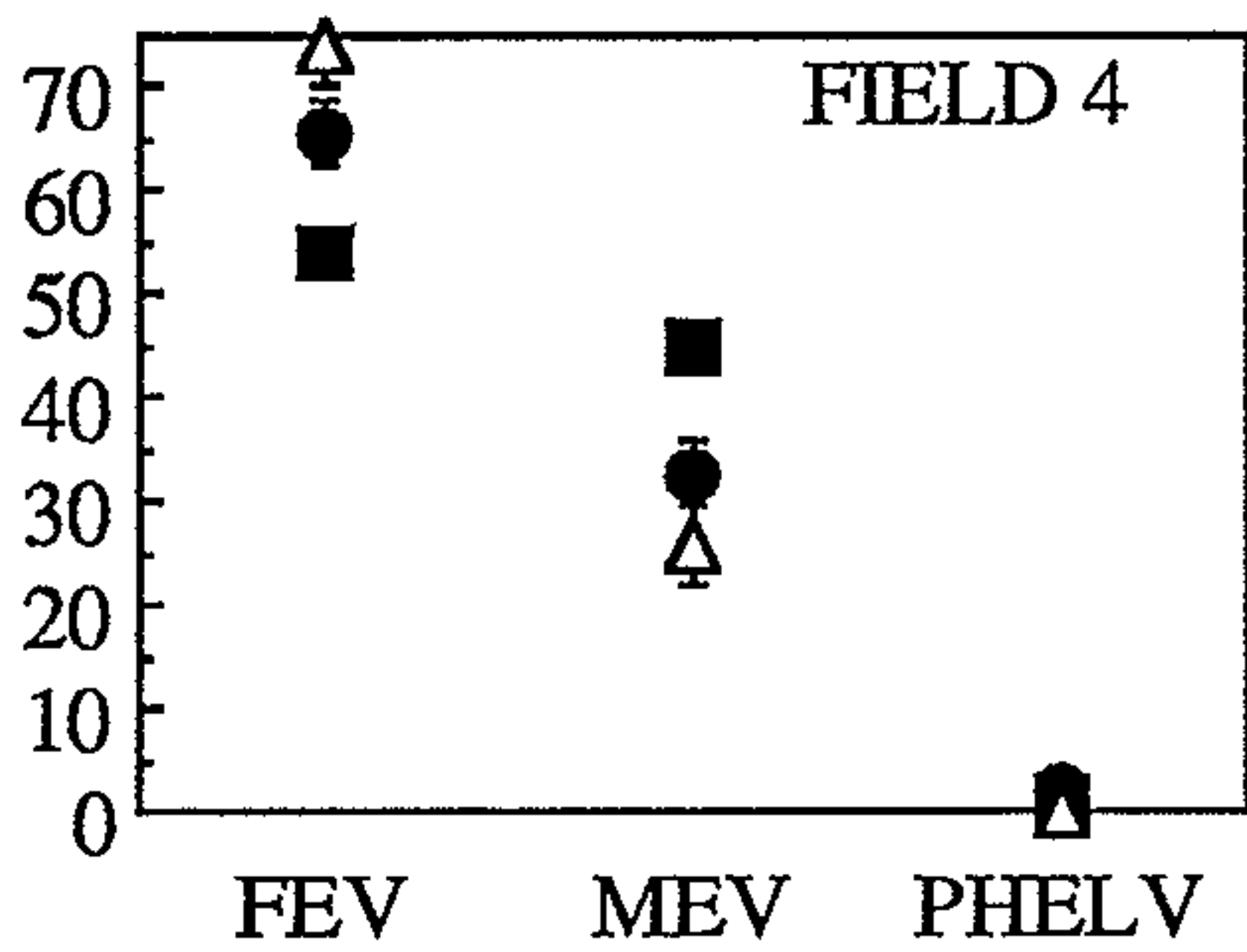
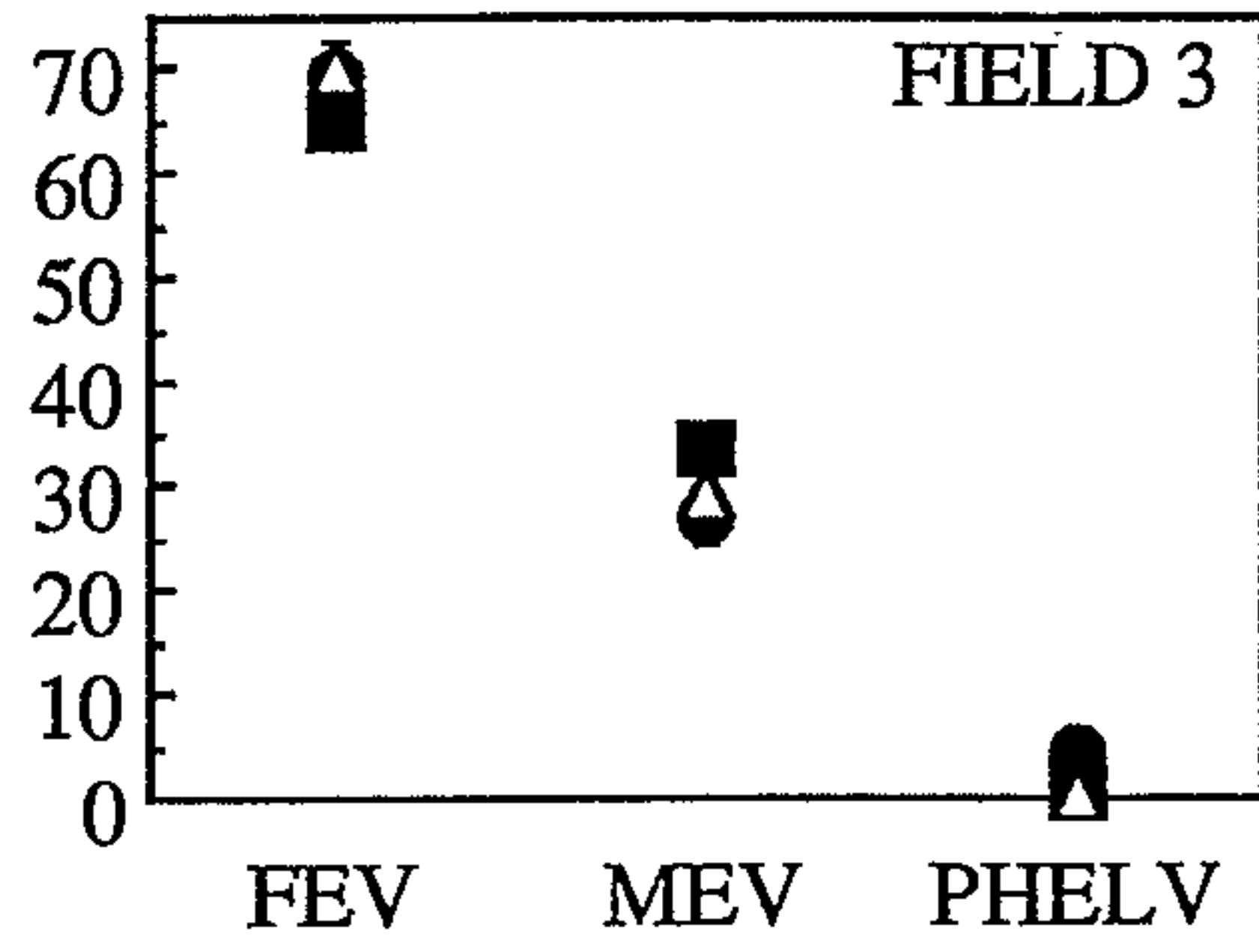
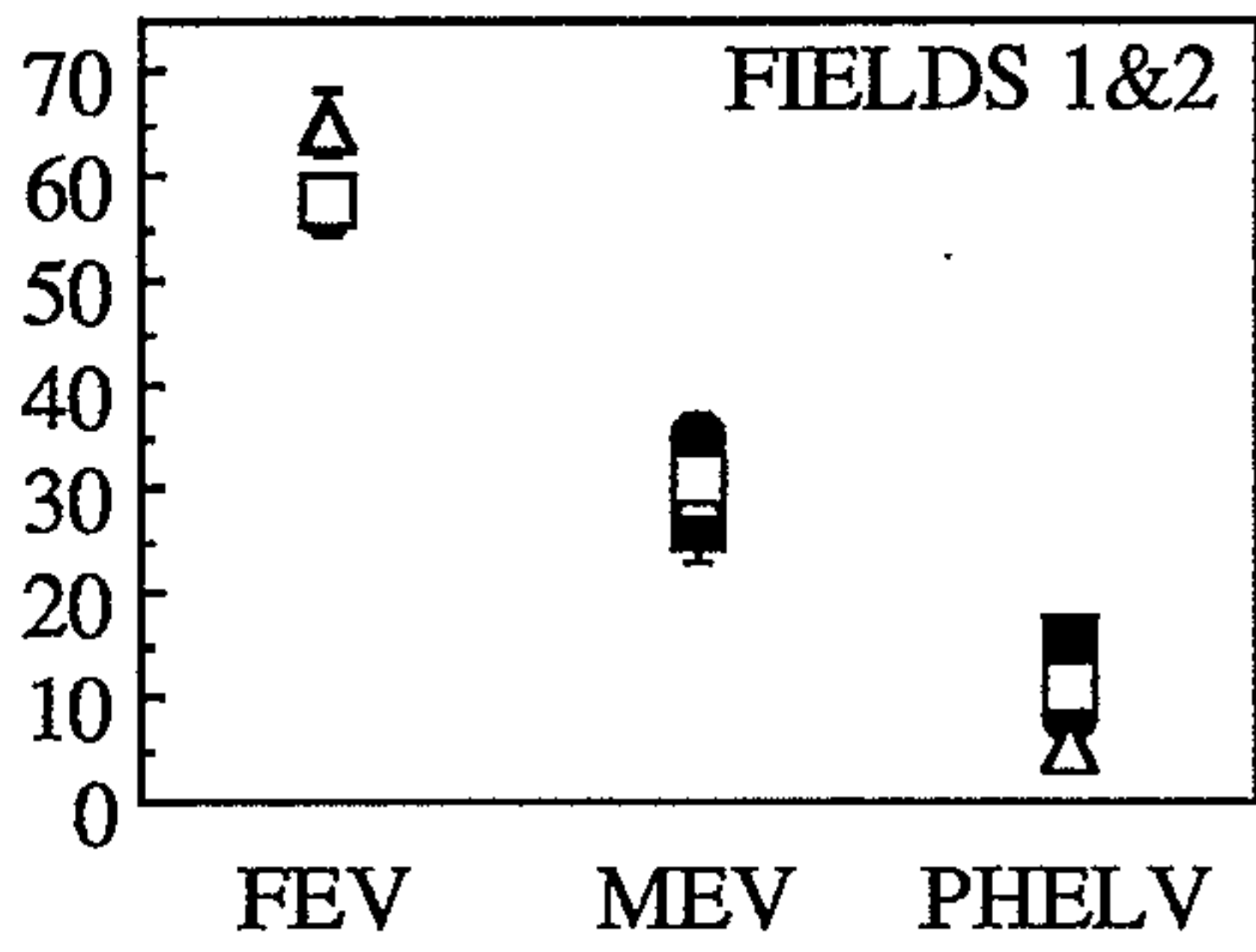


Figure 3.6

Scattergrams showing the percentage distribution of vessels classified on the basis of EC height as being FEVs, MEVs or PHELVs, in each of the fields studied for periodontitis specimens (Field 1 closed squares, Field 2 open squares), gingivitis (filled circles) and minimally inflamed tissues (open triangles).

For each of the lesion types studied, PHELVs were always less prevalent as compared with MEVs ($p < 0.024$). Similarly, FEVs exceeded in number both MEVs ($p < 0.034$) and PHELVs ($p < 0.03$) in almost all fields and lesion types studied. Exceptions to this were in Field 4 of periodontitis and in Field 5 of gingivitis specimens, where no significant difference was demonstrated in the relative proportion of FEVs and MEVs. Also, in Field 5 of periodontitis specimens, MEVs exceeded FEVs in number ($p = 0.0421$).

Within fields, the incidence of FEVs varied slightly between the three types of tissue studied, so that in Fields 1 and 5, significant differences were demonstrated between periodontitis specimens and both gingivitis ($p < 0.017$) and minimally inflamed tissues ($p < 0.037$). Significant differences amongst different lesion types in the incidence of MEVs were only found in Field 4, where periodontitis specimens had more MEVs as compared with gingivitis specimens ($p = 0.0143$).

PHELVs varied in incidence for like fields according to lesion type in Fields 1 and 5. In Field 1, there were more PHELVs in periodontitis than in gingivitis specimens ($p = 0.0075$) and minimally inflamed tissues ($p = 0.0019$). Also, there were more PHELVs in Field 1 as compared with Field 2 of periodontitis lesions ($p = 0.0243$). In Field 5 there were significantly more PHELVs in periodontitis specimens than in both gingivitis ($p = 0.0008$) and minimally inflamed tissues ($p = 0.0099$).

It was concluded that PHELVs represent the smallest component of the vasculature as defined by EC height, and that these vessels are strongly associated with progression of inflammatory disease from health to periodontitis.

DISCUSSION

Vascular Patterns in Inflamed Gingival Tissues

With the approach used in this study, the three dimensional structure of the microvasculature can not be accurately determined. However, it is possible to infer the overall pattern of the vasculature from the arrangement of vessel profiles in sections.

The presence of longitudinal vessel profiles running along the long axis of the tooth in the sub-crevicular network in Field 1 of minimally inflamed tissues, suggested that this network had a planar structure parallel to the sulcular epithelium. In gingivitis and periodontitis specimens, however, vessel profiles were more often either perpendicular to the epithelial surface or were found in cross section as groups of vessels clustered between epithelial rete-pegs. This pattern suggested that these vessels were part of a system of tortuous vascular loops interspersed between tongues of proliferative epithelium. This change in the vasculature from a planar sub-epithelial network, to a system dominated by vascular loops is in good agreement with the changes described by Nuki and Hock (1974) with inflammation of gingival tissues.

No difference in the pattern of the vasculature of the gingival crest (Field 3) and that underlying the oral mucosa (Field 4) was found in this study. This is inconsistent with the observations of Nuki and Hock (1974), who reported a regular vascular network in the sub-crestal tissues and a hair-pin loop system in the oral mucosal tissues. However, without the use of serial sections and image analysis techniques, it is unlikely that it would be possible to distinguish these two patterns using section technology alone. Because of this, observations made in this study do not conflict directly with those made by Nuki and Hock (1974).

Field 5 appeared to be relatively avascular as compared with the sub-epithelial areas, with the bulk of the vasculature being devoted to the supply and drainage of the more superficial fields.

Deep Perivascular Inflammatory Cell Infiltrates

The accumulation of inflammatory cells, and in particular plasma cells around deep collecting venules in Field 5, suggests that the draining vasculature itself may provide a portal for the entry of plaque bacterial products into the tissues. The possible role of small venular ECs as scavengers for intra-vascular bacterial products does not seem to have been addressed in the literature. However, this may help to

explain the presence of the perivascular inflammatory cell infiltrates in deep gingival connective tissues, which are otherwise quite separate from the more clearly assaulted sub-crevicular connective tissues in Fields 1 and 2. The observation that ECs can interact directly with LPS (Yu *et al.* 1986, Miossec *et al.* 1986, Drake and Pang 1989), and also have receptors for FMLP (Rotrosen *et al.* 1987) supports such a suggestion. It is known that LPS is highly toxic when injected directly into the vasculature (Ross 1957). However, the low incidence of endotoxemia, despite the omnipresence of LPS from both exogenous and commensal organisms, is difficult to reconcile with the dramatic nature of endotoxic shock. Perhaps a vital role of the venular microvascular endothelium is to protect the systemic circulation from bacterial products originating from localised infections.

It should be noted, that although the ECs of these deeper venules may not be exposed to large extravascular loads of bacterial toxins, the effective concentration of any intravascular bacterial products at the luminal EC surface, would be greater in these deeper vessels than the actual blood concentration of these materials. This is because the blood is in motion, increasing the number of bacterial molecules exposed to the luminal EC surface over a period of time in proportion to the flow rate. It could be argued that the actual number of bacterial molecules "seen" by deep venular ECs over a period of time might be greater than that of ECs in the more superficial capillary networks. Although superficial capillary ECs may be exposed to high extravascular concentrations of bacterial products, the rate of contaminated blood flow may be sufficiently slow for the effective luminal concentration of such toxins to be less than that of deeper vessels.

Vascular Changes Defined as Angiogenesis

The significantly greater number of vessel profiles in periodontitis Field 1, as compared with Fields 1 of gingivitis and minimally inflamed tissues, suggests that the number of vessel profiles in this field is related to the severity of the inflammatory disease. This possibility is further supported by the relatively greater number of vessel profiles found in fields closer to the bacterial plaque irritant, with Field 4 having the least number of vessel profiles of all the sub-epithelial networks. The increased number of vessel profiles in Field 1, accompanying development of the advanced lesion can be interpreted as indicating either an increase in the number of vessels present, or reflecting increased tortuosity of existing vessels. In light of reports by other workers of increased tortuosity in gingival vessels accompanying inflammation (Nuki and Hock 1974), the latter interpretation seems most likely.

The small number of vessels found in Field 5 as compared with other sites, may in part reflect the role of many vessels in this field as large supply and drainage vessels, servicing the sub-epithelial networks.

In almost all fields, an association was found between dilation of the vasculature and the development of inflammatory disease. The exception to this pattern was found in Field 4, where dilation of the vasculature was not seen in gingivitis specimens, but was present in periodontitis lesions. This might reflect a more aggressive vascular response in periodontitis as compared with gingivitis.

Also, the size of vessels in periodontitis Field 5, could in part be skewed in favour of larger vessels, reflecting the greater vascular need of the larger periodontitis gingival soft tissues. Because of this, it is possible that the apparent dilation of vessels in this field relative to gingivitis and minimally inflamed tissues is artifactual.

As reviewed earlier in this chapter, other workers have observed dilatation and increased tortuosity of gingival vessels during inflammation (Hock and Nuki 1971, Kasperk and Ewers 1968). The data presented in this chapter indicates that considerable remodelling and expansion of the microvasculature occurs during development of the periodontal lesion, confirming and extending earlier reports.

True angiogenesis must be defined as the formation of new blood vessels. However, expansion of the microcirculation through an increase in vascular diameter and tortuosity can be classified as a form of angiogenesis, in so much as proliferation and migration of ECs, at the expense of the extracellular connective tissue elements is a necessary component of such a response. Dilation of the vasculature is reported as an early response in limbic vessels prior to angiogenesis in the injured rat cornea (Schoefl 1963). It could be argued that the widening of vessels in this study reflects a similar phenomenon.

Origin of Angiogenic Factors in Periodontitis

The origin of angiogenic factors in these tissues is difficult to define. Stimulated macrophages release angiogenic factors (Mostafa *et al.* 1980a&b, Polverini *et al.* 1977), and may constitute a source in inflamed gingival tissues. Of particular interest with respect to macrophage-derived angiogenic factors, are reports of the secretion of such factors by macrophages in response to lowered oxygen tension and elevated levels of lactic acid (Knighton *et al.* 1983, Jensen *et al.* 1986). Similar conditions are experienced in anaerobic bacterial plaque, and it is possible that macrophages drawn into plaque by chemotactic agents released by bacteria, produce angiogenic factors which could affect vessels close to the sulcular and pocket

epithelium. Also, it is known that Capnocytophaga sputigena, a suspected periodontal pathogen, causes proliferation of bovine aortic ECs and thus contains a potential angiogenic factor (Taichman *et al.* 1984).

The Role of Endothelial Cells in Tissue Degradation in Periodontitis

As mentioned above, vascular expansion within tissues must be accompanied by an equivalent loss of fibrous connective tissue elements. In relation to this, ECs secrete proteinases in response to angiogenic stimuli (Gross *et al.* 1983). It seems reasonable to suggest that angiogenic stimuli acting on vessels in inflamed gingiva, apart from causing changes in the anatomy of the microcirculation, also may result in considerable degradation of the surrounding connective tissue elements. There is some evidence that angiogenic phenomena may be important in the periodontal fibre remodelling of orthodontic tooth movement (Rygh *et al.* 1986). It is possible that part of the tissue degradation which characterises the destructive periodontitis lesion is the direct result of proteinase secretion related to angiogenesis.

Phenotypic Specialisation of Endothelial Cells in Inflamed Gingival Tissues

Although FEVs and MEVs did not seem to be associated with any particular part of the microcirculation, HECs were only present in PCVs.

Egelberg (1966a) noted that the diameter of vessels forming both the flat planar and looped coil types of plexus were greater than that of typical capillaries, and concluded that these vessels should be described as PCVs and small venules. However, in this study, these vessels were found to be AP positive, and despite their large diameter, clearly drained into AP negative PHELVs that contained large numbers of intravascular leukocytes. From this, the classification of these superficial vessels as PCVs would seem inappropriate, since PCVs are normally considered to be responsible for leukocyte exchange, as are the PHELVs seen in this study. Also, HEVs are AP negative (Anderson *et al.* 1976, Freemont and Jones 1983), whereas the dilated vessels close to the sulcular and pocket epithelium were clearly AP positive. From this, it seems reasonable to argue that the larger diameter of the sub-epithelial capillaries in biopsies of inflamed gingival tissues, is due to dilation of the vessels, rather than the acquisition of phenotypic characteristics normally seen in larger vessels.

Since capillaries are more numerous than their attendant PCVs, the small number of PHELVs relative to other vessel types, may at least in part reflect the location of periodontal HECs in PCVs draining FEVs and MEVs.

The number of PHELVs appears to be clearly related to the presence of chronic inflammation in the tissues, and the apparent role of PHELVs in leukocyte exchange is studied in more detail in Chapters 5 and 6.

Clear distinction between FEVs and MEVs in their distribution between differing lesions within fields was not found, so that classification of these two vessel types as phenotypically distinct may be inappropriate. However, in histological sections, these vessels appear to be morphologically distinct, so that it is tempting to speculate that MEVs may represent vessels which are intermediate in development between FEVs and PHELVs. Failure to achieve PHELV status by MEVs could result from the location of ECs in inappropriate parts of the circulatory network, such as in capillaries; or perhaps from the absence of sufficient inflammatory signalling to induce the PHELV phenotype. The significantly smaller number of MEVs in Field 5 of minimally inflamed tissues as compared with periodontitis and gingivitis Field 5 supports this suggestion.

The absence of a significant difference in the relative proportion of PHELVs between Fields 1 and 3 in gingivitis specimens, as well as the occasional presence of inflammatory cells in Field 3 of inflamed tissues, suggests that there is considerable overlap between adjacent fields, so that only strong trends in the data should be considered meaningful. Although statistical differences were found in the proportional distribution of many vessel types between fields and lesion types, the biological significance of these observations is difficult to define, and may not have physiological relevance.

CHAPTER 4

PERIVASCULAR HYALINE DEPOSITS IN INFLAMED GINGIVAL TISSUES

INTRODUCTION

In the course of performing the histometric survey of vascular changes described in Chapter 3, a previously un-reported perivascular hyaline material (PHyM) was found. The material varied greatly in its extent and distribution amongst patients and was completely absent from some specimens.

In order to document the incidence, distribution, extent and structure of PHyM, an additional study was performed which is described in this chapter.

LITERATURE REVIEW

Hyaline materials are defined by their appearance with the light microscope, as amorphous, seemingly structureless deposits. Despite the similar appearance of various extracellular hyaline materials, the ultrastructure and composition of these materials varies greatly, reflecting the diversity of conditions in which such materials are deposited (Hashimoto 1985). Examples of diseases in which such hyaline deposits appear are amyloidosis, hyalinosis cutis et mucosae, cutaneous porphyria and hyaline arteriosclerosis (Hashimoto 1985, Gamble 1986). In oral tissues, hyaline structures have been observed in a number of conditions including odontogenic cysts (Chen *et al.* 1981), ameloblastomas (Takeda *et al.* 1985) and chronic periostitis (El-Labban and Kramer 1981). Since the material described in this chapter is exclusively found around capillaries, only papers describing perivascular hyaline materials will be discussed in this review.

Perivascular Hyaline Deposits

Hyaline arteriosclerosis is a common condition, in which the walls of the smallest arterioles accumulate a hyaline material. This change is associated with aging, as well as with hypertension and diabetes (Smith 1955). Although the exact origin of the material has not been established, the consistent presence in the material

of the complement fragment iC3b, as well as of some antibody subclasses, has suggested that the trapping of serum proteins by sub-endothelial matrix components may be important in the pathogenesis of this material (Gamble 1986).

The accumulation of plasma proteins around blood vessels is thought to contribute to the formation of perivascular hyaline materials in a number of chronic inflammatory lesions, giving rise to the description of these deposits as "fibrinoid". Examples of diseases where this is thought to occur are, lupus erythematosus, rheumatoid arthritis, granuloma faciale and allergic vasculitis (Lever 1967, Hashimoto 1985)

In amyloidosis, as well as in hyalinosis cutis et mucosae, hyaline deposits often occur surrounding small blood vessels. The structure of these deposits is variable, as are the conditions, but are none-the-less typical of other deposits found elsewhere throughout the tissues (Hashimoto 1985).

Multiplication of basal lamina occurs in the capillaries of muscle tissues during aging, and is accelerated in diabetes (Vracko *et al.* 1980). It is thought that this reflects a response by ECs to damage (Vracko *et al.* 1980). Although the biochemical basis of such damage in diabetes has not been established, it is suggested that the accumulation of polyols (a class of glucose alcohols which are present in cells exposed to excessively high glucose levels) can result in hyper-osmotic damage to ECs (Kador *et al.* 1989). Also, it is thought that non-enzymic glycosylation of extracellular proteins could affect their function and turnover rate in diabetic tissues. It is possible that cytotoxic effects of glycosylated molecules, and aberrant basement membrane proteins may explain the MBL structures around blood vessels in diabetes (Monnier *et al.* 1989). Multiple basal lamina structures have also been found in hyaline arteriosclerosis (McGee and Ashworth 1963). Of special relevance to the present study, are reports of multiple basal-lamina structures around small vessels in inflamed periodontal tissues in humans (Freedman *et al.* 1968, Danilewskij and Kolesowa 1977) and rats (Garant 1976).