

Canine Neural Angiostrongyliasis

Introduction

Canine Neural Angiostrongyliasis (CNA) is a disease caused by the neural migration of larvae of the rat lungworm *Angiostrongylus cantonensis*. It is characterised by ascending central nervous system (CNS) dysfunction often associated with eosinophilic infiltration and an eosinophilic pleocytosis of the CSF. The pathological process associated with the migration of *A. cantonensis* appears to be an aggressive, potentially life-threatening host reaction. While there is no doubt that the larvae themselves damage the CNS, it is probably the host's reaction to the dying larvae or their shed cuticle that contributes most to the onset of clinical signs.

Angiostrongylus cantonensis was first described in 1935 as part of a routine parasitological investigation of rats in Canton.²⁻⁶ Initially called *Pulmonema cantonensis* by Chen, the parasite was implicated as a cause of eosinophilic meningoencephalitis (EME) as early as 1945.⁷ It was not until 1962, however, that the parasite's role in EME was confirmed.⁸ The term 'neural angiostrongyliasis' covers the broad spectrum of neurological symptoms associated with infection with *A. cantonensis*.² During the subsequent decades *A. cantonensis* has emerged as the most common cause of EME in humans and animals.⁹

While experimental infections in animals were described in the late 1960s and early 70s,^{10,11} the first documented cases of naturally occurring angiostrongyliasis in animals (other than rats) were published by Mason in 1976¹²⁻¹⁵ who was investigating an unnamed syndrome in puppies in Brisbane, Australia. Since then, a number of domestic and wild species have also exhibited disease due to infection with *A. cantonensis* including horses, ruminants, macropods, fruit bats, and birds.¹⁶⁻²²

There are few parasites known to have an obligate neural migration. The transition of 3rd stage larvae of *A. cantonensis* to 4th and 5th stages can only take place within the neural tissues of the host and thus involvement of the nervous system is essential for its development. Most nematodes found in the CNS are within the wrong host and have been "washed" there via the blood stream.² For example, the strongyloid *Setaria digitata*, which causes spinal neuropathy in goats, is not found within the CNS of its definitive host, deer.²³ Other parasitic infections of the CNS include gnathostomiasis,

schistosomiasis, cysticercosis, echinococcosis, and toxocariasis.^{23,24} Of the 21 described species of *Angiostrongylus* only three are neurotropic in the definitive host; *A cantonensis*, *A mackerrasae* and *A malaysiensis*⁶

Definitive diagnosis in humans can be realised by obtaining larvae from aqueous and CSF samples. In the dog, a definitive diagnosis of neural angiostrongyliasis had only been achieved at necropsy.^{14,25} The antemortem diagnosis of CNA is therefore presumptive, based on characteristic physical findings, laboratory data and response to treatment in conjunction with a history of exposure to intermediate or definitive hosts. Canine patients with CNA are typically puppies, presenting for hyperaesthesia and hind limb paresis occurring some time after ingestion of slugs or snails. Clinically, signs progress as the parasite migrates rostrally within the spinal cord and animals may die if left untreated. Currently treatment in dogs is limited to glucocorticoids and supportive care.

This thesis compares the signalment, presenting signs, clinical data, response to treatment and mortality rates between previously published cases of CNA and those obtained prospectively. Serology has been used successfully in humans as an aid in the diagnosis of EME due to *A cantonensis*.²⁶ This thesis describes the use of an ELISA, based on a crude adult antigen, on samples of serum and CSF from suspected cases of *A cantonensis*. To determine the accuracy of the ELISA two control canine populations were also tested. Western blot analysis, developed as part of a concurrent study on the disease in macropods, was carried out on a number of samples from suspected cases of CNA.

The literature review focuses on the history of the discovery of *A cantonensis*, its life history and epidemiology. It also attempts to describe different syndromes occurring in a variety of species as well as the underlying pathomechanisms of neural dysfunction. Reference is made to the serology that has been used to aid the diagnosis of neural angiostrongyliasis in humans. The most significant differential diagnoses are described in detail. Future directions in the diagnosis and treatment of angiostrongyliasis and its impact on other species are discussed.

Chapter 1: Literature Review

1.1 History

Angiostrongylus cantonensis was first identified as a parasite of rats in Canton, China by Chen in 1935.²⁷ In 1954 the parasite was reported in Brisbane, Australia.⁵ But it was not until the 1960's that a connection was established between *A cantonensis* and an unusual type of meningitis encountered in the Pacific islands, characterised by eosinophilic pleocytosis. In retrospect, the disease was recognised as early as 1944 when a report of a new syndrome, Eosinophilic Meningoencephalitis (EME), was made by Nomura and Lin in 1945.⁷ They confirmed that a metastrongyloid nematode was responsible for the death of a 15-year-old boy in a Taiwanese hospital after finding a live nematode in a CSF specimen. They named the parasite *Haemastrongylus ratti*. Due to the fact that the original article was published in Japanese in a Taiwanese medical journal during the Second World War, it went unnoticed by Western researchers and was not translated into English until 1964. Subsequently, the parasite identified by Nomura and Lin was reclassified as *A cantonensis* by Beaver and Rosen.^{28,29} Following the surrender of the Japanese in the Pacific during World War II there was an outbreak of eosinophilic meningoencephalitis in the Eastern Caroline Islands, Pohnpei. Despite a thorough investigation by a United States Naval Medical Research team in 1948 no inciting agent was found.³⁰ During the 1950s over 1000 cases of this distinctive disease were documented in Sumatra, the Philippines, Taipan, New Caledonia and as far east as Rarotonga in the Cook Islands and Tahiti.³¹

In 1961, a research pathologist at the University of Hawaii, Joseph Alicata, postulated that the rat lung worm *Angiostrongylus cantonensis* could be a cause of the eosinophilic meningoencephalitis reported previously.^{29,31} Alicata reported that a local Japanese worker had wilfully ingested raw slugs, for their presumed medicinal properties, and nine days later developed hyperaesthesia and paresis of the ears, shoulders and arms. CSF samples demonstrated a mild eosinophilic pleocytosis. Slugs collected in the area where the worker lived were shown to be infected with *A cantonensis*.²⁹ It was not until larvae were recovered by a staff doctor, Leon Rosen, from the brain of an inmate of the State Mental Hospital, Oahu, Hawaii later that same year that the Alicata's theory was proven correct.³² The inmate had been a chronic schizophrenic who had died of acute meningitis and was known to have eaten raw slugs and snails. To validate his theory Alicata conducted a number of experiments by

infecting primates with third stage larvae of *A cantonensis* and showed that these animals did, indeed, develop eosinophilic meningoencephalitis.²⁹

During the late 1960s the disease was first recognised on the mainland of China and since then has been diagnosed throughout Southeast Asia, the Pacific Islands, Micronesia, Australia, Japan, Fiji, Central America, the USA (Louisiana and Hawaii), Ivory Coast, India and Egypt.^{2,31,33,34} There have been human patients diagnosed in New Zealand and Switzerland where the parasite is not endemic; these cases have occurred in overseas travellers visiting one of the endemic regions.^{35,36} It is interesting to consider the spread of the disease with regard to the Imperial Japanese Army's occupation of Asia. More than likely the parasite evolved, along with its close relatives, in South East Asia before spreading via its definitive host, the rat, during the extensive troop and cargo movements in the Pacific theatre of World War 2.^{6,29,31}

1.2 Classification

The Metastrongyloidea consist of 180 species of bursate nematodes divided into 40 genera.⁶ In general they parasitise mammals, mostly inhabiting the lungs and, with few exceptions, their intermediate hosts are molluscs. Of these only 5 are known to be neurotropic in their migration through hosts; *A cantonensis*, *A mackerrasae*, *A malaysiensis*, *Parelaphostrongylus tenius* and *Skirjabingylus chitwoodorum*.^{4,6}

The genus *Angiostrongylus* was originally erected for *Strongylus vasorum* (Baillet, 1866) in 1905 by Kamenskii. Identified initially as *Pulmona cantonensis* by Chen in 1935 and *Haemoststrongylus ratti* by Yokogawa in 1937, it was not until 1967 that Ash reclassified this nematode within the genus *Angiostrongylus*. In 1970 Drozda divided the 15 known species of *Angiostrongylus* into two genera based on the lateral and dorsal rays of their bursa and the habitat of the definitive hosts. The genus *Angiostrongylus* was further divided into two subgenera; *Angiostrongylus* and *Parastrongylus*, *A cantonensis* being placed in the latter according to its definitive host. With 4 new species described in the early 70's; *A schmidtii* (Kinsella, 1971), *A malaysiensis* (Bhaibulaya and Cross, 1971), *A costaricensis* (Morera and Cespedes, 1971), and *A minutes* (Ohbayashi et al., 1973) further sub classification was required. Based on the reduced dorsal ray, short lateral rays and small simple filariform spicules, *A costaricensis* was moved into a new genus, *Morerastrongylus*. The general consensus, however, is that these new classifications are confusing and therefore, particularly in Asia and Australia, most researchers refer to them all as *Angiostrongylus*.³⁷

To date 21 species have been identified within the genus *Angiostrongylus*³⁸;

- A. vasorum* (Baillet, 1866) – French heartworm seen in the domestic dog (*Canis familiaris*). Cases reported in Europe, South America and once in Australia.
- A. raillieti* (Travassos, 1927) – crab-eating dog (*Canis azarae*) in Brazil although Dougherty (1946) suggested that this may have been *A. vasorum*.
- A. tateronae* (Baylis, 1928) – Kemp jerboa (*Tatera kempii*) West Africa
- A. putae* (Clarke, 1932) – Central America
- A. ondatrae* (Schulz et al., 1933) – muskrat (*Ondatra zibethica*) USSR
- A. cantonensis* (Chen, 1935)
- A. ten* (Yamaguti, 1941) – black-footed martin (*Martes melampus*) Japan
- A. gubernaculatus* (Dougherty, 1946) – badger (*Taxida taxus neglecta*) and striped skunk (*Mephitis mephitis holzneri*) California, USA
- A. soricis* (Soltys, 1953) – shrew (*Sorex minutus*) Poland
- A. blarini* (Ogren, 1954) – short tailed shrew (*Blarini brevicauda*) Illinois, USA
- A. chabaubi* (Biocca, 1957) – European wild cat (*Felis silvestris*) Italy
- A. sciuri* (Merdivenci, 1964) – squirrel (*Sciuri vulgaris*) Turkey
- A. michiganensis* (Ash, 1967) – shrew (*Sorex cinereus cinereus*) Michigan, USA
- A. sandarasae* (Alitica, 1968) – rodents (*Mastomys natalensis* and *Gerbil tatera*) Mozambique, East Africa
- A. mackerrasae* (Bhaibulaya, 1968) – East coast of Australia
- A. dujardini* (Drozd and Doby, 1970) – wild rodent (*Cletrionomys glareorus*) France
- A. schmidtii* (Kinsella, 1971) – rice rat (*Oryzomys palustris*) Florida, USA
- A. malaysiensis* (Bhaibulaya and Cross, 1971) – rat (*Rattus jalorensis*) Malaysia
- A. costaricensis* (Morera and Cespedes, 1971) – cotton rat (*Sigmodon hispidus*) Central America
- A. minutus* (Obayashi et al., 1973) – Japanese shrew mole (*Urotrichus talpoides*) Japan
- A. siamensis* (Obayashi, Kamiya and Bhaibulaya, 1979) – rat (*Rattus sabanus*) Thailand

1.3 Identification

In Australia, two species have been identified^{37,39}:

Angiostrongylus cantonensis (Chen, 1935)

Angiostrongylus mackerrasae (Bhaibulaya, 1968)

In 1955, Josephine Mackerras and Dorothea Sandars examined rats caught by the Brisbane City's rat-gang dogs to describe a parasite they had found and assumed to be *A. cantonensis*.⁵ Their aim was to give a detailed account of the morphology and life cycle of the parasite. This became the standard text for the description of the *A. cantonensis*'s life cycle. However Bhaibulaya, in 1972, established that Mackerras and Sandars had actually described a new, indigenous species, *Angiostrongylus mackerrasae*, and not *A. cantonensis*.³

The definite host of *A. cantonensis* is the rat. The two most common murine species identified as hosts are *Rattus norvegicus* and *Rattus rattus*.³ This is probably due to fact that the two organisms evolved side by side in what is now called South East Asia.⁴⁰ Within the host, the parasite resides within the pulmonary arteries and right side of the heart. The morphology of *A. cantonensis* was described by Bhaibulaya in 1979³⁷;

Description: body is filariform and tapers slightly at both ends. Epidermis is smooth and bears transverse striae; transparent when alive. The head is simple possessing 3 lips; one dorsal lip which has 2 submedian papillae; 2 subventral lips, each has 1 submedian papilla. At the base of the lips are 8 papillae, which are grouped into pairs corresponding to the 4 submedian angles. Cervical papillae are present; each situates laterally on the dorsal surface of the body close to the oesophageal-intestinal junction. Buccal capsule is absent; the mouth is seen opening directly into the oesophagus, which is widened before joining the intestine.

Male: caudal bursa is well developed, kidney-shaped, single lobed. The arrangement of the bursal rays is as follows: ventral ray branched at a point two-thirds of its length into a small ventro-ventral and a large latero-ventral ray. Lateral rays arise from a common trunk, the antero-lateral ray is thicker than the others and projected like a thumb, the medio-lateral ray and postero-lateral ray usually originate as a common trunk; the postero-lateral ray is normally shorter than the medio-lateral ray and sometimes reduced to a stump. Externo-dorsal ray is simple and arises from between the lateral and dorsal rays. Dorsal ray is variable, emerging as a short trunk, terminating in several small digitations. Spicules are equal, slender and with conspicuous striations. Gubernaculum is present.

Female: in living specimens, the milky white uterine tubules are spirally wound around the blood-filled intestine and can be seen through the transparent cuticle as a "barber's pole" pattern. A single thin-walled vagina commences at the junction of the uterine tubules, extends posteriorly and opens at the vulva. The posterior end of the female at the tip of the tail has not minute projection.

Ova: elongated ovoid eggs with a delicate hyaline shell. They measure 46 – 48 by 68 – 74 μm and are unembryonated at the time of oviposition. Females can lay up 15,000 eggs per day.

1.4 Life Cycle

The life cycle of *Angiostrongylus cantonensis*, summarised in Figure 1.1, is an indirect one with an intermediate host required for development of the early stages.^{3,23,41} The prepatent period is 42 to 46 days.³ Adult males and females reside with the pulmonary arteries of the definitive host. After copulation, the fertilised eggs are released from the female and become lodged with the pulmonary capillaries. Here they develop into 1st stage larvae and migrate through the wall of the alveoli from which they are coughed up and swallowed. The infective 1st stage larvae are then passed in the definitive host's faeces. Each female can produce up to 1200 larvae/ml of faeces per day.¹⁰

A number of molluscs can act as intermediate hosts. Infection occurs by ingestion or direct penetration of the mollusc's foot by 1st stage larvae.^{3,5} The 1st stage larvae can remain viable for up to 12 days in faeces. Once within the intermediate host the larvae undergo two moults at days 7 to 9, and 12 to 16, respectively. The 3rd stage larvae retain the shed cuticles of the first two stages as a sheath, which protects them against the hostile environment of the definitive host's gastrointestinal tract.³ Larvae can be found throughout the intermediate host's organs although their greatest concentration tends to be within muscular tissues, especially the foot.

Infection of the definitive host is via the oral route and 3rd stage larvae reach the CNS with 1 to 2 days.^{5,42} Infection is thought to occur mainly through ingestion of intermediate hosts but recent studies suggest that raw vegetation contaminated with mollusc secretions or infected planarians represent alternate sources of infection.³ Haynam and Lim demonstrated that the slug *Microparmarion malayanus* secreted larvae in its mucus trails and the larvae were able to survive for up to 3 days on vegetation. Direct penetration may also be a possible mechanism of infection.⁶ A number of animals act as paratenic (transport) hosts such as lizards, fresh water crustaceans and fish, frogs and toads.^{21,40} Within these paratenic hosts there is no further larval development and the larvae are most often found within the musculature. Experimental infections have been induced through subcutaneous injections of larvae in dogs, cats and monkeys.^{22,43,44} Mackerras was also able to establish patent infections in rats within the normal time period by injecting 3rd stage larvae intraperitoneally.⁵

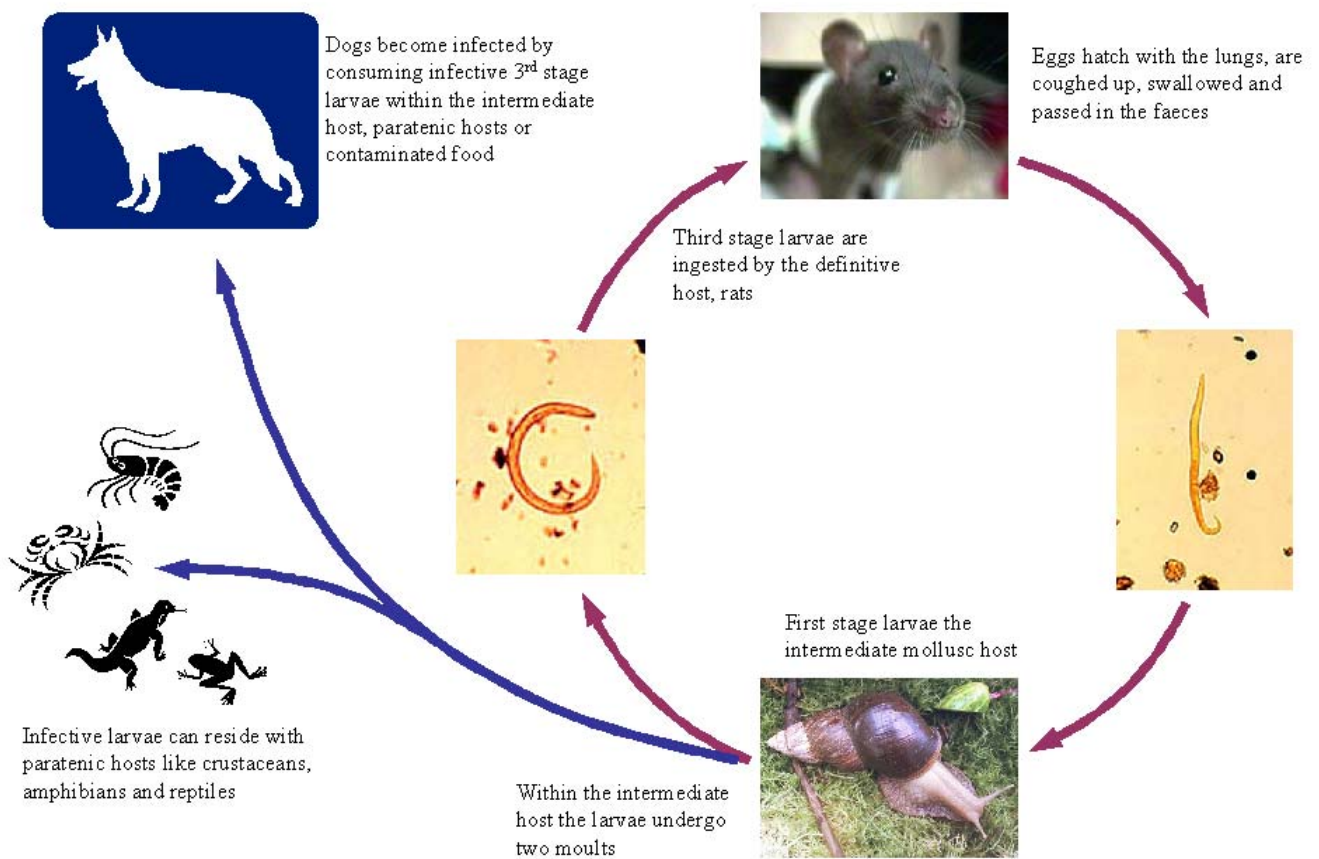


Figure 1.1: Lifecycle of *Angiostrongylus cantonensis*

The majority of the larvae reach the CNS by way of the circulatory system although recent evidence suggests that direct penetration of peripheral nerves and subsequent migration into the CNS provides an alternative route. Experimentally infected rabbits, mice and dogs have all shown significant peripheral nerve damage, especially the sciatic nerve, associated with migration of 3rd stage larvae.^{43,45,46} Mackerras postulated that the parasite used anastomoses between the abdominal and spinal veins to reach the spinal cord.⁵ Bhaibulaya reported that in rats larvae are often found within mesenteric lymph nodes and the thoracic duct and concluded that some larvae may migrate via the lymphatics.³ Experimentally infected calves and pigs also showed large numbers of larvae infiltrating mesenteric and thoracic lymph nodes.¹⁰ This lymphatic migration has been described for many species of lungworm.³

In rats, the majority of larvae are present within the spinal cord within 17 hours of ingestion and upon reaching the brain, they tend to congregate within the rostral region of either cerebral hemisphere.⁵ In the definitive hosts, there appears to be very little inflammation associated with living larvae and it is either the discarded sheaths, dead larvae or expelled metabolic products that incite an inflammatory process.^{5,10}

The majority of the larvae are found within the grey matter, although some may be seen crawling through the meninges.⁵ Here they moult, leaving the sheath behind, and move into the subarachnoid space 4 to 6 days post-infection. A fourth moult occurs in the subarachnoid space 7 to 9 days post infection and the 5th stage (young adult) larvae remain at this site for approximately 10 days where they produce considerable inflammation. Young adult nematodes migrate via the veins of the subarachnoid space to the lungs 26 to 29 days post-infection. In heavily infected animals, some larvae may remain within the grey matter.⁵ Most of the worms reach maturity within the host's pulmonary arteries however, some males may mature within the subarachnoid space prior to migrating to the lungs. By 31 days post-infection there are no longer any living parasites within the CNS⁴⁷. Eggs begin appearing in the host's faeces by 42 to 45 days.³

1.4.1 Comparisons between *A. cantonensis* and *A. mackerrasae*

First stage larvae are virtually indistinguishable in both species and it is not until the 2nd moult that physical differences become apparent. To this point the migration and development of both species is identical.³ As the larvae develop into the infective 3rd stage a narrowing or constriction towards the posterior end is evident in *A. cantonensis*. Within the definitive host the differences become more obvious. *A. cantonensis* tends to develop faster than *A. mackerrasae*, accordingly adults tend to be twice as long. *A. cantonensis* adult females also lack spicules on their tails.³ The moulting times of *A. cantonensis* and *A. mackerrasae* are listed in Table 1.1.

	<i>A cantonensis</i>	<i>A mackerrasae</i>
	(Days)	(Days)
1st moult	7 - 9	7 - 10
2nd moult	12 - 16	12 - 16
3rd moult	4 - 6	6 - 10
4th moult	7 - 9	10 - 11
Reach pulmonary arteries	26 - 29	25 - 26
Prepatent period	42 - 45	40 - 42

Table 1.1: Comparison of development between *A cantonensis* and *A mackerrasae*, Bhaibulaya (1979).³⁷

1.5 Hosts

The definitive host varies from region to region and tends to be the endemic rat species. Because of their widespread distribution *Rattus norvegicus* and *Rattus rattus* are the most common hosts. In Australia, other species include *R alexandrius* and *R exulans*.³ Infection rates vary, although one unpublished survey in Brisbane documented that 80% of a local population of rats were infected.²⁴ In Louisiana, one survey demonstrated 21.3% of the population of *R norvegicus* were infected with *A cantonensis* while no larvae were recovered from *R rattus*.³³ In Australia, several species of native rodent have been infected experimentally although no naturally occurring infections have been identified.^{5,39} The numbers of adult parasites within the host is probably low. Experimental work suggests that doses of 50 to 60 larvae produce fatal infections in rats. Most of the wild rats surveyed contained 9 to 10 adults.¹⁰

Other rodent species, such as mice or guinea pigs, do appear to develop infections, although the severity of the clinical signs associated with infection does vary with the host species infected and the number of larvae ingested. For example, Mackerras demonstrated that guinea pigs are poor hosts and that even with doses of 100 to 200 larvae (a fatal dose in rats) the animals failed to develop any clinical signs of infection.⁵ Very few larvae appeared to reach the CNS and of those that did most died within a few days. Similarly, experimentally infected dogs showed little or no clinical evidence of infection with doses less than 200 larvae.^{14,43} Mice infected with 3rd stage larvae did not develop patent infections either however, they showed severe clinical signs and a high mortality rate when dosed with 70 or more larvae.³

There is a wide range of species infected by 1st stage larvae as *A cantonensis* is promiscuous in its selection of intermediate hosts. The Giant African Land snail, *Achatina fulica* (Bowdich, 1822) appears to be a significant vector³¹, although its importance may be limited to its role in infecting people rather than spreading the parasite.⁶ Despite reports of an incursion into Gordanvale, Queensland in 1977, *A fulica* is not considered to be endemic to Australia and consequently native species of mollusc appear to be the main vectors.⁴⁸⁻⁵⁰ Virtually all species of introduced and native terrestrial molluscs have proven to be potential intermediate hosts in Australia including *Helix aspersa*, *Deroceras laeva*, *Limax aborum*, *Vaginulidae spp*, *Onchidium spp*, *Helicarion spp* and *Physa spp*.³ In Southeast Asia, North America and Japan the findings are similar. For example, Campbell demonstrated that all terrestrial and carnivorous slugs or snails in the Louisiana region were suitable

intermediate hosts.³³ Numbers of infective larvae recovered from intermediates hosts varies according to the size of the host, age and species.^{3,33}

Infections have also been identified in several species of crabs, freshwater fish, prawns, amphibians, sea snakes, lizards and predacious land planarians.³⁹ Within these paratenic hosts, larvae do not tend to develop any further but reside within the muscles or abdominal viscera as quiescent 3rd stage larvae.⁵¹ Experimentally, pigs and cattle also act as paratenic hosts. Their significance as vectors for the disease in humans or dogs is unknown but likely to be important.¹⁰ In Australia, Bhaibulaya demonstrated the terrestrial carnivorous snail (*Strangesta bullacea*) and the blue-tongued lizard (*Tiliqua scincoids*) were natural paratenic hosts.³⁹ Unpublished studies have shown that seawater paralyses 1st and 3rd stage *A cantonensis* larvae, consequently the significance of marine fauna as intermediate hosts or the threat of *A cantonensis* to the marine industries is doubtful.⁶

1.6 Epidemiology

1.6.1 Spread of *Angiostrongylus cantonensis*

There are two proposed theories to explain the apparent rapid spread of *A cantonensis*. Alicata speculated that due to its common ancestry with *A sandarsae*, *A cantonensis* spread from Madagascar using *Achatina fulica*, the Giant African Land snail, as an intermediate host to move throughout the Indian Ocean and south Pacific regions.⁵¹

The parasite appears to be maintained successfully within both the chronically infected definitive host and intermediate host populations. The various paratenic hosts carry small to moderate numbers of larvae but appear to be unimportant to the maintenance of the life cycle. Owing to the molluscs short life span and limited mobility, it is more likely that the behaviour of the true definitive host, the rat, has led to the spread of the parasite.³¹

Accordingly, Drozdz proposed an alternative hypothesis.⁵² Rats are able to withstand relatively large numbers of *A cantonensis* migrating through their CNS without significant disease, suggesting a long-standing relationship, one unlikely to have occurred in the short time frame suggested by Alicata. *A cantonensis*, *A mackerrasae* and *A malaysensis*, the only members of the *Angiostrongylus* genus to have a neurotropic phase in their life cycle, are all found within native rodent species in Southeast Asian and Australia.⁶ Consequently, while first described in China, Drozdz proposed that Southeast Asia was the ancestral habitat of *A cantonensis* along with *A mackerrasae* and *A malaysiensis*.^{6,29,52}

Spread from this region probably occurred via trade routes and importation of contracted labour. In the late 19th Century and early 20th Century 10,000 workers were imported from Indonesia and Indochina to the nickel mines and farms of New Caledonia.²⁹ Rats, presumably, migrated with the workers and it was not uncommon for people to bring *A fulica* with them for its presumed medicinal properties or as ready source of protein.^{29,31}

In the first half of the 20th Century troop movements during WWI and WWII contributed to the spread of the parasite.^{6,29,31} Soldiers of the Imperial Japanese Army carried *A fulica* with them as a

source of protein during the Pacific campaign. Extensive troop and cargo movements enabled the definitive host, the rat, to spread between islands of the Pacific Basin.

A cantonensis is now considered to be endemic to the Indopacific region ranging from the East and West coasts of India to the Pacific Islands, Hawaii and continental USA, north to the islands of Hokkaido, Honshu and Kyushu off the coast of Japan, to as far south as Sydney, Australia (Figure 2).^{18,31} There have been over 2500 reported cases of presumed neural angiostrongyliasis in humans since the first documented case in 1944.³¹ From the mid 1960s until today there has been increasing evidence of the spread of *A cantonensis*, particularly in northern Africa and Central America. Infections outside the Pacific Basin were first reported in Madagascar (1964) and Mauritius (1965)^{29,31}, Egypt (1977)⁵³, Puerto Rico (1984)^{54,55}, Louisiana (1987)¹⁸ and in the Caribbean-Gulf of Mexico area.^{31,56} The establishment of the parasite in the nearctic regions, namely on Hokkaido, Honshu and Kyushu islands of Japan, suggests that the parasite is able to survive in harsh, cooler environments.³¹ Presumably, if there is a suitable molluscan host, capable of withstanding extremes of temperature, then the parasite can be maintained in these regions. There have been isolated reports of angiostrongyliasis in countries like New Zealand and Switzerland, however these have all been in travellers returning from endemic regions.^{35,36}

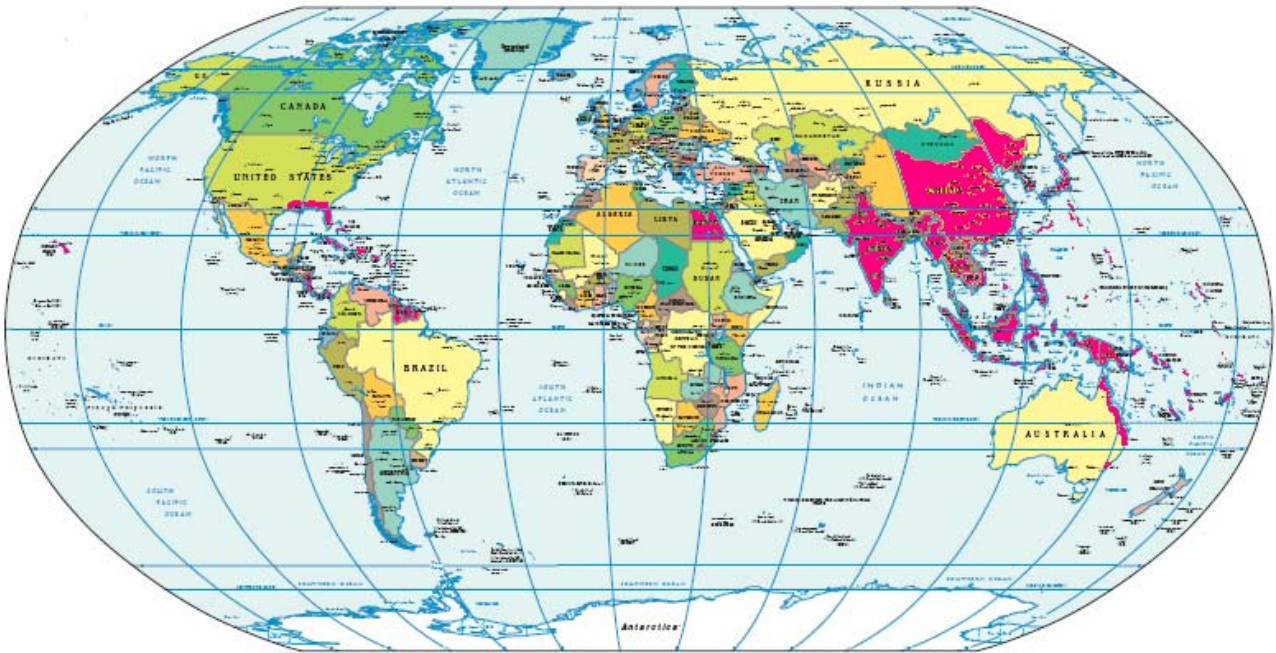


Figure 1.2: Global distribution of *Angiostrongylus cantonensis* indicated by the areas in red.

While war may have been one of the most significant social forces driving the spread of *A. cantonensis* in the early half of the 20th Century, humankind's other great social disorder, drug trafficking, appears to have been at the helm for the majority of the latter half. The exact route by which *A. cantonensis* became established in Cuba in 1971 is not known but certainly its origins in Northern and Southern African, continental USA and Central America can be attributed to the illicit drug trade from Cuba and South America.³¹ During the 1980s, a vast network of contraband trafficking in cocaine, cannabis, heroin, arms and consumer goods existed between the Caribbean and Central southern regions of North America, particularly the Florida Cays, rivers of the Mississippi delta, Atlantic ports of Columbia, Panama and Nicaragua as well as the remote beaches of Haiti, Jamaica, the Dominican Republic and the Gulf Coast ports of Mexico.³¹ It is likely that rats were occasionally transported, along with the contraband, through these illegal trade routes and with them *A. cantonensis*. This scenario has probably been repeated along the coast of West and North Africa.³¹

1.6.2 The Role of *Achatina fulica*

Coupled with the rat's cosmopolitan life style, *Achatina fulica*, the Giant African Land snail, has been implicated in the spread of *A. cantonensis*. *Achatina fulica*'s geographical distribution appears to parallel the outbreaks of eosinophilic meningoencephalitis associated with *A. cantonensis*.³¹ While there are over 40 species of slugs and snails naturally infected with *A. cantonensis*, the fecundity, hermaphroditic reproductive strategy and huge size (up to 25cm in shell length, Figure 1.3) have made *A. fulica* the most significant intermediate host.³¹ *A. fulica*, first described by Bowdich, in Madagascar in 1822, spread via the major sea trading routes to India and Ceylon before moving east towards Southeast Asia and the Malay Peninsula. During Japanese occupation of China and Southern Asia, colonists and troops brought the giant African Land snail with them, wilfully or unintentionally. In Hawaii, the snails were introduced by Japanese immigrants as early as 1936.³¹ Continental USA had brief colonies of the snails in Ohio, Arizona and Florida before they were eradicated.³¹ Similarly the area surrounding Cairns in Northern Queensland, Australia had a large population of the snail before they were eradicated in 1977.^{48,50} *A. fulica* is now endemic to most of the Pacific islands and Southeast Asia.³¹

It is important to note that *A. cantonensis* is well established in a number of areas that the giant African Land snail is not, namely Australia, parts of Polynesia and Melanesia, the Caribbean and southern United States.^{18,33} Work done by Noda and Uchikawa in Japan on the rat/snail interactions,

found that rats prefer smaller species of snails, particularly the juvenile stages.⁵⁷ The giant African Land snail can harbour up to 90,000 infective 3rd stage larvae and yet the lethal dose for rats is less than 200 larvae.¹⁰ Smaller species of molluscs and slugs harbour fewer infective larvae and, consequently, are more likely to be the source of infection for the definitive hosts.³³ Drozdz and colleagues theorised, therefore, that *A fulica* has only recently become important to the spread of angiostrongyliasis. Their research suggests that *A cantonensis*, along with *A mackerrasae* and *A malaysiensis*, developed in rats in the Indo-Malayan region and Australia rather than spreading from other regions. *A mackerrasae*'s preference for the indigenous hosts *R fuscipes* and *R lutreolus* and the fact that it is found only in Australia supports this theory.⁶ Consequently, the significance *A fulica* as a vector for the spread of *A cantonensis* is probably less than that of the definitive host, the rat.



Figure 1.3: *Achatina fulica* adult (Bowdich, 1822). (Reproduced with permission, <http://achatina.ru/Photo/Page.Eng/Fulica.htm>)

1.6.3 Route of Infection

Outbreaks of angiostrongyliasis in human populations are commonly associated with periods of famine and starvation.³¹ Japanese soldiers, for example, used *A fulica* as an emergency source of protein during the occupation of Southeast Asia. In many Asian countries, snails are considered a delicacy and handling when preparing them as food or poor cooking techniques have been implicated in several outbreaks.⁵⁸ Snails and slugs are considered symbols of fertility by many cultures and consequently they are used in many concoctions either for tribal remedies or as aphrodisiacs.³¹ Smaller species of snails and slugs may represent a more important vector for transmission of the disease.³³ While harbouring smaller numbers of infective larvae they are more likely to be overlooked when preparing food.

The incidence of disease and mode of infection varies from region to region. There appears to be some seasonal influence, but this is dependant on a number of factors. For example in Tahiti, most infections are associated with the ingestion of freshwater prawns, especially during March to September when the prawns are most numerous.^{2,29} In New Caledonia, the disease is more likely to occur after the rainy season when the vegetation has grown and infected planarian populations are at their peak.⁶ In Taiwan, *Achitina fulica* plays an important role in the incidence of disease; over 80% of the cases are children under the age of 15 and occur between May and September when the snails are abundant and most active.² In Thailand, the disease incidence is evenly distributed throughout the year and most people (especially males) are infected by ingestion of the raw aquatic *Pila sp* of snails.^{58,59} The role of other paratenic hosts is important also. The yellow tree monitor (*Varanus bengalensis*) in Thailand can harbour infected 3rd stage larvae for up to 6 weeks and it has been implicated in a number of cases.^{21,60} Other paratenic hosts like frogs, toads and freshwater crustaceans can harbour the larvae for similar periods.

Infection by contamination of food with mollusc secretions or excretions is speculative. Reports have shown that infective 3rd stage larvae are found within the mucus trails and excreta of certain species of slugs and snails.³³ However the viability of infective 3rd stage larvae is low when outside intermediate or paratenic hosts and most larvae will die within minutes unless sufficient moisture is present.³³

In Western regions, ingestion of raw intermediate or paratenic hosts is still the most likely source of infection.³³ Children are most at risk of infection. Toddler's fascination with smooth,

glistening objects is a likely scenario when cases have been reported in children. Young adult males also appear to be over represented considering that eating a raw slug or snail seems to be a relatively common practice amongst this group, as was the case with the most recent report in Australia.⁶¹ Contamination of vegetables has been documented as the cause of several outbreaks.^{31,62} Whether this reflects contamination with mollusc secretions or direct ingestion of infected intermediate or paratenic hosts is not known.

To date, there is comparatively little literature published concerning infections in animals. Naturally occurring neural angiostrongyliasis has been reported in dogs, horses, marsupials, birds, reptiles and primates.^{14,16,18,25,26,63-66} Infections appear to parallel that of humans in the corresponding geographical regions. In Australia, Mason demonstrated a peak incidence of infection in dogs occurring in May (Autumn) in southeast Queensland and this seasonality has also been noted with human cases.¹⁴ The route of infection is generally unknown, although many of the animals had been observed eating slugs and snails. Owing to differences in veterinary care, attitudes toward sick animals and diseases like rabies, infection rates in animals in many countries remains unknown.

1.7 *Angiostrongylus cantonensis* in Australia

In Australia, Mackerras & Sandars first described the parasites life cycle in 1955.⁵ Bhaibulaya, however, discovered that the parasite that Mackerras & Sandars had so eloquently described was, in fact, a new species; *Angiostrongylus mackerrasae*.³ The first report of suspected neural angiostrongyliasis in humans occurred in 1971, although infections may have occurred as early as 1959.^{6,67} It would seem that cases occur more frequently after prolonged, unseasonably wet weather in both dogs and humans, and there is a distinct peak in incidence rates in dogs in southeast Queensland between April and June.¹⁴ The first definitive case of human neural angiostrongyliasis was diagnosed at necropsy from a young child in Brisbane in 1999.⁶⁸ Up until this point all human cases had been presumptive, although the diagnosis was supported with serology in some instances.

Angiostrongyliasis was first described in dogs in 1976.¹³ The first report of *A cantonensis* infecting other species was recorded in 1978 in *Macropus rufogriseus* (Bennett's Wallaby).¹⁶ Naturally occurring infections have been identified in horses, captive rufous bettongs, captive tamarins, birds (kingfishers and tawny frogmouths) and fruit bats.^{6,22}

The first report of angiostrongyliasis in dogs in Sydney was recorded in 1989, indicating the parasite was moving south, although the first human case was not reported until 2003.⁶¹ Since 1995 there have been cases reported at Taronga Zoo in non-captive brush-tailed possums and captive small primates.⁶ A fennec fox with CNS disease also appears to have been infected with *A cantonensis* (K Rose, Taronga Zoo, unpublished data). Rats trapped in the area around the zoo have had patent infections (K Rose, Taronga Zoo, personnel communication).

The identification of sporadic outbreaks of neural angiostrongyliasis in fruit bats has been facilitated by the need to rule out lyssa virus infection as a cause of neurological disease.⁶ For this reason, fruit bats with neurological disease are routinely euthanased and necropsied. The route of infection is unknown although fruit bats have been observed feeding on the ground and snails have also been identified in trees, some up to 4 m above the ground.⁶

Clearly *A cantonensis* is well established in Sydney although there is no information on the disease in northern NSW. While the spread of the parasite could be simply due to southerly migration it is also possible that the parasite has been transported directly to Sydney via shipping routes.

1.7.1 *Angiostrongylus mackerrasae*

Angiostrongylus mackerrasae is endemic to Australia. First described in 1955 this species infects the bush rat, *Rattus fuscipes* in Queensland and swamp rat, *Rattus lutreolus* in Tasmania.⁶ In Brisbane, it has been found in co-infections with *A. cantonensis* in the domestic rat *R. norvegicus* but not in *R. rattus*.³⁹ Its pathological potential is unknown because cases of EME are assumed to be due to *A. cantonensis* without specifically identifying the species.^{13,16,19,25,66,68,69} Similarly, *A. malaysiensis*, which is endemic to Malaysia, Indonesia and central Thailand, is present in many native species of rat co-existing with *A. cantonensis*.⁶ But unlike *A. malaysiensis*, which has been shown to cause disease in experimentally infected monkeys⁷⁰, *A. mackerrasae* has not been implicated as a cause of EME in any species. Perhaps genetically identifying each species may help determine their contribution to neural angiostrongyliasis. It is also unknown at the time of writing whether all three species have common antigens and therefore is it no possible to comment on the significance of subclinical infections involving *A. mackerrasae* or *A. malaysiensis* with respect to serology.

1.8 Angiostrongyliasis in Dogs

Australia is the only country to have reported naturally occurring canine neural angiostrongyliasis. The lack of case reports of domestic animals in Southeast Asia is probably due to a number of factors including socio-economic constraints, lack of sophisticated veterinary care and perhaps attitudes towards sickness and disease in animals. Rabies is found throughout the region, consequently dogs found with neurological disease are not likely to receive a necropsy following euthanasia.^{6,18}

The largest case series was reported by Mason and consisted of 55 naturally occurring cases from the Brisbane area¹⁴. The average age of the Mason's patients was 10 weeks (median 9 weeks, range 7 to 28 weeks) and there was no breed predilection. Cases were included if they demonstrated eosinophilic pleocytosis of the CSF in association with ascending CNS dysfunction or if they had affected littermates with histologically-confirmed neural angiostrongyliasis. The details of these cases are outlined in Appendix 4. All 55 dogs displayed lumbar hyperaesthesia, hind limb muscle wasting and ascending paresis involving the tail, urinary bladder and hind limbs. Other clinical signs in order of frequency were vomiting (11%), cranial nerve dysfunction (9%), coma (5.5%), diarrhoea (4%), faecal incontinence (4%), seizures (2%) and constipation (2%). Mason devised a scale according to the severity of the clinical disease. Grade 1 puppies had only mild hind limb ataxia and hyperaesthesia, and tended to recover over a 7 day period. Grade 2 puppies had similar clinical features to Grade 1 and tended to recover within 7 to 14 days, however many had residual neurological deficits that persisted for months and in some cases indefinitely. Grade 3 puppies were most severely affected and progressed to profound, generalised hyperaesthesia, tetraparesis and occasionally coma. All dogs in this category were euthanased on humane grounds.

Cases were treated with supportive care alone, or supportive care and glucocorticoids. Supportive care consisted of expressing the urinary bladder, passive physiotherapy, antibiotics and enteral nutritional support. Prednisolone was administered at a dose of 1 to 2 mg/kg for an average of 7 days. Most dogs recovered over 10 to 16 days although many dogs took up to 2 months to recover fully. Thirty-one of the 55 dogs (56%) died or were euthanased. All of these dogs had necropsies and from each case larvae were collected and confirmed to be *A cantonensis*. Of the surviving cases, 16 (29%) had permanent neurological deficits consisting mainly of hind limb ataxia and tail paresis. Eight

dogs received anthelmintics (levamisole or mebendazole). Of these 8 dogs, 6 died (75%) and the remaining two had significantly longer recovery periods. Half of the eight dogs received glucocorticoids concurrently, including the two surviving dogs, and they were all amongst the most severely affected.

Collins and colleagues reported the first cases of canine neural angiostrongyliasis in Sydney in 1992.²⁵ Five dogs were described; a 9-week-old male Bull Terrier puppy that was euthanased due to progression of clinical signs and four German Shepherd puppies, all from the same property. CSF was collected from the Bull Terrier puppy prior to necropsy and demonstrated a marked eosinophilic pleocytosis (886×10^6 cells/L). Nematode larvae were evident in histological sections of the CNS. Two of the German Shepherd puppies, at 12-weeks-of-age, presented for generalised hyperaesthesia and hind limb weakness. They developed pyrexia and diarrhoea and were treated with flunixin and an anti-diarrheal mixture. They made a complete recovery. Three weeks later 2 more puppies, aged 5-weeks, presented for generalised hyperaesthesia, diarrhoea and hind limb weakness but died soon after. *A. cantonensis* larvae were recovered from the spinal cords of both puppies in association with eosinophilic granulomatous inflammation.

In most of the cases reported there has been no associated lung pathology. However adult *A. cantonensis* have been recovered from some cases, which would suggest that migration to the lungs, and subsequent extension of the disease is possible.⁴⁰ Observations of 1st stage larvae in the faeces of dogs had been made by Guilhon (1965), however it is likely these were actually *A. vasorum* larvae.¹¹

1.9 Experimental Infections in Dogs

1.9.1 Jindrak and Alicata, 1970

In 1970 Jindrak and Alicata infected five juvenile dogs (5 to 8 months of age) to examine the distribution and pathogenicity of the parasite in the CNS and to determine whether or not the parasite reached sexual maturity in the lungs of dogs.¹¹ Some dogs were infected orally with 9000 larvae, while others were infected via subcutaneous injection with the same number of infective 3rd stage larvae. Two dogs were euthanased 3 days post infection (one orally infected and one subcutaneously infected) while the remaining three dogs were euthanased at 21 days (orally infected), 60 days (subcutaneously infected) and 90 days (orally infected) post-infection, respectively. Clinical signs were observed in both groups of dogs starting at 11-12 days post infection and continuing for 2 weeks. Signs were mild ranging from hyperaesthesia and back pain, to hind limb weakness and ataxia. Repeated faecal examinations 45 to 90 days post infection failed to reveal 1st stage larvae and at necropsy, no larvae were found within the lungs.

Distribution of larvae 3 days post infection were similar to that in rats 24 hours post infection. That is, the majority of larvae were within the spinal cord and medulla. Histology demonstrated very little inflammation within the brain and spinal cord. The dura had eosinophilic infiltrations and a large number of larvae were seen around the nerve roots. Twenty one days post infection there was significant inflammation of the brain, spinal cord and dura. Most notable were cuffs of inflammatory cells lining venules, especially adjacent to the central canal and subarachnoid space. These cuffs consisted of plasma cells, lymphocytes and eosinophils. There was also evidence of damage to sciatic nerve fibres without inflammatory infiltrates suggestive of mechanical damage by migrating larvae.

Jindrak attributed the majority of the clinical signs to lesions in the spinal cords and suggested that this because the parasite spends more time in the spinal cord of dogs compared to the definitive host, the rat. Interestingly, there was also heavy infiltration under the dural sheath of both optic nerves by eosinophils, plasma cells and lymphocytes. The authors made no observations of clinical signs relating to optic neuritis (pupillary dilation, visual impairment, etc.).

By 60 days post infection there were a few granulomas present in the subarachnoid space associated with parasite cuticle fragments, but there was no inflammation in the brain tissue or lungs. By 90 days no changes could be detected within the CNS or lungs.

1.9.2 Mason, 1983

Mason infected five 6-week-old cross-bred puppies with 3rd stage larvae.¹⁴ The larvae had been acquired from slugs found on the properties of histologically confirmed CNA cases. The dogs had been treated with pyrantel and vaccinated against distemper and canine adenovirus two weeks prior to infection. The pups were dosed with 100, 200, 300, 700 and 1000 larvae, respectively, via a stomach tube. Puppies were observed daily and either died (unrelated cause) or were euthanased between 15 and 30 days post infection. No treatment was administered to any case.

The mean time to onset of clinical signs was 11 days (range 9 to 14 days) post infection. CSF samples and blood for haematology were collected from 3 of the cases (those dosed with 300, 700 and 1000 larvae) 15 and 24 days post infection. None of the dogs developed a peripheral eosinophilia. CSF results are described in detail below, but briefly eosinophilic pleocytosis was evident in all three dogs 15 days post-infection and in one case the CSF returned to normal by 30 days post infection. Necropsies were performed on all dogs except for one pup that died of causes unrelated to angiostrongyliasis.

The dog infected with 1000 larvae was euthanased 15 days post infection and larvae were collected from the CNS. The majority of the larvae were found within the cerebellum (65%) and only 5% were recovered from the spinal cord. The overall recovery was 110 larvae (11%). The cord showed severe granulomatous myelitis. Although live larvae were recovered from the cerebellum, there was little evidence of encephalitis associated with them. The dog infected with 200 larvae was euthanased 17 days post infection. Granulomatous inflammation associated with larval fragments was found throughout the brain stem and spinal cord. Live larvae were recovered from pons, medullary pyramids and cerebellar meninges.

In the two dogs that were euthanased 25 days post infection (dogs infected with 300 and 500 larvae, respectively) no larvae were identified in any samples. There were variable degrees of

granulomatous inflammation within the spinal cord, brain stem and cerebrum. Extensive eosinophilic meningitis was also evident.

Mason also showed through another experiment that puppies would readily consume live slugs found in their environment despite adequate nutrition.

1.9.3 Yang, 1999

1 dog was infected with 500 *A cantonensis* larvae orally with no detectable clinical disease after 40 days²². There were no larvae or pathological changes noted at necropsy 40 days post infection.

1.10 Experimental Infections in Other Non-murine Species

Calves, pigs, rabbits, guinea pigs, cats and primates have all been experimentally infected with *A. cantonensis*. In all of these species no adult parasites were recovered and the growth of larvae appeared to be retarded in most instances.

1.10.1 Cats

Yang infected 3 cats with *A. cantonensis* larvae.²² Each cat was initially given 500 larvae orally but an unknown proportion of this inoculum was expelled by vomiting within 2 minutes of administration. One of these cats was reinfected orally, but vomited again and there was no evidence of disease 40 days post-infection. The remaining two cats were given 500 and 1000 larvae, respectively, via subcutaneous injection. Within 15 days the cat that received 500 larvae showed dullness, anorexia, reluctance to move, hind limb lameness and vocalisation. At necropsy 20 days post infection six 5th stage larvae were recovered from the spinal cord and brain stem. The 3rd cat, which received 1000 larvae subcutaneously, presented clinically much the same as the 2nd cat, but signs were evident within 7 days of infection and were much more severe. The cat deteriorated over the following 2 weeks but then began to improve. At necropsy, 34 days post infection, no larvae were recovered from the CNS and no pathological changes were evident. Yang noted that the recovered larvae were much smaller and less developed than those of a similar stage recovered from experimentally infected rats.

1.10.2 Rabbits

Rabbits have been used by several authors to characterise the migration of *A. cantonensis* its and effects on the central nervous system.^{45,71} Doses of 1000 to 2000 larvae appear to be fatal while doses less than 500 do not elicit symptomatic disease.⁵¹ Onset of clinical signs was relatively short, ranging from 3 to 5 days indicating that the migrating larvae cause significant damage. At necropsy, Jindrak and colleagues found many of the peripheral nerves, particularly the sciatic (ischiatric) nerve, damaged by migrating larvae. Rabbits reinfected or treated soon after infection with levamisole had evidence of severe myositis without CNS involvement.

1.10.3 Pigs and Calves

Jindrak and Alicata investigated the possibility that pigs and cattle could be vectors for the spread of *A. cantonensis* to humans.¹⁰ Five calves and 5 piglets, all aged 1 month, were infected with 70,000 and 20,000 3rd stage larvae respectively. One animal from each group was euthanased 3, 7, 14, 28 and 56 days post infection. None of the piglets show clinical signs relating to the infection. Three of the calves showed mild ataxia up to 4 weeks post infection. The most significant pathological difference between the two groups was that all of the calves had CNS involvement, with larvae still alive at 28 days post infection. In the pigs the larvae were viable for only the first three days and they were mainly recovered from the liver and regional lymph nodes, especially the mesenteric lymph nodes. It would seem as though the pigs were able to mount an intrinsic immune response sufficient to prevent larvae reaching the CNS, however the difference may also be related to the numbers of larvae ingested.

1.10.4 Rhesus Monkeys

Four Rhesus monkeys (*Macaca mulatta*) were infected with 335, 600, 420 and 1700 larvae by Wienstein, et al.⁴⁴ No monkey showed any overt signs of infection. They were euthanased on days 17, 24, 32 and 69 respectively. Importantly, Weinstein found that there was very little inflammation associated with the parasite but there was an intense eosinophilic response in areas that had been previously penetrated by the individual larvae. This is similar to the findings in humans and suggests that in primates, the metabolic or cuticular antigens likely evoke the severe inflammatory response associated with neural angiostrongyliasis. All of the larvae recovered were significantly retarded in their growth and tended to congregate in the brainstem. No adults were recovered and there were no changes in the lungs. Only the monkey that received the largest dose (1700 larvae) demonstrated a peripheral eosinophilia.

1.10.5 Guinea Pigs

Guinea pigs infected with 3rd stage larvae may develop clinical signs depending on the larval dose. Doses of 30 to 50 larvae did not elicit any clinical signs while doses of 300 to 1000 demonstrated clinical disease from 15 days post infection.⁷² These signs were characterised by a loss of Purkinje cells within the cerebrum, marked eosinophilic infiltration and degenerate larvae surrounded by granulomatous inflammation. Peripheral eosinophilia was evident 3 days post infection. Eosinophil numbers reached a peak within the CSF between days 20 and 28.

1.11 Pathophysiology

The exact pathophysiology of angiostrongyliasis is not known but there are several proposed mechanisms. The two most likely causes are (i) the mechanical trauma attributable to migration of the larvae and (ii) the host response to dead or dying larvae. Other mechanisms include release of toxic metabolites by the migrating larvae and vascular insufficiency.⁷³

Angiostrongylus cantonensis is unique in that it has a tropism for both the CNS and pulmonary arteries. The stage to which the parasite develops and the location where it can be found depends on the species of the host, the host's immune status and the number of larvae ingested. In dogs, only the neurotropic phase has been seen and there are no substantiated reports of pulmonary involvement¹¹. In contrast, *Angiostrongylus vasorum* migrates to the pulmonary arteries of dogs without CNS involvement despite its close taxonomic relationship to *A cantonensis*.⁷⁴

In naturally infected rats there is little clinical evidence of infection with *A cantonensis*. They tend to maintain body weight and occasionally develop respiratory signs. Such a host-parasite relationship is a feature of many parasitic infections and it can enable some parasites to live and reproduce within their definitive host for many years.⁷⁵ It is unlikely that the host remains immunologically ignorant of the parasite consequently, there must be mechanisms in place to enable the parasite to avoid or suppress the host's immune system. For example, while rat eosinophils afford some protection, they may lack the receptors necessary for recognising parasites like *A cantonensis*.⁴⁰ This is evident in the lack of CSF eosinophilia and it is not until the adults reach the lungs and begin producing eggs that a peripheral eosinophilia develops.⁷⁶

The exact path by which larvae migrate through dogs is not known but evidence from experimental infection in other species provides clues.² Once ingested larvae invade the gastric mucosa to reach blood vessels and lymphatics.⁷⁷ This may be associated with vomiting, abdominal pain or other gastrointestinal disturbances.² Once within the circulation, larvae tend to migrate via the portal circulation, hepatic parenchyma and caudal vena cava to reach the lungs. In the lungs, larvae migrate into the pulmonary veins and move into the systemic circulation. They may also reach the circulation by migrating through the peritoneum and into the thoracic cavity. The larvae may make several trips within the circulation before lodging in the target organ. In dogs and rats it has been observed that the larvae lodge within muscle bellies, particularly active muscles (respiratory or

locomotory), destroying muscle fibres as they seek out branches of motor or sensory nerve fibres that subsequently provide access to the CNS.^{43,77,78} While migrating along peripheral nerve fibres they produce focal destruction and inflammation which would explain some of the clinical manifestations such as myalgia and paresthesia². In dogs, peripheral nerve migration would appear to be more important of the two pathways. This is supported by analogy with *Pneumostrongylus tenius* which invades the CNS of the Canadian white-tailed deer (*Odocoileus virginianus*) via peripheral nerves, especially those located in the lumbar muscles⁷⁷. Lumbar pain is a common clinical finding in the initial stages of infection in dogs.^{22,26,43,79} and this could correspond to invasion of peripheral nerves subserving this region.

In rats, larvae may be recovered from the CNS within 4 hours of ingestion but the majority of the parasites arrive in the CNS within two days. While larvae can be found throughout the body earlier, by 4 days they are found only within the CNS⁷⁷. In dogs, larvae appear to take longer to reach the CNS.^{11,14} Once within the CNS larvae either die and become surrounded by granulomatous inflammation, or emerge on the surface of the brain and continue to mature into young adults within the subarachnoid space.

Distribution within the brain varies amongst host species. Larvae migrating along or inside peripheral nerves would first enter the spinal cord and ascend to the medulla, pons and mesencephalon.⁷⁷ Mackerras & Sandars observed that in rats larvae tended to accumulate in the cerebral hemispheres⁵, while Jindrak, et al. found initially larvae concentrate in the spinal cord, diencephalon, cerebellum and medulla^{77,78}. In dogs the latter appears to be the case as at 3 days post infection the majority of larvae were found within the spinal cord, pons, medulla, diencephalon and mesencephalon⁴³.

In human cases, histology has demonstrated the mechanical damage and destruction of neural structures caused by migration of the larvae.² This mechanism is responsible for the myelitic and encephalitic symptoms, particularly in severe forms of the disease.⁷³ In these cases, tracks and microcavities are abundant within the spinal cord and brain.⁸⁰ These can be associated with live or dead larvae. There are also vascular reactions associated with thrombosis and aneurysm formation. The meningitic symptoms are associated with antigen/antibody responses within the CSF. Focal inflammation is evident when CSF escapes from the subarachnoid space, for example into the dural sheaths of the spinal nerves, the spinal ganglia and walls of the cerebral venous sinuses². The cranial nerve signs observed in humans are associated with lymphocytic, plasmacytic and eosinophilic

infiltration of the dural sheaths of these nerves which gives rise to the cranial nerve palsies, optic neuritis and radicular symptoms.²

In any organ system, the inflammatory process proceeds in an ordered series of events starting with movement of blood constituents (fluid, electrolytes, proteins and leukocytes) into the tissues accompanied by activation of mediators including acute phase proteins, the complement and clotting cascades and the fibrinolytic system. While this process is seen in all tissues, including the CNS, there are significant differences attributed to the unique features of the CNS. Summers et al,¹ describe the CNS as “existing in a somewhat sequestered and immunologically dormant state within the body” as a result of the BBB limiting the movement of blood constituents into the CNS, a lack of specialised antigen-presenting cells, absence of a lymphatic system and low expression of major histocompatibility complex molecules. Despite this apparent “dormancy”, the CNS is able to mount a substantial immune response.

CNS injury is mediated to a certain extent by cells within the CNS itself, chiefly glial cells, especially microglia. A significant proportion of inflammatory cells, however, are sequestered from the periphery, namely lymphocytes and macrophages.⁸¹ The BBB limits the involvement of these peripheral cells and macromolecules in CNS inflammation. Consequently, disruption of this barrier represents an important step in inciting injury within the CNS.

“Barrier” is perhaps a misleading term when applied to this conceptual structure within the CNS. The blood brain barrier’s origins can be traced back an experiment in which a vital dye was injected intravenously.⁸² The subsequent lack of uptake by the CNS, when all other organ systems were stained, suggested the presence of a barrier between the circulation and the CNS. The endothelium lining vessels within the CNS do indeed differ from that in other organs. Mitochondria are 2-3 times more abundant in brain endothelium and there are also substantial numbers of pinocytotic vesicles within the cytoplasm suggesting an active transport mechanism. The most significant difference, however, lies in the presence of tight junctions between brain endothelial cells. Beneath the endothelium lies a basement membrane and surrounding this are the processes of numerous astrocytes, which play an important role in the maintaining the BBB.

CSF circulates within the subarachnoid space, the central canal and ventricular system. The majority of the fluid is produced by the choroid plexus within the lateral ventricles, although a small component comes from the brain itself through the perivascular spaces that surround CNS blood

vessels.⁸³ Fluid is absorbed into the venous system via the arachnoid villi. The rate of cerebrospinal fluid production tends to be constant through a variety of conditions. The rate of absorption, however, is inversely correlated with intracranial pressure. Examination of the CSF is generally the single most clarifying test for any patient with suspected inflammatory CNS disease. Determining the albumin quotient (difference between CSF albumin and serum albumin) is useful for establishing BBB integrity as albumin arises exclusively from serum. A quotient greater than 0.3 indicates damage to the BBB. Unlike albumin, Immunoglobulin G (IgG) can be produced within the CNS. Measuring the relative ratios of IgG in serum and CSF can give an indication as to whether the IgG was manufactured locally.

While there are a number of mechanisms suggested for the pathogenesis of *A cantonensis*, the inflammatory response to the organism is certainly a major contributor. Inflammation is an intricate matrix of cellular interactions, cytokine and antibody productions and complement activation. T-cell populations, cytokines, such as interleukin 5 (IL-5), immunoglobulins, matrix metalloproteinases and especially eosinophils are important components in the host's cellular response to infection with *A cantonensis*. Granulomatous inflammation, a hallmark of neural angiostrongyliasis, is characterised by accumulations of mononuclear cells, lymphocytes, plasma cells, macrophages and eosinophils.

1.11.1 Eosinophils

Eosinophilic meningoencephalitis is a salient clinical finding in CNA. The eosinophil's key role in the host's ability to resist infection, as well as contributing to the disease process itself, conveys the importance of this inflammatory cell in any metazoan infection. In the non-permissive or accidental hosts, eosinophilia is induced at a much earlier stage of *A cantonensis* infection.⁸⁴ In rats, eosinophilic pleocytosis of the CSF is dependant on a number of conditions. Experimentally, it has been shown that the presence of peripheral eosinophilia, the pre-existence of larvae within the CNS and an appropriate antigen are required to produce the eosinophilic pleocytosis.⁸⁵ Antigen alone is not enough. This suggests that the BBB must be compromised in order for eosinophils to enter the CSF. This lack of host response, however, is dose dependant. With infection by substantial numbers of larvae, the situation changes. Doses of 150 to 200 larvae prove fatal to the rat.⁸⁶

In comparison to neutrophils, eosinophils are weak phagocytes yet they play an essential role in parasitic infections and allergic reactions. Like all polymorphonuclear cells, eosinophils are produced and stored in the bone marrow prior to release into the circulation and migration into tissues.

Their life span is usually only 4 to 5 days.⁸³ When a parasite invades the host, large numbers of eosinophils are released into the circulation. They attach themselves to the surface of invading larvae and attempt to “kill” them. This is achieved in a number of ways: by releasing hydrolytic enzymes, oxygen free radicals and a highly larvacidal polypeptide call *major basic protein*.⁸³ Other cytotoxic proteins included eosinophil peroxidase, eosinophil-derived neurotoxin (eosinophil protein X) and eosinophil cationic protein.⁸⁷ In allergic reactions, eosinophilic chemotaxis occurs subsequent to mast cell and basophil degranulation. Eosinophils are thought to detoxify some of the pro-inflammatory substances released by mast cells and basophils as well as phagocytose allergen-antibody complexes, thus limiting the extent of the inflammatory process.⁸³

Within the CNS, eosinophils have the ability to produce a disease process known as Gordon’s phenomenon.⁸⁷ This process is characterised by loss of Purkinje cells within the cerebellum. Experimental infection of mice and guinea pigs with *A cantonensis* produces a model of this phenomenon. Gordon’s phenomenon reflects the neurotoxicity caused by eosinophils.⁷² It can be induced in rabbits and guinea pigs by injecting them intracerebrally with eosinophils, or eosinophil extracts, from patients with eosinophilic Hodgkin’s disease. The subsequent destruction of cerebellar Purkinje cells is characterised by stiffness, ataxia and paralysis.⁷² Infecting the same animals with *A cantonensis* 3rd stage larvae can have similar effects.^{71,72}

Experiments have shown that some *A cantonensis* antigens are specifically chemotactic for eosinophils in non-permissive hosts.^{88,89} For example, when young adult worms are surgically transferred to the pulmonary arteries of rabbits and guinea pigs, they produce a local and systemic eosinophilia, while in rats they produce none. The same is true of CSF.⁸⁷ When monoclonal antibodies against these antigens are given pre-emptively, the host’s eosinophilic response is markedly reduced.⁸⁸ Rat and guinea pig eosinophils bind to the surface of *A cantonensis* larvae and destroy them by IgG-dependant and IgG cell-mediated cytotoxicity mechanisms, respectively.^{76,87} But the by-product of this inflammatory reaction in non-permissive hosts is Gordon’s phenomenon.⁸⁷

Eotaxin is the most potent mediator in the chemotaxis of eosinophils.⁹⁰ Its presence in human asthma has been studied extensively. Its role in neural angiostrongyliasis, however, is not well understood. In mice infected with *A cantonensis* eotaxin levels rise after the first week, peaking after 3 weeks. This corresponds to maximum levels of eosinophils within the CSF.⁹⁰ Concentration of eotaxin within the CSF appears to correlate with larval burden.

Experiments in mice treated with mebendazole and interleukin-12 (IL-12) have shown the importance of eosinophils in these infections⁹¹. IL-12, together with gamma-interferon (IFN- γ), drives T-helper cell response towards the T_H1 rather than the T_H2 phenotype (see later). This reduces local eosinophilic infiltration. In mice treated with IL-12 only, there was substantially less eosinophilic infiltration and consequently, meningitis was less evident although the amount of trauma caused by migrating larvae was greater. In thymectomised and athymic nude mice, larvae do not die within the brain, but migrate to the lungs approximately 30 days post infection.^{76,92} This suggests that the eosinophil response is to a certain extent T-cell mediated and while eosinophils and their toxins are responsible for some of the damage to host nervous tissue, they are effective at inhibiting larval migration⁹¹.

Neutrophils are far more effective at killing larvae than eosinophils.⁹³ They are able to bind to and extend along the surface of *A cantonensis* larvae via Fc antibody and complement binding sites. Complement activation plays an important role in the host's defence by enhancing antibody-dependant cell-mediated adherence and subsequent destruction of the parasites.⁹³ In the absence of specific antibodies, complement is unable to be activated and the parasite is able to complete its life cycle in the rat. This would occur during primary infection. Consequently, neutrophil-mediated cytotoxicity is dependant of the co-operation of antibody production and complement fixation. Mice treated with anti-IL-5 antibodies, however, have high levels of neutrophils and macrophages within the CNS but very few eosinophils when infected with *A cantonensis* and yet the larvae are able to mature and migrate to the lungs.⁹⁴ This would suggest that eosinophils, not neutrophils, are responsible for killing larvae within the CNS.

Within the CNS, eosinophils activated by IL-5 are more resistant to apoptosis (programmed cell death). Despite the fact that IL-5 concentrations are high throughout the host, only eosinophils within the CNS remain resistant.⁹⁵

1.11.2 T Cells

By the 1970s, thymus-derived lymphocytes, or T-cells, were broadly classified into two groups (CD4⁺ and CD8⁺) according to cell surface markers.⁹⁶ It was thought that CD4⁺ cells helped B cells produce antibodies, hence the term T-Helper cell, and CD8⁺ cells were predominantly responsible for the lysis of infected or damaged target cells. In mice infected with *A cantonensis* both CD4⁺ and CD8⁺ cell lines increase.⁹⁷ CD4⁺ reach a peak at three weeks, while CD8⁺ levels peak seven weeks post

infection. In T-cell depleted mice significantly more larvae are recovered. More importantly the number larvae recovered were significantly lower in CD4⁺ competent mice compared to CD8⁺ competent mice. There is variation between strains of mice with some strains demonstrating improved resistance to *A. cantonensis* when CD8⁺ is stimulated.⁹⁸ It is clear, however, that T-Helper cells are more important for immunity against *A. cantonensis*.⁹⁷

In the mid 1980s it was discovered that CD4⁺ cells were heterogeneous and could be subdivided into two groups based on their pattern of cytokine expression: T-Helper 1 (T_H1) and T-Helper 2 (T_H2).⁹⁶ T_H1 cells primarily produce gamma interferon (IFN- γ), are pro-inflammatory and provide protection against intracellular pathogens. T_H2 cells produce IL-4, IL-5 and IL-13, and are important for immunity against helminth parasites. They are also responsible for facilitating antibody production.⁹⁹ Both cell types come from the same precursor and their development is dependant on a number of factors including local concentrations of IL-4 and IFN- γ , antigen loads, antigen affinity and MHC haplotypes.⁹⁶ Essentially, the two cell types are able to regulate each other to maintain a balance. There is evidence of a genetic influence to the balance of T-helper cell types, which may explain differences in host reactions to various antigens amongst individuals.⁹⁶ An alteration in the balance between T_H1 and T_H2 cells is thought to contribute to the pathogenesis of many diseases.

The role of T_H1 and T_H2 cells in schistosomiasis has been well documented and it would seem that the acute febrile disease is associated with an imbalance favouring T_H1.⁹⁹ In humans, it has been shown that sensitisation to schistosomes can occur *in utero* and subsequent post-natal infections tend to be less severe favouring the T_H2 response. In mice that have an inability to develop a T_H2 response, infection with *Schistosoma masoni* proves lethal as they are no longer able to modulate the T_H1, pro-inflammatory response.⁹⁹ Mice that have an excessive T_H2 response, however, also had an increased mortality. Thus, a balance of T_H1 and T_H2 responses is required.

Helminths are the main inducers of T_H2 cells in experimental models and humans.⁷⁵ Eosinophilia, mucosal mastocytosis and the production of Immunoglobulin E occur as a result. This response appears to be most beneficial for the host infected with intestinal helminths, as it leads to expulsion of the parasites from the gastrointestinal tract.⁷⁵ With some helminths, for example *S. mansoni*, *Brugia malayi* and *Trichuris muris*, the T_H1 cell response is important for the host defence.⁷⁵ Therefore, again, it is the balance of this system that is vital for combating helminth infections and an exaggerated T_H1 or T_H2 response leads to disease in the host.

There exists a third population of T cells called the T regulator cells (T_{REG} cells). There is a need within any host for T_{REG} cells that recognise normal flora (bacteria and protozoa) and subsequently control the immune response to these antigens.⁷⁵ It may be possible for helminths to exploit this process by activate pre-existing T_{REG} cells and switch off the host's defences.

There are also nematode specific macrophages or nematode-elicited macrophages (NeMacs).⁷⁵ These macrophages are larger, more multivacuolar and produce two important proteins; YM1 and FIZZ1. YM1 is an eosinophilic chemotactic factor. NeMacs have been show to suppress the proliferation of non-lymphoid cells and to induce T_H2 differentiation. Their role in *A cantonensis* infections is not know but they may be important for host immunity and prevention of the parasite reaching the CNS.

1.11.3 Interleukin-5

Interlukin-5 (IL-5) is a homodimeric glycoprotein released from T-cells and mast cells. Originally described as B-cell differentiating factor, IL-5 was later found to enhance B-cell growth, control the production of other haemopoietic cells and promote immunoglobulin synthesis.¹⁰⁰ IL-5 is critically involved in the development and activation of B-cells and eosinophils.⁹⁵

In mice infected with *A cantonensis*, the production of IL-5 is associated with the induction of eosinophilic pleocytosis and peripheral eosinophilia.¹⁰¹ Experimentally it has been shown that IL-5 is produced by T-cells within the CNS.¹⁰¹ IL-5 is known to promote eosinophil differentiation and proliferation, prolong eosinophil survival through modification of apoptosis and activate eosinophils.^{84,95,101} Mice inoculated with anti-IL-5 monoclonal antibodies had significantly reduced eosinophil counts within the CNS and higher worm recovery rates.^{94,100} By inference, IL-5 is partly responsible for the killing of larvae within the CNS. CSF levels of IFN- γ in such mice are very low suggesting suppression of T_H1 responses. It would appear that in mice infected with *A cantonensis*, IL-5 is the most important cytokine provoking eosinophilia.^{76,92}

1.11.4 Immunoglobulins

Immunoglobulins (antibodies) are gamma globulins with molecular weights ranging from 160 to 970 kDa. They constitute 20% of plasma proteins. There are 5 general classes of immunoglobulins: IgA, IgM, IgG, IgD, IgE. IgM is often the first to respond to infections. IgG is the most common immunoglobulin, representing 75% of circulating immunoglobulins. IgE is important in allergic

reactions and helminth infections.¹⁰² Immunoglobulins act in two main ways; (i) direct attack on invading organisms through agglutination, precipitation, neutralisation and lysis, or (ii) complement activation. Production of immunoglobulins within the CNS is increased in hosts infected with *A cantonensis*.¹⁰³

1.11.4.1 Immunoglobulin E

IgE is produced in large quantities in response to helminth infections and there is a well known association between eosinophils and IgE.⁸⁷ IgE antibodies play an important part in the host's response to metazoan parasites particularly with regard to eosinophilic mediation.⁸⁷ Peak IgE levels will be reached at different times, depending on the host species. For example, in guinea pigs a peak is reached at 14 days, compared to 28 days for rats.⁸⁷ IgE has been shown to be an important component of immunity when hosts are rechallenged.⁸⁷ In non-permissive hosts, the IgE response is much greater than in the rat and this tends to correspond to higher levels of eosinophils within the CSF and peripheral blood.⁸⁷ This situation is also seen with other parasites. For example, *Schistosoma mansoni* is associated with substantial IgE levels and eosinophilia in rats, although infection with *A cantonensis* is not.

1.11.4.2 Immunoglobulin G

There are at least 4 subtypes of IgG. The role of IgG4 is poorly understood but it appears to be expressed in allergic reactions and in response to helminth infections. Intapan and colleagues demonstrated that humans infected with *A cantonensis* express all 4 subtypes. Interestingly, IgG4 levels are increased 12- to 13-fold.¹⁰⁴ It has been suggested that IgG4 may block IgG1 complement activation and mast cell degranulation by competitively inhibiting IgE binding to foreign antigens.¹⁰⁴ Because of this competitive inhibition of IgE, patients who express more IgG4 may develop less severe disease.

1.11.5 NF- κ B Protein and iNOS

Signaling for inflammation is complex and there are a number of pathways that involve the mitogen-activated protein kinases, nuclear factor-kappa binding (NF- κ B) protein, nuclear proto-oncogenes, and Janus tyrosine kinase.¹⁰⁵ In mice infected with *A cantonensis* levels of NF- κ B and inducible nitric oxide synthase (iNOS) expression peak 3 weeks post infection.^{105,106} This corresponds to the onset of severe CNS damage, including eosinophilia, neutrophilia and the formation of granulomas. NF- κ B protein has been shown to be an important regulator for the genetic programs

underlying inflammation within the CNS, activating genes involved in immune and inflammatory responses. The target genes include cytokines, chemokines, MHC class 1, iNOS, COX-2 and p53.¹⁰⁶ Inappropriate regulation of NF- κ B protein transcription has been associated with acute inflammatory reactions, cancer, viral replication and several other neuropathies.¹⁰⁵

1.11.6 Plasminogen and Plasminogen Activators

Plasmin is an active serine protease cleaved from the zymogen, plasminogen. There are two types of plasminogen activators; tissue plasminogen activator (tPA) responsible for fibrinolysis, especially of thrombi, and urokinase plasminogen activator (uPA) which is primarily involved in cell surface proteolysis and extracellular matrix degradation leading to cell invasion.¹⁰⁷ Plasmin plays an important role in the pathophysiology of bacterial meningitis through disrupting the blood brain barrier and recruiting leukocytes.¹⁰⁸ In mice, it has been shown that PA levels increase in *A cantonensis* infections and that levels correlate with eosinophil counts within the CSF.¹⁰⁷ Therefore it is possible that increase PA activity leads to disruption of the blood brain barrier and an influx of inflammatory cells to the subarachnoid space. In bacterial meningitis, PAs have been shown to disrupt the BBB and cause extravasation of neurotoxic factors resulting in oedema and increased intracranial pressure. This is likely to occur when *A cantonensis* larvae migrate through the CNS.

1.11.7 Zinc

Zinc deficiency may play a role in host susceptibility to *A cantonensis*. Zinc's role in the immune response has been well documented and zinc deficiencies have been linked to increase incidence of viral, bacterial and fungal infections. In zinc-deficient mice it has been demonstrated that more *A cantonensis* larvae are recovered.¹⁰⁹ In particular these mice appear to be unable to produce enough IL-5, eosinophils and antibodies, which highlights zinc's crucial role in their respective developments.

1.11.8 Matrix Metalloproteinases

The matrix metalloproteinases (MMP) are a group of zinc-dependant endopeptidases that collectively catalyse the breakdown of all components of the extracellular matrix (ECM).^{105,110,111} They can be subdivided according to their substrate specificity.¹⁰⁵ They are important for normal physiological tissue remodelling as well as modulating inflammation and are produced by several leukocytes, including eosinophils.¹¹¹ In the normal mature CNS, MMP levels non-detectable however

they can become upregulated in several disease processes such as gliomas, viral encephalitis, multiple sclerosis, CNS trauma and ischaemia.

In murine models of *A. cantonensis* infection, MMP levels are elevated within CSF, especially MMP-9.¹¹⁰⁻¹¹⁵ Elevation of MMP-9 is associated with degenerative atrophy and disappearance of Purkinje cells 15 days post infection.¹¹⁰ Within the CNS, MMP-9 is involved with the destruction of basement membranes, thereby disrupting the blood brain barrier. It is also responsible for the degradation of various proteins important for the immune response. MMP-9 is also involved in leukocyte migration through its ability to hydrolyse the ECM and basement membranes.¹¹¹ Thus, MMP-9 activity is correlated to the progression of CNS degeneration and rising eosinophil levels within the CSF in neural angiostrongyliasis.

1.11.9 Pulmonary Disease

In the rat, 5th stage larvae enter the blood stream via the large subarachnoid veins and lodge within the pulmonary arteries, where they mature and copulate before the females begin producing ova.³ In other species, it is likely that most of the larvae die within the CNS before they are able to mature and migrate back to the pulmonary circulation. Consequently, pulmonary signs rarely develop. Immunosuppressed mice infected with *A. cantonensis* will have some larvae mature to adulthood and migrate to the lungs⁹⁴. The same may be true for any immunosuppressed host. Pulmonary signs have been documented in humans and there has been one report of infection with *A. cantonensis* where ova were found in the pulmonary capillaries of a patient².

Within the rat, mature *A. cantonensis* adults are capable of living within the lung parenchyma for many months. While antigenically the stages within the permissive host are very similar, the rate at which the cuticle is shed does differ¹¹⁶. The rate at which the adult stage shed their cuticle greatly exceeds that of the third and fourth stages that reside within the CNS. Shedding the cuticle may divest any adherent antibodies, eosinophils or eosinophil toxins and allow the parasite to evade the host's defences¹¹⁶.

1.12 Diagnosis

To diagnose any helminth infection the parasite in question must be identified definitively within the patient. Parasites can be identified in blood smears (*Dirofilaria immitis* in the dog), in the faeces (*Toxocara canis* and *Angiostrongylus vasorum* in the dog), from transtracheal aspirates or bronchialveolar lavage (*Aelurostrongylus abstrusus* in the cat). To date, the only truly definitive way to diagnose infection with *A. cantonensis* is to identify morphologically distinct larvae in either tissue fluid specimens (CSF or aqueous humour), which has only been documented in humans, or at necropsy.

The anti-mortem diagnosis of CNA is, therefore, presumptive. Signalment, history, clinical presentation, CSF cytology and response to treatment remain the corner stones for diagnosing this disease. Although any age of patient can be affected, puppies are over represented. The infection appears to be limited to certain geographical areas and historically it is more likely to occur in Brisbane than in Sydney.

1.12.1 History

Ingestion of an intermediate host is often the most common historical feature of human patients with neural angiostrongyliasis.^{59,65,69,117} While most owners do not see the dog eating the mollusc there is usually evidence of snails and/or rats around the immediate environment.^{14,25,65,66} In human patients, ingestion of contaminated food, especially vegetables and paratenic hosts such as freshwater prawns, monitor lizards and raw fish may be noted in the history. Vomiting or diarrhoea is often a feature of ingestion of the parasite in humans, and experimentally in dogs and cats. This is presumably due to the migration of the larvae through the intestinal wall and takes place a number of days prior to the onset of neurological symptoms.

1.12.2 Clinical Presentation

Head ache and neck stiffness (nuchal rigidity) appear to be the most common presenting complaint in human patients. In dogs, the clinical presentation is more variable but evidence of progressive CNS dysfunction, most often beginning in the hind legs or tail, accompanied by hyperaesthesia is common. Dogs can demonstrate either upper motor neuron or lower motor neuron signs or a combination of both. Severity can range from mild ataxia to paraplegia/quadriplegia. Physical findings include hyperaesthesia, hind limb ataxia, conscious proprioception deficits, muscle

atrophy, hyperreflexia or hyporeflexia, urinary incontinence, faecal incontinence, neck pain, depression, inappetence, vomiting and diarrhoea. Importantly, these signs tend to progress.

1.12.3 Laboratory findings

1.12.3.1 Blood

Peripheral eosinophilia appears to be a common clinical finding in humans cases². Eosinophil counts tend to increase over the first 2 to 3 day and can remain high for weeks or months. In dogs, this may also be the case but Mason suggests that concomitant infections with intestinal parasites may confound interpretation.¹² Biochemical changes tend to be non-specific, unremarkable or absent.

1.12.3.2 Cerebrospinal Fluid

In most canine patients with CNA CSF is abnormal. Grossly, CSF can range from clear to turbid. Eosinophilic pleocytosis is evident in the majority of cases and the percentage of eosinophils often exceeds 80% of the total cell count.^{12,59} Glucose tends to be normal while protein levels are elevated in part due to vascular leakage, disruption to the blood brain barrier and local production of immunoglobulins. In other species, eosinophilic pleocytosis in CSF often precedes peripheral eosinophilia.² IgG, IgA and IgM levels in CSF are often higher than in the blood. Parasites are recovered in the CSF in only a low percentage of human patients and like dogs, cellular counts reflect an eosinophilic pleocytosis in the range of 50 to 90%²³.

In most cases there is a correlation between the severity of the clinical signs and the level of peripheral eosinophilia, eosinophilic pleocytosis and CSF protein levels.¹¹⁸ The likelihood of larval recovery is also correlated with disease severity in humans.¹¹⁸ This is probably a reflection of a higher concentration of larvae within the CNS and CSF.

1.12.4 Imaging

Magnetic Resonance Imaging (MRI) has been suggested as a useful tool in the diagnosis of neural angiostrongyliasis in human patients. Image characteristics include prominence of the Virchow-Robin spaces, subcortical enhancing lesions and abnormally high T2 signal in the periventricular regions, high signal intensities over globus pallidus and cerebral peduncle, leptomeningeal enhancement, ventriculomegally, and punctate areas of enhancement within the cerebral and cerebellar hemispheres on post-gadolinium enhancement T1 signals.^{60,119,120} There is often enhancement of the pia mater however the dura mater is generally unaffected.¹²¹ These findings appear to be

distinguishable from those of cerebral cysticercosis, toxoplasmosis and paragonimiasis in humans. Occasionally, contrast-enhancing “stick-shaped” lesions, corresponding to larvae, are evident within the spinal cord and cerebrum, particularly on FLAIR images.^{121,122}

The severity of the clinical signs is positively correlated with MRI findings, viz. the more severely affected patients have more widespread the changes with MRI.¹¹⁸ These changes can persist for up to 6 months post infection.^{118,121} In one recent report, MRI lesions were more severe 5 to 8 weeks post infection despite the stated incubation period of only 3 to 9 days.¹²¹ Lesions usually resolved within 4 to 8 weeks, but some took up to 22 weeks to resolve completely.

Computer Tomography (CT) does not appear to be useful in the diagnosis of neural angiostrongyliasis in humans.⁸⁰ CT images in patients with neural angiostrongyliasis are often unremarkable or show only non-specific changes associated with cerebral oedema or ventricular dilation.^{118,123,124} In one case report, a two-year-old boy in Hong Kong demonstrated a space-occupying lesion in the basal ganglia on CT.¹²⁴ Based on the clinical presentation of pyrexia, convulsions and unilateral facial palsy, CSF analysis and peripheral eosinophilia a presumptive diagnosis of parasitic granuloma was made. CT may be useful, along with plain radiographs, in detecting disease within the thorax.

1.12.5 Histopathology

The characteristic features of inflammation within the CNS are perivascular cuffing, gliosis and neuronal satellitosis and neuronophagia.¹ Demyelination is noted in only certain inflammatory conditions. A perivascular compartment exists around all CNS blood vessels. It is considered an extension of the subarachnoid space and contains CSF. The movement into and accumulation of leukocytes within this space is termed perivascular cuffing. While some vasculitis is always associated with perivascular cuffing, primary vasculitis tends to occur in multiple organs and there is little evidence of leukocyte migration within the CNS parenchyma.¹ The majority of cells within the cuff tend to be haematogenous in origin. The composition of the perivascular cuff can reflect the nature of the inciting agent. For example, in bacterial disease polymorphonuclear cells predominate. Fungal infections tend to induce mostly mononuclear cells especially macrophages and occasionally eosinophils. Viral diseases are mainly manifested as lymphocyte-rich cuffs. These changes may correspond to those seen within the CSF.

Gliosis is essentially an increase in the prominence of neuroglial cells (oligodendrocytes, astrocytes and microglia). This may be due to proliferation of cells or acquisition of cellular process and cytoplasmic swelling of cells already present. Gliosis implies proliferation of astrocytes by convention, however, oligodendrocytes and microglial cells may contribute. The term gliosis, when used to describe increased cellularity within CNS tissues, may include accumulations of lymphocytes as they can be difficult to distinguish from reactive glial cells.¹

Neuronal satellitosis refers specifically to the proliferation of mainly oligodendrocytes (satellite cells) around degenerating neurons. The destruction of neurons is marked by piecemeal division and phagocytosis.¹ This process leaves a dense nodule of glial cells and neuronal fragments (neuronophagia).

In rats, large numbers of larvae are present within the CNS within 12 hours of infection, although cellular infiltrates are not present for the first two weeks.¹²⁵ From 15 days onwards, eosinophils, macrophages, lymphocytes and plasma cells can be seen within the pia mater and arachnoid. There is very little inflammation associated with the living parasite in the CNS.^{2,5,23} Live larvae are usually surrounded by a few lymphocytes only. The nerve cells in the vicinity of the live larvae often show central chromatolysis, cytoplasmic axonal swelling and secondary axonal degeneration. Reaction to shed cuticle or dead larvae consists of eosinophilic infiltration with lymphocytes, monocytes, and plasma cells. There is often a zone of suppurative necrosis or granuloma formation. Occasionally foreign body giant cells are seen^{2,23}. Sometimes microcavities or small canals can be seen in cross sections of spinal cord or brain. Microscopic findings associated with these tracts include debris, plasma cells, glitter cells, eosinophils, polymorphic leukocytes and occasionally haemorrhage. The diameter of the tracts varies from 60 to 150 μm .

Radiculomyelopathies are common with neural angiostrongyliasis. In one case report, a post mortem examination of a patient revealed severe changes in the lumbar spinal cord with numerous microcavities or tracts indicating that in severe forms of the disease mechanical damage caused by migrating larvae contributes significantly to clinical disease¹²⁶. There was also evidence of periradicular or perivascular inflammation associated with the nerve roots of the spinal cord. This is certainly the case in dogs where a significant proportion of the initial clinical signs are attributable to periradiculomyelitis causing a “cauda equina-like” syndrome¹¹. Vascular changes vary from

congestion to perivascular cuffing with eosinophils to damaged blood vessels with thrombosis and extravasation into surrounding tissues²³.

1.13 Treatment

1.13.1 Glucocorticoids

Treatment of CNA remains controversial. Currently, the mainstay of treatment is administration of glucocorticoids and supportive/symptomatic care. The rationale for using glucocorticoids is that they reduce eosinophilic inflammation associated with dead or dying parasites within the CNS.⁹¹ Recommended dose rates vary from anti-inflammatory to immunosuppressive, in relation to the severity of clinical signs.^{59,126-130} In the human literature there is conflicting evidence as to the efficacy of glucocorticoids but in CNA there is a consensus that they are useful and effective.^{13,25} Recent human studies demonstrated the benefits of glucocorticoid when combined with repeated lumbar puncture to reduce CSF pressure.¹³¹ This is impractical in dogs and does not appear to be necessary in most cases.

1.13.2 Anthelmintics

The effects of various anthelmintics in mice and rats infected with *A. cantonensis* have been studied extensively by a number of authors, as the parasite is considered a useful model to examine the mode of action and efficacy of these agents.¹³²⁻¹³⁵ Most of the macrocyclic lactones (ivermectin, moxidectin, milbemycin, etc.) and benzimidazoles appear to be both larvicidal and adulticidal.¹²⁷ Repeated dosing appears to be more effective than once-off dosing.¹³⁶ The majority of these studies have indicated that dosing beyond a certain point after infection is of little benefit.^{91,127,137,138} Prophylactic dosing days or even hours before infecting appears to have no significant effects on the numbers of larvae recovered and the development of disease.^{91,135}

Information of whether anthelmintics aid or worsen the disease process in non-permissive hosts is scarce. Because the major factor in the disease is the host's reaction to dead or dying parasites it would be logical to assume that killing the parasites would worsen the disease. This would appear to be the case in dogs.¹⁴ Mason presented limited data that the use of anthelmintics worsened the disease in puppies.¹³ In some human case series, however, anthelmintics are used routinely in the treatment of neural angiostrongyliasis. In mainland China for example, a number of case reports describe the successful use of anthelmintics as in reducing the duration of the disease and alleviate clinical

signs.^{139,140} In human patients, a benzimidazole derivative, albendazole, is the anthelmintic of choice when combined with glucocorticoids to treat neural angiostrongyliasis.¹¹⁴ Albendazole kills the parasite by inhibiting glucose uptake. There are a number of characteristics that make albendazole an attractive therapeutic choice. For example over 50% of an oral dose is absorbed into circulation and a high proportion of the dose reaches the CSF.¹⁰⁵ Albendazole has been associated with significant bone marrow suppression in dogs.¹⁴¹

Isolated cases of neural angiostrongyliasis in other species have responded to anthelmintics. One of three rufous bettongs with neural angiostrongyliasis was given levamisole without improvement but also without significant deterioration compared with the two cage-mates.⁶⁶ A flying fox given fenbendazole improved, while three others treated with glucocorticoids only did not and were subsequently euthanased.¹⁹

1.13.3 Cyclosporin

Experimentally cyclosporin has been shown to have direct anti-parasitic effects in mice infected with *A. cantonensis*.¹⁴² Its usefulness in humans or dogs has not been established. Cyclosporin can enhance disease in some parasitic infections while in others it may have both immunosuppressive and anti-parasitic activity. In mice infected with *A. cantonensis*, eosinophil levels were reduced in mice treated with cyclosporin and this decrease did affect worm survival¹⁴².

1.13.4 Matrix Metalloproteinase Inhibitors

The matrix metalloproteinase (MMP) inhibitors play an important role in the migration of leukocytes and subsequent inflammation.¹¹¹ Within the CNS, MMPs play a crucial role in the disruption of the blood brain barrier and the mobilisation and recruitment of eosinophils.^{113,114} The inhibition of MMP-9 may prove a useful adjunct to established therapies for a number of inflammatory meningoencephalopathies including angiostrongyliasis.¹⁴³

A number of compounds show activity against MMP-9. Albendazole shows partial inhibition of MMP-9 activity in addition to its larvacidal activity.¹⁰⁵ In combination with another MMP inhibitor, GM6001, albendazole completely inhibits MMP-9 activity and in mice infected with *A. cantonensis* this significantly reduces both the number of larvae within the CNS and the inflammation associated with them.¹¹⁴ Eosinophil counts are significantly reduced when then MMP inhibitors are

used.¹¹³ Doxycycline, a readily available tetracycline antibiotic, has also been shown to inhibit MMP-9 activity and may be of benefit when treating CNA.¹⁴³

1.13.5 Supportive and Symptomatic Therapy

Analgesia is required for most cases of CNA. Due to the severity of the hyperaesthesia in many canine patients opioids are indicated.¹⁴ Supportive care is important for severely affected cases.¹⁴ Manual evacuation of the urinary bladder, padded bedding, and intravenous fluids are examples of supportive care aimed at reducing the impact of secondary processes. Recently a chronic pain syndrome has been observed in human patients subsequent to neural angiostrongyliasis.^{144,145}

1.13.6 Antibiotics

Use of empirical antibiotics may be indicated as bacteria can be translocated with the parasite as it migrates through the host tissues especially in the setting of immunosuppressive doses of glucocorticoids. The bacteria would most likely be part of the normal gut flora of the infected host. This phenomenon has been described with other Strongyloides including *Aelurostrongylus abstrusus*.^{146,147} The use of a broad-spectrum antibiotic such as doxycycline could be justified on these grounds, and also on the basis of its MMP-9 inhibitory action.

1.14 Acquired Immunity

On average most naturally infected rats contain 9 to 10 adult parasites.¹⁰ The number of infective 3rd stage larvae within an intermediate host varies with species and size, however even small molluscs like *Agriolimax laevis*, an introduced species of slug found throughout Eastern Australia, may contain over 200 larvae.⁵ These slugs are small enough to be consumed in their entirety by a rat and consequently a lethal dose would easily be ingested¹⁰ Therefore, it would seem likely that the definitive host must acquire some immunity to prevent cumulative infection. Acquired immunity has been documented in rats however such immunity may not be sufficient to prevent infection in the face of large challenges, despite significant retardation of development.⁴⁷ With subsequent infections the number of established adults within the pulmonary arteries diminishes.¹⁴⁸

It has been shown experimentally that rats immunised with immune serum demonstrate resistance to infection, as evidenced by decreased numbers of parasites at necropsy and retardation of development.¹⁴⁹ Despite acquired immunity developed in infected rats, *A cantonensis* is a long-lived parasite and adults can reside within the pulmonary arteries for over a year.¹⁵⁰ This apparent immunotolerance to established infections may be due to the adult parasite's ability to avoid the host's defences or as a consequence of the immunity itself. For example, the level of protection is much higher when rats are inoculated with immune serum compared to those inoculated with sensitised lymphoid tissue. In fact, concomitant inoculation with sensitised lymph tissue decreased the efficacy of immune serum.¹⁵¹ This effect is thought to be due to either sensitised lymphocytes sequestering the antibodies, or negative feedback inhibiting host lymphocyte proliferation. It is also possible that *A cantonensis* reacts with antibodies that the sensitised lymphocytes are unable to recognise, enhancing the survival of the parasite by preventing other antibodies from binding.¹⁵¹

Splenectomy has been shown to decrease the hosts ability to mount an immune response to a number of parasites and this is the case with *A cantonensis* in rats and mice.¹⁵² Conversely, rats given sensitised splenic lymphoid tissue demonstrated passive immunity to infection with *A cantonensis*, establishing the spleens protective role. The number of cells injected and the timing of inoculation significantly affected the level of immunity and subsequent antibody response to challenge infections.¹⁵²

Immunisation with a specific antigen has also shown the immunoenhancing effects in rats. Dharmkrong-At & Sirisinha immunised rats with 3rd stage larval somatic and metabolic antigens as well as female adult antigens.⁸⁶ Immunised rats were subsequently challenged with lethal doses of 3rd stage larvae (300 larvae). Of the three groups, only rats inoculated with 3rd stage antigens demonstrated improved survival times and of the two antigens, 3rd stage somatic antigens afforded the best protection. This was due to the different types of immunity produced by the antigens. Rats immunised with 3rd stage antigens were able to prevent most larvae from penetrating the gastrointestinal tract, although larvae that were able to migrate went on to develop into normal adults within the CNS and establish patent infections. Rats immunised with adult female antigens had significantly more larvae present but they demonstrated retarded growth and many did not migrate to the lungs. IgA has been established as the most important immunoglobulin in gastrointestinal infections. The authors suggest that with *A cantonensis* infections, IgA may be prevent larvae from penetrating the gastrointestinal tract and may also cross react with the 1st stage larvae, inactivating them.

Rabbits reinfected 3 weeks after an initial infection developed severe myositis, with very little evidence of CNS involvement.⁴⁵ Clinically, these animals did poorly despite the lack of CNS dysfunction and were unable to feed. In captive animals reinfection seems to occur readily. In captive tamarins, for example, the immunity is short lived. Three of 5 cases reported in the literature improved clinically over the initial 6 months only to be reinfected and die within 12 months.⁶⁵

1.15 Serology

For many parasitic infections diagnosis is reached by demonstrating the parasite within the host's faeces, blood or sputum. There are a number of parasites where this is difficult to achieve and it is in the diagnosis of these diseases that serology plays the greatest role.

The early studies of the host immune reaction to *A. cantonensis* began with intradermal testing.¹⁵³ In 1962 Alicata & Brown injected a small quantity of powdered adult antigen suspended in sterile saline into patients suspected of having neural angiostrongyliasis. While negative results were considered significant, there were a number of negative control patients who reacted. Further work by Kagan & Zaiman in 1964 confirmed that cross reaction with other helminths was a significant problem with this test.¹⁵⁴ Indirect haemagglutination was used by Kamiya in 1970 to study the course of antibody production in rats infected with *A. cantonensis* but levels were very low for the first 10 weeks.¹⁵⁵ Other serological tests included indirect fluorescent antibody staining of frozen sections of larval and adult *A. cantonensis*, indirect fluorescent antibody staining of lipid-free adult homogenates and agglutination of crude adult antigens bound to latex.^{156,157}

Unfortunately, most of these tests proved unreliable or inappropriate for the diagnosis of neural angiostrongyliasis in the clinical setting. For example, an indirect agglutination test first used in 1975, was discontinued when it was found that rats only became positive once the female *A. cantonensis* adults began producing eggs. Since infections do not become patent in humans the test was of no value.¹⁵⁸ Gel diffusion and complement fixation antibody detection tests were also evaluated but found to be insufficiently sensitive¹⁵⁶. Cell-mediated immunity testing (CMIT) had been used to aid the diagnosis of neural angiostrongyliasis in five Brisbane patients but epidemiological studies revealed significant cross reactivity.^{156,159}

Enzyme-Linked Immunosorbent Assay (ELISA) was first used by Cross in 1978 and was based on a crude 4th stage larval antigen.¹⁵⁸ ELISA, like indirect fluorescent antibody staining (IFAS), have the advantage of detecting specific antibodies bound to the surface of an antigen.

1.15.1 ELISA

ELISA refers to an immunoassay where a signal is produced by an enzyme and its reaction with a reporter substrate. ELISAs can be made that detect antibodies, antigens or antibody-antigen complexes. The process typically involves binding an antigen or antibody to a solid state, for example a plastic well or cellulose membrane and adding the substance containing the analyte (substance to be measured). Once the primary antibody-antigen reaction has taken place a conjugate (enzyme-linked detection system) is added to detect the primary antigen-antibody reaction. Finally, a reporter substance is added which changes the colour of the system. This is measured quantitatively, for example, as an optical density. A titre is defined as the reciprocal of the highest dilution of a sample giving a predefined positive reaction.

ELISAs can be made to detect not only antibodies to a specific antigen but also for the detection of a specific class of antibody. In dogs, IgM is produced first and levels tend to decline rapidly. IgG is produced soon after IgM and is present for much longer periods of time. Consequently, a rising IgM titre is indicative of recent or active infection, while a high IgG titre suggests chronic exposure to an antigen.¹⁶⁰ There can be significant variation in IgG and IgM responses between animals. Therefore, the magnitude of an antibody response does not necessarily reflect whether the antigen exposure was, or was not, recent. Documentation of a rise in specific antibody classes, however, does tend to suggest recent exposure.¹⁶⁰

The ELISAs usefulness as a diagnostic test is determined by its sensitivity (the ability of the assay to detect true positives) and its specificity (the ability of the assay to detect true negatives). The analytical sensitivity defines the minimum detectable amount of the analyte that can be accurately measured. The analytical specificity defines whether the substance detected cross-reacts with other substances.¹⁶⁰

- The diagnostic sensitivity of an ELISA for *A. cantonensis* is the proportion of positive test results from known infected animals.
- The diagnostic specificity of such an assay would be the proportion of negative results in animals known to be free of the disease.

1.15.2 ELISA History

Cross first used an ELISA in 1978 for the detection of serum antibodies in suspected human cases of neural angiostrongyliasis.¹⁶¹ Further studies were carried out in 1982 and the specificity was shown to be high despite cross-reaction with other helminths and protozoa.¹⁵⁸ In a report of 116 suspected cases in Thailand, 96% of samples taken at the time of presentation were positive using the same ELISA technique.⁵⁸ Paired sera from some patients demonstrated a rise in antibody titre over the period from acute onset of clinical signs to convalescence. Chen (1986) using the same ELISA technique, demonstrated that titres were significantly elevated in rats as early as 3 weeks post infection.¹⁶² Titres continue to rise over the following 23 weeks. Comparing juvenile antigen to adult antigen extracts, it was demonstrated that rats reacted more strongly with adult antigen extracts. Importantly, cross-reaction with *Toxocaris canis* was high. Chen also tested human sera from suspected neural angiostrongyliasis patients, comparing them to negative controls. He found that humans, like rats reacted most strongly with a ‘purified’ adult antigen but results again showed strong cross reaction with *T canis* antigens in all suspected cases. Serum titres were higher than CSF titres.

Chang compared the somatic (surface) antigens of 3rd stage, 4th stage, juvenile and adult stage larvae in rats.¹⁶³ A rise in antibody titres directed against the juvenile and adult antigens 31 days post infection was demonstrated, similar to Chen’s results. More importantly, an immunological reaction to 3rd and 4th stage larvae could be appreciated as early as 9 days post infection.

1.15.3 Antigens

Antigens from a parasite can be divided into two broad categories: (i) excretory or metabolic antigens relating to waste products, mucus, etc produced by the parasite, and (ii) somatic antigens which represent the parasite itself, e.g. the cuticle. Different life stages of any parasite will have antigens specific for it as well as those antigens that are conserved throughout the life cycle. It would be logical to assume that in order to detect antibodies in a patient’s serum, antigens from the corresponding life stage of the parasite should be used.¹⁵⁸ This is, in part due to certain life stages producing more reaction than others and partly due to the fact that, within certain hosts, *A cantonensis* will not reach adulthood. In dogs, for example, there is very little reaction to the 3rd stage larvae and the majority of larvae do not develop into adults.^{11,14}

As with most parasites, there are a number of antigens that are conserved throughout all life stages. It is therefore unnecessary to obtain the specific larval stage when producing an antigen, crude or otherwise.

While crude and partially purified antigen extracts have been used successfully to identify antibodies to *A cantonensis*, specific antigens are more precise at detecting the relevant antibodies.^{162,165,166} This is in part due to cross reaction with other helminth parasites, as well as whole worm extracts being contaminated with components of the original hosts.¹⁶⁷ The antigens of *A cantonensis* have been well characterised and Dharmkrongat was able to demonstrate the conserved nature of antigens from various stage of *A cantonensis*.¹⁶⁴ Excretory antigens, while detectable, tend to produce insufficient immunoreactions in animals.^{86,162,164} In humans, there appear to be several useful antigens including a 29 kDa antigen, a 31 kDa antigen and a 204 kDa antigen.¹⁶⁸ The 31 kDa appears to be conserved through the 1st, 3rd and female adult stages of *A cantonensis*.¹⁶⁴ In humans, this antigen is highly immunogenic and relatively specific.¹⁶⁹ Unfortunately, there is significant variation in the number and identity of antigens recognised by hosts.⁴ For example, rats demonstrate immunisation against larger molecular weight antigens that are not recognised by human patients suspected of having neural angiostrongyliasis.

Obtaining specific, purified antigens can be difficult. One obstacle when working with parasites is obtaining substantial working quantities of parasitic material for serodiagnosis.¹⁶⁶ This is due to the large number of experimental animals used and the difficulty in harvesting small larvae.¹⁷⁰ Antigens can be more easily obtained using monoclonal antibodies to select out the antigen or immunoelectrotransfer.^{167,171}

While the 31kDa and 29 kDa antigens show promise, corresponding ELISAs are not yet suitable for clinical use. ELISAs based on these antigens in humans have a sensitivity of 100% however the specificity is poor (83% to 67%).¹⁷¹ The 204kDa has been used in a number of published studies with good results.¹⁶⁷ Further refinements have been made and one such example is the detection of specific subclasses of IgG using the 29kDa antigen.^{104,165,171} Currently there are no in-house testing kits available commercially in Australia.

1.15.4 Shared Antigens

There have been a number of reports detailing the “sharing” of antigens between a parasite and its intermediate host.¹⁷⁵ This may represent an alternate source of antigen for the use in ELISAs. For example, *Biomphalaria glabrata*, a species of small snail found in Thailand, has several antigens that are shared with *A. cantonensis*.¹⁷⁵ In particular a 24 kDa and a 48kDa antigen that do not cross react with other parasitic infections. Large amounts of antigen can be more readily and safely produced from these gastropods. Consequently, they may be a more satisfactory source of antigens when attempting to detect the presence of host antibodies.

1.15.5 Monoclonal Antibodies

Purification of specific antigens is a difficult and expensive process. The most common method is column chromatography which is especially time-consuming.¹⁷⁶ An alternative approach is to use monoclonal antibodies directed against specific *A. cantonensis* antigens. The techniques involved in the production of monoclonal antibodies are well known and have been described elsewhere. Briefly, mice are immunised with the chosen antigen. Depending on the antibody required the mice are bled and have their spleens harvested to obtain the antibody producing B-cells. These cells are then fused with murine myeloma cells. Once the integrity of the newly fused hybridoma cell line has been established they are either inoculated into new mice via intraperitoneal injection or incubated in special media. The subsequent supernatant containing the monoclonal antibody is then harvested and evaluated using an appropriate ELISA.^{170,177}

The resulting monoclonal antibodies can then be used to purify antigens in preparation for an ELISA or used directly, after labelling, to detect circulating antigen within a sample. Detecting circulating antigen may be of more benefit as it should precede the immune response and therefore be detectable earlier on in the course of the disease.¹⁷⁸ Circulating antigen levels should also diminish once the parasite has been cleared from the host, which would reduce the likelihood of cross-reactions and false positives. Because of the monoclonal antibody’s high specificity, some sensitivity is lost.^{178,179}

To date, there have been promising studies involving monoclonal antibodies directed against a 3rd stage 91kDa antigen¹⁷⁸ and a female adult 204kDa antigen.¹⁸⁰ These studies have indicated higher levels of antigen within the CSF of human patients compared to serum. Consequently, the sensitivity of the assay using CSF is higher. Sensitivity can also be increased by using two monoclonal antibodies

directed against each specific antigen.¹⁸⁰ The 3rd stage 91kDa antigen may be of little clinical use as the majority of larvae recovered from the CNS of patients are 4th stage or juvenile adults.

Further refinements have improved the sensitivity of ELISAs using monoclonal antibodies. These include Dot-Blot ELISA and Immuno-PCR. Dot-Blot ELISA is a method which involves the use of nitrocellulose which can bind 1000 times more proteins per surface area than a microtitre plate. It therefore allows the detections of less abundant antigens. Use of this technique combined with monoclonal antibodies has shown encouraging results although the sensitivity is still less than that of antigen-based ELISAs.¹⁸¹ In Thailand a Dot-Blot ELISA test kit based on the 31kDa has shown excellent preliminary results.¹⁷²⁻¹⁷⁴ Immuno-PCR involves the labelling of an antibody with a DNA reporter rather than an enzyme. The DNA can then be amplified using standard PCR techniques. An Immuno-PCR using monoclonal antibodies against the female adult 204kDa antigen has been used successfully with a sensitivity in serum of 98 to 100%.¹⁷⁶

1.15.6 Immunology

A number of classes of antibody are produced by animals. IgM tends to be produced first, but levels fall quickly. IgG is produced soon after IgM and levels tend to be maintained for long periods of time. IgE appears to be produced in association with helminth infections.⁸⁷ IgA is thought to play an important role in preventing gastrointestinal parasitic infections because it is secreted as a dimer at epithelial sites such as the intestinal wall.⁸⁶

Antibody production in rats is detectable as early as one week post infection, although the detection of the immune response varies according to the antigen and the technique used.⁴⁷ Antibodies can be detected by indirect agglutination antibodies as early as 35 days post infection with a peak around 50 days, persisting up to 145 days post infection.¹⁵⁵ Precipitating antibodies can be detected as early as one week post infection and reagenic antibodies 2 weeks post infection.¹⁸² With ELISA, antibodies to 3rd and 4th stage larvae are detected first at 9 days, followed by adult antigens 2 weeks later.¹⁶³

Within the rat CNS there is no cellular infiltration for the first two weeks. It is not until day 15 that plasma cells producing IgM and IgG are evident and antibodies against *A cantonensis* can be

detected in the CSF.¹²⁵ In both rats and monkeys, antibodies appear in the CSF before they are detectable in serum.¹²⁵

In rats, the most significant lymphoid response occurs during the 4th week post infection and is centred on the cervical lymph nodes.⁴⁷ This corresponds to the time in which the majority of the parasites are within the CNS. Consequently, antibodies to 3rd stage larvae are most prevalent.¹⁸³ Antibodies to specific life-stage antigens all increase initially, however after the 4th week antibodies against 3rd stage larvae begin to decline.¹⁸³ The lymphoid response subsequently tends to decline, indicating that the CNS phase of the infection is the most immunogenic⁴⁷. A poor lymphoid response during the pulmonary phase is advantageous to the parasite as it can evade the host's defences within the lungs for long periods of time while producing eggs. Regardless of the stage of the infection, the antibody response is proportional to the number of larvae infecting the host.¹⁴⁹

As with most antibody-based ELISA tests for parasitic infections of the CNS, detection of antibodies in CSF appears to be more specific for the parasite, but less sensitive than detecting antibodies in the serum. The same is true for cysticercosis¹⁸⁴. This may be attributable to the parasite not persisting in the circulation once it has produced disease, or it could be due to the low protein levels within CSF^{178,185} as low protein levels are indicative of low immunoglobulin levels and subsequently more antigen may be available to react in the CSF where as within the blood it is eliminated as circulating immuno-complexes.

A case series of 48 patients with suspected neural angiostrongyliasis demonstrated increased levels of IgM, IgG, IgA, and IgE with the highest levels of each immunoglobulin present within the serum.¹⁸⁵ This contributed to an increased sensitivity with serum compared to CSF on ELISA. The report compared the specificity and sensitivity of crude adult and juvenile antigens and found them to be similar.

In some of the more severe cases of human neural angiostrongyliasis ELISA results have been equivocal. The authors suggest that in these severe cases there is a heavy antigen burden within the patient, which could decrease the level of circulating antibodies hence the ELISA results.^{126,144}

1.16 Differential Diagnosis

There are a number of conditions in young dogs leading to progressive neurological dysfunction. While neural angiostrongyliasis is the most common cause of eosinophilic meningoencephalitis in human patients this may not be true in dogs. Detailed below are a number of conditions that can mimic the progressive neurological findings associated with CNA. Of these, neosporosis is the most important differential diagnosis for *A cantonensis* owing to overlapping clinical features, devastating sequelae and juxtaposed treatment regimen.

1.16.1 Parasitic Infections

1.16.1.1 Neosporosis

Neospora caninum is a member of the Apicomplexa group of protozoa. The disease it produces is the most significant differential diagnosis for canine neural angiostrongyliasis in young dogs. The parasite was definitively described in detail by Dubey, et al. in 1988¹⁸⁶ although its presence first established in 1984¹⁸⁶. *N caninum* is considered the type species although another species, *N hughesi* has been recently described in horses¹⁸⁷⁻¹⁸⁹.

While the complete life cycle of this parasite is yet to be characterised it would appear that the dog is the definitive host and that the main route of infection is transplacental.¹⁸⁹⁻¹⁹² Intermediate hosts include cattle, goats, deer and sheep¹⁸⁷. Experimentally, cats, mice, pigs, rats, gerbils, foxes and monkeys have been infected¹⁸⁹. The prepatent period in dogs is 6 to 8 days and sporulation occurs within 24 hours.^{189,192} Dogs infected experimentally continue to shed oocysts up to 19 days post infection although in naturally infected dogs shedding may occur over a longer period.¹⁹³ None of the dogs shedding oocysts showed clinical signs relating to the enteroepithelial cycle of neosporosis.

Naturally occurring infections in clinically healthy dogs occur throughout the world and the seroprevalence ranges from 0.2% to 29%.^{189,190,194} In Australia, the prevalence is estimated at 9%¹⁸⁹. The dog remains the only canid to demonstrate oocyst shedding however antibodies to *N caninum* have been found in red foxes (*Vulpus vulpes*), grey foxes (*Urocyon cinereoargenteus*), American coyotes (*Canis latrans*) and dingos (*Canis dingo*).¹⁸⁸

Presumably the parasite has a similar life cycle to *T gondii* and there are two distinct phases: an enteroepithelial phase occurring only in definitive hosts and an extraintestinal phase occurring in intermediate hosts. The details of the two phases are discussed in the section concerning *T gondii*. Transmission can occur via oral or parental routes in dogs, however transplacental (congenital) infection appears to be the most significant route in naturally occurring cases.¹⁹⁰ More recent epidemiological studies suggest that the feeding of raw bovine meat may significantly contribute to the spread of the disease in dogs.¹⁹⁴ Unlike toxoplasmosis, the disease does not appear to be related to underlying immunocompromise although an over-representation of certain breeds, especially Boxers and Golden Retrievers, to symptomatic neosporosis may reflect an underlying genetic predisposition related to immune competence.

In the acute stages of the extraintestinal phase tachyzoites can be found within any tissue but appear to have a propensity for muscle, CNS and to a lesser extent skin. Tachyzoites and tissue cysts resemble those of *Toxoplasma gondii* under a light microscope but unlike *T gondii*, tissue cysts are generally found only within neural tissues and have a much thicker cyst wall.^{189,190} *N caninum* and *T gondii* have ultrastructural differences, which can be appreciated with the electron microscope.

While the bradyzoites represent the persistent, quiescent stage of any infection, the tachyzoites are the rapidly multiplying stage responsible for the majority of lesions. They trigger lesions by multiplying within a host cell until it ruptures. No parasite-derived toxins have been identified. In the absence of host immunity, tachyzoites continue to multiply, progressively destroying more cells until the host dies.¹⁸⁸ If host immunity is sufficient, tachyzoites differentiate into bradyzoites and encyst. There is little host reaction associated with the tissue cysts.¹⁸⁹

The most significant manifestation of neosporosis in infected cattle is abortion, however in dogs abortion has not been reported.¹⁹⁰ The most common form of symptomatic disease in dogs is ascending paralysis of the limbs in puppies under 6 months of age, although dogs of any age can develop muscular or neurological disease.¹⁸⁸ Although no breed or sex predilection has been established, definitively, most described cases have been Boxers, Labradors, Golden Retrievers, Greyhounds and Basset hounds.¹⁸⁸

Characteristically, infected puppies tend to have neurogenic muscle atrophy, particularly in the hind limbs, due to lower motor neuron damage and myositis. Early in the disease process, they display

lower motor neuron signs, with hyporeflexia and reduced muscle tone. Some dogs may present with hyperaesthesia attributable to myalgia, although generally this is less a feature than in CNA. In severely affected dogs this will progress to irreversible genu recurvatum following fibrous contracture of the quadriceps and gracilis muscles. Cervical weakness, dysphagia and death eventually follow.¹⁹⁰ In mature dogs, multifocal CNS disease, that is often only mild, and/or generalised polymyositis occur. Occasionally myocarditis, dermatitis and pneumonia are seen.^{188,190} Experimental studies have demonstrated that *N caninum* can cause early fetal death, mummification, resorption and the birth of weak puppies.¹⁸⁷

Diagnosis is based on determination of elevated antibody levels in serum using indirect fluorescent antibody titres (IFAT), which tend to rise 1 to 2 weeks after infection. Threshold levels vary between laboratories although in general titres over 1:800 suggest active infection. CSF antibody titres tend to be less.¹⁸⁹ False positives do occur, in one study high titres (1:12,800) persisted in 2 dogs for over 4 years.¹⁸⁹ Recently a multiplex PCR has been developed and used on CSF, frozen muscle and paraffin-embedded tissues samples.¹⁹⁵ It is interesting to note that dogs may not seroconvert when infected and yet still produce oocysts.¹⁹² Serologically, *N caninum* can be distinguished from *T gondii*.¹⁹⁰ Detection of tachyzoites provides the definitive diagnosis of the disease. CSF or muscle biopsies provide suitable specimens for analysis however immuno-histochemistry must be used to distinguish *N caninum* tachyzoites from *T gondii*. PCR may eventually prove superior to histology and serology for diagnostic purposes.

Pyrimethamine, sulfadiazine and clindamycin appear to be the most effective drugs for treating neosporosis and prognosis improves the sooner that treatment is initiated. Administration of glucocorticoids causes marked disease acceleration and it can be difficult to “rescue” such cases. Clinical improvement in the face of muscle contracture is unlikely, although the disease is arrested. All puppies in an affected litter should be treated once the diagnosis is made. It may also be beneficial to treat the bitch. Subclinically, infected bitches can transmit the parasite to successive litters, indicating probable reactivation of a sequestered infection.¹⁸⁹ At present there is no treatment for preventing oocyst shedding or vertical transmission in dogs.¹⁸⁹ A vaccine against a surface protein of *N caninum* is currently being investigated for its efficacy in preventing disease and oocyst shedding in dogs.¹⁹⁶

1.16.1.2 Toxoplasmosis

Toxoplasmosis can occur in any mammalian species. Felidae are the definitive hosts for *Toxoplasma gondii* and most warm-blooded animals, including dogs and humans, are considered intermediate hosts.¹⁹⁰ There are several modes of infection but the most common are congenital infections, ingestion of infected tissues and ingestion of oocysts via contaminated food or water.¹⁹⁰ This intracellular coccidian parasite has two distinct life-cycle phases; an enteroepithelial phase that only occurs in the definitive host, and an extraintestinal phase that occurs in any host.

The extraintestinal phase begins with ingestion of sporulated (infective) oocysts. The oocysts release their sporozoites, which penetrate the cells lining the small intestine and asexually divide to become tachyzoites. Tachyzoites can infect and multiply in any cell within the host's body. It is this prolific multiplication and subsequent necrosis of infected cells that leads to the clinical symptoms seen in toxoplasmosis. Tachyzoites do not produce a toxin but if the infected host cell ruptures, then they will infect any nearby cells.¹⁹⁰ After an undetermined period of time, tachyzoites encyst within the cells and become bradyzoites. Bradyzoite cysts are able to survive the hostile environment of the stomach. Tissue cysts can form in any tissue, particularly the CNS, selected muscles and visceral organs, where they may persist for the life of the host.

The clinical outcome of any infection with *T. gondii* is dependent on the extent of the injury sustained by the host's organs, especially vital structures like the heart and lungs. In dogs, the neurological form can be seen in isolation and made last for several weeks.^{190,195} In the past, toxoplasmosis was often associated with distemper, while today the underlying aetiology is likely to be some sort of immunosuppression.¹⁹⁰ The clinical signs of neural toxoplasmosis depend on the areas of the CNS affected, ranging from seizures and tremors to paralysis. Diagnosis is difficult and tends to be based on demonstrating a rising antibody titre over a 2 to 3 week period. A significant proportion of the population, whether it is canine or human, has antibodies to *T. gondii* present without clinical signs consistent with prior subclinical infection.^{190,195} Recently a multiplex PCR assay has shown promise in the detection of *T. gondii* DNA in various fluid and tissue samples.¹⁹⁵ Changes in CSF tend to be non-specific although eosinophilic pleocytosis has been documented in humans and dogs.^{197,198} Definitive diagnosis is obtained by visualising the parasite from biopsy or necropsy samples or by organism detection: inoculation of cell cultures or naive mice with homogenised suspensions of tissue samples and detection of antibodies to *T. gondii*.¹⁹⁰ In general, these methods are impractical for CNS disease

as the parasite is rarely seen in CSF samples, being limited to parenchyma of the brain or spinal cord¹⁹⁵.

Treatment is similar to neosporosis. Clindamycin, pyrimethamine and sulfadiazine are the drugs of choice. Signs tend to improve within 48 hours of commencing treatment but as with many CNS diseases, recovery may not be complete as some damage to the CNS may be irreparable. Alternative antibiotics strategies include combinations of rapid acting sulfonamides and pyrimethamine, tetracyclines (doxycycline and minocycline) and the newer macrolides (clarithromycin and azithromycin)¹⁹⁰.

1.16.1.3 Cysticercosis

Cysticercosis is the most common parasitic disease of the CNS in humans.¹⁸⁴ Caused by the pig tapeworm, *Taenia solium*, it is endemic to most of the developing world and although it is not present in Australian pigs, the disease is still reported in travellers returning from endemic areas or immigrants. Although humans are the definitive host and acquire infection from eating undercooked pork, they can also act as intermediate host when ova are ingested from human faeces. Similarly dogs can acquire infection from ingestion of human faeces.¹⁹⁹ Once ingested, ova hatch and migrate to various tissues particularly muscle and brain, where they encyst. Cysts can persist for 10 to 20 years and may in themselves cause seizures, although it is generally felt that clinical signs develop when cysts “die” owing to the subsequent inflammatory reaction.¹⁸⁴

1.16.1.4 Schistosomiasis

Schistosomiasis is caused by trematodes from a variety of species. Ova are excreted in urine and faeces of definitive hosts and hatch in water. The miracidia enter molluscs, the intermediate host. After maturation within the mollusc, free-swimming cercariae are released into the surrounding aquatic environment and penetrate the host through the skin before migrating to the liver and lungs. After further development, the parasite migrates back to the venous plexi of the GIT or bladder and produce ova.¹⁸⁴ There are several species, none of which are endemic to Australia. In endemic areas, dogs are considered definitive hosts for most of the pathogenic species although the occurrence of EME has not been reported.^{200,201}

1.16.1.5 Gnathostomiasis

Gnathostoma spinigerum is a parasite of mammalian carnivores, particularly dogs and cats, and is endemic throughout much of the world.^{184,202,203} The mature adults reside within a tumour embedded within the gastric mucosa of the definitive host. Ova are excreted in the faeces, mature in fresh water and enter a crustacean intermediate host; freshwater copepods (cyclops), before being ingested by a freshwater fish as the secondary intermediate host. Larvae invade through the intestines to encyst in the tissue of the fish. Definitive hosts eat infected fish and the larvae migrate through various tissues of the host before returning to the gastric mucosa.¹⁸⁴ In humans, the parasite does not migrate to the gastric mucosa instead invading many tissues including the CNS causing devastating neurological disease, often with long term sequelae.¹⁸⁴

1.16.1.6 Visceral Larval Migrans

Also termed Verminous Encephalomyelitis, visceral larval migrans are a group of parasitic disease characterised by the aberrant migrations of a parasite that may or may not normally reside within that host. Examples include, *Toxocara canis* in children, *Dirofilaria immitis* in the cat and *Strongylus vulgaris* in the horse.¹ Generally the disease is associated with mechanical damage to the CNS. Species known to cause disease in dogs include *D immitis*, *T canis*, *Baylisascaris procyonis*, *A vasorum* and *Cuterebra spp.*¹

1.16.2 Idiopathic Eosinophilic Meningoencephalitis

Eosinophilic meningoencephalitis is diagnosed on the basis of observing a greater than 10 eosinophils per μL of CSF or in patients with nucleated cell counts greater than 100 cells per μL , of which more than 10% are eosinophils.⁹ The idiopathic form of the disease has been reported in a number of species, including the dog. The majority of canine cases recorded are young adult males, with a preponderance of cases in certain breeds (Golden Retrievers and Rottweilers).^{204,205,206,207}

1.16.3 Fungal Diseases

Coccidioides immitis is a soil-borne dimorphic fungus found in the Americas.¹⁰² The organism elaborates as a mycelium, giving rise to arthroconidia, the infectious propagule. Infection occurs by inhalation of arthroconidia, which form spherules in lung. Spherules mature in the presence of phagocytes and CO_2 , eventually breaking open to release endospores. Endospores invade new tissues via the blood stream and mature into spherules. Most infections are subclinical although respiratory

tract signs are occasionally seen. If the infection spreads beyond the hilar lymph nodes it is considered to be disseminated, although this generally occurs only in immunocompromised patients. From the hilar lymph nodes the infection can spread to any tissue including the skin, bones, myocardium and CNS.^{9,102} Ragland and colleagues reported 70% of human patients had eosinophilic pleocytosis.²⁰⁸ The finding of eosinophils in the CSF is an inconsistent finding in dogs with CNS coccidiomycosis.¹⁰²

CNS cryptococcosis rarely causes eosinophilic pleocytosis in humans but the condition has been described in dogs.^{9,209} The *Cryptococcus neoformans* complex refers to a saprophytic yeast found in the environment that has the ability to grow at 37°C, unlike other cryptococcal species. In tissues it produces a heteropolysaccharide capsule that confers virulence and resistance to desiccation.²⁰⁹ There are two species (*C neoformans* and *C gatti*). The exact route of infection is most likely via inhalation. Cryptococcal infections can disseminate to the CNS either haematogenously or direct extension from the nasal cavity. The CNS and the eye are sites commonly affected by *C. neoformans*²⁰⁹. Diagnosis is generally made through cytological evaluation of appropriate tissue and fluid samples. Latex agglutination tests are a useful adjunct to cytology and CSF culture.

Disseminated aspergillosis is occasionally associated with peripheral eosinophilia and in some cases with CNS involvement there is an eosinophilic pleocytosis in CSF.²¹⁰

1.16.4 Bacterial, Rickettsiae, and Viruses

A number of these infectious agents have been implicated as causes of EME in humans⁹ and more than likely the same would be seen in dogs. In humans, eosinophilic pleocytosis of the CSF has been associated with viral meningitis and Rocky Mountain Spotted Fever (*Rickettsia rickettsii*).⁹ CNS involvement with either tuberculous or rapidly-growing mycobacterial infections has been reported in dogs²¹¹. Mycobacteria appear to produce or induce eosinophilotactic factors and therefore patients with CNS involvement may demonstrate eosinophilic pleocytosis in CSF.²¹²

1.16.5 Non-infectious Agents

Neoplasia in humans such as Hodgkin's disease, non-Hodgkin's lymphoma and eosinophilic leukaemia have been associated with eosinophilic meningoencephalitis. Drugs (ciprofloxacin, vancomycin, ibuprofen and gentamicin) as well as contrast media used in myelograms have been implicated as causes of EME.⁹ In pigs, salt poisoning has been reported as a cause of EME.²¹³

Chapter 2: Materials and Methods

2.1 Retrospective Review

In order to compare cohorts of CNA cases published previously to those obtained prospectively, a literature search was undertaken. Relevant papers concerning neural angiostrongyliasis were identified by searching CAB abstracts and Medline databases using the key word “cantonensis”. Data concerning the CSF cytology, necropsy findings and serology were collated. Only cases that had CSF analysis were included in the group. In one published group of CNA cases, the author used a grading scale to divide cases into 3 groups based on the severity of clinical signs.¹⁴ Grade 1 cases were only mildly affected, Grade 2 cases progressed to involve the forelimbs and occasionally the cranial nerves and Grade 3 cases progressed rapidly to severe generalised paresis and hyperaesthesia. All Grade 3 dogs were euthanased on humane grounds.

2.2 Prospective Study

2.2.1 Controls

Samples of CSF and/or serum were collected from two groups of dogs for use as negative controls. Samples were obtained from dogs euthanased at local Sydney council pounds and used in practical demonstration classes at the UVCS during September 2005. These are described as Group A. CSF and serum samples were collected immediately after euthanasia. Once cerebrospinal fluid was obtained, serum was harvested from heart blood obtained percutaneously. A small section of the spinal cord was obtained from a region adjacent to the cisterna magna. Histopathology was used to confirm the absence of inflammation within the sections of spinal cord.

A second group of controls (Group B) consisted of client owned dogs presenting to the UVCS for reasons unrelated to possible infection with *A. cantonensis*. Serum was collected from dogs undergoing routine desexing or orthopaedic procedures at the UVCS during May 2005. None of these cases had detectable neurological dysfunction.

2.2.2 Canine Neural Angiostrongyliasis Cases

Hospital records and clinicopathological samples from dogs with suspected CNA were recruited from practices in the Sydney and Brisbane regions between January 2001 and May 2005. A letter was sent to all registered Small Animal Specialists and Veterinary Pathologists in Queensland and New South Wales regarding the intentions of this thesis and collection of samples from suspected cases of CNA (Appendix 1). Once contact was made with the referring clinician, a questionnaire was sent to gain systematic information concerning the onset of the disease, clinical presentation, its subsequent progression and any additional information such as administration of parasiticides or exposure to intermediate hosts (Appendix 1). Data including signalment, clinical presentation, clinical pathology (including necropsy findings) and treatment outcomes, were collected for each case. Cerebrospinal fluid and or serum samples were obtained where possible. All samples were stored at -80°C prior to analysis.

2.2.2.1 Case inclusion

Case inclusion was based on a presumptive diagnosis of CNA, i.e. those cases that demonstrated a progressive neurological disease. Definitive diagnosis was based on identifying *A cantonensis* larvae within the CNS at necropsy. Only cases for which CSF cytology was available were included in this study. Consequently, of 30 dogs considered initially, only 22 had CSF cytology data. Therefore, only 22 dogs were recruited into the study. None of the cases in the prospective group were confirmed at necropsy. Dogs with an atypical presentation were included only if they were positive using the ELISA and/or Western Blot on CSF samples.

2.2.2.2 Treatment

All dogs were treated with supportive care as required and glucocorticoids (prednisolone). Supportive care included opioids (for analgesia), intravenous fluid therapy, urinary catheterisation, antimicrobials and passive physiotherapy. Prednisolone dosage ranged from 0.5 to 2 mg/kg (divided daily), with tapering of the dose over an extended period, typically 6 to 12 weeks. All dogs were treated with prednisolone for a minimum of 4 weeks.

2.3 Serology

2.3.1 ELISA

All serum and CSF samples from suspected cases of CNA and positive and negative controls were tested using an ELISA developed and preformed by Rogan Lee, ICPMR, Westmead Hospital, Sydney. IgG antibodies against *A cantonensis* were detected by an indirect ELISA adapted from the method described by Cross and Chen¹⁵⁸. The methods for obtaining the adult antigen are outlined in Appendix 4 and the technique used to perform the ELISA is described below. Some samples were also tested for *A cantonensis* antibodies using Western Blot analysis as part of another project.²¹⁴

2.3.2 ELISA Technique

The extract of adult *A cantonensis* (Appendix 3) was coated onto Maxisorb plates (Nalge Nunc International, Denmark) at a concentration of 5µg/mL. Canine serum and CSF were diluted to 1:100 in Blotto (Appendix 5). Two-fold serial dilutions of the 1:100 serum or CSF specimen were made. Serum and CSF dilutions from 1:100 to 1:204,800 were tested in each assay. The secondary antibody, rabbit anti-dog IgG, conjugated to horseradish peroxidase, was added to each well a concentration of 1:1000. Primary and secondary incubation steps were carried out at 37°C for 1 hour with washes in distilled water between steps. Substrate was allowed to react for 5 minutes at room temperature and then stopped with 1M phosphoric acid. Wells were read at 450 nm using a Tecan plate reader (Tecan Asia Limited, Singapore).

2.3.2.1 Cut-off values

The titer of serially diluted serum and CSF was calculated by comparison with the optical density of three known negative controls. Serum and CSF from a necropsy-confirmed case of CNA seen at the Veterinary Teaching Hospital, University of Queensland, Brisbane, Australia was used as a positive control. Figure 1 and Figure 3 illustrate the use of the control samples to validate the ELISA. The optical density of 1 to 3 negative sera and 1 negative CSF sample were determined at a dilution of 1:100 for each batch of specimens tested using the ELISA. The same positive and negative controls were used for each batch of specimens assayed. The mean of each sample of serum or CSF respectively plus three standard deviations was considered the cut-off value above which the next

dilution of the unknown serum or CSF was considered to be positive (Figure 1.4). Based on the results, using the cut-off values as described above, key descriptive statistics were calculated.

2.3.3 Western Blot

A parallel project was conducted using some of the canine serum and CSF samples collected during this study in conjunction with serum samples obtained from macropods.²¹⁴ Western Blot analysis of antibodies to adult *A. cantonensis* antigens of various molecular weights was carried out on the samples. The technique has been described in detail elsewhere.²¹⁴ Briefly, polyacrylamide gel electrophoresis in sodium dodecyl sulphate (SDS-PAGE) was used to separate the constituent antigens within the adult *A. cantonensis* preparation. The electrophoresed proteins were then transferred to a nitrocellulose membrane (iGels®, Gradipore®, Frenchs Forest, Australia) via a semi-dry transfer technique.²¹⁵ The antigen-infused nitrocellulose membrane was then incubated overnight at room temperature with the serum or CSF sample to be tested. Following a final wash, the membrane was incubated with a secondary antibody, rabbit anti-dog IgG conjugated to horseradish peroxidase (HRP, Sigma®, St Louise, Missouri, USA) and a chromagen solution (Appendix 6) added to develop the bands.

Based on human serological studies, the 31 kDa and the 204 kDa antigens were used to determine the presence or absence of serum or CSF antibodies to *A. cantonensis*.^{167,171,174,180,216} The molecular weight of the bands was determined on each nitrocellulose strip by comparison with the migration of molecules of known molecular weight (Biorad®, Richmond, CA, USA, Promega®, Madison, WI, USA). Individual CSF samples were considered positive if there were either discrete bands or wider strips of colour at apparent molecular weights of 31 or 204 kD. The strength of the serum antibody response was subjectively measured by visualising the density of the band. The antibody response was noted as either negative (-), weakly positive (+), positive (2+) and strongly positive (3+). For purposes of this study, the positive responses were grouped together.

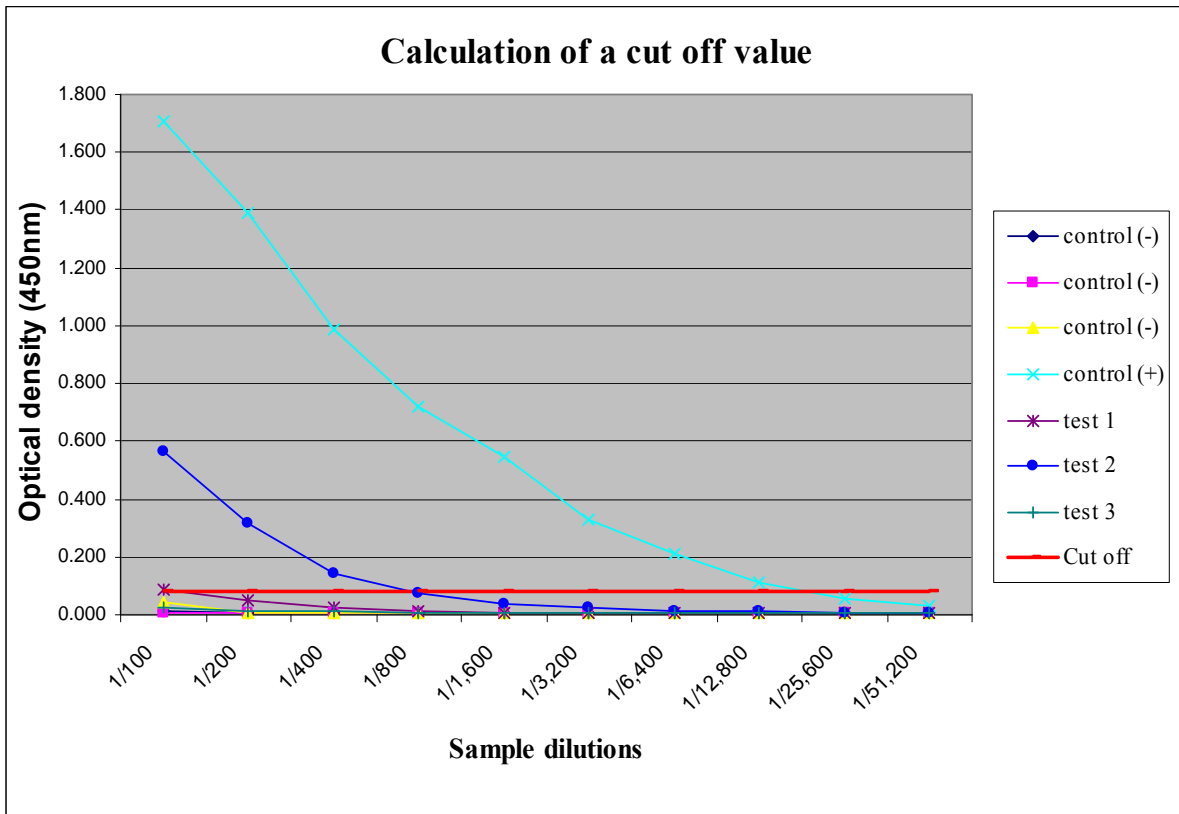


Figure 2.1: Calculation of ELISA cut-off value. The optical density of three negative control sera was determined at serum dilutions of 1:100 to 1:512,000. For example, for the dilution of 1:100 Negative control 1 = 0.011, Negative control 2 = 0.008, Negative control 3 = 0.044. The mean (M) and standard deviation (SD) of these three negative sera were calculated, viz. M = 0.021, SD = 0.02. The cut-off value was taken to be the M + 3SD, in this example 0.083, above which the sample was considered positive. Thus, an optical density value for a specimen above this value was considered positive. The antibody titres for test samples 1 and 2 were determined to be 1:100 and 1:800, respectively, but there was no titre for sample 3. Thus test sample 1 and 2 are considered positive. (Smaller, 2004)²¹⁴

Chapter 3: Results

3.1 Retrospective Study

The published literature contained descriptions of 59 dogs that could be presumed to have had naturally occurring CNA on the basis of CSF cytology, history and clinical findings, or necropsy data.^{11,14,22,25} Published case details are summarised in Appendix 4. Of the 59 naturally occurring cases, only 38 met the inclusion criteria for this study. Thirty-seven were published by Mason¹⁴ and 1 was published by Collins et al.²⁵ The median age of this retrospective cohort was 10 weeks (range 6 to 28 weeks). The month in which the cases presented is illustrated in Figures 3.2 and 3.3. Of the 38 cases, 23 had siblings affected. Breeds represented are listed in Table 3.2. Thirty-one of the cases (82%) were large or giant breed dogs and 14 (37%) were greyhounds. There were 23 males and 15 females, none of which were desexed.

3.1.1 History and Clinical Presentation

All 59 cases presented with hind limb paresis, muscle wasting, urinary bladder paresis, tail paresis and hyperaesthesia. Less common clinical signs are listed in Table 3.1.

3.1.2 Clinical Pathology

Haematology was performed on the majority of cases and the only significant finding was peripheral eosinophilia. The median eosinophil count within the CSF was 1,185 cells/ μ L (range 20 to 6,743). The median percentage of eosinophils was 81% (range 22% to 100%). These results are summarised in Figure 3.3 and Table 3.2.

	Number of dogs	Percentage (of 55 cases)
Vomiting	6	12%
Unilateral hind limb paresis	5	9%
Cranial nerve deficits	5	9%
Coma	3	6%
Diarrhoea	2	4%
Faecal incontinence	2	4%
Convulsions	1	2%
Constipation	1	2%

Table 3.1: Frequency of less common clinical signs in 55 naturally occurring CNA cases published by Mason.¹⁴

3.1.3 Treatment outcomes

All dogs received supportive care consisting of manual expression of the urinary bladder and passive range of motion exercises. Many cases received empirical antibiotic therapy. Betamethasone (1 to 2 mg/kg) was administered subcutaneously or orally for 3 to 7 days. The mortality rate was 58% (22 of 38). The initial severity of the clinical signs did not appear to be strongly associated with the eventual outcome; 9 of the 20 dogs (45%) classified as Grade 1 were euthanased, 5 of the 11 (45%) Grade 2 dogs were euthanased or died and all of the Grade 3 cases were euthanased. Only one dog received anthelmintics (Case 3 – Grade 3) and it was euthanased soon after treatment commenced. Of the remaining 16 cases that survived, at least 3 cases (Cases 2, 50 and 51) had permanent neurological deficits.

Case Identification	Breed	Age (weeks)	Gender	Month	Protein (g/L)	Nucleated Cells (cells/ μ L)	Eosinophils		Necropsy confirmed
							cells/ μ L	%	
<i>Mason^a</i>									
Case 2	Border Collie	9	M	October	0.12	4200	3696	88%	
Case 3*	Daschund	14	M	January		7125	6056	85%	No
Case 13*	Kelpie	6	F	December		3680	2760	75%	No
Case 14*	Kelpie	7	M	December		1300	1053	81%	No
Case 15*	Labrador	8	F	April		2307	2030	88%	No
Case 16*	Greyhound	10	F	July	0.43	4600	3404	74%	Yes
Case 17*	Greyhound	8	M	July		2700	1782	66%	Yes
Case 18*	Greyhound	10	M	July	1.62	7750	6743	87%	Yes
Case 19*	Greyhound	9	M	July	0.13	284	244	86%	No
Case 20*	Greyhound	10	F	May		265	98	37%	No
Case 21*	Corgi	9	F	April	2.3	1350	1053	78%	No
Case 22*	Labrador	7	M	December		90	55	61%	No
Case 27*	GSD	7	F	February		1250	1025	82%	Yes
Case 28*	GSD	7	M	February	0.2	2264	1449	64%	No
Case 29*	Greyhound	8	M	April	0.25	2812	2418	86%	No
Case 31*	Greyhound	10	F	June	0.32	1280	1139	89%	No
Case 32	Greyhound	11	F	June	0.18	3250	2633	81%	
Case 33	Greyhound	11	M	June	0.19	1465	1231	84%	
Case 34	Greyhound	11	F	June	0.23	240	226	94%	
Case 35	Labrador	11	M	April		20	20	100%	
Case 36	Afghan	11	M	June	0.43	2300	1702	74%	
Case 37	Beagle	10	M	May	0.12	83	59	71%	
Case 38*	Old English Sheepdog	9	F	July	0.4	2376	1925	81%	Yes
Case 39	Old English Sheepdog	10	M	July	0.11	7106	6680	94%	
Case 40	Old English Sheepdog	9	F	July	0.12	1197	1029	86%	
Case 41	Old English Sheepdog	9	M	July	0.12	2510	2309	92%	
Case 42	Borzoi	8	F	November		512	435	85%	
Case 43*	Daschund	12	M	October		2800	1652	59%	Yes
Case 44	Greyhound	8	M	July	0.92	700	462	66%	
Case 45*	Greyhound	10	M	May		1760	1390	79%	Yes
Case 46*	Greyhound	9	M	July	2.1	450	95	21%	Yes
Case 49	Labrador	12	F	November		406	256	63%	
Case 50	Great Dane	20	F	April	0.9	1590	350	22%	
Case 51	Great Dane	28	M	February	0.6	2750	2063	75%	
Case 52	Poodle	14	M	May	2.4	250	150	60%	
Case 53*	Weimaraner	12	F	April	0.5	490	441	90%	
Case 54*	Greyhound	16	M	May		2880	2304	80%	Yes
Collins, et al.* ^b	Bull Terrier	9	M	May	0.54	886	886	100%	Yes
	Median	10		June			1185	81%	

Table 3.2: CSF cytology results and details of Retrospective cases of CNA.

*Died or were euthanased ^aMason¹⁴ ^bCollins, et al.²⁵

3.2 Prospective Study

3.2.1 Control Groups

3.2.1.1 Control Group A

Twenty-one dogs euthanased at Sydney council pounds had samples collected for ELISA. The age of these dogs was unknown but based on physical appearance and dentition they were all likely to be under 12 months of age. All dogs were cross breeds. There were 14 males and 7 females, none of the males were desexed and the reproductive status of the females was unknown.

3.2.1.2 Control Group B

Twenty-two dogs of mixed ages and breeds had serum samples collected. There were 14 males and 7 females; 10 of the males were castrated (66.7%) and 4 of the females were speyed (57.1%). The median age of the group was 208 weeks (range 5 months to 12 years). All dogs were on heartworm (*D immitis*) prophylaxis and were regularly treated with anthelmintics for intestinal parasites. Details of Control Group B are summarised in Appendix 4.

3.2.2 Prospective CNA Cases

3.2.2.1 Signalment

Samples of serum and or CSF from 22 dogs with presumptive CNA were collected between January 2002 and May 2005. There were 8 males (4 castrated) and 14 females (7 speyed). No breed predisposition was detected, although 13 (59%) of the dogs were large breeds (Table 3.3). None of the cases had litter mates affected. The median age of cases was 28 weeks (range 8 weeks to 10 years). Sixty-four percent of cases were presented between April and July (Figures 3.1 and 3.2). Figure 3.4 shows the geographic distribution of cases that occurred in the Sydney metropolitan area suggesting that the parasite is not concentrated in one particular area.

Breeds Represented	
Cross Breed	3
Labrador Retriever	3
Boxer	2
Kelpie	2
Golden Retriever	2
Staffordshire Bull Terrier	2
Maltese	1
Cattle Dog	1
Beagle	1
British Bulldog	1
Doberman	1
German Shorthair Pointer	1
Miniature Poodle	1
Rhodesian Ridgeback	1

Table 3.3: Prospective case breeds.

3.2.2.2 History and Clinical Presentation

Only one dog (Case 5) was observed eating slugs and snails by the owner prior to presentation. The route of infection for the remaining 21 cases was not identified, but several clients mentioned that they had noticeable rat populations in the immediate area. The most common clinical signs at presentation were hyperaesthesia, ataxia and hind limb weakness followed by hyperreflexia, urinary incontinence, hyporeflexia and altered mentation. Three dogs had cranial nerve deficits characterised by lack of a menace reflex or facial twitching. These results are summarised in Tables 3.4 and 3.5. History and physical findings for each case are described in detail in Appendix 4.

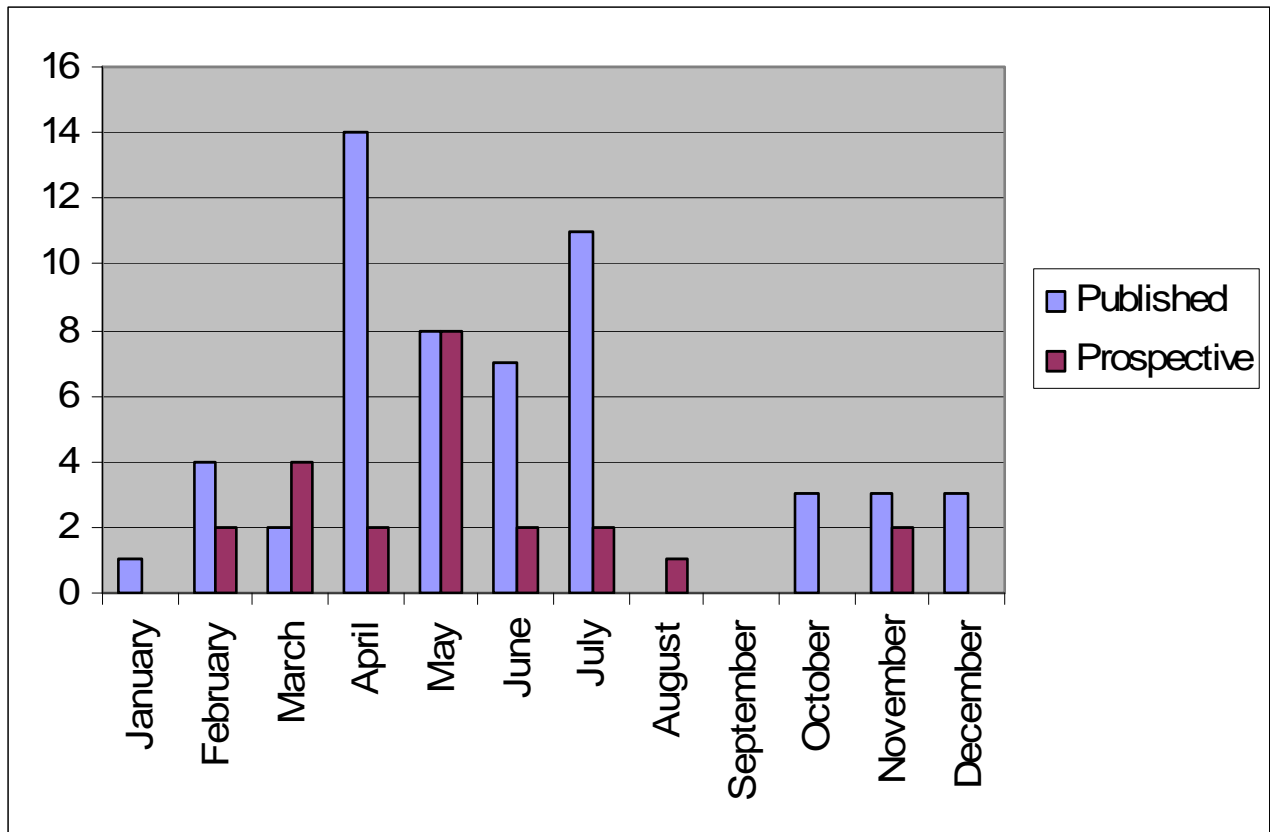


Figure 3.1: Comparison between retrospective and prospective cases as they occurred by month.

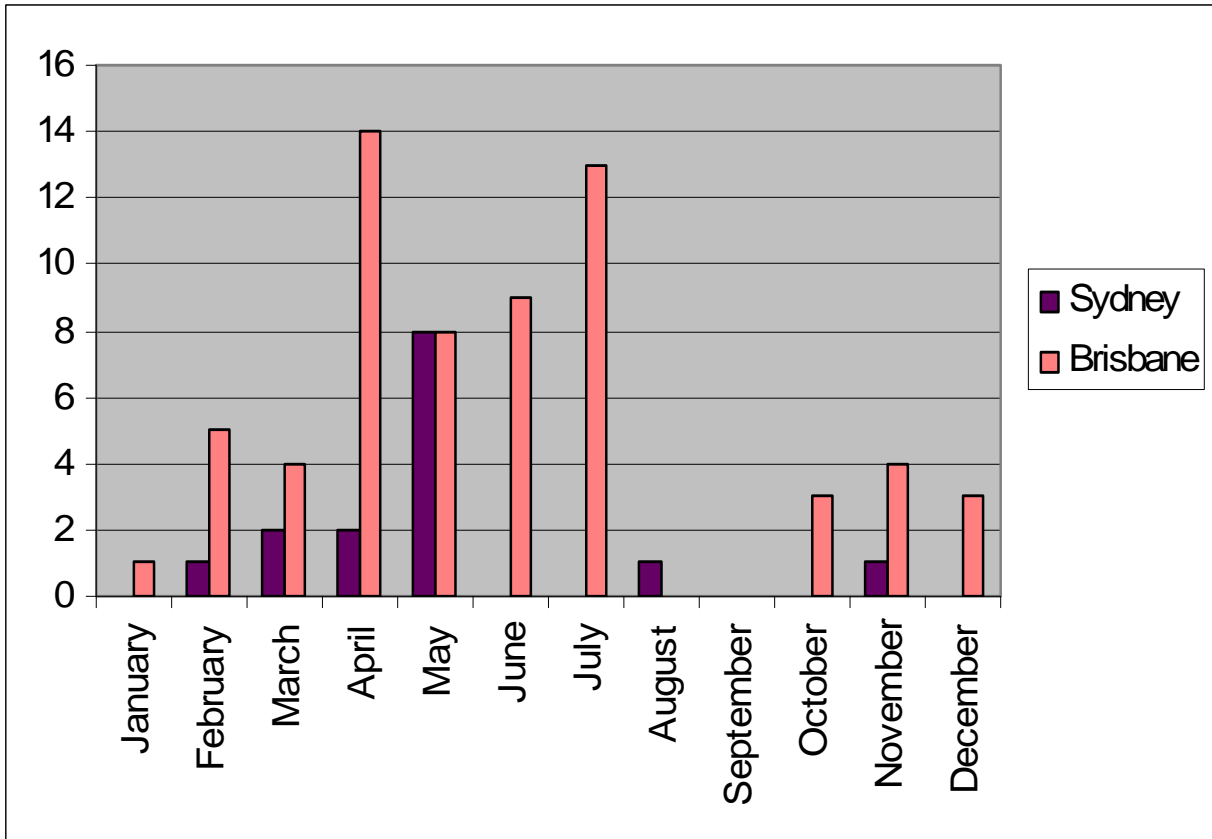


Figure 3.2: Comparison between Sydney and Brisbane cases as they occurred by month.

Clinical signs	No. of Cases	Percentage
Hyperaesthesia	14	64%
Ataxia	10	45%
Hind Limb Weakness	7	32%
Cranial Nerve Dysfunction	7	32%
Urinary Incontinence	6	27%
Ocular Signs	6	27%
Hyperreflexia	5	23%
Altered Mentation	4	18%
Muscle Atrophy	1	5%

Table 3.4: Physical findings of 22 prospective CNA cases.

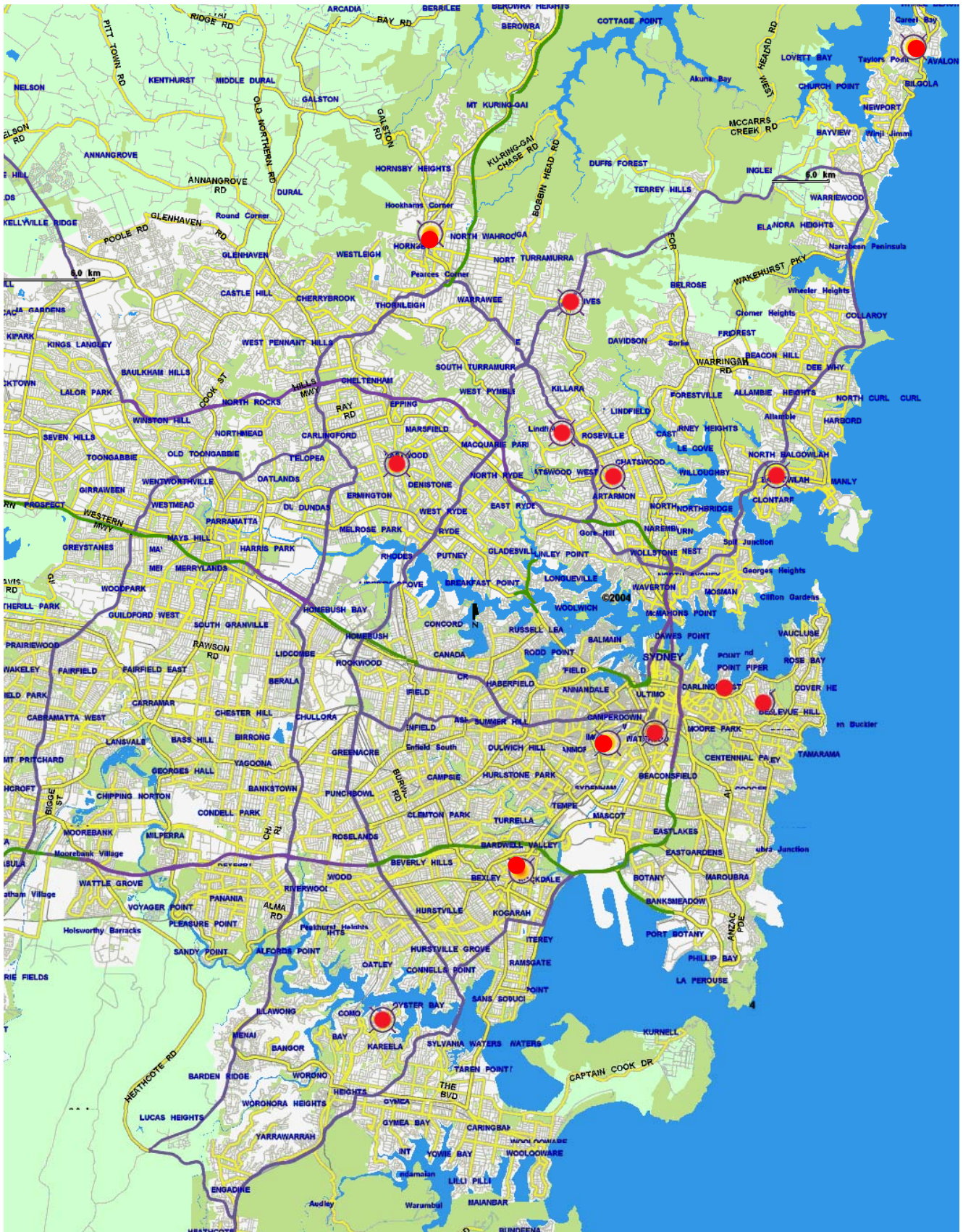

Figure 3.3: Distribution of prospective cases in the Sydney region.

3.2.2.3 Clinical Pathology

Of the 22 dogs from the prospective group, 21 demonstrated eosinophilic pleocytosis in the CSF. Samples were obtained from the cisterna magna in all cases except Cases 16 and 20, which had myelograms with CSF collected via lumbar puncture. Ten of these dogs had concurrent haematology and 8 (80%) demonstrated a peripheral eosinophilia. The median eosinophils count within the CSF was 401 cells/ μ L, while the median percentage of eosinophils was 86%. The CSF results are summarised in Table 3.5.

There were no significant biochemical abnormalities noted within the group. Cases 16 and 20 had myelograms performed, which did not reveal any significant abnormalities apart from diffuse spinal cord swelling in Case 20. Case 18 had a CT scan of the head and neck with no significant abnormalities evident.

3.2.2.4 Treatment Outcomes

The mortality rate was 3 of 22 (14%). The length of prednisolone administration varied from 4 weeks to 3 months and with the exception of four dogs (cases 13, 18, 19 and 22), all dogs rapidly improved over the initial 48 hours and made a complete recovery. Some dogs received antibiotics prior to administration of glucocorticoids. Two dogs (cases 13 and 22) were euthanased due to ongoing, unresponsive behavioural problems. Case 13 made an initial improvement but deteriorated over the subsequent 4 months and was euthanased at the owner's request due to inappropriate aggression. Case 22 was treated for 4 weeks with no improvement in its condition and the owners elected to have it euthanased due to aggressive behaviour. Case 19 had a two weeks history of anisocoria, neck pain and altered behaviour. The dog's neck pain resolved with glucocorticoids but the ocular signs progressed to blindness and owners elected to have the dog euthanased. Unfortunately none of the dogs were subject to necropsy following euthanasia. Case 18 presented with head tremors that proved unresponsive to treatment, however the dog's quality of life was adequate and the owners declined further treatment.

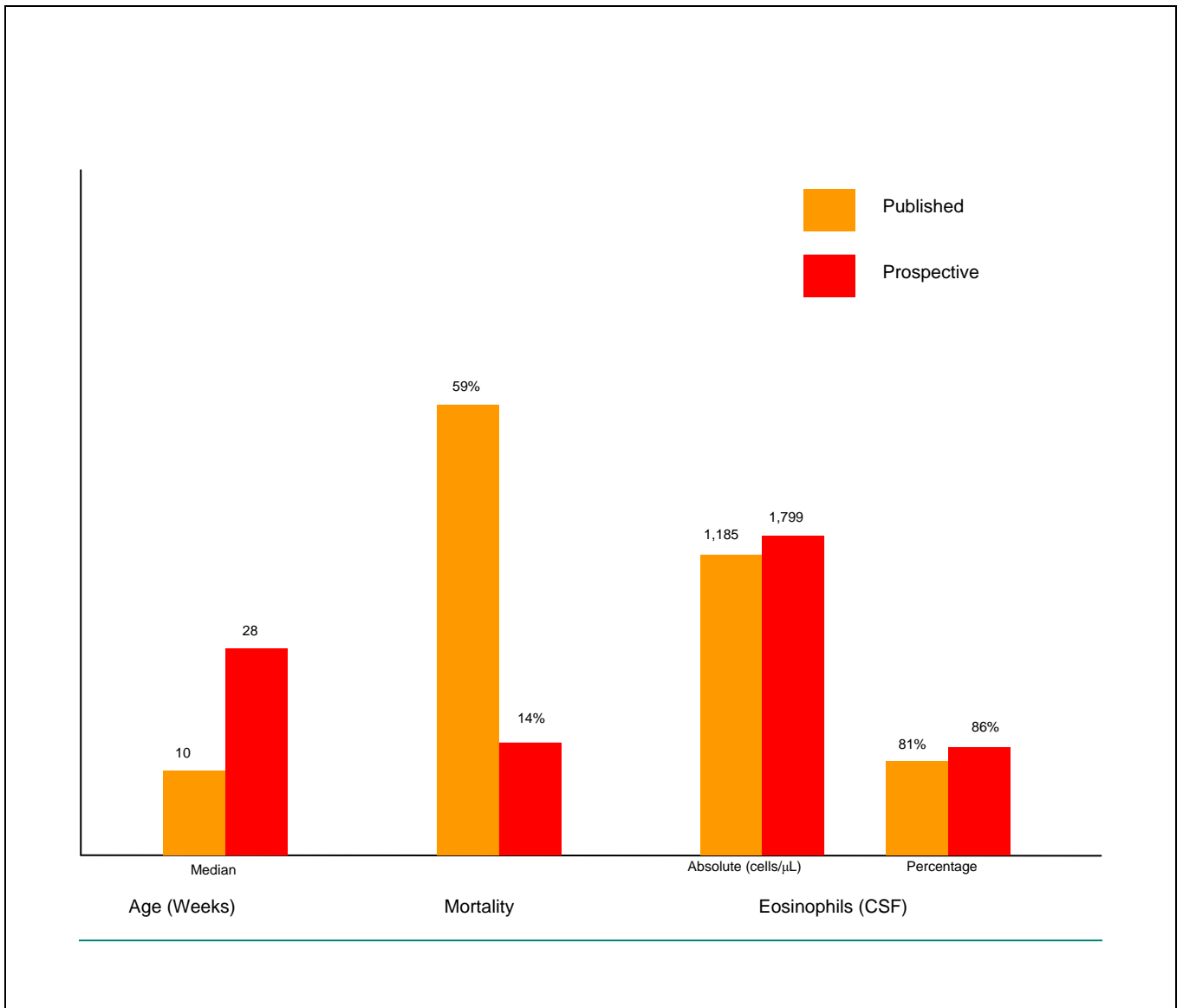


Figure 3.4: Comparison of age, mortality and CSF eosinophils between retrospective and prospective cases

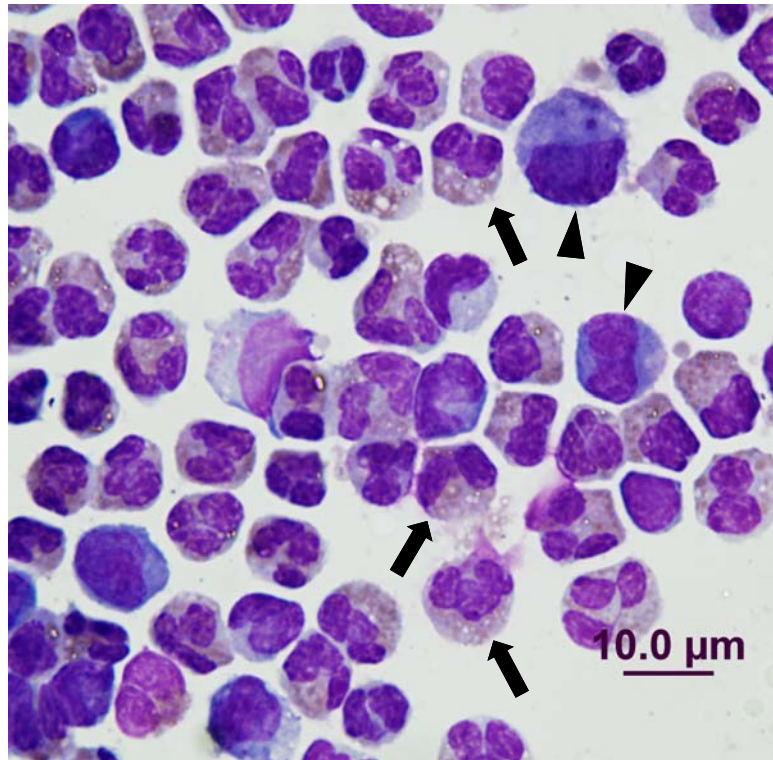


Figure 3.5: Example of eosinophilic pleocytosis within the CSF from Prospective Case 2. Eosinophils are marked with a black arrow. Monocytes are marked with an arrowhead.

Case Number	Breed	Age (weeks)	Sex	Month	CSF Data			
					Protein (g/L)	Nucleated Cells (x 10 ⁶ /L)	Eosinophils cells/ μ L	%
1	Labrador	24	M	May	0.3	270	232	86%
2	Golden Retriever	20	F	May	0.5	4660	3,821	82%
3	Kelpie	24	F	May	0.28	182	173	95%
4	Golden Retriever	16	F	March	0.55	458	412	90%
5	Boxer	16	F	May	0.55	458	389	85%
6	Miniature Poodle	16	M	May	1.35	332	282	85%
7	Cross Bred	16	M	June	1	146	145	99%
8	Beagle	20	F	July	0.61	3651	3,505	96%
9	Australian Cattle Dog	48	F	February	0.55	5952	4,940	83%
10	Staffordshire Terrier	8	F	February	1.07	1,800	1,134	63%
11	Labrador	32	F	April	1	6,970	5,576	80%
12	Labrador	192	F	August	0.86	1782	1,550	87%
13*	Boxer	48	M	May	0.28	182.2	173	95%
14	Kelpie	96	F	July	1	4683	4,449	95%
15	Staffordshire Bull Terrier	400	F	November	1.28	6825	6,279	92%
16	Cross Bred	192	F	April	0.11	4.5	0.23	5%
17	Maltese	96	M	March	0.4	1746	1,397	80%
18	Doberman	44	F	June	2.82	6.2	1	13%
19*	German Shorthaired Pointer	288	M	March	3.3	7860	4,716	60%
20	Rhodesian Ridgeback	32	F	March	0.31	351	260	74%
21	Cross Bred	10	M	May	0.86	132	125	95%
22*	English Bulldog	16	M	November	0.23	15	14	95%
	Average	75					1,799	79%
	Median	28					401	86%

Table 3.5: CSF cytology and details of prospective cases of CNA. * Cases 13, 19 and 22 were euthanased at the owner's request.

3.3 Serology

3.3.1 ELISA

3.3.1.1 Controls

Of the 21 dogs in Control Group A, twenty (95%) had a measurable titre in serum (Figure 3.7). In contrast, in 20 of 21 dogs there were no demonstrable anti-*A. cantonensis* antibodies in the CSF specimens. The one case (Control A15) with a measurable titre in CSF had the highest serum titre. This sample, along with samples from Control A8 and Control A13, were contaminated with blood during collection, which may account for the low titre of antibodies detected in CSF. Within Group B, 10 of 22 dogs (46%) had measurable serum titres (Figure 3.8). These results are summarised in Table 3.6.

3.3.1.2 Prospective CNA Cases

Nineteen of 21 cases (90%) for which CSF specimens were available for testing were positive using the ELISA. Twelve of 19 cases (63%) were positive using the ELISA on serum. The two cases that were negative on CSF were also negative on serum. Four cases that were negative on serum were positive on CSF. Two cases, case 1 and case 3 from the prospective cohort had serum samples tested one year after the initial sample. Both were positive with titres of 1:100 and 1:200, respectively. These results are summarised in Tables 3.6 and 3.7.

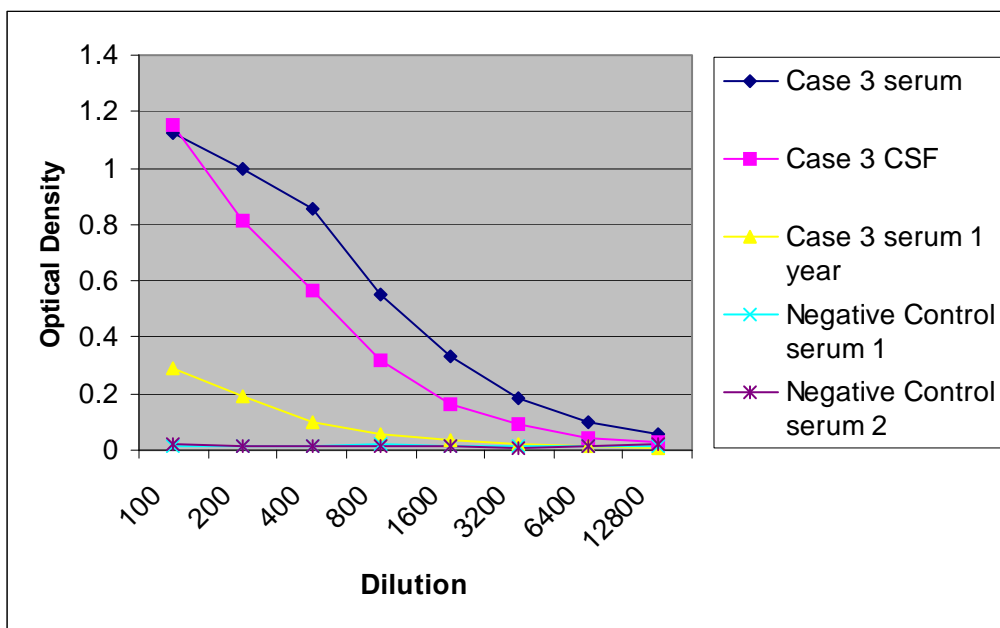


Figure 3.6: ELISA results for serum and CSF from prospective case 3. Note the optical density in the serum sample is still positive one year after therapy, but much lower than at the time of presentation.

Prospective Group			Control Group A			Control Group B	
Case	Serum	CSF	Case	Serum	CSF	Case	Serum
1	1:100	1:800	1	1:800	Negative	1	1:800
2	Negative	1:200	2	1:400	Negative	2	Negative
3	1:800	1:6400	3	1:800	Negative	3	1:100
4	Negative	1:100	4	1:800	Negative	4	1:100
5	N/A	1:200	5	1:200	Negative	5	Negative
6	Negative	1:800	6	1:1600	Negative	6	Negative
7	1:100	1:200	7	1:1600	Negative	7	1:100
8	Negative	1:400	8	1:200	Negative	8	Negative
9	N/A	1:400	9	1:800	Negative	9	1:100
10	1:200	1:6400	10	1:800	Negative	10	Negative
11	N/A	1:3200	11	Negative	Negative	11	Negative
12	1:12800	1:6400	12	1:200	Negative	12	Negative
13	1:400	1:1600	13	1:100	Negative	13	Negative
14	1:800	1:1600	14	1:800	Negative	14	1:200
15	1:25600	1:51200	15	1:6400	1:100	15	Negative
16	1:100	1:100	16	1:100	Negative	16	1:400
17	1:100	1:400	17	1:800	Negative	17	Negative
18	1:100	1:200	18	1:800	Negative	18	Negative
19	1:400	1:200	19	1:100	Negative	19	Negative
20	Negative	Negative	20	1:400	Negative	20	Negative
21	Negative	N/A	21	1:400	Negative	21	Negative
22	Negative	Negative				22	1:100

Table 3.6: ELISA titres for Prospective Group, Control Group A and Control Group B

Case Number	ELISA		Western Blot
	Serum	CSF	
1	Positive	Positive	Positive
2	Negative	Positive	Positive
3	Positive	Positive	Positive
4	Negative	Positive	Positive
5	N/A	Positive	N/A
6	Negative	Positive	Positive
7	Positive	Positive	Positive
8	Negative	Positive	Positive
9	N/A	Positive	Positive
10	Positive	Positive	N/A
11	N/A	Positive	N/A
12	Positive	Positive	Positive
13	Positive	Positive	N/A
14	Positive	Positive	Positive
15	Positive	Positive	N/A
16	Positive	Positive	Positive
17	Positive	Positive	Positive
18	Positive	Positive	Positive
19	Positive	Positive	N/A
20	Negative	Negative	Positive
21	Negative	N/A	Positive
22	Negative	Negative	N/A
Positive %	63%	90%	100%

Table 3.7: ELISA and Western Blot assay results for the Prospective Group.

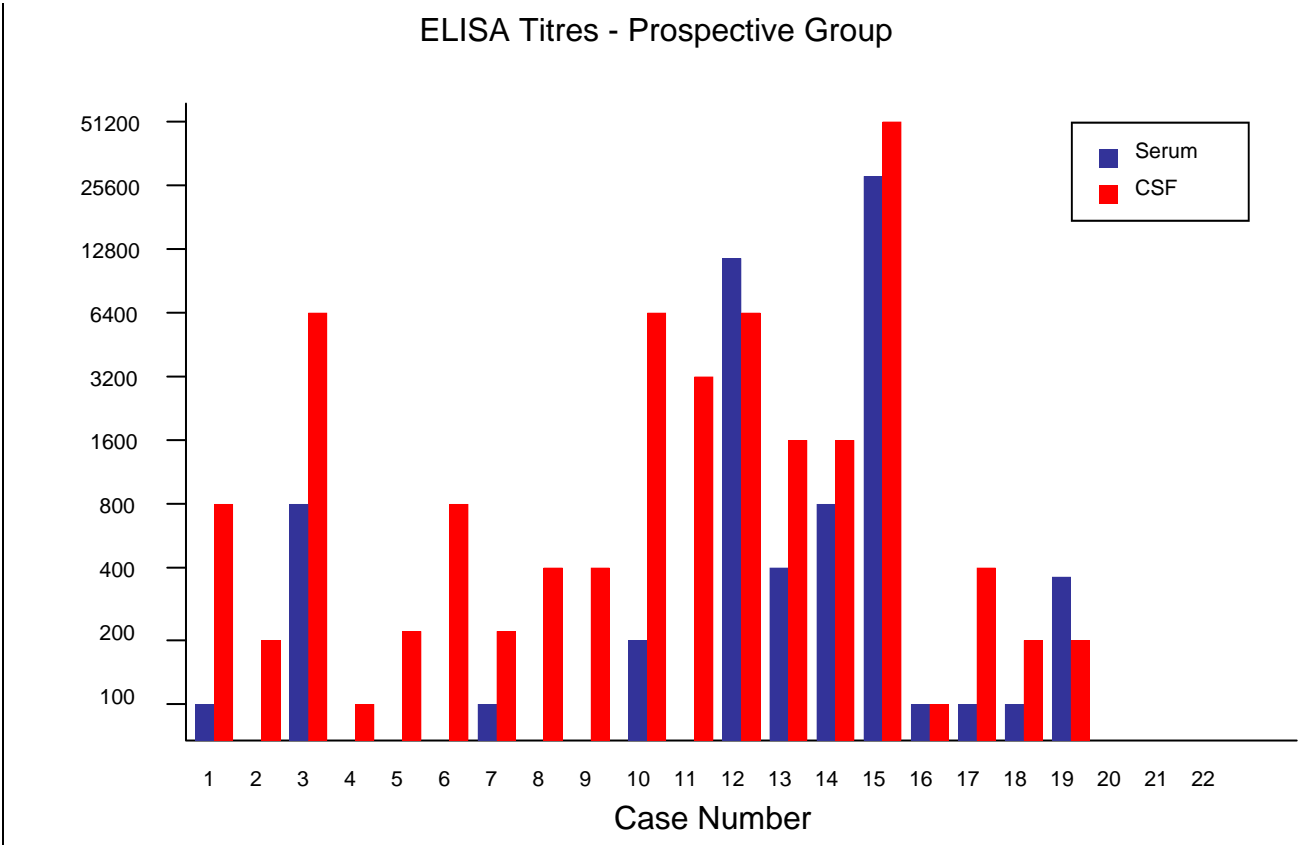


Figure 3.7: ELISA titres from serum and CSF samples of Prospective Group cases. The vertical axis represents serum dilutions.

Control ELISA Titers - Group A

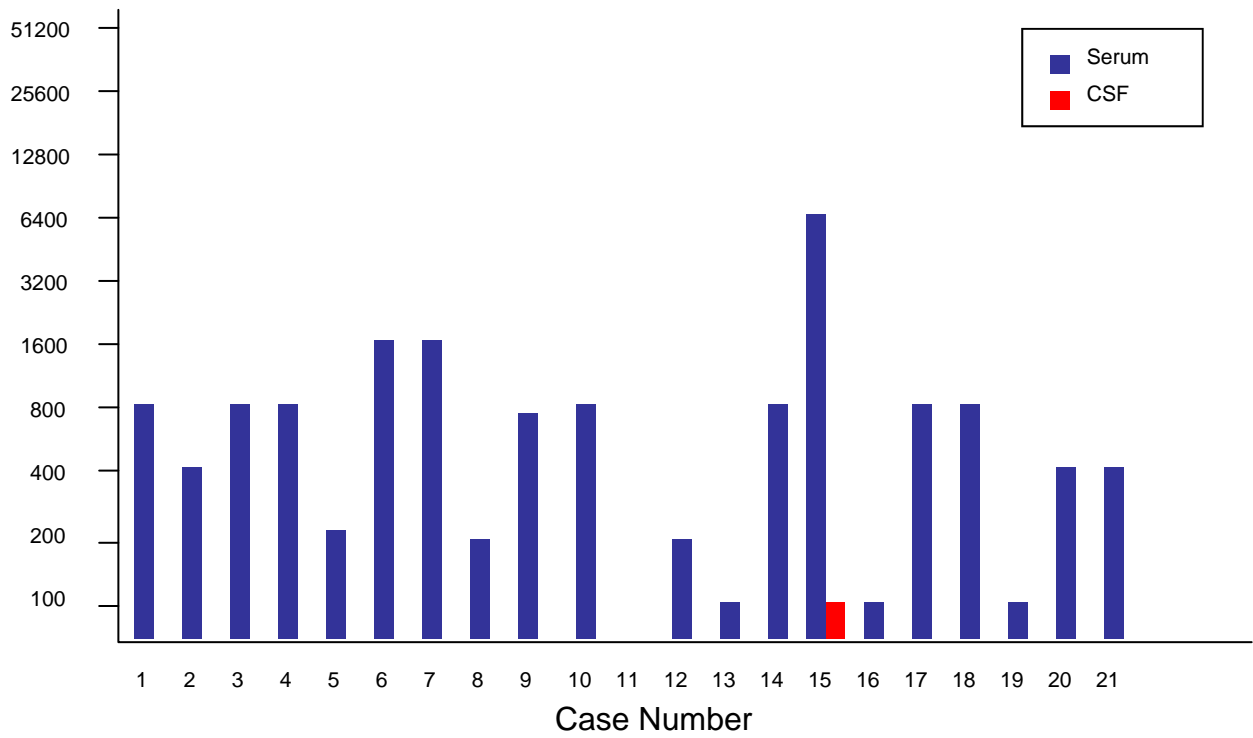


Figure 3.8: ELISA titers from Control Group A. CSF and serum samples were collected post mortem from juvenile dogs used in practical demonstration classes during September 2005. The vertical axis represents serum dilutions.

Control ELISA Titers - Group B

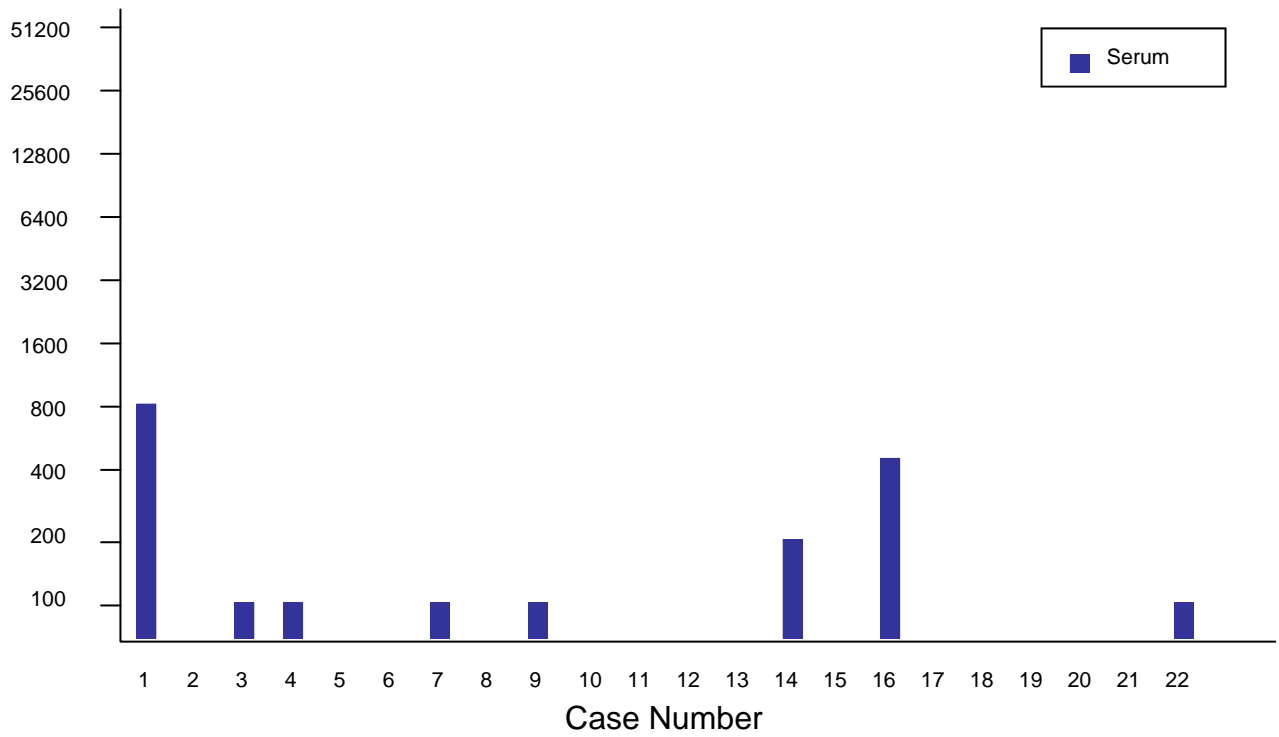


Figure 3.9: ELISA titres for Control Group B. Serum samples were collected from dogs treated at the UVCS for reasons other than neurological dysfunction during May 2005. The vertical axis represents serum dilutions.

3.3.2 Western Blot

Fifteen cases had serum and or CSF submitted for Western Blot assay and all reacted to the 31KDa antigen band, including one case that was negative on CSF and serum (Case 20). None of the dogs demonstrated antibodies to the 204 kDa antigen. The results are summarised in Table 3.7.

Chapter 4: Discussion

4.1 Comparison of Published Cases with Prospective Cases

One of the aims of this study was to compare details from cases published previously to those obtained prospectively. In doing so, it is apparent that there are a number of differences between the two groups. When Mason published the first case series of CNA in 1976,⁷⁹ he was describing a canine syndrome with characteristic clinical signs, viz. puppies less than 20 weeks of age, displaying the clinical triad of hind limb paresis, lumbar and hind limb hyperaesthesia and urinary incontinence. Therefore, the entire cohort of 55 cases published in 1983¹⁴ and the 4 cases published by Collins, et al. in 1992²⁵ were classified as having CNA based on their characteristic physical findings. The diagnosis was supported by CSF cytology and/or necropsy data. Importantly, many patients exhibited only one or two of the three signs initially. Furthermore, many went on to develop other signs such as forelimb paresis, cranial nerve deficits and altered behaviour, although these were not included as part of the classic “syndrome”. Therefore, a more accurate way to describe the retrospective group is that they all had clinical signs referable to a progressive meningoencephalomyelopathy. This is consistent with the definition of human neural angiostrongyliasis and it reflects the typical neural migration of the larvae within a non-permissive host.

In comparison to the published group, the majority of the cases in the prospective arm of this study did not demonstrate the triad of signs outlined by Mason.¹⁴ However, they all demonstrated clinical signs consistent with a progressive meningoencephalomyelopathy. Consequently, rather than limiting CNA as a differential diagnosis for disease occurring in puppies presenting with hind limb paresis, hyperaesthesia and urinary incontinence, we have included dogs of any age demonstrating a progressive meningoencephalomyelopathy. The “classical” presentation in the retrospective cases is likely a feature of severe CNA, perhaps reflecting the puppies’ immature immune system, a large infective dose or the relatively small size of the spinal cord. In support of this proposition it is pertinent that in human neural angiostrongyliasis, children tend to more severely affected, have a higher mortality and increased frequency of permanent neurologic sequelae.⁵⁹

The retrospective cohort had a combined mortality rate of 59% compared to the 14% for prospective group. The 3 cases that were euthanased from the prospective group all had permanent sequelae and two of these (Cases 13 and 22) were young dogs. Mason does not give a figure for the

number of surviving puppies that demonstrated permanent sequelae, but mentions it as a common occurrence with at least one case euthanased as a result. It is clear that CNA has a similar clinical picture to human neural angiostrongyliasis; young dogs are more severely affected, have a higher mortality rate and are more likely to develop residual neurological deficits.

Signs of progressive meningoencephalomyelopathy are not pathognomonic for CNA and can be seen with a number of other diseases. There are some characteristics, however, which may assist differentiation of this diagnosis from other conditions. Large breed dogs appear to be over represented in both the published cases and prospective group, presumably because they have a greater opportunity to ingest molluscs in a predominately outdoor domicile.

Hyperaesthesia is the most common presenting sign noted in both the retrospective and prospective groups of dogs, however in the prospective cohort, the location and extent of the hyperaesthesia was more varied. In Mason's group, all 55 cases demonstrated lumbar hyperaesthesia. In the prospective cohort 16 of the 23 dogs (70%) displayed hyperaesthesia but of these only 6 cases had lumbar hyperaesthesia. Eleven dogs (50%) presented with neck pain and in 4 of these cases (cases 1, 8, 11 and 16) neck pain was the only presenting sign. This presentation is similar to that in humans where the most common presenting signs are headache and neck pain.⁵⁹

Hyperaesthesia is most likely a reflection of a polyradiculopathy. Necropsy samples demonstrate large areas of eosinophilic infiltration associated with the spinal nerve roots in experimentally and naturally infected dogs.^{11,14} Hyperaesthesia may also be associated with migration of larvae along peripheral nerves, particularly the sciatic nerve. This has been documented in experimentally infected dogs, rabbits and mice.^{11,45,46} *Pneumostrongylus tenius* larvae invade the CNS of Canadian White-tailed deer (*Odocoileus virginianus*) via peripheral nerves, especially those located in the lumbar muscles⁷⁷. This may be similar for *A. cantonensis* in dogs and would account for why lumbar hyperaesthesia is one of the more common presenting signs.

Two factors are likely critical in determining the extent of clinical disease in a given species: i) the initial infective dose, and ii) the host's ability to prevent the larvae from reaching the CNS. Guinea pigs, calves, pigs and rhesus monkeys can withstand doses of 1000's of larvae without clinical affect.^{10,44,87} Within many of these non-permissive hosts, paratenic or otherwise, the larvae do not reach the CNS. Presumably this is because the non-permissive host is able to mount a sufficiently

effective immune response in a time frame, which prevents the larvae from migrating or developing normally. In all accidental or non-permissive hosts *A cantonensis*' development is abnormal.

The host's current health status, including nutrition, concurrent and previous parasite burdens and environmental stress may contribute to *A cantonensis*' ability to migrate through the gastrointestinal tract and reach the CNS. Mason documented a number of cases in young puppies that had concurrent intestinal parasite burdens.¹⁴ These pre-existing infections could compromise the dogs' immunity to such an extent that *A cantonensis* larvae may more readily migrate through the intestinal walls. Similarly, a number of the prospective cases had a stressful episode prior to the onset of clinical disease including surgery, chemotherapy, gastrointestinal disease and immunosuppressive therapy.

Mason noted that in some cases vomiting preceded the onset of other clinical signs by 7 to 10 days. The initial penetration of the gastrointestinal tract by 3rd stage larvae is often accompanied by vomiting or abdominal pain in many species.^{11,22,80} In support of this association, antecedent gastrointestinal signs were noted in some of the prospective cases. Vomiting may also occur at the time of onset of other neurological symptoms, presumably due to meningeal irritation.

The "incubation period" of CNA in either the prospective or published groups is impossible to calculate. In experimental infections, signs develop 9 to 14 days post-infection although the parasite can be seen within the CNS within 3 days following ingestion.^{11,14} In humans, the incubation period ranges from 1 day to 36 days with an average of 12 to 16 days.^{80,217-219} This incubation period of approximately two weeks coincides with the larvae's second moult (from 4th stage larvae to 5th stage young adults). The second moult is associated with a dramatic rise in circulating immune complexes, enlargement of neural granulomas and an exacerbation of meningeal inflammation in experimentally infected animals.^{78,220}

There is a trend within both the retrospective and the prospective cohorts for cases to present during late spring and early winter, i.e. between April and July. This has also been documented in the human cases occurring in Brisbane.⁶⁹ When the prospective cases were compared between Brisbane and Sydney the same trend was noted. Thus dogs are more likely to develop CNA during these months although isolated cases can occur sporadically in any month. Evaluating the two region's climates, it would seem that most cases occur during the period of highest humidity and when the average daily temperatures range from 17° to 25° C (Appendix 7). The rate of development of larvae within the intermediate hosts depends on ambient temperature, with an ideal range between 21° and 26° C.³ Once

larvae have matured to the 3rd stage, they become quiescent and will remain viable for the life of the intermediate host.

In other regions, there is a seasonal peak in the incidence of human neural angiostrongyliasis related to key intermediate or paratenic host population changes. For example, in Tahiti cases tend to occur between March and September when fresh water prawns are most abundant.¹²⁸ In New Caledonia, the peak incidence of neural angiostrongyliasis occurs when intermediate hosts (native molluscs) are most numerous.²²¹ In Thailand, there is no seasonal peak in incidence because the most common source of infection is the small aquatic *Pila sp* of snails, which are abundant throughout the year.⁵⁹

In dogs, the most likely route of infection is direct ingestion of an intermediate host. While only one case in the prospective cohort (case 5) was actually seen eating slugs and snails prior to presentation, Mason noted that a number of cases within his group had ingested the intermediate host. In Australia, there are a number of species of molluscs that serve as intermediate hosts and they may contain as many as 1000 infective 3rd stage larvae.¹²³ These larvae can remain viable within a dead intermediate host for up to 11 days. Mason was able demonstrate experimentally that puppies would eat slugs even when other food was offered and suggested that even the normal chewing/mouthing behaviour exhibited by puppies could be enough to allow ingestion of infective 3rd stage larvae.¹⁴

This behaviour is unlikely to be exhibited by adult dogs and contamination of food may well be a more likely route of infection in these cases. Infective 3rd stage larvae are secreted within the mucus trails of molluscs and they can survive for several hours depending on the ambient environment.³³ Contaminated vegetables, whether by mucus secreted from infected molluscs, the molluscs themselves or infected planarian paratenic hosts, are a recognised route of infection in humans in a number of outbreaks.⁶² Direct penetration of the host by larvae or contamination of wounds is also possible. Experimentally, rats, dogs, cats and primates can become infected via subcutaneous or intraperitoneal injections.^{5,11,22,44} The importance of this route of infection in the clinical setting is unknown but unlikely to be of great significance.

Definitive diagnosis of CNA has only been made at necropsy. In humans, neural angiostrongyliasis can be diagnosed definitively by identifying larvae within CSF or from aqueous humour samples. Ten of the retrospective cohort of CNA cases were confirmed at necropsy but none had larvae present within CSF samples. Collection of CSF is easier in humans compared to dogs and

in a number of countries repeated therapeutic lumbar puncture is considered part of the normal treatment regimen for neural angiostrongyliasis.^{59,80} In the largest series of human cases, 54% of patients (261 patients) had CSF opening pressures greater than 20 cm of water.⁵⁹ The increased CSF pressure contributes to the clinical signs, notably headache and neck pain, consequently, patients may have CSF “drained” more than once and the volume of CSF collected tends to be large. Patients, including children, will routinely have up to 25mls of CSF removed.^{222,223} Accordingly, the chance of recovering larvae is greater than in dog where typically 2 mL of CSF or less is obtained.

Most veterinarians would be hesitant in removing large volumes of CSF from any patient, owing to a perceived risk of the cerebello-tonsillar coning or herniation associated with collections from the cistern magna under gaseous anaesthesia. In Australia, larvae have yet to be identified in the CSF of human neural angiostrongyliasis patients antemortem, which may also reflect the local medical profession’s unwillingness to obtain large volumes of CSF for fear of complications or lower numbers of larvae per mL of CSF.⁶

As the majority of dogs in the prospective cohort recovered, the diagnosis of CNA could only be presumptive based on clinical signs, response to treatment and most importantly, evidence of eosinophilic pleocytosis in the CSF. A diagnosis of eosinophilic pleocytosis in humans requires greater than 10% eosinophils of a total cell count, and greater than 10 eosinophils per μL of CSF.^{51,224} This convention has also been adopted for dogs. Changes in protein and glucose levels, and Pandy’s test results do not distinguish CNA from other potential inflammatory aetiologies. The percentage of eosinophils and absolute eosinophil counts in both the published and prospective groups are similar indicating that most dogs with CNA have very high percentages (greater than 76%) and high cell counts (greater than 1,600 cells per μL).

In the retrospective cohort all of the cases had eosinophilic pleocytosis. In the prospective group two dogs (cases 16 and 18) has less than 10 eosinophils per μL . Case 16 did display signs consistent with a progressive meningoencephalomyelitis and responded to treatment with glucocorticoids. Case 18’s neurological signs persisted despite treatment. Both dogs were positive for *A cantonensis* antibodies in serum and CSF using the ELISA and Western Blot techniques. Therefore, despite these dogs having an absence of an eosinophilic pleocytosis of the CSF, they may still be considered possible CNA.

A recent outbreak of human neural angiostrongyliasis in Taiwan demonstrated that only 12 of 17 cases (71%) developed eosinophilic pleocytosis.²²³ Interestingly, of these 12 cases, only 5 initially presented with eosinophilic pleocytosis; the remaining 7 developed it over the subsequent 10 days despite some patients receiving glucocorticoids before the second sample was obtained. Consequently, a lack of eosinophilic pleocytosis should not rule out neural angiostrongyliasis. In rhesus monkeys, the maximal eosinophilic pleocytosis occurs between 14 and 28 days post infection.⁴⁴ In guinea pigs, the peak occurs, on average, 5 days after clinical signs began.⁸⁷ Hence, it might be expected that some animals with CNA will not demonstrate eosinophilic pleocytosis if CSF is collected early in the clinical course.

Perhaps if a second CSF sample had been taken from cases 16 and 18 one week after initial presentation eosinophilic pleocytosis would have been evident. Contrary to this, 10 dogs in the retrospective cohort had second CSF samples collected 2 to 3 weeks after the initial sample.¹⁴ Eosinophil percentages dropped from an average of 75% to 50% in this group. Not all of these dogs were treated with glucocorticoids so this cannot be interpreted as a response to medication. Clinical signs, however were generally mild in comparison to the remainder of the cases and were resolving at the time the second sample was taken.

To summarise, the absence of eosinophilic pleocytosis in CSF does not rule out CNA. Furthermore, its extent does not always correlate with clinical disease. Indeed, numbers of eosinophils within the CSF can increase over the course of the disease and can have several peaks. In a study of 125 human cases most patients had peak eosinophil levels in the CSF at 3 weeks following presentation, some peaked as early as one week while others took up to 5 weeks.²²² In most patients, eosinophil numbers rapidly decreased following the initial peak. However, in a proportion of patients there were reoccurring peaks 5 and 9 weeks after initial presentation, respectively. These subsequent peaks were not associated with relapse or worsening of clinical signs.

Based on evidence from the human literature, it is possible that several of the prospective cohort had sub-acute to chronic clinical disease, for example cases 13 and 22, and were experiencing these secondary peaks at the time of CSF collection. In these cases, the initial severe host inflammatory response may well have dissipated by the time that CSF was collected and clinical signs that the dogs were displaying were due to late sequelae. This would explain the poor response to treatment in both cases.

Advanced imaging has proven useful in human neural angiostrongyliasis, but has yet to be of proven benefit in CNA. Three of the prospective cohort had myelography and/or plain radiographs (Case 1, Case 18 and Case 19) but no pathognomonic abnormalities were detected. In human patients, MRI appears to be the most promising imaging modality for the diagnosis of neural angiostrongyliasis. Higher resolution MRI scanners are capable of displaying images of individual larvae.⁶⁰ However, lesions may not be evident at the time of presentation and may actually be most severe many days after the patient has begun to improve. Lesions documented on MRI can take many months to resolve.^{121,225,226} Computer tomography (CT) lacks sufficient resolution to be of benefit.²²⁷⁻²²⁹

Serum biochemistries were performed in some of the prospective cases but, in general, were unremarkable. Elevation in creatine kinase was noted in one case (case 14), which might have corresponded to muscle damage associated with larval migration. Eight of the 10 dogs in the prospective cohort that had haematology had a peripheral eosinophilia. Mason reported a similar finding in his group of clinical cases, but could not reproduce the peripheral eosinophilia in experimentally infected dogs.¹⁴ All of the dogs in Mason's group that had a peripheral eosinophilia also had intestinal parasites. None of the dogs in our prospective series had faecal samples examined for intestinal parasites. In humans, peripheral eosinophilia is commonly seen with neural angiostrongyliasis and these patients generally have no evidence of concurrent intestinal parasitism.⁵⁹ Not all of the ingested larvae reach the host's CNS, so some must die within the GIT, abdominal lymph nodes, liver and blood vessels inciting an eosinophilic granulomatous reaction.^{3,10,11,14} Such a mechanism would account for the peripheral eosinophilia noted in some of the prospective cases.

Some parasitic infections can be diagnosed by demonstrating patency. For example, with *A vasorum*, faecal analysis may yield 1st stage larvae in symptomatic dogs because the parasite is able to mature to the reproductive stage.²³⁰ Only in the definitive host, the rat, is *A cantonensis* able to establish a patent infection. Consequently, faecal analysis is unlikely to be of benefit when diagnosing CNA. Two fatal human cases reported recently in Australia had adult male and female *A cantonensis* within the lungs at necropsy. Therefore, it may be possible to for patent infections to be established in species other than the rat, particularly if individuals have concurrent immunosuppression.

4.2 Use of ELISA for the Diagnosis of CNA

4.2.1 Serum

Based on the results from the present study it appears that ELISA testing of serum using a crude antigen preparation is neither sensitive nor specific for CNA. Twenty-eight of 43 control dogs (65%) were positive using the ELISA compared to 12 of 19 dogs (63%) in the prospective group. Control Group B samples were collected during May, the period of peak incidence of CNA in Sydney, however Control Group A samples were collected in September, the period where no cases have been reported, yet this group had a higher number of positive titres and the magnitude of these was generally higher than Control Group B (Figures 12 and 13).

Two prospective cases (Cases 1 and 3) had serum samples tested one year after initial presentation and both were still considered positive but with a reduce titre. This suggests that IgG persists for a number of months following infection. Alternatively, it is conceivable that both dogs were re-exposed. It is possible, therefore, that some of the control dogs, particularly Group B, had positive titres because they had been previously exposed to the *A cantonensis* and had mounted a successful immune response.

One human seroepidemiological study published in 1980 suggested a significant level of subclinical *A cantonensis* infections in Aborigines in northern Australia.¹⁵⁶ A lack of adequate controls and use of a crude adult antigen for testing would tend to invalidate these findings and suggest a high level of cross-reaction.⁶ Similarly, the use of a crude antigen for the current ELISA would have the potential for a significant level of cross-reaction. Consequently, the high percentage of control cases that had positive titres might be simply explained with cross-reaction to other helminths. In a serological study of neural angiostrongyliasis in macropods using the same ELISA, there were also a significant number of false positive in the control groups.²¹⁴ These samples were collected from macropods in areas where *A cantonensis* is not thought to be endemic (Melbourne, Victoria and Dubbo, New South Wales). The most likely conclusion for the large number of false positives was thought to be cross-reaction with other metazoan helminths.

Cross reactions are documented between many helminths.²³¹ For this reason a number of immunological tests for *A cantonensis* have been abandoned, including indirect haemagglutination²³², intradermal skin testing¹⁵³ and complement fixation.²³³ There are at least 25 antigens from adult *A cantonensis* that are shared with other helminths²³⁴ and there is also significant cross reactivity with

larval stages.^{161,162,171} Consequently, the 'positive' titres in the control cohort likely represents cross reaction with antibodies produce against *T canis* and other intestinal helminths that are common in young dogs.

The role of *A marrakesae* has not been explored in regards to causing disease in dogs or cross reacting with the ELISA and it may represent a significant confounding factor. It is unlikely that *A mackerrasae* causes canine neural angiostrongyliasis but in order for a serum ELISA to be useful, it is of great importance to determine an antigen unique to *A cantonensis*.

4.2.2 Cerebrospinal Fluid

The results obtained using CSF samples appear much more promising. Positive results were observed in 19 of 21 dogs (90%) in the prospective group versus only one from the control group (Control A15). This dog had the highest serum titre of any control (1:6,400) and the sample was contaminated with blood during collection. This chance finding emphasises the possibility that antibodies against helminths may reach the CSF when the BBB is disrupted or if there is c

ontamination of the CSF with blood during its collection. As CSF normally has extremely low levels of protein, antibodies present in the CSF can reasonably be expected to have been incited by the presence of larvae within the CNS as the normal BBB is not permeable to antibodies in systemic circulation. Testing of CSF samples from dogs with other inflammatory or neoplastic neurological diseases would be useful to determine the usefulness of the ELISA. Four dogs with intervertebral disc disease confirmed at surgery had CSF tested using the ELISA and were negative (data not shown) but large number of specimens from similar cases would make the observation more compelling.

All cases in the prospective cohort that were tested using Western Blot analysis (14 cases) were positive. Unfortunately none of the controls were tested in this manner and the lack of suitable canine controls is a significant problem when evaluating any new technique. With macropod serum, the Western Blot had a sensitivity of 62% and specificity of 92% using the 31kDa antigen.²¹⁴ This is superior to the ELISA in both macropods and dogs using serum but is still insufficient for the test to be a useful diagnostic aid. One of the most significant problems with the Western Blot technique in the macropod study was the high number of false negatives. Despite the lack of sensitivity and specificity, this test does show that the 31kDa antigen may be a useful starting point to develop a future ELISA.

For any serological test, the presence of disease may go undetected for a number of reasons; (i) collection of the sample prior to an antibody response, (ii) species differences in reacting to selected antigens, (iii) insufficient parasite burden to elicit a significant response from the host, and (iv) poor sensitivity of the assay itself.

It is possible that the antibody response in dogs of the prospective cohort that were negative was not measurable at the time the samples were collected. In rats and monkeys, despite antibodies appearing earlier in the CSF than in serum, their production does not begin until 15 days post ingestion when plasma cells are detectable within CSF.^{125,126} Alternatively, those CNA cases that were negative may have had a relatively high antigen load, consequently the amount of antibody available to bind in the ELISA would have been low, as has been postulated with human cases.¹²⁶

Ideally, prospective cases that were initially negative should have had follow-up analysis. This would have allowed those cases that had not seroconverted at the time of initial presentation to be more accurately diagnosed. Unfortunately the cost and morbidity of obtaining serial CSF specimens from veterinary patients are limiting factors. Glucocorticoids may influence the production of antibodies, however in human cases levels remain detectable despite corticosteroid therapy.^{174,176,181}

Small sample size is a problem in many serological studies and will affect the validation of the assay.²³⁵ The period of time in which prospective cases were collected was extended in order to increase the sample size, however, in many cases insufficient data was collected and they could not be included in the study.

Sample handling is also an important factor in determining the number of false negatives. Antibody levels can be adversely affected by freeze-thaw cycles.²³⁶ Samples were divided into smaller aliquots to limit the number of freeze-thaw cycles, however all samples were subjected to multiple cycles and stored at different temperatures for varying lengths of time during collection, transportation and storage. Consequently, there may have been some loss of antibody integrity that might explain the occurrence of false negatives.

In human patients, there are a number of antigens that appear to be specific for the diagnosis of *A. cantonensis*, for example the 29kDa, the 31kDa and the 204kDa antigens.^{167,171} There is considerable species variation in the number and identity of antigens recognised by the infected host.⁴ There has been extensive research to characterise the nature of the antigens recognised by rats,

however an assay that appears to be specific and sensitive using a specific antigen in rats may not display the same results in dogs or humans. Using the Western Blot technique has shown that dogs do not react to the 204kDa antigen but react strongly to the 31kDa antigen, while macropods and humans react to both antigens.^{167,214}

Obtaining a purified antigen is expensive and time consuming due to the low yield from larvae. Recently there have been a number of specific antigens identified that are shared between *A cantonensis* and its intermediate hosts.¹⁷⁵ Intermediate hosts are easier to maintain and larger amounts of antigen can be obtained more readily. Thus, these shared antigens may represent a superior choice if they prove sensitive enough. Alternative techniques used in humans involve the use of monoclonal antibodies and immuno-PCR.^{176,180,181}

4.3 Treatment

4.3.1 Role of Glucocorticoids

All dogs in the prospective cohort received glucocorticoids. Reducing the inflammation associated with dead or moulting larvae should lead to a diminution of clinical signs in dogs that are infected with *A cantonensis*. In the prospective group, this was certainly true, with the exception of 4 cases as described below. The response to glucocorticoid treatment was rapid and most dogs were significantly better within 48 hours. In particular, hyperaesthesia was improved conspicuously with corticosteroid therapy. However, the retrospective cohort demonstrated a very high rate of mortality despite the majority of them being treated with glucocorticoids.

In dogs that have ingested large numbers of larvae, using corticosteroids to inhibit the host's immune response may not in itself resolve the disease. In fact, the disease may progress due to continued migration of larvae, unhindered by the host's immune mechanisms. Several of the dogs in the retrospective cohort worsened despite treatment with glucocorticoids, which could possibly be as a result of this phenomenon. Failure of immunosuppressive therapy in some cases suggests that both mechanical damage due to migrating larvae and inflammation secondary to the host response contribute to clinical disease. Which of the two is the more significant depends on the species infected, the individual and the number of larvae ingested. In very young dogs, like those presented in Mason's thesis, it may be that the immune system is simply overwhelmed and the relatively large number of

migrating larvae produce so much trauma to the neural tissues, which are relatively small, such that the dogs die or must be euthanased.

Of the four dogs in the prospective group that did not respond to glucocorticoids therapy, two dogs (cases 13 and 22) presented for chronic, progressive meningoencephalomyelopathy with behavioural changes; both dogs were eventually euthanased for aggressive behaviour that had developed following unsuccessful treatment. Another dog (case 18) had a 6-month history of head tremors and was unresponsive to treatment. The fourth dog (case 19) presented for cranial nerve dysfunction and neck pain that was also unresponsive to treatment. The signs progressed to blindness and the dog was euthanased. In the retrospective cohort a number of puppies failed to fully recover and had persistent hind limb paresis. Therefore permanent sequelae are an important consequence of CNA and cause of treatment failure. Permanent sequelae are seen in human neural angiostrongyliasis patients, particularly in severely affected children. Signs include blindness, altered mentation and facial nerve palsies.^{123,222}

Jindrak was able to demonstrate that in dogs, granulomas associated with larval fragments are present within the CNS 60 days post infection.¹¹ By 90 days, there were no lesions observable within the CNS. In humans, MRI scans demonstrate lesions within the CNS for up to 22 weeks post infection.¹²¹ Therefore, the length of therapy should continue for a minimum of 6 to 8 weeks and may need to be extended depending on the severity of the disease and clients should be warned of the possible occurrence of permanent sequelae.

There are potential complications associated with long-term administration of corticosteroids. Two of the dogs in the prospective group (cases 2 and 3) were significantly smaller than litter mates following cessation of treatment and when they had grown fully, they appeared to be under size for their respective breeds. Studies on the growth and the development of children receiving corticosteroids as part of a chemotherapeutic regimen have shown that some children fail to grow to their expected height.²³⁷

Long term use of moderate to high doses of glucocorticoids has been shown to reduce the linear growth of long bones, and even relatively low doses of daily glucocorticoids can slow development in children.²³⁷ The mechanisms are complex but involved antagonism of growth hormone, delayed growth of chondrocytes within the physes and reduction in Insulin-like growth factor – I. These changes are transitory and bones tend to display compensatory “catch-up” growth

once the glucocorticoids are withdrawn. However, if the delays occur during rapid phases of growth, then the effects can be permanent.²³⁷

Secondary infections are another complication of long-term corticosteroid use. Case 4 developed demodecosis during treatment, which was successfully managed with topical therapy. Bacterial infections have been described secondary to parasites migrating from the GIT.¹⁴⁷ Coupled with long-term glucocorticoid therapy the risk of infection would increase consequently, the use of broad-spectrum antibiotics may be justified in CNA cases.

4.3.2 Role of Anthelmintics

There is a history of scepticism regarding the role of anthelmintics in the treatment of CNA. If the disease is predominantly due to the host's reaction to dieing/moulting larvae then administering anthelmintics soon after ingestion of the larvae might hasten the onset of clinical signs. Similarly, administering anthelmintics during the natural course of the disease should worsen the clinical signs. In Mason's cohort 8 of the 55 dogs received anthelmintics. Six died or where euthanased and the remaining 2 dogs had prolonged recoveries.¹⁴ Three of the dogs that died were not given glucocorticoids concomitantly and all the cases were amongst the most severely affected of the cohort. Therefore, it is difficult to interpret the results despite Mason's conclusion that anthelmintics worsen the clinical outcome. The preposed mechanism or theoretical disadvantage to using anthelmintics is that they synchronise the release of antigen and thereby increase the effective antigen load.

In humans, the practice of administering anthelmintics is accepted as part of the standard treatment protocol in many regions. The rationale for this approach is based on the notion that in the most severe cases there is a significant component of neural disease associated with mechanical damage caused by migrating larvae.⁸⁰ Furthermore, there is evidence to suggest that vascular lesions (thromboses and aneurysms) occur secondary to migrating larvae.⁸⁰ Anthelmintics have been used successfully in other species to treat neural angiostrongyliasis.^{19,66}

Two cases (see Appendix 4) that did not meet the inclusion criteria for the prospective cohort are worthy of mention with respect to anthelmintics administration. In a litter of 7 Greyhound puppies that were severely affected with multifocal CNS disease, 6 died despite glucocorticoid therapy. The one surviving puppy was treated with fenbendazole as well as glucocorticoids and recovered. A

necropsy of one of the 6 littermates demonstrated numerous *A cantonensis* larvae within the cord, brain and meninges.

The second case, a 3-month-old female boxer, had been treated with corticosteroids and ivermectin for 3 weeks for a presumptive diagnosis of CNA. At the time of referral the dog still had an eosinophilic pleocytosis in CSF (85% eosinophils of 111 cells/ μ L). Ivermectin was stopped and while the dog initially improved over a 2 week period, seven weeks after referral the dog relapsed despite administration of a tapering glucocorticoid regimen and was euthanased. Necropsy revealed *A cantonensis* larvae within the spinal cord and brain.

These two cases would suggest that the administration of anthelmintics may have a useful role in the treatment of CNA, especially when given in concert with corticosteroids and other immune modulators. If the host's immune system is suppressed then there is a potential risk that larvae will mature and the infection become patent.^{46,94} Experimentally, it is clear that immunosuppression may reduce meningeal symptoms but worsens the myelitic and encephalitic disease by inhibiting eosinophil function.⁹¹ It would seem logical, therefore, to administer anthelmintics concomitantly to prevent patency. More importantly, their use may reduce the mechanical trauma caused by migrating larvae.^{105,114} A dosage regimen that kills larvae slowly or at least non-synchronously would be of theoretical benefit.

In a recent study looking at MRI changes in the brains of rabbits infected with *A cantonensis* there was a trend towards more severe lesion in animals treated with albendazole compared to those that were not.²²⁵ The MRI changes were not associated with clinical disease and tended to occur many days after the published incubation period in rabbits. The exception in this study was a group of rabbits that were treated within 5 days of infection. This group did not display any MRI or histopathological lesions. Therefore, while it is probably unwise to use anthelmintics in isolation, they should be considered in some cases, particularly early in the course of the disease.

Only two of the prospective cohort received anthelmintics for heartworm prophylaxis in the two weeks prior to developing clinical CNA (cases 2 and 20). It is difficult to draw any conclusions but it would seem unlikely that the clinical disease was attributable to the administration of prophylactic anthelmintics.

Alternatively, there is also no evidence that routine heartworm or intestinal prophylaxis prevents the disease. The majority of anthelmintics used for routine heartworm or intestinal prophylaxis are administered monthly and the drug has effective levels in the circulation for less than 48 hours. Because *A. cantonensis* larvae can be seen in the CNS within hours of ingestion³ the anthelmintics would need to be present in circulation all of the time.

4.3.3 Adjunct Therapy

All of the dogs in the prospective cohort received symptomatic and supportive care. Such care is critical to preventing secondary sequelae and managing hyperaesthesia. Pure opioid agonists are useful adjuncts for treating the hyperaesthesia unless respiratory compromise is evident.²³⁸ Manual expression of the bladder or urinary catheterisation may be required in some instances. Padded bedding is important for obtunded animals. Intravenous fluids are indicated if the dog is unable to drink or there is a risk of aspiration. Physiotherapy and massage during the convalescence will help minimise muscle wasting and speed recovery, although care must be taken with painful animals.

Cyclosporin has been used in mice infected experimentally with *A. cantonensis*.¹⁴² Its benefits appear to be two fold; i) immunomodulation reduces the host's immune response, particularly eosinophil recruitment and ii) it has a direct anti-parasitic effect. The micro-emulsion formulation of cyclosporin has reduced the need for drug monitoring and simplified regimens.²³⁹ To date there have been no reports of human cases receiving cyclosporine but its use may represent an important adjunct therapy, particularly in severe cases, in improving clinical outcomes and reducing the length of treatment with glucocorticoids.

Other drugs that modify the T_H1 and T_H2 responses may also be beneficial. These included the interferons and thalidomide.⁹⁶ Matrix metalloproteinases (MMP) have a critical role in inflammation within the CNS, including neural angiostrongyliasis.^{110,111} The inhibition of MMPs, specifically MMP-9, has shown to reduce the severity of inflammation associated with neural angiostrongyliasis in mice.^{115,143} There are a number of drugs, including doxycycline and albendazole, that inhibit MMP-9 and may be of use in the treatment of CNA.^{114,143}

4.4 Prevention

At this stage in our understanding of CNA no recommendations can be made with regard to prevention. In other species acquired immunity appears to be short lived or incapable of preventing reinfection.^{47,65,148,151} Most anthelmintics used for routine monthly heartworm and intestinal parasite prophylaxis are cleared rapidly from the host's circulation and would be of limited benefit. A slow release formulation such as the heartworm prophylaxis based on moxidectin may provide some protection but further studies would be required. Attempts have been made to characterise stage-specific gene expression of *A cantonensis*.^{240,241} This may enable regulation of the larval development and produce novel preventative drugs.

Environmental control of definitive and intermediate hosts would be the most effective approach to reducing the likelihood of infection. Preventing contamination of food and food containers, clearing out areas that would harbour rats, limiting access to gardens where slugs and snails may reside and good hygiene are steps that would limit exposure of dogs to potential sources of infection and also reduce the risk of clients themselves becoming infected. Dogs with CNA could be considered sentinels in the prevention of human neural angiostrongyliasis.

4.5 Conclusion

CNA is a disease that can occur in dogs of any age, consequently it should be considered as a differential in any animal with a progressive meningoencephalomyelitis. Veterinarians should be aware that the "classical" presentation outlined in Mason's thesis is probably a feature of the age of the cases in his cohort rather than the disease per se. Clinical signs can range from hind limb paresis and hyperaesthesia to severe, generalised CNS dysfunction, to focal disease such as neck pain and cranial nerve neuropraxia. A minimum workup should include CSF collection and timely evaluation of cytology. Pathologists should be aware that parasites may be present in the CSF sample. The ELISA, in its current form, is best suited as an adjunct to the diagnosis and its use should be limited to CSF specimens. Treatment should include glucocorticoids at immunosuppressive to high anti-inflammatory doses for a minimum of 6 to 8 weeks. This may be combined with opioid analgesia, broad-spectrum antibiotics (doxycycline preferably), supportive care and possibly cyclosporin. Anthelmintics may be beneficial but should be used with caution and in conjunction with glucocorticoids. Owners should be warned of potential permanent sequelae of CNA and the side effects associated with long-term glucocorticoid use, particularly in young animals.

Purification of *A cantonensis*-specific antigen for the ELISA, monoclonal antibodies and immuno-PCR may reduce the need to acquire CSF if they prove sensitive and specific enough using serum. More work needs to be carried out with regards the use of serology in dogs.

Appendix 1

Angiostrongylus in Humans

In 1944 Nomura & Lim published a case report of a 15-year-old Taiwanese boy that had died of eosinophilic meningoencephalitis. At necropsy, they were able to identify a number of nematodes within the spinal cord, brain and meninges surrounded by eosinophilic granulomatous inflammation. The nematode, which they named *Haemastrongylus ratti*, was later reclassified as *A cantonensis*. This seminal case of neural angiostrongyliasis was documented only 9 years after Chen first described *A cantonensis* as part of a routine parasitological survey.

A decade later Mackerras & Sandars, two research parasitologists working in Brisbane (Australia) published the first detailed account of what they considered to be the life history of *A cantonensis*. Although the life cycles are almost identical, they were, in fact, describing a new species, *A mackerrasae*. Nearly 20 years later the first human cases in Australia were reported by Gutteridge in 1972⁶⁷ and then Welch in 1978¹⁵⁷. In 1976 Mason reported an emerging, often fatal disease in puppies, characterised by eosinophilic pleocytosis of the CSF occurring in the Brisbane region, Queensland.¹⁴ At necropsy he was able to identify *A cantonensis* larvae within the CNS and subsequently he named the condition CNA.

In humans, the disease tends to be self-limiting with mild clinical signs⁵⁹. The most common presenting complaints include headache (98%), neck pain (70%), pyrexia (30%) and vomiting (35%).⁵⁸ Cranial nerve signs and spinal neuropathy are seen mainly in children⁶⁸. Fatalities are rare and tend to occur more often in children. There may be initiating signs associated with ingested and migration of the larvae such as fever, malaise, vomiting and diarrhoea². Eosinophilic pleocytosis in CSF tends to peak 24 to 30 days post infection and again 75 to 80 days post infection.⁵⁹

Sources of infections range from ingestion of raw snails, slugs, monitor lizards and crustaceans to contaminated vegetables.⁶⁰

The typical incubation period ranges from 8 to 20 days for cases known to have ingested infected intermediate hosts, with the longest being 36 days^{2,59}. There is, however, considerable

variation in the literature and the incubation period may depend on the dose of infective larvae and which intermediate or paratenic host is ingested². Simple cases of meningitis tend to resolve without specific treatment within 2 to 3 weeks². Patients experiencing hyperesthesia or cranial nerve palsies tend to recover more slowly.

The disease is generally treated symptomatically, with repeated lumbar puncture useful in alleviating some of the clinical signs associated with increase intracranial pressure. Anthelmintics are occasionally administered and corticosteroids are used only in the moderate to severe cases. Surgery is required in some cases to remove the larvae from within the eye. Eosinophilic pleocytosis may persist for some time after clinical signs have resolved². The overall mortality rate is low.

At necropsy brain congestions and thickened meninges are evident. Gross haemorrhage is uncommon.⁶⁰ There is often little reaction around living larvae and they are recovered from the CNS parenchyma, meninges, perivascular spaces and within the CNS blood vessels. One of the most characteristic findings is the presence of microcavities or tracks within the brain and spinal cord.⁶⁰ Microscopic examination of these tracks reveals disruption to the CNS tissues characterised by Wallerian degeneration, haemorrhage and granulomatous infiltration, with a prominent eosinophilic component. The subarachnoid space is often dilated.

The largest case series published in Australia consists of 8 patients recorded over 12 years from the combined Brisbane hospitals.⁶⁹ The majority of these were children. The route of infection varies between case reports in Australia. In one case the only known exposure was to crustaceans as the patients tended to eat a lot of prawns and crayfish²⁴.

In a series of 34 patients from Oahu, Hawaii, the most common presenting clinical sign was headache (90%) followed by vomiting (56%), neck stiffness (56%) and paraesthesia (54%).²⁴² The sources of the infection were predominantly raw snail/slugs or undercooked crustaceans although 20 out of the 34 had no apparent history of exposure to an intermediate or paratenic host. The incubation period ranged from 2 to 18 days. Clinical signs tended to resolve within 2 weeks except for paraesthesia, which in some patients took several months to improve. As with most reported cohorts clinical signs were more severe in children and ranged from facial and extremity weakness to seizures. No patients received any specific treatment but all tended to improve following lumbar puncture. Eosinophilic pleocytosis was evident for several months despite clinical improvement.

Clinical Presentations

Neurological manifestations

The clinical manifestation of neural angiostrongyliasis may be related to neuritic, radiculitic, meningitic, meningoencephalitic, myelitic and ocular lesions. The development of clinical signs reflects the parasitic invasion of nervous system. The severity of the disease is considered to be proportional to the number of ingested larvae².

Eosinophilic Meningitis

This is present in 97% of human clinical case and is characterised by a low mortality and benign course. The majority of patients experience intense headaches, vomiting and neck pain. Some may be febrile. Occasionally signs of photophobia and retro-orbital pain may be seen. Rarely, cranial nerves may be affected. Paresthesia and hyperesthesia are usually evident, often asymmetrical and in a variety of anatomic locations².

Eosinophilic Meningoencephalitis

Clinical signs tend to more severe and associated with altered consciousness. Coma, seizures, mental changes (stupor, agitation and psychotic episodes), weakness, ataxia, tremor and spasticity of the limbs may be evident. The signs tend to occur early on in the disease and persist for varying lengths of time. Gross cerebral symptoms such as hemiplegia, aphasia or hemianopsia have not been reported. This is likely to be due to the small size of the tracts made by the migrating larvae. Small numbers are unlikely to have much affect, however large number of migrating larvae will cause severe neurotrauma.

Radiculomyelitis

This is often characterised by hyperaesthesia, paresthesia and dysesthesia asymmetrically distributed over the body. These clinical signs often display a “migratory pattern”. They may also be accompanied by sensory loss associated with hyporeflexia and muscle wasting, urinary and/or faecal incontinence. Clinical signs of radiculopathy tend to resolve within weeks but may persist for months.

Cranial Neuropathy

In rare cases, cranial nerve deficits may be the only clinical signs evident. Facial, abducens and ocular nerve palsies have been documented and clinical signs can become permanent. In rats, larvae have been observed migrating along the nerve sheath of the optic nerve; presumably this is the mechanism of disease associated with the cranial nerve palsy² or it may be due to involvement of the subservant motor nuclei within the brain stem.

With CNS disease, irrespective of the presenting clinical signs, most cases tend to be self-limiting and recovery is complete. Some patients, however, can have permanent sequelae. These cases are discussed elsewhere. The length of time a patient takes to recover ranges from 1 to 2 weeks to over 6 months.²⁴³

Ocular Disease

Ocular disease appears to be a recognised entity in humans with EME due to *A cantonensis*. In a report of 484 cases, 47 (16%) had evidence of parasites within the eye and of those 47 cases, 7 had actively motile worms visualised within the vitreous.⁵⁹ Complications include intraocular haemorrhage, panuveitis, disc oedema and retinal detachment.²⁴⁴ There have also been a small number of cases reported where ocular disease is the only presenting sign.^{244,245}

The presence of larvae within the eye seen in human case reports is either due migration through the space between the optic nerve and the sheath or haematogenous spread. The larvae tend to be 5th stage and clinical signs often resolve with their removal from the ocular chamber.²⁴⁴ Considering that in the majority of these patients ocular disease is the only manifestation of disease, perhaps only small numbers of larvae may have been ingested and the concurrent migration through the CNS may go undetected.

Pulmonary Disease

Information regarding lung disease is scarce although reported in the very first clinical case of angiostrongyliasis in 1945.⁷ Two recent reports of fatal infections in children in Australia demonstrated *A cantonensis* adults within the lungs.⁴⁰ The infections have not been patent. Patients tend to display symptoms associated with pneumonia; coughing, expectoration, etc.

Paediatric Infections

Infections in children appear to represent a significant proportion of cases reported in many countries and clinically they are generally more severely affected than adults.¹⁰³ In a case series of 125 Taiwanese patients, 88 patients (70%) were less than 10 years-of-age.²²² Eight of these were less than 2-years-old and within this group, 4 died and the surviving 4 became blind or had permanent mental disabilities. In a Hawaiian series of 19 patients, 6 were children less than 10 years of age.²⁴⁶ In Australia, the cases appear in predominantly young adults however, more recently there have been a

number of case reports in children.^{6,68,69,184,247} Southeast Asia's habit of eating raw snails accounts for many of the cases involving adults, outside of this region, however, children are more frequently affected.¹⁰³ For example, in Brisbane, an 11-month-old girl presented for altered mentation and myoclonic jerking of the legs and blindness.¹²³ Over a 3-year period she became profoundly physically and intellectually handicapped. While she did not display an eosinophilic pleocytosis within the CSF, serology was positive for both serum and CSF and *A cantonensis* was evident in rats, slugs and planarians found in the child's environment.

The route of infection is unknown in many of these cases but the authors all speculate on the possibility of direct ingestion of intermediate hosts like slugs and snails or paratenic hosts such as planarians.^{103,123} Certainly infants have been seen with slugs and snails in their mouths and considering terrestrial species of molluscs, like *Helicario spp*, can harbour over 1000 larvae, it would only take one snail to be eaten or "mouthed" to produce clinical disease.¹²³

Angiostrongylus cantonensis is without doubt a highly pathogenic organism but it would appear that the disease and sequelae in children are far more devastating than adults. The clinical severity of the disease in children is a reflection of the larval burden, the immaturity of the immune system and the relatively short migrating distances involved.¹²³

Atypical Manifestations of Angiostrongyliasis

While the most common presenting signs in adults are headache, neck pain and vomiting there are a number of cases with unusual clinical presentations ranging from focal neuropathies to permanent sequale, coma and death.⁵⁹ A recent report described a 59-year-old women presenting with hearing loss and headache over one month.²⁴⁸ Testing confirmed a sensorineuronal hearing loss secondary to eosinophilic meningitis. The woman had eaten raw snails one week before the onset of clinical signs and has a positive ELISA on serum using the 29 kDa antigen. She made a complete recovery with glucocorticoids for 2 weeks and paracetamol as required.

More recently a chronic pain syndrome has been reported in some patients.^{144,145} Three cases, all of which were infected in Fiji, developed chronic limb pain associated with spinal radiculopathies.¹⁴⁴ Two of the patients had typical signs of EME with cranial nerve involvement and while these signs resolved with standard therapy, limb and lumbar hyperaesthesia did not. The authors speculated that periradicular granulomas formed following the death of the larvae. Two of the patients

had equivocal antibody titres and they speculate that this maybe due to heavy antigen burdens reducing the circulating levels of antibody.

Abscessation with the CNS associated with individual larvae has been reported as a chronic consequence of infection with *A cantonensis*.²⁴⁹ A 45-year-old man presented for right focal tonic-clonic seizures. A 2 cm diameter lesion in the left parietal region was demonstrable on CT. The lesion was surgically explored and found to be an abscess containing a larval nematode, later identified as *A cantonensis*. A 26-year-old male presenting with chronic left leg and lumbar paresthesia was diagnosed with a myelopathy.⁷³ MRI demonstrated an intramedullary lesion compressing the spinal cord. The area was biopsied and a hemilaminectomy undertaken. Histopathology revealed sections of a nematode within an area of necrosis and inflammation. The nematode was later identified as *A cantonensis*. In both cases no CSF was obtained prior to surgery and there was no evidence of chronic headache, neck pain or other signs suggestive of a meningoencephalopathy.

In severe cases, patients can present comatose. In a series of 11 patients with a median age of 45 years (range 30 to 61) presenting for coma, 10 died and the one surviving patient was still in a coma when the article was published despite treatment with glucocorticoids.⁸⁰

Appendix 2

Angiostrongyliasis in Other Species

Australia

By far the majority of infections reported in animals have occurred in Australia. The very first report, published in 1978, concerned a Bennett's wallaby (*Macropus rufogriseus*).¹⁶ The wallaby displayed progressive neurological signs over a 7-day period and died. At necropsy, *A cantonensis* larvae were identified in the meninges and brain parenchyma. The spinal cord was not examined. The author suggested that the wallaby became infected by ingestion of contaminated food rather than direct ingestion of an infected mollusc.

Neural angiostrongyliasis has been diagnosed in two foals (4-months and 7-months of age) in Southeast Queensland, both of which received anthelmintics either just prior or soon after the onset of clinical signs.⁶⁴ Both foals were euthanased. Peripheral eosinophilia was not evident in either case. CSF from one foal demonstrated marked eosinophilic pleocytosis (75%). The location of larvae and the appearance of lesions resembled the disease in dogs.

Three captive rufous bettongs (*Aepyprymnus rufescens*) with clinical signs suggestive of EME had *A cantonensis* recovered from CNS tissue samples.⁶⁶ All three were euthanased due to progressive disease and failure to respond to glucocorticoid therapy. One of the bettongs received levamisole orally with no improvement in clinical signs and at necropsy living larvae were recovered from the brain.

Five adult captive tamarins (*Sanguinus spp*) were diagnosed with EME and on necropsy histology identified *A cantonensis*.⁶⁵ All except one case initially improved with glucocorticoid administration and then relapsed 2 to 4 months later and died. Assuming an incubation period similar to dogs and humans, this might indicate reinfection and lack of acquired immunity. The length of clinical disease in tamarins is protracted with 3 of the 5 cases displaying clinical signs for over 8 weeks despite treatment. None of the tamarins received anthelmintics as part of the therapy during the treatment period.

Three captive grey-headed fruit bats (*Pteropus poliocephalus*) died following progression CNS dysfunction.²⁰ Necropsy demonstrated severe eosinophilic meningoencephalitis. Many *A cantonensis* adults were present within the meninges. Another bat, housed in the same environment in North-western Sydney, developed clinical signs associated with neural angiostrongyliasis. The three bats that died were all treated with glucocorticoids. Two remaining fruit bats were also given fenbendazole (10mg/kg orally daily for 5 days) and they recovered uneventfully. All 6 cases occurred between April and May.

While the majority of neural angiostrongyliasis occurs in captive or domestic species, recently the disease has been described in free-living flying foxes (*Pteropus* spp) and tawny frogmouths (*Podargus strigoides*). Flying foxes with neurological disease from Queensland and North-Eastern New South Wales are routinely necropsied to determine the extent of lyssavirus infection with the native population. Of 86 specimens, 16 (19%) necropsied between November 1997 to November 2000 had *A cantonensis* present within the CNS.¹⁹ None were positive for lyssavirus. All of the cases were from South-Eastern Queensland and occurred between April and June or October and December. In Sydney, there have been a number of reported deaths in native tawny frogmouths due to *A cantonensis*.²⁵⁰ To date, 16 cases have been reported to the Australian Wildlife Registry of Pathology and all have occurred between March and July (Richard Montali, personal communication). The disease appears to be increasing in its frequency in this species. A wild brush tail possum (*Trichosurus vulpecular*) and a yellow tailed black cockatoo (*Calyptorhynchus funereus*) have also been diagnosed with eosinophilic meningoencephalitis due to *A cantonensis*.²⁵⁰ Most recently a captive Fennec Fox (*Fennecus zerda*) appears to have been infected at Taronga Zoo, Sydney were a number of macropods and primates have also been diagnosed with the disease, attributable to a substantial rat population (unpublished data).

Americas

The disease has been reported in North and Central America in a howler monkey (*Alouatta caraya*) and a white-handed gibbon (*Hylobates* sp) in New Orleans and the Bahamas, respectively.⁶³ Both animals developed ataxia and lethargy, and the gibbon vomited several times just prior to death. They both received glucocorticoids and anthelmintics but died despite therapy. Clinical signs were apparent for approximately three weeks in both cases. Nematodes were seen in histological sections from the CNS of both primates and *A cantonensis* was identified in rats in the surrounding areas. More

recently, the parasite has been identified as the cause of EME in a 5-month-old American Miniature horse²⁵¹, a lemur (*Varencia var rubra*), and several opossums (*Didelphis virginiana*) all within the state of Louisiana.¹⁸ *A cantonensis* has been identified in native and domestic rats and is now considered endemic to Louisiana.^{18,33}

Appendix 3

Letter sent to all registered Small Animal Specialists and Veterinary Pathologists in Queensland and New South Wales

«Title» «FirstName» «LastName»
«Company»
«Address1»

Monday 19th May 2003

Re: Eosinophilic Meningoencephalitis: neural angiostrongyliasis

Dear «Title» «LastName»,

I am currently undertaking a Masters in Veterinary Clinical Studies at the Veterinary Teaching Hospital, University of Sydney. The main aim of the project is to improve an ELISA used to diagnose canine neural angiostrongyliasis (CNA). Characteristically, the disease is associated with:

- Young dogs
- History of contact with infected slugs and snails.
- Progressive clinical signs characterised by ascending CNS (UMN or LMN) dysfunction and hyperaesthesia.
- Peripheral eosinophilia
- Marked eosinophilic pleocytosis of CSF.
- Improvement after treatment with corticosteroids.

I would greatly appreciate your help in identifying any suspected cases of CNA that you may have or have seen in your practice.

Ideally I would require the history with particular regard to onset of clinical signs post contact with slugs/snails (infected material) and their worming/heartworm prophylaxis status as well as any clinical pathology reports. Serum and CSF samples would be particularly helpful. If possible serial serum samples two weeks apart would be very useful.

Samples from cases that do not appear to be due to infection with *A. cantonensis* but have similar signalment or presentation would be useful in testing the validity of the ELISA or identifying atypical cases.

Currently, the ELISA takes 2 weeks to run and would not greatly facilitate case management, but we are hoping to ultimately reduce the time interval. If you have any questions or require any more information please contact me at the Veterinary Teaching Hospital either by phone: (02) 9351 3437; or email: jalunn@vetc.usyd.edu.au. Please do not hesitate to contact me if you have any further questions.

Yours sincerely,

Julian Lunn BVSc MACVSc
University Veterinary Centre, Sydney
Faculty of Veterinary Science
University of Sydney
NSW 2006

Attention:

Address:

Fax number:

Dear,

Thank you for contacting me regarding your suspected case. There are just a few questions that would help with our research. The sheet can be faxed back to the University Veterinary Centre, Sydney when you have finished. Below is some background information on the disease and the Masters project

Background: Neural Angiostrongylosis

The most common cause of eosinophilic meningoencephalitis (EME) in humans is neural angiostrongyliasis caused by migrating larvae of the rat lungworm *Angiostrongylus cantonensis*. *A. cantonensis* is found throughout the tropical regions of Oceania (South East Asia and Australia) and Central America. In animals species affected include dogs, cats, horses and native species of birds (owls and kingfishers), possums and bats.

Diagnosis of the canine form of neural angiostrongyliasis (CNA) is presumptive and based on history, characteristic clinical findings, and eosinophilic pleocytosis in the CSF. Typically these patients are puppies that have been known to eat slugs, snails or possibly rats (definitive host), that have ascending CNS dysfunction, in particular hyperaesthesia, and have marked eosinophilic pleocytosis of the CSF. Definitive diagnosis has only been obtained at necropsy. However there is an ELISA that is available in humans which shows promise in definitively diagnosing CNA.

Treatment in dogs is confined to immunosuppressive therapy, mainly prednisolone. The pathology of the disease in young animals is thought to be mainly due to the non-definitive host's inappropriate reaction to the migrating parasitic larvae. It is thought that dead or dying larvae produce much more profound inflammation. Consequently the use of anthelmintics in dogs with suspected neural angiostrongyliasis has been found, at least in Australia, to worsen the disease. This is not the case in humans where anthelmintics are commonly used to treat eosinophilic meningoencephalitis due to *A. cantonensis*.

The Project

The main aim of the Masters is to try and improve the ELISA. In Australia the ELISA uses a fairly impure antigen based on the 4th stage larvae of *A. cantonensis*. The ELISA can be run on serum or CSF and certainly in humans it appears that serum is more sensitive. However there is a problem with the test's specificity when using serum, as there is significant cross-reactivity with other strongyloids. Obviously using serum to test for CNA would be preferable so work needs to be done on improving the specificity of the ELISA. Once the ELISA has been established we can then use it to aid the diagnosis in clinical cases.

Stage 1 would be to obtain/make the purified antigens or monoclonal antibodies and then retest all of the samples we have from suspected cases of CNA (both from cases at the UVCS and from other clinics). This would tell us whether or not ELISA is a worthwhile tool in the diagnosis of CNA. The majority of cases of CNA in Australia occur in Queensland so obtaining more samples to validate the ELISA would be beneficial.

Samples

Serum and CSF are desirable if available. Serial serum samples taken every 2 weeks for 8 weeks after the diagnosis would be extremely helpful! Please note that you can take whole clotted blood and leave it in a fridge overnight before extracting the serum and freezing it if you do not have a centrifuge.

Thank you again for your time in filling in the attached form. Your cooperation is greatly appreciated.
Yours sincerely

Julian Lunn BVSc MACVSc
University Veterinary Centre, Sydney
Evelyn Williams Building B10
Faculty of Veterinary Science
University of Sydney NSW 2006

Appendix 4

Case Details

Outlined below are the case details from Mason thesis published in 1983¹⁴, the details of Control Group B and all of the prospective cases including one atypical case involving a litter of Greyhound puppies.

The next page contains the details of Mason 's 55 naturally occurring cases.

Case ID	Location	Treatment	Breed	Age (wks)	Sex	Month	Protein (g/L)	Nucleated Cells (x 10 ⁶ /L)	Eythrocytes (x 10 ⁶ /L)	% eosinophils	Abdsolute counts	Peripheral Eosinophils	Post-mortem Confirmation
1		Supportive only	Cocker Spaniel	9	M	October					0		
2		Glucocorticoids + Supportive care	Border Colli	9	M	October	0.12	4200	1700	88%	3,696	4.3	
3	Euthanased	Glucocorticoids + Supportive care	Daschnund	14	M	January		7125	1200	85%	6,056	1.6	
4	Died	Glucocorticoids + Anthelmintics	Cross Bred	7	F	June					0		Y
5	Euthanased	Supportive only	Greyhound	7	F	April					0		Y
6	Euthanased	Supportive only	Greyhound	7	M	April					0	3	Y
7	Euthanased	Supportive only	Greyhound	7	M	April					0	0.2	
8	Euthanased	Supportive only	Greyhound	7	M	April					0	0.1	Y
9	Euthanased	Supportive only	Greyhound	7	F	April					0		
10	Euthanased	Supportive only	Greyhound	7	F	April					0		
11	Euthanased	Glucocorticoids + Supportive care	GSD	9	F	May					0		
12		Glucocorticoids + Supportive care	Beagle	8	M	November					0	0*	Y
13	Euthanased	Supportive only	Kelpie	6	F	December		3680	411	75%	2,760	0.1	
14	Euthanased	Supportive only	Kelpie	7	M	December		1300	few	81%	1,053	1	
15	Died	Anthelmintics + Supportive care	Labrador	8	F	April		2307	750	88%	2,030	0.5	Y
16	Euthanased	Supportive only	Greyhound	10	F	July	0.43	4600	1500	74%	3,404	3.4	Y
17	Euthanased	Supportive only	Greyhound	8	M	July		2700	230	66%	1,782		Y
18	Euthanased	Supportive only	Greyhound	10	M	July	1.62	7750	0	87%	6,743	0.8	
19	Euthanased	Supportive only	Greyhound	9	M	July	0.13	284	159	86%	244	0.2	
20	Euthanased	Supportive only	Greyhound	10	F	May		265	34	37%	98	0.4	
21	Euthanased	Supportive only	Corgie	9	F	April	2.3	1350	38	78%	1,053	0.5	
22	Euthanased	Supportive only	Labrador	7	M	December		90	50	61%	55	1.6	Y
23	Euthanased	Supportive only	Labrador	10	F	March					0		
24	Died	Anthelmintics + Supportive care	Bull Terrier	7	M	April					0		
25		Anthelmintics + Supportive care	Bull Terrier	9	M	April					0		
26		Glucocorticoids + Supportive care	Labrador	9	M	March					0		
27	Euthanased	Supportive only	GSD	7	F	February		1250	300	82%	1,025	2.5	
28	Euthanased	Supportive only	GSD	7	M	February	0.2	2264	150	64%	1,449		
29	Euthanased	Supportive only	Greyhound	8	M	April	0.25	2812	0	86%	2,418		
30		Glucocorticoids + Supportive care	Greyhound	11	M	June					0		
31	Euthanased	Supportive only	Greyhound	10	F	June	0.32	1280	90	89%	1,139	0.3	
32		Glucocorticoids + Supportive care	Greyhound	11	F	June	0.18	3250	5	81%	2,633	2.5	
33		Glucocorticoids + Supportive care	Greyhound	11	M	June	0.19	1465	15	84%	1,231	2.3	
34		Glucocorticoids + Supportive care	Greyhound	11	F	June	0.23	240	0	94%	226	1.4	
35		Supportive only	Labrador	11	M	April		20	340	100%	20	0.7	
36		Glucocorticoids + Supportive care	Afgan	11	M	June	0.43	2300	few	74%	1,702	4.3	
37		Glucocorticoids + Supportive care	Beagle	10	M	May	0.12	83	few	71%	59	1.05	
38	Euthanased	Supportive only	ld English Sheepdog	9	F	July	0.4	2376	180	81%	1,925		
39		Glucocorticoids + Supportive care	ld English Sheepdog	10	M	July	0.11	7106	3500	94%	6,680	2.81	Y
40		Glucocorticoids + Supportive care	ld English Sheepdog	9	F	July	0.12	1197	0	86%	1,029	9.36	
41		Glucocorticoids + Supportive care	ld English Sheepdog	9	M	July	0.12	2510	0	92%	2,309	7.04	
42		Glucocorticoids + Supportive care	Borzo	8	F	November		512	few	85%	435	2.19	
43	Euthanased	Glucocorticoids + Supportive care	Daschnund	12	M	October		2800	150	59%	1,652		
44		Glucocorticoids + Supportive care	Greyhound	8	M	July	0.92	700	2000	66%	462	0.38	Y
45	Euthanased	Supportive only	Greyhound	10	M	May		1760	200	79%	1,390	0.08	
46	Died	Glucocorticoids + Anthelmintics	Greyhound	9	M	July	2.1	450	900	21%	95	0.1	Y
47		Glucocorticoids + Supportive care	Greyhound	9	F	July					0	0.1*	
48	Euthanased	Supportive only	Greyhound	20	M	May					0	0*	
49		Glucocorticoids + Supportive care	Labrador	12	F	November		406	0	63%	256		Y
50		Glucocorticoids + Anthelmintics	Great Dane	20	F	April	0.9	1590	8	22%	350	1.8	
51		Glucocorticoids + Supportive care	Great Dane	28	M	February	0.6	2750	0	75%	2,063		
52		Glucocorticoids + Supportive care	Poodle	14	M	May	2.4	250	0	60%	150	0.8	
53	Died	Glucocorticoids + Anthelmintics	Weimaraner	12	F	April	0.5	490	130	90%	441	*	
54	Died	Glucocorticoids + Anthelmintics	Greyhound	16	M	May		2880	0	80%	2,304	*	Y
55	Euthanased	Glucocorticoids + Supportive care	Labrador	9	M	February	0.13	6125	5700	81%	4,961		
			Average	10			0.62	2224		75%	1,225		
			Median	9			0.29	1675		81%	435		

lility Rate 59% (33 of 55)

Control Group B Case Details

Control Group B – Serum Controls			
Sample No	Sex	Age (weeks)	Breed
1	MN	208	Doberman cross
2	FN	416	Curly coated Retriever
3	MN	468	Dalmatian
4	MN	312	Malamute
5	ME	48	Staffordshire Bull Terrier
6	ME	36	Papillion
7	FE	260	Staffordshire Bull Terrier
8	FN	208	German Shepherd
9	ME	24	Labrador
10	ME	20	Yorkshire Terrier
11	FE	28	Hungarian Vizla
13	MN	468	Kelpie
14	MN	624	Mastiff cross
15	MN	48	Boxer
16	MN	40	Golden Retriever
17	MN	156	German Shepherd
18	MN	156	Staffordshire Bull Terrier
19	FN	468	German Shepherd
20	FE	104	Doberman
21	FN	624	Cocker Spaniel
22	MN	312	Labrador cross
	Median	208	

Control Group B. All samples were collected from dogs with no appreciable CNS dysfunction undergoing desexing or orthopaedic procedures during May 2005. MN = castrated male, ME = entire male, FN = spayed female, FE = entire female.

Canine Neural Angiostrongyliasis Case Details

Case 1: Labrador Retriever, 6-month-old MN (Eastwood, NSW, May, 2004)

Initial presentation was for lethargy and mild neck pain. The dog had no history of slug or snail ingestion. Clinical signs progressed to severe neck pain and forelimb hyperaesthesia. There was no response to NSAID therapy and the most prominent haematological abnormality was a substantial eosinophilia. Subsequent CSF analysis revealed eosinophilic pleocytosis. Glucocorticoid therapy was commenced and the dog improved within 24 hours. The dog had been given an injectable heartworm prophylaxis given 2 months before onset of clinical signs. Therapy was continued for 8 weeks and the dog made a full recovery.

Case 2: Golden Retriever, 5-month-old FE (Bellevue Hill, NSW, May, 2002)

Presented for hind limb ataxia and urinary/faecal incontinence. Dog had been know to eat slugs and snails all of the time. Two days prior to presentation the owners had noticed that the dog had become ataxic in the hind limbs and was urinating and defecating in the house, which it had not done before. On presentation, the dog could stand but was paraparetic with proprioceptive deficits, reduce patella tendon reflexes and mild muscle atrophy, worse in the left leg. The bladder was easily expressed and the dog was painful around the lumbar region. The dog had been given topical imidacloprid and ivermectin 5 days before the onset of clinical signs. Following CSF results then dog was treated with intravenous glucocorticoids initially. The dog improved significantly over 24 hours and was able to walk unassisted. Seven days after presentation the incontinence was still evident although otherwise the dog was significantly better with no lumbar hyperaesthesia and only mild proprioceptive deficits. The dose of glucocorticoids was lowered from 1mg/kg BID to 1/2mg/kg however clinical signs worsened over the subsequent 7 days and the dose was increased to the original level. Three weeks after initial presentation the dog developed vomiting which was treated with dietary modification, the neurological exam was normal and the dose of glucocorticoids was reduced. Two months following the initial diagnosis the dog was diagnosed with generalised focal demodecosis and the glucocorticoids were stopped. The dog was treated successfully with topical amitraz therapy.

Case 3: Kelpie, 6-month-old FN (Redfern, NSW, May, 2001)

Dog presented 5 days after a routine desexing operation for lethargy. The most significant physical finding was pain on manipulation of the tail and during a rectal exam. The dog had been seen eating slugs and snails on a number of occasions. Hyperaesthesia progressed to involve the hind legs

and lumbar region over the subsequent 3 days and there were no proprioceptive deficits in either hind leg. The following day the dog had neck pain and was ataxic in the hind legs. A CSF exam revealed eosinophilic pleocytosis and there was a mild peripheral eosinophilia. The dog was treated with glucocorticoids and significantly improved over the following 24 hours. The dog was clinically normal six weeks after the initial presentation. Glucocorticoids were stopped 3 months after the commencement of treatment. Published in the Australian Veterinary Journal (2003; 3:128-131).

Case 4: Golden Retriever, 4-month-old FE (Oyster Bay, NSW, March, 2002)

Dog presented for sudden onset of hind limb paresis and urinary incontinence. The clinical signs had progressively worsened over 3 days prior to presentation. On initial consultation, the dog was unable to stand on its hind legs, was painful around the hindquarters and lumbar regions and the bladder was easily expressible. There was significant hind limb muscle atrophy bilaterally, reduced or absent proprioceptive deficits and increased patella tendon reflexes with the left more exaggerated than the right. Haematology and serum biochemistry were unremarkable. Within 12 hours the dog's neurological status had deteriorated; forelimb weakness was now evident, anal tone and hind limb proprioception were absent and there was now clonus associated with patella tendon reflexes. The dog had reduced pupillary light reflexes and shied away from light. CSF analysis revealed an eosinophilic pleocytosis and glucocorticoid therapy was commenced. Within 12 hours of commencing treatment the dog had improved significantly and was now able to stand. The ocular examination showed reduced pupillary light reflexes bilaterally but the dog appeared much less painful. Over the following 7 days the dog continued to improve although the urinary incontinence and hind limb ataxia persisted for another 2 weeks. Glucocorticoids were discontinued after 4 weeks of treatment.

Case 5: Boxer, 4-month-old FE (Balgowlah, NSW, May, 2002)

The dog presented for a 3-day history of lumbar spinal pain and intermittent diarrhoea. On physical examination the most significant finding was pain associated with flexion of the neck. Biochemistry and haematology were unremarkable and neurologically the dog appeared normal apart from cervical pain. CSF analysis revealed an eosinophilic pleocytosis. There was no serological evidence for a *Neospora caninum* infection. There were no significant findings in spinal radiographs. Glucocorticoid therapy was commenced in concert with clindamycin. The dog was clinically normal within 2 days. Glucocorticoid therapy continued for another 5 weeks.

Case 6: Miniature Poodle, 4-month-old ME (St Ives, NSW, May, 2002)

The dog presented 10 days after a routine vaccination with hind limb weakness and severe generalised hyperaesthesia especially around the neck and lumbar spine. The clinical signs had begun three days before presentation but had worsened despite the use of carprofen. On physical examination the dog had generalised hyperaesthesia, proprioceptive deficits bilaterally in the hind legs along with reduced reflexes and weakness, worse on the left. CSF analysis demonstrated an eosinophilic pleocytosis and glucocorticoid therapy was commenced. The dog improved substantially over the following 12 hours. Within two days only lumbar hyperaesthesia was evident. Within one month the dog was clinically normal and glucocorticoids were continued for six weeks in total.

Case 7: Rottweiler X, 4-month-old ME (Albany Creek, QLD, June, 2003)

The dog presented for sudden onset of hind limb ataxia and hyperaesthesia. This progressed over 2 days to faecal and urinary incontinence, LMN signs in the hind legs and neck pain. There was no history of ingestion of slugs or snails. Biochemistry and haematology were unremarkable. CSF analysis demonstrated eosinophilic pleocytosis. Glucocorticoid therapy was commenced and the dog made a complete recovery over a 4-week period.

Case 8: Beagle, 5-month-old FE (Ashgrove, QLD, July 2003)

Dog presented for episodes of extending the neck and crying out in pain for the previous three days. The dog had been given NSAIDs, but with little improvement. The only significant finding on physical exam was neck pain. CSF analysis revealed an eosinophilic pleocytosis. Glucocorticoid therapy was commenced and the dog appeared pain free within 24 hours. The dog was treated for three months and there was no reoccurrence of the episodes.

Case 9: Australian Cattle Dog, 12-month-old FE (Cleveland, QLD, February 2004)

The dog presented for acute onset of hind limb weakness with pyrexia, vomiting and lethargy. Weakness and ataxia progressed over the following 24 hours to involve the fore limbs. Physical exam demonstrated a lack of menace, with dilated pupils and abnormal pupillary light reflexes as well as tetraparesis. Blood tests were unremarkable. CSF analysis revealed an eosinophilic pleocytosis. The dog responded well to glucocorticoid therapy. The dog was ambulatory within 24 hours and the peripheral blindness appeared to resolve within 48 hours. Therapy was continued for 3 months.

Case 10: Staffordshire terrier, 2-month-old FE (Chatswood, NSW, February, 2005)

Presented for acute onset of hind limb ataxia and lumbar hyperaesthesia. Owners had noticed that the dog had diarrhoea about 2 weeks before presentation. The owner was also aware of a significant rat problem in the area. One of 7 puppies, one had died at birth while the others were normal. On physical exam the dog was lethargic, had hind limb paresis with hyperaesthesia and an easily expressible urinary bladder. The dog had urinary incontinence. Blood tests revealed a mild elevation in CK but were otherwise unremarkable. The dog progressed over the subsequent 24 hours to the point where it had a flaccid tail and was unable to stand. CSF analysis revealed marked eosinophilic pleocytosis. Treatment commenced with glucocorticoids (1mg/kg prednisolone BID) and clindamycin (75mg PO BID). The dog improved over the following 24 hours and was less painful. *Toxoplasma sp* and *Neospora caninum* antibody titres were negative. The dog made a full recovery although the urinary incontinence persisted for 10 days.

Case 11: Labrador, 8-month-old FE (Lindfield, NSW, April 2005)

Presented for decreased activity. The most significant finding on physical was neck pain. The dog had been in a Sydney suburban back yard on the lower North Shore but had also been down to the South Coast of NSW. The neck hyperaesthesia was unresponsive to carprofen. At the time of initial presentation the dog demonstrated a mild peripheral eosinophilia ($1.9 \times 10^9/L$; normal less than $1.5 \times 10^9/L$). The hyperaesthesia progressed to involve the right forelimb. Rectal temperature was normal throughout. CSF analysis demonstrated a marked eosinophilic pleocytosis. Glucocorticoids were dispensed (0.5mg/kg BID) in concert with doxycycline (5mg/kg PO BID). The dog was significantly better within 24 hours and was clinically normal two weeks after treatment commenced. Glucocorticoids were continued for another six weeks (eight weeks in total).

Case 12: Labrador Retriever, 4-year-old FN (Avalon, NSW, August, 2003)

Presented for lethargy and neck pain. There was no history of exposure to slugs or snails. Apart from the neck pain there was occasional asymmetrical facial twitching, which subsequently resolved. Haematology was unremarkable except for mild leukocytosis. Eosinophil numbers were at the high end of the normal range. Biochemistry showed a very mild elevation in CK (339, 0 – 180). The dog responded to opioid analgesia. CSF analysis revealed eosinophilic pleocytosis. Glucocorticoid therapy was commenced and the dog showed minor improvement over the subsequent 24 hours. The dog subsequently made a full recovery.

Case 13: Boxer, 12-month-old ME (Banksia, NSW, May, 2002)

Presented for a chronic history of lethargy, hind limb weakness and altered mentation for two months. Dog had not been on intestinal parasite or heartworm prophylaxis. On physical exam the dog was ataxic on all four legs, had crossed extensor reflexes present in all four legs. The dog was weak in all four legs with reduced reflexes. The dog also had reduced menace reflexes in both eyes. Haematology revealed a mild leukocytosis, with eosinophilia (2.5×10^9 cell/L (0.14 – 1.2)). CSF demonstrated an eosinophilic pleocytosis. Serum was collected for cryptococcal and neosporosis serology and therapy with glucocorticoids and trimethoprim sulphar were initiated. The dog showed no significant improvement over the subsequent four weeks. Azithomycin was added to the regimen but failed to illicit any change. The blood tests were negative for *Neospora* and *Cryptococcus*. Two months after the initial visit (4 months after onset of clinical signs) there was some minor improvement in the dog's ataxia and proprioception, however the owners had noticed some aggressive tendencies in the dog. Faecal examination at this time revealed significant number of *Toxocara canis* eggs. The aggressive behavioural changes worsened over the next 4 months and the dog was euthanased at the owner's request. CSF collected immediately following euthanasia was normal cytologically. A necropsy was not performed.

Case 14: Kelpie, 2-year-old FN (Sunnybank Hills, QLD, July, 2003)

Presented for hyperaesthesia that was not localised and altered mentation. The owner had noted that the dog would suddenly cry in pain, was occasionally running into objects within the house over the past 5 days and was no longer eating well. On physical exam, the dog demonstrated ataxia in all four legs, no menace response and diffuse hyperaesthesia. The dog was anaesthetised and CSF was collected. The cytology reflected and eosinophilic pleocytosis. Glucocorticoid therapy was commenced that the dog made a rapid recovery.

Case 15: Staffordshire Terrier, 10-year-old FN (Brisbane, QLD, November, 2002)

Dog had presented initially for a splenic haemangiosarcoma, which was removed and chemotherapy was administered. One month after the chemotherapy had finished, the dog presented with acute onset of severe lumbar hyperaesthesia and paraplegia. Radiographs did not demonstrate any evidence of vertebral metastases. CSF analysis revealed an eosinophilic pleocytosis. On further questioning it was revealed that the owners lived near industrial estates and had noticed a large population of rats that infested the nearby areas and their own residence. The dog responded to glucocorticoids and recovered uneventfully.

Case 16: Rottweiler X, 4-year-old FN (Erskineville, NSW, April, 2002)

Presented for an acute episode of neck pain that was unresponsive to carprofen. The only significant physical finding was neck pain associated with lateral and ventral flexion of the neck, apparently localised to the region of the 1st or 2nd cervical vertebrae. The episodes of pain increased in frequency over the following 3 days and the dog became more depressed. Plain radiographs and myelography were unremarkable apart from some mild degenerative changes associated with the caudal cervical vertebrae. CSF analysis revealed a moderate non-specific inflammatory response with only 5% eosinophils. Glucocorticoid therapy was commenced and the dog made a full recovery over two weeks. There was no history of ingestions of slugs or snails.

Case 17: Maltese, 2-year-old MN (Shailer Park, QLD, March 2004)

The dog presented for hyperaesthesia characterised by yelping in pain when the owner picked it up. On physical exam the dog had neck pain and conscious proprioception deficits in the fore limbs with mild pyrexia. CSF demonstrated eosinophilic pleocytosis. Glucocorticoid therapy was commenced and the following day the dog appeared normal. Treatment was continued for 8 weeks.

Case 18: Doberman, 11-month-old FN (Charleville, QLD, June 2004)

The dog presented for episodes of what the owner described as head tremors. The first episode was noticed six months previously and they continued to occur over the intervening months, increasing in frequency and duration. At the time of presentation the dog was experiencing several episodes per day. The physical exam was unremarkable. There was a mild eosinophilia on a peripheral blood smear but otherwise the blood results were unremarkable. CT scan of the head and neck revealed no significant abnormalities. CSF analysis demonstrated a mild eosinophilic pleocytosis. The CSF was negative for *N caninum*, *T gondii* antibodies and cryptococcal antigens. Glucocorticoid therapy was commenced, however the dog did not improve. After 3 weeks azothiaprine was added to the regimen but there was no improvement. CSF analysis two months after treatment had been commenced was unremarkable despite the dog's clinical signs.

Case 19: German Shorthair Pointer, 6-year-old ME (Wynnum, QLD, March 2002)

The dog presented with a two week history of bilateral ptosis and anisocoria, which was unresponsive to topical glucocorticoids and systemic carprofen. For the week prior to presentation the dog had become increasingly depressed and appeared to have altered mentation. The most significant findings on physical examination were neck pain, anisocoria and exaggerated menace reflexes. The ocular exam was otherwise normal. CSF analysis demonstrated an eosinophilic pleocytosis.

Glucocorticoid therapy was commenced and initially the dog responded well. However 7 days following the first visit the dog presented for depression, neck pain, anisocoria and weakness. The dog appeared to have normal proprioception in all legs despite the ataxia but the neck pain was more pronounced. The anisocoria was accompanied by ptosis. Intravenous glucocorticoids were administered and the dog's hyperaesthesia improved. However the ocular signs progressed and the dog became blind in both eyes over the subsequent 24 hours. The dog was euthanased at the owner's request. No post mortem was performed.

Case 20: Rhodesian Ridgeback, 8-month-old FE (Rushcutters Bay, NSW, March, 2004)

Presented with progressive hind limb ataxia, lumbar and marked cervical hyperaesthesia, reduced proprioception in the hind legs. The dog was nervous and shying away from being touched. The dog had been given routine intestinal and heartworm prophylaxis within two weeks of clinical signs developing. The dog initially presented for lethargy and severe neck pain after ingesting rotten turkey eggs on the owner's property located on the mid-north coast of NSW. On presentation the significant physical findings were neck pain and lumbar pain. Over the following two days the hyperaesthesia worsened despite analgesia and the administration of glucocorticoids. Mild hind limb ataxia was observed. The dog was sent home on strict rest and observation. A myelogram was performed one week later following little improvement in the dog's condition. The most significant finding on the myelogram was attenuated contrast columns from the level of the 3rd cervical vertebra to cauda equina which was presumed to be caused by diffuse swelling of the spinal cord. Following the myelogram the dog was significantly more ataxic with an exaggerated gait and wide based stance. CSF cytology demonstrated an eosinophilic pleocytosis. Glucocorticoids were re-administered. The dog improved over the subsequent weeks although did develop diarrhoea, which resolved with dietary modification.

Case 21: Rottweiler X, 10-week-old ME (Bundaberg, QLD, May, 2004)

Presented with acute onset of hind limb weakness and ataxia associated with back pain. The owners had not noticed the dog eating slugs or snails. On physical examination, the dog had lumbar hyperaesthesia, hind limb weakness and proprioceptive deficits, increased patella jerk reflexes and urinary/faecal incontinence. The clinical signs progressed over the following two days to the point where the dog could no longer support its own weight. Glucocorticoid therapy was commenced and the dog began improving after 24 hours. With supportive therapy the dog made a full recovery.

Case 22: Bulldog, 4-month-old ME (Cobbity, NSW, November, 2002)

The dog had a history of chronic neck pain, behavioural changes, tetraparesis and apparent central blindness that had progressed over two months with little response to carprofen. On physical examination the dog had reduced pupillary light reflexes and reduced sensation to the face and corneas bilaterally. The dog appeared aware of its surroundings but was unresponsive and tended to adopt a wide base stance. Conscious proprioception appeared to be reduced in all four limbs. Limited biochemistry was unremarkable and the dog's packed red cells and plasma protein were within normal limits. CSF analysis revealed an eosinophilic pleocytosis and the dog was treated with glucocorticoids. Subsequent *Neospora canis* serology was equivocal on serum but negative on CSF. The dog's ataxia improved over the following 4 weeks however behavioural changes worsened and the dog became more aggressive. The owners declined further workup and the dog was euthanased.

Miscellaneous Case Details

Positive Postmortem with no CSF: Greyhound, 8-week-old FE (March, 2003)

In a litter of 6 puppies, 5 developed hind limb paralysis, urinary and faecal incontinence and severe hyperaesthesia. Four died within three days of the onset of clinical signs and at necropsy, one of puppies had changes suggestive of granulomatous encephalitis with the occasional nematode section seen within the granulomas. The dogs had been moved to a new kennel, which was near a former rats nest, and there were many snails seen around the dog's run. The 5th surviving puppy deteriorated despite the use of glucocorticoids. Ivermectin was administered subcutaneously (500µg/kg) in conjunction with the prednisolone and the puppy improved. There was complete resolution of clinical signs within 2 weeks and the puppy made a full recovery. Glucocorticoids were discontinued after 5 weeks. Histopathology on one of the pups that died demonstrated multiple, large, circumscribed pyogranulomatous foci distributed randomly through the white matter of the lumbar, thoracic and cervical spinal cord and medulla. Nematode sections were seen within some of these pyogranulomas.

Appendix 5

ELISA Methods: Antigen Production

Obtaining A cantonensis larvae

A cantonensis larval antigen was obtained from the Department of Parasitology, Institute of Clinical Pathology and Medical Research (ICPMR) at Westmead Hospital. The life cycle of *A cantonensis* was sustained using fresh water snails (*Biomphalaria glabrata*) which were infected through ingestion of plant material contaminated with rat faeces. The rat faeces were collected from Wistar rats (*Rattus norvegicus*), housed in the Department of Parasitology, that had already been infected with *A cantonensis* and contained 1st stage larvae confirmed by the Baerman technique.

Snails were examined at 4 weeks post-exposure to confirm the presence of infective 3rd stage larvae. Wistar rats were then infected by ingestion of the infected snails. This process was facilitated by sedation of a rat with carbon dioxide and introduction of a fresh snail carcass into the rat's mouth. Upon recovery from the sedation the rat ingested the snail. Faeces were collected 2 weeks after infection and examined for the presence of 1st stage larvae. The infected rats showed only mild respiratory signs when initially infected and could be maintained for a number of months readily producing large numbers of 1st stage larvae in the faeces. Weight loss was the most significant clinical finding in the long term, although some rats died from respiratory disease.

A single, infected female Wistar rat was euthanased by inhaling carbon dioxide. At necropsy 13 female and 9 male *A cantonensis* adults were recovered from the right ventricle, pulmonary arteries and bronchii for antigen preparation

Preparation of antigen

Antigen from *A cantonensis* adults was prepared by the Department of Parasitology, ICPMR. Adults recovered as described above were washed in phosphate buffered saline (PBS) (Appendix 3) at room temperature. The process was repeated 3 times. Whole adults were frozen to -70°C in a refrigerator then subsequently freeze-dried to -196°C using liquid nitrogen. The freeze-dried adults were then homogenised with a mortar and pestle in 10 mL of anti-protease buffer (Appendix 3). The resulting solution was stored at 4°C for 24 hours to facilitate the extraction of the proteins. The solution was centrifuged at 3000g for 15 minutes and the resultant supernatant extracted. The supernatant was centrifuged at 100,000g for 90 minutes at 4°C (Beckman Refrigerated

Ultracentrifuge). The resulting supernatant containing the adult antigens was decanted and stored in 500 μ L aliquots at -70°C .

The protein concentration was determined using established techniques.²⁵² A Pierce Bicinchoninic Acid Protein Assay kit was used (Pierce®, Rockford, IL, USA).

Secondary Antibodies

A commercially available anti-dog IgG was used as the secondary antibody. Antibodies to canine Immunoglobulin was generated in rabbits using affinity purified canine IgG (heavy and light chain specific) in a two-step glutaraldehyde method.²⁵³ The rabbit anti-dog IgG was conjugated to horseradish peroxidase (HRP, Sigma®, St Louise, Missouri, USA).

Substrate

Tetramethyl benzidine (TMB) (K-BLUE substrate, ELISA Systems) was used as the substrate for the HRP in the ELISA. One molar phosphoric acid (AnalaR®, BHD Laboratory Supplies, Poole, England) was used to stop the enzymic reaction.

Appendix 6

Phosphate Buffered Saline

Sodium Chloride	160 mg
Potassium Chloride	4 g
Sodium Hydrogen Orthophosphate	23 g
Potassium Dihydrogen Orthophosphate	4 g

Salts were added to two litres of distilled water until completely dissolved. A dilution of 1 in 100 was used as required.

Anti-protease Buffer

Aprotinin (Trasylol, Bayer®)	
Phenylmethylsulfonyl fluoride (PMSF) (Sigma®)	

Blocking Buffer

Milk powder (Diploma, Australia)	5 g
Phosphate buffered saline (PBS)	100 mL
Tween 20	50 µL

Blotto

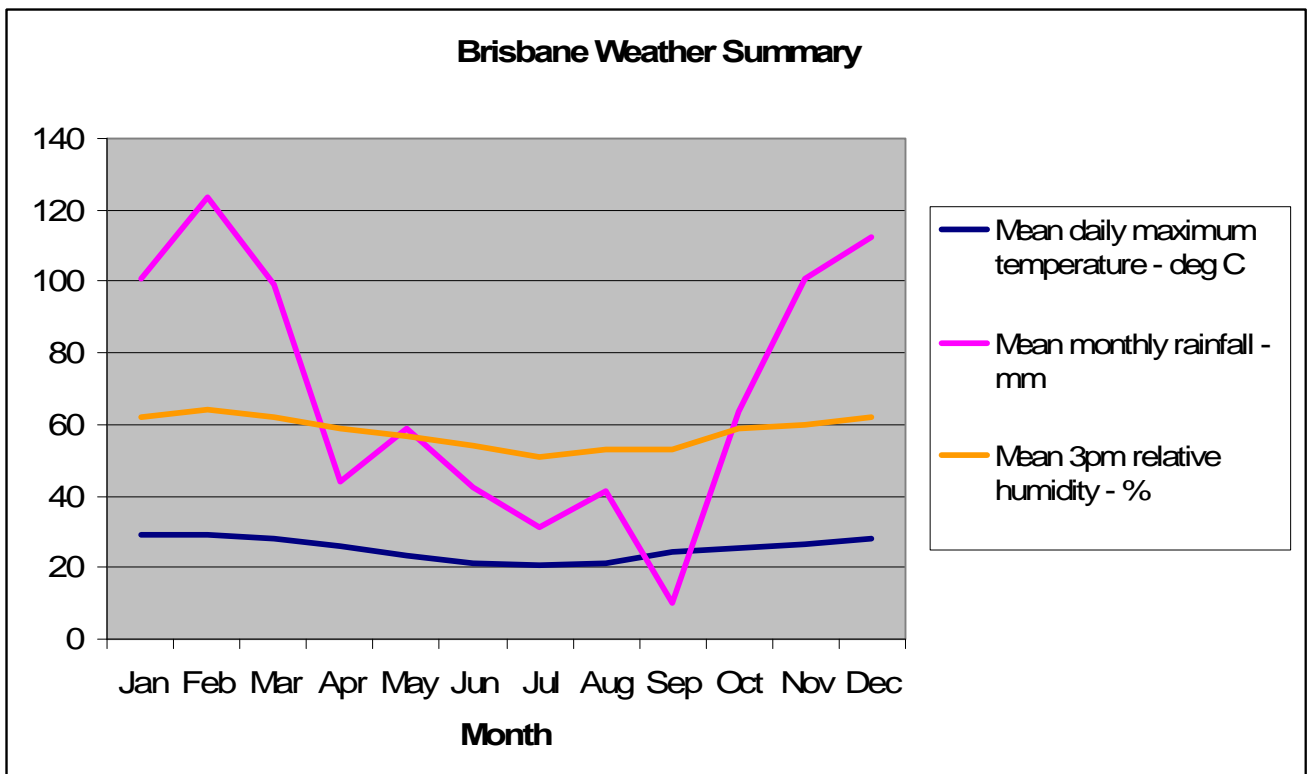
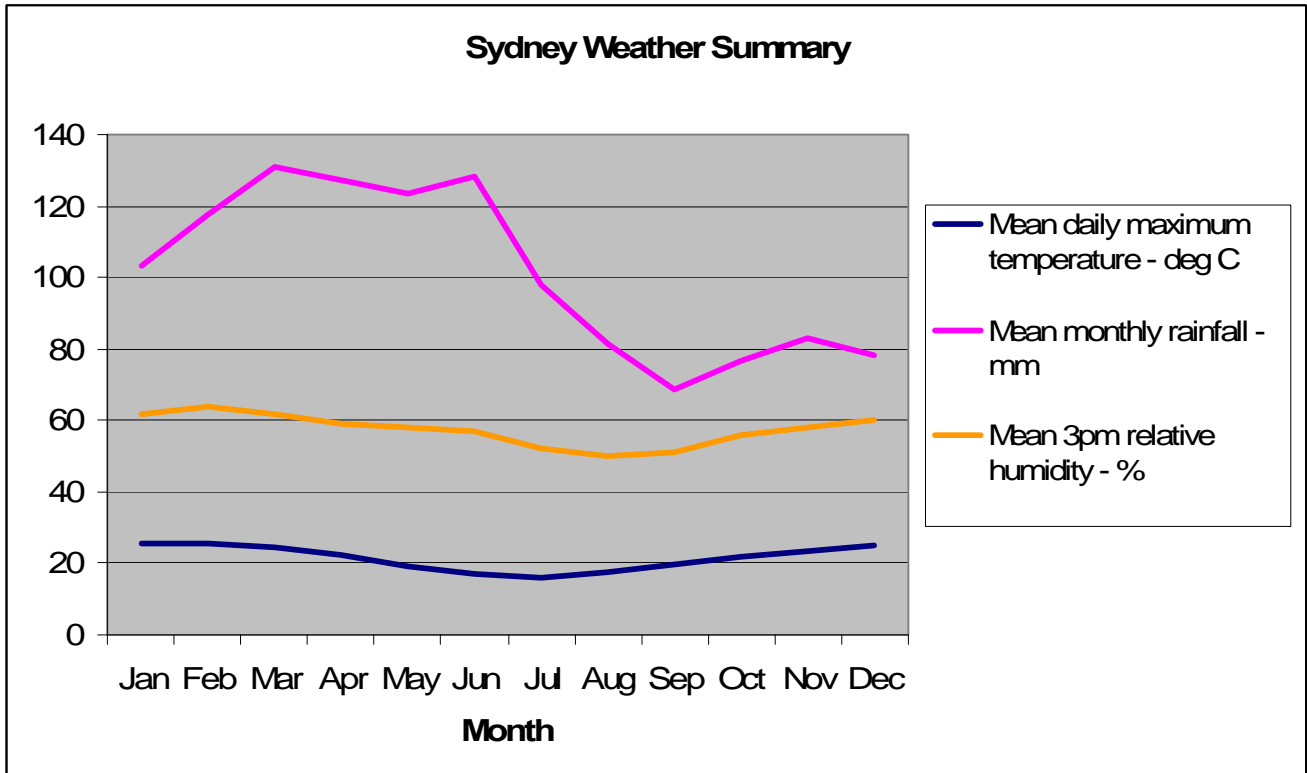
Milk powder (Diploma, Australia)	2 g
Tween 20	100 µL
Sterile water	100 mL

Chromagen Solution

4-chloronaphthol	0.008 g
Methanol	4 mL
H ₂ O ₂	10 µL
PBS	10 mL

Appendix 7

Mean daily temperature, humidity and rainfall for the Sydney and Brisbane regions. Source: Australian Bureau of Meteorology, 2005



References

References

1. Summers BA, Cummings JF, de Lahunta A: Principles of Neuropathology, in Duncan L (ed): Veterinary Neuropathology (ed 1st). St Louis, Mosby, 1995, pp 1 - 56
2. Hung TP, Chen ER: Angiostrongyliasis (*Angiostrongylus cantonensis*). Handbook of Clinical Neurology 52:545-562, 1988
3. Bhaibulaya M: Comparative studies on the life history of *Angiostrongylus mackerrasae* Bhaibulaya, 1968 and *Angiostrongylus cantonensis* (Chen, 1935). International Journal for Parasitology 5:7-20, 1975
4. Akao N, Kondo K, Ohyama TA, et al: Antigens of adult female worm of *Angiostrongylus cantonensis* recognized by infected humans. Japanese Journal of Parasitology 41:225-231, 1992
5. Mackerras MJ, F. SD: The life history of the rat lung-worm *Angiostrongylus cantonensis* (Chen) (Nematoda: Metastrongylidae. Australian Journal of Zoology 3:1 - 25, 1955
6. Prociv P, Spratt DM, Carlisle MS: Neuro-angiostrongyliasis: unresolved issues. International Journal for Parasitology 30:1295-1303, 2000
7. Nomura S, Lin HH: First clinical case of *Haemostrongylus ratti*. Taiwan No Ikai (Japanes Text) 3:589 - 592, 1945
8. Rosen L, Chappel R, Laqueur GL, et al: Eosinophilic meningitis caused by a metastrongyloid lungworm in rats. Journal of the American Medical Association 179:620 - 624, 1962
9. Re VL, 3rd, Gluckman SJ: Eosinophilic meningitis. American Journal of Medicine 114:217-223, 2003
10. Jindrak K, Alicata JE: Comparative pathology in experimental infection of pigs and calves with the larvae of *Angiostrongylus cantonensis*. Journal of Comparative Pathology 78:371 - 382, 1968

11. Jindrak K, Alicata JE: Experimental *Angiostrongylus cantonensis* infection in dogs. *Journal of American Veterinary Research* 31:449 - 456, 1970
12. Mason KV: Haematological and cerebrospinal fluid findings in canine neural angiostrongylosis. *Australian Veterinary Journal* 66:152-154, 1989
13. Mason KV: Canine neural angiostrongylosis: the clinical and therapeutic features of 55 natural cases. *Australian Veterinary Journal* 64:201-203, 1987
14. Mason KV: Naturally acquired *Angiostrongylus cantonensis* infectoin: A cause of ascending paralysis of dogs in the Brisbane area., in Department of Veterinary Medicine. Brisbane, University of Queensland, 1983, p 131
15. Mason KV, Waddell AH, Prescott CW: Naturally acquired *Angiostrongylus cantonensis* infection: a cause of ascending paralysis in pups in the Brisbane area. I. Clinical signs and epidemiology. *Proceedings of the 54th annual conference, Perth, 1977*
16. McKenzie RA, Green PE, Wood AD: *Angiostrongylus cantonensis* infection of the brain of a captive Bennett's wallaby (*Macropus rufogriseus*). *Australian Veterinary Journal* 54:86-88, 1978
17. Lester G: Parasitic encephalomyelitis in horses. *Compendium on Continuing Education for the Practicing Veterinarian* 14:1624-1630, 1992
18. Kim DY, Stewart TB, Bauer RW, et al: *Parastrongylus* (= *Angiostrongylus*) *cantonensis* now endemic in Louisiana wildlife. *Journal of Parasitology* 88:1024-1026, 2002
19. Barrett JL, Carlisle MS, Prociv P: Neuro-angiostrongylosis in wild Black and Grey-headed flying foxes (*Pteropus* spp). *Australian Veterinary Journal* 80:554-558, 2002
20. Reddacliff LA, Bellamy TA, Hartley WJ: *Angiostrongylus cantonensis* infection in grey-headed fruit bats (*Pteropus poliocephalus*). *Australian Veterinary Journal* 77:466-468, 1999
21. Radomyos P, Tungtrongchitr A, Praewanich R, et al: Occurrence of the infective stage of *Angiostrongylus cantonensis* in the yellow tree monitor (*Varanus bengalensis*) in five

- Provinces of Thailand. Southeast Asian Journal of Tropical Medicine & Public Health 25:498-500, 1994
22. Yang F: Observation on the cats and a dog infected by *Angiostrongylus cantonensis* [Parastrongylus cantonensis]. Chinese Journal of Zoonoses 15, 1999
 23. Fernando RL: Angiostrongyliasis, in Fernando RL (ed): Tropical Infectious Diseases. London, Greenwich Medical Media, 2001, pp 107 - 110
 24. Pinn TG: Eosinophilic meningitis. An unusual cause of headache. Australian Family Physician 28:690-691, 1999
 25. Collins GH, Rothwell TLW, Malik R, et al: Angiostrongylosis in dogs in Sydney. Australian Veterinary Journal 69:170-171, 1992
 26. Lunn J, Lee R, Martin P, et al: Antemortem diagnosis of canine neural angiostrongylosis using ELISA.3, 128-131. 121 ref., 2003
 27. Chen HT: A preliminary report on a survey of animal parasites in Canton, China, rats. Lingnan Science Journal 12:65 - 74, 1933
 28. Beaver PC, Rosen L: Memorandum on the first report of *Angiostrongylus* in man by Nomura & Lin, 1945. American Journal of Tropical Medicine & Hygiene 13:589, 1964
 29. Alicata JE: The discovery of *Angiostrongylus cantonensis* as a cause of human eosinophilic meningitis. Parasitology Today 7:151-153, 1991
 30. Bailey CA: An epidemic of eosinophilic meningitis, a previously undescribed disease, occurring in Ponape, Eastern Carolines. Project NM 005 007, Report No 7., in. Bethesda, Maryland, Naval Medical Research Institute, 1948
 31. Kliks MM, Palumbo NE: Eosinophilic meningitis beyond the Pacific Basin: the global dispersal of a peridomestic zoonosis caused by *Angiostrongylus cantonensis*, the nematode lungworm of rats. Social Science & Medicine 34:199-212, 1992

32. Rosen L, Chappel R, Laqueur GL, et al: Eosinophilic meningitis caused by a metastrongyloid lungworm in rats. *Journal of the American Medical Association* 179:620 - 624, 1962
33. Campbell BG, Little MD: The finding of *Angiostrongylus cantonensis* in rats in New Orleans. *American Journal of Tropical Medicine and Hygiene* 38:568-573, 1988
34. Limaye LS, Bhopale MK, Sengupta SR, et al: Transmission of *Angiostrongylus cantonensis* infection to experimental albino rats. *Indian Journal of Helminthology* 42:37-40, 1990
35. Ellis-Pegler R, Parry G: Eosinophilic meningitis due to *Angiostrongylus cantonensis*. *Clinical Infectious Diseases* 35:777-778, 2002
36. Bartschi E, Bordmann G, Blum J, et al: Eosinophilic meningitis due to *Angiostrongylus cantonensis* in Switzerland. *Infection* 2:116-118, 2004
37. Bhaibulaya M: Morphology and taxonomy of major *Angiostrongylus* species of Eastern Asia and Australia. *Studies on angiostrongyliasis in Eastern Asia and Australia US NAMRU* 2:4-13, 1979
38. Bhaibulaya M: Snail borne parasitic zoonoses: angiostrongyliasis. Emerging problems in food borne parasitic zoonosis: impact on agriculture and public health *Proceedings of the 33rd SEAMEO TROPMED Regional Seminar, Chiang Mai, Thailand, 1990*
39. Bhaibulaya M: *Angiostrongylus* spp. in southeast Asia and Australia. *Federacion Latinoamericana de Parasitologos; Asociacion Costarricense de Microbiologia y Parasitologia: IV Latin-American Congress of Parasitology; IV Central American Congress of Microbiology and Parasitology; III National Congress of Microbiology and Parasitology, San Jose, Costa Rica, 7-11 December:1979. 1217-1220., 1976*
40. King T: Canine Neural Angiostrongylosis - An Update, in *Caws and Paws in Crisis, Surfers Paradise*, pp 311 - 327
41. Haigh S: Angiostrongylosis, in *Wildlife Diseases Association (Australian Section) Newsletter*, October 2001/2001, pp 9 - 10

42. Bhaibulaya M: Experimental hybridization of *Angiostrongylus mackerrasae*, Bhaibulaya, 1968 and *Angiostrongylus cantonensis* (Chen, 1935). *International Journal for Parasitology* 4:567-573, 1974
43. Jindrak K, Alicata JE: Experimentally induced *Angiostrongylus cantonensis* infection in dogs. *American Journal of Veterinary Research* 31:449 - 456, 1970
44. Weinstein PP, Rosen L, Laqueur GL, et al: *Angiostrongylus cantonensis* infection in rats and rhesus monkeys, and observations on the survival of the parasite in vitro. *American Journal of Tropical Medicine & Hygiene* 12:358 - 377, 1963
45. Jindrak K, Magnusson MS: Polymyositis and polyneuritis in experimental *Angiostrongylus cantonensis* infection of rabbits. *Annals of Tropical Medicine & Parasitology* 75:205-210, 1981
46. Pan C, Liang S, Ling H, et al: Experimental observation on the distribution of *Angiostrongylus cantonensis* in mice and histopathology of infected mice. *Chinese Journal of Parasitic Disease Control* 13:31-33, 2000
47. Yoshimura K, Soulsby EJJ: *Angiostrongylus cantonensis*: lymphoid cell responsiveness and antibody production in rats. *American Journal of Tropical Medicine & Hygiene* 25:99-107, 1976
48. Watson BJ: The giant African land snail in Australia: pest or nuisance. *Queensland Agricultural Journal* 111:7-10, 1985
49. Sithithaworn P, Brockelman WY, Brockelman C: Transmission of *Angiostrongylus cantonensis* through the giant African snail *Achatina fulica*: an experimental study. *Southeast Asian Journal of Tropical Medicine & Public Health* 22:200-205, 1991
50. Coleman PH: An introduction of *Achatina fulica* to Australia. *Malacological Review* 10:77-78, 1977

51. Alicata JE: Biology and distribution of the rat lungworm, *Angiostrongylus cantonensis*, and its relationship to eosinophilic meningoencephalitis and other neurological disorders of man and animals. *Advances in Parasitology* 3:223 - 248, 1965
52. Drozd J, Gorecka T, Binh NH: The occurrence of nematodes of the subfamily Angiostrongylinae in Viet-Nam and the question of geographical origin of *Parastrongylus cantonensis* (Chen, 1935). *Acta Parasitologica Polonica* 23:115-126, 1975
53. Brown FM, Mohareb EW, Yousif F, et al: *Angiostrongylus* eosinophilic meningitis in Egypt. *Lancet* 348:964-965, 1996
54. Iwanaga Y: Comparative studies on the development of larval *Angiostrongylus cantonensis* in Puerto Rican and Brazilian *Biomphalaria* snails. *Japanese Journal of Tropical Medicine & Hygiene* 30:365-369, 2002
55. Wiscovitch R, Maldonado C, Kozek W. J: Geographical distribution of *Angiostrongylus cantonensis* in Puerto Rico. *Parasitology International* 47:322, 1998
56. Aguiar PH, Morera P, Pascual J: First record of *Angiostrongylus cantonensis* in Cuba. *American Journal of Tropical Medicine & Hygiene* 30:963-965, 1981
57. Noda S, Uchikawa R, Matayoshi S, et al: Observations on the transmission of *Angiostrongylus cantonensis* from snail to rodent. *Journal of Helminthology* 61:241-246, 1987
58. Jaronvesama N, Charoenlarp K, Buranasin P, et al: ELISA testing in cases of clinical angiostrongyliasis in Thailand. *Southeast Asian Journal of Tropical Medicine & Public Health* 16:110-112, 1985
59. Punyagupta S, Juttijudata P, Bunnag T: Eosinophilic meningitis in Thailand. Clinical studies of 484 typical cases probably caused by *Angiostrongylus cantonensis*. *American Journal of Tropical Medicine & Hygiene* 24:921-931, 1975

60. Kanpittaya J, Jitpimolmard S, Tiamkao S, et al: MR findings of eosinophilic meningoencephalitis attributed to *Angiostrongylus cantonensis*. American Journal of Neuroradiology 21:1090-1094, 2000
61. Senanayake SN, Pryor DN, Walker J, et al: First report of human angiostrongyliasis acquired in Sydney. Medical Journal of Australia 179:430 - 431, 2003
62. Slom TJ, Cortese MM, Gerber SI, et al: An outbreak of eosinophilic meningitis caused by *Angiostrongylus cantonensis* in travelers returning from the Caribbean. New England Journal of Medicine 346:668-675, 2002
63. Gardiner CH, Wells S, Gutter AE, et al: Eosinophilic meningoencephalitis due to *Angiostrongylus cantonensis* as the cause of death in captive non-human primates. American Journal of Tropical Medicine & Hygiene 42:70-74, 1990
64. Wright JD, Kelly WR, Waddell AH, et al: Equine neural angiostrongylosis. Australian Veterinary Journal 68:58 - 60, 1991
65. Carlisle MS, Prociv P, Grennan J, et al: Cerebrospinal angiostrongyliasis in five captive tamarins (*Sanguinus spp*). Australian Veterinary Journal 76:167-170, 1998
66. Higgins DP, Carlisle-Nowak MS, Mackie J: Neural angiostrongylosis in three captive rufous bettongs (*Aepyprymnus rufescens*). Australian Veterinary Journal 75:564-566, 1997
67. Gutteridge BH, Bhaibulaya M, Findlater C: Human larval meningitis possibly following lettuce ingestion in Brisbane. Pathology 4:63 - 64, 1972
68. Cooke-Yarborough CM, Kornberg AJ, Hogg GG, et al: A fatal case of angiostrongyliasis in an 11-month-old infant. Medical Journal of Australia 170:541-543, 1999
69. Heaton DC, Gutteridge BH: Angiostrongyliasis in Australia. Australian and New Zealand Journal of Medicine 10:255-256, 1980

70. Cross JH: Experimental studies on *Angiostrongylus* species and strains in monkeys and laboratory animals. Studies on angiostrongyliasis in Eastern Asia and Australia US NAMRU 2:118-137, 1979
71. Shoho C: Observations on rats and rabbits infected with *Angiostrongylus cantonensis* (Chen). British Veterinary Journal 122:251 - 258, 1966
72. Perez O, Capron M, Lastre M, et al: *Angiostrongylus cantonensis*: role of eosinophils in the neurotoxic syndrome (Gordon-like phenomenon). Experimental Parasitology 68:403-413, 1989
73. Petjom S, Chaiwun B, Settakorn J, et al: *Angiostrongylus cantonensis* infection mimicking a spinal cord tumor. Ann Neurol 52:99-101, 2002
74. Caldeira RL, Carvalho OS, Mendonca CLFG, et al: Molecular differentiation of *Angiostrongylus costaricensis*, *A. cantonensis*, and *A. vasorum* by polymerase chain reaction-restriction fragment length polymorphism.8, 1039-1043. 1032 ref., 2003
75. Maizels RM, Yazdanbakhsh M: Immune regulation by helminth parasites: cellular and molecular mechanisms. Nature Reviews: Immunology 3:733 - 744, 2003
76. Yoshimura K, Sugaya H, Ishida K: The role of eosinophils in *Angiostrongylus cantonensis* infection. Parasitology Today 10:231-233, 1994
77. Jindrak K: Early migration and pathogenicity of *Angiostrongylus cantonensis* in laboratory rats. Annals of Tropical Medicine & Parasitology 62:506 - 517, 1968
78. Jindrak K: The pathology of intracranial angiostrongylosis in rats. Journal of Comparative Pathology 80:287 - 296, 1970
79. Mason KV, Prescott CW, Kelly WR, et al: Granulomatous encephalomyelitis of puppies due to *Angiostrongylus cantonensis*. Australian Veterinary Journal 52:295, 1976
80. Chotmongkol V, Sawanyawisuth K: Clinical manifestations and outcome of patients with severe eosinophilic meningoencephalitis presumably caused by *Angiostrongylus cantonensis*. Southeast Asian Journal of Tropical Medicine & Public Health 33:231-234, 2002

81. Vandeveld M: Molecular mechanism in CNS injury - The importance of therapeutic modification of cytokine expression in the brains of domestic animals. *The Veterinary Journal* 168:205 - 206, 2004
82. Summers BA, Cummings JF, de Lahunta A: Inflammatory disease of the central nervous system, in Duncan L (ed): *Veterinary Neuropathology* (ed 1st). St Louis, Mosby, 1995, pp 159 - 170
83. Guyton AC, Hall J: *Textbook of Medical Physiology* (ed 10th Edition). Philadelphia, W B Saunders, 2000, p 1014
84. Sugaya H, Yoshimura K, Abe T: Mediastinal lymph node cells of *Angiostrongylus cantonensis*-infected rats respond to antigens and release interleukin-5 in vitro. *International Journal for Parasitology* 26:543-551, 1996
85. Sugaya H, Ishida K, Yoshimura K: Induction of cerebrospinal fluid eosinophilia in rats by the intraventricular injection of *Angiostrongylus cantonensis* antigen. *International Journal for Parasitology* 27:113-117, 1997
86. Dharmkrong-at A, Sirisinha S: Induction of protective immunity against infection by *Angiostrongylus cantonensis* in rats. *Southeast Asian Journal of Tropical Medicine & Public Health* 16:31-40, 1985
87. Perez O, Lastre M, Capron M, et al: Total and specific IgE in serum and cerebrospinal fluid of rats and guinea pigs infected with *Angiostrongylus cantonensis*. *Parasitology Research* 75:476-481, 1989
88. Ishida K, Yoshimura K: Characterization of monoclonal antibodies against eosinophil chemotactic factors from young adult worms of *Angiostrongylus cantonensis*. *Parasite Immunology* 14:633-644, 1992
89. Ishida K, Yoshimura K: Differences in responses of rat- and guinea-pig-eosinophils to eosinophil chemotactic factors derived from *Angiostrongylus cantonensis*. *Parasite Immunology* 12:269-283, 1990

90. Chang EE, Chung LY, Yen CM: Kinetics of change in the eotaxin concentration in serum and cerebrospinal fluid of mice infected with *Angiostrongylus cantonensis*. 137-141, 2004 January., 2004
91. Du WY, Liao JW, Fan CK, et al: Combined treatment with interleukin-12 and mebendazole lessens the severity of experimental eosinophilic meningitis caused by *Angiostrongylus cantonensis* in ICR mice. *Infection & Immunity* 71:3947-3953, 2003
92. Sugaya H, Aoki M, Yoshida T, et al: Eosinophilia and intracranial worm recovery in interleukin-5 transgenic and interleukin-5 receptor alpha chain-knockout mice infected with *Angiostrongylus cantonensis*. *Parasitology Research* 83:583-590, 1997
93. Shaio MF, Hou SC, Chen JG, et al: Immunoglobulin G-dependent classical complement pathway activation in neutrophil-mediated cytotoxicity to infective larvae of *Angiostrongylus cantonensis*. *Annals of Tropical Medicine & Parasitology* 84:185-191, 1990
94. Sasaki O, Sugaya H, Ishida K, et al: Ablation of eosinophils with anti-IL-5 antibody enhances the survival of intracranial worms of *Angiostrongylus cantonensis* in the mouse. *Parasite Immunology* 15:349-354, 1993
95. Sugaya H, Abe T, Yoshimura K: Eosinophils in the cerebrospinal fluid of mice infected with *Angiostrongylus cantonensis* are resistant to apoptosis. *International Journal for Parasitology* 31:1649-1658, 2001
96. Liew FY: TH1 and TH2 cells: a historical perspective. *Nature Reviews: Immunology* 2:55-60, 2001
97. Lee JD, Wang JJ, Chang JH, et al: Role of T cell subpopulations in mice infected with *Angiostrongylus cantonensis*. *Journal of Helminthology* 70:211-214, 1996
98. Aoki M, Sugaya H, Ishida K, et al: The role of CD4+ and CD8+ T-cells in host morbidity and innate resistance to *Angiostrongylus cantonensis* in the mouse. *Parasitology Research* 84:91-99, 1998

99. Pearce EJ, MacDonald AS: The immunobiology of schistosomiasis. *Nature Reviews: Immunology* 2:499 - 511, 2002
100. Yoshida T, Ikuta K, Sugaya H, et al: Defective B-1 cell development and impaired immunity against *Angiostrongylus cantonensis* in IL-5R alpha-deficient mice. *Immunity* 4:483-494, 1996
101. Sugaya H, Aoki M, Abe T, et al: Cytokine responses in mice infected with *Angiostrongylus cantonensis*. *Parasitology Research* 83:10-15, 1997
102. Greene RT: Coccidioidomycosis, in Greene CE (ed): *Infectious disease of the dog and cat*. (ed 2nd Ed.). Philadelphia, W. B. Saunders, 1998, pp 391 - 398
103. Dorta-Contreras AJ, Reiber H: Intrathecal synthesis of immunoglobulins in eosinophilic meningoencephalitis due to *Angiostrongylus cantonensis*. *Clinical & Diagnostic Laboratory Immunology* 5:452-455, 1998
104. Intapan PM, Maleewong W, Polsan Y, et al: Specific IgG antibody subclasses to *Angiostrongylus cantonensis* in patients with angiostrongyliasis. *Asian Pacific Journal of Allergy & Immunology* 20:235-240, 2002
105. Lan KP, Wang CJ, Lai SC, et al: The efficacy of therapy with albendazole in mice with parasitic meningitis caused by *Angiostrongylus cantonensis*. *Parasitology Research* 93:311-317, 2004
106. Lee H-H, Shioh S-J, Chung H-C, et al: Development of Brain Injury in Mice by *Angiostrongylus cantonensis* Infection Is Associated with the Induction of Transcription Factor NF-[kappa]B, Nuclear Protooncogenes, and Protein Tyrosine Phosphorylation. *Experimental Parasitology* 95:202-208, 2000
107. Hou RF, Tu W, Lee H, et al: Elevation of plasminogen activators in cerebrospinal fluid of mice with eosinophilic meningitis caused by *Angiostrongylus cantonensis*. *International Journal for Parasitology* 34:1355-1364, 2004
108. Winkler F, Kastenbauer S, Koedel U, et al: Role of urokinase plasminogen activator systems in patients with bacterial meningitis. *Neurology* 59:1350 - 1355, 2002

109. Chen C, Huang Y, Yen C: The influence of zinc in mice on infection with *Angiostrongylus cantonensis*. *Parasitology Research* 94:74-81, 2004
110. Chen K, Lee H, Lu K, et al: Association of matrix metalloproteinase-9 and Purkinje cell degeneration in mouse cerebellum caused by *Angiostrongylus cantonensis*. *International Journal for Parasitology* 34:1147-1156, 2004
111. Lee HH, Chou HL, Chen KM, et al: Association of matrix metalloproteinase-9 in eosinophilic meningitis of BALB/c mice caused by *Angiostrongylus cantonensis*. 2004. 2094: 2005, 2321-2328. 2034 ref., 2004
112. Tseng YK, Tu WC, Lee HH, et al: Ultrastructural localization of matrix metalloproteinase-9 in eosinophils from the cerebrospinal fluid of mice with eosinophilic meningitis caused by *Angiostrongylus cantonensis*. *Annals of Tropical Medicine and Parasitology* 98:831-841, 2004
113. Chen KM, Lee HH, Liu JY, et al: Upregulation of MMP-9/TIMP-1 enzymatic system in eosinophilic meningitis caused by *Angiostrongylus cantonensis*. *International Journal of Experimental Pathology* 86:81 - 89, 2005
114. Lai SC, Jiang ST, Chen KM, et al: Efficacy of albendazole-GM6001 co-therapy against *Angiostrongylus cantonensis*-induced meningitis in BALB/c mice. *Acta Tropica* 93:267 - 273, 2005
115. Lai SC, Twu JJ, Jiang ST, et al: Induction of matrix metalloproteinase-9 in murine eosinophilic meningitis caused by *Angiostrongylus cantonensis*. *Annals of Tropical Medicine and Parasitology* 98:715-724, 2004
116. Shih HH, Chen SN: Migratory effects on the body surface of *Angiostrongylus cantonensis* from subarachnoid space to pulmonary artery in rats. *Southeast Asian Journal of Tropical Medicine & Public Health* 21:475-481, 1990
117. Ding BL: Epidemiological survey of the focus of human angiostrongyliasis as first case in mainland China. *Chinese Journal of Epidemiology* 9:261-264, 1988

118. Tsai HC, Liu YC, Kunin CM, et al: Eosinophilic meningitis caused by *Angiostrongylus cantonensis* associated with eating raw snails: correlation of brain magnetic resonance imaging scans with clinical findings. *American Journal of Tropical Medicine & Hygiene* 68:281-285, 2003
119. Wang L, Wan Y: Alteration of antibodies against the fifth-stage larvae and changes in brain magnetic resonance images in experimentally infected rabbits with *Angiostrongylus cantonensis*. *Journal of Parasitology* 90:1193-1196, 2004
120. Podwall D, Gupta R, Furuya EY, et al: *Angiostrongylus cantonensis* meningitis presenting with facial nerve palsy. *Journal of Neurology* 251:1280-1281, 2004
121. Jin E, Ma D, Liang Y, et al: MRI findings of eosinophilic myelomeningoencephalitis due to *Angiostrongylus cantonensis*. 242-250, 2005 Feb., 2005
122. Hsieh T, Liu G-C, Yen C-M, et al: Magnetic resonance imaging findings of eosinophilic meningoencephalitis caused by angiostrongyliasis. *Chinese Journal of Radiology* 26:45 - 49, 2001
123. Prociv P, Tiernan JR: Eosinophilic meningoencephalitis with permanent sequelae. *Medical Journal of Australia* 147:294-295, 1987
124. Ko RC, Chiu MC, Kum W, et al: First report of human angiostrongyliasis in Hong Kong diagnosed by computerized axial topography (CAT) and enzyme linked immunosorbent assay. *Transactions of the Royal Society of Tropical Medicine & Hygiene* 78:354-355, 1984
125. Kanbara T, Ohmomo N, Umemura T, et al: Local antibody production and immune complex formation in rats experimentally infected with *Angiostrongylus cantonensis*. *American Journal of Tropical Medicine & Hygiene* 39:353-360, 1988
126. Kliks MM, Kroenke K, Hardman JM: Eosinophilic radiculomyeloencephalitis: an angiostrongyliasis outbreak in American Samoa related to ingestion of *Achatina fulica* snails. 6, 1114-1122. 1122 ref., 1982

127. Mentz MB, Graeff-Teixeira C: Drug trials for treatment of human angiostrongyliasis.4, 179-184. 155 ref., 2003
128. Roux-Serratrice Cd, Allegre T, Bensaid T, et al: Eosinophilic meningitis on return from Tahiti. Presse Medicale 31, 2002
129. Li D, He A, Wang Y, et al: Three lethal cases of *Angiostrongylus cantonensis* infected children. Chung Kuo Chi Sheng Chung Hsueh Yu Chi Sheng Chung Ping Tsa Chih Chinese Journal of Parasitology & Parasitic Diseases 19:310-311, 2001
130. Weller PF, Liu LX: Eosinophilic meningitis. Seminars in Neurology 13:161-168, 1993
131. Chotmongkol V, Sawanyawisuth K, Thavornpitak Y: Corticosteroid treatment of eosinophilic meningitis. Clinical Infectious Diseases 31:660-662, 2000
132. Lee HH, Terada M: In vitro effects of milbemycin oxime: mechanism of action against *Angiostrongylus cantonensis* and *Dirofilaria immitis*. Parasitology Research 78:349-353, 1992
133. Ishii AI, Terada M, Sano M: Studies on chemotherapy of parasitic helminths. (XXIII). Effects of ivermectin on *Angiostrongylus cantonensis* in rats. Japanese Journal of Parasitology 34:411-417, 1985
134. Terada M, Sano M: Effects of diethylcarbamazine on the motility of *Angiostrongylus cantonensis* and *Dirofilaria immitis*. Zeitschrift fur Parasitenkunde 72:375-385, 1986
135. Kamath VR, Menon S, Bhopale MK, et al: Experimental chemotherapy of *Angiostrongylus cantonensis* infection in mice with flubendazole, lavamizole, and their combination. Folia Parasitologica 34:87 - 92, 1987
136. Lakwo TT, Ishih A, Terada M, et al: Effects of albendazole against larval and adult *Angiostrongylus cantonensis* in rats. Parasitology International 47:281-288, 1998
137. Hwang KP, Chen ER: Larvicidal effect of albendazole against *Angiostrongylus cantonensis* in mice. American Journal of Tropical Medicine & Hygiene 39:191-195, 1988

138. Maki J, Kanda S: Higher sensitivity of the developing larvae of *Angiostrongylus cantonensis* than the adult worms to flubendazole and mebendazole. *Kitasato Archives of Experimental Medicine* 65:131-136, 1992
139. Wang X, Huang H, Dong Q: [A clinical research for eosinophilic meningoencephalitis caused by angiostrongyliasis].326-328, 1999 May., 1999
140. Lin JX, Li YS, Zhu K: Epidemiological study on group infection of *Angiostrongylus cantonensis* in Changle City. *Chinese Journal of Parasitic Disease Control* 21:110 - 112, 2003
141. Stokol T, Randolph JF, Nachbar S, et al: Development of bone marrow toxicosis after albendazole administration in a dog and cat. *Journal of the American Veterinary Medical Association* 210:1753-1756, 1997
142. Yoshimura K, Sugaya H, Ishida K, et al: The effect of cyclosporin A on *Angiostrongylus cantonensis* infection and eosinophilia in mice. *International Journal for Parasitology* 23:997-1003, 1993
143. Lee CZ, Xu B, Hashimoto T, et al: Doxycycline suppresses cerebral matrix metalloproteinase-9 and angiogenesis induced by focal hyperstimulation of vascular endothelial growth factor in a mouse model. *Stroke* 35:1715-1719, 2004
144. Clouston PD, Corbett AJ, Pryor DS, et al: Eosinophilic meningitis: cause of a chronic pain syndrome. *Journal of Neurology, Neurosurgery & Psychiatry* 53:778-781, 1990
145. Crump JA, Chambers ST, Acland RH, et al: Successful management of pain syndrome due to *Angiostrongylus cantonensis* [*Parastrongylus cantonensis*] by implantable spinal cord stimulator. *Australian & New Zealand Journal of Medicine* 29, 1999
146. Caymmi Gomes M: Pathological mechanisms related to autoinfection in a fatal human strongyloidiasis. *Revista de Patologia Tropical* 9:165 - 261, 1980
147. Barrs VR, Swinney GR, Martin P, et al: Concurrent *Aelurostrongylus abstrusus* infection and salmonellosis in a kitten. *Aust Vet J* 77:229 - 232, 1999

148. Yong WK, Dobson C: Immunological regulation of *Angiostrongylus cantonensis* infections in rats: modulation of population density and enhanced parasite growth following one or two superimposed infections. *Journal of Helminthology* 57:155-165, 1983
149. Yong WK, Dobson C: Antibody responses in rats infected with *Angiostrongylus cantonensis* and the passive transfer of protective immunity with immune serum. *Zeitschrift fur Parasitenkunde* 67:329-336, 1982
150. Yong WK, Dobson C: Population dynamics of *Angiostrongylus cantonensis* during primary infections in rats. *Parasitology International* 85:399 - 409, 1982
151. Yong WK, Dobson C: Passive immunity in rats infected with *Angiostrongylus cantonensis*: interactions between syngeneic immune serum and sensitized lymph node cells. *Zeitschrift fur Parasitenkunde* 68:87-92, 1982
152. Yong WK, Glanville RJ, Dobson C: The role of the spleen in protective immunity against *Angiostrongylus cantonensis* in rats: splenectomy and passive spleen cell transfers. *International Journal for Parasitology* 13:165-170, 1983
153. Alicata JE, Brown RW: Preliminary observations on the use of an intradermal test for the diagnosis of eosinophilic meningoencephalitis. *Canadian Journal of Zoology* 40:119 - 124, 1962
154. Kagan IG, Zaiman H: Evaluation of skin-test antigens in a hospital in New York City. *American Journal of Tropical Medicine & Hygiene* 13:82 - 88, 1964
155. Kamiya M, Oku Y, Katakura K, et al: Report on the prevalence and experimental infections of *Angiostrongylus siamensis* Ohbayashi, Kamiya et Bhaibulaya, 1979, parasitic in the mesenteric arteries of rodents in Thailand. *Japanese Journal of Veterinary Research* 28:114-121, 1980
156. Welch JS, Dobson C, Campbell GR: Immunodiagnosis and seroepidemiology of *Angiostrongylus cantonensis* zoonoses in man. *Transactions of the Royal Society of Tropical Medicine & Hygiene* 74:614-623, 1980

157. Welch JS, Dobson C: Immunodiagnosis of parasitic zoonoses: comparative efficacy of three immunofluorescence tests using antigens purified by affinity chromatography. *Transactions of the Royal Society of Tropical Medicine & Hygiene* 72:282-288, 1978
158. Cross JH, Chi JCH: ELISA for the detection of *Angiostrongylus cantonensis* antibodies in patients with eosinophilic meningitis. *Southeast Asian Journal of Tropical Medicine & Public Health* 13:73-76, 1982
159. Welch JS, Dobson C: Immunodiagnosis of parasitic zoonoses: sensitivity and specificity of in vitro lymphocyte proliferative responsiveness using nematode antigens purified by affinity chromatography. *Transactions of the Royal Society of Tropical Medicine & Hygiene* 75:5-14, 1981
160. Lappin MR: ELISA Tests: Methods and Interpretation, in Bonagura JD (ed): *Kirk's Current Veterinary Therapy XIII Small Animal Practice*. Philadelphia, W. B. Saunders, 2000, pp 8 - 11
161. Cross JH: Clinical manifestations and laboratory diagnosis of eosinophilic meningitis syndrome associated with angiostrongyliasis. *Southeast Asian Journal of Tropical Medicine & Public Health* 9:161-170, 1978
162. Chen SN: Enzyme-linked immunosorbent assay (ELISA) for the detection of antibodies to *Angiostrongylus cantonensis*. *Transactions of the Royal Society of Tropical Medicine & Hygiene* 80:398-405, 1986
163. Chang JH, Yen CM, Chen ER, et al: Detection of antibodies to surface antigens of *Angiostrongylus cantonensis* by ELISA. *Annals of Tropical Medicine & Parasitology* 89:569-572, 1995
164. Dharmkrong-At A, Sirisinha S: Analysis of antigens from different developmental stages of *Angiostrongylus cantonensis*. *Southeast Asian Journal of Tropical Medicine & Public Health* 14:154-162, 1983

165. Intapan PM, Maleewong W, Sawanyawisuth K, et al: Evaluation of human IgG subclass antibodies in the serodiagnosis of angiostrongyliasis. *Parasitol Res* 89:425-429, 2003
166. Kum WWS, Ko RC: Isolation of specific antigens from *Angiostrongylus cantonensis* by a combination of preparative isoelectric focusing and affinity chromatography. *Tropical Biomedicine* 3:55-60, 1986
167. Chye S, Chang J, Yen C: Immunodiagnosis of human eosinophilic meningitis using an antigen of *Angiostrongylus cantonensis* L5 with molecular weight 204 kD. *Acta Tropica* 75:9-17, 2000
168. Maleewong W, Sombatsawat P, Intapan PM, et al: Immunoblot evaluation of the specificity of the 29-kDa antigen from young adult female worms *Angiostrongylus cantonensis* for immunodiagnosis of human Angiostrongyliasis. *Asian Pacific Journal of Allergy & Immunology* 19:267-273, 2001
169. Eamsobhana P, Yoolek A, Suvouttho S: Purification of a specific immunodiagnostic *Parastrongylus cantonensis* antigen by electroelution from SDS-polyacrylamide gels. *Southeast Asian Journal of Tropical Medicine & Public Health* 32:308-313, 2001
170. Yen CM, Chen ER, Kojima S, et al: Preparation of monoclonal antibody against *Angiostrongylus cantonensis* antigen. *Southeast Asian Journal of Tropical Medicine & Public Health* 20:119-124, 1989
171. Nuamtanong S: The evaluation of the 29 and 31 kDa antigens in female *Angiostrongylus cantonensis* for serodiagnosis of human angiostrongyliasis. *Southeast Asian Journal of Tropical Medicine & Public Health* 27:291-296, 1996
172. Eamsobhana P, Yoolek A, Kreethapon N: Blinded multi-laboratory evaluation of an in-house dot-blot ELISA kit for diagnosis of human parastrongyliasis. 1-6, 2003 March., 2003
173. Eamsobhana P, Yoolek A, Punthuprapasa P: Dot-blot ELISA for the immunological detection of specific antibody to *Parastrongylus cantonensis*. 1, 1-6. 18 ref., 2003

174. Eamsobhana P, Yoolek A, Punthuprapasa P, et al: A dot-blot ELISA comparable to immunoblot for the specific diagnosis of human parastrongyliasis. *Journal of Helminthology* 78:287-291, 2004
175. Eamsobhana P, Dekumyoy P, Waikagul C: Shared antigens between *Parastrongylus cantonensis* and *Biomphalaria glabrata* and their possible use in immunodiagnosis of human parastrongyliasis.2, 7-13. 23 ref., 1999
176. Chye SM, Lin SR, Chen YL, et al: Immuno-PCR for detection of antigen to *Angiostrongylus cantonensis* circulating fifth-stage worms.51-57, 2004 January., 2004
177. Chang JH, Yen CM, Chen ER: Characterization of monoclonal antibodies to young-adult worms of *Angiostrongylus cantonensis*. *Hybridoma* 9:465-471, 1990
178. Shih HH, Chen SN: Immunodiagnosis of angiostrongyliasis with monoclonal antibodies recognizing a circulating antigen of mol.wt 91,000 from *Angiostrongylus cantonensis*. *International Journal for Parasitology* 21:171-177, 1991
179. Eamsobhana P, Mak JW, Yong HS: Detection of circulating antigens of *Parastrongylus cantonensis* in human sera by sandwich ELISA with specific monoclonal antibody. *Southeast Asian Journal of Tropical Medicine & Public Health* 26:712-715, 1995
180. Chye S, Yen C, Chen E: Detection of circulating antigen by monoclonal antibodies for immunodiagnosis of angiostrongyliasis. *American Journal of Tropical Medicine & Hygiene* 56:408-412, 1997
181. Eamsobhana P, Yong HS, Mak JW, et al: Detection of circulating antigens of *Parastrongylus cantonensis* in human sera by dot-blot ELISA and sandwich ELISA using monoclonal antibody. *Southeast Asian Journal of Tropical Medicine & Public Health* 28:624-628, 1997
182. Dharmkrong-at A, Uahkowitzchai V, Sirisinha S: The humoral and cell-mediated immune responses to somatic and metabolic antigens in rats infected with *Angiostrongylus cantonensis*. *Southeast Asian Journal of Tropical Medicine & Public Health* 9:330-337, 1978

183. Chang C, Chao D: Time-course changes in antibody responses to different stages of *Angiostrongylus cantonensis* in experimentally infected rats. *Zoological Studies* 35:62-67, 1996
184. Hughes AJ, Biggs BA: Parasitic worms of the central nervous system: an Australian perspective. *Internal Medicine Journal* 32:541-553, 2002
185. Yen CM, Chen ER: Detection of antibodies to *Angiostrongylus cantonensis* in serum and cerebrospinal fluid of patients with eosinophilic meningitis. *International Journal for Parasitology* 21:17-21, 1991
186. Dubey JP, Carpenter JL, Speer CA, et al: Newly recognized fatal protozoan disease of dogs. *Journal of the American Veterinary Medical Association* 192:1269-1285, 1988
187. Dubey JP, Barr BC, Barta JR, et al: Redescription of *Neospora caninum* and its differentiation from related coccidia. *International Journal for Parasitology* 32:929-946, 2002
188. Buxton D, McAllister MM, Dubey JP: The comparative pathogenesis of neosporosis. 12, 546-552. 567 ref., 2002
189. Dubey JP: Recent advances in *Neospora* and neosporosis. *Veterinary Parasitology* 84:349-367, 1999
190. Dubey JP, Lappin MR: Toxoplasmosis and Neosporosis, in Greene CE (ed): *Infectious diseases of the Dog and Cat* (ed 2nd Ed.). Philadelphia, W. B. Saunders, 1998, pp 493 - 511
191. McAllister MM, Dubey JP, Lindsay DS, et al: Dogs are definitive hosts of *Neospora caninum*. *International Journal for Parasitology* 28:1473-1478, 1998
192. Lindsay DS, Dubey JP, Duncan RB: Confirmation that the dog is a definitive host for *Neospora caninum*. *Veterinary Parasitology* 82:327-333, 1999
193. McGarry JW, Stockton CM, Williams DJ, et al: Protracted shedding of oocysts of *Neospora caninum* by a naturally infected foxhound. *Journal of Parasitology* 89:628 - 630, 2003

194. Kramer L, De Risio L, Tranquillo VM, et al: Analysis of risk factors associated with seropositivity to *Neospora caninum* in dogs. *Vet Rec* 154:692-693, 2004
195. Schatzberg SJ, Haley NJ, Barr SC, et al: Use of a multiplex polymerase chain reaction assay in the antemortem diagnosis of toxoplasmosis and neosporosis in the central nervous system of cats and dogs. *American Journal of Veterinary Research* 64:1507 - 1513, 2003
196. Nishikawa Y, Ikeda H, Fukumoto S, et al: Immunisation of dogs with a canine herpesvirus vector expressing *Neospora caninum* surface protein, NcSRS2. *International Journal for Parasitology* 30:1167-1171, 2000
197. Woods CR, Englund J: Congenital toxoplasmosis presenting with eosinophilic meningitis. *Pediatric Infectious Disease Journal* 12:347-348, 1993
198. Patitucci AN, Alley MR, Jones BR, et al: Protozoal encephalomyelitis in dogs involving *Neospora caninum* and *Toxoplasma gondii* in New Zealand. *New Zealand Veterinary Journal* 45:231 - 235, 1997
199. Suja MS, Mahadevan A, Madhusudana SN, et al: Cerebral cysticercosis mimicking rabies in a dog. *10*, 304-305. 306 ref., 2003
200. Matsumoto J, Muth S, Socheat D, et al: The first reported cases of canine schistosomiasis mekongi in Cambodia. *3*, 458-461. 414 ref., 2002
201. Fradkin JM, Braniecki AM, Craig TM, et al: Elevated parathyroid hormone-related protein and hypercalcaemia in two dogs with Schistosomiasis. *Journal of the American Animal Hospital Association* 37:349 - 355, 2001
202. Coman BJ, Jones EH, Driesen MA: Helminth parasites and arthropods of feral cats. *7*, 324-327. 318 ref., 1981
203. Jaronvesama N: Differential diagnosis of eosinophilic meningitis. *Parasitology Today* 4:262-266, 1988

204. Smith-Maxie LL, Parent JP, Rand J, et al: Cerebrospinal fluid analysis and clinical outcome of eight dogs with eosinophilic meningoencephalomyelitis. *Journal of Veterinary Internal Medicine* 3:167-174, 1989
205. Bennett PF, Allan FJ, Guilford WG, et al: Idiopathic eosinophilic meningoencephalitis in Rottweiler dogs: three cases (1992-1997). *Australian Veterinary Journal* 75:786-789, 1997
206. Perkins MC, Watson ADJ: Successful treatment of hypereosinophilic syndrome in a dog. *Australian Veterinary Journal* 79:686 - 689, 2001
207. Sykes JE, Weiss DJ, Buoen LC, et al: Idiopathic hypereosinophilic syndrome in 3 Rottweilers. *Journal of Veterinary Internal Medicine* 15:162 - 166, 2001
208. Ragland AS, Arsura E, Ismail Y, et al: Eosinophilic pleocytosis in coccidiodal meningitis: frequency and significance. *American Journal of Medicine* 95:254 - 257, 1993
209. Jacobs GJ, Medleau L: Cryptococcosis, in Greene CE (ed): *Infectious diseases of the dog and cat*. (ed 2nd Ed.). Philadelphia, W. B. Saunders, 1998, pp 383 - 390
210. Day MJ: Canine disseminated aspergillosis, in Greene CE (ed): *Infectious diseases of the dog and cat* (ed 2nd Ed.). Philadelphia, W. B. Saunders, 1998, pp 409 - 413
211. Greene CE, Gunn-Morre DA: Mycobacterial infections, in Greene CE (ed): *Infectious disease of the dog and cat* (ed 2nd Ed.). Philadelphia, W.B. Saunders, 1998, pp 313 - 325
212. Castro AG, Esaguy N, Macedo PM, et al: Live but not heat-killed mycobacteria cause rapid chemotaxis of large numbers of eosinophils in vivo and are ingested by the attracted granulocytes. *Infect Immun* 59:3009-3014, 1991
213. Schifferli C, Savio R: Eosinophilic meningoencephalitis in swine [salt poisoning]. *Archivos de Medicina Veterinaria, Chile* 13:44-47, 1981
214. Smaller J: Serological diagnosis of neural angiostrongylia in macropods and dogs, in Faculty of Veterinary Science. Sydney, University of Sydney, 2004, p 97

215. Kyhse-Anderson J: Electroblothing of multiple gels: a simple apparatus without buffer tank for rapid transfer of proteins from polyacrylamide to nitrocellulose. *Journal of Biochemical and Biophysical Methods* 10:203 - 209, 1984
216. Eamsobhana P, Dechkum N: Recognition of a 31-kDa diagnostic antigen from excretory/secretory products of adult *Parastrongylus cantonensis* by infected human sera.2, 103-108. 119 ref., 2000
217. Alto W: Human infections with *Angiostrongylus cantonensis*. *Pac Health Dialog* 8:176-182, 2001
218. Shih SL, Hsu CH, Huang FY, et al: *Angiostrongylus cantonensis* infection in infants and young children. *Pediatric Infectious Disease Journal* 11:1064-1066, 1992
219. Sato Y, Otsuru M: Studies on eosinophilic meningitis and meningoencephalitis caused by *Angiostrongylus cantonensis* in Japan. *Southeast Asian Journal of Tropical Medicine & Public Health* 14:515-524, 1983
220. Sato Y, Takai A, Watanabe H, et al: Circulating immune complexes in rats infected with *Angiostrongylus cantonensis* - a relation between immune complexes and worm burden. *Japanese Journal of Parasitology* 29:257-265, 1980
221. Ash LR: Observations on the role of mollusks and planarians in the transmission of *Angiostrongylus cantonensis* infection to man in New Caledonia.1, 163-174., 1976
222. Yii CY: Clinical observations on eosinophilic meningitis and eosinophilic meningoencephalitis caused by *Angiostrongylus cantonensis* on Taiwan. *American Journal of Tropical Medicine & Hygiene* 25:233 - 249, 1976
223. Tsai H, Liu Y, Kunin CM, et al: Eosinophilic meningitis caused by *Angiostrongylus cantonensis*: report of 17 cases. *American Journal of Medicine* 111:109-114, 2001
224. Kliks MM, Lau WKK, Palumbo NE: Neurologic angiostrongyliasis: parasitic eosinophilic meningoencephalitis.1988. 1754-1767. 1953 ref., 1988

225. Wang LC, Jung SM, Chen CC, et al: Pathological changes in the brains of rabbits experimentally infected with *Angiostrongylus cantonensis* after albendazole treatment: histopathological and magnetic resonance imaging studies, in *Journal of Antimicrobial Chemotherapy*. 57(2):294-300 2006 Feb., 2006
226. Wang L, Wan DP, Jung S, et al: Magnetic resonance imaging findings in the brains of rabbits infected with *Angiostrongylus cantonensis*: a long-term investigation. *Journal of Parasitology* 91:1237-1239, 2005
227. Chau TTH, Thwaites GE, Chuong LV, et al: Headache and confusion: the dangers of a raw snail supper. 9372, 1866. 9374 ref., 2003
228. Lim J, Lee C, Wilder-Smith A: Eosinophilic meningitis caused by *Angiostrongylus cantonensis*: a case report and literature review. 2004. 2011: 2006, 2388-2390. 2022 ref., 2004
229. Hughes PA, Magnet AD, Fishbain JT: Eosinophilic meningitis: a case series report and review of the literature. 2003. 2168: 2010, 2817-2821. 2038 ref., 2003
230. Costa JO, Lima WS, Nascimento E: Immunodiagnosis by ELISA of experimental angiostrongylosis in dogs. *Arquivo Brasileiro de Medicina Veterinaria e Zootecnia* 48:491-495, 1996
231. Buck AA, Anderson RI, MacRae AA: Epidemiology of poly-parasitism. III. Effects on the diagnostic capacity of immunological tests. *Tropenmedizin und Parasitologie* 29:145-155, 1978
232. Suzuki T, Liu KH, Chen SN, et al: Epidemiological observations on angiostrongyliasis in Taiwan. 1. Results of indirect hemagglutination test for angiostrongyliasis among suspected Japanese encephalitis cases. *Japanese Journal of Parasitology* 22:187-192, 1973
233. Anderson RI, Sadun EH, Rosen L, et al: The detection of antibodies in eosinophilic meningitis. *Journal of Parasitology* 48:15 - 16, 1962

234. Bouthemy F, Capron A, Afchain D, et al: Antigenic structure of the nematode *Angiostrongylus cantonensis*. Immunologic aspects of host-parasite relations. *Ann Parasitol Hum Comp* 47:531 - 550, 1972
235. Boffetta P: Sources of bias, effects of cofounding in the application of biomarkers to epidemiological studies. *Toxicology Letters* 77:235 - 238, 1995
236. Stockham SL, Scott MA: *Fundamentals of Veterinary Clinical Pathology* (ed 1st). Ames, Iowa, Blackwell Publishing Company, 2002, p 610
237. Robson H: Bone growth mechanisms and the effects of cytotoxic drugs. *Archives of Disease of Children* 81:360 - 364, 1999
238. Hall LW, Clarke KW: Principles of Sedation, Analgesia and Premedication, in Hall LW (ed): *Veterinary Anaesthesia* (ed 9th). London, Bailliere Tindall, 1991, pp 51 - 79
239. Steffan J, Strehlau G, Maurer M, et al: Cyclosporin A pharmacokinetics and efficacy in the treatment of atopic dermatitis in dogs. *Journal of Veterinary Pharmacology and Therapeutics* 27:231-238, 2004
240. Bessarab IN, Joshua GWP: Stage-specific gene expression in *Angiostrongylus cantonensis*: characterisation and expression of an adult-specific gene. *Molecular & Biochemical Parasitology* 88:73-84, 1997
241. Joshua GWP, Hsieh CY: Stage-specifically expressed genes of *Angiostrongylus cantonensis*: identification by differential display. *Molecular & Biochemical Parasitology* 71:285-289, 1995
242. Kuberski T, Wallace GD: Clinical manifestations of eosinophilic meningitis due to *Angiostrongylus cantonensis*. *Neurology* 29:1566-1570, 1979
243. Paine M, Davis S, Brown G: Severe forms of infection with *Angiostrongylus cantonensis* acquired in Australia and Fiji. *Australian & New Zealand Journal of Medicine* 24:415-416, 1994

244. Patikulsila D, Ittipunkul N, Theerakittikul B: Intravitreal angiostrongyliasis: report of 2 cases. *Journal of the Medical Association of Thailand* 86:981-985, 2003
245. Toma H, Matsumura S, Oshiro C, et al: Ocular angiostrongyliasis without meningitis symptoms in Okinawa, Japan. *Journal of Parasitology* 88:211-213, 2002
246. Rosen L, Loison G, Laigret J, et al: Studies on eosinophilic meningitis. 3. Epidemiologic and clinical observations on Pacific islands and the possible etiologic role of *Angiostrongylus cantonensis*. *American Journal of Epidemiology* 85:17 - 44, 1967
247. Fuller AJ, Munckhof W, Kiers L, et al: Eosinophilic meningitis due to *Angiostrongylus cantonensis*. *Western Journal of Medicine* 159:78-80, 1993
248. Chotmongkol V, Yimtae K, Intapan PM: *Angiostrongylus* eosinophilic meningitis associated with sensorineural hearing loss. *Journal of Laryngology & Otology* 118:57-58, 2004
249. Purohit AK, Dinakar I, Sundaram C, et al: *Angiostrongylus cantonensis* abscess in the brain. *Annals of Neurology, Neurosurgery and Psychiatry* 54:1015 - 1016, 1991
250. Barnes J: Wildlife List Disease, in Duignan P (ed): *Wildlife Disease Association Newletter*. Sydney, Taronga Zoo, 2004, pp 9 - 10
251. Costa LRR, McClure JJ, Snider TG, III, et al: Verminous meningoencephalomyelitis by *Angiostrongylus (=Parastrostrongylus) cantonensis* in an American Miniature horse. *Equine Veterinary Education* 12:2-6, 2000
252. Lowry OH, Rosebroough NJ, Farr AL, et al: Protein measurement with the folin phenol reagent. *Journal of Biological Chemistry* 93:265 - 275, 1951
253. Komissarenko SV, Avrameas S: [Properties of immunoadsorbents prepared by antigen coupling to glutaraldehydeactivated polyacrylamide gel, BrCN-activated Sepharose and by copolymerization of antigens by glutaraldehyde].500-511, 1978 Jul-Aug.,