

$\text{I}\kappa\beta\alpha$

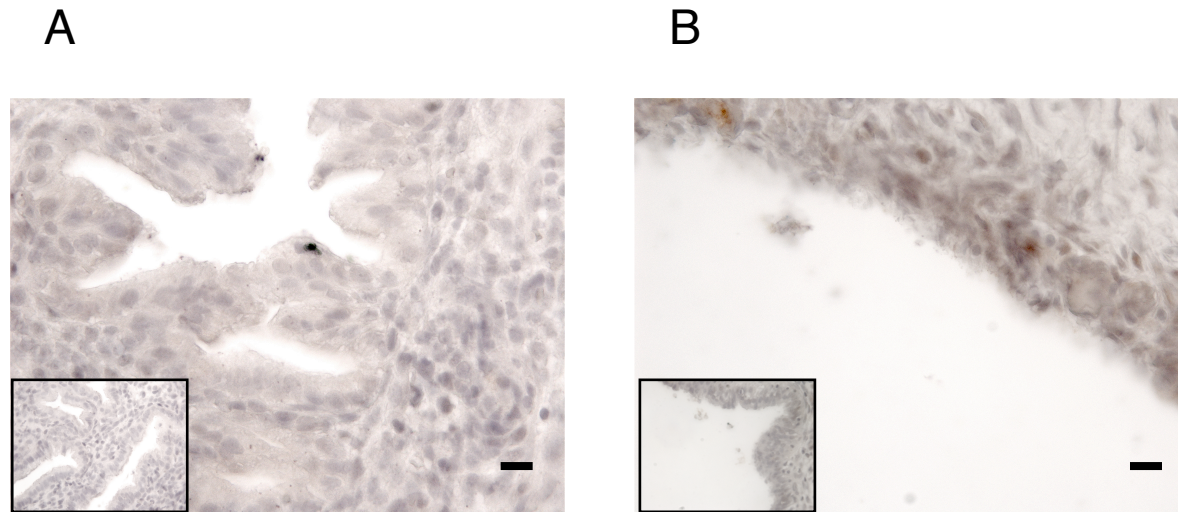


Figure 8.8: Immunohistochemical staining of human endometrial sections with $\text{I}\kappa\beta\alpha$. Secretory *Eutopic endometrium* (A) and *Ectopic endometrium* (B). Inset box = Negative control. Magnification $\times 400$ and bar = 20 μm .